

# Flashes, floaters, and retinal detachment

W W Lai 賴維均, D S C Lam 林順潮

## Summary

*Patients presenting to the family physician and ophthalmologist often have complaints of flashes and floaters. These symptoms may be benign or they may be associated with serious conditions such as a retinal tear or retinal detachment. Recognizing the importance of these symptoms would allow prompt referral to the ophthalmologist for a detailed ocular examination. Today, more than 95% of retinal detachments can be successfully treated, although more than one procedure may be required. Prevention or early diagnosis is important because the rate of successful repair is higher and the visual results are better if the retinal detachment spares the macula, the part of the retina responsible for fine, central vision. Through successful treatment, patients will be able to enjoy a better quality of life and maintain their abilities to read, work, drive, and care for themselves.*

## 摘要

病人常向家庭醫生和眼科醫生主訴眼睛有閃光或有黑影飄動。這些症狀可能是良性的，也可能與一些嚴重疾病有關，如視網膜裂孔或脫落。醫生認識到重要性，就可以迅速轉介醫生進行詳細眼科檢查。如今，通過一次或數次手術，95%以上的視網膜脫落可以成功治療。預防或早期診斷十分重要，因為這樣視網膜脫落今後的成功率更高，若黃斑區即負責精細和中央視覺的視網膜未被波及，視力也會更好。經過成功的治療，病人可以有更好的生活質量，也能保持閱讀、工作、駕駛以及照顧他人的能力。

HK Pract 2004;26:436-439

W W Lai, MD  
Associate Professor,  
D S C Lam, FRCS  
Chairman,

Department of Ophthalmology and Visual Sciences, The Chinese University of Hong Kong.

Correspondence to: Dr W W Lai, Department of Ophthalmology and Visual Sciences, The Chinese University of Hong Kong, 3/F, University Eye Center, The Hong Kong Eye Hospital, 147K Argyle Street, Kowloon, Hong Kong.

## Introduction

It is not uncommon for family physicians and ophthalmologists to hear patients complaining of flashes and floaters. A number of benign as well as pathological conditions may produce these symptoms. Herein, we will provide a review of these conditions so that patients with symptoms associated with pathological conditions may be referred promptly to the ophthalmologist for evaluation and treatment.

## Anatomy

The anatomy of the eye is much akin to that of a camera. Light rays that enter the eye are focused by the cornea and the lens and an image is formed on the retina. Between the crystalline lens and the retina is the vitreous, a jelly-like substance composed predominantly of water. Its integrity is maintained by collagen fibrils and hyaluronic acid polymers. The vitreous is firmly attached to the retina at several sites. Separation of the vitreous from the retina, or posterior vitreous detachment, is the most common event that leads to a retinal tear and retinal detachment.

## Flashes

Flashes, or "photopsia", are entoptic phenomenon: sensation of light that is not due to stimulation by light. Flashes may be the result of the vitreous pulling on the retina. Since the photoreceptor cells in the retina are not capable of perceiving pressure, pain, or temperature, the retina responds to the stimulus by sending a signal to the brain in the form of disorganized light. The latter is perceived by the brain as a flash. Flashes may be more noticeable in a dark room and during eye movements.

Flashes may also be the result of migraine headaches.<sup>1</sup> Patients with the condition may experience flashes of light in the form of jagged lines, or "zigzags" (scintillations), in the centre of their field of vision, before

the throbbing headache develops. Within the lines, there may be visual field defects or "scotoma". These shimmering lights may last for about 15 minutes. Acephalgic or ocular migraine is the experience of the visual aura of classic migraine but without the subsequent headache. These patients may or may not have a history of migraine headache. The condition is benign.

## Floater

Floater can range from being merely annoying to visually disturbing. They are best perceived when one looks at a bright background, such as a diffusely illuminated wall or the blue sky. Floaters may appear as black lines, specks, or cobwebs. They have been referred to as "muscae volitantes", or "moving flies", as they may move when the eye moves.

A number of conditions can result in symptoms of floaters:

### 1. Vitreous syneresis

With ageing, the vitreous may undergo liquefaction or "syneresis". The collagen fibers in the vitreous coalesce and form pockets of fluid within the vitreous. These aggregated collagen fibrils and other debris are often noted by the patient as floaters.

A number of ocular conditions may also result in or exacerbate vitreous syneresis.

#### i. Myopia:

As the eye becomes more near-sighted, or myopic, the concentration of collagen and hyaluronic acid decreases, increasing the chance of vitreous syneresis.

#### ii. Previous intraocular surgery:

Previous eye surgery, especially cataract surgery, causes a decrease in the amount of hyaluronic acid in the vitreous.

#### iii. Ocular trauma with haemorrhage:

Liquefaction of the vitreous occurs in areas of haemorrhage due to depolymerization of the hyaluronic acid by by-products of red blood cells, namely iron and haemosiderin.

### 2. Posterior vitreous detachment

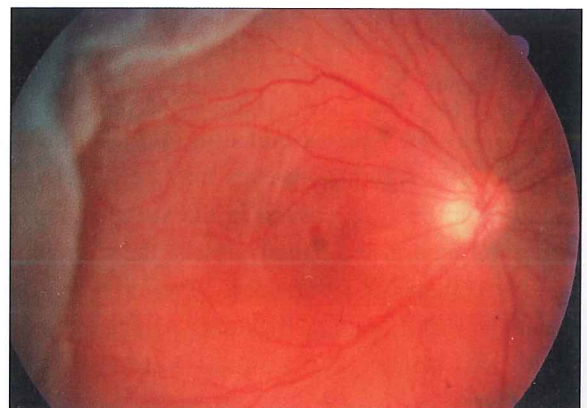
With increase vitreous syneresis, pockets or lacunae form within the vitreous gel. When enough of the lacunae accumulate, the gel collapses and the vitreous separates from the retina, a condition known as posterior vitreous detachment (PVD). The collapse of the vitreous may result in traction to the retina, and the patient may experience the sensation of flashing light. Glial tissue surrounding the optic nerve margin may be avulsed and appears as a large vitreous floater or a Weiss ring. The prevalence of PVD increases with age.<sup>2</sup>

Patients who develop PVD are at an increased risk of retinal detachments (RD)<sup>3-7</sup> (**Figure 1**). Acute PVD is the cause of many retinal tears, which in turn, can result in RD. About 15% of patients with symptoms of flashes and floaters during an acute episode of PVD have a retinal tear.<sup>5,8-9</sup> If there is no retinal break noted on examination, a patient with acute PVD has a 2% to 5% chance of developing them in the ensuing weeks.<sup>6,10</sup> If there is an associated vitreous haemorrhage, the risk of having at least one retinal tear increases to 67%.

### 3. Retinal tear and retinal detachment

When the retina is torn, most often due to an acute PVD, the torn tissue along with pigmented cells, red blood cells, or aggregated collagen fibrils may be liberated into the vitreous, causing the patient to develop the sensation of floaters.

**Figure 1:** Fundus photo of the right eye. A giant retinal tear is noted in the temporal part of the retina with detachment of the retina involving the macula



### 4. Vitreous haemorrhage

Vitreous floaters may develop due to vitreous haemorrhage. Vitreous haemorrhage may develop spontaneously or as a result of trauma. The most frequent causes of spontaneous vitreous haemorrhage include proliferative diabetic retinopathy, retinal breaks with or without retinal detachment, posterior vitreous detachment, and retinal neovascularization due to retinal venous occlusion.

### 5. Inflammation

A variety of conditions may result in invasion of the vitreous by inflammatory cells. Infections, both exogenous and endogenous, and inflammation such as uveitis, may result in symptoms of floaters.

### 6. Remnants of the hyaloid artery

The hyaloid vascular system, which develops during embryonic life, richly nourishes the inside of the eye including the vitreous and lens. These vessels usually have undergone complete reabsorption by birth. Occasionally, remnants of the hyaloid system may be present and the patient may experience the symptoms of floaters.

### 7. Asteroid hyalosis

This benign and degenerative condition of the vitreous consists of refractive, white opacities composed of calcium soaps that aggregate in the otherwise normal vitreous. Vision is rarely affected although floaters may be perceived by the patient. The condition is found more often in older patients and is usually monocular.

### 8. Amyloidosis

This is a rare, autosomal dominantly inherited condition in which both eyes may be affected. In addition to being deposited in the vitreous, amyloid may be found in the retinal vessels, the choroid, and in the trabecular meshwork. Patients may have systemic manifestations including polyneuropathy of the extremities and central nervous system disorders.

## Flashes, floaters, posterior vitreous detachment, and retinal detachment

Flashes are likely to disappear over a few days or weeks, unless they are associated with a retinal detachment. Most floaters are benign, especially those that one has had for a number of years. They tend to last longer than flashes. However, the brain may learn to ignore the floaters over time, or they may get better on their own.

It is the sudden onset or increase in number of floaters often accompanied by flashes that may be serious. These symptoms suggest a retinal tear or a RD. Patients may also complain of loss of part of their field of vision or a curtain blocking their vision. These patients should be referred to an ophthalmologist as soon as possible for evaluation. During the consultation, the ophthalmologist will obtain a detailed medical history to determine the onset and duration of the flashes, if the floaters are old or new, and if there is associated loss of part or all of the patient's vision. Other information including a history of diabetes mellitus or hypertension, intraocular surgery, and trauma should also be sought. A detailed eye examination including dilated fundus examination with scleral depression should be performed to rule out any retinal tears or detachment, or other pathology.

## Treatment of retinal breaks and detachment

It is beyond the scope of the article to detail the surgical procedures employed in the treatment of retinal detachment. In brief, retinal tear without an associated RD may be treated by either laser photocoagulation or cryotherapy around the tear. The goal is to cause chorioretinal adhesion around the tear to prevent the retina from detaching beyond the tear. Various surgical techniques including scleral buckling, pars plana vitrectomy, and pneumatic retinopexy are available today for repairing an RD.

Recognizing the symptoms associated with a retinal tear and RD allows prompt referral to the ophthalmologist. Today, more than 95% of RDs can be successfully treated,<sup>11</sup> although more than one procedure may be required. Prevention or early diagnosis is important because the rate of successful repair is higher and the visual results are better if the RD spares the macula, the part of the retina responsible for our fine, central vision.<sup>8,12</sup> Through successful treatment, patients

**Key messages**

1. Retinal detachment may lead to permanent loss of vision and blindness. Recognizing the symptoms and signs of retinal detachment is critical to its diagnosis and treatment.
2. Flashes and floaters may be associated with a number of ocular conditions, including retinal tear and detachment. An understanding of these conditions will assist the physician to make the necessary referral to an ophthalmologist for evaluation and treatment.

will be able to enjoy a better quality of life and maintain their abilities to read, work, drive and care for themselves.<sup>9</sup>

**Conclusion**

In summary, patients who present to the family practitioner with symptoms of flashes and floaters should be promptly evaluated. A detailed medical history including the onset and duration of the flashes and floaters should be sought. The amount of floaters should also be determined. The patient should be asked if any part of their field of vision was lost. The patient's visual acuity and confrontation visual field should be obtained and performed. Dilated fundus examination should be carried out if the necessary instrumentations are available. If the flashes or floaters have subsided or if the floaters have not increased in amount, along with an apparently normal eye examination, the patient should be asked to consult an ophthalmologist for a routine evaluation. These patients should also be warned of the symptoms of a retinal tear and detachment and instructed to seek

ophthalmologic help immediately should these symptoms develop.

However, if the flashes had been constant or increasing in frequency, the patient had experienced a sudden and a large amount of floaters, and/or the examination revealed abnormal findings, including decrease in vision or loss of part of their visual field, the patient should be immediately referred to an ophthalmologist for evaluation to rule out a retinal tear or detachment. ■

**References**

1. Arunagiri G, Santhi S. Migraine: an ophthalmologist's perspective. *Curr Opin Ophthalmol* 2003;14:344-352.
2. Heller MD, Straatsma BR, Foos RY. Detachment of the posterior vitreous in phakic and aphakic eyes. *Mod Prob Ophthalmol* 1972;10:23-36.
3. Boldrey EE. Risk of retinal tears in patients with vitreous floaters. *Am J Ophthalmol* 1983;96:783-787.
4. Brod RD, Lightman DA, Packer AJ, et al. Correlation between vitreous pigment granules and retinal breaks in eyes with acute posterior vitreous detachment. *Ophthalmology* 1991;98:1366-1369.
5. Tasman WS. Posterior vitreous detachment and peripheral retinal breaks. *Trans Am Acad Ophthalmol Otolaryngol* 1968;72:217-224.
6. Dayan MR, Jayamanne DG, Andrews RM, et al. Flashes and floaters as predictors of vitreoretinal pathology: is follow-up necessary for posterior vitreous detachment? *Eye* 1996;10:456-458.
7. Byer NE. Natural history of posterior vitreous detachment with early management as the premier line of defense against retinal detachment. *Ophthalmology* 1994;101:1503-1514.
8. Tani P, Robertson DM, Langworthy A. Rhegmatogenous retinal detachment without macular involvement treated with scleral buckling. *Am J Ophthalmol* 1980;90:503-508.
9. Scott IU, Smiddy WE, Merikansky A, et al. Vitreoretinal surgery outcomes. Impact on bilateral visual function. *Ophthalmology* 1997;104:1041-1048.
10. van Overdam KA, Bettink-Remeijer MW, Mulder PG, et al. Symptoms predictive for the later development of retinal breaks. *Arch Ophthalmol* 2001; 119:1483-1486.
11. American Academy of Ophthalmology. Posterior Vitreous detachment, retinal breaks, and lattice degeneration. *Preferred Practice Patterns* 2003.
12. Benson WE, Grand MG, Okun E. Aphakic retinal detachment. Management of the fellow eye. *Arch Ophthalmol* 1975;93:245-249.

# REVERSAL

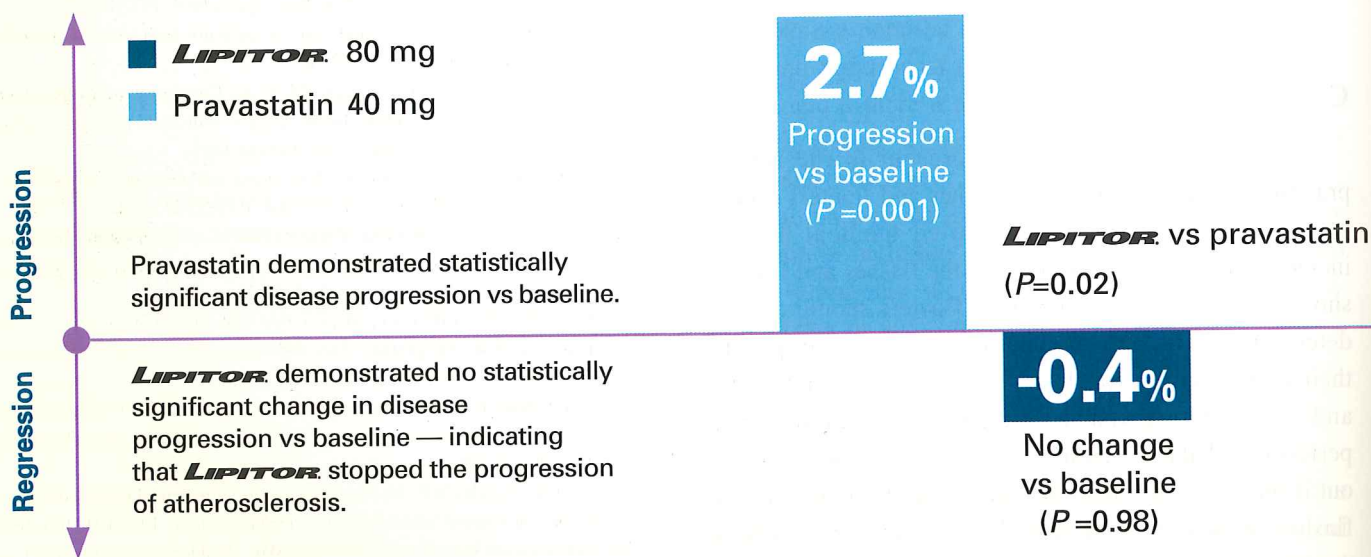
"Reversal of Atherosclerosis  
with Aggressive Lipid  
Lowering"

**NEW  
DATA**

**The first large-scale trial comparing the effect of intensive versus moderate lipid-lowering therapy on progression of coronary atherosclerosis<sup>1</sup>**

**The power of therapy with *LIPITOR* 80 mg to stop the progression of atherosclerosis**

**• *LIPITOR* 80 mg significantly impacted atheroma volume<sup>1</sup>**



A randomized, double-blind, active-control, multicenter, 18-month trial comparing the effects of atorvastatin 80 mg and pravastatin 40 mg in 502 patients with known CHD. IVUS was used to measure progression of atherosclerosis, and was performed at baseline and after 18 months of treatment.

- These findings from REVERSAL provide strong evidence that intensive treatment using atorvastatin 80 mg stops progression of atherosclerosis compared with a more moderate regimen<sup>1</sup>

**References:** 1. Nissen SE, Tuzcu EM, Schoenhagen P, et al, for the REVERSAL Investigators. Effect of intensive compared with moderate lipid-lowering therapy on progression of coronary atherosclerosis: a randomized controlled trial. *JAMA*. 2004;291:1071-1080. **Detailed prescribing information available upon request.**



Pfizer Corporation Hong Kong Limited

16/F, Stanhope House, 738 King's Road, North Point, Hong Kong  
Tel: (852) 2811 9711 Fax: (852) 2579 0599  
Website: [www.pfizer.com.hk](http://www.pfizer.com.hk)



**LIPITOR**  
atorvastatin calcium  
tablets

**power you can trust™**

For stopping the progression of atherosclerosis