

Associations between isolated bundle tear of anterior cruciate ligament, time from injury to surgery, and clinical tests

August Wai-Ming Fok, WP Yau

Division of Sports and Arthroscopic Surgery, Department of Orthopaedics and Traumatology, Queen Mary Hospital, The University of Hong Kong, Hong Kong

ABSTRACT

Purpose. To evaluate the associations between isolated anteromedial (AM) or posterolateral (PL) bundle tear of the anterior cruciate ligament (ACL), the time from injury to surgery, and various clinical tests.

Methods. 36 women and 189 men aged 16 to 52 (mean, 26.4) years underwent ACL reconstruction of the right (n=107) and left (n=118) knees. Patients were evaluated for the International Knee Documentation Committee Subjective Knee Score, Cincinnati Knee Rating System Score, anterior drawer test, Lachman test, pivot shift test, KT1000 arthrometer measurement, isokinetic muscle tests of the extensors, and functional tests (single leg hop and timed hop test). Examination under anaesthesia (EUA) was also performed, followed by diagnostic arthroscopy. The integrity of the ACL bundles was tested using a probe. The AM and PL bundles were morphologically intact if structurally present, and functionally intact if not lax on probing.

Results. Of the 225 patients, 8 had isolated AM bundle tears, 2 had isolated PL bundle tears, and 215 had complete ACL tears in terms of function. The corresponding numbers were 30, 13, and 182 in terms of morphology. Compared with patients with complete ACL tear, the mean time from injury to surgery was significantly shorter in patients with isolated AM or PL bundle tear in terms of function (17.5 vs. 5.6 months, $p<0.001$) and morphology (17.5 vs. 8.8 months, $p<0.001$). Compared with patients with complete ACL tear, those with a functionally intact PL bundle had a higher rate of negative pivot shift test in preoperative evaluation (1% vs. 17%, $p=0.002$) and EUA (1% vs. 63%, $p<0.001$), and had a higher rate of negative Lachman test in EUA (1% vs. 25%, $p=0.02$).

Conclusion. The time from injury to surgery was shorter in patients with isolated bundle ACL tear. In patients with ACL deficiency, the pivot shift test was useful in detecting an intact PL bundle.

Key word: anterior cruciate ligament

INTRODUCTION

As double-bundle anterior cruciate ligament (ACL) reconstruction has become increasingly popular, isolated anteromedial (AM) and posterolateral (PL) bundle injuries are better recognised.¹ 38% of partial ACL tears progress to complete ACL deficiency,² and 62% of patients with partial tears develop unstable knees and have significant decrease in activity levels.³ Furthermore, 11% of patients with partial ACL tear undergo reconstruction of the ACL within the first year owing to progression to complete rupture.⁴ The AM bundle has constant *in situ* forces during knee flexion, whereas the PL bundle has high *in situ* forces between 0° and 30° flexion but rapidly decrease thereafter.⁵ Both bundles provide resistance to anterior tibial translation. The AM bundle contributes to the anterior stability between 60° and 90° flexion, whereas the PL bundle contributes to the anterior stability near full extension. The PL bundle is more important in controlling the rotational stability of the knee in 0° to 30° flexion.⁶

Patients with symptomatic AM bundle tears usually present with a positive anterior drawer test and Lachman test, and negative or slightly positive (grade 0 to 1) pivot-shift test, and the KT-1000 side-to-side difference is usually 2 to 4 mm.¹ Patients with symptomatic PL bundle tears usually present with a positive pivot-shift test, and slightly positive anterior drawer test and Lachman test, and the KT-1000 side-to-side difference is usually 1 to 3 mm.¹ The KT-1000 test cannot differentiate between isolated bundle tears and complete tears.⁷ There are no reliable preoperative clinical assessment tools to differentiate accurately the ACL tear patterns.

The study aimed to evaluate the associations between isolated AM or PL bundle tear of the ACL, the time from injury to surgery, and various clinical tests. We hypothesised that patients with isolated bundle tear had shorter injury-to-surgery time and could be identified by clinical tests.

MATERIALS AND METHODS

Between January 2008 and September 2011, 36 women and 189 men aged 16 to 52 (mean, 26.4) years with instability during pivoting movements and symptoms of ACL deficiency underwent ACL reconstruction of the right (n=107) and left (n=118) knees after restoration of a normal knee range of motion and subsidence of pain and swelling. Patients with radiological evidence of osteoarthritis (Kellgren and Lawrence grade 3 or 4), concomitant grade-III

deficiency of the medial or lateral collateral ligament, posterior cruciate ligament, or posterolateral corner, or any revision procedure involving the ACL were excluded.

The time of injury was determined from patient's memory and medical records; the mean time from injury to surgery was 17.0 (range, 1–147) months. Patients were evaluated for the International Knee Documentation Committee Subjective Knee Score,⁸ Cincinnati Knee Rating System Score,⁹ anterior drawer test, Lachman test, pivot shift test, KT1000 arthrometer measurement at 15, 20 and 30 lb forces, isokinetic muscle tests of the extensors at 60°, 180°, and 240° per second, and functional tests (single leg hop test and timed hop test).¹⁰

On the day of ACL reconstruction, examination under anaesthesia (EUA) was performed, followed by diagnostic arthroscopy through the standard AL portal (Fig.). The integrity of the ACL bundles was tested using a probe through the standard AM portal. The AM bundle was probed at 90° knee flexion and the PL bundle was probed in a 'figure of 4' position.¹¹ The AM and PL bundles were morphologically intact if structurally present, and functionally intact if not lax on probing.

Two-sample *t* test was used to compare the means of the continuous variables. The Fisher's exact test was used to compare the categorical variables. A *p* value of <0.05 was considered statistically significant.

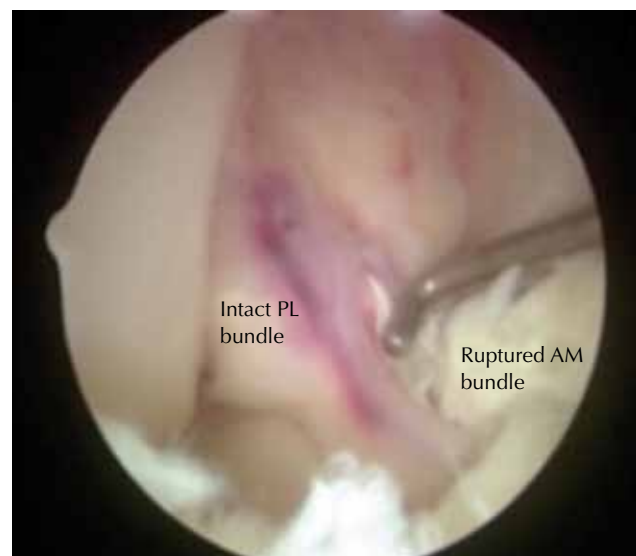


Figure Arthroscopic photo showing a ruptured anteromedial (AM) bundle and an intact posterolateral (PL) bundle of the anterior cruciate ligament.

RESULTS

Of the 225 patients, 8 had isolated AM bundle tears, 2 had isolated PL bundle tears, and 215 had complete ACL tears in terms of function. The corresponding numbers were 30, 13, and 182 in terms of morphology (Table 1).

Compared with patients with complete ACL tear, the mean time from injury to surgery was significantly shorter in patients with isolated AM or PL bundle tear in terms of function (17.5 vs. 5.6 months, $p < 0.001$) and morphology (17.5 vs. 8.8 months, $p < 0.001$) [Table 1].

Compared with patients with complete ACL tear, those with a functionally intact PL bundle had a

Table 1
Patient demographics

Parameter	Isolated anteromedial or posterolateral bundle tear functionally (n=10)	Complete anterior cruciate ligament tear (n=215)	p Value
No. of females:males	3:7	33:182	>0.05
No. of left:right knees	8:2	110:115	>0.05
Mean±SD patient age (years)	30.4±9.1	26.2±7.5	>0.05
Mean±SD time from injury to surgery (months)	5.6±3.7	17.5±22.8	<0.001
No. (%) of medial meniscal tears	1 (10)	74 (34)	>0.05
No. (%) lateral meniscal tears	2 (20)	107 (48)	>0.05
Mean±SD International Knee Documentation Committee Subjective Knee Score	60.2±23.0	60.7±14.9	>0.05
Mean±SD Cincinnati Knee Rating System Score	62.8±23.9	48.6±25.9	>0.05
Mean±SD Single leg hop test (%)	85.8±6.1	79.9±18.6	>0.05
Mean±SD Timed hop test (%)	83.5±4.7	81.6±17.4	>0.05
Mean±SD KT1000 side-to-side difference (mm)			
15 lb	1.9±1.8	1.9±1.7	>0.05
20 lb	2.7±2.4	3.0±2.3	>0.05
30 lb	2.8±2.7	4.2±2.9	>0.05
Mean±SD peak torque deficit of knee extensors (%)			
60°/s	39.7±3.8	29.8±33.1	>0.05
180°/s	31.7±5.9	18.1±26.6	>0.05
240°/s	17.7±12.2	18.6±23.3	>0.05

Table 2
Association of functionally intact posterolateral (PL) bundle and various clinical tests

Test	No. (%) of patients with intact PL bundle (n=8)	No. (%) of patients without intact PL bundle (n=217)	p Value
Preoperative assessment			
Lachman test			>0.05
Grade 0	2 (25)	12 (6)	
Grade 1	4 (50)	111 (51)	
Grade 2	2 (25)	91 (42)	
Grade 3	0 (0)	3 (1)	
Pivot shift test			0.002
Grade 0	1 (17)	2 (1)	
Grade 1	4 (67)	37 (18)	
Grade 2	1 (17)	167 (82)	
(Guarding)	2	11	
Examination under anaesthesia			
Lachman test			0.02
Grade 0	2 (25)	1 (1)	
Grade 1	3 (38)	46 (21)	
Grade 2	3 (38)	153 (71)	
Grade 3	0 (0)	17 (8)	
Pivot shift test			<0.001
Grade 0	5 (63)	3 (1)	
Grade 1	3 (38)	42 (19)	
Grade 2	0 (0)	137 (63)	
Grade 3	0 (0)	35 (16)	

higher rate of negative pivot shift test in preoperative evaluation (1% vs. 17%, $p=0.002$) and EUA (1% vs. 63%, $p<0.001$), and had a higher rate of negative Lachman test in EUA (1% vs. 25%, $p=0.02$) [Table 2]. Isolated AM or PL bundle tear was not associated with other preoperative assessments.

DISCUSSION

Although a proportion of partial ACL tears treated conservatively may progress to complete ACL tears,^{2-4,12-16} it remains controversial to perform ACL reconstruction for patients with a functionally and arthroscopically intact PL bundle.¹⁷ Pivot shift test is useful to detect isolated PL bundle tear, as patients with intact PL bundle present with negative pivot shift test indicating no anterolateral rotatory instability. They also present with a higher rate of negative Lachman test during EUA, as both AM and PL bundles provide anterior stability.^{6,18} The anterior drawer test is less sensitive owing to secondary stabilisers of the knee including the osseous contour of the joint, the posterior horns of the menisci, and the collateral ligament.¹⁹

The rates of isolated AM and PL bundle tears have been reported to be 2.8% to 12.6% and 1.6% to 8.6%, respectively.^{7,11,20-23} In our study, the respective rates were 3.6% and 0.9%. The apparent discrepancy may be due to the use of different methods to test the integrity of the bundle, especially the PL bundle. One study evaluated the PL bundle status arthroscopically by positioning the knee in a 'figure of 4' position and reported an exceptionally high rate of isolated PL bundle tears¹¹; it was criticised for not performing EUA and not examining the ACL through the AM portal.²² The decision to perform bundle augmentation is based on the EUA and arthroscopic findings.⁷ Augmentation is indicated when the ACL remnant is observed to bridge the femur and tibia anatomically, with a thickness of more than half of the AM or PL bundle, and <5 mm laxity on probing.⁷

There is no reliable preoperative clinical

examination to detect isolated AM or PL bundle tears. KT-1000 side-to-side difference is usually smaller in patients with isolated bundle tear,^{1,17} but this was not confirmed in our study and another study.⁷ International Knee Documentation Committee Subjective Knee Score, Cincinnati Knee Rating System Score, functional tests, and isokinetic knee extensors test cannot differentiate the ACL tear patterns; neither can magnetic resonance imaging (MRI) using a low-field strength with standard views, as acute bleeding in remnant fibres leads to signal change and likely misdiagnosis.¹⁷ In addition, the tension of the intact bundle is difficult to assess by MRI.¹⁷ The diagnosis rate of MRI is around 70%.⁷ Thus, clinical examination (including EUA) is indispensable in the management of ACL deficient knees. When the pivot shift test is negative, an EUA is as valuable as an MRI.¹⁷

This study had some limitations. Only patients with symptomatic ACL deficiency who underwent reconstruction were included. The rate of isolated bundle tear and correlation with various tests were unknown among ACL-deficient patients on conservative treatment. Moreover, an objective tool to ascertain the isolated AM or PL bundle laxity was absent. Probing the ACL intra-operatively to determine integrity of bundles is subjective. Only 0.9% of our patients were detected to have isolated PL bundle tear functionally; the number was too small to attain any statistical significance.

CONCLUSION

The time from injury to surgery was significantly shorter in patients with isolated AM or PL bundle tear, compared with those with complete tear. In patients with ACL deficiency, the pivot shift test was useful in detecting an intact PL bundle.

DISCLOSURE

No conflicts of interest were declared by the authors.

REFERENCES

1. Siebold R, Fu FH. Assessment and augmentation of symptomatic anteromedial or posterolateral bundle tears of the anterior cruciate ligament. *Arthroscopy* 2008;24:1289-98.
2. Noyes FR, Mooar LA, Moorman CT 3rd, McGinniss GH. Partial tears of the anterior cruciate ligament. Progression to complete ligament deficiency. *J Bone Joint Surg Br* 1989;71:825-33.
3. Fruensgaard S, Johannsen HV. Incomplete ruptures of the anterior cruciate ligament. *J Bone Joint Surg Br* 1989;71:526-30.
4. Bak K, Scavenius M, Hansen S, Norring K, Jensen KH, Jorgensen U. Isolated partial rupture of the anterior cruciate ligament. Long-term follow-up of 56 cases. *Knee Surg Sports Traumatol Arthrosc* 1997;5:66-71.

5. Sakane M, Fox RJ, Woo SL, Livesay GA, Li G, Fu FH. In situ forces in the anterior cruciate ligament and its bundles in response to anterior tibial loads. *J Orthop Res* 1997;15:285–93.
6. Amis AA, Dawkins GP. Functional anatomy of the anterior cruciate ligament. Fibre bundle actions related to ligament replacements and injuries. *J Bone Joint Surg Br* 1991;73:260–7.
7. Yoon KH, Bae DK, Cho SM, Park SY, Lee JH. Standard anterior cruciate ligament reconstruction versus isolated single-bundle augmentation with hamstring autograft. *Arthroscopy* 2009;25:1265–74.
8. Irrgang JJ, Anderson AF, Boland AL, Harner CD, Kurosaka M, Neyret P, et al. Development and validation of the international knee documentation committee subjective knee form. *Am J Sports Med* 2001;29:600–13.
9. Noyes FR, Barber SD, Mooar LA. A rationale for assessing sports activity levels and limitations in knee disorders. *Clin Orthop Relate Res* 1989;246:238–49.
10. Ross MD, Langford B, Whelan PJ. Test-retest reliability of 4 single-leg horizontal hop tests. *J Strength Cond Res* 2002;16:617–22.
11. Sonnery-Cottet B, Barth J, Graveleau N, Fournier Y, Hager JP, Chambat P. Arthroscopic identification of isolated tear of the posterolateral bundle of the anterior cruciate ligament. *Arthroscopy* 2009;25:728–32.
12. Buckley SL, Barrack RL, Alexander AH. The natural history of conservatively treated partial anterior cruciate ligament tears. *Am J Sports Med* 1989;17:221–5.
13. Johannsen HV, Fruensgaard S. Arthroscopy in the diagnosis of acute injuries to the knee joint. *Int Orthop* 1988;12:283–6.
14. Lehnert M, Eisenschenk A, Zellner A. Results of conservative treatment of partial tears of the anterior cruciate ligament. *Int Orthop* 1993;17:219–23.
15. McDaniel WJ. Isolated partial tear of the anterior cruciate ligament. *Clin Orthop Relate Res* 1976;115:209–12.
16. Sandberg R, Balkfors B. Partial rupture of the anterior cruciate ligament. Natural course. *Clin Orthop Relat Res* 1987;220:176–8.
17. DeFranco MJ, Bach BR Jr. A comprehensive review of partial anterior cruciate ligament tears. *J Bone Joint Surg Am* 2009;91:198–208.
18. Hole RL, Lintner DM, Kamaric E, Moseley JB. Increased tibial translation after partial sectioning of the anterior cruciate ligament. The posterolateral bundle. *Am J Sports Med* 1996;24:556–60.
19. Fetto JF, Marshall JL. The natural history and diagnosis of anterior cruciate ligament insufficiency. *Clin Orthop Relate Res* 1980;147:29–38.
20. Ochi M, Adachi N, Uchio Y, Deie M, Kumahashi N, Ishikawa M, et al. A minimum 2-year follow-up after selective anteromedial or posterolateral bundle anterior cruciate ligament reconstruction. *Arthroscopy* 2009;25:117–22.
21. Ochi M, Adachi N, Deie M, Kanaya A. Anterior cruciate ligament augmentation procedure with a 1-incision technique: anteromedial bundle or posterolateral bundle reconstruction. *Arthroscopy* 2006;22:463.e1–5.
22. Lorenz S, Illingworth KD, Fu FH. Diagnosis of isolated posterolateral bundle tears of the anterior cruciate ligament. *Arthroscopy* 2009;25:1203–5.
23. Zantop T, Brucker PU, Vidal A, Zelle BA, Fu FH. Intraarticular rupture pattern of the ACL. *Clin Orthop Relat Res* 2007;454:48–53.

Reproduced with permission of the copyright owner. Further reproduction prohibited without permission.