

Case Report

Minimal access microsurgical ligation of spinal dural arteriovenous fistula with tubular retractor

Anderson Chun On Tsang, Philip Yat Hang Tse, Grace Hoi Ting Ng, Gilberto Ka Kit Leung

Department of Surgery, Division of Neurosurgery, Li Ka Shing Faculty of Medicine, Queen Mary Hospital, The University of Hong Kong, Hong Kong, China

E-mail: Anderson Chun On Tsang - acotsang@hku.hk; Philip Yat Hang Tse - philipyhtse@yahoo.com; Grace Hoi Ting Ng - hoitinggrace@gmail.com;

*Gilberto Ka Kit Leung - gilberto@hkucc.hku.hk

*Corresponding author

Received: 29 January 15 Accepted: 07 May 15 Published: 09 June 15

This article may be cited as:

On Tsang AC, Hang Tse PY, Ting Ng GH, Kit Leung GK. Minimal access microsurgical ligation of spinal dural arteriovenous fistula with tubular retractor. *Surg Neurol Int* 2015;6:99.

Available FREE in open access from: <http://www.surgicalneurologyint.com/text.asp?2015/6/1/99/158458>

Copyright: © 2015 On Tsang AC. This is an open-access article distributed under the terms of the Creative Commons Attribution License, which permits unrestricted use, distribution, and reproduction in any medium, provided the original author and source are credited.

Abstract

Background: Open surgical ligation is an effective treatment of spinal dural arteriovenous fistula (SDAVF). Until recently, the procedure would require an open laminectomy, which may potentially cause significant postoperative pain, spinal deformity, and instability due to disruptions of the spinal mechanics. Development in minimal access spine surgery provides an alternative approach that can minimize bone and soft tissue trauma.

Case Description: We report two patients who presented with progressive paraparesis secondary to thoracolumbar SDAVF. Minimal access microsurgical ligation was successfully performed through a tubular retractor using a paramedian muscle-splitting approach.

Conclusion: With accurate localization of the fistulous point in each patient, only a hemilaminectomy and a small dura opening were required using the tube-assisted technique. This allows direct visualization and ligation of the fistulous point while minimizing postoperative morbidities.

Key Words: Arteriovenous fistula, minimally invasive surgery, spine, tubular retractor

Access this article online

Website:

www.surgicalneurologyint.com

DOI:

10.4103/2152-7806.158458

Quick Response Code:

INTRODUCTION

Spinal dural arteriovenous fistula (SDAVF) is the most common form of vascular malformations of the spinal cord and a potentially reversible cause of myelopathy.^[3] The classic type of SDAVF is an arteriovenous (AV) shunt between a radicular artery and the bridging vein that connects the spinal cord drainage to the epidural venous system. Due to arterialization of the veins and retrograde flow, SDAVF can result in progressive venous congestion and dysfunction of the spinal cord. Surgical interruption of the AV shunt is the treatment of choice. Until recently, the procedure would have involved an open laminectomy.

Recent advances in minimal access surgery have provided alternative approaches in an attempt to reduce tissue trauma and surgical morbidity.^[2] We report two patients whose SDAVFs were treated with a minimal access tubular retractor-assisted technique.

CASE REPORTS

Patient 1

A 52-year-old woman with good past health presented with progressive lower limbs weakness for 2 years. She had unsteady gait but normal bowel and bladder functions. There was no upper limb symptom. On examination, her lower limb had grade 4/5 motor power. There was a sensory

loss to all modalities between L2 and S1 dermatomes bilaterally. Anal tone was normal.

Magnetic resonance imaging (MRI) studies showed multiple intradural extramedullary flow voids over the thoracolumbar spine [Figure 1a]. Super-selective spinal digital subtraction angiogram revealed a single SDAVF that was fed by the right T7 radicular artery, with tortuous and hypertrophied venous drainage [Figure 1b].

Patient 2

A 83-year-old man with a history of carcinoma of esophagus in remission presented with 3 years' history of progressive paraparesis. In addition to sensory loss bilaterally from L4 to S2 dermatomes, he also had urinary incontinence. His lower limbs power was grade 3/5 that limited ambulation. Similar to patient 1, MRI [Figure 1c] and spinal digital subtraction angiogram confirmed the presence of a right T7 SDAVF.

Surgical procedure and outcome

Surgical ligation was performed in both patients in the prone position under general anesthesia. We used an oblique paramedian tube-assisted approach. The corresponding vertebral level was localized with fluoroscopy followed by a 2.5 cm right paramedian skin and fascia incision. Tubular dilators of increasing calibers (METRx X-Tube Retractor System, Medtronic, Memphis, TN, USA) were introduced sequentially in a muscle-splitting fashion, followed by a tubular retractor that reaches the T7 lamina in an oblique direction. A right T7 hemilaminectomy with undercutting of

the adjacent laminae was performed. Through a small durotomy, an arterialized vein was traced to the fistulous point of the SDAVF at the junction of the nerve root sleeve [Figure 2a and b]. The fistula was coagulated and divided. Primary water-tight dura closure was made with 4/0 polypropylene sutures [Figure 2c]. The skin was closed in the standard manner. Postoperatively, the patient required only paracetamol for pain relief, and was ambulatory within 24 h. There was no evidence of pseudomeningocele. Patient 1's lower limbs power recovered completely in 6 months, with MRI confirmed resolution of venous engorgement around the spinal cord [Figure 1d]. Patient 2 had a partial recovery of lower limbs power to grade 4/5.

DISCUSSION

Spinal cord vascular malformations are classified into four types. Type 1 or SDAVF consists of three subtypes based on their venous drainage patterns.^[1] The lateral epidural subtype, which occurred in our patients, is the classic type of SDAVF that can cause progressive paraparesis. It is a rare condition with a male predominance, and is most often found in the thoracolumbar region.^[4] The symptomatology tends to be progressive. By the time of diagnosis, most of the patients would have leg weakness and sphincter dysfunctions.

The available therapeutic options include endovascular embolization and microsurgical ligation. The former, while avoiding the risks of open surgery, has been found to carry high recurrence rates that range from 40% to 70%. This was particularly evident in early reports of that used polyvinyl alcohol, although more recent series using liquid embolic agents have shown improved success rates.

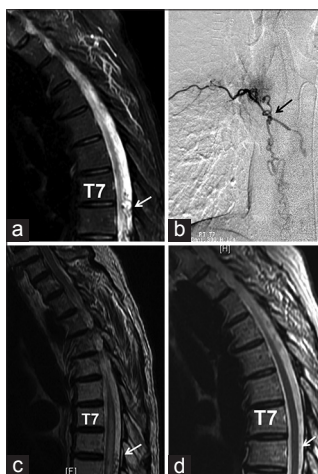

Figure 1: (a) Preoperative T2 magnetic resonance imaging (MRI) of patient 1 showing the serpiginous veins surrounding the thoracic spinal cord most prominent at T7/8 level (arrowed), secondary to the dural arteriovenous fistula (DAVF). (b) Preoperative super-selective angiography of patient 1 showing the DAVF fed by the right T7 radicular artery (arrowed). (c) Preoperative T2 MRI of patient 2 showing the serpiginous veins surrounding the thoracic spinal cord most prominent at T8/9 level (arrowed), secondary to the DAVF. (d) Postoperative T2 MRI of patient 1 showing the resolution of venous engorgement around the thoracic spinal cord (arrowed)

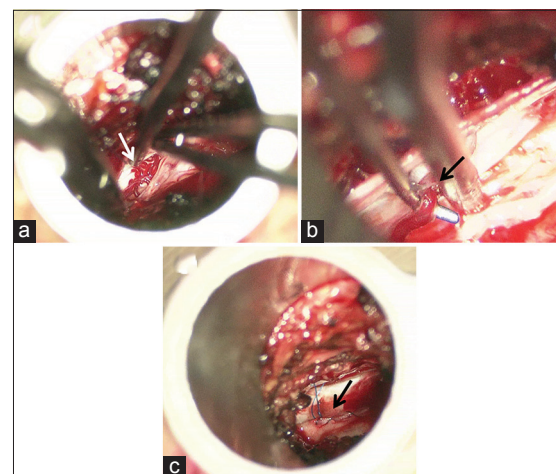


Figure 2: (a) Operative view through the tubular retractor under a surgical microscope, showing dilated serpiginous veins (arrowed) after opening the dura. (b) Dissection of the fistulous point of the spinal dural arteriovenous fistula (arrowed) at the junction of the nerve root sleeve. (c) Water-tight primary dura closure with polypropylene sutures (arrowed)

Microsurgical ligation, on the other hand, allows direct visualization and ligation of the fistula without reliance on the morphology of access vessels. It resulted in superior fistula occlusion rate, and is regarded by many authorities to be the treatment of choice. Its main disadvantages include pain, spinal instability and deformity due to the open laminectomy. These can potentially be minimized with the use of less invasive surgical techniques.

The minimal access tube-assisted approach we used employs a muscle-splitting approach that can better preserve the musculoligamentous integrity and spinal biomechanics. It has already been described for the treatment of herniated discs, lumbar and cervical stenosis, synovial cysts, as well as intradural procedures such as tumor excision and spinal cord untethering. Patel *et al.* reported their successful experiences with seven patients with thoracolumbar SDAVFs using this technique through a midline incision, with dura closure by self-closing nitinol clips. None experienced recurrence and all had stabilized or improved neurological functions.^[5]

Our report of a modified technique provides further evidence on the safety and effectiveness of this application. In contrast to Patel *et al.*, who used a midline approach, we utilized a paramedian incision approach, placing the tubular retractor in an oblique fashion toward the ipsilateral hemilamina. This provided better exposure to the fistulous point, which is typically located at the junction of the exiting nerve root sleeve. Second, in our experience, water-tight dura closure using standard 4/0 polypropylene sutures with long micro needle holder is feasible via the tubular retractor. No postoperative pseudomeningocele was observed in our series. We found this technique well-suited for SDAVF ligation since once the fistula has been localized with respect to its corresponding vertebral level, only minimal exposure of the thecal sac was required. This contrasts with tumor excision in which patient selection is restricted

by tumor size. The tube retractor system also allows for the use of indocyanine green intraoperative angiography for identifying the surgical anatomy and confirming obliteration. Future prospective studies may compare this technique with conventional open laminectomy and/or endovascular embolization in terms of treatment efficacy and postoperative morbidities. The technique, however, may not be so readily applied for other forms of spinal vascular malformations, which may require more extensive surgical exposure.

CONCLUSION

Open surgical ligation is an effective treatment of SDAVF. A minimal access tube-assisted technique using a paramedian muscle-splitting approach allows direct visualization and ligation of the fistulous point while minimizing postoperative morbidities. The present report provides further information and modification of this technique in the treatment of intradural spinal vascular conditions.

ACKNOWLEDGMENTS

We thank Dr. W. S. Ho and Dr. W. M. Lui for their guidance and advice in the clinical management of our patients.

REFERENCES

1. Geibprasert S, Pereira V, Krings T, Jiarakongmun P, Toulgoat F, Pongpech S, *et al.* Dural arteriovenous shunts: A new classification of craniospinal epidural venous anatomical bases and clinical correlations. *Stroke* 2008;39:2783-94.
2. Kim YB, Hyun SJ. Clinical applications of the tubular retractor on spinal disorders. *J Korean Neurosurg Soc* 2007;42:245-50.
3. Klopper HB, Surdell DL, Thorell WE. Type I spinal dural arteriovenous fistulas: Historical review and illustrative case. *Neurosurg Focus* 2009;26:E3.
4. Krings T, Geibprasert S. Spinal dural arteriovenous fistulas. *AJNR Am J Neuroradiol* 2009;30:639-48.
5. Patel NP, Birch BD, Lyons MK, DeMent SE, Elbert GA. Minimally invasive intradural spinal dural arteriovenous fistula ligation. *World Neurosurg* 2013;80:e267-70.