


Contents lists available at [ScienceDirect](https://www.elsevier.com/locate/aott)

## Acta Orthopaedica et Traumatologica Turcica

journal homepage: <https://www.elsevier.com/locate/aott>

# Psoas hematoma formation after violation of the intertransverse plane during posterior spinal surgery for adolescent idiopathic scoliosis



Marvin Man Ting Chung, Jason Pui Yin Cheung\*

Department of Orthopaedics and Traumatology, The University of Hong Kong, Hong Kong, SAR, China

## ARTICLE INFO

## Article history:

Received 17 August 2017

Received in revised form

23 January 2018

Accepted 19 June 2018

Available online 10 July 2018

## Keywords:

Psoas hematoma

Scoliosis

Intertransverse plan

Lumbar fascia

## ABSTRACT

Psoas hematoma is a rare yet potentially serious complication following posterior spinal surgery as it is a possible nidus for infection. We present a case of psoas hematoma formation following scoliosis surgery due to intraoperative violation of the intertransverse plane. A 13-year-old female patient with adolescent idiopathic scoliosis underwent a posterior deformity correction and instrumented fusion which was complicated with intraoperative inadvertent violation of the intertransverse plane during dissection of the posterolateral gutter leading to a unilateral psoas hematoma. She experienced abdominal pain and a CT scan confirmed the presence of a psoas hematoma. Antibiotic coverage was provided in view of positive blood culture of *Bacillus* species to avoid infective seeding of the hematoma. Resolution of the hematoma was observed on the reassessment CT one month postoperatively. It is not uncommon for patients to develop atrophic transverse processes due to spinal deformity. This may cause difficulties in identification of the anatomy intraoperatively and thus, extra caution should be exercised during dissection to prevent violation of the intertransverse plane and subsequent psoas hematoma complication.

© 2018 Turkish Association of Orthopaedics and Traumatology. Publishing services by Elsevier B.V. This is an open access article under the CC BY-NC-ND license (<http://creativecommons.org/licenses/by-nc-nd/4.0/>).

## Introduction

Posterior spinal fusion is the most widely adopted approach for correction of scoliosis and spinal fusion due to its extensibility and relatively low risk.<sup>1,2</sup> Posterolateral fusion via intertransverse fusion is biomechanically sound as the position of the transverse processes are anterior to the paraspinal musculature allowing the fusion mass to be under compression hence increasing the likelihood of successful fusion.<sup>3</sup> A proper preparation for intertransverse fusion requires exposure of the transverse processes and the intertransverse plane. This requires detachment of the erector spinae muscle from their attachment to the transverse processes but maintaining the lumbar fascia that is posterior to the psoas muscle anteriorly. This fascial plane between the transverse processes acts as a good site to lay bone graft for fusion. However

inadvertent violation of this fascial plane will violate the virgin psoas muscle anteriorly and may lead to hematoma formation. We report a case of psoas hematoma caused by intraoperative violation of the intertransverse plane during posterior correction and spinal fusion for adolescent idiopathic scoliosis (AIS).

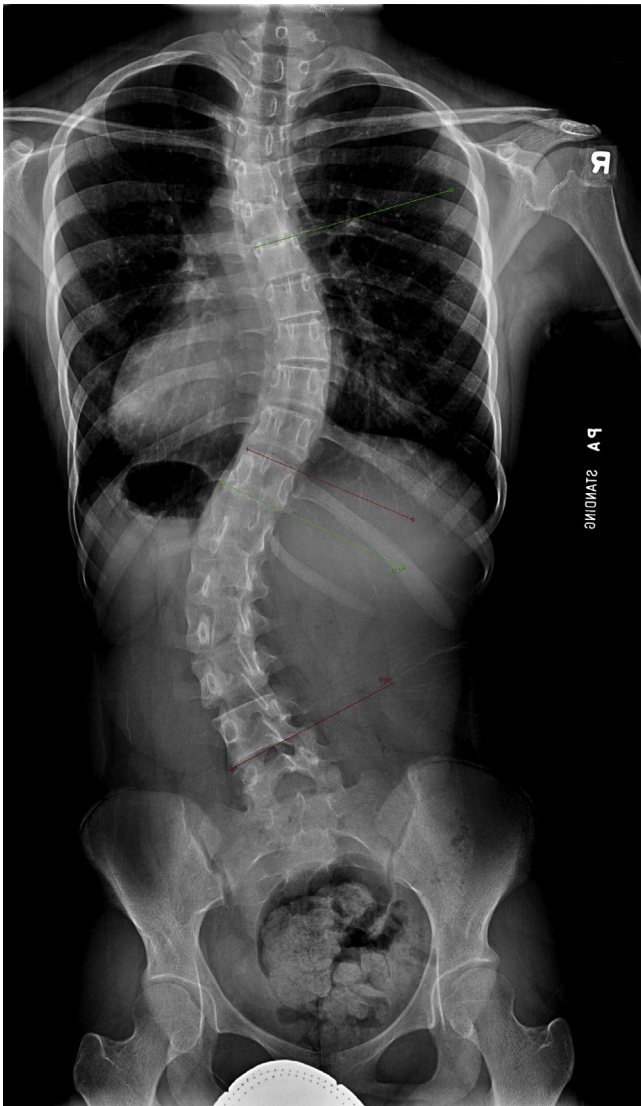
## Material and methods

We managed a 13-year-old female patient with AIS. Clinically she had a prominent right rib hump and left loin hump but no scapular hump. There was a right-sided truncal shift with listing to the left side. The loin hump was only partially correctable with side bending but the rib hump was fully correctable. Standing posteroanterior radiograph of the whole spine showed Cobb angles of 36° for T2-T6, 43° for T6-T11 and 52° for T11-L4 (Fig. 1). Sagittal profile showed a thoracolumbar junction kyphosis. Due to the curve magnitude and significant truncal imbalance, posterior correction of the deformity with spinal fusion was offered to prevent further curve progression and to rebalance her deformity. Pre-operative fulcrum bending radiographs (Figs. 2 and 3) showed a flexible thoracic curve that unbended to 16° and a lumbar curve that unbended to 15°.

\* Corresponding author. Department of Orthopaedics and Traumatology, 5/F Professorial Block, Queen Mary Hospital, The University of Hong Kong Medical Centre, Pokfulam, Hong Kong, SAR, China. Tel.: +(852) 2255 4581. Fax: +(852) 2817 4392.

E-mail address: [cheungjp@hku.hk](mailto:cheungjp@hku.hk) (J.P.Y. Cheung).

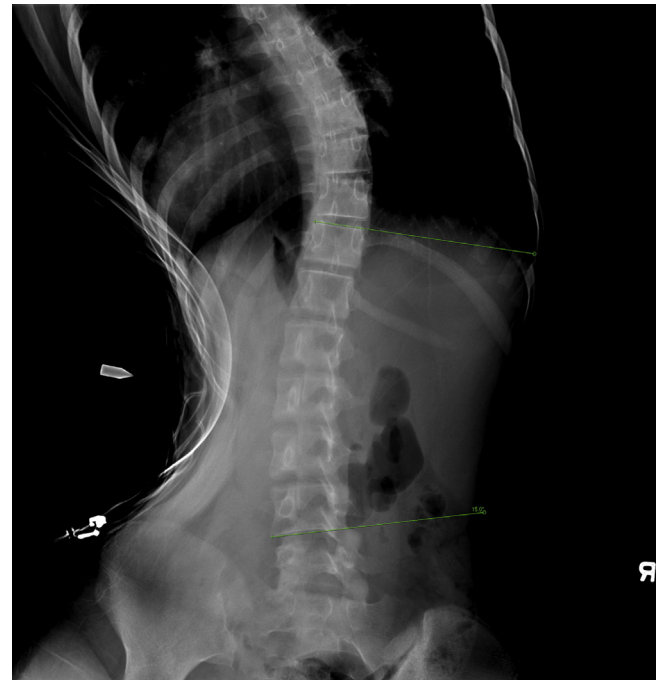
Peer review under responsibility of Turkish Association of Orthopaedics and Traumatology.



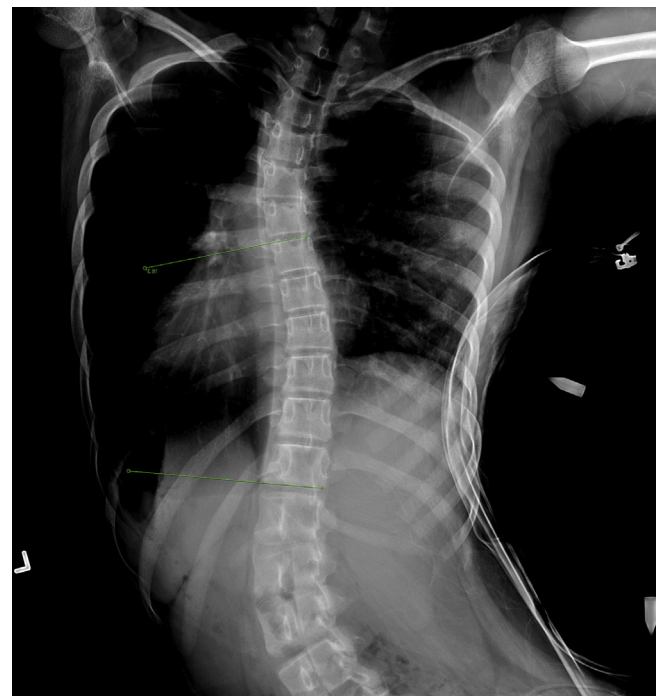
**Fig. 1.** Pre-operative standing posteroanterior x-ray of the whole spine which showed a thoracic curve (T6-11) of 43° and lumbar curve (T11-L4) of 51°.

In view of the thoracic curve magnitude and flexibility, a selective thoracolumbar fusion of T11 to L4 was planned for this Lenke VI scoliosis. One gram cefazolin was given on induction as prophylactic antibiotics. During intraoperative dissection of the posterolateral gutter on the concave side of the lumbar spine, it was observed that the transverse processes were atrophic. The lumbar fascia was violated at the L2 level during exposure of the inter-transverse plane, which was at the apex of the lumbar curve. Nevertheless, no further action was taken due to the absence of active bleeding from the violation site and the rest of the surgery proceeded as planned with alternate level pedicle screw fixation from T11 to L4. There were no pedicle wall breaches during instrumentation. The operative time was 2 h and 38 min so no antibiotic redosing was necessary. Intraoperative blood loss was 500 ml and no intraoperative transfusions were given. Post-operatively, two doses of 1 g cefazolin was given eight hours apart.

On post-operative day 1, the subcutaneous drain output was only 100 ml over 24 h and was thus removed. Her hemoglobin was 9.1 g/dL (preoperative 13.3 g/dL), platelet count was  $273 \times 10^9/L$ , prothrombin time was 12.7 s and activated partial thromboplastin time was 31.3 s. No transfusions were given but she was given



**Fig. 2.** Pre-operative posteroanterior fulcrum-bending x-ray of lumbar spine showing a flexible lumbar curve from T11-L4 that unbent to 15°.



**Fig. 3.** Pre-operative posteroanterior fulcrum-bending x-ray of thoracic spine showing a flexible thoracic curve from T6-11 that unbent to 16°.

ferrous sulfate for 2 weeks. However, she complained of right lower quadrant abdominal pain radiating to the right flank region with signs of guarding and rebound tenderness elicited upon physical examination. She had a low grade fever of 38 °C but remained hemodynamically stable. Range of right hip flexion was slightly impaired but there was no neurological deficit. White blood cell count was elevated to  $11.2 \times 10^9/L$  (preoperative  $9.8 \times 10^9/L$ ).

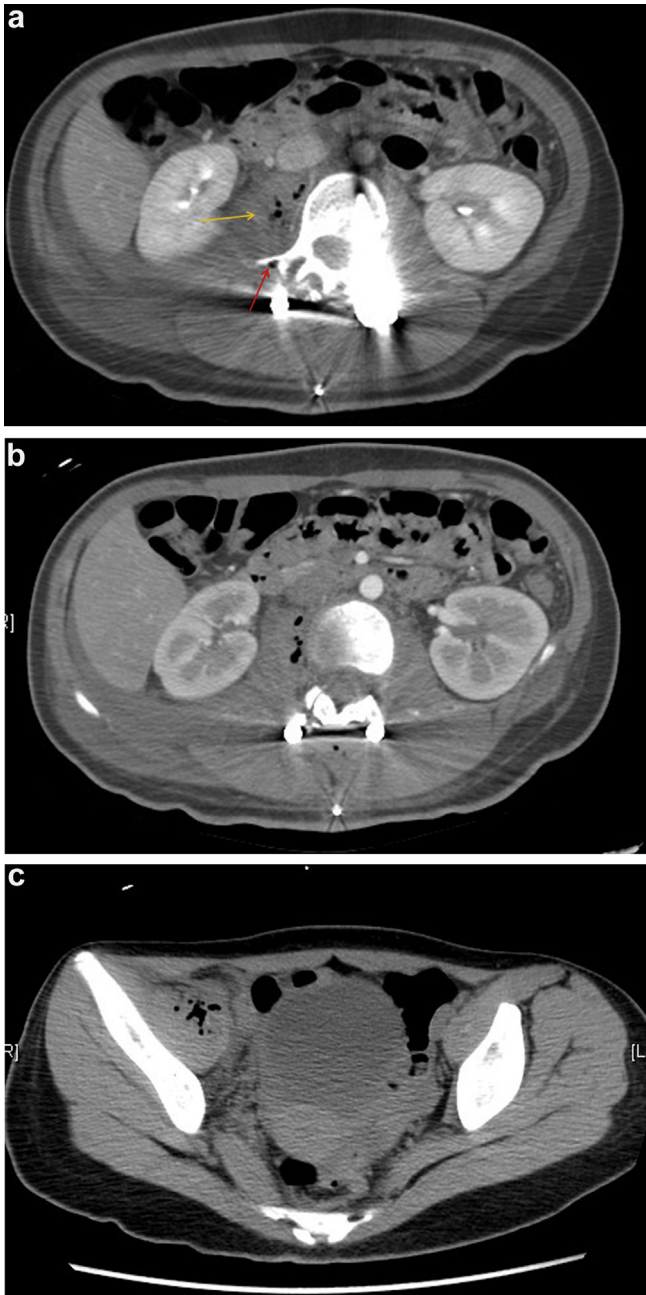
Erythrocyte sedimentation rate (ESR) was 69 mm/h and C-reactive protein (CRP) was 12.9 mg/dl. There was a clinical suspicion of acute appendicitis and an urgent computed tomography scan of the abdomen and pelvis was performed. The scan did not show any signs of appendicitis but instead revealed a swollen right iliopsoas muscle with multiple pockets of gas densities, which appeared to be slightly hyperdense on both pre-contrast and contrast scans, compatible with post-operative hematoma (Fig. 4). No screw penetration beyond the vertebral body was noted. The swelling and gas densities were extensive from L1 level down to the iliopsoas at

the level of the pelvis. Blood culture taken on post-operative day 1 grew *Bacillus* species.

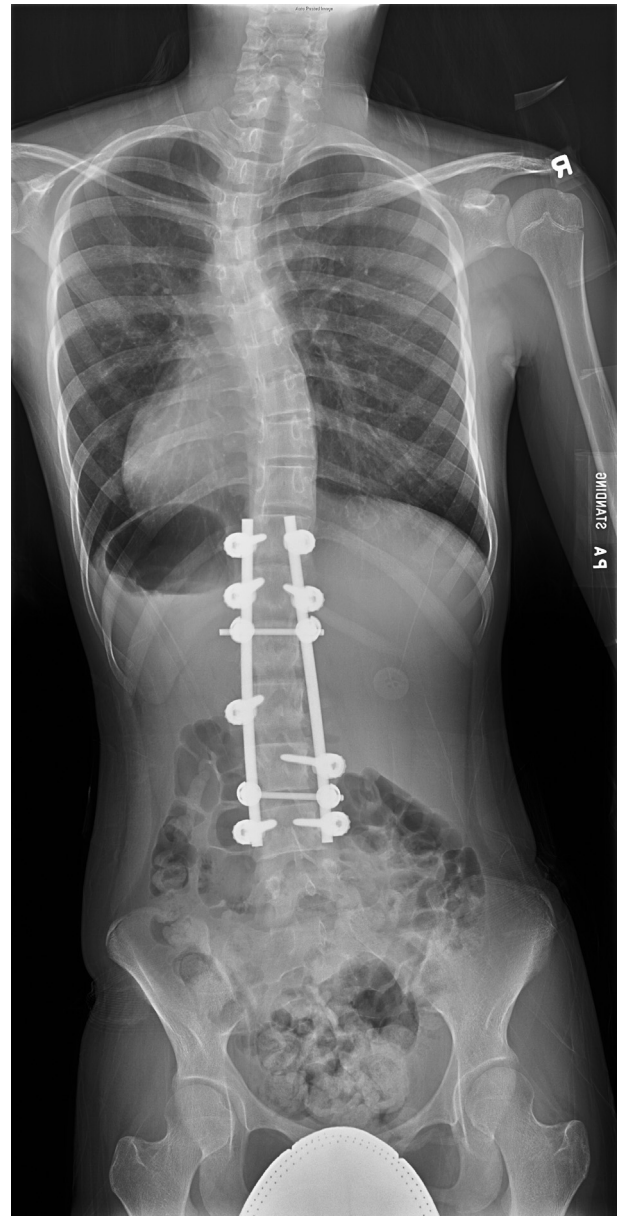
## Results

In view of the hematoma and positive culture growth, the patient was then started on a course of intravenous cefazolin 1 g daily for 5 days in total to avoid potential seeding of the hematoma by the organism. Subsequent resolution of abdominal pain and fever was observed on post-operative day 6.

She underwent a short course of inpatient rehabilitation and was discharged on post-operative day 10. Postoperative x-ray showed a well-balanced spine after correction (Fig. 5). Repeat ESR (7 mm/h) and CRP (<0.35 mg/dl) were normalized and repeated blood culture yielded no growth on post-operative day 7. Reassessment computed tomography scan a month after the operation was performed to reassess the psoas hematoma and showed



**Fig. 4.** (a) Computed tomography scan of the abdomen and pelvis performed on post-operative Day 1 (axial cut at the L2 level), which showed a swollen right iliopsoas muscle with multiple pockets of gas densities (orange arrow). There was a suspected fascial defect at the right transverse process at L2 level which was the apex of the lumbar curve (red arrow). The hematoma with gas densities was extensive reaching proximally to (b) L1 and (c) distally to the pelvis.



**Fig. 5.** Early post-operative standing posteroanterior x-ray of the whole spine showing a squared fusion mass from T11-L4.

complete resolution (Fig. 6). The pain also subsided at this time. She had been followed-up for 2 years after surgery without abdominal or back symptoms.

## Discussion

Psoas hematoma can present with a variety of symptoms including hip pain with the hip joint kept in a flexed position to avoid further irritation to the psoas. Some patients may present with radicular pain at the thigh due to compression of lumbar nerve roots,<sup>4</sup> or even weakness in hip flexion and knee extension due to femoral nerve palsy.<sup>5</sup> In a patient with scoliosis surgery, post-operative abdominal pain may be mistaken for superior mesenteric artery syndrome. For patients with superimposed infection or abscess-complicating hematoma, fever and chills may be observed as well. However, since the symptoms and signs are not very specific, high clinical suspicion is required to prevent delay in diagnosis and facilitate early treatment which may include drainage of the hematoma. A computed tomography scan may help confirm the diagnosis and guide the treatment pathway.

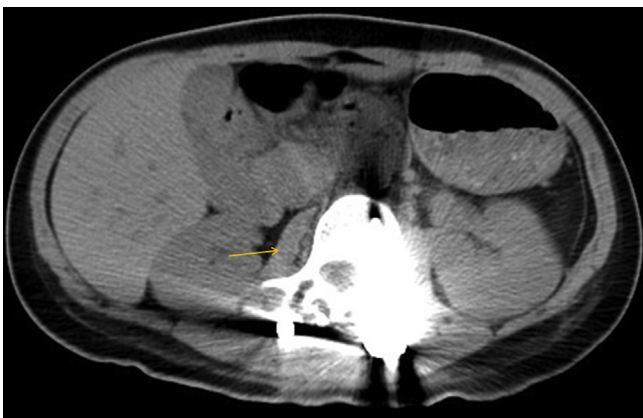Spontaneous psoas hematoma has been reported in patients with coagulopathy, hypertensive urgency<sup>6</sup> or even dengue hemorrhagic fever.<sup>7</sup> However, our patient's coagulation profile was normal and in the clinical context of intraoperative dissection of the intertransverse plane, trauma to the psoas or blood from the surgical site tracking into the psoas gives a better explanation. Several postulations have been proposed in the literature for psoas hematoma following spinal surgery. One possibility is iatrogenic injury of the intertransverse plane,<sup>8</sup> causing hematoma formation either in the psoas muscle or the retroperitoneal space around the psoas muscle. There has also been a reported case of lumbar segmental artery injury leading to formation of psoas muscle hematoma following percutaneous endoscopic discectomy.<sup>9</sup> In this case, no screw penetration was noted on postoperative CT suggesting that traumatic injury during instrumentation is unlikely.

For this patient the operating surgeon suspected direct injury in the intertransverse plane during deep subperiosteal dissection. In view of no active bleeding from the psoas, no further action was taken intraoperatively. The intertransverse ligament varies in thickness and consistency depending on the segment of spine. In the thoracic region, the intertransverse ligaments are round cords closely connected with the deep back muscles; whereas in the lumbar region, the ligaments are thin and membranous – and therefore prone to intra-operative damage. Penetrating injury to the intertransverse membrane in the lumbar region may lead to direct

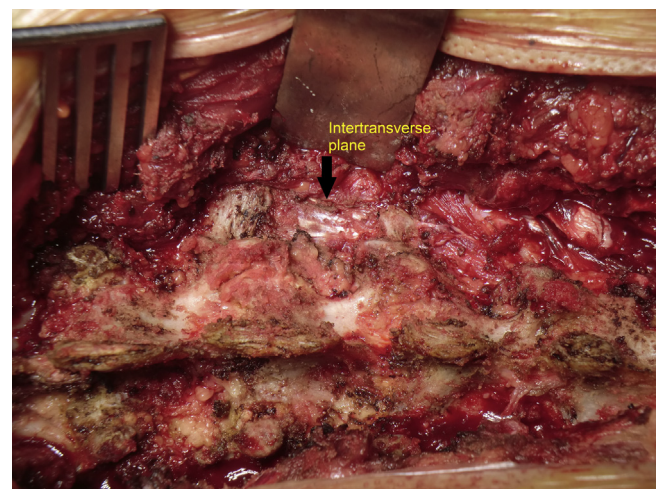
injury to the underlying psoas muscle, origin of which is at the T12/L1 disc. The injury may not be evident during the operation but nevertheless surgeons should be aware of this possible complication and be more cautious during deep dissection especially in the intertransverse plane. In fact, apart from the psoas muscle which lies immediately adjacent to the intertransverse membrane, injury to various deeper structures in the retroperitoneum via similar means has also been reported in the literature including the ureter<sup>10,11</sup> and even the aorta.<sup>12</sup> Hence, extreme care should be taken during dissection, any slip of an instrument such as the Cobb elevator may cause deep penetrating injury to the anterior structures.

The accumulation of gas densities in the CT (Fig. 4) suggests that air is found deep in the psoas muscle. Both incision through the intertransverse plane or slip of an instrument like a Cobb elevator deep into the psoas muscle may give rise to an air collection. There is a direct access from the room air through the defect into the psoas muscle. After fascia closure, the air collected in the psoas is trapped and thus seen in the CT. In our patient, the extent of the hematoma and gas densities were extensive, tracking from L1 down to the pelvis. Fortunately, it was self-limiting and resolved on the repeat CT one month later.

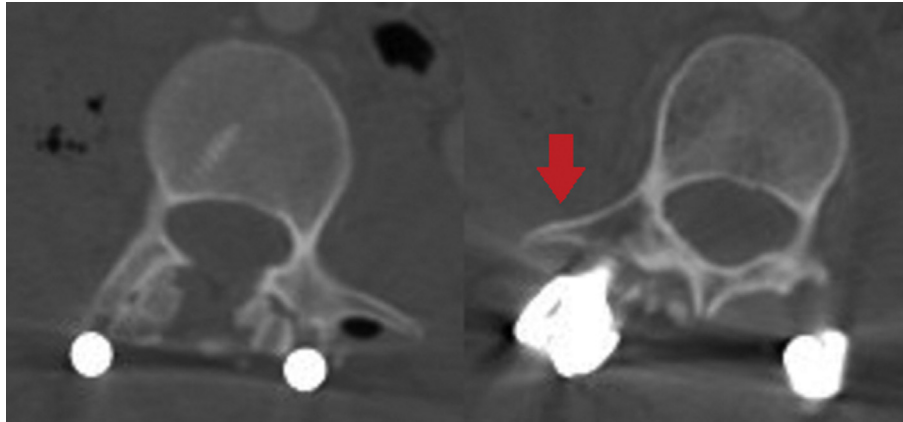
Violation of the intertransverse plane is at higher risk with scoliosis surgery due to the deformity and usual malformation or atrophic transverse processes especially on the concave side.<sup>13</sup> The usual technique is to expose the inferior border of the cranial transverse process and the superior border of the caudal transverse process. By doing so, the muscle attachments to the transverse processes are released and then atraumatic dissection of the muscle laterally can be performed to expose a shiny white surface of the intertransverse plane (Fig. 7). Meticulous dissection is even more pertinent in scoliosis surgery where the transverse processes, especially on the concave side, are commonly small and atrophic (Fig. 8). Thus, careful assessment of the preoperative imaging is important prior to surgery. Preparation of the intertransverse plane offers a better bed for fusion but it can be injured during dissection. The psoas hematoma complication may only be identified postoperatively with accumulation of blood in the psoas. Watertight closure of the superficial fascia is necessary to avoid bleeding from the bone decortication from draining through the wound. However, in the presence of a lumbar fascial defect in the intertransverse plane, blood will pass from the fusion site through to the lower pressure psoas fascia. By this



**Fig. 6.** Computed tomography scan of the abdomen and pelvis performed 1 month after the operation (axial cut at L2 level), which showed resolution of the right psoas hematoma and intramuscular gas pockets (orange arrow).



**Fig. 7.** Operative anatomy during posterior spinal surgery. The black arrow points towards the intertransverse plane where a shiny white layer is shown connecting the cranial to caudal transverse processes.



**Fig. 8.** Computed tomography images (axial cut at L3 level) showing relatively small transverse processes especially over the concave side (red arrow, measuring 3 mm shorter than the convex side).

mechanism and the experience from this case, the authors suggest surgeons to repair this fascial defect, if it occurs, to avoid psoas hematoma formation postoperatively.

Uncomplicated psoas hematoma may be treated conservatively.<sup>4</sup> Image-guided drainage or surgical debridement however remains an option for hematomas with superimposed infection.<sup>8</sup> The literature demonstrated satisfactory outcomes in patients who received surgical treatment,<sup>14</sup> but nonetheless it will inevitably lead to prolonged hospitalization, psychological stress and multiple imaging studies for reassessment. Hematomas may cause fever due to phagocytosis of extravasated blood with subsequent endogenous pyrogen or interleukin-1 release and subsequent elevation of the “set point” in the hypothalamus for thermal regulation.<sup>15</sup> Although the early postoperative fever is more likely to be caused by the hematoma rather than an infection by this mechanism, in view of the early post-operative period with spinal instrumentation, antibiotic coverage was given. Kamath et al<sup>16</sup> suggested that two further doses of cefazolin after surgery is adequate, however, in our case additional antibiotics were given as prophylaxis to prevent potential infected hematoma which will further complicate the patient's subsequent postoperative course. In addition, the blood culture yield of *Bacillus* species may have been a contamination as all inflammatory markers normalized at postoperative one week with only a short course of antibiotics. Nevertheless, this case report serves as a reminder that the anatomy must be respected during surgery. Surgeons should be particularly careful while operating on scoliosis patients due to the distorted anatomy and increased risk of penetrating into the psoas muscle during preparation of the intertransverse plane for fusion.

## Conclusions

Posterior spinal fusion is one of the commonest operations performed and the surgical exposure is generally uncomplicated. However, in scoliosis, the anatomy is distorted and may lead to inadvertent violation of the intertransverse plane during preparation for posterolateral fusion. This may lead to psoas hematoma formation which if goes unnoticed may complicate a patient's recovery with prolonged infection and pain. Hence, it is necessary for surgeons to be aware of any atrophic transverse processes preoperatively and be mindful during the dissection of the posterolateral gutter to avoid injury to this fascial layer. Repair of the defect should be performed to avoid any blood from accumulating in the psoas muscle anteriorly.

## Conflicts of interest

Nil for both authors.

## Acknowledgement

We thank Miss CC and her parents for consenting to this publication.

## References

- Geck MJ, Rinella A, Hawthorne D, et al. Comparison of surgical treatment in Lenke 5C adolescent idiopathic scoliosis: anterior dual rod versus posterior pedicle fixation surgery: a comparison of two practices. *Spine*. 2009;34:1942–1951.
- Wang Y, Fei Q, Qiu G, et al. Anterior spinal fusion versus posterior spinal fusion for moderate lumbar/thoracolumbar adolescent idiopathic scoliosis: a prospective study. *Spine*. 2008;33:2166–2172.
- Evans JH. Biomechanics of lumbar fusion. *Clin Orthop Relat Res*. 1985;193:38–46.
- Lakkol S, Sarda P, Karpe P, Krishna M. Conservative management of psoas haematoma following complex lumbar surgery. *Indian J Orthop*. 2014;48:107–110.
- Ho KJ, Gawley SD, Young MR. Psoas haematoma and femoral neuropathy associated with enoxaparin therapy. *Int J Clin Pract*. 2003;57:553–554.
- Yogarajah M, Sivasambu B, Jaffe EA. Spontaneous iliopsoas haematoma: a complication of hypertensive urgency. *BMJ Case Rep*. 2015;2015. bcr201407517.
- Bhat KJ, Shovkat R, Samoon HJ. Abdominal haematoma and dengue fever: two different cases of spontaneous psoas muscle haematoma and bilateral rectus sheath haematoma complicating dengue haemorrhagic fever. *J Vector Borne Dis*. 2015;52:339–341.
- Korovessis P, Petsinis G, Papazisis Z. Unilateral psoas abscess following posterior transpedicular stabilization of the lumbar spine. *Eur Spine J*. 2000;9:588–590.
- Kim HS, Ju CI, Kim SW, Kim JG. Huge psoas muscle hematoma due to lumbar segmental vessel injury following percutaneous endoscopic lumbar discectomy. *J Korean Neurosurg Soc*. 2009;45:192–195.
- Cho KT, Im SH, Hong SK. Ureteral injury after inadvertent violation of the intertransverse space during posterior lumbar discectomy: a case report. *Surg Neurol*. 2008;69:135–137.
- de Quintana-Schmidt C, Clavel-Laria P, Bartumeus-Jene F. Ureteral injury after posterior lumbar surgery. Case report. *Neurocirugía (Asturias, Spain)*. 2011;22:162–166.
- Yip SL, Woo SB, Kwok TK, Mak KH. Nightmare of lumbar discectomy: aorta laceration. *Spine*. 2011;36:E1758–E1760.
- Kotwicki T, Napiontek M, Nowakowski A. Transverse plane of apical vertebra of structural thoracic curve: vertebra displacement versus vertebral deformation. *Stud Health Technol Inform*. 2006;123:164–168.
- Berti AF, Santillan A, Berti Jr AF. Bilateral psoas abscesses caused by methicillin-resistant *Staphylococcus aureus* (MRSA) after posterolateral fusion of the lumbar spine. *J Clin Neurosci: Off J Neurosurg Soc Australas*. 2010;17:1465–1467.
- Chmel H, Palmer JA, Eikman EA. Soft tissue hematoma as a cause of fever in the adult. *Diagn Microbiol Infect Dis*. 1988;11:215–219.
- Kamath VH, Cheung JP, Mak KC, et al. Antimicrobial prophylaxis to prevent surgical site infection in adolescent idiopathic scoliosis patients undergoing posterior spinal fusion: 2 doses versus antibiotics till drain removal. *Eur Spine J*. 2016;25:3242–3248.