




Contents lists available at ScienceDirect

The Journal of Foot & Ankle Surgery

journal homepage: www.jfas.org

Can the Syndesmosis Procedure Prevent Metatarsus Primus Varus and Hallux Valgus Deformity Recurrence? A 5-Year Prospective Study

Daniel Yiang Wu, MD¹, Eddy Kwok Fai Lam, PhD²

¹Orthopedic Surgeon, Department of Orthopaedic Surgery, Hong Kong Adventist Hospital, Hong Kong

²Associate Professor, Department of Statistics and Actuarial Science, University of Hong Kong, Pokfulam, Hong Kong

ARTICLE INFO

Level of Clinical Evidence: 2

Keywords:

bunion
distal lateral soft tissue release
distal metatarsal articular angle
metatarsal callus
osteodesis procedure
osteotomy procedure
stress fracture

ABSTRACT

One of the main objectives of hallux valgus surgery is correction of the metatarsus primus varus deformity by osteotomy, arthrodesis, or soft tissue correction. The syndesmosis procedure uses intermetatarsal cerclage sutures to realign the first metatarsal and also induces a syndesmotic bonding between the first and second metatarsals to prevent metatarsus primus varus deformity recurrence. The purpose of the present study was to demonstrate radiologic evidence of the effectiveness of the syndesmosis concept and to identify the incidence and nature of deformity recurrence. A total of 55 feet from 60 consecutive procedures were followed regularly at 6 fixed points for 5 years. The radiologic inclusion criterion was a first intermetatarsal angle $>9^\circ$ or metatarsophalangeal angle $>20^\circ$. The initial postoperative radiographs showed significant correction of the intermetatarsal angle from a preoperative average of 14.5° to 4.3° ($p < .0001$). It had increased to 7.0° during the first 6 postoperative months but remained within the normal upper limit of 9° and exhibited no further significant changes for the subsequent 4.5 years ($p = .0792$). Hallux valgus deformity correction also correlated with metatarsus primus varus deformity correction. Three (5%) second metatarsal stress fractures occurred, and all recovered uneventfully. In conclusion, we have report the findings from a detailed medium long-term follow-up study showing, to the best of our knowledge, for the first time that metatarsus primus varus and hallux valgus deformities can be effectively corrected and maintained using a specific surgical technique. Also included are 6 relevant radiographs and photographs of the included and excluded feet in the online Supplementary Material for reference.

© 2017 by the American College of Foot and Ankle Surgeons. This is an open access article under the CC BY-NC-ND license (<http://creativecommons.org/licenses/by-nc-nd/4.0/>).

We were interested in determining whether the syndesmosis concept can stabilize the first metatarsal after its realignment using nonosteotomy intermetatarsal cerclage sutures to prevent metatarsus primus varus (MPV) and hallux valgus (HV) deformities from recurring. We hypothesized that the postoperative primary soft connective tissue ingrowth between the first and second metatarsals could provide a lasting biologic stabilizing mechanism akin to the syndesmosis between the tibia and fibula. Our primary aim was to document any loss of correction during a minimal 5-year period. Our secondary aim was to determine the timing and quantity of any correction loss that might occur. We undertook a prospective cohort study to

understand the nature of deformity recurrence after a soft tissue procedure that specifically incorporated a first metatarsal stabilizing mechanism to prevent recurrence of an MPV deformity.

The HV deformity is a common foot condition. When conservative measures become unsatisfactory and symptoms persist, operative management can be considered to correct the deformity and alleviate the symptoms. More than 150 different surgical corrective techniques have been reported, and many are currently in practice with diverse preferences among surgeons (1,2). The lack of consensus has been a concern for both surgeons and patients alike.

Although many pathologic factors have been deemed to precipitate and accentuate the HV deformity, MPV has been regarded as the principal underlying deformity (3–7) owing to their consistent and close association. It has also become increasingly understood that both metatarsophalangeal joint (MTPJ) subluxation and sesamoid malalignment in HV deformity are primarily caused by the MPV deformity (8). Hence, MPV correction and recurrence prevention have become 2 of the main objectives of all HV surgeries (4,9–13). The

Financial Disclosure: None reported.

Conflict of Interest: Daniel Yiang Wu, MD, FRCS(C), is the owner of The Center for Non-Bone-Breaking Bunions Surgery, Hong Kong, SAR, China.

Address correspondence to: Daniel Yiang Wu, MD, Department of Orthopaedic Surgery, Hong Kong Adventist Hospital, No. 40 Stubbs Road, Hong Kong.

E-mail address: dymjwu@gmail.com (D.Y. Wu).

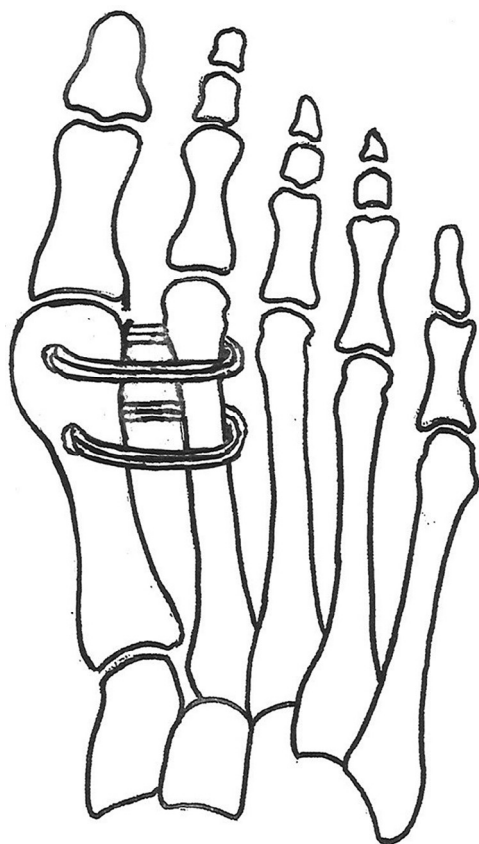


Fig. 1. Schematic illustration of intermetatarsal cerclage sutures over distal one-half of metatarsals to realign the first metatarsal and reduce the intermetatarsal gap. (Figure created by D.Y.W.)

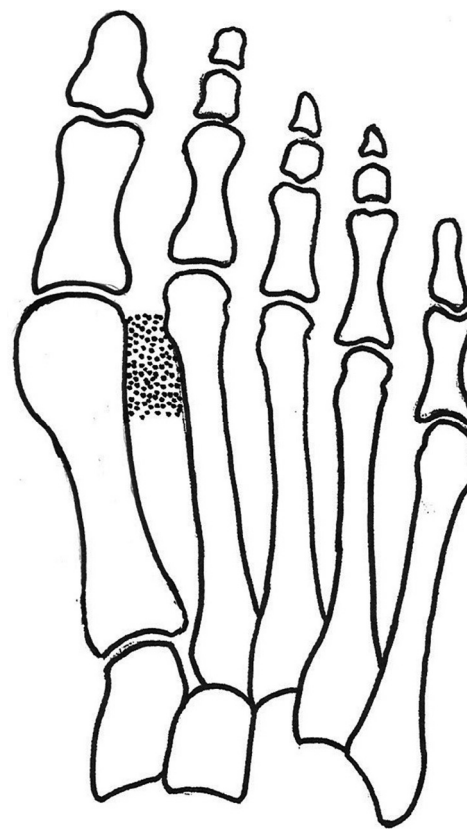


Fig. 2. Schematic illustration of the intended syndesmosis-like soft tissue bonding formation by primary connective tissue in-growth in the first intermetatarsal space. (Figure created by D.Y.W.)

osteotomy concept has been the most popular surgical approach to MPV correction (1,2). Because MPV is the product of failed ligaments and a destabilized first metatarsal, its restabilization is just as important as its realignment (14). Restoration of first metatarsal stability has been sufficiently discussed and understood; however, the recurrence of the MPV deformity remains mostly unresolved (15,16). Although arthrodesis of the metatarsocuneiform joint using the Lapidus procedure has thus been recommended to help prevent recurrence (9), recurrence can still develop (17). In addition to the osseous approach using osteotomies and arthrodesis, the soft tissue approach, such as the McBride procedure and its modifications (18), has also been described. Soft tissue approaches are less traumatic than osseous procedures but have also been deemed less effective (19,20).

The syndesmosis procedure is a soft tissue, nonosteotomy technique. It differs from most HV procedures by addressing both the deformity correction and recurrence prevention issues specifically. It uses an intermetatarsal cerclage suture technique (Fig. 1) to realign the first metatarsal and also induce the formation of a syndesmosis-like bonding between the first and second metatarsals (Fig. 2) to restabilize the first metatarsal and prevent MPV deformity recurrence. The syndesmosis procedure was originally called the osteodesis of the first metatarsal when it was first reported in 1961 (21). Favorable results have since been documented (22–26); however, it is still largely undiscovered and unrecognized by most surgeons (27). The purpose of the present study was to confirm the effectiveness of intermetatarsal cerclage sutures in the initial correction of MPV and HV deformities and to conduct a medium long-term radiologic follow-up study of the syndesmosis concept for first metatarsal restabilization

and deformity recurrence prevention. The present study was also designed to understand the nature of any deformity recurrence pattern for future management using a regular and frequent follow-up schedule.

Patients and Methods

From June to October 2009, 32 consecutive patients (60 feet) from the solo practice of an author (D.Y.W.) in Hong Kong underwent the syndesmosis procedure for HV deformity correction without any deformity limitations or selection criteria, other than the radiologic criterion of an intermetatarsal angle (IMA) $>9^\circ$ or a metatarsophalangeal angle (MPA) $>20^\circ$ and the clinical criterion of unsatisfactory conservative management results. Patients were advised that the syndesmosis procedure was not a mainstream surgical technique, and all provided specific acknowledgment and consent. Of the 32 patients, 29 (90.6%), with a total of 55 procedures (26 [89.7%] bilateral and 3 [10.3%] unilateral), completed the minimal 5-year prospective follow-up study. The mean follow-up duration was 63.2 (range 60 to 83) months. The entire cohort was female, and none had undergone any previous foot surgery or experienced severe trauma. The mean age at surgery was 39 (range 14 to 63) years (Supplemental Table S1).

The primary aim of our investigation was to collect radiologic data to determine the timing of deformity recurrence, if any occurred. The secondary aims were to analyze the radiologic data to identify any risk factors and correlations for deformity recurrence and to document all surgical complications.

All patients underwent clinical and radiologic assessment by an author (D.Y.W.) at their preoperative, and then 10-day, 3-month, 6-month, 1-year, 2-year, and 5-year postoperative visits (Supplemental Fig. S1). All radiographic examinations were conducted using an identical protocol. The patients were positioned, standing, on the same foot markings on a pedal-specific computerized digital x-ray platform by 20/20 Imaging® (Lake in the Hills, IL) by the same nurse-technician. The first MPA for quantifying HV deformity and the first IMA for quantifying MPV deformity were calculated using Hardy's midaxial line technique (28) with the built-in software (Opal-RAD, Viztek, Konica Minolta, Garner, NC). The American Orthopaedic Foot and Ankle Society ankle-hallux scale was used for the overall clinical evaluation.

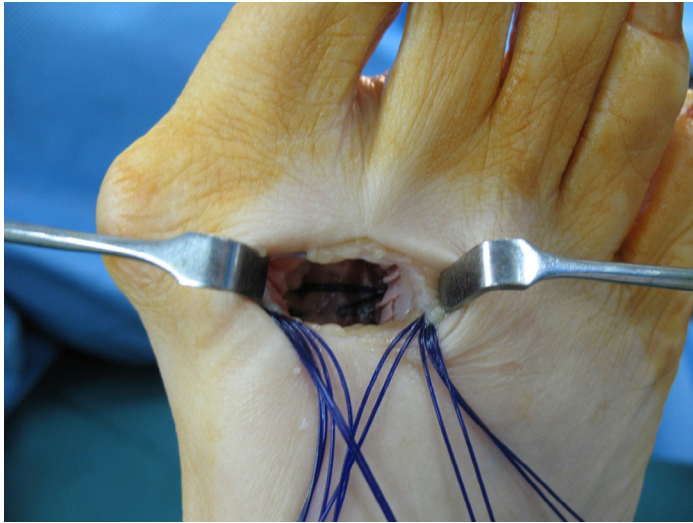


Fig. 3. Intraoperative photograph showing fish-scaling of cortices and polydioxanone sutures deep in the wound after being passed through first metatarsal drill holes and around second metatarsal before being tied to correct the metatarsus primus varus deformity.

Three (9.4%) patients (5 feet; [Supplemental Fig. S1](#); cases 1241, 1243, and 1247) were excluded from the present study because they did not complete their 5-year follow-up examination. Of these 3 patients, 1 (33.3%) had emigrated overseas, 1 (33.3%) had health reasons, and 1 (33.3%) was unhappy with her early deformity recurrence (case 1243).

Assessors

An author (D.Y.W.) initiated and designed the study, examined all the patients at all stages, collected all the clinical data for the study, and performed the surgery for the entire cohort. An author (K.F.L.) performed all the statistical analyses, and both contributed to the outcome assessments and manuscript writing.

Statistical Analysis

The continuous variables are presented as the mean and range. The MPA and IMA of the patients measured preoperatively and at each postoperative examination were compared using repeated measures multivariate analysis of variance. Pairwise comparisons were performed between each of the postoperative measurements and the preoperative measurement using the paired *t* tests. The 2-independent samples *t* test was used in the comparisons between severity groups with Bonferroni correction for multiple comparisons. Pearson correlations were calculated for the corrections in IMA and MPA at each of the 6 examination points. A *p* value $\leq .05$ was considered statistically significant. The 95% confidence intervals (CIs) for proportions were computed using the exact binomial method.

Operative Technique

An initial 1-in. incision was made along the distal dorsal medial border of the second metatarsal (22–26). After blunt dissection, the interosseous muscle was retracted laterally and partially resected if necessary to help expose the lateral soft tissue structures for release of the lateral collateral and metatarsosesamoid ligaments. The adductor hallucis tendon was not released, and the fibular sesamoid was not resected. The distal one third of the first and second metatarsals was then exposed subperiosteally and roughened in a fish-scale fashion with an osteotome. Three drill holes 2 mm in diameter were made in the distal one half of first metatarsal shaft about 5 mm apart in the dorsoplantar direction. Double-strand no. 1 polydioxanone dissolvable sutures (Ethicon, Johnson & Johnson, Somerville, NJ) were then passed through the drill holes and around the second metatarsal, binding the 2 together ([Fig. 3](#)). Four feet underwent additional soft tissue release of the second MTPJ through the same dorsal incision to reduce its dorsal dislocation ([Supplemental Fig. S1](#); case 1225, right and left feet; case 1231, right foot; and case 1237, right foot).

A medial horizontal elliptical incision was then made to remove redundant skin, bursa, capsular tissues, and exostoses. The combined single ligament-tendon-capsular layer was then approximated with interrupted 2-0 Vicryl sutures (Ethicon) without plication.




Fig. 4. The custom-made removable total-contact postoperative protective cast-brace.

Postoperative Protocol

Full weightbearing was permitted as tolerated immediately after surgery in a custom-made thermoplastic total-contact removable foot cast-brace ([Fig. 4](#)) for 3 months, and crutches were optional. The patients were instructed on how to perform their own MTPJ passive range of motion exercises, in particular, dorsiflexion and active plantarflexion strengthening exercises, from the first postoperative day for 6 weeks to regain and maintain MTPJ movement and strength. No physiotherapy was prescribed. Working patients were allowed to return to semisedentary duties 2 to 4 weeks after surgery. Patients could resume unprotected walking in regular shoes after 3 months; however, unrestricted activities and shoes were only allowed at 6 months postoperatively.

Results

All studied patients had their complete series of 7 radiographs reviewed ([Supplemental Fig. S1](#)), except for 4 (13.8%) patients who had missed 1 and 1 (3.4%) patient who had missed 3 interim examinations ([Fig. 5](#); [Supplemental Fig. S1](#), case 1231).

Early Deformity Correction Assessment

Their preoperative and 10-day postoperative standing radiographs taken using the same technique were compared. Their early MPV and HV corrections were considered to result from the cerclage-suture technique of the syndesmosis procedure in realigning the first metatarsal and hallux. The initial reductions ([Table 1](#)) were highly significant, with the mean IMA changing from 14.5° to 4.3° (average correction 10.2°; range 6.3° to 14.8°; 95% CI 9.6° to 10.8°; [Supplemental Table S2](#)) and the mean MPA changing from 32.0° to 15.2° (average correction 16.8°; range 1.8° to 41.5°; 95% CI 14.5° to 19.1°; [Supplemental Table S3](#)).

Deformity Recurrence Assessment

The mean IMA and MPA had increased from 4.3° and 15.2° at 10 days postoperatively to 7.0° and 18.2° at 6 months postoperatively, respectively. However, both became very stable thereafter ([Table 1](#)). Repeated measures analysis was performed of the measurements from the last 4 follow-up examinations only. The analysis revealed that the mean angles at 6 months and 1, 2, and 5 years postoperatively were not significantly different ($p = .9397$ and $p = .0792$ for MPA and IMA, respectively). Each of the 6 postoperative follow-up measurements were lower than the preoperative measurements, and the mean was significantly lower

Table 1
Summary of intermetatarsal angle and metatarsophalangeal angle measurements at multiple follow-up points (N = 55 feet in 29 females)

Angle	Preoperative	Postoperative						Total Correction
		Day 10	Month 3	Month 6	Year 1	Year 2	Year 5	
IMA (°)								
Mean	14.5	4.3	6.2	7.0	7.1	7.1	6.9	7.6
Range	9.4 to 22.7	1.4 to 8.2	3.0 to 10.8	4.6 to 10.6	4.3 to 10.6	4.0 to 10.4	4.3 to 10.0	3.8 to 14.3
MPA (°)								
Mean	32.0	15.2	15.5	18.2	18.2	17.9	18.4	13.6
Range	19.5 to 51.9	-2.1 to 27.3	3.0 to 30.2	5.1 to 36.8	1.8 to 35.8	6.7 to 38.6	0.0 to 36.6	3.2 to 39.0

Abbreviations: IMA, intermetatarsal angle; MPA, metatarsophalangeal angle.

($p < .0001$, paired t test; [Table 2](#)). The measurements had stabilized 6 months after the correction and remained stable for >4.5 years.

Correlations in Changes Between IMA and MPA

Change was defined as the difference between 2 consecutive measurements. The immediate correction in the IMA was defined as the IMA at postoperative day 10 minus the preoperative IMA. The correction at 6 months was defined as the difference between month 6 and month 3, the previous measurement. The correlations of the changes in IMA and MPA at the different examination points were calculated ([Table 2](#)).

The correlation analysis indicated that the changes in IMA and MPA were highly correlated at the early phase after correction. Both the IMA and MPA had decreased substantially in the first 10 days (-10.3° and -16.8° ; correlation 0.6585; $p < .0001$) but had increased slightly at month 3 (1.88° and 0.01° ; correlation 0.4249; $p = .0023$) and month 6 (0.95° and 2.9° ; correlation 0.3684; $p = .0108$), respectively. After 6 months, no significant correlations in the changes of the measurements were detected.

Comparison of Results Between Preoperative Mild and Severe Subgroups

MPV Deformity (IMA)

An arbitrary grouping of the preoperative mild ($IMA \leq 15^\circ$) and severe ($IMA > 15^\circ$) MPV deformity was made for comparison ([Table 3](#)). The IMA of the mild and severe subgroups was corrected to less than

the normal IMA upper limit of 9° (6.6° and 7.4° , respectively). A total correction of 10.4° could be achieved in the severe subgroup compared with 6.2° for the mild subgroup ([Supplemental Table S2a,b](#)). The more severe HV deformity (MPA 37.9°) expected of the severe IMA (MPV deformity) subgroup could also be corrected similar to the correction in the mild subgroup (18.3° versus 18.5° , respectively; $p = .9432$; [Supplemental Table S2c,d](#)).

HV Deformity (MPA)

The preoperative severe HV deformity subgroup (MPA $> 30^\circ$) had a greater residual MPA of 20.5° compared with 16.1° in the preoperative mild HV deformity (MPA ≤ 30) subgroup ($p = .0101$; [Table 4](#); [Supplemental Table S3](#)). This was the case, although the final IMA of the former was satisfactorily maintained at 7.3° , well within the upper normal limit of 9° and only slightly greater than the angle of the mild subgroup ($p = .0152$; [Supplemental Table S3](#)).

Clinical Assessment

The American Orthopaedic Foot and Ankle Society ankle-hallux scale score ([Table 5](#); [Supplemental Table S4](#)) improved from a preoperative average of 65.9 (range 39 to 85) points to 94.9 (range 83 to 100) points at 5 years, with an average improvement of 29.0 (range 15 to 51, 95% CI 26.6 to 31.5) points ($p < .0001$). Of the 29 patients (55 feet) (90%, 95% CI 74% to 97%), 26 (51 feet) were very satisfied (93%, 95% CI 83%, 97%). Of the 55 feet, 47 had first MTPJ extension $> 60^\circ$ (85%, 95% CI 74% to 92%; [Fig. 5](#)).

Table 2
Correlation of changes between intermetatarsal angle and metatarsophalangeal angle at different postoperative stages (N = 55 feet in 29 females)

Variable	Day 10 Minus Preoperative	Month 3 Minus Day 10	Month 6 Minus Month 3	Year 1 Minus Month 6	Year 2 Minus Year 1	Year 5 Minus Year 2
r Value	0.6585	0.4249	0.3684	-0.0307	-0.2680	0.1644
p Value	<.0001	.0023	.0108	.8308	.0717	.2750

Table 3
Comparison of preoperative intermetatarsal angle severity subgroups and corresponding metatarsophalangeal angles (N = 55 feet in 29 females)

Preoperative IMA Subgroup	Feet	Preoperative	Postoperative			Total Correction
			Day 10	Month 6	Year 5	
Severe (IMA $> 15^\circ$)	19 (35)					
IMA (°)		17.8 (15.4 to 22.7)	5.1 (3.6 to 8.2)	7.6 (5.0 to 9.7)	7.4 (4.3 to 9.8)	10.4 (7.4 to 14.3)
MPA (°)		37.9 (29.8 to 51.9)	14.0 (-2.1 to 22.2)	18.4 (5.1 to 36.8)	18.3 (0.0 to 36.6)	19.6 (11.9 to 39.0)
Mild (IMA $\leq 15^\circ$)	36 (65)					
IMA (°)		12.8 (9.4 to 15.0)	3.9 (1.4 to 6.2)	6.7 (4.6 to 10.6)	6.6 (4.3 to 10.0)	6.2 (3.8 to 9.3)
MPA (°)		28.9 (19.5 to 40.2)	15.8 (0.0 to 27.3)	18.1 (6.8 to 26.5)	18.5 (6.7 to 28.0)	10.4 (3.2 to 17.4)
p Value between groups						
IMA		<.0001	.0020	.0286	.0481	<.0001
MPA		<.0001	.2413	.8988	.9432	<.0001

Abbreviations: IMA, intermetatarsal angle; MPA, metatarsophalangeal angle.
Data presented as n (%) or mean (range).

Table 4
Comparison of preoperative metatarsophalangeal angle severity subgroups and corresponding intermetatarsal angle (N = 55 feet in 29 females)

Preoperative MPA Subgroup	Feet	Preoperative	Postoperative			Total Correction
			Day 10	Month 6	Year 5	
Severe (MPA >30°)	29 (53)					
MPA (°)		37.5 (30.9 to 51.9)	16.7 (8.8 to 27.3)	20.3 (5.1 to 36.8)	20.5 (0.0 to 36.6)	16.9 (6.6 to 39.0)
IMA (°)		15.8 (11.1 to 22.7)	4.8 (2.3 to 8.2)	7.4 (5.0 to 9.7)	7.3 (4.3 to 9.8)	8.5 (4.2 to 14.3)
Mild (MPA ≤30°)	26 (47)					
MPA (°)		25.9 (19.5 to 29.9)	13.5 (-2.1 to 21.5)	15.9 (6.8 to 21.5)	16.1 (6.7 to 23.6)	9.9 (3.2 to 16.2)
IMA (°)		13.1 (9.4 to 16.9)	3.8 (1.4 to 6.0)	6.6 (4.6 to 10.6)	6.4 (4.3 to 10.0)	6.7 (3.8 to 10.4)
p Value between groups						
MPA		<.0001	.0239	.0047	.0101	<.0001
IMA		.0003	.0075	.0332	.0152	.0090

Abbreviations: IMA, intermetatarsal angle; MPA, metatarsophalangeal angle.
Data presented as n (%) or mean (range).

Complications

The complications evaluated included MPV recurrence, HV recurrence, MTPJ subluxation, stress fracture, and others.

MPV recurrence developed in 6 feet (11%; Supplemental Fig. S1, case 1228, left foot; case 1231, right foot; case 1234, both feet; case 1235, left foot). These 6 feet had a mild residual IMA ranging from >9° to ≤10° (Table 6; Supplemental Table S5a,b). Their residual HV deformity with a MPA of 22.5° was also greater than that of the rest of the cohort at 17.9° (Supplemental Table S5c,d). The IMA and MPA of both subgroups remained virtually unchanged after the first 6 postoperative months.

HV recurrence developed in 19 feet (35%; Table 7), with a residual HV deformity of a MPA >20°. These patients experienced early reversion of both their HV and MPV deformities during the first 6 postoperative months that was greater than the rest of the cohort (Supplemental Table S6). Neither subgroup experienced further deterioration of their MPA and IMA during the ensuing 4.5 years.

MPJ subluxation developed in 4 feet (7%; Supplemental Fig. S1, case 1223, left foot; case 1229, left foot; case 1236, right foot; case 1237, right foot). The early postoperative medial subluxation of the MTPJ was temporary, and all were resolved by taping and the slight IMA increases during the first 3 postoperative months.

Two feet (4%; Supplemental Fig. S1, case 1219, left foot; case 1220, left foot) had asymptomatic second metatarsal stress fracture that was only detected radiologically at their 5-year examination with mild valgus angular deformity. One foot (2%; Supplemental Fig. S1, case 1237) suffered stress fracture 2 months postoperatively and healed uneventfully in a weight bearing forefoot slipper cast after 6 weeks.

No cases of infection, neuralgia, transfer metatarsalgia, hallux varus deformity, or first metatarsal malformation occurred.

Discussion

HV deformity has several possible underlying causative factors such as an increased distal metatarsal articular angle, HV interphalangeus, and axial deformity of the first metatarsal (29,30). However, MPV deformity is still considered the most consistent factor, and its importance is reflected by its mandatory correction in all surgical techniques

and that it is one of the most recognized measurements for operative success.

Soft tissue procedures using nonosteotomy and nonarthrodesis methods have generally been regarded as less effective, especially for moderate and severe deformity correction and recurrence prevention. However, as a soft tissue technique, the syndesmosis procedure has been shown to be effective in the past. Its capability and effectiveness were also confirmed in the present study. Its initial dramatic and overcorrection of the IMA to an average of 4.3° using the intermetatarsal cerclage sutures alone confirmed the normal metatarsocuneiform joint flexibility and unobstructed first metatarsal realignment even years after the onset of the HV deformity. This free mobility was also clinically suggested by the lack of early and late postoperative discomfort in the metatarsocuneiform joint and midfoot region. We also believe that realignment of the first metatarsal in its entirety has another advantage of improving the congruence of the metatarsocuneiform joint (Fig. 5A,D), which might not be possible after osteotomy techniques. Therefore, the previous concerns of poor MPV correction without osteotomies might not be valid and should be reexamined.

Although the present study has demonstrated with statistical significance that the first metatarsal of the MPV deformity can be realigned without osteotomy, our primary purpose was to document the clinical history of deformity recurrence during a 5-year period after the syndesmosis procedure. Stainsby (31) reported that metatarsals were connected and stabilized to each other independently and mainly through a distal tie-bar system. Stainsby (31) also reported that failure of the tie-bar system from attenuation and elongation of the medial metatarsos sesamoid ligament at its medial end was the cause of the destabilization and varus deviation of the first metatarsal (Fig. 6). In addition, the destabilization and varus deviation did not result from any failure of the deep intermetacarpal ligament (31). The medial collateral ligament of the MTPJ was also attenuated and gave way in the HV deformity formation. Hence, HV and MPV deformities largely result from displaced normal bones secondary to failure of their soft tissue stabilizing structures. The present study conducted an unprecedented number of 6 regular radiographic follow-up examinations to understand the clinical effectiveness of the syndesmosis concept in MPV recurrence prevention. We have demonstrated that the primary

Table 5
American Orthopaedic Foot and Ankle Society ankle-hallux metatarsophalangeal-interphalangeal scale scores (N = 55 feet in 29 females)

Score	Pain (40 Points)	Function (45 Points)	Alignment (15 Points)	Total (100 Points)
Preoperative	23.5 (10 to 30)	35.8 (29 to 42)	6.7 (0 to 15)	65.9 (39 to 85)
Final	37.1 (30 to 40)	44.7 (42 to 45)	12.8 (8 to 15)	94.6 (80 to 100)
Correction	13.6 (10 to 20)	8.9 (3 to 16)	6.2 (0 to 15)	28.7 (15 to 51)

Data presented as mean (range).

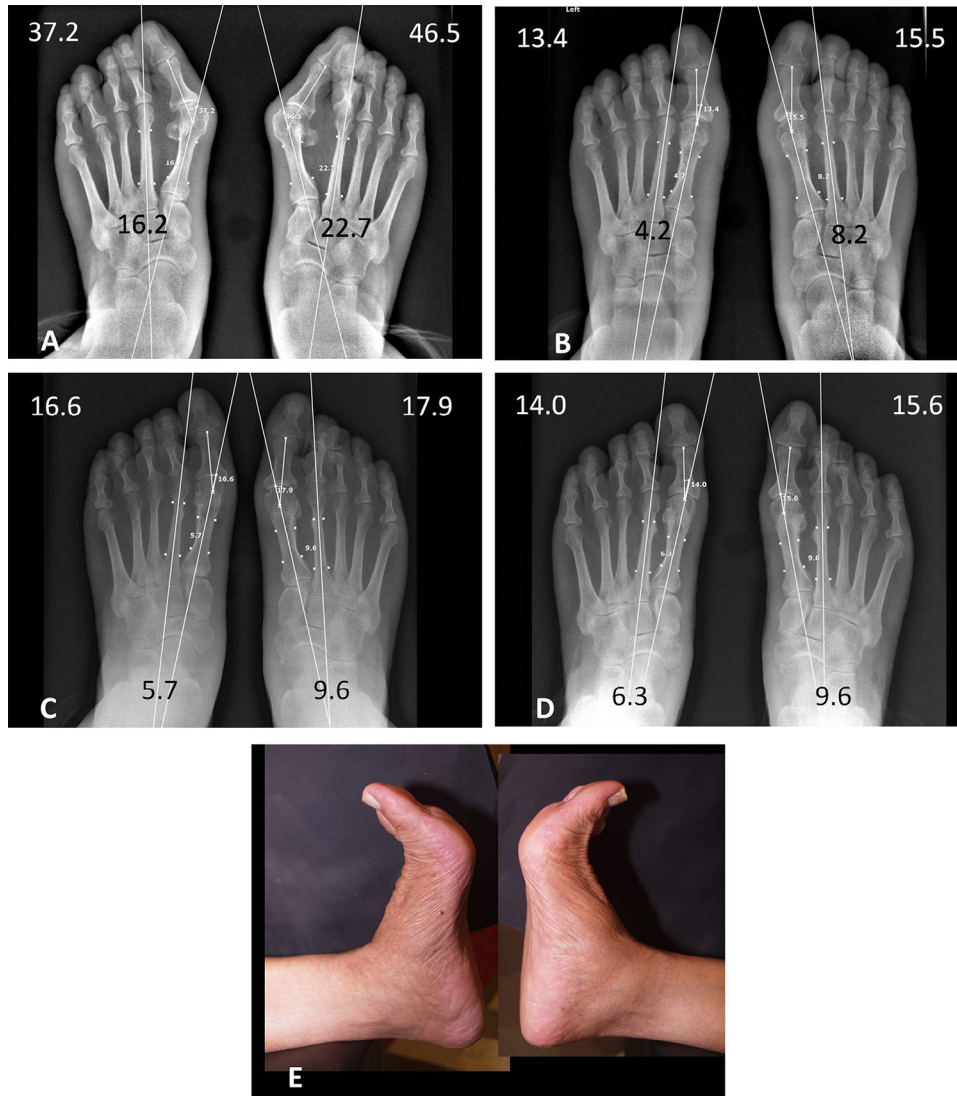


Fig. 5. (A) Preoperative standing anteroposterior radiograph of a 68-year-old female's feet showing severe metatarsus primus varus deformity of the right foot with overlapping second clawed toe deformity and metatarsophalangeal joint dorsal subluxation. (B) Ten-day postoperative anteroposterior radiograph showing good realignment of the first metatarsal, hallux, sesamoids, metatarsophalangeal and metatarsocuneiform joints, and the right second toe, including its metatarsophalangeal joint. (C) Six-month postoperative standing anteroposterior radiograph showing slight reversion of hallux valgus and metatarsus primus varus deformities of both feet, especially intermetatarsal angle of right foot, which is abnormal at 9.6°. (D) Five-year postoperative standing anteroposterior radiograph showing no remarkable alignment changes of the first metatarsal, hallux, sesamoids, or second toe after 4.5 years. (E) Five-year photograph showing good active dorsiflexion movement.

Table 6
Comparison of feet with final intermetatarsal angle >9° and ≤9° and corresponding metatarsophalangeal angles (N = 55 feet in 29 females)

Final IMA	Feet	Preoperative	Postoperative			Total Correction
			Day 10	Month 6	Year 5	
>9°	6 (11)					
IMA (°)		17.5 (14.1 to 22.7)	6.5 (5.5 to 8.2)	9.5 (8.5 to 10.6)	9.7 (9.2 to 10.0)	7.8 (3.8 to 13.1)
MPA (°)		37.2 (25.6 to 51.9)	15.8 (10.4 to 21.0)	21.8 (15.3 to 34.4)	22.5 (15.6 to 36.1)	14.8 (4.0 to 30.9)
≤9°	49 (89)					
IMA (°)		14.1 (9.4 to 19.8)	4.0 (1.4 to 6.8)	6.7 (4.6 to 9.0)	6.5 (4.3 to 8.5)	7.6 (3.9 to 14.3)
MPA (°)		31.4 (19.5 to 51.5)	15.1 (-2.1 to 27.3)	17.8 (5.1 to 36.8)	17.9 (0.0 to 36.6)	13.4 (3.2 to 39.0)
<i>p</i> Value between groups						
IMA		.0251	.0008	<.0001	<.0001	.8784
MPA		.2142	.7095	.2148	.1840	.7363

Abbreviations: IMA, intermetatarsal angle; MPA, metatarsophalangeal angle.
Data presented as n (%) or mean (range).

Table 7
Comparison of feet with final metatarsophalangeal angle $>20^\circ$ and $\leq 20^\circ$ and corresponding intermetatarsal angles (N = 55 feet in 29 females)

Final MPA	Feet	Preoperative	Postoperative			Total Correction
			Day 10	Month 6	Year 5	
$>20^\circ$	19 (35)					
MPA ($^\circ$)		36.6 (25.6 to 51.9)	17.9 (10.0 to 27.3)	23.7 (18.1 to 36.8)	25.0 (20.4 to 36.6)	11.6 (3.2 to 18.9)
IMA ($^\circ$)		14.6 (11.6 to 19.2)	4.6 (2.5 to 7.0)	7.9 (6.0 to 10.6)	7.8 (6.3 to 10.0)	6.8 (3.8 to 11.0)
$\leq 20^\circ$	36 (65)					
MPA ($^\circ$)		29.6 (19.5 to 46.5)	13.8 (-2.1 to 21.5)	15.5 (5.1 to 20.9)	14.9 (.0 to 19.8)	14.6 (4.2 to 39.0)
IMA ($^\circ$)		14.4 (9.4 to 22.7)	4.1 (1.4 to 8.2)	6.6 (4.6 to 9.6)	6.4 (4.3 to 9.6)	8.1 (3.9 to 14.3)
p Value between groups						
MPA		.0011	.0047	<.0001	<.0001	.0802
IMA		.7991	.2550	.0007	.0002	.0831

Abbreviations: IMA, intermetatarsal angle; MPA, metatarsophalangeal angle.
Data presented as n (%) or mean (range).

formation of a syndesmosis-like biologic connective structure to prevent MPV recurrence was accomplished by the sixth postoperative month. No significant increases in the IMA or MPV could be identified radiologically from 6 months to 4.5 years postoperatively. To the best of our knowledge, such radiologic evidence of a definitive time and stopping point of any MPV deformity recurrence has not yet been documented or known for HV surgical techniques. Such long-term protection could not have resulted from the intermetatarsal cerclage sutures, because we used dissolvable polydioxanone sutures. Thus, the outcomes resulted from a biologic binding mechanism like syndesmosis.

Attempts to restabilize the first metatarsal by repairing and reconstructing the medial metatarsosesamoid and medial collateral ligaments have not, in the past, been shown useful in the prevention of MPV and HV deformity recurrence. The Lapidus procedure is the only known surgical technique to specifically address the first metatarsal instability and MPV recurrence issue. However, it is still unclear how osteotomy procedures can restabilize the first metatarsal after its realignment (32), and recurrence remains a well-known complication (5,6). The syndesmosis procedure bypasses the irreparably damaged medial end of the tie-bar system to reconnect the first and second metatarsals directly through an intermetatarsal bridge. Our data have also demonstrated that even the syndesmosis bonding of the 19 feet with an MPA $>20^\circ$ was strong enough to resist the increased deforming force on the first metatarsal and maintain the IMA unchanged (Table 7; Supplemental Table S6).

Bock et al (4) analyzed 3 postoperative points over 10 years, and HV deformity recurrence with a MPA $>20^\circ$ could be detected ≤ 2.8 years after a Scarf with or without Akin osteotomy in 30% of cases. Pentikainen et al (33) performed 4 examinations over 8 years and found

HV recurrence with a MPA $>20^\circ$ in 58% after distal chevron osteotomy. However, their recurrence pattern was not described (33). No MPV recurrence was analyzed nor was the correlation with HV recurrence reported after either surgical technique. Our study of the syndesmosis procedure revealed MPV recurrence with an IMA $>9^\circ$ in 11% of our 55 feet and HV recurrence with a MPA $>20^\circ$ in 35%. Most of these recurrences developed during the first 3 postoperative months and were partial. Compared with other long-term IMA follow-up results, the syndesmosis procedure used in our study had the lowest final IMA and greatest total correction (Table 8). The early recurrence within the first 3 postoperative months probably resulted from excessive walking by the patient, which caused suture loosening. However, no further correction loss occurred in these feet once their syndesmosis had become established by the sixth postoperative month, similar to the rest of the cohort (Table 6; Supplemental Table S5). It seems that the risk factor for abnormal MPV deformity reversion (IMA $>9^\circ$) is a severe preoperative MPV deformity, because the absolute correction of 7.8° for the severe group was similar to that of the rest of cohort, although not sufficient to reduce it to within the normal range. Their final MPA was, as expected, greater than that of the rest of the cohort.

MPV has been strongly correlated with the development of HV deformity (40), and our study also demonstrated a significant correctional correlation between MPV (IMA) and HV (MPA) deformities. However, an unexpectedly high residual MPA in the present study was found in view of the relatively excellent MPV correction compared with that in other studies (Table 8). We believe it was largely related to our not using the Akin osteotomy to correct any underlying HV interphalangeus deformity and not using the distal metatarsal osteotomy to correct

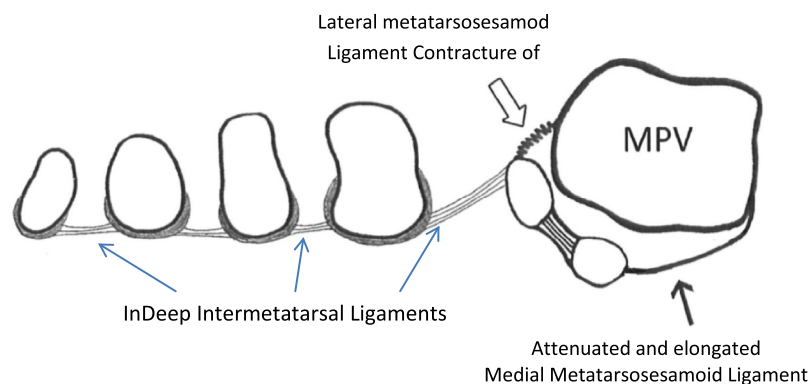


Fig. 6. Schematic coronal cross-section view of distal metatarsals of a metatarsus primus varus (MPV) deformity showing first metatarsal medial displacement, increased first intermetatarsal distance, and sesamoid lateral subluxation related to attenuation and elongation of the medial metatarsosesamoid ligament at the very medial end of the tie-bar system. (Figure created by D.Y.W.)

Table 8
Comparison of most recent and longest follow-up studies with radiologic evaluation

Investigator	Surgical Procedure	Feet (n)	Duration (y)	Preoperative (°)		Postoperative (°)		Total Correction (°)	
				IMA	MPA	IMA	MPA	IMA	MPA
Present study	Syndesmosis	55	Minimum 5	14.5	32.0	6.9	18.4	7.6	13.6
Schneider et al (34)	Chevron	64	Minimum 5	13.2	26.1	9.4	13.9	3.8	12.2
Berg et al (35)	Scarf	72	Minimum 6	15	32	9	18	6	14
Chow et al (36)	Crescentic	32	Mean 8	16.1	34.2	9.7	17	6.4	17.2
Yucel et al (18)	Modified McBride	36	Mean 6.6	10.1	32.7	9.5	20.6	0.6	12.1
Chong et al (37)	Scarf	97	Minimum 5	13	31.5	7.4	13.2	5.6	18.3
Akman et al (38)	Modified Simmonds	51	Mean 8	17.3	36.9	14.3	28.9	3	8
Dermon et al (39)	Mitchell	204	Mean 13	15.2	33.8	8.2	16.1	7	17.7
Bock et al (4)	Scarf	105	Mean 10.3	13.9	31.1	7	15	6.9	16.1

Abbreviations: IMA, intermetatarsal angle; MPA, metatarsophalangeal angle.

any increased distal metatarsal articular angle. However, the high rate of functional satisfaction among the patients with a residual HV deformity might suggest a possible lack of understanding of the true implications of these anatomic variances that might be still compatible with normal hallux function. In addition, the residual HV deformity could have been related to the surgeon not performing adductor hallucis tendon release, fibular sesamoid excision, or first metatarsal shortening in these patients. The greater residual HV deformity (MPA >20°) subgroup seemed to be related more to their greater preoperative HV deformity (MPA >30°) compared with their preoperative MPV deformity (IMA), which was not different from that of the final MPA ≤20° subgroup (Table 7; Supplemental Table S6). The preoperative and postoperative greater HV deformity (MPA) of some feet compared with others with a similar MPV deformity (IMA) could have resulted from the shorter and contracted lateral head of the flexor hallucis brevis tendon (Supplemental Fig. S1, case 1230). Despite their residual HV deformities, most of these patients were very satisfied with their painless and strong foot function in walking. We attribute their functional improvement to the truly reduced intermetatarsal gap (Fig. 5A,D) and forefoot widths, nondistortional first metatarsal realignment technique, and improved plantar pressure redistribution in walking, evidenced by the consistently reduced metatarsal calluses (24) (Supplemental Fig. S1). Because of the unexpectedly high finding of residual HV, we have started performing partial release of the adductor hallucis tendon in feet with a preoperative HV deformity with an MPA >30°. However, management of possible lateral flexor hallucis brevis tendon contracture has not yet been determined. No patients with residual HV deformity wanted to undergo the Akin osteotomy for cosmetic improvement.

We strongly believe that it was the intended intermetatarsal connective soft tissue bonding that was the mechanism responsible for the first metatarsal stabilization after the syndesmosis procedure. It has also been suggested that “first interspace adhesion” is contributory to the maintenance of “the corrected first metatarsal alignment” after osteotomy procedures (41). If the latter is true, the syndesmosis concept for first metatarsal stabilization would be further validated.

We also believe that the postoperative stress fracture complication of the second metatarsal could have been precipitated by cerclage suture compression-erosion injury to its cortex. Consequently, a minimetal plate on the lateral surface of the second metatarsal has been introduced to protect it from the cerclage sutures. Future studies will determine whether these procedural modifications provide any beneficial effects.

The present study had some limitations. Strong clinical and radiologic evidence of the syndesmosis effect was presented. However, to truly understand its biologic and mechanical nature will require future related studies. The present study comprised patients from a practice that applied the syndesmosis procedure exclusively for HV

deformity correction. Our results could have been biased by our experience, which might not be readily reproduced by others without sufficient practice. We also realize that surgeons assessing their patients' radiographic outcomes imparts some degree of bias; however, our use of the AOFAS score, the subjective component of which has been shown to produce valid information pertaining to foot-related quality of life (42), importantly substantiates the 5-year durability of the improvement achieved with the syndesmosis procedure. To diminish single surgeon reporting bias, the complete radiographic database for the present study has been provided online as Supplemental Fig. S1 for reference and verification. One excluded patient (1 foot; Supplemental Fig. S1, case 1243) was unhappy with the recurrence of her deformity and refused to return for her final fifth year examination. Her inclusion would have reduced some of the exclusion bias in our findings (Supplemental Table S8).

In conclusion, the present study has provided evidence that the syndesmosis-like soft tissue bonding between the first and second metatarsals can stabilize the first metatarsal and prevent MPV deformity recurrence for 5 years. The syndesmosis procedure produced satisfactory results and can be considered an effective and safe alternative to the current osteotomy and arthrodesis procedures for HV deformity correction.

Acknowledgments

We would like to thank clinical assistant, Ms. Rachel Tam, for her capable and dedicated assistance in conducting the radiologic images and photographs of the entire study cohort throughout the entire study period and measuring all their radiologic variables. She also organized the image gallery for Supplemental Fig. S1. Thanks also to Ms. Grace Lam for tracking the patients and constructing all Excel tables.

Supplementary Material

Supplementary material associated with this article can be found in the online version at <https://doi.org/10.1053/j.jfas.2017.10.012>.

References

- Pinney SJ, Song KR, Chou LB. Operative treatment of mild hallux valgus deformity: the state of practice among academic foot and ankle surgeons. *Foot Ankle Int* 27:970–973, 2006.
- Pinney SJ, Song KR, Chou LB. Operative treatment of severe hallux valgus: the state of practice among academic foot and ankle surgeons. *Foot Ankle Int* 27:1024–1029, 2006.
- Truslow W. Metatarsus primus varus or hallux valgus. *J Bone Joint Surg* 7:98–108, 1925.
- Bock P, Kluger R, Kristen KH, Mittlböck M, Schuh R, Trnka HJ. The scarf osteotomy with minimally invasive lateral release for treatment of hallux valgus deformity. *J Bone Joint Surg Am* 97:1238–1245, 2015.

5. Kilmartin TE, Barrington RL, Wallace WA. Metatarsus primus varus: a statistical study. *J Bone Joint Surg Br* 73:937–940, 1991.
6. Bock P, Lanz U, Kröner A, Grabmeier G, Engel A. The scarf osteotomy: a salvage procedure for recurrent hallux valgus in selected cases. *Clin Orthop Relat Res* 468:2177–2187, 2010.
7. Shibuya N, Jupiter DC, Plemmons BS, Martin L, Thorud JC. Correction of hallux valgus deformity in association with underlying metatarsus adductus deformity. *Foot Ankle Spec* 2017. doi:10.1177/1938640017690441. [Epub ahead of print].
8. Tanaka Y, Takakura Y, Sugimoto K, Kumai T, Sakamoto T, Kadono K. Precise anatomic configuration changes in the first ray of the hallux valgus foot. *Foot Ankle Int* 21:651–656, 2000.
9. Myerson MS, Badekas A. Hypermobility of the first ray. *Foot Ankle Clin* 5:469–484, 2000.
10. Jeuken RM, Schotanus MG, Kort NP, Deenik A, Jong B, Hendrickx RP. Long-term follow-up of a randomized controlled trial comparing scarf to chevron osteotomy in hallux valgus correction. *Foot Ankle Int* 37:687–695, 2016.
11. Akpınar E, Buyuk AF, Cetinkaya E, Gursu S, Ucpınar H, Albayrak A. Proximal intermetatarsal divergence in distal chevron osteotomy for hallux valgus: an overlooked finding. *J Foot Ankle Surg* 55:504–508, 2016.
12. Ellington JK, Myerson MS, Coetzee JC, Stone RM. The use of the Lapidus procedure for recurrent hallux valgus. *Foot Ankle Int* 32:674–680, 2011.
13. Duan X, Kadakia AR. Salvage of recurrence after failed surgical treatment of hallux valgus. *Arch Orthop Trauma Surg* 132:477–485, 2012.
14. Sorensen MD, Hyer CF. Metatarsus primus varus correction: the osteotomies. *Clin Podiatr Med Surg* 26:409–425, 2009.
15. Raikin SM, Miller AG, Daniel J. Recurrence of hallux valgus: a review. *Foot Ankle Clin* 19:259–274, 2014.
16. Iyer S, Demetropoulos CA, Sofka CM, Ellis SJ. High rate of recurrence following proximal medial opening wedge osteotomy for correction of moderate hallux valgus. *Foot Ankle Int* 36:756–763, 2015.
17. Faber FWM, van Kampen PM, Bloembergen MW. Long-term results of the Hohmann and Lapidus procedures for the correction of hallux valgus. *Bone Joint J* 95-B:1222–1226, 2013.
18. Mann RA, Pfeffinger L. Hallux valgus repair. DuVries modified McBride procedure. *Clin Orthop* 213–218, 1991.
19. Johnson JE, Clanton TO, Baxter DE, Gottlieb MS. Comparison of chevron osteotomy and modified McBride bunionectomy for correction of mild to moderate hallux valgus deformity. *Foot Ankle* 12:61–68, 1991.
20. Yucel I, Tenekecioglu Y, Ogut T, Kesmezacar H. Treatment of hallux valgus by modified McBride procedure: a 6-year follow-up. *J Orthop Traumatol* 11:89–97, 2010.
21. Botteri G, Castellana A. L'Osteodesi distale dei due primi metatarsi nella cula dell'alluce valgo. *La Clinica Orthopedica* 13:139, 1961.
22. Pagella P, Pierleon GP. Hallux valgus and its correction. *LO Scalpello* 1:55–64, 1971.
23. Irwin LR, Cape J. Intermetatarsal osteodesis: a fresh approach to hallux valgus. *Foot* 9:93–98, 1999.
24. Wong DWC, Wu DY, Leung AKL. Syndesmosis procedure for the treatment of hallux valgus: good clinical and radiological results two years post-operatively. *Bone Joint J* 96-B:502–507, 2014.
25. Wu DYA. Retrospective study of 63 hallux valgus corrections using the osteodesis procedure. *J Foot Ankle Surg* 54:406–411, 2015.
26. Wu DY, Lam KF. Osteodesis for hallux valgus correction: is it effective? *Clin Orthop Relat Res* 473:328–336, 2015.
27. Dayton P, Sedberry S, Feilmeier M. Complications of metatarsal suture techniques for bunion correction. *J Foot Ankle Surg* 54:230–232, 2015.
28. Hardy RH, Clapham JC. Observations on hallux valgus: based on a controlled series. *J Bone Joint Surg Br* 33-B:376–391, 1951.
29. Yasuda T, Okuda R, Jotoku T, Shima H, Hida T, Neo M. Proximal supination osteotomy of the first metatarsal for hallux valgus. *Foot Ankle Int* 36:696–704, 2015.
30. Dayton P, Feilmeier M, Kauwe M, Holmes C, McArdle A, Coleman N. Observed changes in radiographic measurements of the first ray after frontal and transverse plane rotation of the hallux: does the hallux drive the metatarsal in a bunion deformity? *J Foot Ankle Surg* 53:584–587, 2014.
31. Stainsby GD. Pathological anatomy and dynamic effect of the displaced plantar plate. *Ann R Coll Surg Engl* 79:58–68, 1997.
32. Coughlin MJ, Jones CP, et al. Hallux valgus and first ray mobility: a cadaveric study. *Foot Ankle Int* 25:537–544, 2004.
33. Pentikainen I, Ojala R, Ohtonen P, Piippo J, Leppilähti J. Preoperative radiological factors correlated to long-term recurrence of hallux valgus following distal chevron osteotomy. *Foot Ankle Int* 35:1262–1267, 2014.
34. Schneider W, Knahr K. Keller procedure and chevron osteotomy in hallux valgus: five-year results of different surgical philosophies in comparable collectives. *Foot Ankle Int* 23:321–329, 2002.
35. Berg RP, Olsthoorn PG, Pöll RG. Scarf osteotomy in hallux valgus: a review of 72 cases. *Acta Orthop Belg* 73:219–223, 2007.
36. Chow FY, Lui TH, Kwok KW, Chow YY. Plate fixation for crescentic metatarsal osteotomy in the treatment of hallux valgus: an eight-year followup study. *Foot Ankle Int* 29:29–33, 2008.
37. Chong A, Nazarian N, Chandrananth J, Tacey M, Shepherd D, Tran P. Surgery for the correction of hallux valgus: minimum five-year results with a validated patient-reported outcome tool and regression analysis. *Bone Joint J* 97-B:208–214, 2015.
38. Akman YE, Yalçınkaya M, Çirçi E, Atıcı Y, Öztürkmen Y, Doğan A. Modified Simmonds-Menelaus procedure for moderate or severe adult hallux valgus. *Acta Orthop Traumatol Turc* 49:648–653, 2015.
39. Dermon A, Tilkeridis C, Lyras D, Tryfonidis M, Petrou C, Tzanis S, Kazakos K, Petrou G. Long-term results of Mitchell's procedure for hallux valgus deformity: a 5- to 20-year followup in 204 cases. *Foot Ankle Int* 30:16–20, 2009.
40. Coughlin MJ, Man RA. Hallux valgus: forefoot. In: *Surgery of the Foot and Ankle*, ed 8, Vol. I, pp. 210–213, edited by P Hetherington, Mosby, Philadelphia, PA, 2007.
41. Roukis TS, Landsman AS. Hypermobility of the first ray: a critical review of the literature. *J Foot Ankle Surg* 42:377–390, 2003.
42. Ibrahim T, Beiri A, Azzabi M, Best AJ, Taylor GJ, Menon DK. Reliability and validity of the subjective component of the American Orthopaedic Foot and Ankle Society clinical rating scales. *J Foot Ankle Surg* 46:65–74, 2007.