

Herpes zoster and its neurological complications

C.M. Chang, E. Woo, Y.L. Yu, C.Y. Huang and D. Chin

Department of Medicine, Queen Mary Hospital, University of Hong Kong, Hong Kong.

Summary: Ninety-three Chinese patients with cutaneous herpes zoster were seen during a 4-year period. Thoracic zoster occurred most commonly, followed by ophthalmic, cervical and lumbosacral zoster. Neurological complications were present in eleven patients (11.8%), the commonest being Ramsay-Hunt syndrome and segmental limb paresis. The clinical picture, pathogenesis, treatment and outcome of segmental limb paresis, myelitis and delayed contralateral hemiparesis following zoster ophthalmicus are discussed. Nine immunocompromised patients received intravenous adenine arabinoside (vidarabine) or acycloguanosine (acyclovir), and no cutaneous or visceral spread occurred in these patients.

Introduction

Herpes zoster infection is a common condition with predominantly cutaneous involvement along the dermatomes. Neurological complications beyond the posterior root ganglia and the first-order sensory neurones are infrequent. We undertook a retrospective analysis of the pattern of cutaneous involvement, the neurological complications and their outcome in 93 Chinese patients seen over a 4-year period.

Materials and methods

Patients under the care of the University Medical Unit, Queen Mary Hospital, Hong Kong between January 1981 and December 1984 with a diagnosis of herpes zoster were reviewed, with particular emphasis on the nature of any underlying disorder, the pattern of cutaneous involvement and the neurological complications. Those patients with definite motor complications were reassessed to determine their prognostic outcome. The use of intravenous adenine arabinoside (vidarabine) or acycloguanosine (acyclovir) for herpes zoster in 9 immunocompromised patients was also evaluated.

Results

Ninety-three patients were identified with a diagnosis of herpes zoster, and their age and sex distribution are shown in Figure 1. There were 34 males and 59

females. Their median age was 57 years with a range of 13 to 96 years; 69% of them were aged 50 or above. Eighty-five patients were hospitalized on account of the herpes zoster; the other eight (8.6%) patients developed shingles while in hospital for another medical illness.

Twenty-one patients (22.6%) had underlying diseases (Table I), mainly haematological malignancy, diabetes mellitus and systemic lupus erythematosus (SLE). Twelve of these 21 patients, including all 5 with SLE, were on steroid therapy at the time of the zoster infection.

The pattern of cutaneous involvement is shown in Table II. The thoracic dermatomes were most commonly affected, followed by the ophthalmic division of the trigeminal nerve, and the cervical and lumbosacral dermatomes.

Table I Underlying diseases in 21 patients with cutaneous herpes zoster

| | Number |
|--|--------|
| Hodgkin's lymphoma | 3 |
| Non-Hodgkin's lymphoma | 1 |
| Leukaemia | 1 |
| Myeloproliferative disorder | 1 |
| Nasopharyngeal carcinoma | 1 |
| Bronchogenic carcinoma | 1 |
| Carcinoma of bladder | 1 |
| Diabetes mellitus | 5 |
| System lupus erythematosus (on steroids) | 5 |
| Chronic obstructive airway disease (on steroids) | 1 |
| Weber-Christian disease (on steroids) | 1 |

Correspondence: E. Woo, M.B., B.S.(H.K.), M.R.C.P. (U.K.)

Accepted: 10 September 1986

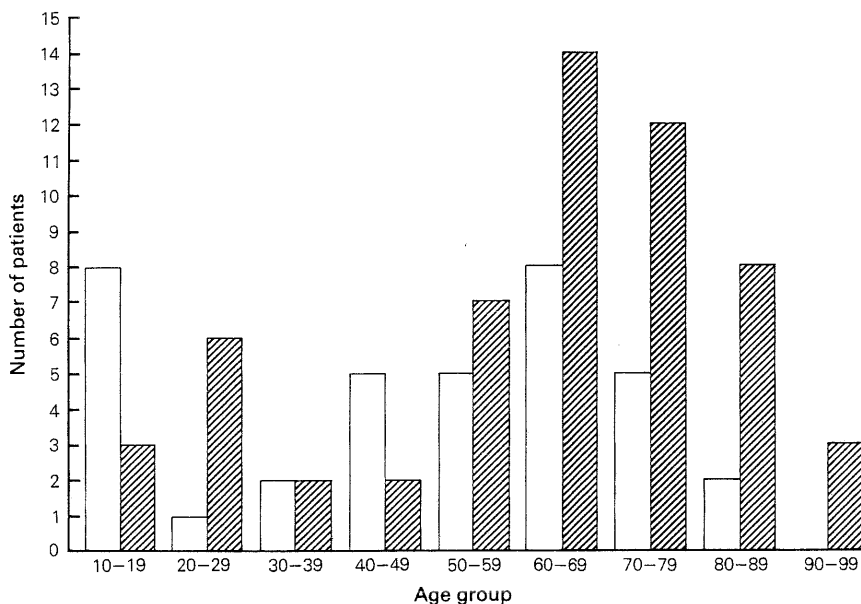


Figure 1 Age and sex distribution of 93 patients with herpes zoster; □ male; ▨ female.

Neurological complications occurred in 11 patients (11.8%) and the clinical data of these patients are presented in Table III. There were 3 patients with Ramsay-Hunt syndrome, 3 with segmental limb paresis, 2 with myelitis and 1 each with delayed contralateral hemiparesis, third nerve palsy and meningitis. Underlying diseases were present in 4 of these 11 patients.

The interval between the cutaneous zoster and the neurological complication ranged from simultaneous presentation to two and a half weeks, and was within one week in the majority of cases. In no patient did the neurological complication precede the cutaneous manifestation. The neurological complication evolved

over hours in 4 patients and over days in 7. The degree of disability was graded as mild in 1, moderate in 6 and severe in 4.

Computed tomographic (CT) scan of the brain was performed in 3 patients, being normal in patient 1, with delayed contralateral hemiparesis, and patient 2, with third nerve palsy, but showing mild cerebral oedema in patient 11, who had meningitis. Cerebral angiography in the patient with delayed contralateral hemiparesis showed carotid siphon stenosis. Myelography was performed in patient 9 with acute spinal cord syndrome and this was normal. The cerebrospinal fluid (CSF) showed changes consistent with aseptic meningitis in patient 11, but was normal in the 2 patients with myelitis (patients 9 and 10) and in patient 2. Electromyographic (EMG) changes of denervation were present in all 3 patients (6, 7 and 8) with segmental limb paresis.

A 4 week course of steroid therapy was given to patient 1 with delayed contralateral hemiparesis. The other 10 patients were given supportive treatment only. They did not receive any steroid or antiviral therapy. Eight patients made a complete recovery in a period ranging from 1 week to 9 months, with the majority having recovered within 3 months. Two patients had partial recovery and one was lost to follow-up.

Intravenous vidarabine (10 mg/kg/day for one week) was given to 7 patients and intravenous acyclovir (500 mg/m² every 8 hours for one week) to 2 patients. These 9 patients were immunocompromised

Table II Cutaneous distribution of herpes zoster in 93 patients

| | | Number of cases |
|-------------|------------|-----------------|
| Trigeminal | ophthalmic | 19 |
| | maxillary | 6 |
| | mandibular | 2 |
| Otic | | 3 |
| Cervical | | 14 |
| Thoracic | | 45 |
| Lumbosacral | | 9 |

Table III Clinical data of the 11 patients with neurological complications

| Patient | Sex/Age | Cutaneous | Underlying disease | Complication | Interval | Onset | Severity | Investigations | Outcome |
|---------|---------|--------------|-----------------------------|--|--------------|----------|----------|---|-------------------|
| 1 | M/52 | R ophthalmic | Myeloproliferative disorder | Delayed contralateral hemiparesis | 2½ weeks | subacute | mild | CT normal Angiography R carotid siphon stenosis | CR 2 weeks |
| 2 | F/74 | R ophthalmic | Diabetes mellitus | R third nerve palsy | 3 days | subacute | moderate | CT and CSF normal | Lost to follow up |
| 3 | F/16 | R otic | nil | R facial palsy | simultaneous | acute | moderate | | CR 2 months |
| 4 | F/22 | R otic | nil | R facial palsy | simultaneous | acute | severe | | PR 6 months |
| 5 | M/40 | L otic | nil | L facial palsy | simultaneous | acute | moderate | | CR 3 months |
| 6 | F/73 | R C4 to C7 | nil | Segmental C6, C7, C8 paresis of R upper limb | 1 day | subacute | severe | EMG denervation changes | CR 7 months |
| 7 | F/78 | R C5 to C7 | Diabetes mellitus | Segmental C5, C6, C7 paresis of R upper limb | 3 days | subacute | moderate | EMG denervation changes | CR 9 months |
| 8 | M/67 | L C5 to C6 | nil | Segmental C5, C6 paresis of L upper limb | 2 weeks | subacute | moderate | EMG denervation changes | CR 3 months |
| 9 | M/68 | L T3 | nil | Myelitis | simultaneous | subacute | moderate | CSF normal | CR 1 week |
| 10 | F/62 | L T9 | Lymphoma | Myelitis | 5 days | acute | severe | Myelogram and CSF normal | PR 4 weeks |
| 11 | M/15 | L T7 | nil | Meningitis | 5 days | subacute | severe | CT mild cerebral oedema CSF lymphocytic pleocytosis with elevated protein and normal glucose | CR 3 weeks |

L = left, R = right, CT = computed tomography, CSF = cerebrospinal fluid, EMG = electromyography, CR = complete recovery, PR = partial recovery.

with either a haematological malignancy or SLE. Cutaneous spread, visceral dissemination or neurological complications did not occur in any of them.

Discussion

Herpes zoster is a common cutaneous infection and is due to the reactivation of the varicella-zoster virus in the posterior root ganglion.¹ The exact incidence in Hong Kong is not known, but in a large English series, the incidence was reported as 3.4 per 1,000,¹ being higher in immunocompromised patients. It usually affects the elderly but no age group is spared. The age distribution and the pattern of involvement in our patient population are similar to other reported series.^{1,2} However, our patient population belongs to a highly selected group as we have included only hospitalized subjects. It is therefore obvious that we have more patients with underlying malignancy or other predisposing systemic diseases. Furthermore, 8.6% of our patients developed zoster eruption whilst inpatients receiving specific therapy for their underlying problems. It is also interesting to note a female preponderance in our series, which probably reflects the predominance of females in our elderly population.

Motor complications are uncommon and occur in 5% of all cases of herpes zoster.³ Our higher figure of 11.8% probably reflects selection bias as patients having complications are more likely to be hospitalized. Of cranial nerve involvement, the most widely known is the Ramsay-Hunt syndrome with facial nerve paralysis. Other cranial nerves are seldom involved.² Third nerve palsy associated with ophthalmic zoster is a rare but well-recognized condition.^{4,5,6} We encountered one case in our series. Although the associated diabetes mellitus may have caused the third nerve palsy, the temporal relationship with the infection and the pupillary involvement would favour this being a complication of ophthalmic zoster.

Segmental limb paresis occurred in 3.2% of patients in this series which is comparable to the 2.5% figure in a large series by Thomas & Howard with 1,210 patients.² In their series, the incidence of underlying malignancy was 3 times higher in patients with segmental zoster paresis than in those with cutaneous zoster alone, while none of our 3 patients had any underlying malignancy. The onset of weakness is usually acute and occurs within days of the cutaneous rash. Occasionally it may precede the cutaneous rash and the diagnosis may then be difficult.⁷ Muscle weakness usually occurs in the same segments as the cutaneous rash but weakness in less than 10% of cases may also occur in widely separated segments.² Paresis is more common with the upper than the lower limbs.

Although neurogenic changes are demonstrated by EMG, it is uncertain whether the pathology lies in the anterior horn cells or in the anterior nerve root because of the lack of detailed neuro-pathological examination. However, the frequent reversibility of the motor deficits would favour primary affliction of the nerve root rather than the nerve cells.⁸ With physiotherapy alone, ultimate recovery is good in 70–80% of cases although this may take a few months to a few years. All our 3 cases had excellent recovery within a period of 3 to 9 months, indicating the benign course of this motor complication.

Other neurological complications of zoster include encephalitis, meningitis, myelitis, polyneuritis and, rarely, delayed contralateral hemiparesis following ophthalmic zoster.

Herpes zoster myelitis is a rare complication. In the series of Thomas and Howard, there was only 1 patient out of 1,210.² The pathogenesis of the cord lesion is not fully understood as pathological confirmations are few and difficult to obtain. Direct viral invasion of the cord was demonstrated in one autopsy case.⁹ There was extensive serpentine necrosis of the cord extending through many segments. Moreover, typical nuclear inclusions were seen and the varicella-zoster virus was isolated from the destroyed cord. Apart from direct viral invasion of the cord, destruction by an autoimmune vasculitis has also been proposed as a pathogenetic mechanism.^{10,11} Spontaneous recovery is not uncommon.¹² Our 2 patients recovered spontaneously in one week and 4 weeks respectively. However, relentless ascending myelitis ending in death has also been reported.^{9,11,13} A recent report described arrest of progression of myelitis in one case with intravenous vidarabine treatment¹⁴ and another reported improvement in one case,¹⁵ but the use of intravenous acyclovir in zoster myelitis has so far not been reported.

Fifty-one cases of herpes zoster ophthalmicus complicated by delayed contralateral hemiparesis were recently reviewed.¹⁶ Histological confirmation was obtained in 14 patients; the diagnosis in the remainder was based on circumstantial evidence. It is postulated that a direct spread of the virus along the ophthalmic division of the trigeminal nerve to the wall of ipsilateral main proximal branches of the circle of Willis results in necrotizing angiitis with thrombosis,^{17,18} although *in situ* thrombosis without inflammatory vasculitis has also been reported.¹⁹ The mortality is around 20%, being especially high among those with clinical features of meningoencephalitis or diffuse granulomatous angiitis.²⁰ We encountered only one patient with delayed contralateral hemiparesis among 19 with ophthalmic zoster. Although there was no histological confirmation, the temporal relationship to the ophthalmic zoster, the lack of risk factors for cerebral thrombosis and the

angiographic demonstration of siphon stenosis would favour this being a complication of the zoster infection. This patient did not have signs of diffuse involvement and he made a good recovery.

For immunocompromised patients, intravenous vidarabine or acyclovir has been shown to be effective in preventing potentially fatal cutaneous and visceral dissemination.^{21,22} Therapy administered within 72 hours of the onset of cutaneous zoster confers the greatest benefit. Our 9 immunocompromised patients were treated (7 with vidarabine and 2 with acyclovir) and none developed cutaneous or visceral spread. Specific anti-viral treatment is therefore indicated in these patients and acyclovir is preferred to vidarabine because of its greater efficacy in zoster infection²³ and better solubility. Moreover, the relative lack of renal or marrow toxicity renders acyclovir particularly suitable for patients with concomitant renal or

haematological diseases, although judicious use of this drug with appropriate dosage adjustment must be emphasized.

In immunocompetent patients, intravenous acyclovir improves the rate of cutaneous healing and decreases pain in acute zoster although it does not decrease the incidence of post-herpetic neuralgia.^{24, 25} With its high cost and inconvenience of administration, routine use of intravenous acyclovir in immunocompetent subjects with herpes zoster is hard to justify. Oral acyclovir, still under clinical trial,^{26, 27} may, however, have a promising role in the future.

Acknowledgement

We wish to thank Mrs Shirla Tam and Mrs Monica Chan for secretarial assistance.

References

- Hope-Simpson, R.E. The nature of herpes zoster: A long term study and a new hypothesis. *Proc Roy Soc Med* 1965, **58**: 9–20.
- Thomas, J.E. & Howard, F.M. Segmental zoster paresis – a disease profile. *Neurology (Minneapolis)* 1972, **22**: 459–466.
- Grant, B.D., Rowe, C.R. Motor paralysis of the extremities in herpes zoster. *J Bone Joint Surg* 1961, **43A**: 885–896.
- Godtfredsen, E. Pathogenesis of cranial nerve lesions, notably ophthalmoplegias, complicating herpes zoster ophthalmicus. *Acta Psychiatr (Kbh)* 1948, **23**: 69–77.
- Kendall, D. Motor complications of herpes zoster. *Br Med J* 1957, **2**: 616–618.
- Payten, R.J. & Dawes, J.D.K. Herpes zoster of the head and neck. *J Laryngol Otol* 1972, **86**: 1031–1055.
- Taterka, J.H. & O'Sullivan, M.E. The motor complication of herpes zoster. *JAMA* 1943, **122**: 737–739.
- Schliack, H. & Schnedider, H. Segmentale motorische Paresen beim Zoster. *Deutsch Med Wschr* 1969, **94**: 1861–1866.
- Hogan, E.L. & Krigman, M.R. Herpes zoster myelitis: Evidence for viral invasion of spinal cord. *Arch Neurol* 1973, **29**: 309–313.
- Applebaum, E., Kreps, S.I. & Sunshine, A. Herpes zoster encephalitis. *Am J Med* 1962, **32**: 25–31.
- Rose, F.C., Brett, E.M. & Burston, J. Zoster encephalomyelitis. *Arch Neurol* 1964, **11**: 155–172.
- Harrison, R.J. Zoster myelitis presenting with acute retention of urine. *Proc Roy Soc Med* 1964, **57**: 589–590.
- Cole, M. Myelopathy associated with herpes zoster. *Rocky Mt Med J* 1978, **75**: 317–319.
- Muder, R.R. & Lumish, R.M. Myelopathy after herpes zoster. *Arch Neurol* 1983, **40**: 445–446.
- Corston, R.N., Logsdail, S. & Godwin-Austen, R.B. Herpes zoster myelitis treated successfully with vidarabine. *Br Med J* 1981, **283**: 698–699.
- Reshef, E., Greenberg, S.B. & Jankovic, J. Herpes zoster ophthalmicus followed by contralateral hemiparesis: report of two cases and review of literature. *J Neurol Neurosurg Psychiatry* 1985, **48**: 122–127.
- Linnemann, C.C. & Alvira, M.M. Pathogenesis of varicella-zoster angitis in the CNS. *Arch Neurol* 1980, **37**: 239–240.
- Gasperetti, C. & Song, S.K. Contralateral hemiparesis following herpes zoster ophthalmicus. *J Neurol Neurosurg Psychiatry* 1985, **48**: 338–341.
- Eidelberg, D., Sotrel, A., Horoupian, D.S., Neumann, P.E., Pumarola-Sune, T. & Price, R.W. Thrombotic cerebral vasculopathy associated with herpes zoster. *Ann Neurol* 1986, **19**: 7–14.
- Rosenblum, W.L. & Hadfield, M.G. Granulomatous angitis of nervous system in cases of herpes zoster and lymphosarcoma. *Neurology (Minneapolis)* 1972, **22**: 348–354.
- Whitley, R.J., Soong, S.J. & Dolin, R. Early vidarabine therapy to control the complications of herpes zoster in immunosuppressed patients. *N Eng J Med* 1982, **307**: 971–975.
- Balfour, H.H., McMonigal, K.A. & Bean, B. Acyclovir therapy of varicella-zoster virus infections in immunocompromised patients. *J Antimicrob Chemother* 1983, **12**: (Suppl. B): 169–179.
- Shepp, D.H., Dandliker, P.S. & Meyers, J.D. Treatment of varicella-zoster virus infection in severely immunocompromised patients. *N Engl J Med* 1986, **314**: 208–212.
- Peterslund, N.A., Seyer-Hansen, K., Ipsen, J., Esmann, V., Schonheyder, H., Juhl, H. Acyclovir in herpes zoster. *Lancet* 1981, **ii**: 827–830.
- Bean, B., Braun, C., & Balfour, H.H. Jr. Acyclovir therapy for acute herpes zoster. *Lancet* 1982, **ii**: 118–121.
- Finn, R. & Smith, M.A. Oral acyclovir for herpes zoster. *Lancet* 1984, **ii**: 575.
- McKendrick, M.W., McGill, J.I., Bell, A.M., Hickmott, E. & Burke, C. Oral acyclovir for herpes zoster. *Lancet* 1984, **ii**: 925.