

## UPDATE ARTICLE

### Conservative Surgery For Breast Cancer

Ronnie T.P. Poon\*, FRCS(Edin)

Medical Officer

Louis W.C. Chow, FRCS(Glas), FHKAM(Surgery)

Lecturer

Gordon K.H. Au, FRCR, FHKAM(Radiology)

Consultant

Department of Surgery and Radiotherapy

Queen Mary Hospital

#### Abstract

*Modified radical mastectomy has been the traditional surgical treatment of early breast cancer but in recent years breast conserving surgery has been used with no significant difference in local recurrence and survival rates. This article describes the principle of breast conservation therapy, reviews the outcome of trials of breast conservation therapy and discusses the criteria for selecting patients with early breast cancer for breast conservation therapy. The results of 64 breast conserving surgery performed in Queen Mary Hospital from 1986-1994 are presented. Ten patients (16%) developed local recurrence and seven of them had salvage mastectomy. The five year survival rate was 85%, comparable to Western series.*

**Keywords:** Breast cancer, breast conservation surgery

#### Introduction

The incidence of breast cancer in Hong Kong has increased by 30% since 1981.<sup>1</sup> It is the second leading cause of death among women in Hong Kong.

Surgery remains the only hope of cure for early operable breast cancer. Operable breast cancer can be defined as a mobile tumour in the breast with or without mobile axillary lymph nodes in the absence of obvious distant metastasis. The main objective of surgery is to eradicate local disease and prevent loco-regional recurrence. Up to early 1980s, surgical treatment of breast cancer almost always involved total removal of the breast, in the form of either radical mastectomy or more popularly modified radical mastectomy. However, mastectomy results in loss of body image and psychological trauma in many patients. Studies have documented high levels of anxiety, depression and sexual dysfunction among those who have had mastectomy, sometimes severe enough to require psychiatric intervention.<sup>2-3</sup> This has led to the increasing use of breast conserving surgery in the last decade.

#### Principle of Conservation Therapy for Breast Cancer

Different techniques and terms have been used for conservative breast surgery. The terms 'lumpectomy', 'tumourectomy', and 'tylectomy' imply removal of the tumour mass with a minimal margin of normal breast tissue around it. Wide local excision or segmental mastectomy implies excision of the tumour with at least 1 cm tumour free margin. Because of the propensity for ductal carcinoma to spread towards the nipple along the ducts, Veronesi *et al* used a more aggressive approach of excision of a breast quadrant (quadrantectomy) which included excision of the overlying skin and underlying pectoralis major fascia.<sup>4</sup> This more extensive resection theoretically reduces local recurrence but at the expense of more cosmetic deformity.

\*Address for correspondence: Dr. Ronnie T.P. Poon, Department of Surgery, Queen Mary Hospital, Hong Kong.

After local excision of the tumour, radiotherapy should be given to the remaining breast tissue, first to eradicate any residual microscopic disease at the site of primary tumour, and second, to treat other possible foci of invasive or in-situ cancer elsewhere in the remaining breast tissue. This has been shown to reduce the risk of local recurrence after conservative surgery.<sup>5</sup> Two prospective studies with short follow-up suggest that breast irradiation can be safely omitted in patients with small (<2cm) completely excised unifocal tumours found on mammogram.<sup>6-7</sup> However, until further studies have clarified the need of irradiation in small completely excised tumours, the current recommendation is that all patients should have post-operative radiotherapy after conservative surgery for breast cancer.

About 50% of patients with symptomatic operable breast cancer have axillary lymph node metastasis at the time of presentation but clinical assessment of axillary node involvement is notoriously unreliable with an overall error rate of approximately 30%.<sup>8</sup> The management of the axilla in early breast cancer is controversial.<sup>8</sup> Axillary dissection gives excellent local tumour control but axillary irradiation has been shown to be as effective, with long term recurrence rate of less than 2%.<sup>9</sup> However, axillary irradiation can result in an uncommon but serious complication of radiation-

induced brachial plexus neuropathy. Another drawback of axillary irradiation is that it does not give information on prognosis nor identify the group of patients with positive lymph nodes who will benefit most from systemic adjuvant therapy. Axillary lymph node sampling instead of dissection reduces complication rate but is often inaccurate.<sup>10-11</sup> We consider wide local excision, plus axillary dissection and post-operative breast irradiation as the best form of breast conservation therapy.

### Outcome of Breast Conservation Surgery vs Mastectomy

Hayward and his colleagues reported the first randomized trial to compare radical mastectomy and wide local excision plus both breast and nodal irradiation in 1977.<sup>12</sup> In their trial conservative surgery resulted in increased local recurrence and decreased survival compared to radical treatment, but the dose and technique of radiotherapy used to treat the breast and axilla after local excision are now known to be inadequate. Five more recent large randomized prospective trials have shown no significant difference in local recurrence and survival in comparison between breast conservation surgery with mastectomy.<sup>4-5,13-15</sup> **Table 1** shows the results of these randomized trials.

**Table 1 : Randomized Trials of Conservative Breast Therapy for Breast Cancer**

Trial	Treatment arms	No. of patients	Follow up (yr)	Local relapse (%)	Survival (%)
Hayward <i>et al</i> 1977	RM + RT	130	10	8	68
	LE + RT	122		30	58
Veronesi <i>et al</i> 1990	RM	349	13	2	69
	QUART	352		3	71
Fisher <i>et al</i> 1989	MRM	590	8	8	71
	LE + AD	630		16	71
	LE + AD + RT	629		6	76
Sarrazin <i>et al</i> 1989	MRM	91	10	10	80
	LE + AD + RT	88		6	79
Litcher <i>et al</i> 1992	MRM	116	5	10	85
	LE + AD + RT	121		17	89
Blichert <i>et al</i> 1988	MRM	306	2	4	76
	LE + AD + RT	321		2	80

RM = radical mastectomy, MRM = modified radical mastectomy, RT = radiotherapy, LE = local excision, AD = axillary dissection, QUART = quadrantectomy, axillary dissection, and breast irradiation.

## Local Recurrence after Breast Conservation Surgery

The overall recurrence rate after breast conservation surgery is 3-6% although some series reported higher figures (Table 1). Local recurrence may be treated with salvage mastectomy and further conservative surgery is sometimes possible in small localized recurrence. However, ipsilateral breast tumour recurrence is a marker of risk of developing distant metastasis though it is not the cause of the metastasis.<sup>16</sup>

The identification of factors associated with breast recurrence after conservation surgery is important to help selecting appropriate patients for conservative surgery. The most important factors that predict increased risk of breast recurrence are:<sup>7</sup>

- Positive surgical margin
- Extensive DCIS (ductal carcinoma in-situ)
- Multiple tumours
- High nuclear grade of tumour

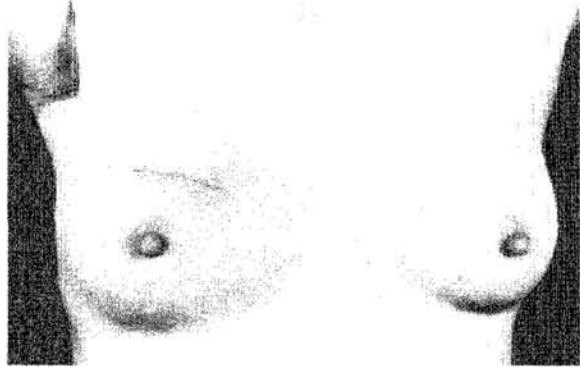
The size of tumour, tumour histological type and nodal status are not consistently associated with increased risk of local recurrence.<sup>18</sup>

## Cosmetic Result after Breast Conservation Surgery

An important goal of conservative breast surgery is a good cosmetic outcome after surgery and radiotherapy. The cosmetic result is affected by the extent and technique of local surgery and radiotherapy. Factors related to the operation that adversely affect cosmesis include large resection (especially in a small breast), large radial incision, same incision for breast resection and axillary dissection and re-excision of tumour bed, while factors related to radiotherapy include number of radiation fields and radiation boost dose.<sup>19</sup> The best cosmetic result is obtained with a circumferential incision for the lumpectomy and a separate axillary

incision for the axillary lymph node dissection, as shown in Figure 1.

Figure 1: Cosmetic Result after Wide Local Excision and Axillary Dissection

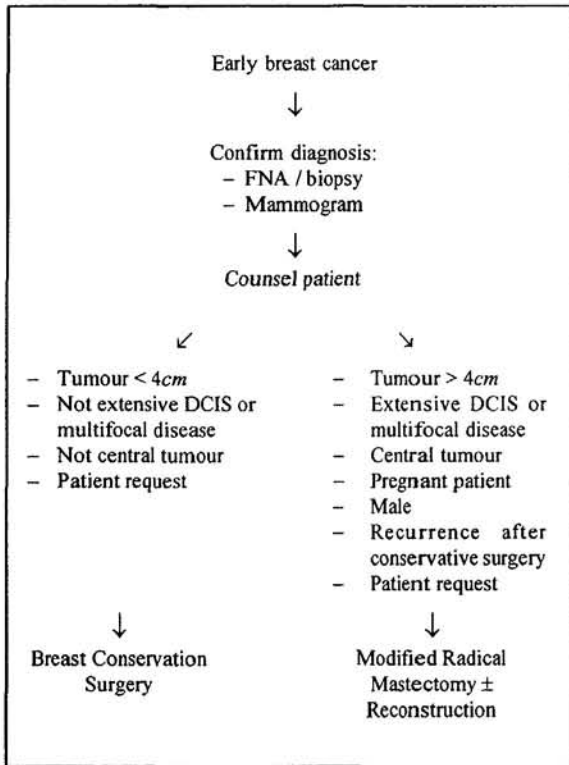


## Patient Selection for Breast Conservation Surgery

The important criteria for patient selection for breast conservation surgery are the feasibility of removing the primary tumour without causing serious cosmetic deformity or unacceptable risk of tumour recurrence. The size of the primary tumour is an important factor and tumours larger than 4cm are considered not suitable for breast conservation but the size of the tumour must be related to the size of the breast in the judgment. Central tumours are relative contraindication as such tumours are often diffuse and difficult to resect without major cosmetic deformity and many women will prefer mastectomy if the nipple has to be excised. Extensive DCIS and multifocal disease on mammogram are highly predictive of local recurrence and conservative surgery is contraindicated. Hence it is important to obtain mammography before consideration of surgical options. Breast conservation surgery is also inappropriate in male patients and pregnant patients. Patient's preference is important as some patients may prefer mastectomy to avoid the need of post-operative breast irradiation while some may feel more secure after mastectomy. Figure 2 summarizes the surgical management protocol for patients presenting with operable breast cancer in our centre.

## Conservative Surgery for Breast Cancer

Figure 2: Management of Early Breast Cancer



DCIS = Ductal Carcinoma In-Situ

### Local Experience

From 1986-1994 64 female patients underwent wide local excision and axillary dissection followed by breast irradiation in Queen Mary Hospital. The median age at diagnosis was 51 (range 24-81) years and 50% of patients were post-menopausal. The median tumour size was 2.5cm and 20% had axillary lymph node involvement. Ten (16%) patients developed recurrence in the ipsilateral breast and seven underwent salvage mastectomy. Five (8%) eventually died. The 5-year survival was 85%. The result was comparable to Western series.

### Conclusion

Breast conservation therapy is an established treatment option for early breast cancer. It produces similar survival rate when compared with radical or modified radical mastectomy, but it has the advantage

of improved cosmesis and hopefully a reduction in psychological trauma. The majority of early operable breast cancer patients are suitable candidates and with the earlier detection of breast cancer by screening, more patients may benefit from conservative surgery. There is a group of patients who should have mastectomy instead of conservative surgery, and reconstruction may be offered as an alternative to improve cosmesis. ■

### References

- Cheung PSY. Breast cancer in Hong Kong- the need for early detection. *JHK Med Assoc* 1992; 44: 298-252.
- McGuire WL, Clark GM. Prognostic factors and treatment decisions in axillary node-negative breast cancer patients. *N Eng J Med* 1992; 326: 1756-1761.
- Morris T, Greer HS, White P. Psychological and social adjustment to mastectomy: a two year follow-up study. *Cancer* 1977; 40: 2381-2387.
- Veronesi U, Banfi A, Salvadori B *et al*. Breast conservation is the treatment of choice in small breast cancer: long term results of a randomized trial. *Eur J Cancer* 1990; 26: 668-670.
- Fisher B, Redmond C, Poisson R *et al*. Eight year results of a randomized trial comparing a conservative treatment to mastectomy in early breast cancer. *N Eng J Med* 1989; 320: 822-828.
- The Uppsala-Orebro Breast Cancer Study Group. Sector resection with or without post-operative radiotherapy for stage breast cancer: a randomized trial. *J Nat Cancer Inst* 1990; 82: 277-282.
- Clark RM, McCulloch PB, Levine MN *et al*. A randomized clinical trial to assess the effectiveness of breast irradiation following lumpectomy and axillary dissection for node negative breast cancer. *J Nat Cancer Inst* 1992; 84: 683-689.
- Sacks NPM, Barr LC, Allan SM *et al*. The role of axillary dissection in operable breast cancer. *Breast* 1992; 1: 41-49.
- Mazeron JJ, Omezguine Y, Huart J *et al*. Conservative treatment of breast cancer: results of management of axillary lymph node in 3353 patients. *Lancet* 1985; 1(8442): 1387.
- Locker AP, Ellis IO, Morgan DAL, *et al*. Factors influencing local recurrence after excision and radiotherapy for primary breast cancer. *Br J Surg* 1989; 76: 890-894.
- Davies GC, Millis RR, Hayward JL. Assessment of axillary node status. *Ann Surg* 1980; 192: 148-151.
- Hayward JL. The Guy's trial of treatment of early breast cancer. *World J Surg* 1977; 1: 314-316.
- Sarrazin D, Le MG, Arriagada R *et al*. Ten-year results of a randomized trial comparing a conservative treatment to mastectomy in early breast cancer. *Radiother Oncol* 1989; 14: 177-184.
- Litcher AS, Lippman ME, Danforth DN *et al*. Mastectomy vs breast-conserving therapy in the treatment of stage 1 and 2 cancer of the breast: a randomized trial at the National Cancer Institute. *J Clin Oncol* 1992; 10: 976-983.
- Blichert-Toft M, Brincker M, Anderson JA *et al*. A Danish randomized trial comparing breast-preserving therapy with mastectomy in mammary carcinoma. *Acta Oncol* 1988; 27: 621-677.
- Fisher B, Anderson S, Fisher ER *et al*. Significance of ipsilateral breast tumour recurrence after lumpectomy. *Lancet* 1991; 338: 327-331.
- Stotter A, Atkinson EN, Fairstone BA *et al*. Survival following locoregional recurrence after breast conservation therapy for cancer. *Ann Surg* 1990; 212(2): 166-172.
- Kurtz JM. Factor influencing the risk of local recurrence in the breast. *Eur J Cancer* 1992; 28: 660-666.
- Haffty BG, Goldberg NB, Fisher D *et al*. Conservative surgery and radiation therapy in breast carcinoma: local recurrence and prognostic implications. *Int J Radiat Oncol Biol Phys* 1989; 17: 727-732.