

# HPV and p53 in cervical cancer

H Y S Ngan, M Stanley, S S Liu, H K Ma

## Abstract

**Objective**—To determine the prevalence of HPV 16 and 18 E6 by DNA detection and p53 abnormal protein expression in cervical cancers in Hong Kong.

**Materials and methods**—Seventy-three squamous cell cervical cancer biopsy were analysed. Detection of HPV DNA was carried out by the polymerase chain reaction and Southern blotting (PCR/SB) technique using primers to the HPV16 & 18 E6 region and consensus primers to the L1 region. Abnormal expression of the p53 protein was detected by immunohistochemical staining (IHS) using the antibody CM1 on frozen sections of 55 cervical cancer samples. Forty-six samples were analysed for both the presence of HPV DNA and abnormal expression of p53.

**Results**—67.2% of the 64 samples showed the presence of HPV 16 E6 DNA and 39.1% showed the presence of HPV 18 E6 DNA. 32.8% showed the presence of both HPV 16 and 18 E6 DNA. No HPV DNA was shown in 10.9% of samples. Only 3.6% (2) of 55 samples showed positive IHS with CM1. One occurred in a HPV negative sample and the other in a HPV positive sample.

**Conclusion**—A high prevalence of HPV DNA was detected in cervical cancer in Hong Kong using the PCR/SB technique. However, abnormal expression of p53 was uncommon amongst patients with or without HPV 16 or 18 infection.

(*Genitourin Med* 1994;70:167-170)

## Introduction

Human papillomaviruses (HPVs) are small double stranded DNA viruses which in the natural infection induce benign self-limiting proliferative lesions. There is a remarkable multiplicity of HPVs and about 65 types are recognised at present.<sup>1</sup> About 20 types infect the genital tract and a subset of these is associated with ano-genital cancer, particularly cervical carcinoma.<sup>2,3</sup> HPV DNA sequences have been found in at least 90% of cervical carcinomas in virtually all studies reported<sup>4</sup> with almost 100% of lesions positive in some studies.<sup>5</sup> In all studies the most frequently identified viral type is HPV 16 which is found in 50-70% of lesions followed by HPV 18 and to a lesser extent HPV 31, 33 and 35.<sup>3</sup> Furthermore the introduction of cloned HPV 16 or 18 DNA sequences into primary genital

keratinocytes results in the immortalisation of these cells<sup>6</sup> and this phenomenon requires only the expression of the early genes E6 and E7.<sup>7</sup>

Insight into the possible mechanisms by which the oncogenic HPVs exert their effects comes from observations of interactions between the E6 and E7 gene products and cellular proteins encoded by tumour suppressor genes. Thus the E7 protein of HPV 16 binds the retinoblastoma p105 protein<sup>8</sup> and HPV 16 or 18 E6 interacts with the p53 gene product.<sup>9-11</sup> Abnormal expression of p53 has been found in many human carcinomas, particularly breast and colon, predominantly as elevated levels of the protein as a consequence of point mutation. Abnormal expression of p53 can be due to either gene mutation or enhanced degradation of the normal gene product<sup>12</sup> and both pathways lead to a deregulation of crucial cell regulatory processes.<sup>13</sup> The observation that p53 mutations could be found in HPV negative cervical cancer cell lines<sup>14</sup> and HPV negative anal carcinomas<sup>15</sup> but not in HPV positive cell lines or lesions suggested an alternative mechanism for p53 inactivation in HPV containing cancers in which wild type p53 was rapidly degraded by the E6 gene product of oncogenic HPVs. In the present study we have examined the status of p53 expression by immunohistochemistry in a group of patients with cervical carcinoma in Hong Kong and determined the prevalence of HPV infection in these patients with the polymerase chain reaction (PCR) using both consensus and type specific primers. We show that the prevalence of HPV DNA in our cases is comparable to other studies although the incidence of double infections of HPV 16 and 18 is considerably higher. However, no association between the absence of HPV DNA and enhanced expression of p53 protein in the cancers could be shown.

## Materials and methods

Biopsies of squamous cell carcinoma of the cervix of 73 patients seen in the Department of Obstetrics and Gynaecology, University of Hong Kong, Queen Mary Hospital were taken before treatment and stored in liquid nitrogen. Only 46 of the 73 samples were big enough for both DNA extraction and frozen section. A total of 64 samples were extracted for DNA for detection of human papillomavirus by polymerase chain reaction and southern blot hybridization. Fifty-five samples were stained for the detection of p53 protein on frozen sections.

Department of  
Obstetrics and  
Gynaecology,  
University of Hong  
Kong, Queen Mary  
Hospital, Hong Kong  
H Y S Ngan  
S S Liu  
H K Ma

Department of  
Pathology, University  
of Cambridge, UK  
M Stanley

Address for correspondence:  
Dr Hextan Y S Ngan,  
Department of Obstetrics  
& Gynaecology, University  
of Hong Kong, Queen Mary  
Hospital, Pokfulam Road,  
Hong Kong.

Accepted for publication  
19 January 1994

*HPV 16 and 18 E6 and consensus primers  
PCR/Southern hybridisation*

High molecular weight DNA was extracted from cervical cancer tissue by proteinase K digestion followed by phenolchloroform extraction.<sup>16</sup> Polymerase chain reaction was carried out on 0.5 µg DNA in 50 µl reaction mixture using Taq polymerase (Perkin Elmer Cetus). The template DNA was denatured at 94°C for 1 minute, followed by 39 cycles of PCR as follows: annealing at 57°C for 1'15", polymerisation at 65°C for 2'15", then denaturation at 94°C for 1'15". The primers used for the E6 sequence were HPV 16A—TCA AAA GCC ACT GTG TCC TG; HPV 16B—GT GTT CTT GAT GAT CTG CA (120 bp); HPV 18A—ACC TTA ATG AAA AAC CAC GA; HPV 18B—CGT CGT TGG AGT CGT TCC TG (100 bp).<sup>17</sup> The HPV L1 consensus primers were MY11—GCM CAG GGW CAT AAY AAT GG and MY09—CGT CCM ARR GGA WAC TGA TC (448-454 bp).<sup>18</sup> Precautions against contamination were taken and cuffed micropipette tips were used. All solutions were autoclaved and prepared only for the use of PCR. One third of the PCR products were analysed by electrophoresis on 2% agarose gels and the amplified products were visualised by ethidium bromide staining. PCR was repeated using beta-globin gene primers for control sequence in all DNA samples. The amplified products were run by electrophoresis on a 2% agarose gel and stained by ethidium bromide. Southern blotting of the amplified HPV products was performed using alkali transfer to nylon membrane (Amersham Hybond N plus).

Hybridisation was performed with oligonucleotide probe of 20 nucleotides to the internal portion of the amplified sequence using 5'-end labelling and P32 gamma ATP. The oligonucleotide probes used were HPV160P: TGG ACC GGT CGA TGT ATG TC, HPV180P: TAG CTG GGC ACT ATA GAG GC, consensus GP1: CTG TTG TTG ATA CTA CAC GCA GTA C and consensus GP2: CTG TGG TAG ATA CCA CA/TC GCA GTA C. Membrane blot was prehybridised with 10% dextran sulphate, 5 × Denhardt's solution, 1% SDS, 5 × SSPE and 200 µg/ml salmon sperm DNA at 52°C for 6 hours. Hybridisation was performed using the same solution with addition of radio-labelled oligonucleotide probe at 52°C overnight.

DNA extracted from the Caski cell line and HeLa cell line were used as positive controls for HPV 16 and 18 PCR reaction respectively. DNA extraction from C33 cell line which contains no HPV sequences and water were used as negative controls for the PCR reaction.

*p53 immunohistochemical staining on frozen section of cervical cancer*

Frozen sections of 6 µm thickness were cut and mounted on APES<sup>19</sup> coated slides and air dried for 45 minutes. Sections were fixed in 10% acetone stored at -20°C for 10 minutes and then immersed in 25% hydrogen perox-

ide to block endogenous peroxidase activity for 10 minutes. Sections were subsequently taken to water and immunostaining carried out using the ABC immunoperoxidase method (Dakopatts UK Ltd.). A polyclonal antibody, CM1 (full-length recombinant human p53) (Novocastra Lab Ltd., UK), was used at a 1:75 dilution. After incubation of the primary antibodies at room temperature for 1 hour, incubation with polyclonal biotinylated goat antirabbit antibody for CM1 were carried out at room temperature for 30 minutes. Further incubation after washing in PBS was carried out with avidinbiotin complex conjugated to horseradish peroxidase followed by 3,3'-diaminobenzidine-hydrogen peroxide as a c. omogen. A light haematoxylin counterstain was used. Sections were dehydrated in alcohol, cleared in xylene, and mounted.

Each section was scored by two separate observers. A score of 0 was assigned to sections showing no evidence of tumour cell nuclear staining with p53; a score of 1 was assigned to staining of 1-25% of tumour cell nuclei; a score of 2 to staining of 26-75% and a score of 3 to staining of more than 75%.

Negative controls were included by performing duplicate assays on the same sample with one of the primary antibodies replaced by phosphate buffered saline. A known positive control for each antibody was included with each batch of staining.

## Results

*HPV 16, 18 and consensus primers PCR and Southern blot*

A positive HPV 16 E6 PCR/Southern blot reaction was shown in 43 of the 64 samples (67.2%) and a positive HPV 18 reaction was shown in 25 of the 64 samples (39.1%). Both HPV 16 and 18 were positive in 21 of the 64 samples (32.8%) and both were negative in 17 of 64 samples (26.6%). Of the 17 samples negative for HPV 16 or 18 E6 sequences, 10 were positive for the consensus sequence. Thus, 57 of the 64 samples (89.1%) were HPV positive and seven of the 64 samples (10.9%) were HPV negative (table 1) (fig 1).

All DNA samples showed the presence of amplification products of PCR with the use of the beta-globin gene primers.

*p53 immunohistochemical staining*

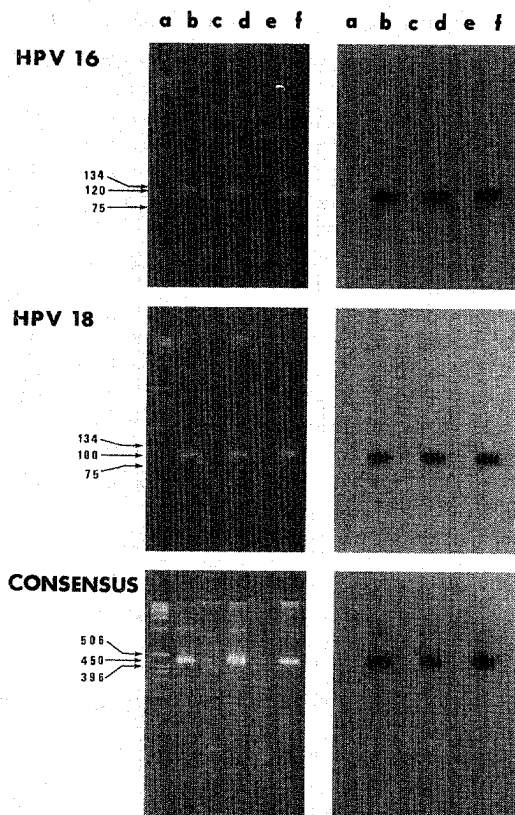
Only two of the 55 (3.6%) cervical cancer samples were positive for p53 CM1 staining. (fig 2) Both scored 2. A section of endometrial cancer positive for p53 with the CM1 antibody was used as positive control.

Table 1 Results of HPV 16 and 18 E6 PCR/SB in 64 squamous cell carcinomas

HPV 16	HPV 18	No.	%
positive	negative	22	34.4
negative	positive	4	6.2
positive	positive	21	32.8
negative	negative	17	26.6

\* 10 positive for consensus sequence.

Figure 1 PCR/SB of HPV16, HPV18 and consensus primers: a = marker, b = positive control, c = negative control, d and f = positive samples, e = negative samples.



#### Correlation between HPV PCR detection and positive p53 staining

Of the 46 samples where both PCR for HPV and immunohistochemical staining for p53 could be carried out, 13 (28.3%) were negative for HPV 16 and 18. Four of the 46 samples (8.7%) were negative for HPV 6, 11, 16, 18 and 33. Twelve (26.1%) were positive for both HPV 16 and 18. 29 (63.0%) were HPV 16 positive and 16 (34.8%) were HPV 18 positive. One of the two samples showing positive

Table 2 Results of HPV PCR/SB and p53 immunohistochemical staining in 46 squamous cervical carcinomas

HPV 16	HPV 18	no	%	p53 CM1 positive no
positive	negative	17	37.0	0
negative	positive	4	8.7	0
positive	positive	12	26.1	1
negative	negative	13*	28.2	1†

\* 9 positive for consensus sequence.

† negative for consensus sequence.

p53 staining was HPV negative and the other was both HPV 16 and 18 positive. (table 2)

#### Discussion

The results of the present study reveal HPV DNA sequences in almost 90% of the carcinomas examined with PCR using consensus primers for the major genital HPVs.<sup>18</sup> This observation is in accord with most studies which have used PCR as the detection system. When primers specific for the E6 of HPV 16 or 18 were used in the assay, 43 (67%) of 64 squamous cell carcinomas were positive for HPV 16 and 25 (39%) for HPV 18. Interestingly mixed infections of 16 and 18 accounted for 21 (33%) of these cases. This incidence of double infection is considerably higher than has been reported in other studies but is in accord with a retrospective analysis by Ip and colleagues (20) in Hong Kong. These workers examined the HPV status of the cervical cancers of 45 young patients using PCR on paraffin wax sections. They found HPV 16 in 69%, HPV 18 in 44% and double infections of 16 and 18 in 31%, a distribution very comparable to that reported here.

The p53 status of 46 cases, of which 42 were HPV DNA positive and four HPV DNA negative, was examined by immunohistochemical staining of frozen sections using the polyclonal antibody CM1. Two cases showed positive staining but only one case was HPV negative, the other p53 positive case containing both HPV 16 and 18 DNA sequences. These observations are consistent with other studies in which p53 status in cervical carcinoma has been examined.<sup>21-22</sup> In these reports in which p53 expression was examined by GC-clamp PCR, SSCP, or immunohistochemical staining as screening for mutation followed by direct DNA sequencing for confirmation. None of the HPV negative cervical cancers showed p53 over-expression or mutation. In another report<sup>23</sup> point mutations in p53 were found in two of the patients with a low copy number of HPV but wild type p53 was found in the HPV negative cases. However the situation in anal carcinoma appears to be different and in a small study by Crook *et al*,<sup>15</sup> six HPV positive lesions contained wild type p53 but the three HPV negative lesions had point mutations. A recent study on cervical cancer by the same workers also found point mutations in p53 in the three HPV negative cervical cancers in the series.<sup>24</sup> However, to date the numbers of HPV negative cervical cancer cases examined for p53

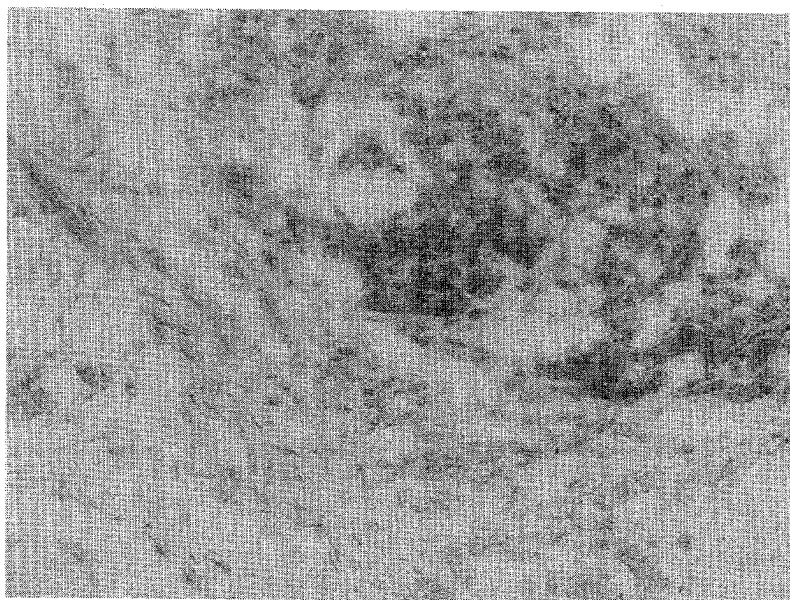


Figure 2 Positive p53 immunohistochemical staining in cervical cancer: 400x magnification.

expression are small, four in the present study and 16 reported in the literature.<sup>21-23</sup> The assay methods have differed in the various investigations and in no study to date have p53 protein levels been quantitated in HPV negative and positive lesions or any clinico-pathologic correlations made. Although point mutation appears to be the basis for the deregulation of p53 expression in human cancers there is evidence from experimental murine epidermal carcinogenesis of novel mechanisms for p53 inactivation which do not involve point mutation.<sup>25</sup> Furthermore in this model system in which tumour progression can be monitored, the level of p53 protein related to the degree of differentiation of the tumours with negligible levels in poorly differentiated carcinomas. Data of this type suggest caution in the interpretation of p53 inactivation by mutation in cervical cancers and the relationship to HPV.

There is evidence that HPV negative and positive cervical carcinomas have a different clinical course and by implication may have alternative routes to malignancy. In a recent study in which HPV status was determined by in situ hybridisation with subgenomic riboprobes<sup>26</sup> approximately 10% of lesions were HPV negative. Interestingly in this population, patients with HPV negative lesions were older, had a poorer response to therapy than the HPV positive population and there was some evidence that HPV negative lesions were not associated with an intra-epithelial lesion. Crook *et al*<sup>27</sup> documented a p53 mutation in the metastasis from an HPV positive p53 wild type primary and speculated that tumours with a p53 mutation exhibited more aggressive behaviour but the validity of this requires data from a larger series of cases.

However, it is evident that the inter-relationship between p53 expression and HPV in cervical cancer is unclear and requires further work in which large numbers of HPV negative cervical cancers are examined for p53 status by direct sequencing and p53 protein expression by immunoprecipitation and Western blotting.

This study was supported partly by the Mary Sun Oncology Fellowship and partly by the RGC funded research project HKU271/92M, Hong Kong.

- 1 De Villiers EM. Heterogeneity of the human papillomavirus group. *J Virol*. 1989;63:4898-903.
- 2 Koutsky L, Holmes K, Critchlow C, *et al*. A cohort study of the risk of cervical intraepithelial neoplasia grade 2 or 3 in relation to papillomavirus infection. *N Engl J Med*. 1992;327:1272-8.

- 3 Munoz N, Bosch FX, De Sanjose S, *et al*. The causal link between human papillomavirus and invasive cervical cancer: a population-based case-control study in Colombia and Spain. *Int J Cancer*. 1992;52:743-9.
- 4 Zur Hausen H. Human papillomaviruses in the pathogenesis of anogenital cancer. *Virology*. 1991;184:9-13.
- 5 Meijer CJ, Van Den Brule AJ, Snijders PJ, Helmerhorst T, Kenemans P, Walboomers JM. Detection of human papillomavirus in cervical scrapes by the polymerase chain reaction in relation to cytology: possible implications for cervical cancer screening. *LARC Sci Publ*. 1992;119:271-81.
- 6 Villa LL, Schlegel R. Differences in transformation activity between HPV-18 and HPV-16 map to the viral LCR-E6-E7 region. *Virology*. 1991;181:374-7.
- 7 Romanczuk H, Villa LL, Schlegel R, Howley PM. The viral transcriptional regulatory region upstream of the E6 and E7 genes is a major determinant of the differential immortalization activities of human papillomavirus types 16 and 18. *J Virol*. 1991;65:2739-44.
- 8 Dyson N, Howley PM, Munger K, *et al*. The human papilloma virus-16 E7 oncoprotein is able to bind to the retinoblastoma gene product. *Science*. 1989;243:934-7.
- 9 Crook T, Tidy JA, Vousden KH. Degradation of p53 can be targeted by HPV E6 sequences distinct from those required for p53 binding and trans activation. *Cell*. 1991;67:547-56.
- 10 Werness BA, Levine AJ, Howley PM. Association of human papillomavirus types 16 and 18 E6 proteins with p53. *Science*. 1990;248:76-9.
- 11 Hubert NL, Sedman SA, Schiller JF. Human papillomavirus type 16 E6 increases the degradation rate of p53 in human keratinocytes. *J Virol*. 1992;66:6237-41.
- 12 Levine AJ, Momand J, Finlay CA. The p53 tumour suppressor gene. *Nature*. 1991;351:453-6.
- 13 Lane DP. p53 guardian of the genome. *Nature*. 1992;358:15-6.
- 14 Crook T, Wrede D, Vousden KH. p53 point mutation in HPV negative human cervical carcinoma cell lines. *Oncogene*. 1991;6:873-5.
- 15 Crook T, Wrede D, Tidy J, *et al*. Status of c-myc, p53 and retinoblastoma genes in human papillomavirus positive and negative squamous cell carcinoma of the anus. *Oncogene*. 1991;6:1251-7.
- 16 Di Luca D, Costa S, Monini P, *et al*. Search for human papillomavirus, herpes simplex virus and c-myc oncogene in human genital tumors. *Int J Cancer*. 1989;43:570-7.
- 17 Young LS, Bevan IS, Johnson MA, *et al*. The polymerase chain reaction: a new epidemiological tool for investigating cervical human papillomavirus infection. *BMJ*. 1989;298:14-8.
- 18 Ting Y, Manos MM. In: Gelfand DH, Shinsky JJ, White TJ, eds. *PCR protocols: A Guide to Methods and Applications*, Academic Press Inc, CA, 1990, pp356-67.
- 19 Maddox PH, Jenkins D. 3-aminopyropyl triethoxysilane (APES) a new advance in section adhesion. *J Clin Pathol*. 1987;40:1256-60.
- 20 Ip EW, Collins RJ, Srivastava G, Cheung AN, Wong LC. Human papillomavirus and its prognostic significance in invasive carcinoma of the cervix in young patients. *Intern J Gynecol Pathol*. 1992;11:258-65.
- 21 Borresen AL, Helland A, Nesland J, *et al*. Papillomaviruses, p53, and cervical cancer. *Lancet*. 1992;339:1350-1.
- 22 Busby-Earle RMC, Steel CM, Williams ARW, *et al*. Papillomaviruses, p53, and cervical cancer. *Lancet*. 1992;339:1350.
- 23 Fujita M, Inoue M, Tanizawa O, Iwamoto S, Enomoto T. Alterations of the p53 gene in human primary cervical carcinoma with and without human papillomavirus infection. *Cancer Res*. 1992;52:5323-8.
- 24 Crook T, Wrede D, Tidy JA, Mason WP, Evans DJ, Vousden KH. Clonal p53 mutation in primary cervical cancer: association with human-papilloma virus-negative tumours. *Lancet*. 1992;339:1070-3.
- 25 Han KA, Kulesz-Martin M. Altered expression of wild type p53 tumor suppressor gene during murine epithelial transformation. *Cancer Res*. 1992;52:749-53.
- 26 Higgins GD, Phillips GE, Smith LA, Uzelin DM, Burrell CJ. High prevalence of human papillomavirus transcriptions in all grades of cervical intraepithelial glandular neoplasia. *Cancer*. 1992;70:136-46.
- 27 Crook T, Vousden KH. Properties of p53 mutations detected in primary and secondary cervical cancers suggest mechanisms of metastasis and involvement of environmental carcinogens. *EMBO*. 1992;22:3935-40.