

**Replacement and modifications of  
anterior teeth: aesthetic  
considerations**

**A dissertation submitted as partial fulfilment for the**

**Post-graduate Diploma in Dental Surgery**

**by**

**Dr. Benjamin Ho**

**Paediatric dentistry and Orthodontics**

**Faculty of Dentistry**

**Supervisor: Professor Nigel M King**

**September 2000**

THE UNIVERSITY OF HONG KONG  
LIBRARIES



*This book was a gift  
from*

Dr. Benjamin Ho

**Replacement and modifications of  
anterior teeth: aesthetic  
considerations**

## **Abstract:**

When one looks upon an object, whether it is a face, a landscape, or a painting, one begins to subconsciously analyse it. One's eye is attracted first to a single location in the composition, most likely the most dominant, or bright, or moving part. In a face, the smile contains contrasts of bright teeth against red lips and is active in speech and expression. Thus, it is dominant and attracts one's attention first. A dentist can plan these visual channels in his/her composition using line, contrast and the size of objects by attending to the many details of a smile, including tooth position and the development of the smile to establish self-esteem, harmony and symmetry.

Children often present with teeth damaged by trauma or congenitally malformed teeth so they are in need of aesthetic reconstruction of their anterior teeth. However, before the reconstruction of the teeth can commence it is essential that the clinician has a comprehensive knowledge of the elements and basic principles of aesthetics and the specific characteristics of the individual teeth.

Therefore, in a review of the published literature, it is proposed to consider the form of the incisors then to consider the size and symmetry of the maxillary anterior teeth, followed by the colour and translucency. Then to indicate when these characteristics should be observed and applied when restoring fractured central incisors and microdont lateral incisor teeth.



# Table of Contents

<b>Abstract</b>	i
<b>Acknowledgements</b>	ii
<b>Table of Contents</b>	iii
1.0 Introduction	1
1.1 Facial view	1
1.2 Dentofacial view	3
1.3 Dental view	5
1.4 Artistic elements	9
2.0 Principles of dental aesthetics	10
2.1 Size	10
2.2 Shape	13
2.3 Proportion and symmetry	16
2.4 Surface texture	19
2.5 Position and alignment	20
2.6 Colour	22
2.6a Hue	24
2.6b Translucency and opacity	24
2.6c Chroma	25
2.6d Value	25
2.7 Shape and size of incisal embrasures	26
2.8 Balance	26
2.8a Properties of the central incisors	27
2.8b Incisal edge position	29
2.8c Emergence profile	30

2.8d	Labial contour	30
2.8e	Incisal embrasures	31
2.8f	Labial anatomy	32
2.8g	Surface finish	33
3.0	Natural variations	33
4.0	The importance of aesthetics in restoring fractured anterior teeth	36
5.0	The principle of restorative technique and materials	39
6.0	Technique for the correction of teeth of abnormal size and shape	42
7.0	Conclusions	44
8.0	Appendix 1. Step-by-step operative techniques in the direct adhesive restoration of fractured anterior teeth	46
9.0	Appendix 2. Step-by-step operative techniques in the direct adhesive restoration of microdont anterior tooth	50
10.0	Appendix 3. Restorative material considerations in relation to the restorative sequence	51
11.0	Figures	56
12.0	References	72

## **1.0 Introduction**

The word *aesthetic* refers to an understanding of beauty. Therefore it is required to have an understanding of beauty and the artistic tools available to develop a beautiful smile (Valo 1995).

The geometric rules of Pythagoras' "Golden Proportion" and Plato's "Beautiful Proportion" demonstrate a desire to find a rational, physically measurable definition of beauty. The perception of beauty varies according to culture and a perception of life. Similar expressions are found in dentistry. "Beauty is that pleasant experience seen with subjective senses, interpreted by our associations, filtered by a philosophy of life, capturing our imagination through variety and distortion, and felt by intuition. The essence of beauty has been sought since the beginning of time" (Valo 1995).

Dental aesthetics as first described by Lombardi (1974) are defined by the way things are perceived visually. Visual perception can be divided into two categories: composition and proportion. Composition is the way colour, contour and texture are related to one another. Proportion is defined as balance, symmetry, parallel lines, curves and how they work together. The aesthetics of the face are said to encompass three views: the facial, the dentofacial and the dental views (Levine 1995).

### **1.1 Facial view:**

The paramount element of the facial view is the midline, which acts as the centralised vertical line. Organised around this midline and perpendicular to it are horizontal



reference lines: the hairline, the ophriac line (eyebrows), the interpupillary line, the interalar line and the commissural line (Levine 1995). According to Golub (1988), "The dental midline runs perpendicular to the interpupillary lines and serves to anchor the smile on the face." It is agreed that the midline should be placed at the centre of the smile and that symmetry and balance instead of facial anatomy (Goldstein 1976, Rufenacht 1990) should guide its location. The interpupillary line is used as a reference for the occlusal and incisal plane orientations (Ahmad 1998). It also serves to evaluate the orientation of the incisal plane, gingival margins, and maxilla. In addition, the general direction of the incisal plane/incisal edges of the maxillary teeth and the gingival margin must be parallel to the interpupillary line and be perpendicular to the facial midline. This harmony must be reinforced by the incisal plane's following the lower lip during smiling (Levine 1995).

The facial composition is the most important element to the patient. It is this composition that influences most patients' concept of an aesthetic smile. From the normal distance at which one focuses on a person's face, the dentition appears white and straight. However, upon closer examination, the teeth are not straight they exhibit distinct proportions, characterisations and embrasures.

The length and curvature of the lips significantly influence the amount of teeth that is exposed at rest and in function. For example, full concave lips are often associated with a prominent display of the maxillary teeth. From a cultural standpoint, a prominent smile with bright teeth is synonymous with youth and dynamism (Goldstein 1984). Vig and Brundo (1978) demonstrated that the average amount of the maxillary incisors displayed when the lips are at rest is 1.91 mm in men and 3.40

mm in women. Short upper lips generally display more maxillary tooth structure (3.65 mm) than do long lips (0.59 mm). Younger patients (up to 29 years) display more maxillary tooth structure (3.37 mm) than middle-aged (30 to 50 years) patients (1.26 mm).

Youth is expressed with prominent and well-developed central incisors, well-defined incisal embrasures, and a convex or "gull wing" smile line. Age is associated with reduced incisal embrasures, levelling of the "gull wing" effect, and a straight smile line (Goldstein 1984, Kessler 1991). The upper lip line serves to evaluate the length of maxillary incisor exposed at rest and during smiling and the vertical position of the gingival margins during smiling. While the lower lip line serves to evaluate the buccolingual position of the incisal edge of maxillary incisors and the curvature of the incisal plane (Chiche & Pinault 1994).

Lip position (either prominent or receding) affects the shape and position of the upper anterior teeth and is consequently an important element to consider. In general, a prominent upper arch (i.e. a convex profile) requires a reduction in size of the upper anterior teeth. A receded upper arch (i.e. a concave profile) calls for a more prominent position of the teeth (Levine 1995).

## **1.2 Dentofacial view:**

The second component in anterior dental aesthetics is the dentofacial composition (i.e., orofacial view). The constituents of this element are the oral orifice, the highly

vascularized red lips, and the teeth, which act as a gate or entrance to the oral cavity (Ahmad 1998).

The smile line is an imaginary line that extends from the incisal edges of the maxillary incisors and is parallel to the curvature of the lower lip. It should not be confused with the lip line, which is the position of the upper lip during smile formation. It is the lip line that determines the display of teeth and gingiva. Proper placement of the incisal edges maintains the harmonious patterns that we see in natural smile lines (Lichter et al 1999). The anterior and lateral negative spaces act as a border to the dental elements, while the lips represent the frame (Ahmad 1998).

Thus the dentofacial view involves the teeth and the surrounding structures of the gingiva and the lips. Rufenacht (1990) described this view as a coincidence of curves created by the contact points, incisal edges and the lower lip. It is important to evaluate the amount of tooth exposed when smiling and at rest.

According to Tjan and Miller (1984), the average smile reveals 75% to 100% of the maxillary anterior tooth; the incisal curve of the teeth should be parallel to the lower lip and the incisal curve of the maxillary teeth should touch or just fail to touch the lower premolars. On average, women expose twice as much of their maxillary teeth as men (3.40mm vs. 1.91mm) (Levine 1995).

Gingival symmetry at the midline is critical for the patient with a moderate to high smile line and needs careful evaluation (Allen 1988). The "f" and "v" sounds help to determine the incisal third position and the "s" serves as the guide for vertical

dimension and the closest speaking space (Pound 1973) during “f” and “v” sounds of speech, the maxillary incisors should contact the inner mucosal surface of the lower lip. The axial inclination of the maxillary anterior teeth is such that the incisal edges converge mesially. The contact points of the anterior dental sextant coincide with the incisal edges and the curvature of the lower lip, enhancing the cohesiveness of the dentofacial composition (Ahmad 1998).

Viewed in the dentofacial perspective, the midline needs to coincide with the median of the philtrum (Miller et al 1979) and should be parallel to the imaginary line dividing the face. Problems occur when the midline is deviated to one side. Logically, the maxillary central incisal midline should coincide with the midline of the face. Therefore, the facial midline serves as the standard or baseline from which to evaluate the location and axis of the dental midline and mediolateral discrepancies in tooth position or orientation.

In summary, the perfect smile is aligned with the interpupillary line and centred on a perpendicular midline of the face.

### **1.3 Dental view:**

The dental composition consists of the dental elements proper that is the teeth, their size, shape, and intra- and interarch relationships. Tooth size can be determined by measuring the incisogingival length and dividing it by its mesiodistal width. The width/length ratio of the central incisor should range from 0.75 to 0.80; lower values create a long narrow tooth, while values greater than this range result in a short wide

tooth see Figure 1. The central incisors are the dominant elements in the anterior dental view. Youthful teeth tend to have sharp, unworn incisal edges, and although the central incisors should dominate the view they must be in harmony with the lateral incisor and canine teeth (Ahmad 1998).

The tooth-to tooth relationship is the next point that needs to be considered. It was the Greeks who tried to formulate beauty as an exact mathematical concept, they believed that beauty could be quantified and represented in a mathematical formula. This led Pythagoras to conceive the “Golden Proportion” ( $1/1.618=0.618$ ), and Plato, the “Beautiful Proportion” ( $1/1.733=0.577$ ), both concepts stated that a shape or object with specific proportions is perceived as having innate beauty. The most widely used concept in dentistry is that of the Golden Proportion, whose formula is as follows:

$$S/L = L/(S + L) = 2/(1 + \sqrt{5}) = 0.618$$

Where S is the smaller and L the larger part. The uniqueness of this ratio is that when applied by three different methods of calculation (linear, geometric, and arithmetic), the proportional progression from the smaller to the larger to the whole part always produces the same results, see Figure 2 (Lombardi 1973, Levin 1978). Other researchers have indicated that in reality this Golden Proportion is not always evident, and variations are frequently apparent (Woelfel 1990). If a clinician is to use the 0.75 ratio as a standard for determining the dimensions of a central incisor, then a progressive application of this ratio, from the central-lateral-mesial aspect of the canine tooth, will create an aesthetic composition (Ahmad 1998).

Incisal embrasures have a distinct appearance and are said to be a function of age and sex. An increase in the embrasure angle from the maxillary central incisor to the

canine can be observed in virgin teeth soon after eruption. Pronounced embrasures are a feature of youth and femininity; shortened, worn edges convey advancing age and masculinity. Patient preferences, age, and gender prior should guide the clinician to the determination of embrasure angles see Figures 3 & 4 (Ahmad 1998).

The buccolingual thickness of teeth varies; for example, the maxillary central incisor has a range between 2.5 mm to 3.3 mm (Chiche & Pinault 1994). For reference the latter is measured at the junction between the middle third and incisal third of the tooth.

The contour of a tooth can be further broken down into important compositional elements based on its axial inclination, line angle (i.e. contour ridges), heights of contours, incisal edge contour and position, and gingival contour (Muia 1985). Geometrically, the anterior teeth are trigonal, with the height of the contour (viewed incisopically) distal to a line running vertically through the middle of the tooth. The mesial line angles of the central teeth mirror each other and so create symmetry around the midline (Appleby 1986); this is reinforced by an even gingival height. The axial inclinations of the anterior teeth are directed distally (Levin 1995).

Both tooth proportion and tooth-to-tooth proportion are important elements of the overall proportions in this view. Tooth-to tooth proportion is guided by the law of the “Golden Proportion”: the ratio of the width of the central incisor to that of the lateral incisor to that of the canine, which has been defined as 1.618 to 1.0 to 0.618 see Figure 5 (Levin 1978). Dominance of the central incisor is paramount in the provision of good dental aesthetics. Tooth proportion is defined as the width-to-height ratio of

the central incisor alone. This ratio should be between 75% to 80%. Anything less will give a long narrow tooth; anything more will give a short wide tooth (Chiche & Pinault 1994).

Proportions of the central incisors must be aesthetically and mathematically correct because the central incisors are the key features of the smile. In turn their shape and position will influence the relative positions and appearance of the lateral incisors and canines. The average anatomic crown length of the central incisor ranges from 10.4 mm to 11.2 mm, while the width-to-length ratio should be 4:5. However, a range for their width of 75 % to 80 % is acceptable (Chiche 1993).

The smile is probably the single most impressive aspect of a face. It captures another person attention, and its characteristics are critical to beauty. There are repeating lines in a beautiful smile, the incisal edges of the upper teeth and the border of the lower lip form repeating lines that are referred to as the smile line. This repetition imparts harmony and unity to the smile, so too, does the repetition of vertical lines separating each tooth and the parallelism of the upper gingival line and lower border of the upper lip (Valo 1995).

By virtue of their central position and their colour contrast with respect to the rest of the face, the teeth are understandably the dominant element within the face. Furthermore, because of their forward position, size, and brightness, the maxillary central incisors play a dominant role within the dental composition see Figure 6 (Valo 1995).

Thus the dominant teeth; the central incisors, initially attract ones attention, but not so much as to prevent one from moving laterally along the natural visual channels within the dental arch. When the smile is beautiful it is perceived as being soft, beautiful, and in harmony with the rest of the face. However, if there are elements of disharmony the eye will detect at once the distractive elements because of prominent or incorrectly coloured central incisors: this will be followed by detecting their disproportionate size compared with the adjacent teeth. Hence prominent gingiva and short teeth become the primary distractive element because the vertical and horizontal proportions of the teeth are similar and although on different scales, are in accordance with the “Golden Proportion”. It is the repetition of shapes that develops harmony; slight variation in size, which is present in nature, serves to create interest. Similarly, the variation in colour within each tooth, and from tooth to tooth is interesting and attractive, and it provides a perceivable degree of separation between the tooth units. Finally, the smile lines created by the lips, incisal edges, and the gingival line are repeating lines that develop harmony (Valo 1995).

#### **1.4 Artistic elements:**

Regardless of the desired final result, there are certain basic artistic elements that must be considered so as to ensure an acceptable aesthetic result. In aesthetic dentistry, these features will include shape or form, symmetry and proportionality, surface texture, position and alignment, and colour.

Awareness of these elements is essential to dentists because they are common to virtually every conservative aesthetic dental procedure. Therefore, a basic knowledge



and understanding of these artistic elements is required if a tooth or multiple teeth are to be restored in such a way as to attain an acceptable aesthetic result.

Tooth morphology, incisal edge position, emergence profile, contact points, incisal and cervical embrasures all play an important role in identifying and determining the aesthetic smile. These criteria must be evaluated during the planning and operative stages of aesthetic dentistry in order to achieve success with the final restorations.

The aesthetic restoration of a single anterior tooth is extremely difficult to perform using porcelain or composite resin. By using a previsualised mock-up and knowledge of composite materials, the modifiers selected, and its shade and orientation, the definitive restoration can be visualised prior to completion. The transformation of this "vision" into an aesthetic creation that replicates natural variations constitutes the clinician's final challenge (Winter 1993).

## **2.0 Principles of dental aesthetics**

### **2.1 Size:**

The size of a tooth is relevant not only for dental aesthetics, but also for the facial aesthetics. Although teeth must be kept in a proportional relationship with each other, they must also be in proportion to the face. A large degree of variation in the proportion between teeth size and the face can present a problem and not produce the

best aesthetic result. This is a powerful consideration when placing restorations that involve the incisal edge of maxillary anterior teeth (Baratieri et al 1998).

In cases where only one tooth needs to be restored, the dentist only has to reproduce the length of the homologous teeth to achieve the desired proportions. A problem arises when it is necessary to rebuild partially erupted central incisors or when the whole group of upper anterior teeth has damaged incisal edges. In such cases, there are no pre-defined landmarks to use to determine the sizes of teeth. Teeth of young patients are under active eruption, so the initial restoration should be considered as being a “semi-permanent” restoration. Later, with the eruption has been completed, the correct crown length can be established with a definitive restoration (Baratieri et al 1998).

In cases where the tooth has reached full eruption (young adult patients) but there is no homologous tooth or teeth to serve as a reference, the dentist can use the relationship between the upper lip and the exposed portion of the teeth to serve as a reference. An important factor in the proportion between the upper lip and the incisal edge of the teeth is that the more exposed the incisal edges, the younger the patient's appearance. During youth, the incisal edge of upper incisors is approximately 2 to 3 mm longer than the upper lip line at rest. With advanced age, the incisal edge is worn, offering no exposure (Yamamoto et al 1990). Conversely, lengthening upper front teeth creates a younger smile. It must be remembered that teeth, which have been lengthened by porcelain or composite resin restorations, become more vulnerable to fracture.

The visibility of the tooth, when lips and mandible are at rest, is an important factor for dental aesthetics. Mean exposure of the upper central incisor has been calculated to be 1.91 mm for men and 3.40 mm for women (Rufenacht 1990); thus, tooth visibility assumes a greater degree of significance for women. Lip line and smile line is also relevant. If restoration margins would be visible during smiling, there is reason to place them subgingivally. However, even if the cervical margins are not visible during a smile, a survey of 383 patients showed 15% of men and 11% of women objected to supragingival margins (Watson & Crispin 1981). Lip and smile lines have to be studied before the restoration of an anterior tooth. The aesthetic advantage and possible periodontal risks/disadvantages involved in margin placement should be discussed with the patient (Qualtrough & Burke 1994), and the result may be a compromise.

Teeth with identical widths but with different lengths will appear to the observer to have different widths see Figure 7. This is an important principle to remember when reducing or closing diastemas in the anterior region since any alteration to the size of the teeth will introduce a change in the length-width relationship. This in turn could alter the smile unfavourably. While it is possible to alter the length of anterior teeth by direct restoration the incisal edge, the aesthetic results are generally better and more easily attained when the real apparent length of the teeth is changed by restoration of the whole facial surface. This can be accomplished by using composite resins, porcelain laminate veneers or full crowns. An important feature when determining the size of upper central incisors is that they usually present the same incisal-cervical length as the canines. This is especially important when all six of the maxillary anterior teeth are to receive veneers (Baratieri et al 1998).

## 2.2 Shape:

The ideal form for any restoration should theoretically be similar to that exhibited by the patient's natural tooth. The shape of the face has morphological characteristics (modified by gender and age) which can also help in developing the shape of a tooth form. Reference material such as existing photographs and stone models can also be extremely useful. There is no ideal form, which can be successfully applied to all cases. Above all, the individual characteristics of the patient must be taken into consideration. Nevertheless, a variation in what is considered to be the perfect tooth form will not always adversely affect aesthetics (Heymann 1987).

The many different shapes of natural teeth can for convenience be divided into three categories: square, triangular, and oval see Figures 8&9. It is apparent that, tooth morphology displays some correlation with face morphology. Also all of the teeth in one dentition have a great similarity to each other in shape and size. Subtle variations in shape and contour can produce marked differences in appearance. The clinician, when crafting, for example, a direct adhesive restoration should strive to replicate the basic form of the neighbouring teeth in respect of the parameters of size, shape, and surface contour (Baratieri et al 1998).

When the shape of a tooth is altered, the direction of light striking that tooth is also changed. Flatter and smoother surfaces tend to reflect a greater amount of light directly to the observer so they tend to look wider, enlarged and closer to the observer. Alternatively, rounded and irregular surfaces reflect light sideways,

reducing the amount of light directly reflected to the observer. Hence, they appear to be narrower, smaller and farther away from the observer (Baratieri et al 1998).

The appearance of the three basic tooth forms is related to features such as the developmental ridges and grooves and general morphology of the facial surfaces as they are seen from various angles. On square teeth, the vertical ridges appear to be well developed and uniformly distributed on the facial surface. The incisal and the central ridges are well balanced, so dividing the facial surface into thirds. On triangular teeth, there is a depression in the facial surface. Although the central ridge is neither prominent nor well developed, the marginal ridges are quite well developed and thick. Thus presenting more rounded angles directed towards the adjacent surface (Baratieri et al 1998).

The vertical ridges that help to define the light-reflecting areas of the facial surface of anterior teeth can vary in shape, location and size. This area has been referred to as the “plane area” (Bartista & Martins 1990). Changes in dimensions and position of the plane area can contribute to apparently altering the length and width of the teeth. Ridges and horizontal grooves are also characteristic features of these teeth. The typical youthful feminine smile is characterised by rounded incisal angles, opens incisal embrasures and softened facial line angles. While a man’s smile, generally, has incisal embrasures that are more closed and the incisal angles are more prominent. Minor modification to existing tooth contours by reshaping enamel, by rounding incisal angles, opening incisal embrasures, and reducing prominent facial line angles can produce a more feminine, or youthful appearance to the teeth (Heymann 1987).

To achieve an optimal aesthetic appearance, it is imperative that natural anatomic forms are recreated. As such, a basic knowledge of normal tooth anatomy is fundamental to the success of any conservative aesthetic dental procedure.

Restorations involving individual teeth, rather than all anterior teeth simultaneously may require greater artistic ability. However, the success in treatment of an isolated tooth is largely determined by how well the restored tooth matches the surrounding natural teeth. The tooth contralateral to that being restored should be closely examined for subtle features such as ridges grooves developmental depressions, embrasures, or other distinguishing characteristics of shape and form. A high degree of realism needs to be produced if an optimal result is to be achieved when restoring teeth (Heymann 1987). But the clinician needs to be aware of which characteristics and features are present and the relative effects on the overall appearance of a tooth or teeth.

Illusions of shape and form also have a significant role in aesthetic dentistry. Outline form is primarily two-dimensional (length and width). However, the third dimension, depth, is crucial in creating illusions, especially of apparent width and length (Heymann 1987).

Prominent contours on a tooth are highlighted by direct illumination, making them more noticeable whereas depressed areas or diminishing contours are shadowed and so less conspicuous. By controlling the areas of light reflection and shadowing, full-facial coverage restorations can be aesthetically contoured to achieve various illusions of shape and form. Moreover, altering the position of a facial prominence can change

the apparent size of a tooth or heights of contour without changing the actual dimension of the tooth see Figure 10. For example, a tooth can be made to appear narrower by positioning the mesial and distal facial line angles closer together. Developmental depressions also can be positioned closer together to enhance the illusion of narrowness. Similarly, greater width can be apparently achieved by positioning the line angles and developmental depressions further apart (Heymann 1987).

Although more difficult, the apparent length of teeth can also be changed by an illusion see Figure 11. The tooth can be made to appear shorter by emphasising the horizontal elements, such as gingival perikymata, and by positioning the gingival height of contour further incisally. Slight modification of the incisal area, achieved by moving the incisal height of contour further gingivally, also enhances the illusion making a shorter tooth. The opposite tenets are true for apparently increasing the length of a tooth see Figure 11. The heights of contour are moved further apart incisogingivally, and vertical elements such as developmental depressions are emphasised (Heymann 1987).

### **2.3 Proportion and Symmetry:**

The many components of the normal human body are proportionally related to each other (Albers 1992), contributing thus towards the aesthetics of the body as a whole.

The term proportion implies geometry and arithmetic functions so if beauty is associated with numerical values there is a tendency to adopt the concept that beauty is fundamentally an exact characteristic (Rufenacht 1990).

Idealism and proportion are merely tools, not goals; they are just a useful guide within which the artist's imagination has freedom to play (Richet 1971). Lombardi (1973) highlighted the importance of the proportion between width and length in the dimensions of individual teeth and between the respective size of the anterior teeth. In aesthetic dentistry, proportion and idealism serve to determine (i) the optimum sizes of the maxillary central incisors and (ii) the optimum relationship between the dimensions of the maxillary central incisor, lateral incisor, and canine (Chiche & Pinault 1994).

Symmetry refers to the regularity or balance of tooth arrangements and serves to define how much regularity is required and how much asymmetry can be permitted in the dental composition (Chiche & Pinault 1994). Interestingly, it is accepted that symmetry is almost synonymous with unity (Parramon 1980). Facial features are more symmetrical close to the facial midline and more asymmetrical further away from the facial midline. For a pleasing smile, this means: the closer to the dental midline, the more symmetrical the smile must be; the further away from the dental midline, the more asymmetrical the smile may be (Chiche & Pinault 1994).

The proportionality of the teeth is an important factor in beauty of the smile. It depends on the proportion between length and width of teeth, their distribution in the arch, the shape of the arch and the smile configuration see Figure 12.



When two teeth show the same width, but different lengths, the longer tooth seems to be narrower. The width-length relationship of each tooth with its neighbours has a significant effect on the overall visual appearance of the group of teeth (Alber 1992). The proportion of the teeth can be easily modified by applying adhesive restorations, by performing limited enamoplasties, or with orthodontic movement of the teeth.

A widely accepted concept on the relative proportions of the teeth is the “Golden Proportion” (Levin 1978, Heymann 1987). Originally formulated by elements from Euclides, the concept has long been used as a geometric basis for proportionality in both art and nature (Borissavlievitch 1964). Employing this formula, the smile, as seen in a frontal view, is considered to be more aesthetically pleasing when each tooth is approximately 60% of the size of that of its immediate anterior (Boris 1964). As seen in Figure 13 the exact proportion of the smaller to the larger is 0.618. It must be emphasised that these proportions are based on the apparent sizes of the teeth, when viewed straight on, and not the actual sizes of the individual teeth. Figure 13 shows a pleasing smile in which the anterior teeth can comply with the golden proportion. Although this theorem is not the absolute determinant of aesthetic appearance, it provides a practical and proven guide for establishing proportions when restoring anterior teeth (Heymann 1987).

Another widely accepted concept of proportion proposes that the maxillary central incisors should have a 10:8 length/width relationship; that is, a central incisor’s width should never exceed 80% of its length. Nevertheless, an aesthetically more pleasant

result can be achieved when this length/width proportion is slightly modified to be the order of 10:7 or 10:6 (Baratieri et al 1998).

Asymmetric teeth or those out of proportion to the surrounding ones tend to disrupt the sense of balance and harmony essential to an optimal aesthetic appearance. Assuming the teeth are in a normal alignment, dental symmetry can be maintained if the sizes of the contralateral teeth are equivalent (Heymann 1987).

Particular attention must also be given to the form of the incisal and gingival embrasures. The mesial contours of both central incisors must be mirror images of one another to ensure an optimally symmetrical and aesthetic result and this includes the relative embrasures.

The proportionality is relative and varies greatly, depending on other factors such as tooth position, tooth alignment, arch form, and the configuration of the smile. The central incisors are dominant in this pleasing natural smile. A dynamic youthful smile is associated with dominant, prominent central incisors, and a convex smile line. Pleasing proportions of the central incisors are expressed in width-to-length ratio of approximately 75% to 80%. Pleasing proportions are an essential aspect of the successful aesthetic rehabilitation of a tooth or teeth (Chiche & Pinault 1994).

## **2.4 Surface texture:**

The surface texture of anterior teeth, modified over time as the enamel is abraded during function, is a major factor to be observed when creating aesthetic restorations.

Natural teeth of children and young people present a significant characteristic roughness of surface, whereas, in adults, a smooth surface with minimal textural characteristics is present (Baratieri et al 1998). So care should be exercised not to produce a smooth surface on a tooth in a young patient for it will adversely affect the end result.

As has already been stated the surface of natural teeth scatter light, reflecting it in many directions (Heymann 1987), and that the size and colour of the teeth are also influenced by the amount of ambient light that is so scattered by the surface.

The individuality of teeth is to some extent determined by their texture and surface characteristics. Hence, realistic restorations must closely mimic these subtle areas of stippling, concavity, and convexity that are typical of natural teeth. Important anatomical details, difficult to duplicate on the surface of composite resin restorations are the horizontal lines (Baratieri et al 1998). The teeth of young persons have significantly more surface characterisations, than those of older persons, which tend to possess a smoother surface texture because of wear (Heymann 1987). Consequently, anatomic features such as developmental depressions, prominence, facets, and gingival perikymata should be closely examined and reproduced to the extent that they are present on the surfaces of adjacent teeth.

## **2.5 Position and alignment:**

The position and alignment of teeth in the arch can significantly affect the appearance of a smile, possibly disrupting its harmony and balance. A smile is more pleasant

when the teeth are well positioned and aligned. Poorly positioned or rotated teeth not only disrupt the shape of the arch but they also interfere with their apparent relative proportions. One or both of the following treatment options can manage such problems: (i) orthodontic treatment, (ii) direct or indirect adhesive restorations (Baratieri et al 1998).

Orthodontic treatment must always be considered particularly when other positioning and occlusion problems are present. If orthodontic treatment is not feasible, minor positioning defects, can be improved by adding composite resin or porcelain to strategic areas see Figure 14a (Ingervall and Hedegard 1974, Albers 1985). As can be seen in Figure 14b, minor rotations can be corrected by first reducing the enamel in the area of prominence and then augmenting the deficient area with composite resin. Care must be used to ensure that the resultant emergence profile of the restoration is not detrimental to the gingival health. Furthermore, a functional incisal edge should be maintained by appropriate contouring of the restoration. An excessively wide incisal edge should be avoided. If the occlusion allows, limited reduction of enamel on the lingual aspect can be done to reduce the faciolingual dimension of the incisal portion of the tooth (Heymann 1987). This is a compromise so unfortunately, only a few of these imperfections can be conservatively treated without significantly altering the occlusion and/ or the contour of the teeth especially in the gingival region (Heymann 1987) so orthodontic alignment has to be the prime treatment because the other features of the tooth or teeth remain natural.

## 2.6 Colour:

The natural tooth is polychromatic because it is composed of numerous structures and tissues (dentin, enamel, and pulp) which exhibit different optical properties. These components are non-uniformly distributed along the tooth crown. To duplicate such optical characteristics in monochromatic restorative materials with different physical and chemical properties to those of the tooth is a difficult challenge (Baratieri 1994). The polychromatic characteristic of teeth is mainly related to the colour of dentin and the varying thickness of the enamel at different sites in the tooth crown. Even though monochromatic teeth are found, polychromatic nuances are generally thought to be more attractive to the aesthetic eye. Sometimes a fourth colour dimension can be encountered as described by Muia (1993).

Colour, as well as form, has been divided into three dimensions (Clark 1973, Baratieri 1992, Miller et al 1993). Hue can be defined as the “name” a colour has, or “the basic colour of an object” (Sproull 1973) such as blue, green, yellow. Hue may be a primary colour or a combination of colours. Chroma can be defined as the “degree of hue saturation” or the “intensity” exhibited by a colour or the strength of the hue. Value can be defined as the “brightness” of a colour responsible for its “luminosity” (Baratieri et al 1998). Value is the relative amount of lightness or darkness in a hue so it is a very important characteristic when shade matching.

Colour gradation happens usually from the cervical region to the incisal, the first being generally darker or with greater chroma. In addition, many people have canines, which are slightly darker than these incisors (same hue, different chroma and value). Children and teenagers with thick enamel, large pulpal chamber and as a

consequence, little secondary dentin; have teeth that are more translucent (Baratieri et al 1998).

Translucency also affects the aesthetic outcome of restorations. The degree of translucency is determined by how intensely light penetrates the tooth or the restoration and the tooth before being reflected to the outside. Reduced light penetration due to the addition of opacifier results usually in a loss of aesthetic vitality. Illusions of translucency can be created to enhance the lifelike aspect of a restoration. Colour modifiers (known as tints) can be used to simulate translucency, to modify moderate discolourations, or to characterise the restoration (Baratieri et al 1998).

The artistic aspect of colour and its role in aesthetic dentistry are said to be undoubtedly the most complex and least understood characteristics (Heymann 1987). Nevertheless, a basic understanding of colour is essential for the accurate and consistent selection of appropriate shades of restorative materials. As teeth are typically composed of many colours, several different shades of restorative material may be needed to restore a tooth. By applying and curing small amounts of different coloured composite resins in different areas of the tooth it can be restored more appropriately. Shade selection should be done before the teeth are isolated to avoid colour variation that can occur from drying and dehydration of the teeth. Problems with perception also complicate the selection of the appropriate shade of restorative material because different light sources alter one's perceptions of colour; a phenomenon that is called metamerism (Sproull 1976).

The body of the tooth can be fairly uniform in colour, but the gingival third must be noticeably richer in chroma. The incisal usually should have blue, violet and/or grey hue to convey translucency. Opacities in the incisal region may also be used to reproduce the polychromatic nature of a tooth (Blitz 1997).

If appropriate a thin halo can be incorporated in the restoration and a hint of faint, internal mamelons may be desirable in some situations with younger patients (this may need to be modified later). Stains and crazing lines of a faint type can add a pleasing result (Blitz 1997).

### ***2.6a Hue***

The same hue is frequently found at the cervical and middle thirds. Because of the way the light is reflected, refracted, absorbed, and transmitted, distinct hues can be seen at the incisal third. Around the dentinal mamelons and extending to the proximal aspects towards the middle third, predominantly bluish or greyish hues are projected, imparting a beautiful and youthful characteristic. Maverick colours along the tip of the mamelons, as well as white hypoplastic spots and mottled enamel, may also contribute to an aesthetic hue variation at the incisal middle third (Fahl et al 1998).

### ***2.6 b Translucency and opacity***

Muia (1993) states that it is the dentin, which imparts the entire colour of a tooth, with the exception of the maverick colours, which usually, are present within the enamel

matrix. The enamel is but a fiberoptic structure which conducts light through its rods to capture the colour of the underlying dentin. Therefore, a decrease in dentin thickness from the cervical third (the thickest) to the incisal third (the thinnest) will automatically result in a decrease in opacity. Conversely, an increase in enamel thickness from the cervical third (the thinnest) to the incisal third (the thickest) will enhance the translucency (Vargas & Bouschlicher 1995).

### ***2.6c Chroma***

Since the dentin decreases in thickness from the cervical to the incisal third, the saturation also decreases. For restorative purposes, it could be stated that the chroma of the cervical third is one degree higher than that of the middle third (Fahl et al 1998).

### ***2.6d Value***

Value is perhaps the most important of all three-colour dimensions (Unbassy 1993). The variation in hue, chroma, and degrees of opacity is responsible for a variation in value along the crown. Normally, a higher chroma (more saturated hue) will elicit a lower value (darker). More opaque areas of greater opacity will show a higher value, whereas more translucent areas will show lower values because they reflect light wavelengths, which contain more grey and blue hues. The incisal third presents the lowest value of the three thirds (Fahl et al 1998).



## **2.7 Shape and size of incisal embrasures:**

The shape and size of the incisal embrasures change over time, which in turn affects the appearance of the teeth. By altering the shape of the incisal embrasure, the width of the tooth can apparently be changed see Figure 15. Smaller embrasures can make teeth look wider, while larger embrasures make them seem narrower see Figure 16 (Baratieri et al 1998).

## **2.8 Balance:**

A smile is more pleasing when the teeth are symmetrical (Heymann 1987). Hence, the importance of symmetry about the vertical line angles on the mesial of the maxillary central incisors cannot be over emphasised. However, reproduction of this characteristic in direct bonded restorations involving one or more proximal surfaces is extremely difficult, if not impossible to accurately reproduce (Baratieri et al 1998). But nature rarely produces absolute symmetry nor can the eye distinguish minor variations, possibly because many other factors are instantaneously being processed by the brain. Hence, a composite image is created within which a balance between the component parts is or is not achieved.

Thus balance may be more important than symmetry. Ideally, teeth on the left side of the arch must have the same “weight” in the composition of a smile as those on the right. That is all other aesthetic components observed in the dental and facial views (size of tooth, visibility, form, colour, position, surface texture, alignment, tilt, proximal embrasures, incisal embrasures, contact points, groove and development

ridges, and inciso-proximal angles) would be perceived to be in a much more harmonious form than their symmetry would predict. Similarly, the teeth in the opposing arch must be part of this balance (Baratieri et al 1998).

### *2.8a Proportions of the central incisors*

The proportions of the central incisors must be aesthetic and mathematically correct (Lombardi 1973) and can be determined/calculated in several different ways using different reference points and features of the oro-facial structures.

The width to length ratio of the centrals should be 4:5; however, a range for the width of 75%-80% of the length is, according to Chiche (1993), acceptable. They must be the dominant teeth in a smile and they must display pleasing proportions. The centrals are clearly the keys to the smile (Goldstein 1976). Their shape and location influences or determines the appearance and placement of the laterals and canines. Below 65%, the central incisors appear too narrow and above 85%, they appear too short and square. Selecting a pleasing proportion for the central incisor involves determining its ideal shape in relation to the face. The question for the clinician is: "what are the determinants of an ideal tooth proportion?" (Chiche & Pinault 1994)

#### *Proportion determined by statistical average*

The mesiodistal diameter of the maxillary central incisor was measured in numerous studies producing a range from a low average of 8.37 mm to a high average of 9.30 mm (Shillingburg 1972). The average crown length on extracted teeth according to

Shillingburg (1972) ranges from 10.4 mm to 11.2 mm. Therefore, the average width-to-length ratio extends from a low value of 0.74 to a high value of 0.89.

*Proportion determined by face form*

In 1887 Hall proposed the "typal form concept" in which he classified natural teeth into ovoid, tapering, and square categories. While Berry's (1905) "biometric ratio" method advocated that the outline forms of the inverted maxillary central incisor closely approximated the outline form of the individual face. In 1914 Williams introduced, under the "typal form method", his concept of harmony of tooth form with face form, which was almost universally accepted as the standard determinant of tooth form throughout the subsequent 40 years (Hughes 1951, Young 1954).

*Proportion determined by anatomic characteristics*

It is highly unlikely that ideal dimensions of the maxillary central incisor can scientifically be generated from face form or any oro-facial features. Instead, subjective criteria probably prevail. Esthetically pleasing proportions being expressed as a width-to-length ratio ranging between 0.75 to 0.80. In spite of wide variations in personal interpretation and perception, and personal preference it is the clinician that must refine a sense of proportion based on his or her observations of what is pleasing. Restrictions may be imposed by the actual tooth positions, arch width, and gingival outline; however, obviously narrow and elongated, or short and wide central incisors must always be avoided in aesthetic reconstruction (Chiche & Pinault 1994).

One of the commonest mistakes in aesthetic restorations is to make maxillary incisors appear out of proportion to one another: the lateral incisors are often slightly oversized at the expense of the central incisors. The goal of the clinician is to shift the dominance from the lateral incisor to the central incisor. When in doubt, the central incisors should be slightly oversized because their line angles may be readjusted later to give the illusion of a narrower tooth (Chiche & Pinault 1994).

### ***2.8b Incisal edge position***

Phonetics help determine the incisal edge position. The incisal edges should lightly touch the vermilion border of the lower lip when making “f” and “v” sounds (Pound 1973, Dawson 1974). This feature then helps in the determination of the length of each tooth. The principles of proportion are also instrumental in determining desired tooth length. The combination of correct lip support and the linguolabial position of the incisal edge determines the pitch of each anterior tooth. Anterior guidance and the labial contour further influence this location and lingual contours (Dawson 1974).

The incisal edges of the maxillary central incisors and the cusp tips of the canines should be on the same gently curved horizontal line, with the lateral incisors approximately 1.0 mm above the line. It should also be noted that beginning with the mesial of the central incisors, the interproximal contacts of the maxillary anterior teeth are situated successively more gingivally, all the way to the distal of the canines (Shillingburg 1997).

Care and attention to correctly locating the incisal edge position is crucial because it determines the pitch of the anterior teeth, establishes the correct labial contours, provides proper lip support, determines the lingual contour, influences anterior guidance and ensures that restorations follow the curvature of the superior border of the lower lip (Blitz 1997).

### ***2.8c Emergence profile***

The emergence profile, the cross section of the tooth at the point of emergence from the gingival tissue, needs to be carefully determined because a proper emergence profile helps to avoid gingival inflammation and swelling due to overhanging margins and to avoid the appearance of unsightly dark spaces in the gingival embrasure. Hence, the emergence profile must reproduce the idealised, apparently natural eruption of the enamel from the healthy gingiva (Blitz 1997).

### ***2.8d Labial contour***

The labial contour should exhibit two distinct planes; gingival and incisal. This should be evaluated from the lateral view. The most common error made in anterior restorations is over-contouring of the incisal one third, thereby making the profile of the incisors too straight or too flat (Dawson 1983, Blitz 1997). Ideally, the incisal edge should be posterior to the gingival margin on the labial face in order to achieve the correct labial contour. It is said that the contour of the incisor can be verified by locating the incisal edge position relative to the mucous cutaneous border of the lower lip during “f” and “v” formation during speech (Dawson 1983).

The pleasing appearance of the natural maxillary central incisor lies in its two pronounced facial curvatures, in part because it generates different reflective patterns. When not present in a poorly contoured restoration it leads to a monochromatic bright appearance (Dawson 1983).

Clinically, the challenge is to produce a labial contour that preserves the original aesthetic appearance and provides a comfortable and unrestricted anterior guidance. Gross overcontouring of the incisal third may be detected by measuring the buccolingual thickness of the crown at the junction of the middle and incisal third. The average thickness of a natural maxillary central incisor ranges in this zone from 2.5 mm for a thin tooth to 3.3 mm for a thick tooth. Thus overcontouring may be suspected when the crown thickness exceeds 3.5 mm (Chiche & Pinault 1994).

### ***2.8e Incisal embrasures***

From the central to the canine there should be a natural, progressive increase in the size of the incisal embrasure. This is a function of the anatomy of these teeth and as a result, the contact points moves apically from the central incisor to canine. Failure to abide by this characteristic and not to provide proper incisal embrasures will make the teeth appear too uniform (Blitz 1997).

When the contacts are located farther gingivally, the incisal embrasures become larger, creating a more dynamic and youthful smile. Also, with age and increased wear, the incisal embrasure becomes minimal. So soliciting the patient's opinion for which "type of look" they would like should be considered (Shillingburg 1997).

The incisal edge of the central incisor can be considered to be the cornerstone on which the smile is built, because it serves to determine proper tooth proportion and the gingival level. Elongation of the incisal edge is often indicated to correct incisal wear, insufficient tooth display, or displeasing tooth or crown proportion (Chiche & Pinault 1994).

The primary determinants of incisal length are the age and gender of the patient; the length and curvature of the upper lip; and the patient's preference. The accessory determinants of incisal length are the posterior plane of occlusion (Spear 1991) and average anatomic crown length values for the maxillary central incisor (Shillingburg 1972, Allen 1978) which range from 10.4 to 11.2 mm.

### ***2.8f Labial anatomy***

The presence of lobes on the labial surface is important characteristics because they allow a more natural and varied pattern of light reflection. The proper placement of lobes can also influence the perception of width. Incisors of similar dimensions can be made to appear wider by placing the lobes slightly closer to the interproximal surfaces and conversely teeth can be made to appear narrower by locating the lobes and height of contour slightly closer together (Blitz 1997).

### ***2.8g Surface finish***

Consideration must be given to customising the surface texture for each individual i.e., smooth vs. perikymata (stippling, rippling of enamel). The degree of polish and lustre should be influenced by the presence of these features on the various teeth that are visible for examination (Blitz 1997).

### **3.0 Natural variations:**

#### *Dental midline*

It is well known that “A perfectly vertical dental midline reinforces the perception of order and organisation but also imparts some artificiality” (Frush & Fisher 1958). Miller and co-workers (1979) found that the dental midline coincided with the median line of the face in 70.4% of the population. This is consistent with the "dentogenic" concept, which states that “an eccentric midline, if not too exaggerated, is acceptable and lends to the illusion of the natural dentition.” (Frush & Fisher 1958)

#### *Maxillary central incisors*

These teeth must be kept symmetrical at least within reasonable limits. Only minor asymmetries are allowed, because bilateral asymmetry of the maxillary central incisors has been found not to exceed 0.3 to 0.4mm in the mesiodistal width (Garn et al 1968, Marroskoufis & Ritchie 1980).



### *Maxillary lateral incisors*

Maxillary lateral incisors differ bilaterally in shape, rate of attrition, axis, rotation, and length. This variation can be exploited when placing a restoration, which in turn can display asymmetry.

### *Maxillary canines*

The canine tips are generally not displayed evenly during a smile and the incisal embrasures will progressively deepen from central incisor to canine (Greenberg 1992) and tend to be bilaterally asymmetrical. Another common finding is a difference in the buccolingual inclination of the canines, which results in bilateral asymmetry of the incisal embrasures. Therefore, an important role of the canines is to control the effective width of the smile.

Mesial inclinations of the teeth are more pleasing than a distal inclination (Kessler 1991). Maxillary anterior sextant tooth length and position are evaluated by comparison or contrast with the adjacent teeth. Altering an individual tooth's shape may cause an alteration in the perception of the adjacent teeth. Therefore, anterior teeth are interpreted in perspective to one another, giving rise to the cardinal rule "... everything is relative to each other." (Chiche & Pinault 1994).

In the natural dentition, the four maxillary incisors usually have the same shade, whereas the canines appear darker. It is preferable to create a smooth transition with

progressive shade saturation from the central incisor through to the canine. This characteristic emphasises the dominance of the maxillary central incisors because their value is higher than the lateral incisors and this generates a pleasing diversity and individuality between the crowns of the teeth (Geller 1991).

In summary, the three most commonly made mistakes when reconstructing anterior teeth are producing a flat facial aspect on the central incisors; making the lateral incisors too wide and/or making the central incisor too narrow; and leaving a straight incisal plane. The overriding objective should be to shift the dominance from the lateral incisors to the central incisors. If the central incisors must be widened, they should, if feasible, also be elongated to achieve optimal proportions.

## **4.0 The importance of aesthetics in restoring fractured anterior teeth:**

The appearance of any individual's face is an extremely important role in the aesthetic of that person. The maxillary anterior teeth play a fundamental role in the overall facial aesthetics (Jenny & Proshek 1986, Jenny et al 1990). Since these teeth are often subjected to trauma and, consequently, fractures, it is necessary for the clinician to be aware of the elements and basic norms of aesthetic so that restorations can be provided for the patient that restores a more pleasant smile. The clinician has to be especially aware of these principles when placing a direct restoration to replace lost coronal tissue (Baratieri et al 1998).

Pilkington (1936) defined dental aesthetics as "the science of copying or harmonising our work with that of nature, making our art inconspicuous". Recently, greater emphasis has begun to be placed on aesthetics and even this is changing the focus of dental practice from restoring carious teeth to treating healthy teeth to make them more aesthetic (Reinhardt & Capiulonto 1990). The development of new techniques and restorative materials to meet this new demand now means that a greater number of treatment options, capable of improving or restoring the natural look of teeth, are available to the clinician (Qualtrough 1994). Although these options are becoming simpler and more conservative, the clinician must still be conversant with the principles necessary to produce a pleasing result. However, it must be remembered that aesthetics are something very personal. The standards vary according to the time and the region where people live and personal preferences. Therefore, an individual's preferences and their image of their own smile must not be ignored. If a person feels

comfortable and happy accepting that his/her smile is not the loveliest in the world, there is no reason to change it, and when reconstructing a damaged tooth the ultimate goal for that individual may well be different to that of another patient. Nevertheless, there are norms, which can guide clinicians to render their patients' smile more aesthetically pleasant. Such norms must start with considering aspects of an individual's general appearance and then focusing down on the details of a single tooth. Contrary to many dentists' beliefs, only 30% to 40% of adults with, what a dentist would perceive as inharmonious anterior teeth, are not satisfied with the appearance of their smile (Goldstein & Lancaster 1984). Unfortunately, many dentists apply their own aesthetic standards to their opinions rather than seeking the patient's expectation of the treatment. As a consequence, many teeth end up unacceptably or even unnecessarily restored in an effort to produce a "standardised beauty" (Goldstein 1969).

When one, or more teeth, which influence the smile, have to be restored, the clinician must analyse those teeth and the relationship of the individual teeth to the adjacent teeth, the periodontium, and the other oro-facial structures. For a better understanding of the subject, the different factors influencing the smile can be divided into two categories: those, which cannot be changed by the clinician and those that can be modified (Baratiari et al 1998).

A primary objective in restoring anterior teeth is to blend the new restorations into the tooth structure so as to make them imperceptible by the patient and other people he or she may encounter. Probably, one of the greatest secrets in the art of being able to produce unnoticeable restorations, using composite resin, is to be able to observe the

natural teeth from all possible angles and to be aware of the subtle features of the various surfaces. Then to be able to reproduce the features of natural teeth by paying attention to those natural teeth and remembering that they exist not only as discrete entities but also as part of the dental arch (Baratiari et al 1998).

While aesthetics is a fundamental consideration in the treatment planning for traumatised anterior teeth It is crucial to institute a systematic follow-up programme for at least two years post-trauma because subsequent changes to the pulp, root, or supporting structures might compromise an initially good prognosis (Andreasen & Andreasen 1985, Andreasen 1989).

The treatment of fractured incisors is a major part of any paediatric dentists work because the frequency of fractures in children between 8 and 17 years old is approximately 16% (Black et al 1981). The conventional methods for the treatment of coronal fractures of anterior teeth using pin-retained composite resins, porcelain laminate veneers, or full-coverage porcelain crowns have now given way to less invasive procedures using directly applied composite resin. The procedures frequently utilise a freehand build-up of composite resin. Advanced formulations of composite resins with high sculptability with a wide range of shade now allow the anterior teeth to be predictably restored in a manner that replicates the polychromatic characteristics of the natural dentition. When utilised with an understanding of tooth morphology and the physical properties of the materials; optimally aesthetic restorations can be predictably placed (Terry 2000). These techniques can also be successfully applied to teeth with a size discrepancy, morphological abnormality, localised areas of

discoloration and even correcting discoloration of an entire tooth (Fahl 1996, Dietschi and Schatz 1997).

## **5.0 The Principle of Restorative Techniques and the Materials:**

The materials available for conservative restorations cannot be expected to mimic every variation of a natural tooth. Composite resins are anisotropic, in that their structures are characterized by two phases; glass particles or crystals contained in a resinous matrix (Roulet 1994). Although the dentist seeks to prepare a surface on the restoration that is as smooth as possible, unfortunately they become rough with time (Willems 1992).

If the purpose of a reconstruction is to imitate nature and achieve the illusion of natural, healthy teeth, one might conclude that tooth conservation with directly applied composite materials are unable to produce a satisfying result. However, this conclusion would be false for it is possible to create a perfect aesthetic result with the appropriate adhesive technique. However, this is true only of results viewed from the distances conventionally maintained between people in normal social environments. Such restorations are invisible at a distance of approximately 1m, but cannot be concealed from a close-up examination (Roulet 1999)

Good aesthetic results can only be produced by meticulously observing the properties and manipulation details of the materials used in adhesive dentistry. The choice of shade should be made before the rubber dam is placed, so that drying of the teeth, which results in shade alterations of white and opaque, does not give rise to an

inappropriate choice. It is advantageous, according to Roulet (1992) to produce personal shade matching guides from the composite materials because the shade guides produced by the manufacturer do not correspond accurately in colour and translucency of their composite resin. Even so no single monochromatic composite resin can be expected to replicate the complex mixture of colour in a natural tooth, the dentist has to learn to make the appropriate selection of multiple shades (Kim and Um 1996). The cavity should include a bevel so that a natural transition arises between the composite and the enamel (Porte et al 1984). A realistic shade is achieved when a dentinal core is built up with a colour that is somewhat too dark, which is then covered with a lighter, more translucent “enamel” material. If indicated, incisal translucency can be achieved well with a translucent variation of the material.

Sculptable composite resins that easily maintain their shape have also been developed, which permit the clinician to realistically replicate teeth contours and minimise finishing procedures. Although a direct restoration may have a more limited life span than an indirect restoration, this can present certain clinical advantages. Direct resins are weaker than tooth structure, and are less able to withstand damage by teeth in the opposing arch than porcelain. Nevertheless, their longevity is acceptable and they are significantly cheaper than porcelain (Roulet 1999). Composite resins can also be more easily repaired than porcelain, which can be a benefit in certain instances. In addition, the placement of indirect restorations requires tooth reduction, so the more conservative approach used with composite resins is favoured by many clinicians because it does not compromise biologic, functional, and aesthetic integrity (Roulet 1999).

Composite resins have become an everyday item in the armamentarium of aesthetic restorative dentistry. However, technological changes take place very rapidly with respect to the composites and their bonding systems. Therefore it is essential for dentists to regularly update their knowledge to ensure that patients will benefit from the latest developments (Roulet 1999), and recommendations for the manipulation of these materials

### **Restorative technique:**

Whether or not composite resin is being placed to restore a damaged tooth, or to build-up its size or shape there are some basic principles that should be followed. Placement of use of rubber dams, cotton rolls, or gingival retraction cord will help prevent moisture contamination of the restoration site (Valentine 1987). Once a preparation has been made and the enamel etched, the careful addition of small increments of composite resin with a thin, flat plastic type of instrument should be commenced avoiding the entrapment of air. Building up the lingual before the labial surface will assure ease of placement and decrease the risk of creating voids.

Mylar strips can be used to create the final proximal contour, but precautions should be taken not to create an air-inhibited layer on the surface of the composite (Philips 1982); because when composite resins are polymerized, the reactive sites at the surface of the resin have free radicals at the end of the long-chain polymers which can continue to be used by additional macromolecules contained in additional increments. This process allows continuous addition of new composite resins to the already



polymerised resin. However, if the material is cured with a Mylar strip or a celluloid crown form placed directly on the material, an air-inhibited layer is produced. Additional material can no longer be added to this cured surface without a drastic reduction in the final compression and sheer strengths. Therefore, the Mylar strip must be placed over the composite surface only when the final increment of composite has been placed (Valentine 1987).

If a void is found when finishing a restoration, either the composite resin should be removed entirely and the bonding process restarted, or a new carbide bur can be used to enlarge the void and to create a mechanical undercut (Valentine 1987). Finishing should be minimal and done using flexible disks coated with aluminium oxide so as to preserve the integrity of the enamel resin bond so as to leave an aesthetic result (Roulet 1999).

## **6.0 Technique for the correction of teeth of abnormal size and shape:**

The presence of a microdont maxillary lateral incisor can have negative affects on the balance, proportion, and symmetry of the teeth in the anterior sextant, which results in the loss of aesthetics (Kokich 1993).

In the past as tooth with an abnormal morphology would have been extracted if crowding were present. However, with the availability of modern materials such as composite resin, crowns and veneers to modify the tooth, it is not mandatory to extract the affected tooth. Nevertheless, these two options for the management do exist (Miller et al 1987).

The recent advances in restorative materials mean that there are available to alter the morphology of such microdont teeth; direct composite build-ups, indirect composite resin veneers, porcelain veneers and resin-bonded porcelain crowns (Counihan 2000). In the young child a composite build-up is probably the best restoration since it can be used without any preparation of the enamel and is essentially reversible (Kidd & Smith 1992).

In some situations, there is sufficient space to restore a microdont tooth; however, when there is insufficient interproximal space for the restoration, the adjacent central incisor and canine may need to be moved apart orthodontically to facilitate recontouring (Lewis and Eldridge 1992). This simple and rapid tooth movement will provide sufficient space to temporarily restore the lateral incisor. Immediate temporary restoration of proper tooth width is advisable to avoid shifting of the adjacent teeth during the final portion of the orthodontic therapy. Extra space should be created to permit adequate finishing of the interproximal surfaces of the temporary restoration when the space is open. Several phases of tooth movement maybe necessary to restore all surfaces of the appropriate teeth. Final restoration of the tooth should follow orthodontic retention and when the gingival level is also stable The final restoration may even be a veneer see Figure 17 (Kokich 1993).

The stages of the technique of building up peg-shaped right maxillary lateral incisor are shown in Figure 18. Following the technique as described by Jordan (1993) (Appendix 2).

## 7.0 Conclusions:

Today's dentists are highly trained in the science of adhesive dentistry and are able to carry out the mechanical steps to achieve a sound restorative result quite easily. However, the artistic skills to achieve a highly aesthetic (i.e., invisible) restoration at the same time, can sometimes prove elusive. This is because it requires an in depth understanding of the components of colour and their relationship to natural tooth structure and composite resin restorative materials. As in all art, it also requires a heightened sensation on behalf of the observer.

If the clinician understands the relationship of hue, chroma, and the values of translucency and opacity, and can relate these characteristics of natural teeth to the available composite resins and their modifiers, it will not be necessary to memorise formulae to aesthetically restore anterior teeth, and the process will be less complex than it may seem.

Through an enhanced understanding of the three-dimensional concepts of tooth morphology, colour, and the optical properties of light as well as their interrelationships with the natural tooth structures; composite resin can be used to fabricate restorations that are virtually indistinguishable from the adjacent dentition (Terry 2000).

To contribute to a pleasing facial appearance, particularly when the patient smiles, contours, size, incisal edges, occlusal plane, and midline must be in harmony.

In conclusion, there are two main objectives in dental aesthetics; (i) to create teeth of pleasing inherent proportions and of pleasing proportions with respect to one another, and (ii) to create a pleasing tooth arrangement in harmony with the gingiva, lips, and face of the patient.

These objectives can be achieved, in a more predictable way, by offering a resin composite that exhibits an appropriate degree of fluorescence and opalescence, as well as a suitable range of shades and opacities. The second step is the use of a natural layering technique in the application of the composite, based on the distinctive replacement of both dentin and enamel (Dietschi 1997).

The main advantage of direct composite resin bonding is the possibility to obtain an immediate aesthetic result and patient satisfaction after only one or two dental office visits, conservatively and at a relatively low cost (Feigenbaum & Mopper 1984, Heymann 1987). The entire procedure is controlled by the dentist and yields good results if he or she is skilled and knowledgeable. Strength and wear resistance are moderate, and repeated chipping or discoloration can occur. Hence, longevity is fair to good, and the coverage of certain discoloration is difficult. In addition, good clinical ability with shade and contour is essential for medium and large restorations (Chiche & Pinault 1994).

The pursuit of excellence in adhesive dentistry is yet further confirmation of Leonardo Da Vinci's philosophy; which postulated that "art and technology are one and the same." (Dietschi 1997).

## **Appendix 1**

### **Step-by-step Operative Techniques in the Direct Adhesive Restoration of Fractured Anterior Teeth (adapted from Baratieri et al 1998):**

1. Control the patient's health/disease condition before starting restorative treatment.  
Instruct the patient of the importance of maintaining this balance for the total success of treatment.
2. Mark the occlusal contacts (lateral and protrusive).
3. Select the composite resin according to what the case requires. If necessary, conduct a "diagnostic restoration" to test the effect of the shade selected and to "preview" the shape and anatomical details of the restoration.
4. Isolate the field.
5. If necessary, prepare a bevel or chamfer.
6. Apply antimicrobial agent for 10 seconds (chlorhexidine).
7. Select the treatment to be given to enamel and dentin. Use a "current generation" resin adhesive system, which can be used without liners. Etch enamel and dentin, wash, dry (do not dehydrate), apply primer, dry, apply adhesive, spread lightly, and cure. In case a traditional system is used, apply a glass ionomer liner over the dentin and a universal adhesive following acid etching of the enamel.
8. Select, prepare and install the matrix.
9. Apply and cure the composite resin, following the incremental sequence.
10. If a rubber dam has been used, remove it.

11. Check the occlusion for adjustment.
12. Finish and polish the restoration.
13. Instruct patient in postoperative care.
14. Schedule the patient for re-evaluation visit.

### **Indications for Direct Veneers (Baratieri et al 1998):**

1. A tooth with a colour alteration, which markedly affects the smile and which, does not respond positively to bleaching techniques.
2. Poorly formed teeth, e.g.: (a) cone-shaped lateral incisors (b) hypoplastic anterior teeth (c) Hutchinson's incisors
3. Anterior teeth with large carious lesions.
4. Anterior teeth with multiple deficient restorations (Class III, IV and V) which cannot be successfully be replaced with simple restorations.
5. Very special situations calling for the "transformation" of lateral incisors into central incisors and canines into lateral incisors.
6. The "realignment" of anterior teeth which have a slight lingual inclination.
7. Teeth with long erosion/ abrasion lesions.
8. The reduction or closing of some diastemas.
9. Fractured anterior teeth when adjacent teeth already present resin veneers
10. Fractured anterior teeth with intact adjacent teeth, when fracture is large and aesthetics cannot be adequately restored with short bevel preparations.

### **Advantages of Direct Veneers (Baratieri et al 1998):**

1. Direct composite veneers are amenable to repair, usually fast, safe and efficacious.
2. In a few instances (e.g. teeth in linguo-version and /or with and altered shape but no discoloration), direct veneers can be performed without any kind of preparation which make them fully reversible.
3. Since these restorations are done without a laboratory phase, their costs can be substantially lower than that of indirect veneers.
4. With a special matrix, these restorations permit reproduction of shape, contour, texture, and size of the tooth similar to those existing before preparation.
5. Time involved in placing direct veneers, depending on the dentist's skill, artistic aptitude, and training is substantially less than for indirect restorations, which reduces costs.
6. Direct veneers are usually prepared more conservatively than indirect ones.
7. No temporaries are required.
8. No impressions are necessary.

### **Disadvantages of Direct Veneers (Baratieri et al 1998):**

1. Direct composites have a lower resistance to wear than enamel.
2. There is a risk of air bubbles being formed under the veneer surface. These bubbles, exposed by wear of surface resin by brushing and/or abrasive food, have non-polymerised composite. It is more vulnerable to discoloration and degradation.

3. In most situations, the contour and texture of the veneers is dependent on the dentist's skill and artistic ability. Time spent to place them may make the cost too high to many patients.
4. Microfilled composites are subject to chipping, particularly when used in high stress areas.
5. The translucency of thin layers of composite makes it extremely difficult to mask dark backgrounds without the use of opaquers.
6. All composites suffer polymerisation reaction shrinkage. This can introduce enamel cracks and/or break the adhesive bond with dentin, introducing unfavourable consequences.



## **Appendix 2**

### **Step-by-step operative techniques in the direct adhesive restoration of microdont anterior tooth (adapted from Jordan 1993):**

- (1) The distolabial enamel surface is flattened (enameloplasty) using an appropriate diamond instrument (Figure 19).
- (2) A maxillary right lateral incisor crown form is trimmed and fitted and then removed (Figure 20).
- (3) The enamel surface is then phosphoric acid etched, washed, and warm-air dried (Figure 21).
- (4) A layer of bond resin is then brush applied to the enamel surface and visible-light cured (Figure 22).
- (5) The crown form matrix is then filled with hybrid composite, placed into position, and an anatomically contoured wooden wedge is placed in the proximogingival embrasure (Figure 23) and the composite is visible-light cured.
- (6) The composite material is then finished, contoured, and polished. Discs (Figure 24) are used to finally contour and smooth the composite surfaces; strips are used for final proximal (Figure 25).
- (7) Surface lustre is accomplished using foam-polishing cups (Figure 26).
- (8) The final restoration is shown in Figure 27 and another example is shown in Figure 28.

## **Appendix 3**

### **Restorative material considerations in relation to the restorative sequence:**

A comprehensive knowledge of composite resins and their individual properties is necessary in order to properly restore the anterior dentition. Since the introduction of visible light-cured composite resins in the early 1970s (Buonocore 1973), numerous formulations with varying physical properties have become available.

Micro-hybrids have enough resistance for most stress-bearing areas in the anterior segment of the arch, and the initial polish may equal that of a microfill, depending on the polishing material used. However, they are neither capable of maintaining, nor enhancing their high gloss with time, as do the microfills. It is therefore necessary to employ different resins bearing different physical properties for the various areas of the tooth (Fahl et al 1998).

### **Restorative sequence**

Each third of the tooth is restored with a composite resin according to the principles of hue, chroma, value, opacity, translucency, strength, and polishability necessary for each area (Fahl et al 1998). A prepared natural central incisor is used to illustrate the sequence (Figure 29 & 30).

### **Cervical third**

A composite resin with a certain amount of resiliency is required for this area to withstand the flexural stresses that increase during function (Grippio 1991). A more highly filled composite will probably lead to marginal breakdown with subsequent leakage (Miller 1995). A combination of higher opacity and intensified chroma is another characteristic to be considered. Finally, a resin that will impart the best polishability should be the material of choice. When all of these requirements are fulfilled, the end result is an opaque, slightly saturated, microfilled composite resin (Figure 31).

### **Middle third**

In this area, there is a need for increased strength. Shear forces are of greater magnitude, and a restorative resin, bearing high cohesive strength, is indicated (Grippio 1991). There can be a very slight increase in translucency at the middle third when compared with the cervical third, although this is not true in every situation. Therefore, a resin combining strength and diverse degrees of opacity should be used as the core, body or "artificial dentin" of the restoration (Figures 32 & 33) (Fahl et al 1998). Among today's composite formulations, the hybrids and /or microhybrids are the resins, which are best suitable for the core of the restoration. Due to the similarities in optical properties they share with dentin, hybrids and microhybrids can mimic natural dentin quite well. A chroma one tone darker than the final desired shade should be used for this reconstructive step (Fahl et al 1998).

The shape of the artificial dentin should equal that of the natural dentin after a complete enamel demineralisation. The outermost boundaries of the artificial dentin should not exceed the projected dentoenamel junction (DEJ) of the tooth leaving a space for a layer of "artificial enamel". The final layer must be of a microfilled composite resin whose characteristics should resemble those of the natural enamel. There is a need for more translucency here than that given by the opaque microfill used on the cervical third. Yet, the resin must be capable of imparting the final blocking shade (usually with a lower chroma) to the restoration without totally blocking out the reflection of the underlying hybrid (Fahl et al 1998).

The final desired shade must be achieved with the "artificial enamel" resin. To produce a life-like restoration, polishability is once more necessary at the outer surface of the restoration. Freehand bonding relies on the artistry of sculpting composites into a precise anatomic shape with the aid of spatulas and brushes, not merely on confining a disorganised mass of resin into a performed matrix before polymerisation. Therefore, sculptability is another absolutely essential property that must be present in a microfill (Fahl et al 1998).

### **Incisal third**


Of all three thirds, the incisal third is perhaps the one that presents the most serious challenge, because perception of the multiple variations in hues, chromas, and values is necessary in addition to the intricacy of anatomic details, to precisely reproduce the natural dentition. Since this area has to withstand the greater stress of all, it is imperative that a composite resin with high fracture resistance be used. In addition to

strength, a high degree of translucency is necessary between and around the mamelons, which may vary from imperceptibility to accentuated dentin elongation of distinct polychromatic effects (Figures 34-37). Hybrids are usually the best restorative material for this area. Shades in the darker range (higher chroma) are required for the mamelon buildups. The resistance of incisal hybrid should encompass the incisal and proximal aspects (Figures 38 & 39). The incisal third can at times be so diversified in terms of polychromatic nuances that the aid of tints and opaquers is necessary to mimic a natural tooth. These aids allow the creation of an intricate refinement of hue, chroma and value. Blue, grey, or lavender tints should be used sparingly in order not to overemphasise the desired outcome (Figure 40) (Fahl et al 1998).

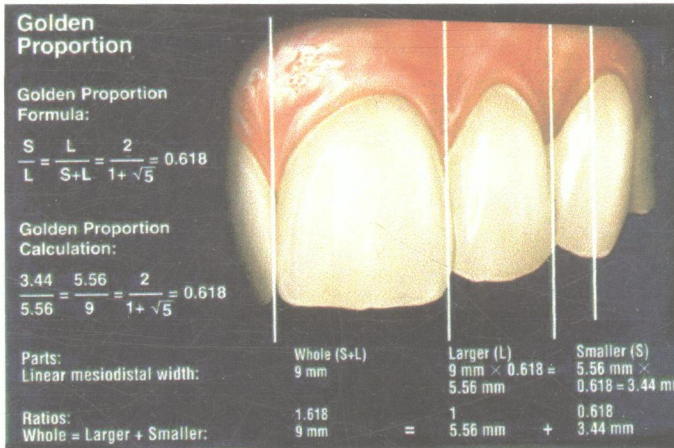
Opaquers most frequently used to mask undesired dark spots in teeth or even restorations can be of significant value when used to chromatize mamelons, simulate craze lines, hypoplastic lesions, or any other type of stains (Figures 41-43) (Fahl et al 1998).

Finally, care must be taken not to overbuild the artificial dentin, which would then leave insufficient space for the final microfilled layer. This microfilled layer must completely cover the cervical, middle, and incisal thirds, imparting the final anatomic form to the restoration (Figures 44 & 45). Usually, the shade of microfill that is used for the middle third can be used for the incisal third, depending on the particular case. If extra translucency is desired, and the intricate colouring must project through, a microfilled incisal should be layered over the entire underlying hybrid core, which consists of the artificial mamelons and the translucent hybrid incisal. After the restoration is finished and polished, the intricacy of anatomical details and colour

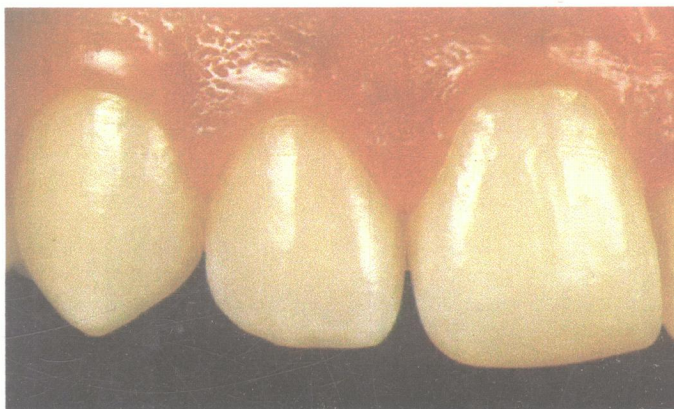
variation can best be perceived (Figures 46 & 47) (Fahl et al 1998). Therefore, it is highly possible today to restore anterior teeth to a higher level of functional integrity and aesthetic excellence (Figures 48 & 49).



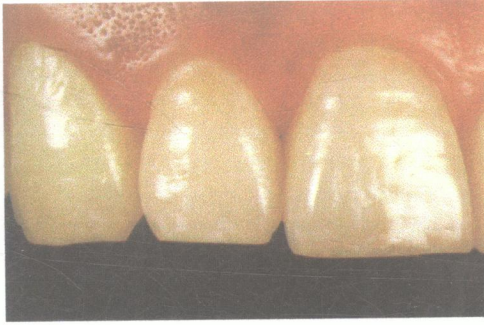
**Figure 1.** The width/length ratio of 3 maxillary central teeth: the blue tooth has a ratio of 0.9 and is short and wide; the green tooth is 0.6 and appears long and narrow. The red has the correct ratio of 0.75.



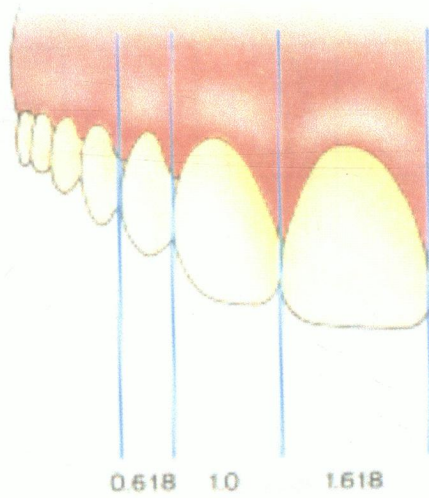
**Figure 2.** The Golden Proportion representation.



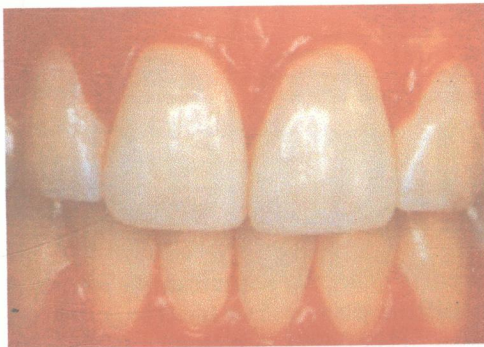
**Figure 3.** Youthful teeth demonstrating sharp, unworn incisal edges with an increasing incisal embrasure angle progression from the central incisor to the canine.



**Figure 4.** Aged teeth reveal attrition of incisal edges and inconspicuous incisal embrasure angle progression.

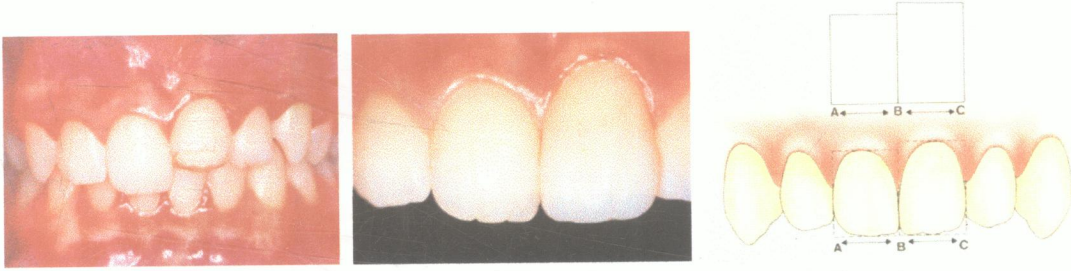

**Figure 5.** Schematic drawing showing “golden proportion” exhibited by the teeth on the right side.



**Figure 6.** Example of how the lips apart and the angle of sight affects the appearance of the teeth.





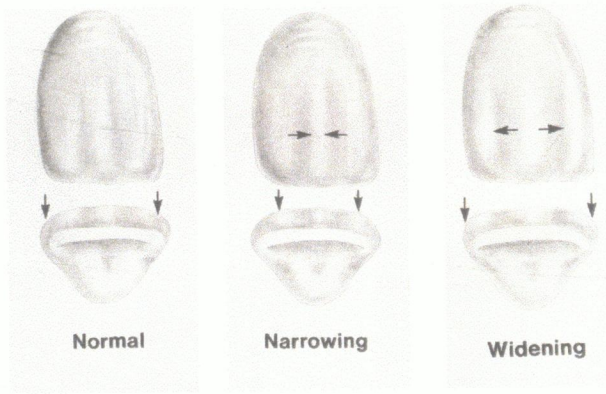
**Figure 7.** Influence that length has upon the apparent width of teeth.

Types of basic forms	Square	Triangular	Oval
<b>A</b> Facial ridges and grooves (frontal view)			
<b>B</b> Incisal line (incisal view)			
<b>C</b> Incisal line (frontal view)			
<b>D</b> Thickness and lip line (horizontal sectioning at center of crown)			

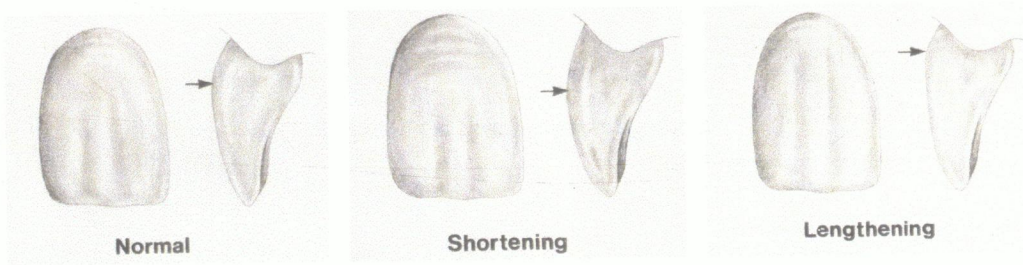
**Figure 8.** The three basic forms of teeth, and their different surface patterns.

Type	A	B	C	D	E
Percentage	51%	19%	0.5%	17%	12%

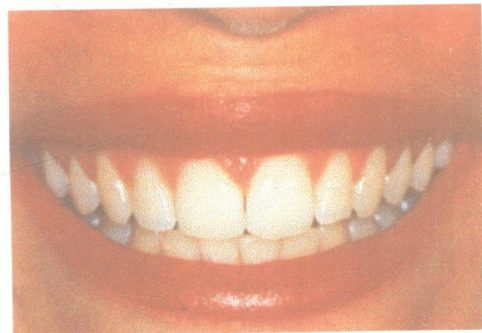
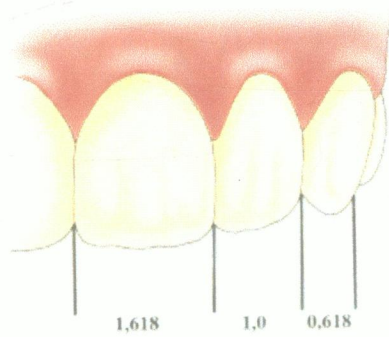
**Figure 9.** Yazaki's classification according to the depressions and the extension of facial surface characteristics on upper central incisors. (Yamamoto et al 1990/1991)



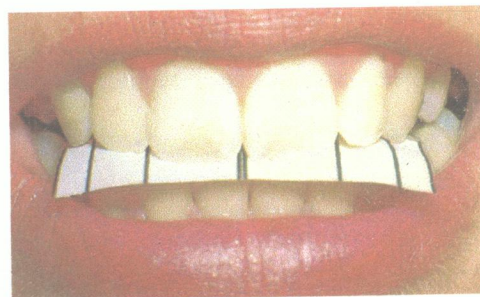
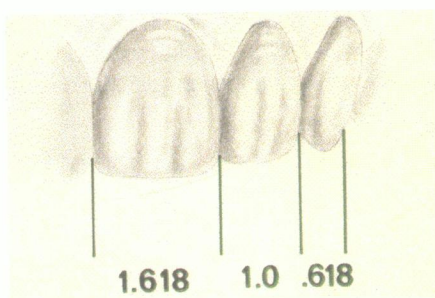
**Figure 10.** Creating illusions of width.



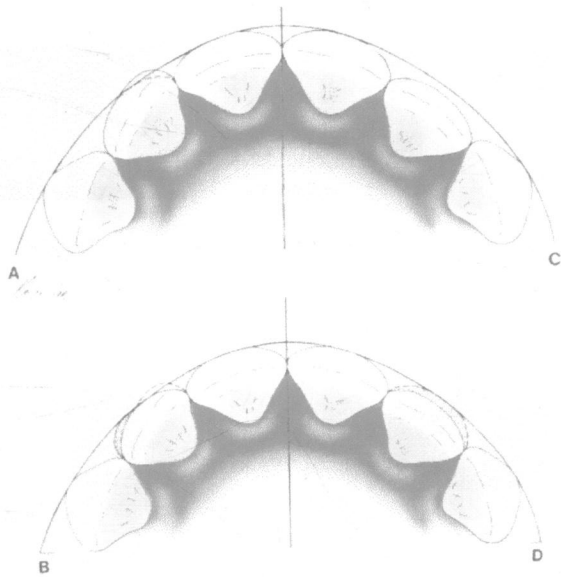
**Figure 11.** Creating illusions of length.



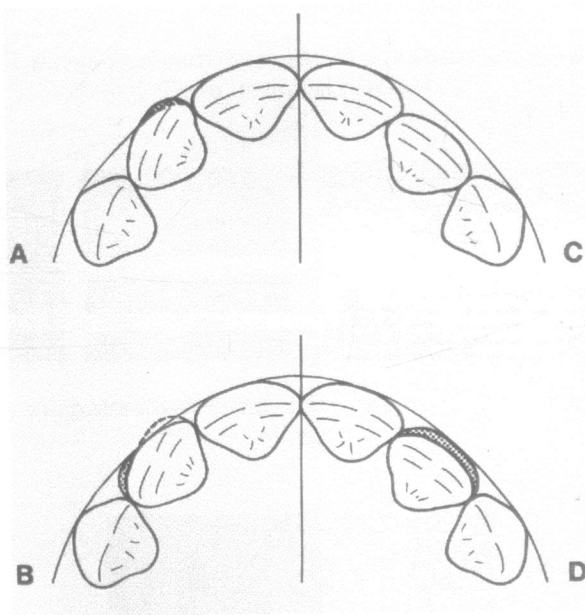
**Figure 12.** "Golden proportion" applied to the composition of anterior teeth.



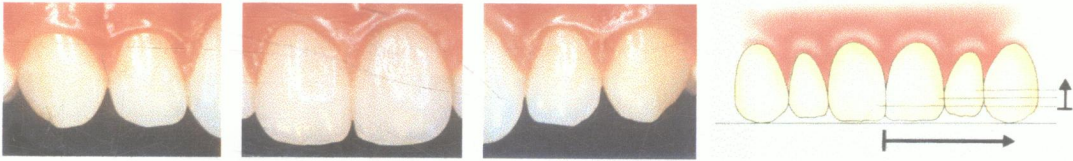**Figure 13.** The anterior teeth in "golden proportion" to one another.



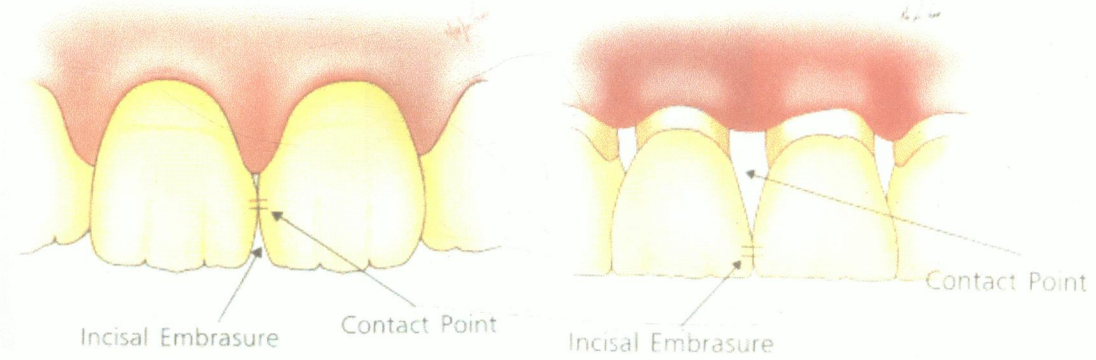
**Figure 14a.** Position and alignment.



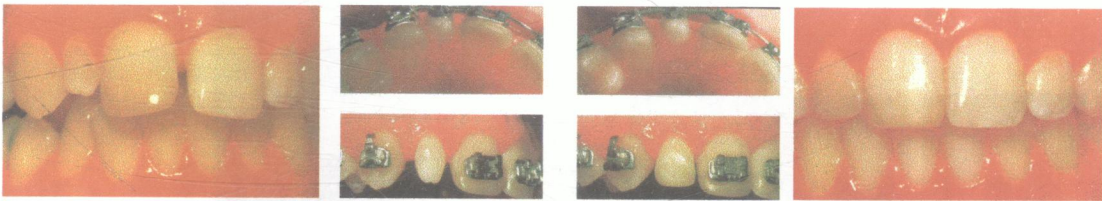
**Figure 14b.** A. minor rotation is first treated by reducing enamel in the area of prominence.  
 B. composite resin is used to restore the deficient area to proper contour. C. maxillary lateral incisor is in slight linguoversion. D. restorative augmentation of facial surface corrects malposition.



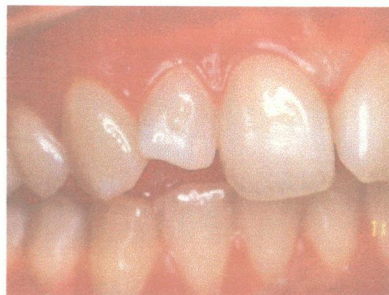
**Figure 15.** Form and size of incisal embrasures.



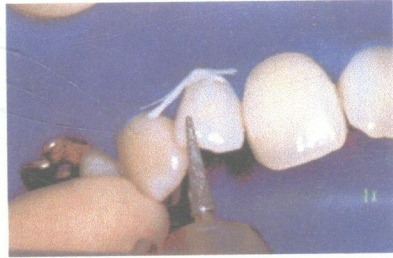
**Figure 16.** Inciso-cervical alteration of embrasure according to morphologic alterations due to aging or parafunctional habits.



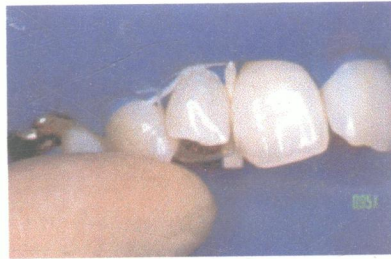
**Figure 17.** Orthodontic and restorative treatment for malformed peg-shaped maxillary right lateral incisor.



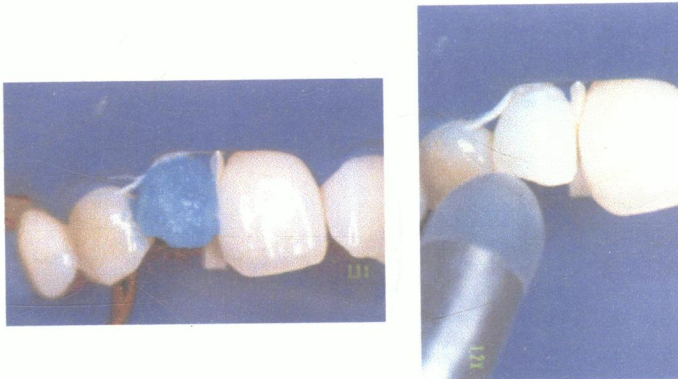
**Figure 18.** Short maligned maxillary right lateral incisor.



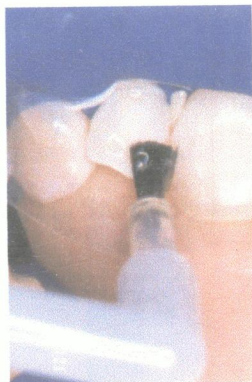
**Figure 19.** Enameloplasty, labial enamel surface.



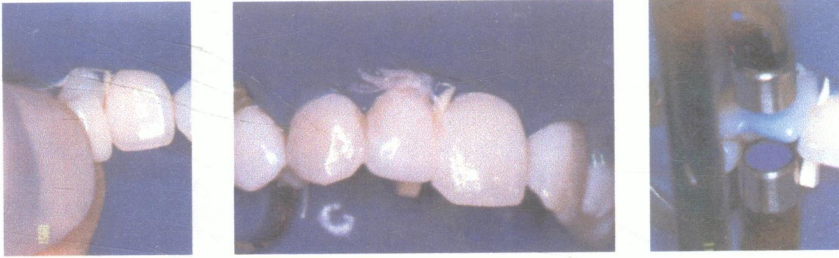**Figure 20.** Fitting of thin crown form matrix.



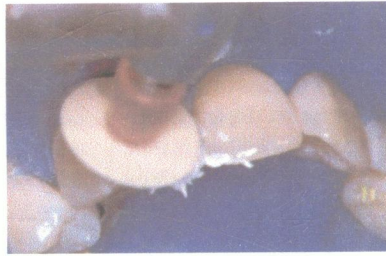
**Figure 21.** Phosphoric acid etching using viscous gel etchant with warm air drying.



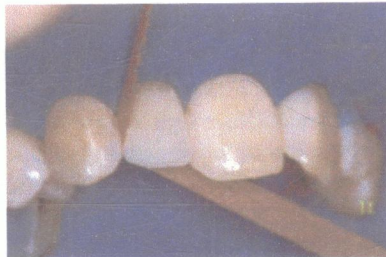**Figure 22.** Application of bond resin.



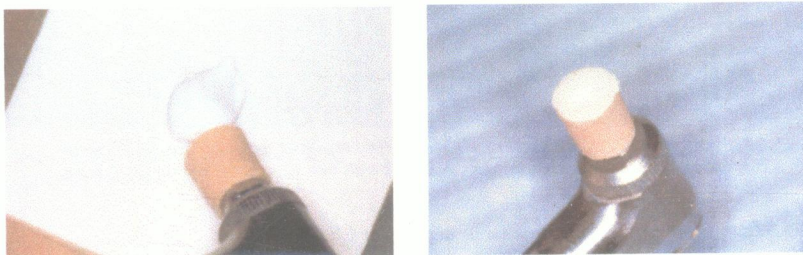
**Figure 23.** Composite placement in crown form matrix, placement of anatomically contoured wooden wedge and visible light cure.



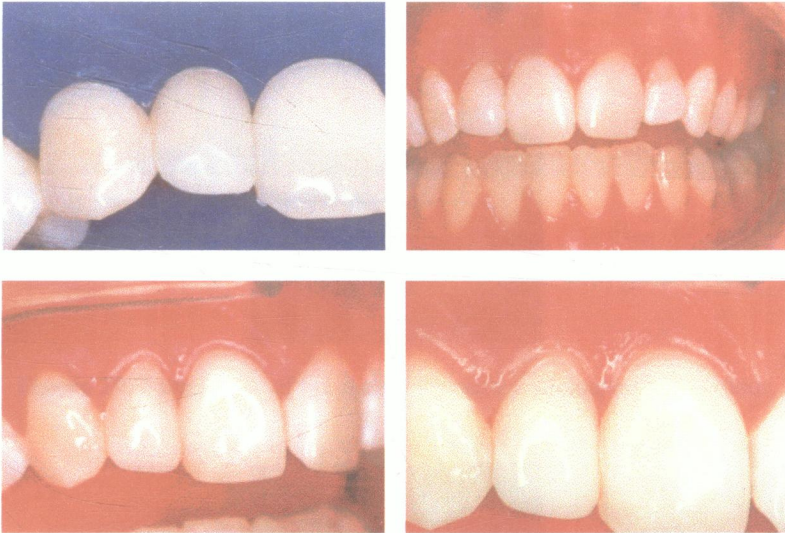
**Figure 24.** Disc finishing of composite



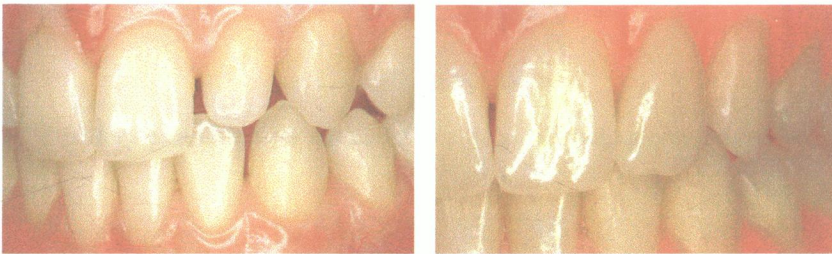**Figure 25.** Use of strip.



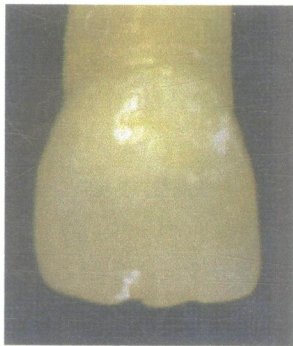**Figure 26.** Foam polishing cup and prisma gloss.



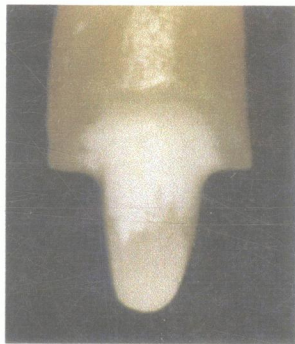
**Figure 27.** Composite surface after prisma gloss application and completed composite crown buildup.



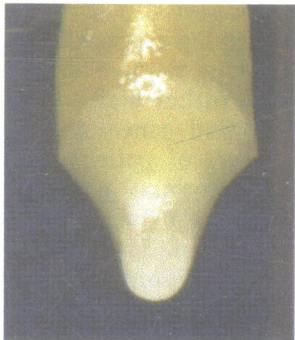
**Figure 28.** Composite buildup for microdont maxillary left lateral incisor.



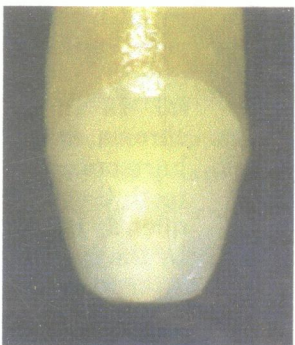
**Figure 29.** Facial view of the maxillary central incisor-natural colour.



**Figure 30.** Maxillary central incisor with accentuated butt shoulder preparation-buccal aspect.

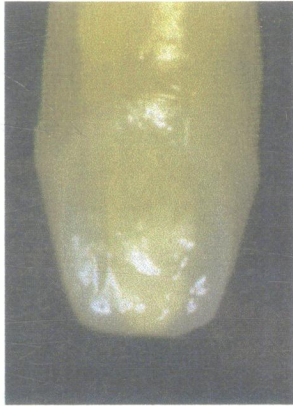

**Figure 31.** Opaque microfill applied onto the cervical third-buccal aspect.

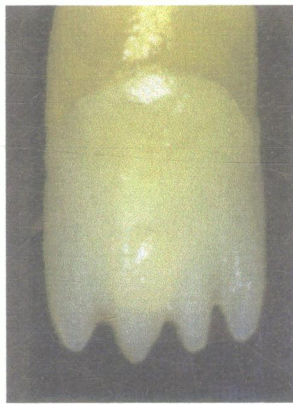


**Figure 32.** Artificial dentin-hybrid composite cure-buccal aspect.

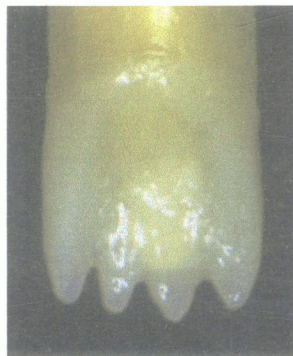




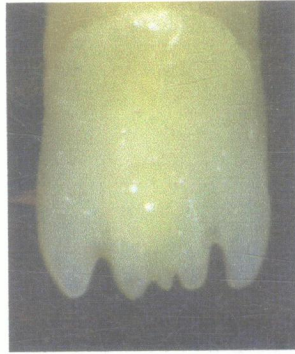**Figure 33.** Artificial enamel-hybrid composite cure-palatal aspect.



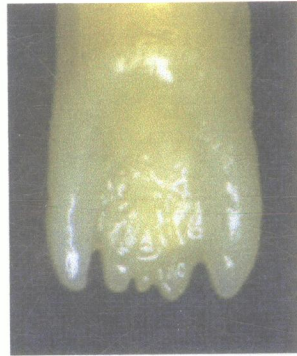**Figure 34.** Artificial dentin-hybrid composite core (initial shape of mamelons)-buccal aspect.



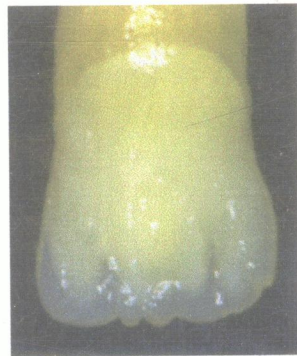
**Figure 35.** Artificial dentin-hybrid composite core (initial shape of mamelons)-palatal aspect.



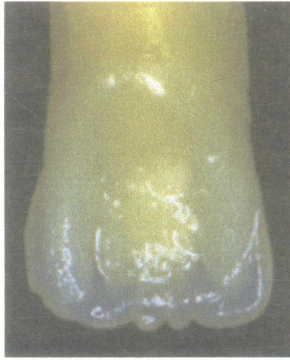**Figure 36.** Artificial dentin-hybrid composite core (final shape of mamelons)-buccal aspect.



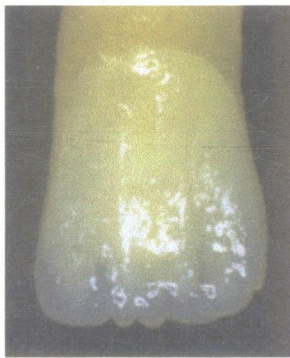**Figure 37.** Artificial dentin-hybrid composite core (final shape of mamelons)-palatal aspect.



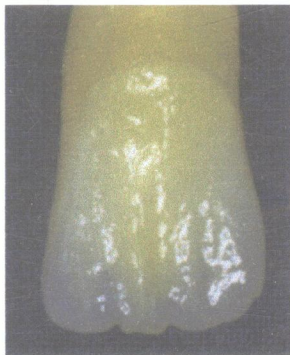
**Figure 38.** Artificial dentin-hybrid composite core (translucent resin)-buccal aspect.



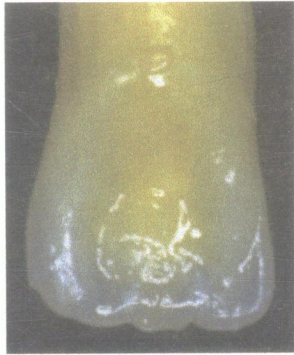**Figure 39.** Artificial dentin-hybrid composite core (translucent incisal resin)-palatal aspect.



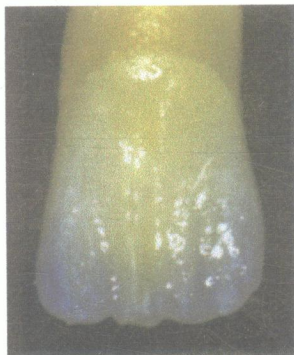
**Figure 40.** Incisal third characterization-blue, gray, or lavender tints applied to accentuate translucency.



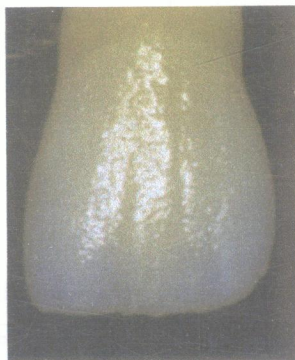
**Figure 41.** Incisal third characterization-tints and opaques applied to achieve maverick colours.



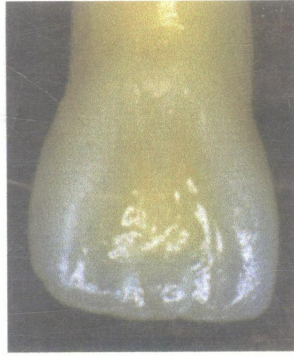**Figure 42.** Incisal third and palatal fossa characterization-tints and opaques applied to achieve maverick colours.



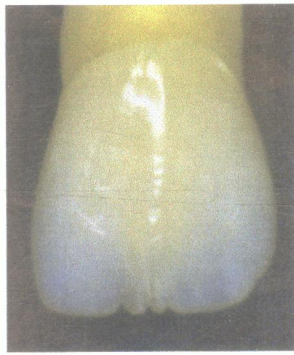
**Figure 43.** Incisal third characterization-tints and opaques applied to achieve maverick colours.



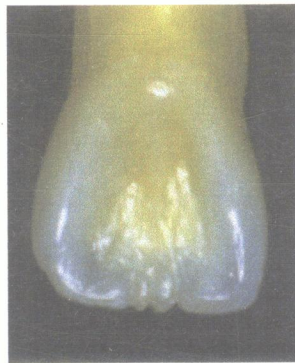
**Figure 44.** Artificial enamel-microfill applied onto the facial aspect.



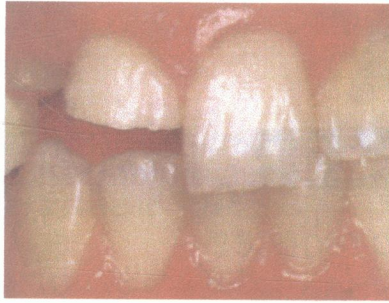**Figure 45.** Artificial enamel-microfill applied onto the palatal aspect.



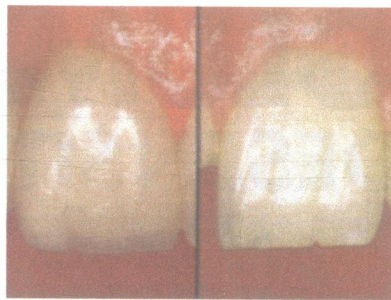
**Figure 46.** Final polished restoration-buccal aspect.



**Figure 47.** Final polished restoration-palatal aspect.



**Figure 48.** Preoperative facial view of fracture maxillary central and lateral incisors, due to a fall while skating.



**Figure 49.** Postoperative close-up of both maxillary central incisors. Compare the life-like appearance of restored tooth #8 (left) when compared with the natural intact tooth #9 (right).

## References:

Ahmad I

Geometric considerations in anterior dental aesthetics: restorative principles.  
Pract Periodont Aesthet Dent 1998; 10: 813-822.

Albers HF

Tooth colored restoratives.  
Cotati: Alto Books, 1985, 7: 31-32.

Albers HF

Esthetics treatment planning.  
Adept Report 1992; 3: 45-52.

Allen EP

Use of mucogingival surgical procedures to enhance esthetics.  
Dent Clin North Am 1988, 32: 307-330.

Andreasen FM, Andreasen JO

Diagnosis of luxation injuries: The importance of standardized clinical, radiographic and photographic techniques in clinical investigations.  
Endod Dent Traumatol 1985; 1: 160-169.

Andreasen FM

Pulpal healing after luxation injuries and root fracture in the permanent dentition.  
Endod Dent Traumatol 1989; 5: 111-131.

Appleby DC, Craig C

Subtleties of contour: a system for recognition and connection.  
Compendium 1986, 7: 109-120.

Baratieri LN, Monteiro SJr, Andrada MAC, Arcari GM

Composite resin veneers: a new technique.  
Quintessence Int 1992; 23: 237-243.

Baratieri LN, Ritter AV, Andrada MAC

Como melhorar o desempenho das restauracoes esteticas diretas? In Feller C, Bottino MA ( coord). Atualizacao na Clinica Odontologica-A Pratiacal da Clinica Geral. Sao Paulo: Artes Medicas, 1994, 33-60.

Baratieri LN, Junior SM, Caldeira de Andrada MA, Vieira LCC, Cardoso AC, Ritter AV

Esthetics- Direct Adhesive Restorations on Fractured Anterior Teeth.  
Chicago, Quintessence Publishing Co; 1998.

Batista JG, Martins S.

Estetica com metalo-ceramica.  
Rev Gaucha Odont 1990; 38: 219-224.

Berry FH

Is the theory of temperament the foundation to the study of prosthetic art?  
Dent Mag 1905; 61: 405.

Block PL

Restorative margins and periodontal health: A new look at an old perspective.  
J Prosthet Dent 1987; 57: 683-689.

Blitz N

Criteria for success in creating beautiful smiles.  
Oral Health 1997; 12: 38-42.

Borissavlievitch M

The golden number.  
London : Alec Tiranti, 1964.

Buonocore M, Davila J

Restoration of fractured teeth with ultraviolet light polymerized bonding materials.  
J Amer Dent Assoc 1973; 86: 1349-1354.

Chiche G

Esthetics of Anterior Fixed Restorations.  
Chicago, Quintessence Publishing Co; 1993.

Chiche G, Pinault A

Esthetics of Anterior Fixed Prosthodontics.  
Chicago, Quintessence Publishing Co., 1994.

Clark EB

Tooth color selection.  
J Am Dent Assoc 1933; 20: 1065-1073.

Counihan D

The Orthodontic Restorative Management of the Peg-lateral.  
Dental Update 2000; 27: 250-256.

Dawson PE

Evaluation Diagnosis and Treatment of Occlusal Problems.  
St. Louis. Mo: C.V.Mosby 1974.

Dawson PE

Determining the determinants of occlusion.  
Int Periodont.Rest.Dent. 1983; 6: 9.

Dietschi D

Free-hand bonding in the esthetic treatment of anterior teeth: creating the illusion.  
J Esthet Dent 1997; 9: 156-164.



- Dietschi D, Schatz JP  
Current restorative modalities for young patients with missing anterior teeth.  
Quintessence Int 1997; 28: 231-240.
- Fahl N  
The direct/indirect composite resin veneer: a case report.  
Pract Periodont Aesthet Dent 1996; 8: 627-638.
- Fahl N, Denehy GE, Jackson RD  
Protocol for predictable restoration of anterior teeth with composite resins.  
Pract Periodont Aesthet Dent 1995; 7: 13-21.
- Feigenbaum NL, Mopper WKA  
A complete guide to bonding.  
East Windsor, NJ: M.E.D. Communications, 1984.
- Frush JP, Fisher RD  
The dynesthetic interpretation of the deontogenic concept.  
J Prosthet Dent 1958; 8: 558.
- Garn SM, Lewis AB, Walenga AJ  
Maximum-confidence value for the human mesiodistal crown dimension of human teeth.  
Arch Oral Biol 1968; 13: 841.
- Geller W  
Dental ceramics and esthetics.  
Chicago, February 15, 1991.
- Goldstein RE  
Study of need for esthetic in dentistry.  
J Prosthet Dent 1969; 21: 589-598.
- Goldstein RE  
Esthetics in Dentistry.  
Philadelphia, Lippincott, 1976.
- Goldstein RE, Lancaster JS  
Survey of patient attitudes toward current esthetic procedures.  
J Prosthet Dent 1984; 52: 775-780.
- Golub J  
Entire smile pivotal to teeth design.  
Clin Dent. 1988, 33.
- Greenberg JR  
Shaping anterior teeth for natural esthetics.  
Esthet Dent update 1992; 3: 86.

Grippo J

Abfractions: A new classification of hard tissue lesions of teeth.  
J Esthet Dent 1991; 3: 9-14.

Hall WR

Shapes and sizes of teeth from American system of dentistry.  
Philadelphia: Lea Bros, 1887: 971.

Heymann HO

The artistry of conservative esthetic dentistry.  
J Am Dent Assoc 1987; Special Issue: 14-E-23E.

Hughes GA

Facial types and tooth arrangement.  
J Prosthet Dent 1951; 1: 82.

Ingervall B, Hedegard B

Awareness of malocclusion and desire of other treatment in 18-year old Swedish males.  
Acta Odont Scand 1974; 32: 93-101.

Jenny J, Proshek JM

Visibility and prestige of occupations and the importance of dental appearance.  
J Can Dent Assoc 1986; 12: 987-989.

Jenny J, Cons NC, Kohout FJ

Relationship between dental esthetics and attributions of self-confidence.  
J Dent Res 1990; 69: 204 (Abst 761).

Jordan R

Esthetic composite bonding- techniques and materials.  
St. Louis, Mosby 1993.

Kessler JC

Maximizing the esthetic potential of ceramo-metal restorations. The American Academy of Crown and Bridge Prosthodontics. Fourtieth Annual Scientific Seminar. Chicago, February 15, 1991.

Kidd EAM, Smith BGN in collaboration with Pickard HM

Pickards Manual of Operative Dentistry, 6 th ed.  
Oxford: Oxford Medical Publications 1992.

Kim HS, Um CM

Color differences between resin composites and shade guides.  
Quintessence Int 1996; 27: 559-567.

Kokich V

Esthetics and anterior tooth position: an orthodontic perspective. Part III: mediolateral relationships  
J Esthet Dent 1993; 5: 200-207.

Leinfelder K, sluder T, santos I, Wall J  
Fiver-year clinical evaluation of anterior and posterior restorations of composite resin.  
Oper Dent 1980; 5: 57-65.

Levin EI  
Dental esthetics and the golden proportion.  
J Prosthet Dent 1978; 40: 244-252.

Levin JB  
Esthetic diagnosis. In Current Opinion in Cosmetic Dentistry. Golub-Evan J,  
Philadelphia, Current Science, 1995: 9-17.

Lewis DH, Eldridge DJ  
Orthodontic/ Restorative Interface  
Dental Update 1992; 6: 195-203.

Lichter JA, Solomowitz BH, Sauco M, Sher M  
What's behind your smile?  
NYSDJ 1999; 12: 35-39.

Lombardi RA  
The principles of visual perception and their clinical application to denture esthetics.  
J Prosthe Dent 1973; 29: 358.

Lombardi RA  
Method for classification of errors in dental esthetics.  
J Prosthe Dent 1974; 32: 501-513.

Mavroskoufis F, Ritchie GM  
Variation in size and form between left- and right maxillary central incisor teeth.  
J Prosthet Dent 1980; 43: 254.

Miller EL, Bodden WR, Jamison HC  
A study of the relationship of the dental midline to the facial median line.  
J Prosthet Dent 1979; 41: 657-660.

Miller WB, Mclendon WJ, Hines FB  
Two treatment approaches for missing or peg-shaped maxillary lateral incisors: A  
case study on identical twins.  
Am J Orthod 1987; 92: 249-256.

Miller A, Long J, Cole J, Staffanou R  
Shade selection and laboratory communication.  
Quintessence Int 1993; 24: 305-309.

Miller M  
The techniques: Class V resin in reality.  
Reality 1995; 6: 313.

Morley J  
The positive side of dentistry: An interview with Dr. Jeff Golub-Evans.  
Dent Today 1994; March: 42.

Muia PJ  
Esthetic harmony.  
In The Four Dimensional Tooth Color System.  
Chicago, Quintessence Publishing Co; 1985: 221-245.

Muia P  
Esthetic Restorations: Improved Dentist Laboratory Communications.  
Chicago: Quintessence, 1993.

Perard V  
Anatomy and Geometry.  
New York: Bonanza Books, Crown 1989.

Philips RW  
Skinner's science of dental material, ed 8.  
Philadelphia, W.B. Saunders Co, 1982.

Pilkington EL  
Esthetics and optical illusions in dentistry.  
J Am Dent Assoc 1936; 23: 641-651.

Porte A, Lutz F, Lund MR, Swartz ML, Cochran MA  
Cavity design for composite resins.  
Oper Dent 1984; 9: 50-56.

Pound E  
Personalized denture procedures.  
In Dentist's Manual. Anaheim: Denar Corp.; 1973: 10.

Qualtrough AJE, Burke FJT  
A look at the dental esthetics.  
Quintessence Int 1994; 25: 7-14.

Reinhardt JW, Capiulonto ML  
Composite resin esthetic dentistry survey in New England.  
J Am Dent Assoc 1990; 120: 541-544.

Richer P  
Artistic Anatomy.  
New York: Watson-Guptill, 1971.

Roulet JF, Lufi A  
Eine verbesserte Methode zur Farbwahl von Kompositen.  
Schweiz Monatsschr Zahnheilk 1992; 92: 447-449.

Roulet JF

Marginal integrity: clinical significance.

J Dent 1994; 22: 9-12.

Roulet JF

In Esthetic and Prosthetics- an interdisciplinary consideration of the state of the art.

ed. Jens Fischer. Chicago, Quintessence Publishing Co, 1999.

Rufenacht CR

Fundamentals of Esthetics.

Chicago, Quintessence Publishing Co., 1990.

Shillingburg HT, Kaplan MJ, Grace CS

Tooth dimensions- a comparative study.

J South Calif Dent Assoc 1972; 40: 830-839.

Shillingburg HT, Hobo S, Whitsett LD, Jacobi R, Brackett SE

Fundamentals of Fixed Prosthodontics.

Chicago, Quintessence Publishing Co, 1997.

Singer B

Principles of Esthetics in Current Opinion in Cosmetic Dentistry, 2<sup>nd</sup> edition.

Philadelphia: current Science, 1994.

Spear F

Facially generated treatment planning: A restorative viewpoint.

American Academy of Esthetic Dentistry, 16<sup>th</sup> Annual Meeting, Santa Barbara, Calif., 1991.

Sproull RC

Color matching in dentistry. Part I: The three-dimensional nature of color.

J Prosthet Dent 1973; 29: 416-423.

Sproull RC

Color matching in dentistry. Part III: Color control.

J Prosthet Dent 1974; 31: 146-154.

Terry DA

Direct composite resin restoration of adolescent class IV tooth fracture: a case report.

Pract Periodont Aesthet Dent 2000; 12: 23-29.

Tjan A, Miller G

Some esthetic factors in a smile.

J Prosthet Dent 1984; 51: 24-28.

Ubassy G

Shape and color-the key to successful ceramic restorations.

Hong Kong: Quintessence, 1993.

Valentine CW

Composite resin restoration in esthetic dentistry  
J Am Dent Assoc 1987; Special Issue: 55E- 61E.

Valo TS

Anterior esthetics and the visual arts: beauty, elements of composition, and their clinical application to dentistry. In Current Opinion in Cosmetic Dentistry. Golub-Evan J, Philadelphia, Current Science, 1995: 24-32.

Vargas MA, Bouschlicher MR

Translucency/opacity of proprietary composite resins.  
J Dent Res 1995; AADR Abstracts (Abstract #1384)

Vig RG, Brundo GC

The kinetics of anterior tooth display.  
J Prosthet Dent 1978; 39: 502-505.

Watson JF, Crispin BJ

Margin placement of esthetic veneer crowns. Part III. Attitudes of patients and dentists.

J Prosthet Dent 1981; 28: 502-507.

Williams JL

A new classification of human tooth forms with a special reference to a new system of artificial teeth.

Dent Cosmos 1914; 56:627.

Willems G

Multi standard criteria for the selection of potential posterior composites.  
Thesis, Leuven 1992.

Winter R

Visualizing the natural dentition.  
J Esthet Dent 1993; 5: 103-117.

Woelfel JB

Dental Anatomy: Its Relevance to Dentistry, ed 4.  
Philadelphia: Lea & Febiger, 1990.

Yamamoto M, Miyoshi Y, Kataoka S

Special discussion-Fundamental esthetics: Contouring techniques for metal ceramic restorations.

Quintessence Dent Tech 1990/1991; 14: 10-81.

Young HA

Selecting the anterior tooth mold.  
J Prosthet Dent 1954; 4: 748.

X15059085

