

## Age-related diffusion patterns in intervertebral disc degeneration

Z. Zhang<sup>1</sup>, Q. Chan<sup>2</sup>, M. P. Anthony<sup>1</sup>, K. M. Cheung<sup>3</sup>, and M. Kim<sup>1</sup>

<sup>1</sup>Department of Diagnostic Radiology, The University of Hong Kong, Hong Kong, China, People's Republic of, <sup>2</sup>Philips Healthcare, Hong Kong, China, People's Republic of, <sup>3</sup>Division of Spine Surgery, Department of Orthopaedics and Traumatology, Faculty of Medicine, The University of Hong Kong, Hong Kong, China, People's Republic of

**Objective:** The intervertebral disc (IVD) is a highly organized matrix that serves as an articulating structure between the vertebral bodies allowing for complex spinal motion [1]. The IVD undergoes structural and morphological changes throughout the various stages of development and aging. These age-related changes can be an important part of degenerative disc disease (DDD), with associated loss of matrix molecules [1]. Matrix accumulation and/or degradation due to aging may alter the biochemical and biomechanical properties of the tissue as well as cellular reparative pathways. Investigating age-related matrix alterations by a sensitive and non-invasive MRI methodology may help improve our understanding of the regulatory mechanisms involved during IVD degeneration. Previous studies have reported various age-related changes in the intervertebral disc, including decreased disc volume [2], dehydration and decreased proteoglycan content [3], which may contribute to the loss of disc integrity and play a role in the pathogenesis of the degenerative process. However, no studies have reported age-associated matrix changes in IVD using diffusion tensor imaging (DTI), to our knowledge, which is known as a sensitive tool to demonstrate microstructural matrix changes. The purpose of this study is to characterize the age-related diffusion patterns of human IVDs using DTI at 3 Tesla (3T) clinical MRI system.

**Materials and Methods:** After informed written consent was obtained, 20 healthy volunteers (10 females, 10 males; mean age = 42.3 years;  $\pm$  standard deviation (SD) = 14.8 years; age range = 25-67 years) with no history of lumbar DDD were recruited. Sagittal images covering IVD levels from L1/L2 to L5/S1 for each subject were acquired using a 3T Achieva scanner (Philips Healthcare, Best, The Netherlands) with body coil transmission, phased-array coil reception and high order shimming. Only non-degenerated discs of the lumbar spine with DDD = 0, graded on T<sub>2</sub>-weighted (T2w) MRI by 2 raters using Schneiderman's classification [4] were selected (65 discs in total). Discs with DDD = 1 or above were excluded for data analysis. Four averaged minimally weighted ( $b_0$ ) and 15 diffusion-weighted volumes ( $b$ -value = 500 s/mm<sup>2</sup>) were acquired using single-shot EPI sequence. DTI imaging parameters were: TR, 3000 ms; TE, 65.11 ms; 12 slices with 5 mm thickness, pixel size, 0.625 x 0.625 mm<sup>2</sup>; total scan time, 6 min. 24 sec. The diffusion tensor was estimated as described in Mori et al. [5] and the fractional anisotropy (FA) and mean diffusivity (MD) were derived using DtiStudio [6]. Geometry-matched T2w images with DTI were acquired with the following parameters: TR, 2500 ms; TE, 90ms; total scan time, 2 min. After co-registration between T2w and DTI images, the outside of the annulus fibrosus (AF) was manually segmented from a midline slice of T2w images for region of interest (ROI) at each disc level using ImageJ (National Institutes of Health, Bethesda, MD). A histogram was obtained for each disc using the ROI described above, normalized against the total number of voxels within an ROI. The value intervals (bins) for FA and MD ranged from 0 to 1 (dimensionless) and 0 to 3 x 10<sup>-3</sup> mm<sup>2</sup>/s, with bin sizes of 0.016 and 0.047 x 10<sup>-3</sup> mm<sup>2</sup>/s, respectively. Histograms of FA and MD were smoothed by 6<sup>th</sup> order polynomial fitting using MATLAB (Mathworks, Natick, MA) and Savitzky-Golay 5 points algorithm using Origin (OriginLab Corporation, Northampton, MA), respectively. To assess the extent to which age-related changes in a given measure are different, the subjects were divided into two age domains, young and elderly adult groups (age range = 25–35 and 47-67 years, respectively). Mean values of histogram-derived measures were compared between two groups by two-tailed unpaired student's t-test using SPSS (SPSS Inc., Chicago, IL).

**Results and discussion:** Fig.1 illustrates average histograms of DTI-derived metrics in IVDs for young and elderly adult groups, showing that the nucleus pulposus (NP) can be distinguished from the AF using FA values, but not MD values. This may indicate that FA is more sensitive to differences in fiber structures: the high FA value measured in the AF correlates with the well-organized fibrous collagen structure of the AF; while the less structured gelatinous core of the NP [1] is reflected by the low FA values. Fig.2. shows quantitative comparisons of mean FA and MD between two groups as follow: 1) the peak location of mean FA in the NP is significantly higher ( $p < 0.001$ ) in elderly adult group while that in the AF remains unchanged between two groups, 2) for the peak height of mean FA both in the NP and the AF, no statistical difference is observed and 3) the peak location and the height of mean MD in the entire disc are significantly lower ( $p < 0.001$ ) in elderly adult group. Our observations described above may represent that different degenerative-related changes taking place in the NP and the AF through aging can be quantitatively accessed by DTI-derived metrics while the morphologic changes are not yet identified in T2w images. Finally, table 1 describes detailed comparisons of average DTI indices between upper (L1/2 and L2/3) and lower (L3/4-L5/S1) IVDs levels. Interestingly, the  $p$ -values at all histogram-derived measures in table 1 show much higher significant difference of young and elderly groups in lower disc levels, which agree with pathologic expectations and histology reports in the literature suggesting that discs in lower level showed more degeneration than discs at other lumbar levels [7].

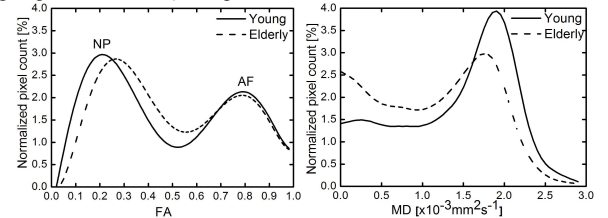


Fig.1. Average histograms of FA and MD from young (continuous line) and elderly adult groups (dashed line).

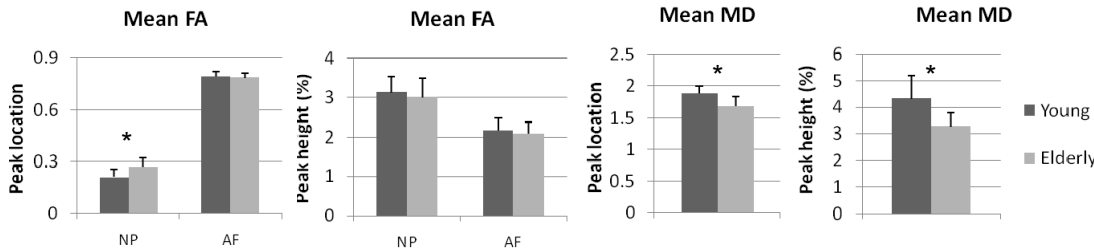


Fig. 2. The peak location and height of mean FA and MD between young and elderly adult groups. Significant difference between groups is indicated by \*  $p < 0.001$ .

**Conclusion:** In the present study, we have demonstrated that age-related degenerative changes can be quantitatively assessed in human lumbar IVDs using DTI. Our results show that DTI-derived metrics are sensitive to microstructural matrix alteration and the histogram-derived measures can detect early disc degeneration due to aging, while no morphological changes are observed in conventional T2w images. Therefore, by adding the quantitative capability of DTI to the existing clinical methods it may be possible to develop a better understanding of the early progression of DDD, and thus to more objectively evaluate the effect of therapeutic intervention.

**References:** [1] Mwale F et al., Eur Spine J, 2008. [2] Anderson DG, Tannoury C, Spine J, 2005. [3] Roughley PJ et al., Spine, 2004. [4] Schneiderman G et al., Spine, 1987. [5] Mori S et al., Ann Neurol, 1999. [6] Jiang, H, et al., Comput Meth Programs Biomed, 2006. [7] Miller JA, et al., Spine, 1988.

Table 1. The histogram-derived measures of mean FA and MD in L1/2 & L2/L3 and L3/4-L5/S1 of young and elderly adult groups. Mean (SD) of each disc group is displayed.

Age group	Mean (L1/2 & L2/3)			Mean (L3/4 - L5/S1)		
	Young	Elderly	<i>p</i>	Young	Elderly	<i>p</i>
Number of discs	18	12		26	9	
Mean FA peak location: NP	0.22 (0.04)	0.26 (0.06)	0.05	0.20 (0.04)	0.28 (0.02)	<0.001
Mean MD peak location ( $\times 10^{-3}$ mm <sup>2</sup> s <sup>-1</sup> )	1.86 (0.11)	1.74 (0.14)	0.01	1.88 (0.10)	1.62 (0.10)	<0.001
Mean MD height (%)	4.23 (0.87)	3.33 (0.67)	<0.01	4.37 (0.89)	3.15 (0.36)	<0.001