

Clinical Examination Of The Breast

K L Cheung,* MBBS(HK), FRCSEd, FACS, FHKAM(Surgery)

Department of Surgery
The University of Hong Kong

Summary

Clinical examination of the breast plays a crucial role in the management of symptomatic breast conditions. Triple assessment, with clinical assessment forming part of the process, is superior to using any one modality alone in the diagnostic work-up of a breast symptom. The techniques of clinical examination are described with reference to the common breast symptoms.

There is little evidence to support the use of either breast self-examination or physical examination by professionals as a screening procedure for the well women. However, the concept of breast awareness should be practised and encouraged. (HK Pract 1999;21:62-70)

摘要

對臨床上有乳房症狀的患者，臨床檢查至為重要，使用包括其在內的三聯診斷方法較單獨採用任何一種方法更為有效。本文詳述臨床常見症狀的檢查技巧。

對沒有乳房症狀的健康婦女，現時尚無證據支持自我檢查或經專業醫護人員檢查是有效的篩選方法。但應鼓勵婦女警惕乳房疾病。

Introduction

The scope of breast service includes the management of symptomatic breast conditions and breast cancer screening. Initial investigation of breast symptoms should be by clinical examination (CE).¹ Clinical assessment, with physical examination forming the pillar, should be the starting point of the triple assessment process for a woman with breast symptoms. Not all women need breast imaging from the radiologist.¹ This article discusses the role of CE of the breast in the management of symptomatic

breast conditions. Description of the techniques of examination forms the core of this article, which should better be read in conjunction with the author's article on common breast conditions.² It is followed by a short review of the current evidence on the usefulness of breast examination in screening for the well women.

Role of clinical examination of the breast

The crucial role of CE of the breast lies in the symptomatic management of breast conditions. A

woman with a breast symptom should first be assessed clinically. Clinical examination generally plays a much more important role than the history in the diagnostic assessment of the symptom. Very often radiological and cytological assessments, the other components in the triple assessment process, are not necessary after a carefully performed examination has excluded any clinical abnormality. For a woman complaining of feeling a lump, she can be reassured and discharged if CE detects no abnormality. On the contrary, CE should aim to identify features that distinguish a malignant

* Address for correspondence : Dr K L Cheung, Department of Surgery, The University of Hong Kong, Queen Mary Hospital, Hong Kong.

UPDATE ARTICLE

from a benign lump.³ Clinical examination can differentiate single-duct from multi-duct nipple discharge which is often physiological or surgically insignificant. A woman with mastalgia can be discharged if CE is normal and the pain does not disturb her quality of life.²

Although the sensitivity of CE of the breast (84% in one series)⁴ is not as high as mammography or fine needle aspiration cytology, CE plays a complementary role in the triple assessment process. Around 10% of cancers are not detected by mammography. The combination use of all assessments is superior to using any one modality alone and leads to a very high diagnostic accuracy.^{5,6}

Many other breast conditions such as gynaecomastia, accessory breasts and nipples, and Mondor's disease are diagnosed by CE only.^{2,7} In a series of Paget's disease of the nipple, half of the patients had normal mammograms and the diagnosis was suspected only on clinical ground.⁸

Techniques of clinical examination of the breast

Clinical examination of the breast is an embarrassing procedure for the woman and can sometimes lead to medicolegal consequences if inappropriately performed. To minimize embarrassment and to avoid misunderstanding, adequate explanation of the procedure and competence in the skills are essential. Privacy should be ensured and the room temperature should be

acceptable. A nurse can both act as a chaperon for a male clinician and give explanation and instruction to the woman prior to CE. Other tips include: not to stay with the woman while she is taking off or putting on her top; to give appropriate cues when necessary e.g. before palpating the 'normal' breast; to complete the procedure efficiently and to avoid chatting on other subjects while carrying out the examination.

There are many ways to perform CE of the breast. The traditional method has been criticized to be time-consuming because of the complicated manoeuvres necessary to inspect for retraction or tethering.⁹ Here the author introduces one acceptable method which, if competently carried out, can be completed within a couple of minutes on average. The techniques are outlined and emphases relating to different symptomatic presentations are described.

Clinical examination of the breast involves adequate exposure. The woman's top should be removed to expose her body above the waist. Inspection and palpation are carried out separately and respectively in a sitting and a semi-recumbent position. With the woman sitting on the side of the examination couch, the clinician faces her squarely, sitting on a chair if available. The objectives are to look for the presence of (a) a lump, (b) inflammation and (c) tethering. The presence of a lump is suspected in any kind of asymmetry and is certainly obvious when an ulcerated or fungating mass is evident. Inflammation manifested as redness,

oedema and/or peau d'Orange can be due to an inflammatory condition such as mastitis or abscess, or an inflammatory breast cancer. The next step is to ask the woman to raise her arms slowly up in the air (**Figure 1**). By doing so, tethering of the skin and/or subtle nipple retraction can be seen. Tethering or retraction can be due to an underlying cancer but can also be the result of inflammation or previous surgery. The lower half of the breast is inspected again for the presence of a lump and inflammation.

The woman is asked to lie comfortably in a semi-recumbent position. There are many acceptable ways in doing palpation e.g. circular or zig-zag fashion. The most important points are (a) to use the palmar aspect of the fingers; and (b) to make sure that the whole breast, including the retroareolar region and the axillary tail, is systematically covered. With the woman's hands placed alongside her body, a general palpation is done for both breasts with an aim of identifying any gross abnormalities which need to be concentrated on at a later stage. The woman is then asked to put her hands behind the head (**Figure 2**). In doing so, the breast, especially the lower part which is ptotic, becomes 'lifted upwards and flatter'. This makes palpation more accurate. Detailed palpation is carried out in this posture. For a woman with large pendulous breasts, the outer part of the breast can be better examined by palpation when she turns slightly in a lateral manner, again to make the part of the breast flatter.

(Continued on page 65)

UPDATE ARTICLE

Figure 1: Inspection of the breasts

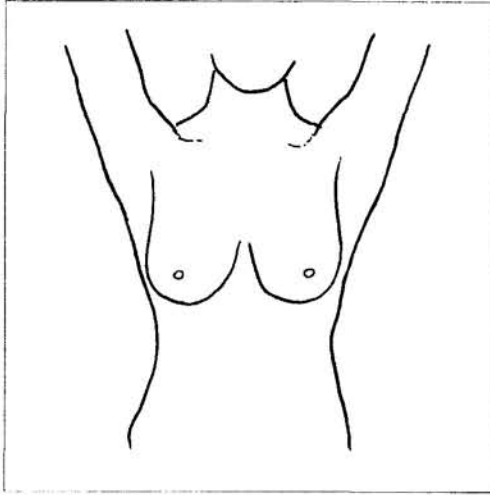
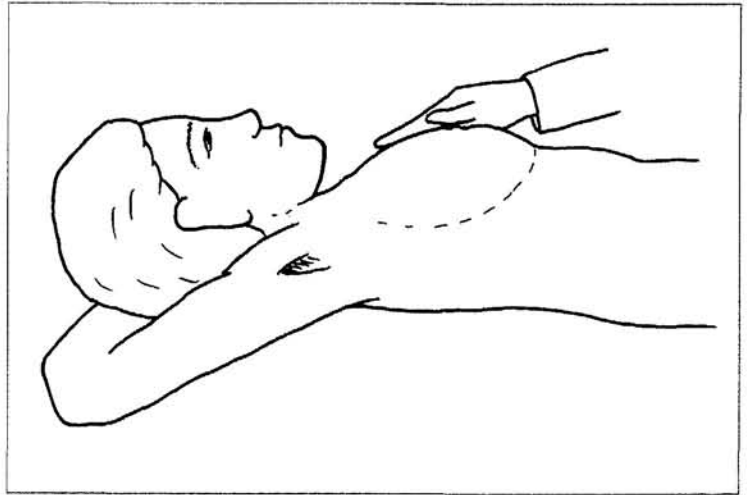


Figure 2: Palpation of the breasts



When a discrete lump is felt, its surface/edge, consistency/fluctuation, size, mobility are defined and documented together with its location on a diagram. Before the clinician concludes that a lump is freely mobile, one should demonstrate that (a) the skin can be picked up freely from the lump; (b) the lump is mobile in the posture described in **Figure 2** (the pectoralis major is relaxed in this posture – fixation implies adherence to the chest wall); and (c) the lump is mobile when the pectoralis major is contracting (by asking the woman to press hard on the waist – the muscle can be felt tensing up in the anterior axillary fold).

Occasions sometimes happen when the clinician cannot find the lump complained of by the woman. Clinical examination has lower sensitivity for small lesions and in young women.⁴ The author would normally ask the woman to point to the alleged lump with one finger. If she can do this swiftly, there is usually a lump which has been

missed in the initial CE. Sometimes the woman might wish to change to a different posture which can better show up the lump. However if she just fiddles around with many fingers, it usually means that a true discrete lump is not present.

After palpation of both breasts, the axillae are palpated in turn for the presence of lymph nodes. The clinician uses the right hand to feel the left axilla and *vice versa* (**Figure 3**), with the exception of the lateral group of lymph nodes along the upper arm where a change of hand is acceptable. While feeling for axillary lymph nodes, the clinician holds the woman's opposite hand to ensure relaxation (**Figure 3**). Whenever a lymph node is felt, its size, consistency and mobility should be delineated. The group or level to which the lymph node belongs is clinically irrelevant. When there is a lump found in the supero-lateral aspect of the breast, sometimes it is difficult to tell whether it is a lump in the axillary tail of the breast or a lymph node in the low axilla. The

trick is to ask the woman to tense the pectoralis major which forms the anterior boundary of the axilla. A lump situated behind the muscle is most likely an axillary lymph node.

For a complete examination when breast cancer is the clinical diagnosis, palpation of both supraclavicular fossae for lymph nodes, the abdomen for hepatomegaly, and percussion/auscultation of the lung bases for pleural effusion are necessary.

Following an outline of the techniques of CE of the breast, important features which should be looked for in different symptomatic presentations are now described.² After examining a woman with a discrete lump, the clinician must arrive at a conclusion as to whether the lump is clinically benign, indeterminate, suspicious or malignant. A clinically benign lump is smooth and mobile. However, most women with cancer first present to a family

(Continued on page 68)

UPDATE ARTICLE

physician and even a breast surgeon with a lump which is small (the mean size in the author's series is 2 cm¹⁰) and mobile. Ulceration, fungating mass with fixation to structures and large axillary lymph nodes are diagnostic signs of breast cancer but are rarely seen. The consistency of a lump cannot reflect its nature since a very tense simple cyst can feel firm and even hard. The size of a lump is also not useful in distinguishing a benign from a malignant lump, though one has to think of the possibility of phyllodes tumour in case of a large but clinically benign lump.² In the author's opinion, the most useful subtle signs for a malignant lump are (a) a lump with an irregular surface/edge; and (b) skin tethering/retraction of nipple.

In a woman with nipple discharge, CE aims, after excluding milky or purulent discharge, at differentiating multi-duct from single-duct discharge which can be due to a duct carcinoma. The author usually would not attempt to elicit discharge when the woman does not have such symptom. In case of a complaint of nipple discharge, the woman is asked to squeeze her nipple to confirm the presence of discharge and its appearance. The nipple is then wiped dry with a piece of gauze. The woman is asked to squeeze the nipple again. Multi-duct discharge is diagnosed if multiple droplets are seen almost at the same time. Single-duct discharge, on the contrary, is seen consistently and persistently as a single droplet from a constant position. The discharge is dried again. The segment of breast tissue close to the areola corresponding to the location of the discharging duct

is then pressed gently. The reproduction of the discharge supports the diagnosis of a lesion such as papilloma or carcinoma in the duct (**Figure 4**). Although there are 15-20 ducts in one nipple, it is convenient to document the location of single-duct discharge in such a way as "discharge from the 3 o'clock duct". Finally, for a woman with mastalgia, after excluding palpable abnormalities, gentle palpation to elicit tenderness is done.

Occasionally a tender spot in the breast can be identified while very often tenderness in the medial (costochondral junctions) and lateral chest wall can be elicited in cases of non-cyclical pain.

Examination of the breast of the well women

Although mammographic screening of women above the age of

Figure 3: Palpation of the axillae

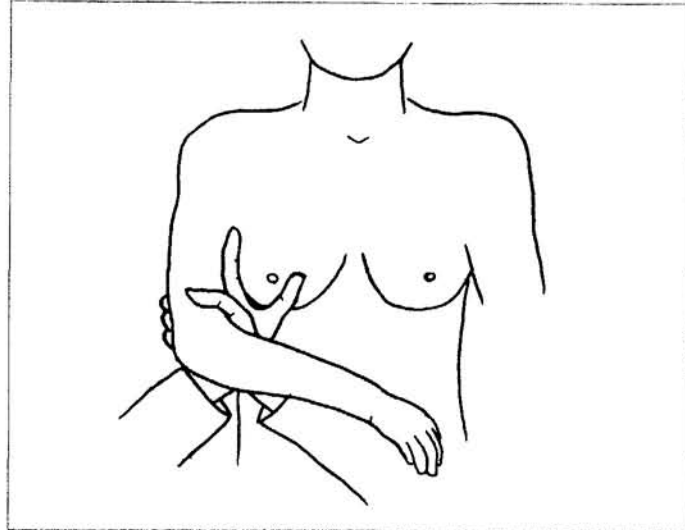
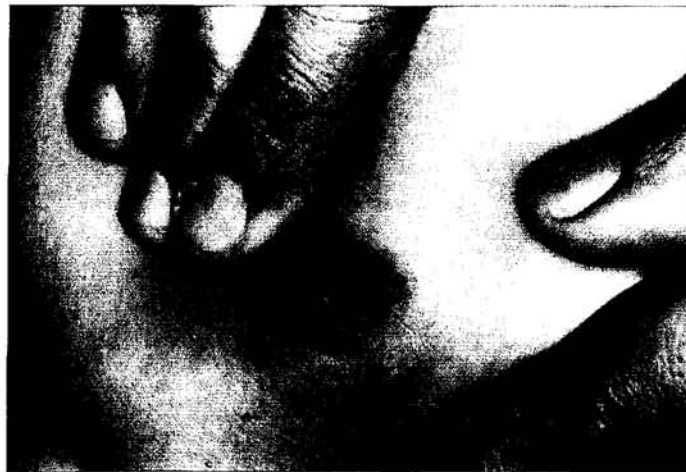

Figure 4: Single-duct nipple discharge



UPDATE ARTICLE

Key messages

1. Clinical assessment, with physical examination forming the pillar, should be the starting point of the triple assessment process for a woman with breast symptoms.
2. Despite having a relatively low sensitivity, clinical examination (CE) of the breast, when combined with radiological and cytological assessments, is superior to using any one modality alone in the diagnostic process of breast symptoms.
3. A number of breast conditions are diagnosed only by CE.
4. Clinical examination involves inspection in a sitting position and palpation in a semi-recumbent position.
5. In the case of a lump in the breast, CE aims at distinguishing a benign from a malignant lump, the subtle signs of which in an early stage being an irregular surface/edge and associated skin tethering/nipple retraction.
6. In the case of non-galactorrhoeic and non-purulent nipple discharge, CE aims at identifying surgically significant discharge which is often unilateral and from a single duct.
7. There is little evidence to give support to the practice of breast examination, either as self-examination or as physical examination by professionals, as a screening procedure for the well women.
8. The concept of breast awareness should be practised and encouraged.

50 has been demonstrated to produce a significant survival benefit,¹¹⁻¹² there is little evidence to support the usefulness in routinely examining the breast, either as self-examination or as physical examination by professionals, as a screening procedure for the well women.¹³⁻¹⁴ Neither a change in the size of breast cancer, nor in the extent of nodal involvement, could be seen in a population study.¹⁵ The efficacy of breast examination of the well women by professionals is questionable, and is liable to give false reassurance. The Government's Advisory Committee on Breast Cancer Screening, United Kingdom has advised that palpation of the breast by either medical or nursing staff should not be included as part

of routine health screening for women.¹⁶

Breast self-examination is the monthly palpation performed by a woman at the same time each month according to a set method. The effectiveness of breast self-examination in reducing mortality from breast cancer has never been consistently demonstrated. In addition it produces a high number of false positives and can induce unnecessary anxiety. Therefore the Advisory Committee also recommended that it should not be promoted as a screening procedure.¹⁶ Instead the idea of breast awareness has been introduced. The Committee noted that over 90% of breast cancers were found by women themselves.

Women should be conscious of what was normal for them, about the feel and look of their breasts throughout the menstrual cycle. They recommended that women, especially those aged over 40 years, should be aware of their breasts in such every day activities as bathing, showering and dressing.¹⁷ They should seek medical advice whenever they notice any change in the breast. The concept of breast awareness should be widely practised and encouraged. ■

References

1. Breast Surgeons Group of the British Association of Surgical Oncology. Guidelines for surgeons in the management of symptomatic breast disease in the United Kingdom. *Eur J Surg Oncol* 1995;21A:1-13.

UPDATE ARTICLE

- Cheung KL. Common breast conditions – when to refer and what will the specialist do? *HK Pract* 1998;20:260-268.
- Steering Committee on Clinical Practice Guidelines for the Care and Treatment of Breast Cancer. The palpable breast lump: information and recommendations to assist decision-making when a breast lump is detected. *CMAJ* 1998; 158(Suppl 3):S3-S8.
- Cardona G, Cataliotti L, Ciatto S, *et al.* Reasons for failure of physical examination in breast cancer detection (analysis of 232 false-negative cases). *Tumori* 1983;69:531-537.
- Winchester DP. Physical examination of the breast. *Cancer* 1992;69(Suppl 7):1947-1949.
- Mok CO, Yang WT, Ying SY, *et al.* Triple evaluation of palpable breast lump in Chinese women [Abstract]. Presented in 8th Overseas Meeting of the Royal College of Surgeons of Edinburgh jointly with the College of Surgeons of Hong Kong 1996.
- Duff P. Mondor disease in pregnancy. *Obstet Gynecol* 1981;58:117-119.
- Ikeda DM, Helvic MA, Frank TS, *et al.* Paget disease of the nipple: radiologic-pathologic correlation. *Radiology* 1993;189:89-94.
- Mahoney L, Csima A. Efficiency of palpation in clinical detection of breast cancer. *Can Med Assoc J* 1982;127:729-730.
- Cheung KL. Improving the quality standards in the management of primary breast cancer. *Asian J Surg* 1998;21:117-123.
- Shapiro S. Evidence on screening for breast cancer from a randomized trial. *Cancer* 1977; 39:2772-2782.
- Department of Health & Social Security. Breast cancer screening (Chairman: Sir Patrick Forrest). London: HMSO, 1986.
- Miller AB. Screening for cancer. *West J Med* 1988;149:718-722.
- Baines CJ, Miller AB, Bassett AA. Physical examination. Its role as a single screening modality in the Canadian National Breast Screening Study. *Cancer* 1989;63:1816-1822.
- Saltzstein SL. Potential limits of physical examination and breast self-examination in detecting small cancers of the breast. An unselected population-based study of 1302 cases. *Cancer* 1984;54:1443-1446.
- Department of Health. Clinical examination of the breast. London: Department of Health, 1998 (Professional Letter: PL/CMO/98/1, PL/CNO/98/1).
- Department of Health. Breast awareness. London: Department of Health, 1991 (Professional Letter: PL/CMO/91/15, PL/CNO/91/12).



DEPARTMENT OF COMMUNITY MEDICINE & GENERAL PRACTICE

together with the

PENANG MEDICAL PRACTITIONERS' SOCIETY

present the

12th ANNUAL POSTGRADUATE MEDICAL REFRESHER COURSE

RASA SAYANG RESORT, PENANG, MALAYSIA

3 - 7 July, 1999

TOPICS:

Allergy, Respiratory Disease,
Dermatology, Neurology,
Pain Management, Health Promotion
in General Practice

SKILLS WORKSHOPS:

Musculoskeletal Medicine (Spinal Mobilisation
Techniques, Joint and Soft Tissue Injection),
Allergy (Sensitivity Testing),
Dermatology (Biopsy & Excision)

For further information and registration forms, please contact:

Mrs Annabel Whitby or Ms Katy Symmons

Department of Community Medicine & General Practice

867 Centre Road, East Bentleigh, Victoria 3165, Australia

Tel: 61 3 9579 3188 Fax: 61 3 9570 1382

Email: annabel.whitby@med.monash.edu.au