

SCOLIOSIS RESEARCH SOCIETY *presents*



19th International Meeting on Advanced Spine Techniques

FINAL PROGRAM

IMAST

July 18-21, 2012
Istanbul, TURKEY
Istanbul Congress Center

IMAST Chair

Christopher I. Shaffrey, MD

IMAST Past-Chair

Todd J. Albert, MD

IMAST Committee

Jacob M. Buchowski, MD, MS

Charles H. Crawford, III, MD

Benny T. Dahl, MD

Mark Dekutoski, MD

Lawrence G. Lenke, MD

Morio Matsumoto, MD

Praveen Mummaneni, MD

Michael F. O'Brien, MD

Glenn Rechtine, II, MD

Justin S. Smith, MD, PhD

Daniel J. Sucato, MD, MD

AAOS
AMERICAN ACADEMY OF ORTHOPAEDIC SURGEONS



Jointly sponsored by
the American Academy of Orthopaedic Surgeons (AAOS)
and the Scoliosis Research Society (SRS)

www.srs.org

2011 CORPORATE SUPPORTERS

We are pleased to acknowledge and thank those companies that provided financial support to SRS in 2011. Support levels are based on total contributions throughout the year and include the Annual Meeting, IMAST, Worldwide Conferences, Global Outreach Scholarships, Edgar Dawson Memorial Scholarships, SRS Traveling Fellowships and the Research Endowment Fund. Their support has helped SRS to offer high quality medical meetings and courses throughout the world, fund spinal deformity research, develop new patient materials, and provide educational opportunities for young surgeons and those from developing nations.

Double Diamond Level Support



Platinum Level Support



Gold Level Support

Globus Medical NuVasive

Silver Level Support

Zimmer Spine

Bronze Level Support

Ackermann Medical GmbH Apatech Ltd, a Baxter Co. Biomet Spine BrainLAB GmbH Ellipse Technologies Elsevier
EOS Imaging Lanx S.R.L. Lippincott, Williams, Wilkins Mazor Robotics Medicea International Misonix
Osseon Therapeutics, Inc. Paradigm Spine Providence Medical Technology Salient Surgical Technologies Spineguard Trans1
Vexim Zimmer Spine

TABLE OF CONTENTS

Welcome	2
General Information	2
Program Outline	5
Meeting Information	6
Istanbul Congress Center Floorplan	7
Conflict of Interest Disclosures	8
Meeting Agenda	
Wednesday, July 18	27
Thursday, July 19	27
Friday, July 20	34
Saturday, July 21	42
Social Events & Optional Tours	48
Paper Abstracts	51
E-Poster Index	113
Exhibits and Hands-On Workshops	
Exhibit Hall Floorplan	185
Exhibitors	186
Hands-On Workshops	190
Author Index	195

FUTURE EDUCATIONAL EVENTS

47th Annual Meeting & Course

September 5-8, 2012 • Chicago, Illinois, USA

20th International Meeting on Advanced Spine Techniques

July 10-13, 2013 • Vancouver, British Columbia, Canada

48th Annual Meeting & Course

September 18-21, 2013 • Lyon, France

21st International Meeting on Advanced Spine Techniques


July 16-19, 2014 • Valencia, Spain

Worldwide Conferences

Tel Aviv, Israel • October 17-19, 2012

Ho Chi Minh City, Vietnam • December 1-2, 2012

In conjunction with Spine Society of Ho Chi Minh City



SCOLIOSIS RESEARCH SOCIETY

555 E. Wells Street, Suite 1100

Milwaukee, WI 53202

Tel: +1-414-289-9107

Fax: +1-414-276-3349

info@srs.org

www.srs.org

WELCOME



Dear Participant,

I want to personally welcome you to Istanbul, one of the cradles of civilization and arguably the most beautiful city in the world, for what promises to be a wonderful academic meeting.

In conjunction with the SRS Board of Directors (BOD) and Presidential Line, we have substantially restructured the program to enhance and broaden international involvement and to focus on evidence-based spine care, complication avoidance, emerging technologies, and surgical technique pearls from recognized international leaders in spinal surgery. We estimate that there will be more than 900 participants from around the world, meeting here at the Istanbul Congress Center (ICC), taking in more than 130 paper presentations, 500+ e-posters, 20 Instructional Course Lectures, and the newest additions to the IMAST program – the Debates and Complications Series, offering opportunity for audience participation and to individually address knowledge gaps.

I am delighted to serve as your IMAST Chairman. I want to thank those whose leadership and diligent efforts have created such a successful meeting, including Drs. B. Stephens Richards, Larry Lenke, Kamal Ibrahim, Steve Glassman and the IMAST Program Committee. I would especially like to thank Dr. Todd Albert for the past three successful IMAST meetings and for his advice and support during the program preparation.

With warmest personal regards,

Christopher I. Shaffrey, MD

CME Information

CME certificates will be available to pre-registered delegates upon the opening of the meeting at www.srs.org/imast/2012/. Delegates who registered on-site may access their certificates after August 4, 2012. **Delegates are REQUIRED to complete evaluations to obtain a CME certificate. These evaluations may be completed during the meeting by pre-registered delegates, using the link provided above.** However, evaluations and certificates are NOT available to delegates registering on-site until August 4.

Delegates should log on to the website listed above and enter their last name and the ID# listed at the top of the IMAST registration confirmation form. The system will then ask delegates to indicate which sessions they attended, to complete evaluation forms for each of those sessions, and then will generate a PDF certificate which may be printed or saved to the delegate's computer. Session attendance and evaluation information are saved in the database, and certificates may be accessed again, in the event the certificate is lost or another copy is required. Please note that certificates will not be mailed or emailed after the meeting. The online certificate program is the only source for this documentation. Please contact SRS at meetings@srs.org for any questions. SRS asks that all CME certificates be claimed no later than November 1, 2012.

NEW! – Debates & Complications Series

During the concurrent sessions of the program, two new session types will be offered. The Debates replaced the former Fundamentals sessions last year, and are intended to present the advantages and disadvantages of various treatment options available for specific conditions. The Complications Series presents a variety of illustrative case presentations, demonstrating the most common complications encountered, as well as strategies to manage them. Interaction between faculty and participants will focus on treatment options with an emphasis on reducing further morbidity and improving eventual outcomes.

More information on the Debates and Complications Series can be found in the Meeting Agenda, beginning on page 27.

E-Posters

There are over 500 E-Posters available for delegates review at the E-Poster computer kiosks just outside the Exhibit Hall. The E-Posters are also available on the CD-ROM included with delegate registration materials, supported, in part, by a grant from K2M.

Exhibits & Hands-On Sessions

Many new spinal systems and products are on display in the Exhibit Hall. We encourage you to visit the exhibits throughout the meeting to learn more about the technological advances.

IMAST is pleased to continue the Hands-On Workshops (HOWs) introduced in 2010. Each one-hour workshop is supported and programmed by a single supporting company and will feature presentations on topics and technologies selected by the Corporate Supporter. Breakfast or cocktails and snacks will be served in the HOWs, as noted in the program on pages 190-191.

Internet Access


Wireless Internet access is available on the B2 level of the Istanbul Congress Center, supported, in part, by a grant from Medtronic. Log on to the "IMAST 2012" network, using the password "spine." Delegates without laptops may access complimentary Internet kiosks adjacent to the Exhibit Hall, supported, in part, by grants from K2M and Medtronic.

Messages

A self-service message board (non-electronic) will be available in the Registration Area, located on Level B0 of the Istanbul Congress Center, for attendees to post notes or leave messages for other attendees, courtesy of K2M. Please remember to check for any messages that may be left for you.



GENERAL INFORMATION



The Scoliosis Research Society gratefully acknowledges K2M, Inc.
for their support of the E-Poster CD-ROM and Internet Kiosks.



PROGRAM OUTLINE

	Wednesday, July 18	Thursday, July 19	Friday, July 20	Saturday, July 21
Morning	8:00 – 12:00 Exhibit Set-Up Board of Directors (BOD) Meeting	7:00 – 16:30 Registration Open Exhibits Open 7:00 – 8:00 *Morning Hands-On Workshops with Breakfast Breakfast & Exhibit Viewing 8:00 – 8:15 Walking Break 9:15 – 9:40 General Session <i>Supported, in part, by a grant from Medtronic.</i> 9:40 – 9:55 Walking Break 9:55 – 10:55 Instructional Course Lectures 1A-D 10:55 – 11:10 Walking Break 11:10 – 12:10 Concurrent Sessions & Debates	7:00 – 16:00 Registration Open Exhibits Open 7:00 – 8:00 *Morning Hands-On Workshops with Breakfast Breakfast & Exhibit Viewing 8:00 – 8:15 Walking Break 8:15 – 9:15 Concurrent Sessions & Debates 9:15 – 9:30 Walking Break 9:30 – 10:30 Instructional Course Lectures 3A-D 10:30 – 10:45 Walking Break 10:45 – 11:45 Concurrent Sessions & Complications Series 11:45 – 12:00 Walking Break	Exhibits Closed 7:00 – 13:50 Registration Open 7:00 – 8:00 Morning Hands-On Workshops with Breakfast 8:00 – 8:15 Walking Break 8:15 – 9:15 Instructional Course Lectures 5A-D 9:15 – 9:30 Walking Break 9:30 – 11:30 Concurrent Sessions & Complications Series 11:30 – 11:45 Walking Break 11:45 – 13:50 General Session <i>Supported, in part, by a grant from Medtronic.</i> 13:50 Adjourn
Afternoon	12:00 – 15:00 Exhibit Set-Up BOD Meeting 14:00 – 19:30 Delegate Registration Open 15:00 – 17:00 NEW! Premium Hands-On Workshops	12:10 – 13:00 Lunch Exhibit Viewing 13:00 – 14:00 Concurrent Sessions & Complication Series 14:00 – 14:15 Walking Break 14:15 – 15:15 Instructional Course Lectures 2A-D 15:15 – 15:30 Walking Break 15:30 – 16:30 *Afternoon Hands-On Workshops w/ Cocktails, Snacks	12:00 – 13:00 Roundtable Case Discussions 13:00 – 13:45 Lunch Membership Information Session Exhibit Viewing 13:45 – 14:45 Instructional Course Lectures 4A-D 14:45 – 15:00 Walking Break 15:00 – 16:00 * Afternoon Hands-On Workshops w/ Cocktails, Snacks	
Evening	17:00 – 19:30 Welcome Reception <i>Supported, in part, by grants from Medtronic and Synthes Spine.</i>	Free Evening	19:00 – 23:00 Course Reception	

*CME credits are not offered for indicated sessions

GENERAL MEETING INFORMATION

Meeting Description

IMAST gathers leading spine surgeons, innovative research, and the most advanced spine technologies for all areas of spine (cervical, thoracic, and lumbar), most spinal conditions (degenerative, trauma, deformity, tumor), and a variety of treatment techniques. The IMAST program will include didactic presentations, panel discussions, papers, and posters on current research, roundtable case discussions and Instructional Course Lectures, all lead by an international and multidisciplinary faculty. IMAST is jointly-sponsored by the American Academy of Orthopaedic Surgeons (AAOS) and Scoliosis Research Society (SRS).

Learning Objectives

Upon completion of IMAST, participants should be able to:

- Assess recent advances in surgical techniques for the treatment of spinal disorders, compare them with traditional treatments and determine if and/or when to use them for optimal patient care.
- Analyze indications and potential complications for various spine fixation systems, including spinal arthroplasty, dynamic stabilization and lateral transpsoas procedures, and apply that analysis to treatment decisions.
- Compare and contrast treatment options for various spinal disorders in order to present the full range of nonoperative and operative interventions to patients to allow informed choices for optimal care and improved outcomes.
- Consider a variety of new objective cost and outcome analyses of operative and nonoperative interventions to better understand the cost effectiveness in both the short and intermediate time periods.

Target Audience

Spine surgeons (orthopaedic and neurological surgeons), residents, fellows, nurses, nurse practitioners, physician assistants, engineers and company personnel.

Disclosure of Conflict of Interest

It is the policy of AAOS and SRS to insure balance, independence, objectivity and scientific rigor in all of their educational activities. In accordance with this policy, AAOS and SRS identify conflicts of interest with instructors, content managers, and other individuals who are in a position to control the content of an activity. Conflicts are resolved by AAOS and SRS to ensure that all scientific research referred to, reported, or used in a CME activity conforms to the generally accepted standards of experimental design, data collection and analysis. Complete faculty disclosures are included in this Final Program beginning on page 8.

Accreditation Statement

This activity has been planned and implemented in accordance with the Essential Areas and Policies of the Accreditation Council for Continuing Medical Education (ACCME) through the joint sponsorship of AAOS and SRS. AAOS is accredited by the ACCME to provide continuing medical education for physicians.

AAOS designates this live activity for a maximum of 15.75 *AMA PRA Category 1 Credit(s)*[™]. Physicians should only claim credit commensurate with the extent of their participation in the activity.

FDA Statement (United States)

Some drugs and medical devices demonstrated during this course have limited FDA labeling and marketing clearance. It is the responsibility of the physician to be aware of drug or device FDA labeling and marketing status.

Insurance/Liabilities and Disclaimer

SRS will not be held liable for personal injuries or for loss or damage to property incurred by participants or guests at IMAST including those participating in tours and social events. Participants and guests are encouraged to take out insurance to cover loss incurred in the event of cancellation, medical expenses or damage to or loss of personal effects when traveling outside of their own countries. SRS cannot be held liable for any hindrance or disruption of IMAST proceedings arising from natural, political, social or economic events or other unforeseen incidents beyond its control. Registration of a participant or guest implies acceptance of this condition.

The materials presented at this Continuing Medical Education activity are made available for educational purposes only. The material is not intended to represent the only, nor necessarily best, methods or procedures appropriate for the medical situations discussed, but rather is intended to present an approach, view, statement, or opinion of the faculty that may be helpful to others who face similar situations. SRS and AAOS disclaim any and all liability for injury or other damages resulting to any individual attending a scientific meeting and for all claims that may arise out of the use of techniques demonstrated therein by such individuals, whether these claims shall be asserted by a physician or any other person.

Language

Presentations and course materials will be provided in English.

No Smoking Policy

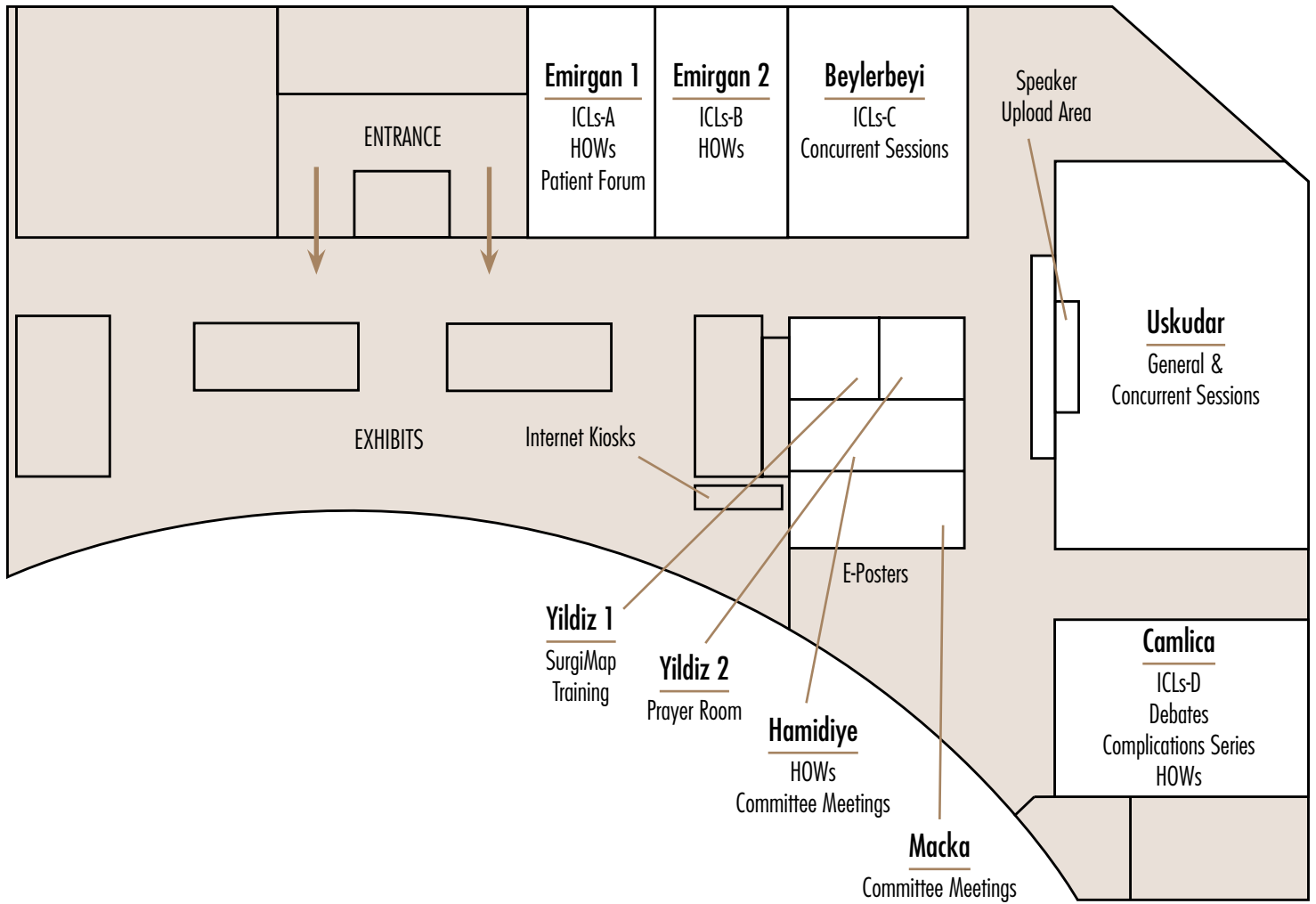
Smoking is not permitted during any IMAST activity or event.

Attire

Business (suits) or business casual (polo or dress shirts, sport coats) are appropriate for IMAST sessions. Cocktail attire is recommended for the Course Reception.

ISTANBUL CONGRESS CENTER FLOORPLANS

B2 Level



CONFLICT OF INTEREST DISCLOSURES**SRS Board of Directors**

B. Stephens Richards, MD	USA	Journal of Pediatric Orthopedics (e); Pfizer (c); Saunders – Elsevier (g)
Kamal Ibrahim, MD, FRCS(C), MA	USA	DePuy Spine (g); K2M (e); Medtronic (g); SpineCraft (b,c,g)
Steven D. Glassman, MD	USA	Medtronic (a,b,e,g); Norton Healthcare (a,f); NuVasive (a)
Lawrence G. Lenke, MD	USA	Axial Biotech (a); DePuy Spine (a); Medtronic (g); Quality Medical Publishing (g)
Kenneth M. Cheung, MBBS(UK), FRCS(England), FHKCOS, FHKAM(Orth)	Hong Kong	Ellipse Technologies (a,b); Synthes Spine (a)
John R. Dimar, II, MD	USA	Medtronic (a,b,g); Norton Healthcare (a,f); NuVasive (a)
Hubert Labelle, MD	Canada	DePuy (a,f); Medtronic (f); Spinologics (c)
David S. Marks, FRCS	United Kingdom	DePuy Spine (g); K2M (d); Medtronic (b)
Richard E. McCarthy	USA	Medtronic (d)
Francisco Javier Sanchez Perez-Grueso, MD	Spain	Depuy (a,b); K2M (a)
Christopher I. Shaffrey, MD	USA	Biomet (b,g); DePuy Spine (b); Medtronic (b,g); NACTN (a); NuVasive (b)
Suken A. Shah, MD	USA	DePuy Spine (a,b,g); Globus Medical (c); Harms Study Group Foundation (a)
Paul D. Sponseller, MD	USA	DePuy Spine (a,b,g); Globus Medical (g); Oakstone Medical Publishers (e)
Daniel J. Sucato, MD, MS	USA	No Relationships
Todd J. Albert, MD	USA	Biomerix (c); Biomet (b); DePuy Spine (b,g); In Vivo (c); K2M (c); Paradigm (c); Pioneer (c); United Healthcare (e); Vertech (c)

IMAST Committee *if not listed above*

Jacob M. Buchowski, MD, MS	USA	CoreLink (b); K2M (d); Globus Medical (d); Stryker Spine (b,d); Support Complex Spine Study Group/ K2M (a)
Charles H. Crawford, MD	USA	Alphatec (b); Medtronic (b); Synthes Spine (d)
Benny Dahl, MD, PhD, DMSci	Denmark	Globus Medical (e); Medtronic (e)
Mark B. Dekutoski, MD	USA	BroadWater Associates (e); Synthes Spine –Education (f); AOSNA (a,e); Mayo Medtronic Perc Trauma (g); Mayo Medtronic Percutaneous Deformity (b,g)
Morio Matsumoto, MD	Japan	No Relationships
Praveen V. Mummaneni, MD	USA	DePuy Spine (b,g); Quality Medical Publishers (g)
Michael F. O'Brien, MD	USA	Axial Biotech (g); DePuy Spine (a,b,g); Medtronic (b,g); Osteotech (b)
Justin S. Smith, MD, PhD	USA	Biomet (b); DePuy Spine (a,b); Globus Medical (g); Medtronic (a,b,e)

CME Committee *if not listed above*

Ronald A. Lehman, MD	USA	No Relationships
Oheneba Boachie-Adjei, MD	USA	DePuy Spine (a,b,g); K2M (a,b,c,d,g) Medtronic (a); Trans1 (b,d)
Glenn Rechtine, II, MD	USA	No Relationships
Frank Schwab, MD	USA	DePuy Spine (a); Medtronic (a,b,g); Nemarix (c)
Richard H. Gross, MD	USA	No Relationships
Lori Ann Karol, MD	USA	No Relationships
Yongjung J. Kim, MD	USA	No Relationships

*If noted, the relationships disclosed are as follows: (a) Grants/Research Support (b) Consultant (c) Stock/Shareholder (self-managed)
(d) Speaker's Bureau (e) Advisory Board or Panel (f) Salary, Contractual Services
(g) Other Financial or Material Support (royalties, patents, etc.)*

CONFLICT OF INTEREST DISCLOSURES

Program Committee *if not listed above*

Laurel C. Blakemore, MD	USA	K2M (a,d,e); Stryker Spine (d)
Yutaka Sasao, MD, PhD	Japan	Medtronic (b)
R. Haluk Berk, MD	Turkey	No Relationships
William F. Donaldson, III, MD	USA	Stryker Spine (a)
Daniel W. Green, MS, MD, FACS	USA	No Relationships
Timothy S. Oswald, MD	USA	Medtronic (b); Stryker Spine (d)
Stanley S. Lee, MD	USA	Biomet (b, d); Stryker Spine (b,d)
John G. Thometz, MD	USA	No Relationships
James O. Sanders, MD	USA	No Relationships

Program Reviewers *if not listed above*

S. Elizabeth Ames, MD	USA	Stryker Spine (a)
Paul A. Glazer, MD	USA	No Relationships
James T. Guille, MD	USA	No Relationships
Lawrence L. Haber, MD	USA	DePuy Spine (a,b); NuVasive (b)
Judson W. Karlen, MD	USA	No Relationships
D. Raymond Knapp, Jr., MD	USA	No Relationships
Stephen J. Lewis, MD, MSc, FRCSC	Canada	Medtronic (b); Stryker (b)
Kamran Majid, MD	USA	No Relationships
Michelle Marks, PT, MA	USA	DePuy Spine (a)
Hani Mhaidli, MD, PhD	Spain	K2M (a)
Sean Molloy, MBBS, MSc, FRCS	United Kingdom	Medtronic (a,g)
Mohammad M. Mossaad, Prof	Egypt	No Relationships
Kenneth J. Paonessa, MD	USA	K2M (a)
Michael S. Roh, MD	USA	No Relationships
John Tis, MD	USA	No Relationships
Hee-Kit Wong	Singapore	No Relationships
Muharrem Yazici, MD	Turkey	DePuy Spine (b); K2M (b)

Invited Faculty *if not listed above*

Emre Acaroglu, MD	Turkey	DePuy Spine Spine (a); Medtronic (b)
Behrooz A. Akbarnia, MD	USA	DePuy Spine (a,b); Ellipse Technology (b); K2M (a,b); Kspine (b); NuVasive (a,b,c)
Ahmet Alanay, MD	Turkey	Johnson and Johnson (a,b); Medtronic (b)
Christopher P. Ames, MD	USA	Aesculap (g); DePuy Spine (a); Lanx (g); Medtronic (b); Stryker Spine (b,g)
Neel Anand, MD	USA	Co Align(b); Globus Medical (c,e,g); Medtronic (b,e,g); NuVasive (g); Trans1 (b,c,e)
D. Greg Anderson, MD	USA	DePuy Spine (b,g); Globus Medical (b); Medtronic (b,g); Synthes Spine (b)
Sigurd H. Berven, MD	USA	Acculif (c); AOA (a); AO Spine (a); Baxano (c); Biomet (d); DePuy Spine (d); Globus Medical (d); Loma Vista Medical (c); Medtronic (d,g); OREF (a); Providence Medical (c); Simpirica (c); Stryker Spine (d)
J. Abbott Byrd, III, MD	USA	Biomet (b,g); CoAlign (b,c)
Michael G. Fehlings, MD, PhD, FRCSC, FACS	USA	DePuy Spine (b,g)
Ziya L. Gokaslan, MD	USA	DePuy (a); JNS Spine (e); K2M (a); Medtronic (a); Spinal Kinetics (c); US Spine (c,e)

If noted, the relationships disclosed are as follows: (a) Grants/Research Support (b) Consultant (c) Stock/Shareholder (self-managed) (d) Speaker's Bureau (e) Advisory Board or Panel (f) Salary, Contractual Services (g) Other Financial or Material Support (royalties, patents, etc.)

CONFLICT OF INTEREST DISCLOSURES

Henry F.H. Halm, MD	Germany	DePuy Spine (a,b,g); NuVasive (b)
Azmi Hamzaoglu, MD	Turkey	Medtronic (b)
Ian J. Harding, BA, BM, BCh, FRCS(Orth)	United Kingdom	No Relationships
Tyler Koski, MD	USA	DePuy Spine (f); Globus (b); Medtronic (b); NuVasive (b); Stryker Spine (f)
Brian K. Kwon, MD, PhD, FRCSC	Canada	Medtronic (b)
Jean-Charles Le Huec, MD, PhD	France	No Relationships
Peter O. Newton, MD	USA	Biospace Med (a); DePuy Spine (a,b,g); NuVasive (c)
Hilali Noordeen, FRCS	United Kingdom	Ellipse Technologies (b); K2M (a,b,e)
F. Chumhur Oner, MD	Netherlands	No Relationships
Frank Phillips, MD	USA	Axiomed (c); Baxano (c); BioAssets (c); Cross Trees (c); DePuy Spine (b,g); Facet Solutions (c); Flexuspine (c); Kyphon (b); Nuvasive (b,c,g); SI Bone (c); Spinal Kinetics (c); Spinal Motion (c); Stryker (b)
David W. Polly, MD	USA	No Relationships
Yong Qiu	China	No Relationships
K. Daniel Riew, MD	USA	Amedica (c); Benvenue Medical (c); Biomet (g); Expanding Orthopedics (c); KASS (e); Medtronic (g); Nexgen Spine (c); Osprey (c,g); Paradigm (c); PSD (c); Spinal Kinetics (c); Spineology (c); Vertiflex (c)
Vincent C. Traynelis, MD	USA	Globus Medical (a); Medtronic (a,b,g)
Mark Weidenbaum	USA	No Relationships
Michael J. Yaszemski, MD, PhD	USA	No Relationships
Paper Authors <i>if not listed above</i>		
Kariman Abelin-Genevois, MD	France	No Relationships
Franck Accadbled, MD, PhD	France	No Relationships
AlaaEldin A. Ahmad, MD	Occupied Palestinian Territory	No Relationships
Michael Aiona, MD	USA	No Relationships
Tsutomu Akazawa, MD	Japan	No Relationships
Aytac Akbasak, MD	Turkey	No Relationships
Ibrahim Akel, MD	Turkey	No Relationships
Usman Akhtar, BA	USA	No Relationships
Todd F. Alamin, MD	USA	Medtronic(g); Simpircica Spine(c); Synthes Spine (b)
Michael C. Albert, MD	USA	No Relationships
Rodrigo A. Amaral	Brazil	NuVasive (b)
Terry D. Amaral, MD	USA	DePuy Spine (a); K2M (a); Stryker Spine (a)
Thomas Andersen, MD, PhD	Denmark	No Relationships
Paul A. Anderson, MD	USA	Aesculap (b); Expanding Ortho (b,c); Medtronic (b); Pioneer (b,c,g); SI Bone (b,c); Stryker Spine (g); Titan (b,c)
Tate M. Andres, BS	USA	No Relationships
Prokopis Annis, MD	USA	No Relationships
Luis Miguel Antón-Rodrigálvarez, PhD	Spain	No Relationships
Efe L. Aras	Denmark	No Relationships
Robert T. Arrigo, BS	USA	No Relationships

If noted, the relationships disclosed are as follows: (a) Grants/Research Support (b) Consultant (c) Stock/Shareholder (self-managed) (d) Speaker's Bureau (e) Advisory Board or Panel (f) Salary, Contractual Services (g) Other Financial or Material Support (royalties, patents, etc.)

CONFLICT OF INTEREST DISCLOSURES

Jahangir Asghar, MD	USA	DePuy Spine (b)
Alfred Atanda, MD	USA	No Relationships
Pergin Atilla, MD PhD	Turkey	No Relationships
Carl-Éric Aubin, PhD, PEng	Canada	BostonBrace (a); Lagarrigue (a); Medtronic (a,b,e); Natural Sciences and Engineering Research Council of Canada (a)
Kavita Baghel, MSc	India	No Relationships
Juan Bago, MD	Spain	DePuy Spine (a)
Navpreet Bains, BS	USA	No Relationships
Mehmet B. Balioglu, MD	Turkey	No Relationships
Eli Baron, MD	USA	No Relationships
Carlos Barrios, MD, PhD	Spain	No Relationships
Lambertus W. Bartels	Netherlands	No Relationships
Carrie E. Bartley, MA	USA	No Relationships
Tracey Bastrom, MA	USA	No Relationships
Saumyajit Basu, MD	India	No Relationships
John M. Beiner, MD	USA	No Relationships
Senol Bekmez	Turkey	No Relationships
John A. Bendo, MD	USA	No Relationships
Fiona Berryman	United Kingdom	No Relationships
Ernesto Bersusky, MD	Argentina	No Relationships
Shay Bess, MD	USA	Allosource (e); DePuy Spine (a,b,d); Medtronic (b); Pioneer Spine (g)
Randal R. Betz, MD	USA	CWSDSG (e); DePuy Spine (a,b,d,g); Medtronic (b,g); Orthobond (b); Orthocon (b); SpineGuard (b); Synthes Spine (a,b,g); Thieme (g)
Vidya Bhalodia	USA	No Relationships
Upendra Bidre, MS	India	No Relationships
Amitava Biswas, MS(Orth)	India	No Relationships
Benjamin Blondel, MD	USA	No Relationships
Justin Boey	Singapore	No Relationships
Ben Boreham, MB, BCh, FRCS(Orth)	United Kingdom	No Relationships
Sarah Bouchard	Canada	No Relationships
Étienne Bourassa-Moreau	Canada	No Relationships
J. Richard Bowen, MD	USA	No Relationships
Michael Boyd	Canada	No Relationships
Kelly R. Bratcher, RN, CCRP	USA	No Relationships
Paul Brewer, BSc, MB, ChB	United Kingdom	No Relationships
Keith H. Bridwell, MD	USA	DePuy Spine (b); NIH (a)
Jerome Briot, PhD	France	No Relationships
Michael R. Briseno, MD	USA	No Relationships
Darrel S. Brodke, MD	USA	Amedica (c,g); DePuy Spine (g); Medtronic (g); Pioneer (c); Vertiflex (c)
David B. Bumpass, MD	USA	No Relationships

If noted, the relationships disclosed are as follows: (a) Grants/Research Support (b) Consultant (c) Stock/Shareholder (self-managed) (d) Speaker's Bureau (e) Advisory Board or Panel (f) Salary, Contractual Services (g) Other Financial or Material Support (royalties, patents, etc.)

CONFLICT OF INTEREST DISCLOSURES

Cody E. Bunger	Denmark	No Relationships
Evalina L. Burger, MD	USA	No Relationships
Lauren O. Burke, MPH	USA	No Relationships
Douglas C. Burton, MD	USA	Axial BioTech (b); DePuy Spine (a,b,g)
Enric Caceres, Prof	Spain	No Relationships
Patrick J. Cahill, MD	USA	DePuy Spine (a,b); Synthes Spine (d)
Christopher M. Cain, MD	USA	Synthes Spine (b,g)
Chelsea E. Canan, MPH	USA	No Relationships
Eugene Carragee, MD	USA	Acension Health Ventures (b); Cytonics (a); Intrinsic Orthopaedics (e); Kaiser-NIH (a); NuVasive (a); Radiology-NIH (a); Simpirica (c)
Leah Y. Carreon, MD, MSc	USA	Medtronic (a); Norton Healthcare (a,f); NuVasive (a)
Alexandra Carrer, MD	USA	No Relationships
Rene M. Castelein, MD, PhD	Netherlands	No Relationships
Carlos a. Castro	USA	No Relationships
Thomas D. Cha, MD, MBA	USA	No Relationships
Chris Yin Wei Chan, MS(Orth)	Malaysia	No Relationships
Abhijit Chandra, MD	India	No Relationships
Edward Chay	USA	No Relationships
Ivan Cheng, MD	USA	Medtronic (a); NuVasive (e); Stryker Spine (b); Synthes Spine (d)
Jason Pui Yin Cheung, MBBS (HK)	Hong Kong	No Relationships
Wai Yuen Cheung, MD	China	No Relationships
Kazuhiro Chiba, MD, PhD	Japan	No Relationships
Woojin Cho, MD, PhD	USA	No Relationships
Seung Myung Choi, MD	Republic of Korea	No Relationships
Hyon Su Chong	Republic of Korea	No Relationships
Dean Chou, MD	USA	Stryker Spine (b)
Jae Yoon Chung	Republic of Korea	No Relationships
Krishna Cidambi, MD	USA	No Relationships
Marc Cloutier	Canada	No Relationships
Jeffrey D. Coe, MD	USA	Benvenue Medical (a); Implantium (c); Medtronic (a); NuTech (a); NuVasive (a,b); Phygen (c); SI Bone (b); Synthes Spine (b); Trans1 (b)
Amanda B. Coffman, PA-C, MCHS	USA	No Relationships
Patrick J. Connolly, MD	USA	Apatech (e); K2M (e)
Etevaldo Coutinho	Brazil	No Relationships
Thiago Coutinho	Brazil	No Relationships
Quanqi Cui, MD	USA	No Relationships
Matthew E. Cunningham, MD, PhD	USA	No Relationships
Bradford L. Currier, MD	USA	AOSNA (a); DePuy Spine (g); Stryker Spine (g); Zimmer Spine (b)
Charles R. d'Amato, MD, FRCSC	USA	No Relationships
Jacques D'Astous, MD	USA	No Relationships

If noted, the relationships disclosed are as follows: (a) Grants/Research Support (b) Consultant (c) Stock/Shareholder (self-managed)
(d) Speaker's Bureau (e) Advisory Board or Panel (f) Salary, Contractual Services
(g) Other Financial or Material Support (royalties, patents, etc.)

CONFLICT OF INTEREST DISCLOSURES

Scott D. Daffner, MD	USA	Amgen (c); Pfizer (c); Synthes Spine (g)
Fei Dai	China	No Relationships
Andrew T. Dailey, MD	USA	Biomet (b); Stryker Spine (a)
Jonathan R. Dattilo, BS	USA	No Relationships
Michael D. Daubs, MD	USA	Stryker Spine (a); Synthes Spine (b,g)
Adriana De La Rocha, MS	USA	No Relationships
Nicolas Dea, MD, FRCSC	Canada	No Relationships
Thomas C. Dean, MD	USA	No Relationships
Donald A. Deinlein, MD	USA	K2M (a,b)
Jason Demakakos	USA	No Relationships
H Gokhan Demirkiran, MD	Turkey	No Relationships
Armen R. Deukmedjian, MD	USA	No Relationships
Vedat Deviren, MD	USA	NuVasive (b,g); Stryker Spine (b)
Christopher DeWald, MD	USA	No Relationships
Beverly E. Diamond, PhD	USA	No Relationships
Stephen Dierdorf, MD	USA	No Relationships
Christian P. DiPaola, MD	USA	Allen Medical (b); DePuy Spine (b); Medtronic (a)
Mladen Djurasovic, MD	USA	Medtronic (b)
Patrick K. Do	USA	No Relationships
Josh Doan, MEng	USA	No Relationships
Montse Domingo-Sabat	Spain	DePuy Spine (a)
Aaron R. Ducoffe, BS	USA	No Relationships
Marcel F. Dvorak, MD, FRCSC	Canada	DePuy Spine (a,d); Medtronic (a,b,d,e,g); NuVasive (a); Synthes Spine (a,d)
Jason C. Eck, DO, MS	USA	DePuy Spine (a,b); Medtronic (a,d)
Mostafa H. El Dafrawy, MD	USA	No Relationships
Rami El Rachkidi	France	No Relationships
John B. Emans, MD	USA	Medtronic (b); Synthes Spine (b,g)
Sanford E. Emery, MD, MBA	USA	No Relationships
Meric Enercan	Turkey	No Relationships
David Essig, MD	USA	No Relationships
Michael Faloon, MD	USA	No Relationships
Yung K. Fan	USA	No Relationships
Jean-Pierre C. Farcy, MD	USA	No Relationships
Christine L. Farnsworth, MS	USA	No Relationships
Jing Feng, PhD	USA	No Relationships
Tito Fernandez	Spain	No Relationships
Charles G. Fisher, MD, MHSc, FRCSC	Canada	DePuy Spine (a); Medtronic (a,b,g); NuVasive (b)
Neil Fleming, PhD	USA	No Relationships
Jesús J Burgos Flores, PhD	Spain	No Relationships
John M. Flynn, MD	USA	Biomet (g); Orthopedics Today (e); Wolters-Kluwer Health - Lippincott Williams & Wilkins (g)

If noted, the relationships disclosed are as follows: (a) Grants/Research Support (b) Consultant (c) Stock/Shareholder (self-managed)
(d) Speaker's Bureau (e) Advisory Board or Panel (f) Salary, Contractual Services
(g) Other Financial or Material Support (royalties, patents, etc.)

CONFLICT OF INTEREST DISCLOSURES

Jeremy L. Fogelson, MD	USA	No Relationships
Geneviève Foley	Canada	No Relationships
John C. France, MD	USA	No Relationships
Alejandra Francheri, MD	Argentina	No Relationships
Sara K. Fuhrhop, BS	USA	No Relationships
Peter G. Gabos, MD	USA	No Relationships
Robert W. Gaines, MD	USA	No Relationships
Vishal Gala, MD, MPH	USA	No Relationships
Eduardo Galaretto, MD	Argentina	No Relationships
Adrian Gardner, BM, MRCS, FRCS (T&O)	United Kingdom	Medtronic (a,e)
Bhavuk Garg	India	No Relationships
Sumeet Garg, MD	USA	No Relationships
Matthew J. Geck, MD	USA	DePuy Spine (d); Difusion (c); Globus Medical (b,e); Medtronic (d); Zimmer (g)
Edward J. Gerber, PA-C	USA	No Relationships
Jay D. Ghosh, MBBS, MS(Orth)	India	No Relationships
Diana A. Glaser, PhD	USA	AlphaTec (a,c); Biospace (a); DePuy Spine (a); K2M (a); KCI (a); MAKO (c); Naval Medical Center, San Diego (a); NuVasive (c)
Jeffrey A. Goldstein, MD	USA	Johnson and Johnson (c); K2M (c); Medtronic (b); NuVasive (b); Synthes Spine (b)
S. Raymond Golish, MD, PhD	USA	Cytonics (f)
Judith L. Gorelick, MD	USA	No Relationships
Ankur Goswami, MS(Orth)	India	No Relationships
Maureen Grady, RN	USA	No Relationships
Samuel Grozman, MD	Philippines	No Relationships
Munish C. Gupta, MD	USA	DePuy Spine (b,e,d); Lanx (b); Medtronic (a); Osteotech (b,d)
Yoon Ha, MD, PhD	Republic of Korea	No Relationships
Tim Hammett, MRCS	United Kingdom	No Relationships
Ebbe S. Hansen, MD, DMSc	Denmark	No Relationships
Elliot Harmon	USA	No Relationships
Anna Harris	United Kingdom	No Relationships
James S. Harrop, MD	USA	Axiomed (c); DePuy Spine (b); Ethicon (b); Geron (e); Neurostem (e)
Robert A. Hart, MD	USA	DePuy Spine (a,b,d,g); Medtronic (a,b); SeaSpine (g); Synthes Spine (a)
Hiroshi Hashizume, MD, PhD	Japan	No Relationships
Hamid Hassanzadeh, MD	USA	No Relationships
Ilkka Helenius, MD, PhD	Finland	Baxter (a); Medtronic (a); Synthes Spine (a)
Michael W. Hennessy, MD	USA	No Relationships
Stuart Hershman, MD	USA	No Relationships
Eduardo Hevia, MD	Spain	No Relationships
Alan S. Hilibrand, MD	USA	Aesculap (g); Amedica (c); Amedics (g); Alphatec Spine (g) Benvenue Medical (c); Biomet (g); Knee Creations (c); Lifespine (c); Paradigm Spine (c); Pioneer (c); PSD (c); Spinal Ventures (c); Stryker Spine (g); Syndicom (c); Vertiflex (c); Zimmer (g)

If noted, the relationships disclosed are as follows: (a) Grants/Research Support (b) Consultant (c) Stock/Shareholder (self-managed) (d) Speaker's Bureau (e) Advisory Board or Panel (f) Salary, Contractual Services (g) Other Financial or Material Support (royalties, patents, etc.)

CONFLICT OF INTEREST DISCLOSURES

Sarah Hipps, MD	USA	No Relationships
Toru Hirano	Japan	No Relationships
Jayme R. Hiratzka, MD	USA	No Relationships
Christian Hoelscher, BS	USA	No Relationships
Justin B. Hohl, MD	USA	No Relationships
Laurens Holmes, PhD,DrPH	USA	No Relationships
Jonathan J. Horn	USA	No Relationships
Naobumi Hosogane, MD	Japan	No Relationships
Richard Hostin, MD	USA	DePuy Spine (a)
Michael T. Hresko, MD	USA	Medtronic (a); NuVasive (a)
Serena S. Hu, MD	USA	DePuy Spine (a); Medtronic (b); NuVasive (b); Synthes Spine (d)
Xiaobang Hu, PhD	USA	Mazor Robotics (g)
Paul M. Huddleston, MD	USA	No Relationships
Hua Hui, MD	China	No Relationships
Paisal Hussin, MS(Orth)	Malaysia	No Relationships
Shiro Imagama, MD	Japan	No Relationships
Ken Ishii, MD, PhD	Japan	No Relationships
Yoshimoto Ishikawa	Japan	No Relationships
Yuyu Ishimoto	Japan	No Relationships
Agnes Ith	USA	No Relationships
Keigo Ito	Japan	No Relationships
Manabu Ito, MD, PhD	Japan	Hoya Corporation (a); Pfizer (a); Robert Reid (a); Synthes Spine (a)
Hiroshi Iwasaki, MD	Japan	No Relationships
Amit Jain	USA	No Relationships
Tuomas Jalanko, MD	Finland	No Relationships
Michiel Janssen, PhD	Netherlands	No Relationships
Peter Jarzem, MD	Canada	Medtronic (e); Porosteon (e)
Arvind Jayaswal, MS(Orth)	India	No Relationships
Robin D. Jenson, MD	USA	No Relationships
Charles E. Johnston, MD	USA	Medtronic (a,g); Saunders/Mosby Elsevier (g)
Sean M. Jones-Quaidoo, MD	USA	No Relationships
Ajeya P. Joshi, MD	USA	Christus Santa Rosa Children's Hospital (a); Phygen (c); SpineSmith (c)
Jennifer M. Jupitz	USA	No Relationships
Muayad Kadhim, MD	USA	No Relationships
Ryohei Kagotani, MD	Japan	No Relationships
Sinan Kahraman	Turkey	No Relationships
Sheila Kahwaty, PA-C	USA	No Relationships
Shunsuke Kanbara	Japan	No Relationships
Pankaj Kandwal, MS(Orth)	India	No Relationships
Shinjiro Kaneko	Japan	No Relationships

If noted, the relationships disclosed are as follows: (a) Grants/Research Support (b) Consultant (c) Stock/Shareholder (self-managed)
(d) Speaker's Bureau (e) Advisory Board or Panel (f) Salary, Contractual Services
(g) Other Financial or Material Support (royalties, patents, etc.)

CONFLICT OF INTEREST DISCLOSURES

Tokumi Kanemura, MD	Japan	No Relationships
Daniel G. Kang, MD	USA	No Relationships
Ali F. Karatas	USA	No Relationships
Fumihiko Kato, MD	Japan	No Relationships
Masaki Kawai, MD	Japan	No Relationships
Noriaki Kawakami, MD, DMSc	Japan	Medtronic (b)
Khaled Kebaish, MD	USA	DePuy Spine (a,b); K2M (b,c)
Bastiaan Kemp, BSc	Netherlands	No Relationships
Abbey Kennedy	USA	No Relationships
Christopher K. Kepler, MD, MBA	USA	No Relationships
Sassan Keshavarzi	USA	No Relationships
Adam Khan, BA	USA	No Relationships
Safdar N. Khan, MD	USA	No Relationships
Babak Khandehroo, MD	USA	No Relationships
Do Yeon Kim, MD	Republic of Korea	No Relationships
Dong Soo Kim	Republic of Korea	No Relationships
Hak-Sun Kim, MD	Republic of Korea	No Relationships
Han Jo Kim, MD	USA	No Relationships
Hyoung Bok Kim	Republic of Korea	No Relationships
Kyle Kim, MD, PhD	USA	No Relationships
Sung-Kyu Kim	Republic of Korea	No Relationships
Whoan Jeang Kim	Republic of Korea	No Relationships
Yong Min Kim, MD, PhD	Republic of Korea	No Relationships
Akilah B. King, BA	USA	No Relationships
Cassie L. Kirby, BA, CCRP	USA	No Relationships
Shyam Kishan, MD	USA	Globus Medical (b); K2M (a); Medtronic (b)
Eric Klineberg, MD	USA	Alphatec (b); AO (a,d); DePuy Spine (a,d); Stryker Spine (d); Synthes Spine (a,d)
Alauddin Kochai	Turkey	No Relationships
Linda Koester, BS	USA	No Relationships
Antti Koivusalo, MD, PhD	Finland	No Relationships
Hitoshi Kono, MD	Japan	No Relationships
Katariina Korhonen	Finland	No Relationships
Panagiotis Korovessis, MD, PhD	Greece	No Relationships
Toshiaki Kotani	Japan	No Relationships
Rustam Kudryakov, MD, MPH	USA	No Relationships
Craig A. Kuhns, MD	USA	Stryker Spine (b); Doctors Research Group (c)
Preethi M. Kulkarni, MD	USA	No Relationships
Mun Keong Kwan, MS(Orth)	Malaysia	No Relationships
Kwaku A. Kyere, BA	USA	No Relationships
Virginie Lafage, PhD	USA	DePuy Spine (a); Medtronic (b); Nemaris (c)

If noted, the relationships disclosed are as follows: (a) Grants/Research Support (b) Consultant (c) Stock/Shareholder (self-managed)
(d) Speaker's Bureau (e) Advisory Board or Panel (f) Salary, Contractual Services
(g) Other Financial or Material Support (royalties, patents, etc.)

CONFLICT OF INTEREST DISCLOSURES

Michael O. LaGrone, MD	USA	Innovasis (b)
Frank La Marca, MD	USA	Biomet (b); DePuy Spine (a); Globus Medical (b); Lanx (b); Stryker Spine (a)
Jeffrey Lange, MD	USA	Medtronic (a)
Anthony S. Lapinsky, MD	USA	No Relationships
A. Noelle Larson, MD	USA	No Relationships
Brandon Lawrence, MD	USA	No Relationships
Charles Gerald T. Ledonio, MD	USA	No Relationships
Chong C. Lee, MD, PhD	USA	No Relationships
Jeff A. Lehmen, MD	USA	No Relationships
Jean-Christophe Leveque, MD	USA	No Relationships
Fangcai Li, PhD	China	No Relationships
Isador Lieberman, MD, MBA, FRCSC	USA	Alphatec (b); Axiomed Spine (b); Crosstrees (b); Mazor Surgical (b); Merlot OrthopediX (b); Orthofix (b); Stryker Spine (g); Synthes Spine (b); Trans1 (b); Zyga (b)
Michelle B. Lierl, MD	USA	No Relationships
Jea-Woo Lim	Republic of Korea	No Relationships
Chia-Ying Lin, PhD	USA	No Relationships
Emily M. Lindley, PhD	USA	Synthes Spine (a)
Breton Line, BSME	USA	No Relationships
Shaohua Liu	China	No Relationships
Yungtai Lo	USA	No Relationships
William C. Loftus, PhD	USA	No Relationships
Baron S. Lonner	USA	Axial Biotech (d); DePuy Spine (a,b,d,e); ICEOS (c); K2M (c,d); Paradigm (c); Spine Search (c,e)
Michael Lu, MD	USA	No Relationships
Scott J. Luhmann, MD	USA	Medtronic (d)
Keith D. Luk, MD	China	No Relationships
Zhuojing Luo	China	No Relationships
Jean-Marc Mac-Thiong, MD, PhD	Canada	DePuy Spine (a); Medtronic (a); MMDS Medical (g); Spinologics (c,e,f,g)
Masafumi Machida, MD	Japan	No Relationships
Masaaki Machino	Japan	No Relationships
Kin Cheung Mak, BSc, MBBS	Hong Kong	No Relationships
Luis Marchi, MSc	Brazil	No Relationships
Steven M. Mardjetko, MD, FAAP	USA	DePuy Spine (b); K2M (a,b); Medtronic (b); Spinecraft (b,c,g)
Tanaka Masato	Japan	No Relationships
Akiyuki Matsumoto	Japan	No Relationships
Yukihiko Matsuyama, MD	Japan	No Relationships
Ian McCarthy, PhD	USA	NuVasive (a)
Kathryn J. McCarthy, MD	USA	No Relationships
Robert T. McClellan, MD	USA	No Relationships
Anna M. McClung, RN	USA	No Relationships
Erik H. McDonald, BS	USA	No Relationships

If noted, the relationships disclosed are as follows: (a) Grants/Research Support (b) Consultant (c) Stock/Shareholder (self-managed) (d) Speaker's Bureau (e) Advisory Board or Panel (f) Salary, Contractual Services (g) Other Financial or Material Support (royalties, patents, etc.)

CONFLICT OF INTEREST DISCLOSURES

Mark McElroy, MS	USA	No Relationships
Hossein Mehdian, MD, MS(Orth), FRCS(Ed)	United Kingdom	No Relationships
Charles T. Mehlman, DO, MPH	USA	Attorney's Offices for Expert Testimony (f); Oakstone (g)
Addisu Mesfin, MD	USA	No Relationships
Weber Michael, MD, PhD	USA	No Relationships
Shohei Minami	Japan	No Relationships
Shohei Minami	Japan	No Relationships
Akihito Minamide, MD, PhD	Japan	No Relationships
Stefan A. Mindea, MD	USA	DePuy Spine (b); Medtronic (b)
Kyle A. Mitsunaga, MD	USA	No Relationships
Bertrand Moal, MS	USA	No Relationships
Hitesh N. Modi, MS, PhD	India	No Relationships
Alain Moreau, PhD	Canada	Fourth Dimension Spine (a); Paradigm Spine (e)
Daigo Morita	Japan	No Relationships
Isaac L. Moss, MDCM, MASc, FRCSC	USA	No Relationships
Charbel D. Moussallem, MD	USA	No Relationships
Tanguy Mouton, Resident	France	No Relationships
Sevda Muftuoglu, MD, PhD	Turkey	No Relationships
Gregory M. Mundis, MD	USA	DePuy Spine (a); K2M (a,b,d); NuVasive (a,b,d)
Keiji Nagata	Japan	No Relationships
Yukihiro Nakagawa, MD, PhD	Japan	No Relationships
Masaya Nakamura	Japan	No Relationships
Ahmad Nassr, MD	USA	No Relationships
Geraldine I. Neiss, PhD	USA	No Relationships
Philip Neubauer, MD	USA	No Relationships
Dolores Njoku, MD	USA	No Relationships
Mariano A. Noel, MD	Argentina	No Relationships
Yutaka Nohara, MD	Japan	No Relationships
Kenya Nojiri	Japan	No Relationships
Edward K. Nomoto, MD	USA	No Relationships
Andriy Noshchenko, PhD	USA	No Relationships
Susana Núñez Pereira, MD	Germany	No Relationships
Roosevelt Offoha	USA	No Relationships
Gerald Ogola	USA	No Relationships
Stephen J. Olivar, MD	USA	No Relationships
Leonardo Oliveira, BSc	Brazil	No Relationships
Margaret A. Olsen, PhD, MPH	USA	No Relationships
Ibrahim Ornek	Turkey	No Relationships
Yasushi Oshima, MD, PhD	Japan	No Relationships
Roger K. Owens, MD	USA	No Relationships

If noted, the relationships disclosed are as follows: (a) Grants/Research Support (b) Consultant (c) Stock/Shareholder (self-managed)
(d) Speaker's Bureau (e) Advisory Board or Panel (f) Salary, Contractual Services
(g) Other Financial or Material Support (royalties, patents, etc.)

CONFLICT OF INTEREST DISCLOSURES

Cagatay Ozturk, MD	Turkey	Medtronic (b)
Mary Ruth A. Padua, MD	Philippines	No Relationships
Joshua M. Pahys, MD	USA	No Relationships
Mikko P. Pakarinen, MD, PhD	Finland	No Relationships
Scott Paquette, MD, FRCSC	Canada	No Relationships
Umesh Parashri	India	No Relationships
Stefan Parent, MD, PhD	Canada	DePuy Spine (a,b); Medtronic (b); Spinologics (c)
Paul Park, MD	USA	NIH (a)
Vikas V. Patel, MD	USA	Aesculap (a,e); Cerapedics (a); Lanx (b); Medtronic (a); Orthofix (a); Synthes Spine (a)
Jeff Pawelek	USA	No Relationships
Murat Pekmezci, MD	USA	NuVasive (a); Stryker Spine (a)
Ferran Pellise, MD	Spain	DePuy Spine (a,b,g)
Miguel A. Pelton, BS	USA	No Relationships
Maty Petcharaporn, BS	USA	No Relationships
Mark Pichelmann, MD	USA	No Relationships
Bruno Piedboeuf, MD	Canada	No Relationships
Rosemary Pierce, BS	USA	No Relationships
Carles Pigrau, MD	Spain	No Relationships
Luiz Pimenta, MD, PhD	Brazil	Baxter (a); Globus Medical (b); Impliant (a); Nexgen Spine (a); NuVasive (b,g); Pionner (a) Zyga Tech (b)
Ryan P. Pong, MD	USA	No Relationships
Jean-Paul Praud, MD, PhD	Canada	No Relationships
Themistocles Protopsaltis, MD	USA	K2M (d); Surgimap Spine (d)
Paul Pynsent, PhD	United Kingdom	No Relationships
Bangping Qian	China	No Relationships
Kris Radcliff, MD	USA	No Relationships
Shayan Rahman, MD	USA	No Relationships
Saloni Raj	India	No Relationships
Sreeramalingam Rathinavelu, MS	India	No Relationships
Shashank Ravi	USA	No Relationships
Rodrigo G. Remondino, MD	Argentina	No Relationships
Thomas Repantis, MD, PhD	Greece	No Relationships
Pedro A. Ricart Hoffiz, MD, MS	USA	No Relationships
James W. Rice, MD	USA	No Relationships
Kathleen M. Richter, MS, MFA, ELS	USA	No Relationships
Jeffrey A. Rihn, MD	USA	DePuy Spine (a)
Anthony S. Rinella, MD	USA	No Relationships
Risto Rintala	Finland	No Relationships
Jody A. Rodgers, MD, FACS	USA	Exactech (a,b,d,e); NuVasive (a,b,c,d,e,g); Spineart (a,b,d); VTI (a,b)
William B. Rodgers, MD	USA	Exactech (a,b,d,e); NuVasive (a,b,c,d,e,g); SpineArt (a,b,d); VTI (a,b)

If noted, the relationships disclosed are as follows: (a) Grants/Research Support (b) Consultant (c) Stock/Shareholder (self-managed)
(d) Speaker's Bureau (e) Advisory Board or Panel (f) Salary, Contractual Services
(g) Other Financial or Material Support (royalties, patents, etc.)

CONFLICT OF INTEREST DISCLOSURES

Dolors Rodríguez-Pardo, MD, PhD	Spain	No Relationships
Kenneth J. Rogers, PhD	USA	No Relationships
Peter S. Rose, MD	USA	No Relationships
David Ross, MFA	USA	No Relationships
Pierre Roussouly, MD	France	SMAIO (e)
David P. Roye, MD	USA	Biomet (a); CWSDRF (a); CWSDSG (g); OMeGA (a); Stryker Spine (b)
John Nathaniel M. Ruiz, MD, MRCS	Singapore	No Relationships
Rajiv Saigal, MD, PhD	USA	No Relationships
Masashi Saito	Japan	No Relationships
Jerome Sales de Gauzy, PhD	France	No Relationships
Päivi M. Salminen	Finland	No Relationships
Dino Samartzis, DSc, PhD (C), MSc	China	No Relationships
Amer F. Samdani, MD	USA	DePuy Spine (b,d); SpineGuard (b,d); Synthes Spine (b,d)
Nathalie Samson	Canada	No Relationships
Zeeshan Sardar, MD, CM	Canada	No Relationships
Mercan Sarier	Turkey	No Relationships
Vishal Sarwahi, MD	USA	DePuy Spine (a); K2M (a); Stryker Spine (a)
Kotaro Satake, MD	Japan	No Relationships
Lim Beng Saw, MS(Orth)	Malaysia	No Relationships
William Schairer	USA	No Relationships
Justin K. Scheer, BS	USA	No Relationships
Justin K. Scheer, BS	USA	No Relationships
Daniel M. Schwartz, PhD	USA	No Relationships
Gaetano Scuderi	USA	Atlas (c); Cytonics (c,e,g)
Shoji Seki, MD	Japan	No Relationships
Hyoung-Yeon Seo, MD	Republic of Korea	No Relationships
Anthony K. Sestokas, PhD	USA	No Relationships
Rajiv K. Sethi, MD	USA	No Relationships
Shallu Sharma, MPT	Denmark	No Relationships
Dong-Eun Shin, PhD	Republic of Korea	No Relationships
Masanobu Shioda	Japan	No Relationships
Harry L. Shufflebarger, MD	USA	Axial Biotech (a); DePuy Spine (a,b,e,g)
Brenda A. Sides, MA	USA	No Relationships
Clement Silvestre, MD	France	No Relationships
Devender Singh, PhD	USA	No Relationships
Kern Singh, MD	USA	No Relationships
Murat Sirickci	Turkey	No Relationships
Michael Slivka, MSc	USA	DePuy Spine (f); Johnson & Johnson (c)
Donald A. Smith, MD	USA	No Relationships
John T. Smith, MD	USA	CWSDRF (e); Synthes Spine (b,g)

If noted, the relationships disclosed are as follows: (a) Grants/Research Support (b) Consultant (c) Stock/Shareholder (self-managed)
 (d) Speaker's Bureau (e) Advisory Board or Panel (f) Salary, Contractual Services
 (g) Other Financial or Material Support (royalties, patents, etc.)

CONFLICT OF INTEREST DISCLOSURES

Micah W. Smith, MD	USA	No Relationships
William D. Smith, MD	USA	NuVasive (a,b,c,d,g)
Matthew Smuck, MD	USA	Arthrocare (a,b); Cytonics (a)
Brian D. Snyder, MD, PhD	USA	No Relationships
Gbolabo Sokunbi	USA	No Relationships
Kai Song	China	No Relationships
Jonathan B. Spilsbury, FRCS(Orth)	United Kingdom	No Relationships
Rajeshwar N. Srivastava, MD	India	No Relationships
Tricia St. Hilaire, BS	USA	Synthes Spine (a)
Jeremy J. Stallbaumer, MD	USA	No Relationships
Karen D. Standefer, BS	USA	No Relationships
Andrew F. Stasic, MD	USA	No Relationships
Meredith Steinman	USA	No Relationships
John Street, MD, PhD	Canada	Medtronic (d)
Growing Spine Study Group	USA	Growing Spine Foundation (a)
Harms Study Group	USA	DePuy Spine (a)
International Spine Study Group	USA	DePuy Spine (a)
Peter Sturm, MD	USA	DePuy Spine (a,b); Pioneer Surgical (c)
Dong Sun, PhD	China	No Relationships
Xu Sun	China	No Relationships
Nobumasa Suzuki, MD	Japan	No Relationships
Pascal Swider, PhD	France	No Relationships
Katsushi Takeshita, MD	Japan	No Relationships
Eric W. Tan, MD	USA	No Relationships
Hiroshi Taneichi, MD	Japan	No Relationships
Jessica A. Tang, BS	USA	No Relationships
Mingxing Tang	China	No Relationships
Huiren Tao	China	No Relationships
Erol - Tasdemiroglu	Turkey	No Relationships
Bobby Tay, MD	USA	BioMet (b); NuVasive (a); Omega (a); Stryker Spine (b); Synthes Spine (b)
Lee A. Taylor, MD	USA	No Relationships
Carlos A. Tello, MD	Argentina	No Relationships
Masatoshi Teraguchi, MD	Japan	No Relationships
Joseph Thambiah, FRCS	Singapore	No Relationships
Khoi D. Than, MD	USA	No Relationships
Tracey T. Than	USA	No Relationships
Alistair G. Thompson, FRCS	United Kingdom	No Relationships
Cynthia Thompson, PhD	Canada	No Relationships
George H. Thompson, MD	USA	Journal of Pediatric Orthopaedics (f); K2M (b); OrthoPediatrics (b); SpineForm (b); SpineGuard (b)
Beverly Thornhill, MD	USA	No Relationships

If noted, the relationships disclosed are as follows: (a) Grants/Research Support (b) Consultant (c) Stock/Shareholder (self-managed)
 (d) Speaker's Bureau (e) Advisory Board or Panel (f) Salary, Contractual Services
 (g) Other Financial or Material Support (royalties, patents, etc.)

CONFLICT OF INTEREST DISCLOSURES


Agnivesh Tikoo, MS(Orth)	India	No Relationships
Patrick Tomak, MD	USA	No Relationships
Benjamin Tow, MBBS, M.MED(Orth), FRCS(Orth)	Singapore	No Relationships
Yoshiaki Toyama	Japan	No Relationships
Clifford B. Tribus, MD	USA	Amedica (c,g); ESM Technologies (g); Stryker Spine (b,g); Zimmer (b)
Patrick Tropiano, MD	France	Synthes Spine (b)
Taichi Tsuji, MD	Japan	No Relationships
Takashi Tsuji	Japan	No Relationships
Shunji Tsutsui	Japan	No Relationships
Levent Ulusoy	Turkey	No Relationships
Benjamin Ungar	USA	No Relationships
Koki Uno, MD, PhD	Japan	No Relationships
Juan S. Uribe, MD	USA	NuVasive (b)
Timothy D. Uschold, MD	USA	Synthes Spine (a)
Alexander R. Vaccaro, MD, PhD	USA	Advanced Spinal Intellectual Properties (c); Aesculap (g); Alphatec (g); Benvenue Medcal (b); Biodynamics (c); Biomet Spine (g); Bonovo Orthopaedics (c); Cerapedics (a); Computational Progressive Spinal Technologies (c); Cross Current (c); Cytonics (c); DePuy Spine (g); Disk Motion Technology (c); Electrolux (c); Flagship Surgical (c); FlowPharma (c); Gamma Spine (c); Gerson Lehrman Group (b); Globus Medical (c,g); Guidepoint Global (b); In Vivo (c); K-2 Medical (c); Location Based Intelligence (c); Medacorp (b); Medtronic (g); NeuCore (c); NuVasive (g); Paradigm Spine (c); Replication Medica (c); R.I.S (c); Rothman Institute and Related Holdings (c); Small Bone Innovations (c); Spine Medica (c); Spinology (c); Stout Medical (c); Stryker Spine (g); Syndicom (c); Vertiflex (c)
Konstantinos Vardakastanis	Greece	No Relationships
Patrick Vavken	Switzerland	No Relationships
Max A. Viergever, DSc	Netherlands	No Relationships
Alba Vila-Casademunt	Spain	DePuy Spine (a)
Carlos Villanueva, MD, PhD	Spain	Prim (e); Scient'x (g)
Koen L. Vincken, PhD	Netherlands	No Relationships
Michael G. Vitale, MD, MPH	USA	Biomet Spine (b,g); CWSDSG (a,e); OMeGA (a); Stryker Spine (b); Synthes Spine (a)
Vasilis Vitsas, MD	Greece	No Relationships
Tomaz Vrtovec, PhD	Slovenia	No Relationships
Eugene K. Wai, MD, MSc, CIP, FRCSC	Canada	No Relationships
Zeke J. Walton, MD	USA	No Relationships
Ling Wang, MD	USA	No Relationships
Miao Wang, MD	Denmark	No Relationships
Yuxiang Wang, MD	China	No Relationships
Douglas Wardlaw, MB, ChB, ChM, FRCS(Ed)	United Kingdom	Medtronic (a,b)
Daniel T. Warren, MD	Canada	No Relationships
Hironobu Watanabe	Japan	No Relationships
Kota Watanabe	Japan	Medtronic (b)

If noted, the relationships disclosed are as follows: (a) Grants/Research Support (b) Consultant (c) Stock/Shareholder (self-managed)
(d) Speaker's Bureau (e) Advisory Board or Panel (f) Salary, Contractual Services
(g) Other Financial or Material Support (royalties, patents, etc.)

CONFLICT OF INTEREST DISCLOSURES


Nicholas J. White, MPH	USA	No Relationships
Shirvinda Wijesekera, MD	USA	No Relationships
Brendan A. Williams, AB	USA	No Relationships
Adam L. Wollowick, MD	USA	DePuy Spine (a,b,d); Stryker Spine (a)
Guoruey Wong, BSc, MSc	Canada	No Relationships
Yat Wa Wong	Hong Kong	No Relationships
Kirkham B. Wood, MD	USA	AO Spine (a); Globus Medical (a); Synthes Spine (a); Trans1 (c)
Tao Wu	China	No Relationships
Jianzhong Xu, MD	China	No Relationships
Hiroshi Yamada, MD, PhD	Japan	No Relationships
Takuya Yamamoto	Japan	No Relationships
Yu Yamato	Japan	No Relationships
Ken Yamazaki, MD	Japan	No Relationships
Haruhisa Yanagida, MD	Japan	Japanese Government (a); Medtronic (a)
Burt Yaszay, MD	USA	DePuy Spine (a,d); Ellipse (a,b); K2M (a,b); KCI (a); Orthopediatrics (g); Synthes Spine (b)
Can H. Yildirim, MD	Turkey	No Relationships
Guney Yilmaz	USA	No Relationships
Petya Yorgova, MS	USA	No Relationships
Munehito Yoshida	Japan	No Relationships
Miao Yu, MD	China	No Relationships
Yang Yu	China	No Relationships
Yasutsugu Yukawa, MD	Japan	No Relationships
Lin Zeng, PhD	China	No Relationships
Hong Zhang, MD	USA	No Relationships
Hongqi Zhang, MD	China	No Relationships
Huina Zhang, MD, PhD	USA	No Relationships
Jianguo Zhang, MD	China	No Relationships
Yonggang Zhang, PhD	China	No Relationships
Xin Zhen	China	No Relationships
Xuhui Zhou, MD	USA	No Relationships
Feng Zhu	China	No Relationships
Ze Zhang Zhu	China	No Relationships
SRS Staff		
Cydni Chapman	USA	No Relationships
Tressa Goulding, CAE, CMP	USA	No Relationships
Megan M. Kelley	USA	No Relationships
Courtney Kissinger	USA	No Relationships
Katy Kujala-Korpela	USA	No Relationships
Brian Lueth	USA	No Relationships
Nilda Toro	USA	No Relationships

If noted, the relationships disclosed are as follows: (a) Grants/Research Support (b) Consultant (c) Stock/Shareholder (self-managed)
 (d) Speaker's Bureau (e) Advisory Board or Panel (f) Salary, Contractual Services
 (g) Other Financial or Material Support (royalties, patents, etc.)

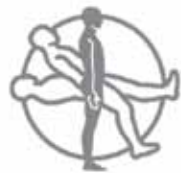



MEETING AGENDA



The Scoliosis Research Society gratefully acknowledges Medtronic for their support of the General Session, Wireless Internet, Internet Kiosks, and Welcome Reception.



Medtronic

† = Whitecloud Award Nominee – Best Clinical Paper * = Whitecloud Award Nominee – Best Basic Science Paper

MEETING AGENDA

WEDNESDAY, JULY 18, 2012

14:00 – 19:30 Registration Open

Room: B0 Foyer

15:00 – 17:00 Hands-On Workshops (see "Exhibits and Hands-On Workshops section on page 190-191 for more information")

17:00 – 19:30 Welcome Reception

Room: B2 Foyer

THURSDAY, JULY 19, 2012

7:00 – 16:30 Registration and Exhibits Open

7:00 – 8:00

Breakfast & Exhibit Viewing

Room: B2 Foyer

Hands-On Workshops with Breakfast (see "Exhibits and Hands-On Workshops section on page 190-191 for more information")

8:00 – 8:15 Walking Break

8:15 – 9:40 General Session #1: Whitecloud Award Nominees - Clinical Science

The general sessions are supported, in part, by a grant from Medtronic.

Room: Uskudar

Moderators: Lawrence G. Lenke, MD

David W. Polly, Jr., MD

8:15 Welcome

Christopher I. Shaffrey, MD

IMAST Committee Chair

8:14 †Paper # 1: Does Recombinant Human Bone Morphogenetic Protein-2 (BMP) Use in Adult Spinal Deformity (ASD) Increase Complications and are Complications Dose Related? A Prospective, Multicenter Study of 257 Consecutive Patients

Shay Bess, MD; Breton Line, BSME; Oheneba Boachie-Adjei, MD; Robert A. Hart, MD; Virginia Lafage, PhD; Frank Schwab, MD; Behrooz A. Akbarnia, MD; Christopher P. Ames, MD; Douglas C. Burton, MD; Richard Hostin, MD; Eric Klineberg, MD; Gregory M. Mundis, MD; Christopher I. Shaffrey, MD; Justin S. Smith, MD, PhD; International Spine Study Group

8:19 †Paper # 2: "Sex and the Sacrum" - An Analysis of the Effects of Long Fusion to the Sacrum on Sexual Function

Michael O. LaGrone, MD; Amanda B. Coffman, PA-C, MCHS

8:23 †Paper # 3: Unmarked Image Validation of the SRS-Schwab Adult Deformity Classification

Frank Schwab, MD; Jason Demakakos; Benjamin Blondel, MD; Benjamin Ungar; Jacob M. Buchowski, MD, MS; Jeffrey D. Coe, MD; Donald A. Deinlein, MD; Christopher DeWald, MD; Hossein Mehdiian, MD, MS(Orth) FRCS(Ed); Christopher I. Shaffrey, MD; Clifford B. Tribus, MD; Virginia Lafage, PhD

8:27 Discussion

8:35 †Paper # 4: A Critical Assessment of Growing Rods for the Treatment of Pediatric Scoliosis in Cerebral Palsy

Mark McElroy, MS; Paul D. Sponseller, MD; Jonathan R. Dattilo, BS; George H. Thompson, MD; Behrooz A. Akbarnia, MD; Suken A. Shah, MD; Brian D. Snyder, MD, PhD; Growing Spine Study Group

8:39 †Paper #5: Age, Sagittal Deformity and Operative Correction are Risk Factors for Proximal Junctional Failure (PJF) Following Adult Spinal Deformity (ASD) Surgery

Robert A. Hart, MD; Richard Hostin, MD; Themistocles Protopsaltis, MD; Shay Bess, MD; Frank Schwab, MD; Virginia Lafage, PhD; Praveen V. Mummaneni, MD; Christopher P. Ames, MD; Christopher I. Shaffrey, MD; Justin S. Smith, MD, PhD; Oheneba Boachie-Adjei, MD; Eric Klineberg, MD; Douglas C. Burton, MD; Munish C. Gupta, MD; International Spine Study Group

8:43 †Paper # 6: Functional Outcomes in Duchenne Muscular Dystrophy: Comparing the Differences between Surgery vs. No Surgery in the Management of Scoliosis Deformity

Hyon Su Chong; Hak-Sun Kim, MD; Jea-Woo Lim; Hyoung Bok Kim; Do Yeon Kim, MD; Dong-Eun Shin, PhD; Mary Ruth A. Padua, MD

8:47 Discussion

MEETING AGENDA

† = Whitecloud Award Nominee – Best Clinical Paper * = Whitecloud Award Nominee – Best Basic Science Paper

- 8:55 †Paper # 7: Cost Effectiveness of Single-Level Anterior Cervical Discectomy and Fusion Five Years After Surgery
Leah Y. Carreon, MD, MSc; Paul A. Anderson, MD; Vincent C. Traynelis, MD; Praveen V. Mummaneni, MD; Steven D. Glassman, MD
- 8:59 †Paper # 8: Safety and Efficacy of One-Stage Surgical Treatment for Congenital Spinal Deformity Associated with Split Spinal Cord Malformation
Huiren Tao; Zhuojing Luo; Hua Hui, MD
- 9:03 †Paper # 9: Coagulopathy in Adult de novo Scoliosis Surgery: Timing and Onset of Breakdown of the Coagulation Cascade as Measured by D Dimer and Fibrinogen Levels
Rajiv K. Sethi, MD; Jean-Christophe Leveque, MD; Thomas C. Dean, MD; Ryan P. Pong, MD; Stephen J. Olivar, MD; Sarah Hipps, MD; Vishal Gala, MD, MPH; Chong C. Lee, MD, PhD; Kyle Kim, MD, PhD
- 9:07 Discussion
- 9:15 Keynote Address
Introduction
*Kamal N. Ibrahim, MD, FRCS(C), MA
SRS President-Elect*
What do we Learn from Complications?
*B. Stephens Richards, III, MD
SRS President*
- 9:35 Preview of the 47th Annual Meeting & Course and 20th IMAST

9:40 – 9:55 Walking Break

9:55 – 10:55 Instructional Course Lectures 1A-D

1A: Spondylolisthesis

Room: *Emirgan 1*

Moderator: *Jean-Charles Le Huec, MD, PhD*

- 9:55 The Importance of Pelvic Incidence, Sacral Slope, & Sagittal Balance and Their Incorporation into New Spondylolisthesis Classification System
Hubert Labelle, MD
- 10:07 Evaluation and Treatment for Symptomatic Spondylolysis in the Young Athlete
Benny T. Dahl, MD, PhD, DMSci
- 10:19 Surgical Options for Degenerative Spondylolisthesis
Stephen J. Lewis, MD, MSc, FRCSC
- 10:31 Treatment Options for High-Grade Spondylolisthesis: The Role for Reduction
Jean-Charles Le Huec, MD, PhD
- 10:43 Discussion and/or Cases

1B: Options in Cervical Motion

Room: *Emirgan 2*

Moderator: *Todd J. Albert, MD*

- 9:55 How to Choose ACDF vs. CDR
Todd J. Albert, MD
- 10:07 Cervical Adjacent Segment Disease – Natural History or the Fusion?
K. Daniel Riew, MD
- 10:19 Does the Type of Cervical Disc Replacement Impact Outcome?
Praveen V. Mummaneni, MD
- 10:31 When is Multilevel Cervical Disc Replacement Appropriate?
Frank M. Phillips, MD
- 10:43 Discussion and/or Cases

† = Whitecloud Award Nominee – Best Clinical Paper * = Whitecloud Award Nominee – Best Basic Science Paper

MEETING AGENDA

1C: Adult Deformity I: Surgical Management of Lumbar Degenerative Deformity

Room: *Beylerbeyi*

Moderator: *Frank J. Schwab, MD*

9:55 *The SRS/Schwab Adult Scoliosis Classification System and its Importance in Patient Evaluation and Treatment*

Frank J. Schwab, MD

10:07

Adult Degenerative Deformity- Clinical Presentation and Informed Choice on Options for Care

Sigurd H. Berven, MD

10:19

Operative Strategies: Choosing Levels and Strategies for Correcting Coronal Deformity

Sean Molloy, MBBS, MSc, FRCS

10:31

Strategies for Reducing Proximal Junctional Kyphosis

Hilali H. Noordeen, FRCS

10:43

Discussion and/or Cases

1D: Early Onset Scoliosis I

Room: *Camlica*

Moderator: *Ahmet Alanay, MD*

9:55

Evaluation and Classification

Ahmet Alanay, MD

10:07

The Role and Options for Nonoperative Management

Richard E. McCarthy, MD

10:19

Timing of Surgical Intervention and Impact on Spinal and Thoracic Growth

Behrooz A. Akbarnia, MD

10:31

EOS Surgical Options and Techniques

Muharrem Yazici, MD

10:43

Discussion and/or Cases

10:55 – 11:10

Walking Break

11:10 – 12:10

Concurrent Sessions & Debates

Concurrent Session #2A: Whitecloud Award Nominees – Basic Science

Room: *Uskudar*

Moderators: *Brian K. Kwon, MD, PhD, FRCSC*

Michael Fehlings, MD, PhD, FRCSC

11:10

**Paper # 10: The Effect of Contouring on Fatigue Strength of Deformity Rods: Is it Okay to Rebend and Which Materials are Best?*

Michael Slivka, MSc; Yung K. Fan; Jason C. Eck, DO, MS

11:14

**Paper # 11: Can a Novel Rectangular Footplate Provide Higher Resistance to Subsidence when Compared to Circular Footplates? An Ex Vivo Biomechanical Study*

Murat Pekmezci, MD; Abbey Kennedy; Erik H. McDonald, BS; Christopher P. Ames, MD; Robert T. McClellan, MD; Vedat Deviren, MD

11:18

**Paper # 12: Feasibility of Percutaneous Posterolateral Spinal Fusion with Recombinant Bone Morphogenetic Protein - 2 (rh-BMP2): A Comparison with Standard Methods using an Animal Model Study*

Chris Yin Wei Chan, MS Orth; Lim Beng Saw, MS Orth; Paisal Hussin, MS Orth; Mun Keong Kwan, MS Orth

11:22

Discussion

11:30

**Paper # 13: Three Dimensional Visualization of the Intervertebral Disc: The Effects of Growth Modulation*

Diana A. Glaser, PhD; Christine L. Farnsworth, MS; Josh Doan, MEng; Peter O. Newton, MD

11:34

Paper # 14: TNF- β Nco1 Polymorphism in Relation to Postoperative Sepsis Outcome

Rajeshwar N. Srivastava, MD; Kavita Baghel, MSc; Saloni Raj

11:38

**Paper # 15: Intradiscal Injection of Simvastatin Results in Radiologic, Histologic, and Genetic Evidence of Disc Regeneration in a Rat Model of Degenerative Disc Disease*

Khoi D. Than, MD; Shayan Rahman, MD; Lin Wang, MD; Kwaku A. Kyere, BA; Tracey T. Than; Adam Khan, BA; Frank La Marca, MD; Paul Park, MD; Huijin Zhang, MD, PhD; Chia-Ying Lin, PhD

MEETING AGENDA

† = Whitecloud Award Nominee – Best Clinical Paper * = Whitecloud Award Nominee – Best Basic Science Paper

- 11:42 Discussion
- 11:50 *Paper # 16: Occipital Incidence - A Novel Morphometric Parameter for Understanding Occipitocervical Spinal Alignment
Han Jo Kim, MD; Lawrence G. Lenke, MD; K. Daniel Riew, MD; Yasushi Oshima, MD, PhD; Addisu Mesfin, MD; Jeremy L. Fogelson, MD; Stuart Hershman, MD; Brenda A. Sides, MA
- 11:54 *Paper # 17: Pedicle Screw Epiphysiodesis of Neurocentral Synchondrosis for Correction of Scoliosis: Histological Evaluation in a Growing Porcine Model
Xuhui Zhou, MD; Hong Zhang, MD; Daniel J. Sucato, MD, MS
- 11:58 *Paper # 18: Inflammatory or Mechanical? Can Inflammatory Profiles Predict Outcomes from Lumbar Discectomy for Disc Herniation?
Micah W. Smith, MD; S. Raymond Golish, MD, PhD; Agnes Ith; Ivan Cheng, MD; Gaetano Scuderi; Todd F. Alamin, MD; Kyle A. Mitsunaga, MD; Eugene Carragee, MD; Matthew Smuck, MD
- 12:02 Discussion
- Concurrent Session #2B: Early Onset Scoliosis**
- Room : *Beylerbeyi*
- Moderators: *Emre Acaroglu, MD*
Richard E. McCarthy, MD
- 11:10 Paper # 19: Introducing the Early Onset Scoliosis Classification System
Brendan A. Williams, AB; Behrooz A. Akbaria, MD; Randal R. Betz, MD; Laurel C. Blakemore, MD; John M. Flynn, MD; Charles E. Johnston, MD; Richard E. McCarthy; John T. Smith, MD; Brian D. Snyder, MD, PhD; Paul D. Sponseller, MD; Peter Sturm, MD; George H. Thompson, MD; Muharrem Yazici, MD; Michael G. Vitale, MD, MPH; David P. Roye, MD
- 11:14 Paper # 20: Is the RVAD in Infantile a Reflection of the Spine's Rotation or of the Chest Wall Configuration?
James O. Sanders, MD; Geneviève Foley; Hubert Labelle, MD; Charles E. Johnston, MD; Jacques D'Astous, MD; Stefan Parent, MD, PhD; Carl-Éric Aubin, PhD, Peng
- 11:18 Paper # 21: Pulmonary Function Changes During EDF Casting for Early Onset Scoliosis - A Preliminary Report
Shyam Kishan, MD; Robin D. Jensen, MD; Andrew F. Stasic, MD; Stephen Dierdorf, MD
- 11:22 Discussion
- 11:30 Paper # 22: The Efficacy and Complications of Dual Growing Rod Technique for Congenital Scoliosis
Jianguo Zhang, MD
- 11:34 Paper # 23: Scoliosis Creation By Growth Modulation Of The Chest Cage In A Fetal Ovine Model
Stefan Parent, MD, PhD; Jean-Paul Praud, MD, PhD; Sarah Bouchard; Nathalie Samson; Marc Cloutier; Peter O. Newton, MD; Bruno Piedboeuf, MD
- 11:38 Paper # 24: Convex Growth Arrest in Immature Spine: Comparison of Posterior/Anterior Non-Instrumented and All-Posterior Pedicle Screw Instrumented Fusion in an Animal Model
H Gokhan Demirkiran, MD; Senol Bekmez; Guney Yilmaz; Ibrahim Akel, MD; Pergin Atilla, MD, PhD; Sevda Muftuoglu, MD, PhD; Muharrem Yazici, MD; Ahmet Alanay
- 1:42 Discussion
- 11:50 Paper # 25: Risk Factors for Postoperative Complication in Treatment of Early Onset Scoliosis Using Growing Rod Technique
Kota Watanabe; Morio Matsumoto, MD; Koki Uno, MD, PhD; Noriaki Kawakami, MD, DMSc; Taichi Tsuji, MD; Haruhisa Yanagida, MD; Manabu Ito, MD, PhD; Toru Hirano; Ken Yamazaki, MD; Shohei Minami; Hiroshi Taneichi, MD; Shiro Imagama, MD; Katsushi Takeshita, MD; Takuya Yamamoto
- 11:54 Paper # 26: The Safety and Efficacy of a Remotely Distractible, Magnetic Controlled Growing Rod (MCGR) for the Treatment of Scoliosis in Children: A Prospective Case Series with Minimum Two Year Follow-Up
Kenneth M. Cheung, MBBS(UK), FRCS(England), FHKCOS, FHKAM(Orth); Jason Pui Yin Cheung, MBBS (HK); Dino Samartzis, DSc, PhD(C), MSc; Kin Cheung Mak, BSc, MBBS; Yat Wa Wong; Wai Yuen Cheung, MD; Behrooz A. Akbaria, MD; Keith D. Luk, MD
- 11:58 Paper # 27: VEPTR Graduates: Definitive Fusion of Patients Treated with VEPTR at an Early Age
Jahangir Asghar, MD; Ajeya P. Joshi, MD; Joshua M. Pahys, MD; Harry L. Shufflebarger, MD; Timothy D. Uschold, MD; Tricia St. Hilaire, BS; Sumeet Garg, MD; Randal R. Betz, MD; Charles R. d'Amato, MD, FRCSC; Michael G. Vitale, MD, MPH; John M. Flynn, MD; John T. Smith, MD; Amer F. Samdani, MD
- 12:02 Discussion

† = Whitecloud Award Nominee – Best Clinical Paper * = Whitecloud Award Nominee – Best Basic Science Paper

MEETING AGENDA

Debate #1: Optimal Treatment of Moderate (30-Degree) Thoracolumbar Scoliosis with Stenosis in 70-Year-OldRoom: *Camlica*Moderator: *John R. Dimar, II, MD*11:10 Optimal Treatment is MIS
*Neel Anand, MD*11:20 Optimal Treatment is Posterior-Only Instrumentation and Fusion
*Stephen J. Lewis, MD, MSc, FRCS*11:30 Optimal Treatment is a Circumferential Approach
*Christopher P. Ames, MD***Debate #2: Grade II Isthmic Spondylolisthesis in a 22-Year-Old with Radiculopathy**Room: *Camlica*Moderator: *F. Chumhur Oner, MD, PhD*11:30 Optimal Treatment is Decompression and Instrumented In-Situ Fusion
*Jean-Charles Le Huec, MD, PhD*11:40 Optimal Treatment is Open Reduction and Instrumentation with Interbody Fusion
*David W. Polly, Jr., MD*11:50 Optimal Treatment is MIS
*Mark B. Dekutoski, MD***12:10 – 13:00 Lunch & Exhibit Viewing**Room: *B2 Foyer***13:00 – 14:00 Concurrent Sessions & Complications Series****Concurrent Session #3A: Adolescent Idiopathic Scoliosis**Room: *Uskudar*Moderators: *Suken A. Shah, MD**B. Stephens Richards, III, MD*13:00 Paper # 28: Does Scoliosis Surgery Change Lung Volume or Lung Asymmetry in AIS Patients? A Three-Dimensional CT-Based Volumetric Study
*Vishal Sarwahi, MD; Beverly Thornhill, MD; Jonathan J. Horn; Elliot Harmon; Meredith Steinman; Terry D. Amaral, MD; Adam L. Wollowick, MD*13:04 Paper # 29: Analyzing the Relationship Between Apical Vertebral Rotation and Truncal Rotation in AIS Using 3D Reconstructions
*Krishna Cidambi, MD; Carrie E. Bartley, MA; Tracey Bastron, MA; Burt Yaszay, MD; Peter O. Newton, MD*13:08 Paper # 30: A Morphological Classification of 120 Cases in Young Idiopathic Scoliosis
Miao Yu, MD; Clement Silvestre, MD; Rami El Rachkidi; Lin Zeng, PhD; Tanguy Mouton; Pierre Roussouly, MD

13:12 Discussion

13:20 Paper # 31: The Importance of Sagittal Stable Vertebrae in Adolescent Idiopathic Scoliosis (AIS) Surgery
*Woojin Cho, MD, PhD; David Essig, MD; Michael Faloan, MD; Gbolabo Sokunbi; Akilah B. King, BA; Matthew E. Cunningham, MD, PhD; Oheneba Boachie-Adjei, MD*13:24 Paper # 32: Analysis of the Scoliosis Research Society -22 Questionnaire Scores. Is There a Difference between a Child and Parent and does Physician Review Change That?
*Adrian Gardner, BM, MRCS, FRCS (T&O); Paul Brewer, BSc, MB, ChB; David S. Marks, FRCS; Jonathan B. Spilsbury, FRCS(Orth); Alistair G. Thompson, FRCS; Fiona Berryman; Paul Pynsent, PhD*13:28 Paper # 33: The Influence of BMI on the Clinical, Radiographic, and Functional Outcomes in Adolescents treated with a Posterior Fusion for AIS
Adriana De La Rocha, MS; Anna M. McClung, RN; Daniel J. Sucato, MD, MS

13:32 Discussion

13:40 Paper # 34: Pedicle Screw Instrumentation Does Not Cause Hypokyphosis Following the Surgical Correction of AIS
*Adam L. Wollowick, MD; Terry D. Amaral, MD; Elliot Harmon; Jonathan J. Horn; Preethi M. Kulkarni, MD; Yungtai Lo; Vishal Sarwahi, MD*13:44 Paper # 35: Does Anterior Release Prevent Adding-On following Thoracic Fusion for Lenke 1 Adolescent Idiopathic Scoliosis?
*Steven D. Glassman, MD; B. Stephens Richards, MD; Lawrence G. Lenke, MD; Daniel J. Sucato, MD, MS; Kathryn J. McCarthy, MD; Leah Y. Caneon, MD, MSc*13:48 Paper # 36: Preoperative Metal Allergy Testing for Adolescent Idiopathic Scoliosis Patients
Charles T. Mehlman, DO, MPH; Michelle B. Lierl, MD; Maureen Grady, RN; Cassie L. Kirby, BA, CCRP

MEETING AGENDA

† = Whitecloud Award Nominee – Best Clinical Paper * = Whitecloud Award Nominee – Best Basic Science Paper

13:52 Discussion

Concurrent Session #38: Complications/Infection

Room : Beylerbeyi

Moderators: J. Abbott Byrd, III, MD
David W. Polly, Jr., MD

13:00 Paper # 37: Clinical Complications following rhBMP-2 Use in a Minimally Invasive Transforaminal Lumbar Interbody Fusion
Kern Singh, MD; Miguel A. Pelton, BS; Thomas D. Cha, MD, MBA; Safdar N. Khan, MD

13:04 Paper # 38: Catastrophic Complications Following Minimally Invasive Lateral Lumbar Interbody Fusion
Armen R. Deukmedjian, MD; Juan S. Uribe, MD; Donald A. Smith, MD

13:08 Paper # 39: Outcomes of Three Different Techniques Using the Lateral Approach for Lumbar Interbody Arthrodesis
Michael R. Briseno, MD; Stefan A. Mindea, MD; Robert T. Arrigo, BS; Shashank Ravi; Navpreet Bains, BS; Todd F. Alamin, MD; Ivan Cheng, MD

13:12 Discussion

13:20 Paper # 40: Anterior vs. Posterior Procedure for Surgical Treatment of Thoraco-Lumbar Tuberculosis: A Retrospective Analysis
Pankaj Kandwal, MS (Ortho); Bhavuk Garg; Upendra Bidre, MS; Ankur Goswami, MS (Ortho); Arvind Jayaswal, MS (Ortho)

13:24 Paper # 41: Adverse Events in Emergent Oncologic Spine Surgery: A Prospective Analysis
Nicolas Dea, MD, FRCSC; John Street, MD, PhD; Michael Boyd, MD; Scott Paquette, MD, FRCSC; Brian K. Kwon, MD, PhD, FRCSC; Marcel F. Dvorak, MD, FRCSC; Charles G. Fisher, MD, MHS, FRCSC

13:28 Paper # 42: Does Patient Diagnosis Predict Blood Loss during Posterior Spinal Fusion in Children?
Amit Jain; Dolores Njoku, MD; Paul D. Sponseller, MD

13:32 Discussion

13:40 Paper # 43: EMG Alone Can Be Misleading For Assuring Safe Entry During Transpoas Access to the Lumbar Spine
Vidya Bhalodia; Shirvinda Wijesekera, MD; Anthony K. Sestokas, PhD; William C. Loftus, PhD; Judith L. Gorelick, MD; Patrick Tomak, MD; John M. Beiner, MD; Daniel M. Schwartz, PhD

13:44 Paper # 44: Implant Survival After Deep Surgical Site Infection Following Instrumented Spine Surgery
Susana Núñez Pereira, MD; Ferran Pellise, MD; Dolores Rodríguez-Pardo, MD, PhD; Carles Pignau, MD; Juan Bago, MD; Carlos Villanueva, MD, PhD; Enric Caceres

13:48 Paper # 45: Rod Fracture after Long Construct Fusion in Spinal Deformity: Clinical and Radiographic Risk Factors
Tsutomu Akazawa, MD; Toshiaki Kotani; Shohei Minami

13:52 Discussion

Complications Series: My Worst Complication in Spine Trauma and Strategies to Prevent

Room: Camlica

Moderator: F. Chumhur Oner, MD, PhD

Faculty: Vincent Traynelis, MD
Michael G. Fehlings, MD, PhD, FRCSC, FACS
John R. Dimar, II, MD
F. Chumhur Oner, MD, PhD

14:00 – 14:15 Walking Break

† = Whitecloud Award Nominee – Best Clinical Paper * = Whitecloud Award Nominee – Best Basic Science Paper

MEETING AGENDA

14:15 – 15:15

Instructional Course Lectures 2A-D

2A: Management of Sacropelvic TumorsRoom: *Emirgan 1*Moderator: *Michael J. Yaszemski, MD, PhD*14:15 *Evaluation of the Patient with a Sacral Tumor*
*Jacob M. Buchowski, MD, MS*14:27 *Surgical Management of Sacral Chordomas*
*Ziya L. Gokaslan, MD*14:39 *Management of Giant Cell Tumors of Sacrum*
*Michael J. Yaszemski, MD, PhD*14:51 *Advanced Reconstructive Techniques of the Sacropelvis*
Stephen J. Lewis, MD, MSc, FRCSC

15:03 Discussion and/or Cases

2B: Management of Cervical Spondylotic MyelopathyRoom: *Emirgan 2*Moderator: *Christopher I. Shaffrey, MD*14:15 *Evaluation, Timing and Management of Central Cord Syndrome*
*Michael G. Fehlings, MD, PhD, FRCSC, FACS*14:27 *What is the Best Strategy for the Asymptomatic Patient with Mild Signs of Myelopathy?*
*Vincent Traynelis, MD*14:39 *Anterior vs. Posterior Approaches for CSM*
*Todd J. Albert, MD*14:51 *What is the Role for Cervical Laminoplasty?*
*Christopher I. Shaffrey, MD*15:03 *Complications in Treatment of CSM*
*Justin S. Smith, MD, PhD***2C: Adult Deformity II: Use of Osteotomies in Adult Spinal Deformity**Room: *Beylerbeyi*Moderator: *Frank J. Schwab, MD*14:15 *The Impact of Spinal Balance and Pelvic Parameters on Management of Fixed Sagittal Imbalance*
*Frank J. Schwab, MD*14:27 *Posterior Osteotomies: The Role and Technique of (SPO, PSO) to Manage Adult Spine Deformity*
*Henry F.H. Halm, MD*14:39 *Vertebral Column Resection for Severe Adult Deformity*
*Lawrence G. Lenke, MD*14:51 *Complication of Spinal Osteotomies: How to Recognize, How to Avoid and How to Manage Them*
Sigurd H. Berven, MD

15:03 Discussion and/or Cases

MEETING AGENDA

† = Whitecloud Award Nominee – Best Clinical Paper * = Whitecloud Award Nominee – Best Basic Science Paper

2D: Adolescent Idiopathic Scoliosis I: Classification and Fusion Level Selection

Room: *Camlica*

Moderator: *David S. Marks, FRCS*

14:15 *How the Lenke Classification System Guides Fusion Levels*
Francisco Javier Sanchez Perez-Grueso, MD

14:27 *Beyond 2D Classification, the Role for 3D Classification of AIS*
Hubert Labelle, MD

14:39 *Evaluation and Management of AIS with Atypical Curve Patterns*
David S. Marks, FRCS

14:51 *When Does the Lenke Classification Not Work Well?*
Emre R. Acaroglu, MD

15:03 *Discussion and/or Cases*

15:15 – 15:30 *Walking Break*

15:30 – 16:30 *Hands-On Workshops (see "Exhibits and Hands-On Workshops section on page 190-191 for more information)*

FRIDAY, JULY 20, 2012

7:00 – 16:00 *Registration and Exhibits Open*

7:00 – 8:00

Breakfast & Exhibit Viewing

Room: *B2 Foyer*

Hands-On Workshops with Breakfast (See "Exhibits and Hands-On Workshops section on page 190-191 for more information.)

8:00 – 8:15 *Walking Break*

8:15 – 9:15 *Concurrent Sessions & Debates*

Concurrent Session #4A: Adult Deformity

Room : *Uskudar*

Moderators: *Todd J. Albert, MD*

Oheneba Boachie-Adjei, MD

8:15 *Paper # 46: Improvement of Segmental Lordosis in Transforaminal Lumbar Interbody Fusion: A Comparison of Two Techniques*
John C. France, MD; James W. Rice, MD; Sanford E. Emery, MD, MBA; Scott D. Daffner, MD

8:19 *Paper # 47: Relationship Between Spino-Pelvic Parameters and QOL in Adult Spinal Deformity in Japanese Patients - Which Factor is Important for Better QOL in Treatment of Adult Spinal deformity?*
Yu Yamato; Yukihiko Matsuyama, MD; Manabu Ito, MD, PhD; Ken Yamazaki, MD; Hiroshi Taneichi, MD; Yutaka Nohara, MD; Morio Matsumoto, MD; Tanaka Masato; Nobumasa Suzuki, MD

8:23 *Paper # 48: The Contribution of Intraoperative Patient Positioning to Overall Correction of Coronal and Sagittal Deformity in Adults*
Michael D. Daubs, MD; Brandon Lawrence, MD; Prokopis Annis, MD; Darrel S. Brodke, MD

8:27 *Discussion*

8:35 *Paper # 49: Impact of Radiographic Parameters on HRQoL in Adult Spinal Deformity. The Lordosis Gap Better than Lumbar Lordosis?*
Ferran Pellise, MD; Montse Domingo-Sabat; Ahmet Alanay; Juan Bago, MD; Alba Vila-Casademunt; Carlos Villanueva, MD, PhD; Azmi Hamzaoglu, MD; Emre Acaroglu, MD

8:39 *Paper # 50: The Comprehensive Anatomical Spinal Osteotomy Classification*
Frank Schwab, MD; Benjamin Blondel, MD; Edward Chay; Jason Demakakos; Lawrence G. Lenke, MD; Patrick Tropiano, MD; Christopher P. Ames, MD; Justin S. Smith, MD, PhD; Christopher I. Shaffrey, MD; Steven D. Glassman, MD; Robert W. Gaines, MD; Jean-Pierre C. Farcy, MD; Virginie Lafage, PhD

8:43 *Paper # 51: Weight Change and Clinical Outcomes Following Adult Spinal Deformity Surgery in Overweight and Obese Patients*
Addisu Mesfin, MD; Lawrence G. Lenke, MD; Keith H. Bridwell, MD; Jeremy L. Fogelson, MD; Stuart Hershman, MD; Han Jo Kim, MD; Linda Koester, BS

† = Whitecloud Award Nominee – Best Clinical Paper * = Whitecloud Award Nominee – Best Basic Science Paper

MEETING AGENDA

- 8:47 Discussion
- 8:55 Paper # 52: Comparison of Pulmonary Function in Adults Younger and Older than Age 60 Undergoing Spinal Deformity Surgery
Ronald A. Lehman, MD; Daniel G. Kang, MD; Lawrence G. Lenke, MD; Jeremy J. Stallbaumer, MD; Brenda A. Sides, MA
- 8:59 Paper # 53: Analysis of Health Related Quality of Life Improvements among Patients with Adult Spinal Deformity
Michael F. O'Brien, MD; Richard Hostin, MD; Ian McCarthy, PhD; Neil Fleming, PhD; Gerald Ogola; Rustam Kudyakov, MD, MPH; Kathleen M. Richter, MS, MFA, ELS; Rajiv Saigal, MD, PhD; Sigurd H. Berven, MD; Vedat Deviren, MD; Christopher P. Ames, MD; International Spine Study Group
- 9:03 Paper # 54: Reoperation Rates and Impact on Outcome in a Large Prospective Multicenter Adult Spinal Deformity Database
Christopher P. Ames, MD; Justin K. Scheer, BS; Justin S. Smith, MD, PhD; Eric Klineberg, MD; Robert A. Hart, MD; Gregory M. Mundis, MD; Douglas C. Burton, MD; Richard Hostin, MD; Michael F. O'Brien, MD; Christopher I. Shaffrey, MD; Shay Bess, MD; Frank Schwab, MD; Khaled Kebaish, MD; Vedat Deviren, MD; International Spine Study Group
- 9:07 Discussion
- Concurrent Session #4B: Trauma/Tumor**
Room : Beylerbeyi
Moderators: Daniel J. Sucato, MD, MS
Muharrem Yazici, MD
- 8:15 Paper # 55: A Randomized Trial of Balloon Kyphoplasty and Non-Surgical Management for Treating Acute Vertebral Compression Fractures
Outcomes Vertebral Body Kyphosis Correction and Surgical Parameters
Douglas Wardlaw, MB, ChB, ChM, FRCSEd
- 8:19 Paper # 56: Non-Neurological Complication Rate Following Surgical Treatment of Vertebral Fracture with Spinal Cord Injury; Does Surgical Timing Matter?
Jean-Marc Mac-Thiong, MD, PhD; Étienne Bourassa-Moreau; Cynthia Thompson, PhD; Stefan Parent, MD, PhD
- 8:23 Paper # 57: Comparison of Results of Surgical Treatments for Osteoporotic Vertebral Collapse
Naobumi Hosogane, MD; Shinjiro Kaneko; Hironobu Watanabe; Kenya Nojiri; Kota Watanabe; Takashi Tsuji; Ken Ishii, MD, PhD; Hitoshi Kono, MD; Masaya Nakamura; Masanobu Shioda; Masafumi Machida, MD; Masashi Saito; Yoshiaki Toyama; Kazuhiro Chiba, MD, PhD; Mario Matsumoto, MD
- 8:27 Discussion
- 8:35 Paper # 58: Perioperative Complications in Open vs. Percutaneous Treatment of Spinal Fractures in Patients with an Ankylosed Spine
Charbel D. Moussallem, MD; Ahmad Nassr, MD; Qunqi Cui, MD; Bradford L. Currier, MD; Michael J. Yaszemski, MD, PhD; Paul M. Huddleston, MD; Peter S. Rose, MD; Mark Pichelmann, MD; Mark B. Dekutoski, MD
- 8:39 Paper # 59: Return to Play and Cervical Spine Injury, What Level of Play and How Soon?
John C. France, MD; Andrew T. Dailey, MD; James S. Harrop, MD
- 8:43 Paper # 60: A Randomised Control Trial of Neurological Outcome with Different Treatment Modalities in Acute Thoracolumbar Spinal Injuries and Complete Paraplegia - A Preliminary Report
Rajeshwar N. Srivastava, MD; Saloni Raj
- 8:47 Discussion
- 8:55 Paper # 61: Survival Analysis of the Spinal Metastases Patients with Different Breast Cancer Subtypes
Miao Wang, MD; Cody E. Bunger; Benny Dahl, MD, PhD, DMSci
- 8:59 Paper # 62: Neurological Function and Survival Outcome of Aarhus Algorithm in Patients with Spinal Solitary Plasmacytoma or Multiple Myeloma
Miao Wang, MD; Cody E. Bunger
- 9:03 Paper # 63: Posterior Column Reconstruction with Titanium Lamina Mesh after Total En bloc Spondylectomy of Spinal Tumor
Jae Yoon Chung; Hyoung-Yeon Seo, MD; Sung-Kyu Kim; Whoan Jeang Kim
- 9:07 Discussion

MEETING AGENDA

† = Whitecloud Award Nominee – Best Clinical Paper * = Whitecloud Award Nominee – Best Basic Science Paper

Debate #3: Optimal Treatment for a 13-Year-Old, 6-Month Post-Menarchal Elite Soccer Player with a 45-Degree Thoracic, 40-Degree Lumbar Lenke 3C Scoliosis

Room: *Camlica*

Moderator: *Azmi Hamzaoglu, MD*

8:15 Optimal Treatment is Observation
Paul D. Sponseller, MD

8:25 Optimal Treatment is Selective (Thoracic Only) Posterior Instrumentation
B. Stephens Richards, III, MD

8:35 Optimal Treatment is Fusion of Both Curves
Peter O. Newton, MD

Debate #4: Optimal Treatment for 22-Year-Old with a T-12 Burst Fracture, 60% Canal Compromise and 25-Degrees of Kyphosis and No Neurological Deficit

Room: *Camlica*

Moderator: *Ziya L. Gokaslan, MD*

8:45 Optimal Treatment is Observation with Bracing or Casting
Brian K. Kwon, MD, PhD, FRCSC

8:55 Optimal Treatment is Open Surgery
Christopher P. Ames, MD

9:05 Optimal Treatment is MIS Instrumentation and Fusion
D. Greg Anderson, MD

9:15 – 9:30 Walking Break

9:30 – 10:30 Instructional Course Lectures 3A-D

3A: Lumbar Posterior Fusion Options/Instrumentation (Degenerative)

Room: *Emirgan 1*

Moderator: *Steven D. Glassman, MD*

9:30 When is Circumferential Fusion Better than Posterolateral Fusion?
Sigurd H. Berven, MD

9:42 Surgical Intervention for Degenerative Disc Disease: When is it Warranted?
John R. Dimar, II, MD

9:54 Is There Still a Role For Lumbar Disc Arthroplasty?
Henry F.H. Halm, MD

10:06 Economics of Lumbar Fusion: How Does it Compare with Other Common Surgical Procedures?
Steven D. Glassman, MD

10:18 Discussion and/or Cases

† = Whitecloud Award Nominee – Best Clinical Paper * = Whitecloud Award Nominee – Best Basic Science Paper

MEETING AGENDA

3B: Thoracolumbar Trauma*Room: Emirgan 2**Moderator: F. Chumhur Oner, MD, PhD*

9:30 Update on Thoracolumbar Classification Systems: Do They Impact Treatment and Prognosis?

F. Chumhur Oner, MD, PhD

9:42 Thoracolumbar Decompressive Techniques: When Anterior, When Posterior, When Combined?

Praveen V. Mummaneni, MD

9:54 Reconstruction Techniques for Post-Traumatic Kyphosis

Christopher I. Shaffrey, MD

10:06 MIS Applications for Thoracolumbar Spine Trauma

D. Greg Anderson, MD

10:18 Discussion and/or Cases

3C: Adult Deformity III: Decision Making Relative to Extension to the Sacrum Pelvis*Room: Beylerbeyi**Moderator: Frank J. Schwab, MD*

09:30 Indications of Extending Fusions to the Sacrum/Pelvis: When Can I Spare it and When do I Include It?

Tyler Koski, MD

09:42 Spino-Pelvic Parameters: How do They Affect my Decision Relative to Extension to the Sacrum

Frank J. Schwab, MD

09:54 Fusion Options at the Lumbo-Sacral Junction: Approach, Graft Type, Interbody Support

Oheneba Boachie-Adjei, MD

10:06 Sacro-Pelvic Fixation: Options, Techniques and Complications

Hilali H. Noordeen, FRCS

10:18 Discussion and/or Cases

3D: Early Onset Scoliosis II*Room: Camlica**Moderator: Richard E. McCarthy, MD*

09:30 Indications for Tether and Staple-Based Surgery

Suken A. Shah, MD

09:42 Indications for Growing Rod Surgery

Behrooz A. Akbarnia, MD

09:54 VEPTR and Shilla: Indications for Each Technique

Yong Qiu, MD

10:06 Promising New Technology for the Treatment of EOS

Muharrem Yazici, MD

10:18 Discussion and/or Cases

10:30 – 10:45 Walking Break

MEETING AGENDA

† = Whitecloud Award Nominee – Best Clinical Paper * = Whitecloud Award Nominee – Best Basic Science Paper

10:45 – 11:45 Concurrent Sessions & Complications Series

Concurrent Session #5A: Cervical Spine

Room : *Uskudar*

Moderators: *Christopher P. Ames, MD*
Kenneth M C Cheung, MD

- 10:45 Paper # 64: Cervical Alignment Parameters as Part of Global Sagittal Balance
Jayne R. Hiratzka, MD; Michael D. Daubs, MD; Prokopis Annis, MD; Justin B. Hohl, MD; Brandon Lawrence, MD; Darrel S. Brodke, MD
- 10:49 Paper # 65: The Impact of Standing Regional Cervical Sagittal Alignment on Outcomes in Posterior Cervical Fusion Surgery
Jessica A. Tang, BS; Justin K. Scheer, BS; Justin S. Smith, MD, PhD; Vedat Deviren, MD; Shay Bess, MD; Robert A. Hart, MD; Virginie Lafage, PhD; Christopher I. Shaffrey, MD; Frank Schwab, MD; Christopher P. Ames, MD
- 10:53 Paper # 66: The Crucial Role of Cervical Alignment in Regulating Sagittal Spino-Pelvic Alignment in Human Standing Posture
Benjamin Blondel, MD; Frank Schwab, MD; Christopher P. Ames, MD; Jean-Charles Le Huec, MD, PhD; Justin S. Smith, MD, PhD; Christopher I. Shaffrey, MD; Shay Bess, MD; Jason Demakakos; Bertrand Moal, Master of Science; Patrick Tropiano, MD; Jean-Pierre C. Farcy, MD; Virginie Lafage, PhD
- 10:57 Discussion
- 11:05 Paper # 67: Concomitance of Adult Spinal Deformity and Cervical Spondylosis
William Schairer; Alexandra Carrer, MD; Kyle A. Mitsunaga, MD; Michael Lu, MD; Sigurd H. Berven, MD; Vedat Deviren, MD; Dean Chou, MD; Bobby Tay, MD; Christopher P. Ames, MD; Serena S. Hu, MD
- 11:09 Paper # 68: Scoliosis with Cervical Spine Pathologies
Mehmet B. Balioglu, MD; Can H. Yildirim, MD; Erol - Tasdemiroglu; Aytac Akbasak, MD
- 11:13 Paper # 69: Radiological and Clinical Outcome of the Operated and Adjacent Segments Following Cervical Arthroplasty after a Minimum 24-Month Follow-Up: A Single Surgeon-Center Experience
Murat Sirickci; Meric Enercan; Sinan Kahraman; Mercan Sarier; Ibrahim Ornek; Levent Ulusoy; Alauddin Kochai; Cagatay Ozturk, MD; Ahmet Alanay; Azmi Hamzaoglu, MD
- 11:17 Discussion
- 11:25 Paper # 70: Lessons Learned on Cervical Total Disc Replacement after Eight Years Follow-Up
Luis Marchi, MSc; Leonardo Oliveira, BSc; Rodrigo A. Amaral; Carlos A. Castro; Thiago Coutinho; Etevaldo Coutinho; Luiz Pimenta, MD, PhD
- 11:29 Paper # 71: Anterior Cervical Discectomy and Fusion vs. Cervical Disc Arthroplasty: Cost-Utility Analysis-Based on an Institutional Financial Data Economic Model
Tate M. Andres, BS; Daniel T. Warren, MD; Pedro A. Ricart Hoffiz, MD, MS; Christian Hoelscher, BS; Virginie Lafage, PhD; Jeffrey A. Goldstein, MD; John A. Bendo, MD
- 11:33 Paper # 72: Does Cervical Disc Arthroplasty Reduce Adjacent Segment Disease and Other Complications in Comparison to Anterior Cervical Discectomy and Fusion? A Meta-Analysis of Randomized Controlled Trials
Dino Samartzis, DSc, PhD (C), MSc; Patrick Vavken; Hitesh N. Modi, MS, PhD; Keith D. Luk, MD; Kenneth M. Cheung, MBBS(UK), FRCS(England), FHKCOS, FHKAM(Orth)
- 11:37 Discussion

Concurrent Session #5B: Lumbar Degenerative/Spondylolisthesis

Room : *Beylerbeyi*

Moderators: *Mark B. Dekutoski, MD*
Mark Weidenbaum, MD

- 10:45 Paper # 73: A Randomized Control Trial Evaluating Effectiveness of a Synthetic B2A Peptide in Achieving Lumbar Interbody Fusion: Twelve-Month Results of a Multicenter, Blinded Canadian Study
Zeeshan Sardar, MD, CM; Peter Jarzem, MD; Eugene K. Wai, MD, MSc, CIP, FRCS(C); D. Greg Anderson, MD
- 10:49 Paper # 74: Two Year Bone Morphogenetic Protein Clinical Effects after Lumbar Fusion in Degenerative Disc Disease
Andriy Nashchenko, PhD; Evalina L. Burger, MD; Christopher M. Cain, MD; Emily M. Lindley, PhD; Vikas V. Patel, MD
- 10:53 Paper # 75: Can Decompression Surgery Relieve Low Back Pain in Patients with Lumbar Spinal Stenosis Combined with Degenerative Lumbar Scoliosis?
Ryohei Kagotani, MD; Shunji Tsutsui; Hiroshi Yamada, MD, PhD; Hiroshi Hashizume, MD, PhD; Akihito Minamide, MD, PhD; Yukihiko Nakagawa, MD, PhD; Masaki Kawai, MD; Hiroshi Iwasaki, MD; Keiji Nagata; Yuyu Ishimoto; Munehito Yoshida

† = Whitecloud Award Nominee – Best Clinical Paper * = Whitecloud Award Nominee – Best Basic Science Paper

MEETING AGENDA

- 10:57 Discussion
- 11:05 Paper # 76: National Trends in the Use of Interbody Fusion Techniques to Treat Degenerative Spondylolisthesis: Data from the American Board of Orthopaedic Surgeons (ABOS)
Christopher K. Kepler, MD, MBA; Alexander R. Vaccaro, MD, PhD; Alan S. Hilibrand, MD; D. Greg Anderson, MD; Jeffrey A. Rihn, MD; Todd J. Albert, MD; Kris Radcliff, MD
- 11:09 Paper # 77: Predictive Factors for the Use of Cell Saver Infusion in Lumbar Spinal Surgery
Roger K. Owens, MD; Charles H. Crawford, MD; Mladen Djurasovic, MD; Chelsea E. Canan, MPH; Lauren O. Burke, MPH; Kelly R. Bratcher, RN, CCRP; Kathryn J. McCarthy, MD; Leah Y. Carreon, MD, MSc
- 11:13 Paper # 78: Differentiating Minimum Clinically Important Difference for Primary and Revision Lumbar Fusion Surgeries
Leah Y. Carreon, MD, MSc; Mladen Djurasovic, MD; Kelly R. Bratcher, RN, CCRP; Chelsea E. Canan, MPH; Lauren O. Burke, MPH; Steven D. Glassman, MD
- 11:17 Discussion
- 11:25 Paper # 79: Lumbar Arthrodesis Instrumentation with and without Postoperative Brace
Hani Mhaidli, MD, PhD; Tito Fernandez
- 11:29 Paper # 80: Spinal Instrumentation Surgery for Diabetes Patients: Predisposing Factors for Surgical Site Infection
Kotaro Satake, MD; Tokumi Kanemura, MD; Akiyuki Matsumoto; Yoshimoto Ishikawa
- 11:33 Paper # 81: Fusion vs. Non-Fusion Technology for Meyerding Grade I Degenerative Spondylolisthesis Patients: Four-Year Follow-Up Outcomes
Justin Boey; Benjamin Tow, MBBS, MMED(Orth), FRCS (Orth)
- 11:37 Discussion

Complications Series: My Worst Complication in AIS and Strategies to Prevent

Room: *Camlica*
 Moderator: *B. Stephens Richards, III, MD*
 Faculty: *Lawrence G. Lenke, MD*
Peter O. Newton, MD
Kamal N. Ibrahim, MD, FRCS(C), MAO
Paul D. Sponseller, MD

11:45 – 12:00 Walking Break

12:00 – 13:00 Roundtable Case Discussions

Lumbar Degenerative

Room: *Emirgan 1*
 Moderator: *John R. Dimar, II, MD*
 Panelists: *Luiz Henrique Pimenta, MD, PhD*
D. Greg Anderson, MD

Pediatric Deformity

Room: *Emirgan 2*
 Moderator: *Ahmet Alanay, MD*
 Panelists: *David S. Marks, FRCS*
Sean Molloy, MBBS, MSc, FRCS
Francisco Javier Sanchez Perez-Gruoso, MD

Adult Deformity

Room: *Beylerbeyi*
 Moderator: *Tyler Koski, MD*
 Panelists: *Sigurd H. Berven, MD*
Steven D. Glassman, MD
Frank J. Schwab, MD

MEETING AGENDA

† = Whitecloud Award Nominee – Best Clinical Paper * = Whitecloud Award Nominee – Best Basic Science Paper

Tumor / Trauma / Infection

Room: Camlica
 Moderator: Michael J. Yaszemski, MD, PhD
 Panelists: Jacob M. Buchowski, MD, MS
 Ziya L. Gokaslan, MD
 Azmi Hamzaoglu, MD

Cervical Reconstruction

Room: Hamidiye
 Moderator: K. Daniel Riew, MD
 Panelists: Todd J. Albert, MD
 Michael G. Fehlings, MD, PhD, FRCSC, FACS
 Justin S. Smith, MD, PhD
 Vincent Traynelis, MD

13:00 – 13:45 Lunch & Exhibit Viewing

Room: B2 Foyer

13:10 – 13:45 SRS Membership Information Session

Room: Beylerbeyi
 Join us and learn more about the Scoliosis Research Society.

- How to Apply
- Membership Requirements
- Benefits of Membership
- Leadership Opportunities
- Scholarships
- Networking
- Education

A Q&A segment will follow the presentation.

Speakers: Steven D. Glassman, MD, Vice President
 Carlos Tello, MD, Fellowship Committee Chair

13:45 – 14:45 Instructional Course Lectures 4A-D

4A: Infection and Post-Infectious Deformity

Room: Emirgan 1
 Moderator: Kenneth MC Cheung, MD

13:45 Preventing Postoperative Spinal Wound Infections – What Does the Evidence Show?
 Hilali H. Noordeen, FRCS

13:57 Current Management of Spinal Tuberculosis
 Azmi Hamzaoglu, MD

14:09 Deep Wound Infection Following Spinal Instrumentation: Best Management
 Justin S. Smith, MD, PhD

14:21 Postinfectious Thoracolumbar Spinal Deformity: Principles of Surgical Management
 Kenneth M C Cheung, MD

14:33 Discussion and/or Cases

† = Whitecloud Award Nominee – Best Clinical Paper * = Whitecloud Award Nominee – Best Basic Science Paper

MEETING AGENDA

4B: Cervical Spinal Cord and Spinal Column Injury: State of the Art

Room: *Emirgan 2*

Moderator: *Michael G. Fehlings, MD, PhD, FRCSC, FACS*

13:45 *The Impact of Timing of Surgical Intervention on Outcome*
Michael G. Fehlings, MD, PhD, FRCSC, FACS

13:57 *Current and Future Direction in Pharmacological Intervention*
Brian K. Kwon, MD, PhD, FRCSC

14:09 *Anterior vs. Posterior Approach for Cervical Facet Dislocation*
Vincent Traynelis, MD

14:21 *Evaluation and Management of Hyperextension Injuries in Patients with DISH and AS*
K. Daniel Riew, MD

14:33 Discussion and/or Cases

4C: Adult Deformity IV: MIS Alternatives in Adult Deformity

Room: *Beylerbeyi*

Moderator: *Mark Weidenbaum, MD*

13:45 *Pre-Operative Planning and Robotic Guidance for Deformity Surgery*
J. Abbott Byrd, III, MD

13:57 *Minimally Invasive Lateral and Trans-Sacral Techniques for Deformity Correction*
Neel Anand, MD

14:09 *MIS, Mini-Open and Open Surgery: How to Choose?*
Mark B. Dekutoski, MD

14:21 *MIS Sagittal Deformity Correction: Theoretical to Practical*
Behrooz A. Akbarinia, MD

14:33 Discussion and/or Cases

4D: Adolescent Idiopathic Scoliosis II: Correction Techniques for Simple to Severe Curves

Room: *Camlica*

Moderator: *Suken A. Shah, MD*

13:45 *Tried and True: Compression, Distraction, Translation, Rod Rotation*
Francisco Javier Sanchez Perez-Gruoso, MD

13:57 *Posterior Releases & Sagittal Plane Restoration for Kyphotic Conditions*
Daniel J. Sucato, MD, MS

14:09 *Techniques to Reduce Blood Loss During Major Deformity Corrections*
Emre R. Acaroglu, MD

14:21 *Vertebral Column Resection*
Lawrence G. Lenke, MD

14:33 Discussion and/or Cases

14:45 – 15:00 Walking Break

15:00 – 16:00 Hands-On Workshops with Cocktails & Snacks (See "Exhibits and Hands-On Workshops section on page 190-191 for more information.)

MEETING AGENDA

† = Whitecloud Award Nominee – Best Clinical Paper * = Whitecloud Award Nominee – Best Basic Science Paper

SATURDAY, JULY 21, 2012

7:00 – 13:50

Registration Open
Exhibits Closed

8:00 – 8:15

Walking Break

8:15 – 9:15

Instructional Course Lectures 5A-D

5A: The Osteoporotic Spine: Fixation Challenges and Solutions

Room: *Emirgan 1*

Moderator: *Michael J. Yaszemski, MD, PhD*

8:15 *Fixation Problems in the Osteoporotic Spine*
Ian J. Harding, BA, FRCS (Orth)

8:27 *Biomechanical Evaluation and Instrumentation Strategies*
Sigurd H. Berven, MD

8:39 *New Technologies for Osteoporotic Fixation*
Justin S. Smith, MD, PhD

8:51 *The Medical Management of Osteoporosis*
Michael J. Yaszemski, MD, PhD

9:03 Discussion and/or Cases

5B: Cervical Degenerative Techniques

Room: *Emirgan 2*

Moderator: *Todd J. Albert, MD*

8:15 *Timing and Type of Surgical Intervention for Central Cord Injury*
Michael G. Fehlings, MD, PhD, FRCSC, FACS

8:27 *Indications for Cervical Arthroplasty in Cervical Degeneration*
Vincent Traynelis, MD

8:39 *Surgical Approach Selection for Cervical Spondylotic Myelopathy*
Todd J. Albert, MD

8:51 *Management of Cervical Kyphotic Deformity*
K. Daniel Riew, MD

9:03 Discussion and/or Cases

5C: Principles and Practice in the Treatment of Metastatic Spine Disease

Room: *Beylerbeyi*

Moderator: *Ziya L. Gokaslan, MD*

8:15 *Radiation Therapy, Stereotactic Radiation Therapy and Surgery: How to Choose*
Mark B. Dekutoski, MD

8:27 *Classification of Spinal Metastatic Disease: When Should Surgery be Performed?*
Christopher I. Shaffrey, MD

8:39 *Role for MIS Treatment of Spinal Metastatic Disease*
Praveen V. Mummaneni, MD

8:51 *Role for Complete Spondylectomy in Metastatic Disease*
Ziya L. Gokaslan, MD

9:03 Discussion and/or Cases

† = Whitecloud Award Nominee – Best Clinical Paper * = Whitecloud Award Nominee – Best Basic Science Paper

MEETING AGENDA

5D: Adolescent Idiopathic Scoliosis IIIRoom: *Camlica*Moderator: *Daniel J. Sucato, MD, MS*8:15 *Anterior vs. Posterior Indications for AIS Surgery**David S. Marks, FRCS*8:27 *Is There Still a Role for Anterior Surgery in AIS?**Peter O. Newton, MD*8:39 *MIS Approaches for AIS**Mark Weidenbaum, MD*8:51 *Use of Posterior Pedicle Screws and DVR for AIS**Francisco Javier Sanchez Perez-Grueso, MD*9:03 *Discussion and/or Cases*9:15 – 9:30 **Walking Break**9:30 – 11:30 **Concurrent Sessions & Complications Series****Concurrent Session #6A: Innovative & Diagnostic Methods**Room : *Uskudar*Moderators: *Sean Molloy, MBBS, MSc, FRCS, DC**Michael J. Yaszemski, MD, PhD*9:30 *Paper # 82: Comparison of Direct Pars Repair Techniques of Spondylolysis: Pedicle Screw-Rod- Hook vs. Laminar Pars Compression Screw**Ali F. Karatas; Alfred Aranda, MD; Laurens Holmes, PhD, DrPH; Kenneth J. Rogers, PhD; Peter G. Gabos, MD; Suken A. Shah, MD*9:34 *Paper # 83: Superior Articulating Facet Violation: Percutaneous vs. Open Techniques**Sean M. Jones-Quaidoo, MD; Mladen Djurasovic, MD; Roger K. Owens, MD; Leah Y. Carreon, MD, MSc*9:38 *Paper # 84: Outcomes in Minimally Disruptive Lateral Interbody Fusion: 24- Month Minimum Follow-Up in 268 Patients**William B. Rodgers, MD; Edward J. Gerber, PA-C; Jeff A. Lehmen, MD; Jody A. Rodgers, MD, FACS; William D. Smith, MD*9:42 *Discussion*9:50 *Paper # 85: Use of Robotic Assisted Pedicle Screw Placement in Deformity and Revision Spine Surgery**Isador Lieberman, MD, MBA, FRCS; Xiaobang Hu, PhD*9:54 *Paper # 86: Minimally Invasive Lateral Interbody Fusion in the Morbidly Obese**William D. Smith, MD; William B. Rodgers, MD; Edward J. Gerber, PA-C; Jeff A. Lehmen, MD; Jody A. Rodgers, MD, FACS*9:58 *Paper # 87: Fluid Resuscitation using Enteral Route is a Safe and Effective Alternative to Parental Resuscitation in Patients Undergoing Major Elective Surgery**Kavita Baghel, MSc; Saloni Raj; Abhijit Chandra, MD; Rajeshwar N. Srivastava, MD*10:02 *Discussion*10:10 *Paper # 88: A New Thoracic Reconstruction Technique "Transforaminal Thoracic Interbody Fusion (TTIF)"**Yasutsugu Yukawa, MD; Fumihiko Kato, MD; Keigo Ito; Masaaki Machino; Shunsuke Kanbara; Daigo Morita*10:14 *Paper # 89: A Novel Rod Link Reducer System Provides Stability and Ease of Correction during Posterior Vertebral Column Resection in an Angular Kyphosis In-Vivo Pig Model**Hong Zhang, MD; Daniel J. Sucato, MD, MS; David Ross, MFA; Karen D. Standefer, BS; Xuhui Zhou, MD*10:18 *Paper # 90: Long Posterior Spinopelvic Fusions using Single vs. Multiple-Screw Iliac Constructs in Major Scoliotic Deformities. The Challenge of Ambulatory Patients**Jesús J Burgos Flores, PhD; Eduardo Hevia, MD; Luis Miguel Antón-Rodrigálvarez, PhD; Carlos Barrios, MD, PhD*

MEETING AGENDA

† = Whitecloud Award Nominee – Best Clinical Paper * = Whitecloud Award Nominee – Best Basic Science Paper

- 10:22 Discussion
- 10:30 Paper # 91: 3D Kinematic Analysis of Regional Chest Wall Motion and Volume Changes During Respiration in Healthy Children
Patrick K. Do, MD; Lee A. Taylor, MD; Jing Feng, PhD; Rosemary Pierce, BS; Michael Aiona, MD; Charles R. d'Amato, MD, FRCS
- 10:34 Paper # 92: Hybrid Vertebral Body Augmentation (KIVA) Plus Short Pedicle Screw Instrumentation with MIS for Fresh Thoracolumbar Burst and Severe Compression Fractures
Panagiotis Korovessis, MD, PhD; Thomas Repantis, MD, PhD; Vasilis Vitsas, MD; Konstantinos Vardakastanis
- 10:38 Paper # 93: Accuracy of Intraoperative CT-Based Navigation for Placement of Percutaneous Pedicle Screws
Jason C. Eck, DO, MS; Jeffrey Lange, MD; John Street, MD, PhD; Anthony S. Lapinsky, MD; Patrick J. Connolly, MD; Christian P. DiPaola, MD
- 10:42 Discussion
- 10:50 Paper # 94: MRI in Spinal Trauma - A Predictor of Neurological Recovery?
Rajeshwar N. Srivastava, MD; Umesh Parashri
- 10:54 Paper # 95: Better Understanding Postoperative Changes in Adolescent Idiopathic Scoliosis using 3D Reconstructions of 2D Radiographs
Krishna Cidambi, MD; Shoji Seki, MD; Carrie E. Bartley, MA; Maty Petcharaporn, BS; Burt Yaszay, MD; Peter O. Newton, MD
- 10:58 Paper # 96: In Vivo Assessment of Mechanotransduction of AIS patients
Guaruey Wong, BSc, MSc; Carl-Eric Aubin, PhD, PEng; Alain Moreau, PhD
- 11:02 Discussion
- 11:10 Paper # 97: Assessment of Skeletal Maturity: A New Classification Scheme Using Distal Radius and Ulna Radiographs
Keith D. Luk, MD; Lim Beng Saw, MS Orth; Samuel Grozman, MD; Kenneth M. Cheung, MBBS(UK), FRCS(England), FHKCOS, FHKAM(Orth); Dino Samartzis, DSc, PhD (C), MSc
- 11:14 Paper # 98: Measurement Discrepancy of Sagittal Parameters Between Plain Radiography and 3D CT in Thoracolumbar and Lumbar Fractures
Yong Min Kim, MD, PhD; Seung Myung Choi, MD; Dong Soo Kim
- 11:18 Paper # 99: How Many Motor Pathways to the Target Muscle can be Monitored by Transcranial Motor Evoked Potentials during Spinal Surgery?
Shunji Tsutsui; Hiroshi Yamada, MD, PhD; Hiroshi Hashizume, MD, PhD; Akihito Minamide, MD, PhD; Yukihiko Nakagawa, MD, PhD; Masaki Kawai, MD; Hiroshi Iwasaki, MD; Ryohei Kagotani, MD; Masatoshi Teraguchi, MD; Munehito Yoshida
- 11:22 Discussion

Concurrent Session #6B: Kyphosis/Congenital/Neuromuscular Deformity

Room : *Beylerbeyi*

Moderators: *Jacob M. Buchowski, MD, MS*
Francisco J. Sanchez Perez-Grueso, MD

- 9:30 Paper # 100: National Trends, Hospital Costs and Complications of Spinal Fusion for Scheuermann's Kyphosis: Analysis of 2,796 Patients
Amit Jain; Paul D. Sponseller, MD; Addisu Mesfin, MD
- 9:34 Paper # 101: Neurological Recovery in Patients of Old Healed Tubercular Rigid Kyphosis with Myelopathy Treated with Transpedicular Decancellation Osteotomy (TDO)
Saumyajit Basu, MD; Sreeramalingam Rathinavelu, MS; Jay D. Ghosh, MBBS, MS(Ortho); Agnivesh Tikoo, MS (Ortho); Amitava Biswas, MS (Orth)
- 9:38 Paper # 102: Guidelines for Choosing the Lower Instrumented Vertebra in Scheuermann's Kyphosis: Revisited
Muayad Kadhim, MD; Suken A. Shah, MD; Baron S. Lonner; Harry L. Shufflebarger, MD; Paul D. Sponseller, MD; Peter O. Newton, MD; Harms Study Group
- 9:42 Discussion
- 9:50 Paper # 103: Scheuermann's Kyphosis: What Patient Factors Cause Transition from Non-Operative to Surgical Management?
David W. Polly, MD; Beverly E. Diamond, PhD; Charles Gerald T. Ledonio, MD; Hubert Labelle, MD; Daniel J. Sucato, MD, MS; John B. Emans, MD; Michael T. Hresko, MD; Michael G. Vitale, MD, MPH; A. Noelle Larson, MD
- 9:54 Paper # 104: Key Radiographic Parameters Correlate to Life Quality with Sagittal Imbalance in AS Kyphosis
Yonggang Zhang, PhD; Kai Song
- 9:58 Paper # 105: Sagittal Spinopelvic Parameters in Scheuermann's Kyphosis: A Preliminary Study
Patrick J. Cahill, MD; Baron S. Lonner; Peter O. Newton, MD; Suken A. Shah, MD; Amer F. Samdani, MD; Paul D. Sponseller, MD; Harry L. Shufflebarger, MD

† = Whitecloud Award Nominee – Best Clinical Paper * = Whitecloud Award Nominee – Best Basic Science Paper

MEETING AGENDA

- 10:02 Discussion
- 10:10 Paper # 106: Segmental Spinal Dysgenesis. A Report of 13 Cases
Rodrigo G. Remondino, MD; Carlos A. Tello, MD; Ernesto Bersusky, MD; Alejandra Francheri, MD; Mariano A. Noel, MD; Eduardo Galaretto, MD
- 10:14 Paper # 107: Occipital-Cervical Instability in Morquio-Brailsford's Disease (MPSIV): A Cohort of 16 Patients Treated in the SpineHope/Casa de Colombia Global Outreach Clinic
Matthew J. Geck, MD; Craig A. Kuhns, MD; Steven M. Mardjetko, MD, FAAP; Anthony S. Rinella, MD; Devender Singh, PhD
- 10:18 Paper # 108: The Four Rib Construct for Severe Early Onset Thoracic Kyphosis
AlaaEldin A. Ahmad, MD; Zeke J. Walton, MD; Richard H. Gross, MD
- 10:22 Discussion
- 10:30 Paper # 109: Posterior Only Spinal Fusion without Rib Head Resection in Treating Type I Neurofibromatosis with Intra-Canal Rib Head Dislocation
Jianzhong Xu, MD; Dong Sun, PhD; Fei Dai
- 10:34 Paper # 110: Use of Sublaminar Polyester Bands in Treatment of Neuromuscular Scoliosis
Michael C. Albert, MD
- 10:38 Paper # 111: One-Stage Posterior Surgery Assisted with Halo-Femoral Traction for the Treatment of Scoliosis with Chiari I Malformation
Hongqi Zhang, MD; Mingxing Tang; Shaohua Liu; Yuxiang Wang, MD
- 10:42 Discussion
- 10:50 Paper # 112: Scoliosis Surgery in Rett Syndrome - Can We Monitor These Patients and What Complications They Get?
Tim Hammett, MRCS; Anna Harris; Ben Boreham, MB, BCh, FRCS(Orth); Hossein Mehdian, MD, MS(Orth), FRCS(Ed)
- 10:54 Paper # 113: Gastrointestinal Complications after Surgical Correction of Neuromuscular Scoliosis
Tuomas Jalanko, MD; Antti Koivusalo, MD, PhD; Katariina Korhonen; Mikko P. Pakarinen, MD, PhD; Päivi M. Salminen; Risto Rintala; Ilkka Helenius, MD, PhD
- 10:58 Paper # 114: Is Curve Direction Correlated with the Side of Dominant Displacement of Cerebellar Tonsil and Syrinx Deviation in Thoracic Scoliosis Secondary to Chiari Malformation Type I and Syringomyelia?
Ze Zhang Zhu; Tao Wu; Xu Sun; Yang Yu; Xin Zhen; Bangping Qian; Feng Zhu; Yong Qiu
- 11:02 Discussion
- 11:10 Paper # 115: Prevalence of Complications in Neuromuscular Scoliosis Surgery. A Meta-Analysis of the Literature From the Last 15 Years
Shallu Sharma, MPT; Thomas Andersen, MD, PhD; Ebbe S. Hansen, MD, DMSc; Cody E. Bunger; Efe L. Aras
- 11:14 Paper # 116: Longitudinal Analysis of Radiation Exposure During the Course of Growing Rod Treatment for Early Onset Scoliosis
Gregory M. Mundis, MD; Edward K. Nomoto, MD; Michael W. Hennessy, MD; Jeff Pawelek; Burt Yaszay, MD; Behrooz A. Akbarnia, MD
- 11:18 Paper # 117: Vertebral Body Stapling for Juvenile and Early Adolescent Idiopathic Scoliosis: Indications, Results, and Complications
David B. Bumpass, MD; Sara K. Fuhrhop, BS; Scott J. Luhmann, MD
- 11:22 Discussion

Complications Series: My Worst Complication in Adult Deformity and Strategies to Prevent

Room: *Camlica*
 Moderator: *Sigurd H. Berven, MD*
 Faculty: *Christopher I. Shaffrey, MD*
 Tyler Koski, MD
 David W. Polly, Jr., MD
 Christopher P. Ames, MD

Complications Series: My Worst Complication in Tumor Surgery and Strategies to Prevent

Room: *Camlica*
 Moderator: *Kenneth M C Cheung, MD*
 Faculty: *Ziya L. Gokaslan, MD*
 Michael J. Yaszemski, MD, PhD
 Michael G. Fehlings, MD, PhD, FRCS, FACS
 Jacob M. Buchowski, MD, MS

MEETING AGENDA

† = Whitecloud Award Nominee – Best Clinical Paper * = Whitecloud Award Nominee – Best Basic Science Paper

11:30 – 11:45 Walking Break

11:45 – 13:50 General Session #7: Mixed Meeting Highlights

The general sessions are supported, in part, by a grant from Medtronic.

Room: *Uskudar*

Moderators: *Christopher I. Shaffrey, MD
Justin S. Smith, MD, PhD*

11:45 Whitecloud Award Presentation

11:50 Paper # 118: Pulmonary Function Following Adult Spinal Deformity Surgery: Minimum Two-Year Follow-Up
Ronald A. Lehman, MD; Daniel G. Kang, MD; Lawrence G. Lenke, MD; Jeremy J. Stallbaumer, MD; Brenda A. Sides, MA

11:54 Paper # 119: Perioperative Complications of Pedicle Subtraction Osteotomy
Michael D. Daubs, MD; Prokapis Annis, MD; Brandon Lawrence, MD; Darrel S. Brodke, MD

11:58 Paper # 120: Outcomes and Complications of Sacro-Pelvic Fixation Using S2 Alar-Iliac (S2AI) Fixation in Adult Deformity Patients Fused to the Sacrum: A Prospective Study with Minimum 2-Year Follow-Up
Khaled Kebaish, MD; Mostafa H. El Dafrawy, MD; Hamid Hassanzadeh, MD; Philip Neubauer, MD; Roosevelt Offoha; Eric W. Tan, MD; Paul D. Sponseller, MD

12:02 Discussion

12:10 Paper # 121: Preliminary Experience with Clinical Use of a DNA Prognostic Test for Adolescent Idiopathic Scoliosis in 234 Patients
Suken A. Shah, MD; Petya Yorgova, MS; Geraldine I. Neiss, PhD; Peter G. Gabos, MD; J. Richard Bowen, MD

12:14 Paper # 122: Revision vs. Primary Vertebral Column Resection for Severe Spinal Deformities
Yasushi Oshima, MD, PhD; Lawrence G. Lenke, MD; Linda Koester, BS

12:18 Paper # 123: Modified Lenke Classification System for Infantile and Juvenile Idiopathic Scoliosis
Takuya Mishiro, MD, PhD; Lawrence G. Lenke, MD; Linda Koester, BS; Keith H. Bridwell, MD; Scott J. Luhmann, MD

12:22 Discussion

12:30 Paper # 124: Prevalence and Risk Factors for Proximal Junctional Kyphosis Following Realignment Surgery by Pedicle Subtraction Osteotomy: A Multicenter Review
Virginie Lafage, PhD; Frank Schwab, MD; Christopher P. Ames, MD; Bertrand Moal, MS; Richard Hostin, MD; Praveen V. Mummaneni, MD; Khaled Kebaish, MD; Justin S. Smith, MD, PhD; Vedat Deviren, MD; Christopher I. Shaffrey, MD; Eric Klineberg, MD; Aaron R. Ducoffe, BS; Shay Bess, MD; International Spine Study Group

12:34 Paper # 125: Identification of Decision Criteria for Revision Surgery among Patients with Acute Proximal Junctional Failure following Surgical Treatment for Spinal Deformity
Richard Hostin, MD; Michael F. O'Brien, MD; Ian McCarthy, PhD; Christopher P. Ames, MD; Khaled Kebaish, MD; Douglas C. Burton, MD; Virginie Lafage, PhD; Frank Schwab, MD; Christopher I. Shaffrey, MD; Justin S. Smith, MD, PhD; Kirkham B. Wood, MD; Robert A. Hart, MD; Breton Line, BSME; Vedat Deviren, MD; International Spine Study Group

12:38 Paper # 126: Can Minimally Invasive Surgical Strategies for Deformity Correction Avoid the Need for Routine Osteotomies in Moderate to Severe (>50 degrees) Adult Scoliosis?
Neel Anand, MD; Babak Khandehroo, MD; Sheila Kahwaty, PA-C; Eli Baron, MD

12:42 Discussion

12:50 Paper # 127: Long-Term Two to Five Year Clinical and Functional Outcomes of Minimally Invasive Surgery (MIS) for Adult Spinal Deformity
Neel Anand, MD; Babak Khandehroo, MD; Sheila Kahwaty, PA-C; Eli Baron, MD

12:54 Paper # 128: Sagittal Spinal Profile And Spinopelvic Balance In Parents Of Scoliotic Children, As Compared to Normal Controls
Michiel Janssen, PhD; Koen L. Vincken, PhD; Tomaz Vrtovec, PhD; Bastiaan Kemp, BSc; Max A. Viergever, DSc; Lambertus W. Bartels; Rene M. Castelein, MD, PhD

12:58 Paper # 129: The Effect of Complications on Health Outcomes Among Patients Undergoing Three-Column Osteotomy Surgery
Michael F. O'Brien, MD; Richard Hostin, MD; Ian McCarthy, PhD; Christopher P. Ames, MD; Justin S. Smith, MD, PhD; Munish C. Gupta, MD; Robert A. Hart, MD; Douglas C. Burton, MD; Christopher I. Shaffrey, MD; Shay Bess, MD; Frank Schwab, MD; Virginie Lafage, PhD; Khaled Kebaish, MD; Vedat Deviren, MD; International Spine Study Group

† = Whitecloud Award Nominee – Best Clinical Paper * = Whitecloud Award Nominee – Best Basic Science Paper

MEETING AGENDA

- 13:02 Discussion
- 13:10 Paper # 130: Increased Utilization of Fusion with Instrumentation and BMP in the Medicare Patient Population Over Time
Jacob M. Buchowski, MD, MS; Nicholas J. White, MPH; Margaret A. Olsen, PhD, MPH
- 13:14 Paper # 131: Does Preoperative Narcotic use Persist after Spinal Deformity Surgery? A Comparison of Non-Narcotic and Narcotic Using Groups
Addisu Mesfin, MD; Lawrence G. Lenke, MD; Keith H. Bridwell, MD; Usman Akhtar, BA; Jennifer M. Jupitz; Jeremy L. Fogelson, MD; Stuart Hershman, MD; Han Jo Kim, MD; Linda Koester, BS
- 13:18 Paper # 132: The Role of Minimally Invasive Lateral Retroperitoneal Transpsoas Interbody Fusion for Sagittal and Coronal Alignment Correction in Adult Lumbar Scoliosis Patients
Yoon Ha, MD, PhD; Weber Michael, MD, PhD; Sassan Keshavarzi; Gregory M. Mundis, MD; Vedat Deviren, MD
- 13:22 Discussion
- 13:30 Paper # 133: Five-Year Results of Selective Single-Level Artificial Lumbar Disc Replacement in the Presence of an Adjacent Degenerate Level
John Nathaniel M. Ruiz, MD, MRCS; Joseph Thambiah, FRCS; Hee-Kit Wong
- 13:34 Paper # 134: PLF vs. TLIF in the Treatment of Degenerative Lumbar Scoliosis
Fangcai Li, PhD
- 13:38 Paper # 135: Does the Use of Pelvic Screws Decrease the Revision Rate of Long Spinal Fusions to the Sacrum
Christopher DeWald, MD; Isaac L. Moss, MDCM, MASc, FRCSC
- 13:42 Discussion

13:50 Adjourn

SOCIAL EVENTS

Welcome Reception

Wednesday, July 18, 2012

17:00 – 19:30

B2 Foyer

All registered delegates and registered guests are invited to pick up their registration materials and to attend the IMAST Welcome Reception on Wednesday, July 18 from 17:00 – 19:30. The reception will be hosted in the Exhibit Hall on the B2 level of the Istanbul Congress Center, where beverages and light hors d'oeuvres will be served. There is no charge for registered delegates, though a ticket must be requested at the time of registration. The Welcome Reception add-on fee is \$20 USD for registered guests, and a ticket must be requested at the time of registration. Dress for the Welcome Reception is business casual.

The Welcome Reception is supported, in part, by grants from Medtronic and Synthes Spine.

Course Reception

Friday, July 20, 2012

19:00 – 23:00

Haliç Congress Center

The Local Host Committee from Istanbul is excited to welcome IMAST delegates and registered guests to a unique evening, highlighting the finest in Turkish culture. The IMAST Course Reception will be held on Friday, July 20 from 19:00 – 23:00, featuring Fire of Anatolia, a Turkish dance group consisting of more than 120 performers. The group has performed in more than 85 countries from the U.S. to China and Japan, and holds two Guinness records, one for fastest dance performance with 241 steps per minute and another for largest audience.

18:45 First bus departs Istanbul Congress Center.

19:30 Welcome cocktails and hors d'oeuvres served at the Haliç Congress Center, Sadabad Auditorium Foyer.

20:15 Fire of Anatolia performance in the Sadabad Auditorium.

20:45 Cocktails and hors d'oeuvres reception on the Haliç Congress Center Terrace.

22:00 Buses begin to depart Haliç Congress Center.

23:00 Last bus departs Haliç Congress Center.


Tickets are \$25 each for registered delegates and \$30 for registered guests. A limited number of tickets may be available onsite. Please visit the Registration Desk on the B0 level. Cocktail dress is appropriate for the Course Reception, and portions of the event will be held outside.

OPTIONAL TOURS

Both daily and pre/post-conference tours are available and are handled by Dekon Group. To pick up tour tickets and for tour-related questions, please visit Dekon's Tour Desk on the B0 Level of the Istanbul Congress Center. The SRS Registration Desk will NOT have any tour-related information.

A decorative geometric pattern, possibly a traditional Islamic or Arabic motif, is visible in the top left corner of the page. It features a complex, interlocking star and polygonal design in shades of grey and white.

PAPER ABSTRACTS



The Scoliosis Research Society gratefully acknowledges DePuy Spine for their overall support of the 19th IMAST.



1. Does Recombinant Human Bone Morphogenetic Protein-2 (BMP) Use in Adult Spinal Deformity (ASD) Increase Complications and are Complications Dose Related? A Prospective, Multicenter Study of 257 Consecutive Patients

*Shay Bess, MD; Breton Line, BSME; Oheneba Boachie-Adjei, MD; Robert A. Hart, MD; Virginie Lafage, PhD; Frank Schwab, MD; Behrooz A. Akbarnia, MD; Christopher P. Ames, MD; Douglas C. Burton, MD; Richard Hostin, MD; Eric Klineberg, MD; Gregory M. Mundis, MD; Christopher I. Shaffrey, MD; Justin S. Smith, MD, PhD; International Spine Study Group
USA*

Summary: Evaluation of BMP use in ASD using a large, multi-center, prospective, consecutive database demonstrated BMP mean PSF dose 2.4mg/level does not correlate with major complications, wound problems, superficial or deep infections or complications requiring surgical treatment. Future BMP research needs to carefully evaluate complications associated with specific BMP dosing and correlate BMP use and complications with clinical outcomes.

Introduction: Off label BMP use in ASD surgery has increased, however BMP associated complications and under-reporting of acute complications have come under scrutiny. Purpose: evaluate BMP associated complication rates following ASD surgery.

Methods: Multicenter, prospective analysis of complication rates following ASD surgery for consecutive ASD patients receiving BMP (BMP) or no BMP (NOBMP). Inclusion criteria: age ≥ 18 years, ASD surgery (ASD=scoliosis ≥ 20 degrees, sagittal vertical axis (SVA) ≥ 5 cm, pelvic tilt (PT) ≥ 25 degrees, or thoracic kyphosis (TK) > 60 degrees), complete demographic, radiographic, and operative data, and minimum 8 weeks follow up. Rates of major, minor, and complications requiring surgery evaluated. Correlations between total BMP dose, BMP dose/level and complications evaluated. Multivariate analysis performed.

Results: 257 of 316 patients, mean follow up 20.3 months (range 2.2-38), met inclusion criteria. BMP (n=155; average PSF dose 2.4mg/level; range 0-12 mg/level; average interbody dose 2 mg/level; range 0-18 mg) and NO BMP (n=102) had similar age, BMI, smoking history, prior spine surgery, maximal scoliosis, SVA, levels fused, and estimated blood loss ($p>0.05$). BMP had greater Charlson comorbidity index, operative time, osteotomies/patient, and anteroposterior surgery ($p<0.05$). Total complications per patient were greater for BMP vs. NOBMP (1.0 vs. 0.5; $p<0.05$), however major complications, neurological and wound complications, superficial and deep infections, and complications requiring surgery were similar for BMP vs. NOBMP ($p>0.05$). Total posterior (PSF) BMP dose statistically correlated with total, major and neurological complications ($p<0.05$), however r values indicated small correlations (0.32, 0.14 and 0.14, respectively). PSF BMP dose per level did not correlate with major, wound or neurological complications, deep infections or return to OR ($p<0.05$).

Conclusion: BMP use in ASD, at BMP dose/level reported, is not associated with wound, superficial or deep infections or return to OR. Further research is needed to evaluate long term complications and complications associated with higher dosing.

The FDA has not cleared the drug and/or medical device for the use described in this presentation (i.e., the drug or medical device is being discussed for an 'off label' use).

2. "Sex and the Sacrum" - An Analysis of the Effects of Long Fusion to the Sacrum on Sexual Function

*Michael O. LaGrone, MD; Amanda B. Coffman, PA-C, MCHS
USA*

Summary: The few available studies in the spine literature regarding sexual function are related to the effects of back pain. To our knowledge, there are no studies describing the consequences of long fusion to the sacrum (LFS) on sexual function. We show there are significant limitations and modifications in sexual activity specifically related to long fusion to the sacrum compared to a control group with fusions ending short of sacrum (FSS).

Introduction: The aim of this study was to determine if there are significant untoward effects on sexual activity in patients with long fusions to the sacrum compared to those fused short of the sacrum.

Methods: Fifty-four female patients (mean age 58, range 38-71) with LFS for spinal deformity (single surgeon, proximal fused level T-12 or higher, minimum 2 year follow-up) and 30 female control patients with fusions ending above the sacral level (mean age 57, range 23-73) were evaluated by survey and follow-up telephone interviews. Utilizing a privacy conscious questionnaire developed in conjunction with The Kinsey Institute, the participant identities remained anonymous to the surgeon. A modified 7-point Likert scale was used to assess sexual function, with 70 points representing a "perfect" score. SRS-30 and ODI scores were calculated and correlated with the findings.

Results: Of the 54 patients with LFS, 26 self-responded as being sexually active. Of the 28 patients not sexually active, 9 listed spine related complaints as the cause. Eighteen of the 30 FSS patients reported being sexually active. Twelve were abstinent, but only 4 reported back pain as the limiting factor.

In the LFS group, the mean Likert score was 59 (range 21-67). By comparison, the mean score in the FSS group was 70 (range 26-68). There was a statistically significant difference between the 2 groups ($p=.046$). The ODI difference was not significant ($p=.201$).

Lack of pelvic mobility and limitations in comfortable sexual positions were the most common complaints among the LFS group. In contrast, the FSS respondents listed few, if any, difficulties regarding sexual positions or need for modifications.

Conclusion: Long fusions to the sacrum in females have significant untoward effects on sexual function when compared to patients fused short of the sacrum. Loss of pelvic mobility appears to be a predominant factor. Current outcome instruments may not be sensitive enough to accurately assess significant restriction in sexual function. Surgeons should counsel spinal deformity patients undergoing long-fusions to the sacrum regarding the potential consequences on sexual function.

PAPER ABSTRACTS

3. Unmarked Image Validation of the SRS-Schwab Adult Deformity Classification

Frank Schwab, MD; Jason Demakakos; Benjamin Blondel, MD; Benjamin Ungar; Jacob M. Buchowski, MD, MS; Jeffrey D. Coe, MD; Donald A. Deinlein, MD; Christopher DeWald, MD; Hossein Mehdian, MD, MS(Orth) FRCS(Ed); Christopher I. Shaffrey, MD; Clifford B. Tribus, MD; Virginie Lafage, PhD USA

Summary: While classifications in the pediatric population are well established, there is still a need for a clinically relevant classification for adult spinal deformity. A previous classification system has been revised to include pelvic parameters, which have shown marked correlation with HRQOL measures in recent studies. Initiated by the SRS Adult Deformity Committee, this study demonstrates that the proposed new adult spinal deformity classification system is clear and has excellent intra- and inter-rater reliability and agreement.

Introduction: A classification system can serve several purposes, including providing: a) consistent characterization of a clinical entity, b) a basis for comparing different treatments, and c) recommended treatments. Characteristics of a good classification system include ease of use, reliability, and clinical relevance. Previous adult spinal deformity classification systems have not included pelvic parameters, some of which have been shown to highly correlate with HRQOL measures. This study seeks to determine if the proposed classification system, which includes pelvic parameters, is clear and reliable in the clinical setting.

Methods: On two separate occasions approximately one week apart, 7 readers graded 21 unmarked cases of coronal and sagittal radiographs of patients with adult spinal deformity, identifying curve type, PI-LL, PT, and SVA. Inter- and intra-rater reliability and inter-rater agreement were determined for the curve type and each modifier separately. Fleiss' Kappa was used for reliability measures, with values of 0.00-0.20 considered slight, 0.21-0.40 fair, 0.41-0.60 moderate, 0.61-0.80 substantial, and 0.81-1.00 almost perfect agreement.

Results: Inter-rater Kappa for curve type was 0.69 and 0.72 for the two readings respectively, with modifier Kappas of 0.51 and 0.58 for PI-LL, 0.70 and 0.65 for PT, and 0.87 and 0.87 for SVA. Across all readers Kappa values averaged 0.89 for Curve Type, 0.71 for PI-LL, 0.82 for PT, and 0.91 for SVA. Intra-rater agreement was measured as 90% (0.83 kappa), while inter-rater agreement was measured as 52% (0.71 kappa). SVA type agreement was identified by all readers consistently in 71% of cases.

Conclusion: This study shows that there is excellent intra and inter rater reliability with the proposed system. Unmarked classifications are a more accurate approach to replicate clinical usage for physicians as these images are typical in practice. Similar classification systems have shown a decrease in intra and inter rater reliability when comparing marked vs. unmarked grading. While this classification system has limitations in inter-observer agreement, it offers a substantial gain in clinically relevant information over previous systems by including pelvic parameters.

4. A Critical Assessment of Growing Rods for the Treatment of Pediatric Scoliosis in Cerebral Palsy

Mark McElroy, MS; Paul D. Sponseller, MD; Jonathan R. Dattilo, BS; George H. Thompson, MD; Behrooz A. Akbarnia, MD; Suken A. Shah, MD; Brian D. Snyder, MD, PhD; Growing Spine Study Group USA

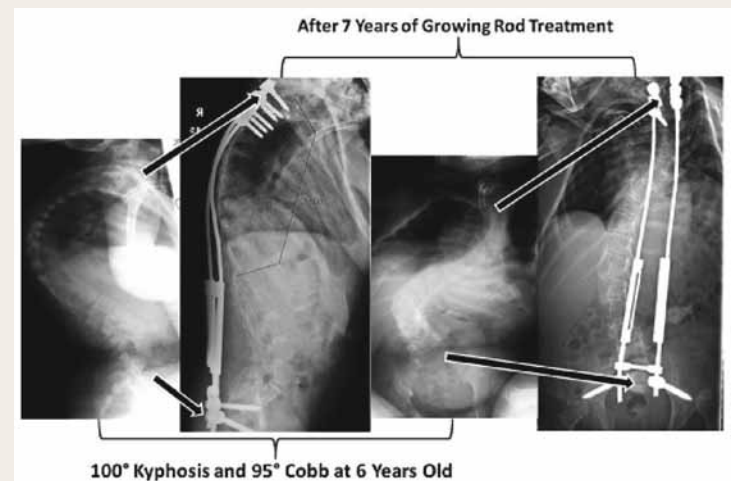
Summary: Control of scoliosis and pelvic obliquity (PO) in children with cerebral palsy (CP) may help prevent restrictive pulmonary disease and increase quality of life. Growing rods (GR) are effective in controlling scoliosis, and constructs extending to the pelvis better control PO. However, 33% of patients experienced a post-operative deep wound infection (DWI) and 15% abandoned treatment.

Introduction: Children with CP frequently develop severe spinal deformity and PO. Growth-preserving strategies are attractive, but co-morbidities raise the risk/benefit ratio.

Methods: Clinical and radiographic multi-center review of patients with CP treated with GR between 1996-2011 with at least 2 yrs follow-up.

Results: Twenty-seven patients with CP underwent GR surgery at age 7.6 ± 2.4 yrs. GR treatment time was 3.5 ± 1.8 yrs. Instrumentation (1 rod in 4 patients, dual rods in 23 patients) spanned 15.2 ± 1.4 levels. Constructs extended to the pelvis in 15 patients. Primary scoliosis was 85 ± 20 degrees preoperatively, 40 ± 15 degrees after GR insertion, and 49 ± 21 degrees at follow-up. PO was 27 ± 19 degrees preoperatively, 9 ± 8 degrees after GR insertion, and 14 ± 13 degrees at follow-up. When compared to lumbar fixation, pelvic fixation (sacral and/or iliac) led to similar scoliosis correction ($p=0.56$) but significantly better PO correction ($p<0.001$). T1-S1 length was 25.6 ± 3.4 cm preoperatively, 30.7 ± 4.0 cm after GR insertion, and 33.4 ± 4.1 cm at follow-up. Patients had 4.4 ± 3.2 lengthenings at 11 ± 7 month intervals. Hospital stay was 8.7 ± 12.1 days after GR insertion and 1.4 ± 2.5 days after lengthening, with 45% of lengthenings being outpatient. Complications from a total of 147 operations included DWI (9), rod fracture (5), superficial wound infection (2), anchor dislodgement (2), and wound dehiscence (2). GR therapy was abandoned in 3 patients due to DWI and 1 patient at family's preference after rod fracture. Eight patients underwent final fusion at age 12.3 ± 1.7 yrs. In these patients, scoliosis improved 37 ± 25 degrees, and T1-S1 length increased 9.1 ± 6.4 cm from pre-insertion to post-fusion.

Conclusion: GRs can be useful for patients with CP. Pelvic fixation is useful in controlling PO. The most common surgical complication is DWI, which may lead to treatment abandonment in this patient population.



The FDA has not cleared the drug and/or medical device for the use described in this presentation (i.e., the drug or medical device is being discussed for an 'off label' use).

5. Age, Sagittal Deformity and Operative Correction are Risk Factors for Proximal Junctional Failure (PJF) Following Adult Spinal Deformity (ASD) Surgery

Robert A. Hart, MD; Richard Hostin, MD; Themistocles Protopsaltis, MD; Shay Bess, MD; Frank Schwab, MD; Virginie Lafage, PhD; Praveen V. Mummaneni, MD; Christopher P. Ames, MD; Christopher I. Shaffrey, MD; Justin S. Smith, MD, PhD; Oheneba Boachie-Adjei, MD; Eric Klineberg, MD; Douglas C. Burton, MD; Munish C. Gupta, MD; International Spine Study Group
USA

Summary: Case-control analysis of ASD surgical patients showed age, sagittal deformity, and extent of sagittal correction were risk factors for PJF. Patients with PJF were more likely to have had a pedicle subtraction osteotomy (PSO), and upper thoracic (UT) fusion patients were more likely to have had distal extension to the pelvis. Patients experiencing PJF were more likely to undergo revision surgery than patients without this complication. Further research is needed to identify methods to prevent PJF in patients requiring large deformity correction.

Introduction: PJF is a significant complication following ASD surgery. Risk factors for PJF are poorly understood. **Purpose:** Evaluate risk factors for clinically significant PJF following ASD surgery.

Methods: Multi-center, case-control analysis of consecutive PJF patients following ASD surgery. PJF defined as kyphosis increase $> 10^\circ$ from upper instrumented vertebra (UIV) to two levels above (UIV+2) from preop value, and UIV or UIV+1 fracture, dislocation, or implant failure. PJF patients were matched to patients without PJF (NOPJF) from a prospective ASD database. Matching criteria: levels fused and UIV. Groups divided by level of UIV: thoracolumbar (TL; UIV=T9-T11) or upper thoracic (UT; UIV=T2-T5). Risk factors included: age, sagittal vertical axis (SVA), thoracic kyphosis (TK), lumbar lordosis (LL), pelvic incidence minus lumbar lordosis (PI-LL), and pelvic tilt (PT).

Results: TL group differences between PJF (n=37) and NOPJF (n=21) included age (59.2 vs 43.7 years), preop TK (40.5° vs 29.6°), preop LL (18.8° vs 43.6°), preop PI-LL (35.9° vs 17.5°), and change in LL (30° vs 9.6°), respectively ($p<0.05$). UT group differences between PJF (n=15) and NOPJF (n=33) included age (67.8 vs 59.5 years), preop SVA (68.3 vs 1.6 mm), preop PT (26.8° vs 17.5°), preop PI-LL (19.2° vs 0.61°), preop TK (55.2° vs 33.7°), and change in SVA (69 vs 49 mm), respectively ($p<0.05$). PSO was more common in all PJF patients (29% vs 6%) and more UT PJF patients were fused to pelvis than NOPJF (73.3% vs 39.4%), respectively ($p<0.05$). Revision surgery was performed more frequently for PJF than NOPJF (TL 35% vs 9%; UT 67% vs 18%; respectively; $p<0.05$).

Conclusion: Case-control analysis of ASD surgical patients demonstrated risk factors for PJF include age, sagittal deformity and sagittal correction. PSO and fusion to pelvis are also risk factors. Revision surgery is more frequent among patients experiencing PJF. Further research is needed to identify methods to prevent PJF in ASD patients requiring large sagittal correction.

6. Functional Outcomes in Duchenne Muscular Dystrophy: Comparing the Differences between Surgery vs. No Surgery in the Management of Scoliosis Deformity

Hyon Su Chong; Hak-Sun Kim, MD; Jea-Woo Lim; Hyoung Bok Kim; Do Yeon Kim, MD; Dong-Eun Shin, PhD; Mary Ruth A. Padua, MD
Republic of Korea

Summary: 1. Sixty three patients (40 surgical and 23 non-surgical) are evaluated using the Muscular Dystrophy Spine Questionnaire (MDSQ).

2. Surgery for DMD scoliosis deformity significantly improves trunk balance, aiding in performance of daily activities, sleep, breathing, and better self-perception.

3. Back and hip pain persist even with significant correction of deformity.

4. With disease progression, the generalized body involvement in DMD hinders independent mobilization despite spinal stabilization.

5. Younger age at surgery (<14 years) is associated with improved functional outcome.

Introduction: The indication for reconstructive surgery in patients with neuromuscular scoliosis is to improve or prevent further decline in their abilities. With most studies focusing on technical and radiographic indices, functional status is actually the most important outcome to consider in their management. To date, only a limited number of studies have been published to compare surgical and nonsurgical management of Duchenne muscular dystrophy (DMD) using non-specific and non-validated questionnaires.

The purpose of this study is to compare the differences in the functional outcome of patients managed conservatively and with surgery.

Methods: A comparison of 63 patients diagnosed with DMD scoliosis was done. Records from outpatient consultations, admission, operations and radiographs were reviewed for the 40 surgical and 23 non-surgical patients included in the study. All were evaluated using the Muscular Dystrophy Spine Questionnaire (MDSQ) to measure the functional outcomes.

Results: The MDSQ score for the surgical group was higher (37.67 ± 19.75 versus 24.89 ± 14.55) compared to the nonoperative group ($p=0.0165$). Patients in the surgical group had better patient satisfaction in performing activities of daily living, and trunk balance. However, mobilization remained unimproved despite surgery ($p=0.0992$). The surgical group had better scores in terms of appearance, sleep and breathing ($p<0.05$). Back and hip pain severity in the surgical group was not significantly different ($p=0.4489$) from the control group. Younger patients (<14 years of age at time of surgery) showed higher outcome scores than older patients after a minimum of 2 years from surgery.

Conclusion: Reconstructive surgery in DMD scoliosis improves level of function with higher satisfaction rates compared to patients treated conservatively. However, independent mobilization, back and hip pain remain persistent problems even with surgery.

7. Cost Effectiveness of Single-Level Anterior Cervical Discectomy and Fusion Five Years After Surgery

Leah Y. Carreon, MD, MSc; Paul A. Anderson, MD; Vincent C. Traynelis, MD; Praveen V. Mummaneni, MD; Steven D. Glassman, MD
USA

Summary: Surgeons need to demonstrate cost effectiveness as well as clinical efficacy to justify payment for interventions, including instrumented anterior cervical discectomy and

PAPER ABSTRACTS

fusion. In this study, the five year cumulative cost and SF-6D were determined in 241 patients who underwent single-level ACDF. Single-level instrumented ACDF is both effective and durable, with a Cost per QALY gained of \$25,798 at five years after surgery.

Introduction: Economic value is an increasingly important component of healthcare policy decision making. The purpose of this study is to determine the cost/QALY gained for single-level instrumented Anterior Cervical Discectomy and Fusion (ACDF) over five years.

Methods: Control ACDF patients with complete five year follow-up data who were part of the IDE trials for cervical disc arthroplasty were included in the analysis. All in-patient healthcare events over five years were identified. Direct costs for each intervention were determined using the 2012 Medicare Fee schedule. Health utility was determined using the SF-6D, calculated by transformation from the SF-36. Sensitivity analysis to include/exclude upper extremity procedures was performed.

Results: There were 241 patients (120 females, 121 males), mean age 45.0 years (22 to 71 years).

Cost per patient for the index ACDF was \$15,714. Over five years 33 revision ACDFs, 15 posterior fusions, 6 foraminotomies, 2 implant removals, 2 hematoma evacuations and 1 esophageal fistula repair were performed; most during the first two years after the index surgery. Mean QALY gained in each year post-op was 0.15, 0.17, 0.17, 0.15 and 0.16 for a cumulative 0.81 QALY gain over five years. The resultant Cost/QALY gained at one year was \$116,935, \$57,713 at year two, \$40,622 at year three, \$31,381 at year four and \$25,798 at year five. In this cohort, 20 carpal tunnel releases and 19 rotator cuff repairs were done within five years after the index ACDF. These may be due to persistence of the patient's original symptom complex after the index ACDF. Sensitivity analysis to include upper extremity procedures was performed. The Cost/QALY gained at one year including upper extremity procedures was \$119,015, \$59,758 at year two, \$42,145 at year three, \$32,795 at year four and \$27,358 at year five.

Conclusion: Surgeons need to demonstrate cost effectiveness as well as clinical efficacy in order to justify payment for interventions, including ACDFs. This study indicates that at 5 year follow-up, single-level instrumented ACDF is both effective and durable resulting in a favorable cost/QALY gained as compared to other widely accepted healthcare interventions.

8. Safety and Efficacy of One-Stage Surgical Treatment for Congenital Spinal Deformity Associated with Split Spinal Cord Malformation

*Huiren Tao; Zhuojing Luo; Hua Hui, MD
China*

Summary: Correction of progressive congenital spinal deformity (CSD) with split spinal cord malformation (SSCM), has been reported that all SSCM should be operated firstly before any orthopedic intervention and then the second surgery for correction and stabilization of the spinal deformity 3 to 6 months later. Recently, more different viewpoints have been approved. The common belief of treatment for these 2 associated conditions is needed to be revised.

Introduction: The aim of this study is to retrospectively evaluate the safety and efficacy of one-stage surgical treatment for 45 consecutive patients,

who had progressive CSD associated with SSCM.

Methods: Patients had one stage surgery; after exposure of the determined levels and placement of instruments, bony spur was resected in the patients of type I; in patients of type II we did nothing to the SSCM. In the next correction surgery, posterior fusion surgery was performed in 38 patients; non-fusion surgery was performed in 7 patients.

Results: 36 female and 9 male patients formed the basis of the study. The mean age was 14 years and the mean follow-up period was 31 months. Type I SSCM in 15 patients and type II in 30 patients. Seven patients had progressive neurologic deteriorations preoperatively. The mean major curves were corrected from an average of 73.7o to 33.5o with a correction rate of 54.5%. The overall complication was transient, including 2 patients of neurological compromise and 1 patients of cerebrospinal fluid leakage. The average loss of correction at final follow-up was 2.5o for major curves.

Conclusion: The one-stage surgical treatment for CSD associated with SSCM provides a satisfactory option to effectively improve the spinal deformity without significant complications. Neurosurgical interventions are recommended to patients with Type I SSCM before spinal deformity surgery; however, patients with Type II SSCM can be treated safely without a need of neurosurgical intervention.

9. Coagulopathy in Adult de novo Scoliosis Surgery: Timing and Onset of Breakdown of the Coagulation Cascade as Measured by D Dimer and Fibrinogen Levels

*Rajiv K. Sethi, MD; Jean-Christophe Leveque, MD; Thomas C. Dean, MD; Ryan P. Pong, MD; Stephen J. Olivar, MD; Sarah Hippias, MD; Vishal Gala, MD, MPH; Chong C. Lee, MD, PhD; Kyle Kim, MD, PhD
USA*

Summary: Surgery for the treatment of adult de novo scoliosis is associated with the development of a breakdown in the coagulation cascade in a way specific to adult scoliosis surgery. Our data suggests that within 2-3 hrs after incision, a breakdown of the coagulation cascade begins as heralded by 3 fold elevation in D dimer levels. INR does not reliably predict the status of the coagulation cascade.

Introduction: Surgery for adult de novo scoliosis is associated with a unique breakdown in the coagulation cascade. A similar rapid decline in coagulation parameters is not seen in other complex operations involving the same time frame. The literature is sparse regarding the analysis of this phenomenon.

Methods: Our group has standardized the dual attending surgeon approach to adult spinal deformity surgery and institutionalized a robust complex spine anesthesia protocol, as presented at prior SRS and IMAST meetings. We retrospectively studied 13 consecutive cases done using this protocol to discern the timeframe of changes in the coagulation cascade. All cases were done in a single stage and consisted of primary adult de novo scoliosis patients. All other spinal deformities (idiopathic, iatrogenic, neuromuscular) or those needing three column osteotomies were excluded. The same group of complex spine surgeons and anesthesiologists was utilized in all 13 cases in order to reduce confounding bias. All patients had posterior only fusion from T10-S1 with iliac fixation utilizing pedicle screw fixation and had TLIFs at L4-5 and L5-S1.

Results: Mean age was 67 (+/-7.2). Mean preop lumbar curve magnitude was 40 degrees (28-51). Mean incision to closure time was 5 hrs 56 min (+/-40min). All lab values were measured at hourly timepoints. Mean D dimer at incision was 0.43 (+/- 0.24). Mean starting fibrinogen level was 311 (+/-60). 3-fold elevation in D

dimer was seen within 2 hrs and 22 min of incision (+/-46 min). Within the same timeframe, fibrinogen levels dropped 21%. D dimer at closure was 8.35 (+/-3.64) (19 fold increase). Fibrinogen at closure was 200 (+/-36) (35% decrease). Final INR was less than 1.5 in all cases following appropriate resuscitation. Mean blood loss was 2169 ml (+/- 817).

Conclusion: Our data suggests that within 2-3 hrs after incision, a breakdown of the coagulation cascade begins with 3 fold elevation in D dimer levels. Within 6 hrs of surgery, there is a 19 fold increase in D dimer concentration and a corresponding 35% decrease in fibrinogen. This is the first study quantifying the decline in coagulation cascade in adult spinal deformity surgery. INR does not reliably predict the status of the coagulation cascade.

10. The Effect of Contouring on Fatigue Strength of Deformity Rods: Is it Okay to Rebend and Which Materials are Best?

Michael Slivka, MSc; Yung K. Fan; Jason C. Eck, DO, MS
USA

Summary: In this study, we measured the effect of bending and rebending on the fatigue properties of four commonly used deformity rod materials.

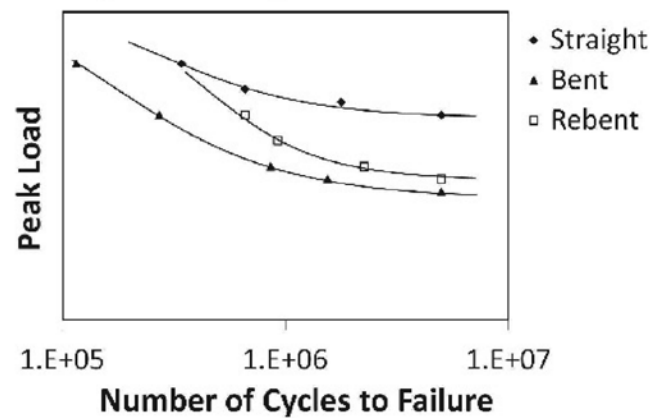
Introduction: Spinal deformity surgeons have a variety of rod materials to choose from and selecting the best rod depends on patient characteristics and rod material properties. Implanted rods must withstand repeated loading due to daily living activities and few studies have been published regarding the differences between materials and the effects of contouring.

Methods: Four rod materials were tested, all 4.5 mm diameter: titanium alloy, two different grades of stainless steel (125 ksi and 200 ksi minimum ultimate strength), and cobalt-chromium alloy (CoCr). For each rod material, three conditions were tested: "Straight" - virgin rods, "Bent" - rods bent to a radius of curvature of 100 mm, and "Rebent" - rods overbent to a radius of curvature of 50 mm, then partially straightened to a 100 mm radius. Fatigue testing was conducted on unilateral vertebrectomy constructs with polyaxial screws following the guidelines of ASTM-F1717. Samples were run until failure or until 5 million cycles were reached. The endurance limit for each rod/bending condition was defined as the highest load for which the sample achieved 5 million cycles without failure.

Results: In the Straight condition, the endurance limit of the CoCr rods was at least 25% higher than all other materials. In the Bent condition, the endurance limit of all materials was reduced between 20-40%, and the CoCr rods remained well above the others. The reduction is explained by the fact that contouring introduces stress concentrations caused by micro-cracks in the surface of the rod. In the Rebent condition, the endurance limit of all materials increased compared to the Bent condition, only slightly for Ti but nearly or completely back to the Straight condition for the others. This was an unexpected result, which may be explained by strain-hardening of the metals. The fatigue life curves for Ti are shown in Figure 1.

Conclusion: It appears safe to overbend and then rebend, for one cycle, spinal rods made of the materials tested in this study using tube benders, and CoCr rods were clearly superior for all conditions. However, multiple cycles of bending and rebending were not tested, nor were more commonly used French benders, which may result in worse performance.

Figure 1: Fatigue of Ti-6Al-4V Rods



11. Can a Novel Rectangular Footplate Provide Higher Resistance to Subsidence when Compared to Circular Footplates? An Ex Vivo Biomechanical Study

Murat Pekmezci, MD; Abbey Kennedy; Erik H. McDonald, BS; Christopher P. Ames, MD; Robert T. McClellan, MD; Vedat Deviren, MD
USA

Summary: A novel rectangular footplate design is more resistant to subsidence when compared to a circular footplate design in an ex vivo biomechanical model. The advantage of the rectangular design is maintained even in the presence of a central endplate defect. These findings suggest that rectangular footplates may provide better subsidence resistance when used to reconstruct defects following thoracolumbar corpectomy.

Introduction: Cage subsidence is a post-operative complication following reconstruction of corpectomy defects in the thoracolumbar spine and depends on factors such as bone quality, adjunctive fixation and the relationship between the footplate on the cage and the vertebral body endplate. The purpose of this study is to compare the subsidence characteristics of a novel rectangular footplate design with a conventional circular footplate design.

Methods: Twenty-four cadaveric vertebrae (T12-L5) were disarticulated, potted in a commercial resin, loaded with either a circular or rectangular footplate, and tested in a servo hydraulic testing machine. Twelve vertebral bodies were loaded with a circular footplate and following subsidence the same vertebral bodies were loaded with a rectangular footplate. The second set of 12 vertebral bodies was loaded with a rectangular footplate only. Force-displacement curves were developed for the three groups, and the ultimate load to failure and stiffness values were calculated.

Results: The ultimate load to failure with the circular footplate was 1310N (SD 482). The ultimate load to failure with a rectangular footplate with a central defect and without a central defect was 1636N (SD 513) and 2481N (SD 1191), respectively. The stiffness of the constructs with circular footplate was 473N/mm (SD 205). The stiffness of the constructs with a rectangular footplate with a central defect and without a central defect was 754N/mm (SD 217) and 1054N/mm (SD 329), respectively.

Conclusion: A rectangular footplate design is more resistant to subsidence compared with a circular footplate design in an ex vivo biomechanical model. The new design had higher load to failure even in the presence of a central

PAPER ABSTRACTS

defect. These findings suggest that rectangular footplates may provide better subsidence resistance when used to reconstruct defects following thoracolumbar corpectomy.

12. Feasibility of Percutaneous Posterolateral Spinal Fusion with Recombinant Bone Morphogenetic Protein - 2 (rh-BMP2): A Comparison with Standard Methods using an Animal Model Study

*Chris Yin Wei Chan, MS Orth; Lim Beng Saw, MS Orth; Paisal Hussin, MS Orth; Mun Keong Kwan, MS Orth
Malaysia*

Summary: To date, no study has evaluated the feasibility of percutaneous posterolateral fusion of the spine. This is an animal research model involving 32 New Zealand white rabbits stratified into four groups; Placebo, Autogenous Iliac Crest Bone Graft (ICBG), Demineralised Bone Matrix (DBM), and rh-BMP2 group. This study shows percutaneous posterolateral spinal fusion with rh-BMP2 is feasible with better and faster fusion rate compared to ICBG. However, the occurrence of ectopic bone formation is significant when rh-BMP 2 is used.

Introduction: The clinical application of recombinant bone morphogenetic protein in spinal surgery has been shown to be safe and effective. However, its use in minimally invasive spine surgery has been limited to anterior interbody fusion procedures. To date, no study has evaluated the feasibility of percutaneous posterolateral fusion in the spine utilizing rh-BMP 2.

Methods: This is an animal research model involving 32 New Zealand white rabbits stratified into four study groups: Placebo, Autogenous Iliac Crest Bone Graft (ICBG), Demineralised Bone Matrix (DBM), and rh-BMP2 group with 8 study subjects per group. The rh-BMP-2 group was subdivided into open technique (right side), and percutaneous technique group (left side). Fusion was graded at 6 weeks and 3 months after plain radiographic, computed tomography and clinical assessment with the following grading system; Grade A: no bone formation, Grade B: Non-bridging bone formation, Grade C: Fusion, Grade D: Fusion with ectopic bone formation.

Results: No fusion was noted in the placebo group and DBM group. However, in the DBM group, bone formation occurred in 43.8 % of subjects. Rh-BMP 2 group had a higher fusion rate compared to ICBG group at 6 weeks and 3 months. The fusion rate for ICBG group, rh-BMP(open) and rh-BMP(percutaneous) was 37.5%, 87.5% and 50.0% at 6 weeks and 50.0%, 100.0% and 62.5% at 3 months. Ectopic bone formation occurred in 12.5% in the rh-BMP 2 (percutaneous group) and 25.0% in rh-BMP 2 (open group)

Conclusion: Usage of rh-BMP 2 is feasible for percutaneous posterolateral fusion of the lumbar spine in this animal model. However, a more precise delivery system might improve the fusion rate when percutaneous technique is used. Significant rate of ectopic bone formation occurred when rh-BMP 2 is used.

13. Three Dimensional Visualization of the Intervertebral Disc: The Effects of Growth Modulation

*Diana A. Glaser, PhD; Christine L. Farnsworth, MS; Josh Doan, MEng; Peter O. Newton, MD
USA*

Summary: Anterolateral spinal tethering in a growing animal model on three-dimensional (3D) disc morphology was found to decrease disc height, without a tethered vs. non-tethered side height differences.

Introduction: Spinal growth modulation may correct deformities without fusion. Maintained motion requires disc health. Disc shape from tethered bovine spines was evaluated using 3D micro-computed tomography (μ CT) reconstructions. Disc heights on the instrumented side vs non-instrumented side and between tethered spines and surgical sham controls were compared.

Methods: Six 5-week old calves received 4 consecutive thoracic anterolateral vertebral body (VB) screws connected with a flexible tether (Tether Group); 6 calves had sham surgeries (screws only, Sham Group). Spines were harvested after 3 months of growth. An apical motion segment was harvested from 3 spines in each group and proximal and distal segments harvested from 3 each, resulting in 9 motion segments in each Group. Individual motion segments were embedded in methylmethacrylate for previous histology. Samples were imaged by microtomograph (Skyscan, Belgium) at 35 μ m resolution, 0.4 degree rotation step, 100mA, 100KV, using a 1.0mm Aluminum filter. Vertebral surface reconstructions were created using MIMICS (Materialise, Belgium). VB epiphyses were identified. Using a custom MATLAB (Mathworks, MA, USA) script, inter-epiphyseal distances were calculated, generating disc-space height maps. Average height values were calculated for the right (instrumented) and left (non-instrumented) sides of each cross-sectional map. Two-tailed unpaired student t-tests evaluated left-right disc height differences and tethered vs. sham results. Significance was $p < 0.05$.

Results: Sham group: left-side disc height was significantly less than right-side disc height (normalized left-right height difference shows inverse disc wedging, Table 1). Tether group: left and right-side disc heights were not significantly different ($p=0.27$). Disc height was less in the tethered vs the sham group (Table 1, $p < 0.01$) with average Tether group disc thickness decreased on the left by 24% and on the right by 34% compared to the Sham group. All discs received a Thompson Grade I upon harvest¹.

Conclusion: Significant wedging away from the instrumentation in the Sham group suggests that the screws alone or the surgical approach affected disc shape. Tethering resulted in thinner, though healthy appearing discs.

1. Newton et al. Spine 2008

The FDA has not cleared the drug and/or medical device for the use described in this presentation (i.e., the drug or medical device is being discussed for an 'off label' use).

14. TNF- β Nco1 Polymorphism in Relation to Postoperative Sepsis Outcome

*Rajeshwar N. Srivastava, MD; Kavita Baghel, MSc; Saloni Raj
India*

Summary: Postoperative sepsis is a major catastrophe and remains a significant cause of morbidity and mortality. Despite adequate antibiotics, source control and good supportive care morbidity remain high suggesting possibility of causal factors yet to be identified. Genetic predisposition and immunosuppression may have a role and need to be examined. TNF- β Nco1 polymorphism has been found to be associated with increased mortality rate in severe sepsis. We therefore postulated that TNF- β Nco1 polymorphism may be associated with postoperative sepsis development.

Introduction: Postoperative sepsis remains a challenge for joint care surgeons. Genetic factors have role in etio-pathogenesis of sepsis. Tumor Necrosis Factor (TNF) is believed to be a cytokine central to pathogenesis of sepsis and the TNF- β Nco1 polymorphism has been found to be associated with increased mortality rate in severe sepsis.

Methods: The study group consisted of 153 patients undergoing major elective surgery. Blood samples were obtained for DNA isolation, Genotyping for TNF- β polymorphism by analyzing restriction fragments of an NcoI-digested DNA fragment using PCR. All patients were followed for 1 month following surgery for any evidence of sepsis as determined by guidelines from Bone et al. Genotypes were then related to the occurrence of postoperative sepsis.

Results: The overall allele frequency for TNF- β genotype was 0.32 for TNFB1 and 0.68 for TNFB2. In TNF- β genotype, homozygous recessive TNFB1 were 17 (11.1%), heterozygous TNFB1/TNFB2 were 63 (41.2%) and homozygous dominant TNFB2 were 73 (47.7%). 125 patients showed an uncomplicated postoperative recovery, while sepsis developed in 28 patients. Genotype distribution in patients with an uncomplicated clinical course was significantly different from that in patients with postoperative sepsis. Development of postoperative sepsis was significantly higher in patients homozygous for the allele TNFB2. When compared with patients carrying at least one TNFB1 allele (TNFB1 homozygous and heterozygous genotype), the TNFB2 homozygous was associated with an OR of 3.39 ($p=0.005$; 95%CI 1.4 to 8.3) for the development of severe sepsis. Compared with the heterozygous genotype, the OR for the homozygous TNFB2 was 5.5 ($p=0.001$; 95%CI 1.78 to 17.33). Although the small number of TNFB1 homozygous surgical patients makes their risk estimate less accurate, the data indicate that both homozygous genotypes possess a significantly increased susceptibility for development of postoperative sepsis compared with the heterozygous genotype.

Conclusion: The NcoI polymorphism within the TNF- β gene influences the postoperative sepsis outcome. TNFB1 and TNFB2 homozygous have a higher risk of developing postoperative infection; although TNFB2 homozygous genotype is more significantly associated with development of postoperative sepsis.

15. Intradiscal Injection of Simvastatin Results in Radiologic, Histologic, and Genetic Evidence of Disc Regeneration in a Rat Model of Degenerative Disc Disease

Khoi D. Than, MD; Shayan Rahman, MD; Lin Wang, MD; Kwaku A. Kyere, BA; Tracey T. Than; Adam Khan, BA; Frank La Marca, MD; Paul Park, MD; Huina Zhang, MD, PhD; Chia-Ying Lin, PhD USA

Summary: Injection of simvastatin into degenerate intervertebral discs may result in retardation of disc degeneration and represents a promising investigational therapy for the conservative treatment of degenerative disc disease.

Introduction: Back pain is a common medical problem, and a large percentage can be attributed to degeneration of the intervertebral disc (IVD). Bone morphogenetic protein-2 (BMP-2) is known to play an important role in the chondrogenesis of the IVD. The drug simvastatin is known to up-regulate the expression of BMP-2. We hypothesized that intradiscal injection of simvastatin in a rat model of degenerative disc disease (DDD) would result in retardation of DDD.

Methods: Disc injury was induced in 272 rats via needle puncture. After 6 weeks, injured discs were treated with simvastatin in saline or hydrogel. Rats were sacrificed at predetermined time points. Outcomes measures assessed were radiologic, histologic, and genetic. Radiologically, the MRI index was determined and then normalized by comparing with non-injured discs. Histologically, disc spaces were read by 3 blinded scorers based on a previously used grading scale. Genetically, nuclei pulposus were harvested and polymerase chain reaction was run to determine relative levels of aggrecan and collagen-type 2 gene expression.

Results: Radiologically, discs treated with 5 mg/ml simvastatin in hydrogel or saline demonstrated MRI indices that were normal through 8 weeks post-treatment; this was more sustained when delivered in hydrogel. Doses > 10 mg/ml were toxic to the disc. Histologically, discs treated with 5 mg/ml simvastatin in hydrogel demonstrated improved grades in comparison with discs treated with 15 mg/ml, confirming the toxicity of higher dosing. Genetically, discs treated with 5 mg/ml of simvastatin in hydrogel demonstrated higher gene expression of aggrecan and collagen type II than control.

Conclusion: In interpreting data for all 3 outcomes measures, degenerate discs treated with 5 mg/ml simvastatin in a hydrogel carrier demonstrated radiographic and histologic features resembling normal, non-injured IVDs. In addition, gene expression of aggrecan and collagen type II (important constituents of the IVD extracellular matrix) was up-regulated in treated discs.

The FDA has not cleared the drug and/or medical device for the use described in this presentation (i.e., the drug or medical device is being discussed for an 'off label' use).

16. Occipital Incidence - A Novel Morphometric Parameter for Understanding Occipitocervical Spinal Alignment

Han Jo Kim, MD; Lawrence G. Lenke, MD; K. Daniel Riew, MD; Yasushi Oshima, MD, PhD; Addisu Mesfin, MD; Jeremy L. Fogelson, MD; Stuart Hershman, MD; Brenda A. Sides, MA USA

Summary: Occipital Incidence is a constant morphometric parameter that can be measured to understand the anatomic relationship between the occipitocervical spine and global spinal alignment. Although other non-morphometric parameters might change, OI is a constant value that is inherent to one's unique anatomy much like pelvic incidence.

Introduction: Since the discovery of Pelvic Incidence as an anatomic constant, our understanding of the lumbopelvic relationship and sagittal balance has improved. However, no such anatomic parameter in the occiput has been established that is intimately related to cervical spine alignment, global sagittal balance and the drive for maintaining forward optical gaze. We aim to introduce a novel morphometric parameter that can be used for understanding the relationship between occipitocervical alignment and global sagittal balance.

Methods: EOS total body X-rays were reviewed and only those which allowed for complete visualization of the occiput to the feet were used. Of the 201 films, anatomic abnormalities, a fixed deformity of the cervical spine or surgery in the cervical spine were excluded leaving a total of 104 for review. Occipital incidence (OI), occipital slope (OS), occipital tilt (OT), cervical lordosis (CL) and standard sagittal balance parameters (SSVA) were measured on each image. (See Figure 1)

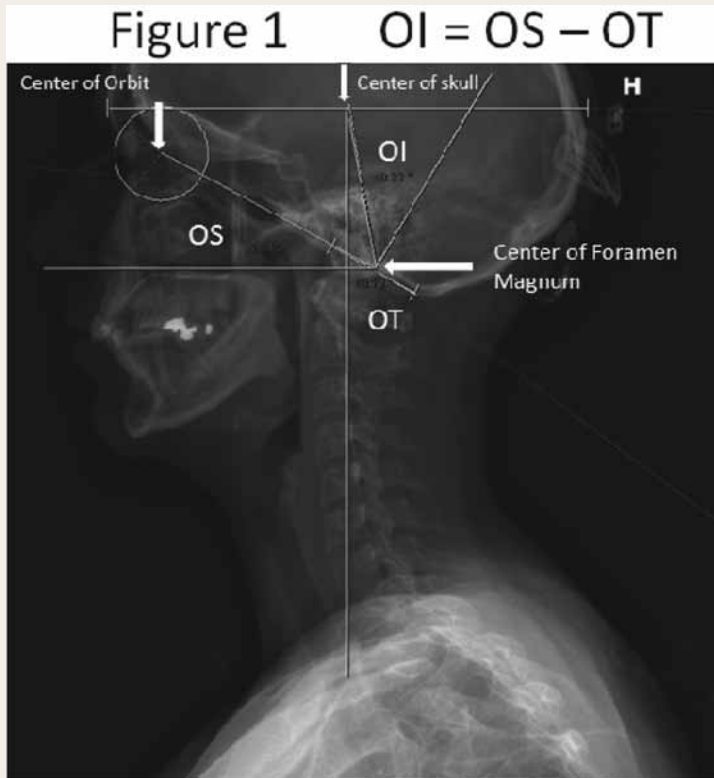
Results: The mean OI was constant through all age groups (OI 34.3 ± 4.3 , 35.1 ± 3.9 , 35.1 ± 3.6 in age groups <40, 40-60 and >60 respectively, $p=0.67$) and despite differences in global sagittal balance (OI 34.6 ± 4.0 , 34.9 ± 4.6 , 34.7 ± 3.5 respectively with SSVA <-2cm, -2 to +2 cm, >+2cm, $p=0.920$).

However, OT increased and OS decreased with increasing age (OT = -12.2 ± 6.9 , -10.8 ± 7.7 , -5.9 ± 8.1 and OS = 22.6 ± 8.0 , 24.3 ± 7.9 , 28.2 ± 7.5 in age groups <40, 40-60 and >40 respectively, $p=0.003$, 0.015). OT and OS also showed a trend to increase with increasing positive sagittal balance (OT = -11.6 ± 8.1 , -10.5 ± 8.6 , -9.7 ± 7.7 , OS = 21.3 ± 7.8 ,

PAPER ABSTRACTS

24.6±7.4, 25.9±8.2 with SSVA <-2cm, -2 - +2 cm, >+2cm respectively, p =0.171, 0.136). One way ANOVA showed no difference between OI and (OS minus OT) (p=0.72) and bivariate correlation analysis showed a moderate statistical relationship between the values (p=0.009) suggesting that OI = OS-OT (r = 0.56, p < 0.001)

Conclusion: OI is a novel morphometric parameter which can be used for better understanding the relationship of the occipitocervical spine to the global sagittal balance and the need for maintaining forward gaze.



OI = Center of Skull to Center of Foramen Magnum to line perpendicular to Foramen Magnum opening (clivus to opisthion) [morphometric] OS = Center of Orbit to Center of Foramen Magnum to Horizontal [non-morphometric] OT = Center of Skull to Center of Foramen Magnum in relation to Center of Skull Plumb Line [non-morphometric]

17. Pedicle Screw Epiphysiodesis of Neurocentral Synchondrosis for Correction of Scoliosis: Histological Evaluation in a Growing Porcine Model

Xuhui Zhou, MD; Hong Zhang, MD; Daniel J. Sucato, MD, MS
USA

Summary: In an immature growing porcine model, an average 46 degree scoliosis was created through unilateral pedicle screw epiphysiodesis of the neurocentral synchondrosis (NCS). The deformity was corrected to measure an average 17 degree via the contra-lateral staged pedicle NCS screw placement. The pedicle NCS screw resulted in a 29% decrease of the hypertrophic zone and a 26% decrease of the hypertrophic cell height to produce a 44% NCS fusion rate, which obtained a 63% correction of the scoliosis.

Introduction: Unilateral pedicle screw epiphysiodesis of the neurocentral synchondrosis (NCS) can create a

scoliosis in a straight immature growing spine. This study was to determine whether the contra-lateral staged pedicle NCS screw placement would correct this scoliosis by histological analysis in a growing pig model.

Methods: Twelve one-month-old pigs were used in this study. Three animals received a sham operation without a pedicle screw fixation. Nine animals underwent the right pedicle NCS screw placement from T7 to T14 to create right thoracic scoliosis. Five of the nine animals were treated with a second set of pedicle NCS screw fixation on the left side at 6 weeks postoperatively to correct the deformity. All animals were euthanized at 17 weeks and radiographed to assess the curve in the coronal and sagittal planes. A quantitative histology of the NCS was performed measuring the NCS fusion rate, the hypertrophic zone (HZ), and the hypertrophic cell (HC).

Results: An average 41 degree scoliosis was created in all 9 animals at 6 weeks postoperatively. In 5 animals, after the second NCS screw placement on the contra-lateral side, the scoliosis was limited and decreased to average 17 degree at 17 weeks postoperatively. The scoliosis in 4 animals which did not receive the second set of screw fixation progressed to 46 degree. No scoliosis was seen in the sham animals at the 17-week follow-up. The second set of pedicle NCS screws resulted in a 29% (p<0.0001) decrease of the HZ and a 26% (p<0.05) decrease of the HC to produce a 44% NCS fusion rate on the contra-lateral side, which obtained a 63% correction of the scoliosis.

Conclusion: The pedicle NCS screw inhibited the overgrowth of the NCS with the decreased HZ and HC height to prevent further curve progression and obtained some correction of the deformity. This study demonstrates a preexisting experimentally created scoliosis can be limited and corrected by modulating the growth of the faster-growing NCS using a contralateral staged pedicle NCS screw placement. This no-fusion strategy may have some role in the treatment of growing patients with spinal deformity.

18. Inflammatory or Mechanical? Can Inflammatory Profiles Predict Outcomes from Lumbar Discectomy for Disc Herniation?

Micah W. Smith, MD; S. Raymond Golish, MD, PhD; Agnes Ith; Ivan Cheng, MD; Gaetano Scuderi; Todd F. Alamin, MD; Kyle A. Mitsunaga, MD; Eugene Carragee, MD; Matthew Smuck, MD
USA

Summary: An inflammatory component of radiculopathy plays an important role in clinical improvement. At 3 months, 81% of patients were "better" as predicted by the presence of FAC (p=0.02) with a 88% PPV.

Introduction: Multiple theories for causes of radiculopathic pain exist including mechanical compression from herniated nucleus pulposus (HNP), chemical/inflammatory, primary nerve injury, and non-spinal neuropathy. Recently, a cartilage degradation product, the fibronectin-aggreacan complex (FAC) identified in the epidural space, has been shown to predict response to lumbar epidural steroid injection in patients with radiculopathy from HNP.

Methods: We conducted a single-center prospective consecutive study of four spine surgeons completing microdiscectomy for radiculopathy for HNP. Intra-operative sampling was done via lavage of the excised fragment by ELISA for presence of FAC. Oswestry disability index (ODI) and visual analog scores (VAS) were noted at baseline and at 3-month follow-up. Primary outcome of clinical improvement ("better") was defined as patients with both a decrease in VAS of at least 3 points and ODI >20 points. A "best case" outcomes was defined as final VAS 0-2 and ODI <20.

Results: 84 patients had full complement of data (91%) and were included in this analysis. At 3-month follow-up, 68/84 (81%) were “better”. There was a statistically significant association of the presence of FAC and clinical improvement ($p=0.02$) with an 88% PPV. 48/84 (57%) met the criteria for “best case”, but only a weak association was found with the presence of FAC and a “best case” improvement ($p=0.3$). Significant variability among the four surgeons was observed in regards to the percent of patients who were FAC positive ranging from 56-89%.

Conclusion: Patients who are “FAC+” are more likely to get “better” following microdiscectomy. However, other factors appear to be involved in those who do “best”, possibly “mechanical”, “neuropathic” or socioeconomic variables. Variability among surgeons and the presence of FAC may be due to differences in practice profiles.

19. Introducing the Early Onset Scoliosis Classification System

Brendan A. Williams, AB; Behrooz A. Akbarnia, MD; Randal R. Betz, MD; Laurel C. Blakemore, MD; John M. Flynn, MD; Charles E. Johnston, MD; Richard E. McCarthy; John T. Smith, MD; Brian D. Snyder, MD, PhD; Paul D. Sponseller, MD; Peter Sturm, MD; George H. Thompson, MD; Muharrem Yazici, MD; Michael G. Vitale, MD, MPH; David P. Roye, MD
USA

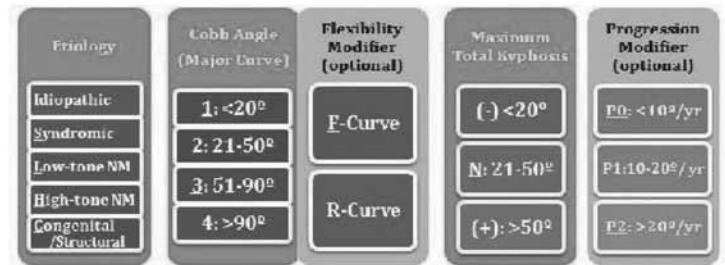
Summary: Early Onset Scoliosis (EOS) is a complex spine disorder seen in young children with a diverse array of co-morbid conditions. Efforts to better understand natural history and management options have been hindered by a lack of evidence in the literature. Our group of experienced pediatric spine surgeons collaborated to develop a consensus-based EOS Classification System to facilitate communication, guide future research, and improve surgical decision making.

Introduction: While the classification of adolescent idiopathic scoliosis has facilitated communication, focused research and informed surgical decision making, the field of early onset scoliosis lacks a similar organizing classification system. The purpose of the current initiative is to create an EOS classification system answering these needs.

Methods: 14 senior members of the Chest Wall & Spine Deformity Study Group and the Growing Spine Study Group took part in an extended Nominal Group Technique consisting of 2 group meetings and iterative surveying. Participants reviewed project goals, proposed a draft classification structure based on literature review findings, and created a list of potential variables. All identified variables were rated on a 3-point Likert scale, and then ranked based on content validity ratio and sum of ranks. Consensus was achieved regarding overall classification structure, final variables, and number of variable subgroups and cut points. Inter- and intra-observer reliability analysis via survey of the study group is underway.

Results: 13 potential variables were identified; Etiology, Cobb angle, Kyphosis, Age, and Progression Rate ranked highest and were retained in the final classification. We determined that Age should be a continuous prefix while Spine Flexibility and Progression Rate should be optional modifiers.

Conclusion: Utilizing a formalized consensus building process among a group of experienced pediatric spine surgeons, a novel Classification System for the field of EOS has been developed. Future study will assess validity as a prognostic tool using real patient data from prospectively gathered EOS databases.



Early Onset Scoliosis Classification System

20. Is the RVAD in Infantile a Reflection of the Spine's Rotation or of the Chest Wall Configuration?

James O. Sanders, MD; Genevieve Foley; Hubert Labelle, MD; Charles E. Johnston, MD; Jacques D'Astous, MD; Stefan Parent, MD, PhD; Carl-Éric Aubin, PhD, PEng
USA

Summary: We evaluated the RVAD on standard radiographs and compared it to both the RVAD in 3D and spinal rotation using 3D reconstructed radiographs in 42 patients with infantile scoliosis. The RVAD in 3D correlated very highly with the RVAD on plain radiographs but neither the RVAD in 3D or 2D correlated well with spine rotation implying that the RVAD is reflective of chest wall deformity rather than spine rotation.

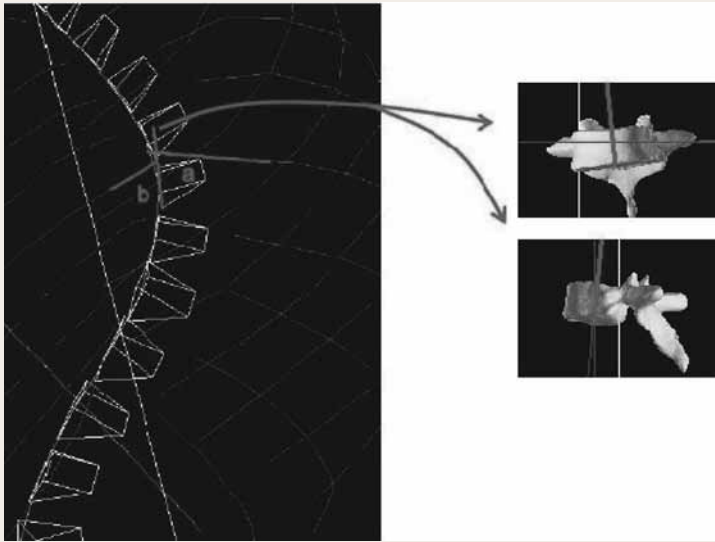
Introduction: The Rib Vertebral Angle Difference (RVAD) is commonly used for prognosis in infantile scoliosis and has been described as prognostic in juvenile scoliosis. However, it is not clear whether the RVAD is a measurement of the rib configuration relative to the spine, a reflection of vertebral rotation, or a combination of the two. The purpose of this study is to evaluate the RVAD in 3D to determine its physical significance.

Methods: The RVAD was measured on PA radiographs for children who could stand and AP radiographs of those who could not yet stand in 42 progressive infantile scoliotic patients according to the method described by Mehta. Cases were divided into Phase I and Phase II according to the rib head overlap with the apical vertebral body on coronal plane radiographs. The RVAD3D was computed using the same landmarks from 3D reconstructions generated from the calibrated bi-planar radiographs using a validated algorithm. The standard RVAD of the apex as well as the vertebral body above and below were compared both to the spinal rotation and the 3D RVAD of the same vertebral levels.

Results: The RVAD on plain radiographs was strongly associated with the RVAD3D ($R^2=0.647$). RVAD and RVAD3D were not associated with spinal axial rotation in the phase I subgroup ($R^2=0.096$ and 0.084 respectively), and were weakly associated in the Phase II subgroup ($R^2=0.333$ and 0.167 respectively).

Conclusion: The RVAD in infantile scoliosis reflects rib configuration relative to the spine with sloped ribs on the convexity and perpendicular ribs on the concavity. It is not a strong indicator of spinal rotation. The RVAD is an important visible radiographic finding in early onset scoliosis and reflects chest wall configuration relative to the spine apart from spinal rotation.

PAPER ABSTRACTS



21. Pulmonary Function Changes During EDF Casting for Early Onset Scoliosis - A Preliminary Report

Shyam Kishan, MD; Robin D. Jenson, MD; Andrew F. Stasic, MD; Stephen Dierdorf, MD USA

Summary: Pulmonary function changes were studied during the application of EDF Casts for early onset scoliosis. Significant decreases in Compliance and Tidal Volume, and increases in Airway Resistance and Peak Inspiratory pressures were noted, none of which returned to baseline at the end of the procedure.

Introduction: While EDF Casting for Early Onset Scoliosis (EOS) has gained popularity and acceptance, little is known about the effects of the cast on Pulmonary Function. Compliance, Tidal Volumes, Airway Resistance and Peak Inspiratory Pressures were studied as measures of pulmonary function in children being casted under general anesthesia for EOS. Preliminary findings from a consecutive series treated by the same surgeon and anesthesiology team, are being reported.

Methods: 12 children (10mo to 8 years) with EOS were brought to the OR for EDF Casting under general endotracheal anesthesia using a standard protocol. Measurements of Compliance (C), Tidal Volume (TV), Airway Resistance (AR) and Peak Inspiratory Pressure (PIP) were made using a Philips M1014A Spirometry Module and airway flow sensor (Philips Healthcare, Andover MA).

Baseline measurements were obtained after intubation, with subsequent measurements before and after spine traction, after cast application, and out of traction after cast windows had been cut out.

Results: Curves ranged from 18 to 87 degrees, with correction from 25% to 62% (Avg 40%).

Results were studied as % deviations from the baseline defined as 100%.

Compliance had the greatest decline, decreasing to 15% of baseline after cast application before returning to 62% of baseline after windows were cut-out.

PIP increased to 247% after casting and returned to 26% above baseline after the windowing.

AR increased to 409% with cast application before improving to 11% above baseline following cast cut-outs.

TV decreased by 47% with casting, most likely because of pressure limitations with volume ventilation, which was set to a maximum PIP of 50 cmH₂O. Windowing improved the TV to 89%.

Transient hypoxemia occurred in one patient, which resolved by removing her from traction and quickly cutting out the windows.

Conclusion: The decreases in Compliance and TV, as well as the increases in PIP and AR, while intuitive, have not been described or quantified yet. The restrictive nature of spinal deformity is further aggravated by the cast. The long term effects of these transient abnormal pulmonary parameters is unknown vis-a-vis barotrauma etc. Further study with longitudinal followup of these patients is under way.

22. The Efficacy and Complications of Dual Growing Rod Technique for Congenital Scoliosis

*Jianguo Zhang, MD
China*

Summary: This is a retrospective study conducted to evaluate the efficacy and complications of dual growing rod technique in treating children with congenital scoliosis.

Introduction: Published reports on dual growing rod technique results for early onset scoliosis demonstrate it to be safe and effective. Until now there has been no reports on the results and complications of dual growing rod technique for congenital scoliosis with large series of patients.

Methods: From 2005 to 2009, 31 patients with congenital scoliosis underwent dual growing rod procedures. Of 167 total procedures within the treatment period, 125 were lengthenings with an average of 4.2 lengthenings per patient. 4 patients with severe rigid deformity or short angular kyphosis had an osteotomy at apex vertebra with short segmental fusion. The Analysis included age at initial surgery and final fusion (if applicable), number and frequency of lengthenings, and complications. Radiographic evaluation included measured changes in scoliosis Cobb angle, thoracic kyphosis, lumbar lordosis, trunk shift, length of T1-S1 and instrumentation

Results: The mean scoliosis improved from 72.3° to 34.9° after initial surgery and was 35.2° at the last follow-up or post-final fusion. T1-S1 length increased from 18.50cm to 29.03cm after initial surgery and to 33.32 cm at last follow-up or post-final fusion with an average T1-S1 length increase of 1.49 cm per year. The length of instrumentation increased from 21.88cm after initial surgery to 24.76cm at last follow-up or post-final fusion. 3 patients reached final fusion. Complications occurred in 7 of the 32 patients, and they had a total of 12 complications. All of patients with complications underwent unplanned surgeries.

Conclusion: The dual growing rod technique is safe and effective for congenital scoliosis. It maintains correction achieved at initial surgery while allowing spinal growth to continue. And it has an acceptable rate of complications. The osteotomy at the apex vertebra with short segmental fusion for the patients with severe rigid scoliosis or short angular kyphosis could help to improve the correction and decrease the implants failures, with little influence to the length of the spine.

23. Scoliosis Creation By Growth Modulation Of The Chest Cage In A Fetal Ovine Model

Stefan Parent, MD, PhD; Jean-Paul Praud, MD, PhD; Sarah Bouchard; Nathalie Samson; Marc Cloutier; Peter O. Newton, MD; Bruno Piedboeuf, MD
Canada

Summary: Thoracic insufficiency syndrome is the inability of the thorax to support normal respiration and lung growth. The objective of this study was to develop an animal model to evaluate the effect of chest deformity on lung development. Following exposure of the fetus through a hysterotomy, a left thoracic deformity was created in 9 lambs by either tying 3 ribs together or adding resection of the 7th rib. Pulmonary lung function was adversely affected.

Introduction: Congenital scoliosis and fused ribs can create a three-dimensional deformity affecting the normal thoracic growth and function resulting in thoracic insufficiency syndrome (TIS). The objective of this study was to develop an animal model to evaluate the effect of chest deformity on pre- and post-natal lung development and volume. There is currently no animal model of chest wall deformity mimicking TIS seen in humans available to study the impact of the chest wall deformity and ultimately the impact of an expansion thoracoplasty.

Methods: Fetal surgery was performed between 65 and 70 days gestation (term:140d) under general anesthesia. Following exposure through a hysterotomy, a left thoracic deformity was created in 15 fetal lambs by either tying ribs together or adding resection of one or two ribs. Pulmonary function tests were performed in vivo and post-mortem for the last 6 lambs.

Results: In total, 14 pregnant ewes underwent a laparotomy and hysterectomy to create a thoracic deformity in 15 fetal lambs. Two lambs died in the very first hours of life from respiratory distress with severe lung hypoplasia (resection of 2 ribs). A third lamb died of failure to thrive and infection 1 month after birth. Deformities ranged from mild to severe with the most severe deformities observed with rib resection. Even though some lambs did not have any significant spinal deformity, the simple removal of two ribs resulted in a mean decrease in respiratory system compliance of 64% and a decrease in inspiratory capacity of 33% compared to normal controls. Similarly, histomorphometric analysis found a severe delay in the development of the distal regions of the lungs as well as in the pulmonary arteries in the affected animals (see Figure A). Although the left lower lobe was the most affected, the impact of the thoracic deformity on the right lower lobe was still significant.

Conclusion: This novel approach is attractive because it mimics a congenital scoliosis as seen clinically very early in infancy. In addition, the possibility to induce a severe thoracic deformity and scoliosis is unique to our ovine model and contrasts with conclusions from previous investigators, who underlined the difficulty of creating a significant scoliosis in a quadruped animal

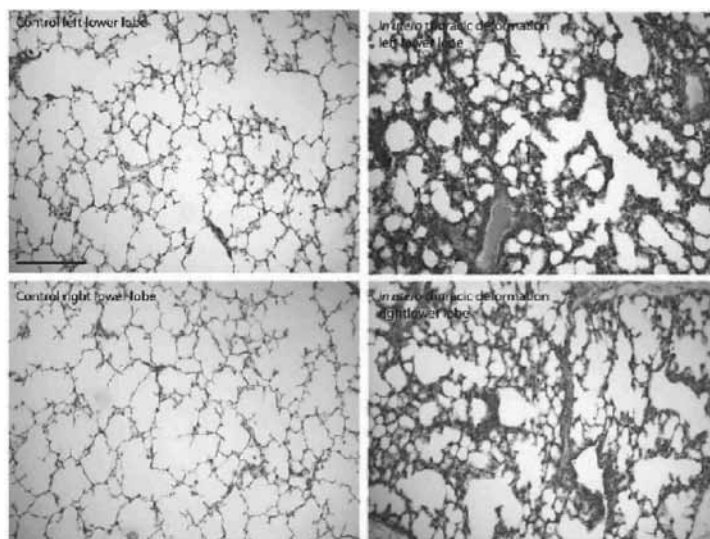


Figure A: Assessment of lung function following in utero thoracic deformation: The panel shows an hematoxylin and eosin coloration of lungs sections from the control and in utero thoracic deformation groups. The antenatal intervention caused an important delay in the development of the distal regions of the lungs as well as in the pulmonary arteries.

24. Convex Growth Arrest in Immature Spine: Comparison of Posterior/Anterior Non-Instrumented and All-Posterior Pedicle Screw Instrumented Fusion in an Animal Model

H Gokhan Demirkiran, MD; Senol Bekmez; Guney Yilmaz; Ibrahim Akel, MD; Pergin Atilla, MD, PhD; Sevdal Muftuoglu, MD, PhD; Muharrem Yazici, MD; Ahmet Alanya
Turkey

Summary: The study was designed to mimic posterior convex growth arrest (CGA) in immature spine and compare two different techniques (all posterior instrumented versus posterior-anterior non-instrumented hemiepiphyodesis). The aim was to evaluate fusion characteristics on anterior and posterior part of the related spine level in macroscopic and microscopic level.

Introduction: The efficacy and safety of CGA/hemiepiphyodesis in treatment of congenital scoliosis have been shown in multiple studies. The posterior/anterior convex growth arrest has been used widely but the technique is invasive and prone to complications. Pedicle screws has been widely used in spine procedures in the last two decades. They have the advantage of controlling all three columns of the spine which may obviate the anterior procedure in CGA.

Methods: Twelve 10-weeks old pigs were used in the study and the animals were grouped into two. In the first group, pedicle screws and a rod construct were applied on the left side of L1-L4 vertebra followed by decortication in order to stimulate instrumented CGA. In the second group posterior followed by anterior fusion was performed in the same surgical session to the left side between L1-L4 vertebrae without instrumentation. The angulation of the spine in coronal plane and the fusion characteristics of the anterior and the posterior spine in macro/microscopic level were evaluated at the end of twelve weeks.

Results: There was complete fusion on both anterior and pos-

PAPER ABSTRACTS

terior sites in all (L1-2, L2-3, L3-4) segments in all animals in the first group. There was complete fusion in all animals except one in the second group. Assessment of fusion with manual palpation in levels L1-2, L2-3 and L3-4 showed no statistically significant difference between groups 1 and 2 ($p>0.05$). There was complete fusion on both anterior and posterior sites in all animals in both groups radiographically. The coronal plane Cobb angle between the proximal and distal instrumented levels were 12.2 ± 2.5 and 9.2 ± 1.3 for the first and the second group, respectively indicating successful hemiepiphyodesis effect. There was significant difference between the groups ($p=0.033$).

Conclusion: The study demonstrated both anterior and posterior epiphyodesis effect of transpedicular screw application macroscopically and microscopically. Anterolateral growth of the vertebra can be controlled by application of posterior transpedicular screws and this finding can decrease the requirement of anterior surgical interventions in the management of children with congenital scoliosis.

Table 1: Mean local kyphosis and scoliosis degrees

	Group 1 mean \pm sd, range	Group 2 mean \pm sd
Kyphosis L1-L4	11.2 \pm 1.0	12.0 \pm 5.2
Scoliosis L1-L4	12.2 \pm 2.5	9.2 \pm 1.3

sd, standard deviation

25. Risk Factors for Postoperative Complication in Treatment of Early Onset Scoliosis Using Growing Rod Technique

Kota Watanabe, Mario Matsumoto, MD, PhD; Koki Uno, MD, PhD; Noriaki Kawakami, MD, DMSc; Taichi Tsuji, MD; Haruhisa Yanagida, MD; Manabu Ito, MD, PhD; Toru Hirano; Ken Yamazaki, MD; Shohei Minami; Hiroshi Taneichi, MD; Shiro Imagama, MD; Katsushi Takeshita, MD; Takuya Yamamoto
Japan

Summary: Multicenter survey in Japan was conducted to determine the risk factors of complications associated with GR for early onset scoliosis. 88 patients had undergone GR under the age of 10 years with a minimum follow-up of two years.. The complications occurred in 57% of the patients. The independent risk factors were hooks for proximal anchor rod lengthening more than 5 times, proximal thoracic scoliosis more than 40°, and lumbar lordosis more than 40°.

Introduction: Growing rod technique (GR) has been widely used for the treatment of early onset scoliosis (EOS). However, relatively high complication rates have been reported. The purpose of this study was to determine the risk factors for postoperative complication in the treatment of EOS using GR by multicenter survey in Japan.

Methods: 88 patients who underwent GR for EOS in twelve spine institutes in Japan were included in this study. All patients had started GR under the age of 10 years with a minimum follow-up of two years. The mean age at the time of surgery was

6.5 ± 2.2 years and the mean follow-up period was 3.9 ± 2.6 years. The etiology of these patients were combined skeletal and visceral anomalies in 31 patients, mesenchymal disorders in 13, neurofibromatosis in 9, neuromuscular in 9, congenital in 8, osteochondrodystro-

phy in 3, and iatrogenic in 1. Multiple logistic regression analysis was performed to determine the independent risk factors of complications from clinical and radiographic parameters (Table).

Results: 119 complications occurred in 538 procedures conducted in 50 patients. The complications included 86 implant-related failures (72%), 19 infections (16%), 3 neurological impairments (3%), and 11 others. Among clinical and radiological parameters (Table), the significant independent risk factors were hooks for proximal anchor (Odds ratio; OR 3.069), rod lengthening more than 5 times (OR 1.647), proximal thoracic scoliosis more than 40° (OR 2.110), and lumbar lordosis more than 40° (OR 1.506).

Conclusion: In this multicenter survey, the complications occurred in 57% of the patients. Since proximal thoracic scoliosis more than 40° and lumbar lordosis more than 40° were the risk factors for the complications, the magnitude of compensatory curves and sagittal profiles should be considered in the decision-making for GR in addition to the magnitude of main thoracic curve.

26. The Safety and Efficacy of a Remotely Distractible, Magnetic Controlled Growing Rod (MCGR) for the Treatment of Scoliosis in Children: A Prospective Case Series with Minimum Two Year Follow-Up

Kenneth M. Cheung, MBBS(UK), FRCS(England), FHKCOS, FHKAM(Orth); Jason Pui Yin Cheung, MBBS (HK); Dino Samartzis, DSc, PhD(C), MSc; Kin Cheung Mak, BSc, MBBS; Yat Wa Wong; Wai Yuen Cheung, MD; Behrooz A. Akbarnia, MD; Keith D. Luk, MD
Hong Kong

Summary: The growing rod has been the gold standard for the treatment of scoliosis in young children. However, such management requires multiple open surgeries under general anesthesia for rod distraction and is associated with numerous post-operative complications. To avoid such pitfalls, we utilized a magnetically-controlled growing rod (MCGR) implant. Our study found that the MCGR was safe and effective, allowing for distractions on a non-invasive out-patient basis at monthly intervals, eliminating the need for surgeries and their associated complications.

Introduction: Traditionally, growing rods are the standard of treatment for young children with severe spinal deformities and significant residual growth potential. However, this requires repeated open distractions under general anesthesia and is associated with numerous post-operative complications. This report addresses the safety and efficacy of the MCGR implant for non-invasive out-patient distractions for scoliosis correction in young children.

Methods: This was a prospective, patient series of the MCGR procedure. From November 2009 to March 2011, five patients (n=3 female; n=2 male) were treated with the MCGR. In this study, we report the first three patients (2 females and 1 male) with minimum 2 years follow-up. All cases were non-invasively distracted using an external magnet on a monthly basis. Pre and post distraction radiographs were carried out to assess the Cobb's angle, predicted versus achieved rod distraction length and spinal length. Clinical outcome assessment was performed with the pain score (Visual Analogue Scale) and the SRS-30 questionnaire. All procedural or rod related complications were recorded.

Results: The main correction of the Cobb's angle was obtained in the initial surgery and was maintained. The mean monthly increase in T1-T12, T1-S1 and instrumented segment length was 1.6mm, 2.5mm and 1.2mm, respectively. Predicted versus actual length gain per distraction were similar. One case had a superficial wound

infection and there was one event of loss of distraction. On last follow-up, no pain was noted and SRS-30 scores remained unchanged to baseline.

Conclusion: The MCGR is a safe and effective procedure for the surgical treatment of scoliosis in children. The MCGR provides external distractions on an out-patient basis without the need for sedation or anesthesia, and that remote distraction allows more frequent lengthening of the rod that may more closely mimic physiologic growth.

27. VEPTR Graduates: Definitive Fusion of Patients Treated with VEPTR at an Early Age

Jahangir Asghar, MD; Ajeya P. Joshi, MD; Joshua M. Pahys, MD; Harry L. Shufflebarger, MD; Timothy D. Uschold, MD; Tricia St. Hilaire, BS; Sumeet Garg, MD; Randal R. Betz, MD; Charles R. d'Amato, MD, FRCSC; Michael G. Vitale, MD, MPH; John M. Flynn, MD; John T. Smith, MD; Amer F. Samdani, MD USA

Summary: No previous studies have evaluated the surgical outcomes for patients undergoing definitive fusion after VEPTR placement. We reviewed 33 patients and report autofusion occurring in half of these patients, with a subsequent coronal Cobb correction of 40%. Our study shows definitive fusion after VEPTR is a feasible and effective treatment with modest ability to correct residual spinal deformity.

Introduction: VEPTR implantation is utilized for conditions such as TIS/EOS. However, little data exists on management of this cohort at maturity. Our study is a retrospective multi-institutional review of patients treated with VEPTR implantation that have had a definitive fusion at maturity.

Methods: A multi-institutional retrospective chart review of 33 patients with definitive fusion at maturity following VEPTR treatment was performed. Radiographic, peri-operative and clinical data was collected. Chi-Square and T-tests were performed when appropriate.

Results: The mean age at VEPTR implantation was 4.2 years and at definitive fusion was 10.35 yrs. The number of operative procedures per patient prior to fusion was 12.75 ± 6.4 . Definitive fusion required extension of proximal fixation at least one level above VEPTR in 36% of patients, and distal extension in 39%. The percent coronal Cobb correction from immediate pre-fusion to 1st erect was 39.8%. However, this was significantly less in patients with congenital scoliosis and fused ribs (15.5%, $p < 0.05$). 48% of patients exhibited instrumentation related auto fusions of the spine and 21% of the ribs at time of definitive fusion. The auto fusion group had a significantly higher number of pre fusion procedures vs. the no auto fusion group (15.1 vs. 7.3, $p < 0.01$). However, there was no statistical difference in diagnosis, complication, age of VEPTR insertion, or number of implant devices. There was a significantly higher EBL in patients that underwent osteotomies vs. none ($p < 0.001$). 4 Intra-operative neuromonitoring changes were noted. No postoperative neurologic deficits documented. 9 of 33 patients were performed in staged manner. 12.2% of patients had a reoperation in the perioperative period. 3 patients required more than one reoperation. 1 patients required re-implantation of VEPTR for coronal imbalance.

Conclusion: Definitive fusion post-VEPTR was feasible and effective in our cohort, with a mean percent correction of 39.8%. Proximal and distal extension of the fusion was commonly performed. High rates of auto-fusion may additionally necessitate multiple osteotomies. A strong need exists for prospective analysis of the maturing VEPTR population to optimize outcomes.

28. Does Scoliosis Surgery Change Lung Volume or Lung Asymmetry in AIS Patients? A Three-Dimensional CT-Based Volumetric Study

Vishal Sarwahi, MD; Beverly Thornhill, MD; Jonathan J. Horn; Elliot Harmon; Meredith Steinman; Terry D. Amaral, MD; Adam L. Wollowick, MD USA

Summary: CT-based volumetric measurement is a relatively new technique that can be used to assess lung volume. Total lung volume and the ratio of left to right lung volume did not change following scoliosis correction. This study suggests that the improvement of pulmonary function after scoliosis surgery may be due to normalization of chest wall mechanics and symmetry.

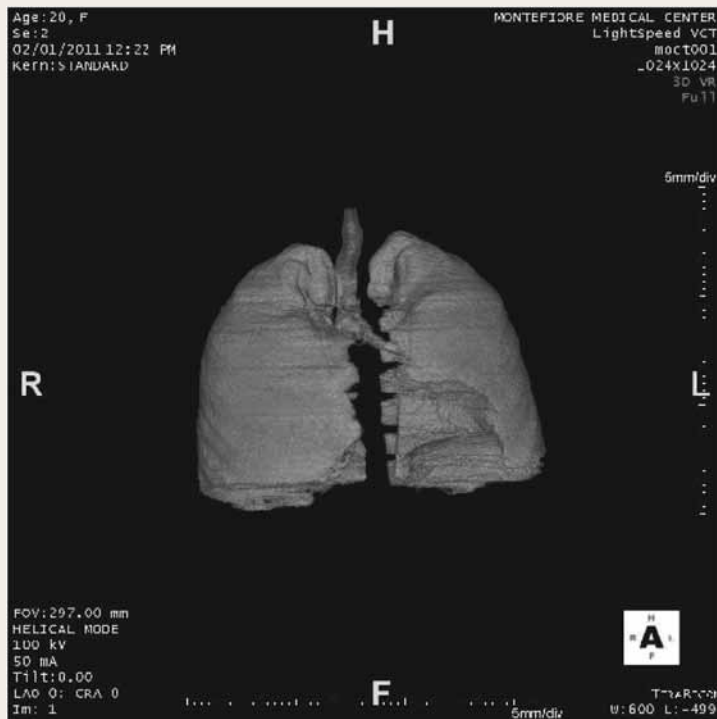
Introduction: Previously published studies have shown that pulmonary function tests improve following scoliosis correction. CT-based volumetric studies in scoliosis patients have previously shown differences in lung volume and lung volume ratio when compared to a normal population. To date, no study exists that analyzes changes in these parameters after scoliosis surgery.

Methods: 30 AIS patients who had pre- and post-op CT scans on file were included in this study. Three-dimensional lung volume reconstruction was performed (TeraRecon software). Appropriate masking methods were utilized to isolate the lung tissue. Total lung volumes, left and right lung volumes, and left/right lung volume ratio were obtained from the pre- and post-op CT scans. Pre- and post-op Cobb angle and kyphosis were also calculated.

Results: Neither total lung volume nor left/right lung volume ratio changed significantly post-op. Surgery did not significantly change total lung volume ($p=0.58$), right lung volume ($p=0.57$), left lung volume ($p=0.64$) or the ratio between right and left lung volumes ($p=0.46$). Mean pre-op major Cobb angle was 55.1° and mean pre-op kyphosis was 33.4° . Post-operatively, the mean major Cobb was 11.7° , resulting in a 79% Cobb correction, and mean postop kyphosis was 30.2° .

Conclusion: Corrective scoliosis surgery does not alter total lung volume or the ratio of right to left lung volume. Deformity correction leads to an improvement in the symmetry of the thoracic architecture and costovertebral joint mechanics. Thus, the change in pulmonary function tests, which has been previously documented, may be a dynamic rather than a static phenomenon.

PAPER ABSTRACTS



Three-dimensional reconstruction of a patient's lungs based upon CT scan. The lung volume is calculated using the reconstructed images.

29. Analyzing the Relationship Between Apical Vertebral Rotation and Truncal Rotation in AIS Using 3D Reconstructions

Krishna Cidambi, MD; Carrie E. Bartley, MA; Tracey Bastrom, MA; Burt Yaszay, MD; Peter O. Newton, MD USA

Summary: There is a correlation between thoracic rib prominence and the apical rotation obtained from 3D reconstructions of 2D radiographs.

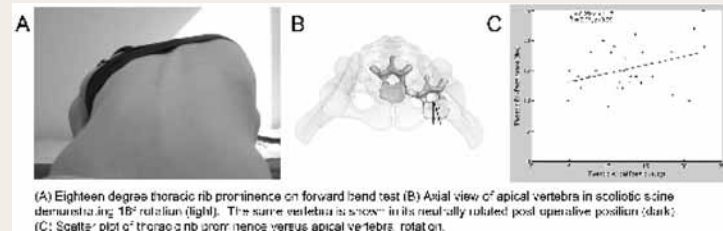
Introduction: The purpose of this study was to evaluate the relationship between apical vertebral rotation in AIS and truncal rotation measured on forward bend via scoliometer.

Methods: Thirty AIS patients with primary thoracic curves (Lenke type 1-2) were included. Simultaneous biplanar 2D radiographs were taken and 3D reconstructions produced using the EOS System (EOS, Paris, France). Thoracic apical vertebral rotations were obtained from the 3D reconstructions. Thoracic rib prominence (angle of trunk rotation) data from the corresponding pre-operative visits were correlated with the apical vertebral rotation using Pearson's correlation analysis.

Results: The apical vertebral and trunk rotation assessments were made at the patients' pre-operative visits. The average thoracic Cobb was $54.9 \pm 9.7^\circ$ (40.5 - 79.3). Thoracic rib prominence averaged $15.3 \pm 3.8^\circ$ (9-25). Thoracic apical rotation averaged $12.7 \pm 5.0^\circ$ (4.8-22.7). A significant, but moderately sized correlation was found between the thoracic apical vertebral rotation and the thoracic rib prominence ($r = 0.37, p < 0.05$).

Conclusion: There is a significant correlation between the thoracic apical vertebral rotation as calculated from 3D EOS reconstructions and the thoracic rib prominence measured by

scoliometer. The regression equation slope indicates an increase of 0.3° in rib hump for every 1° of apical rotation. The y-intercept of 12° indicates the contribution of independent rib deformation to the thoracic prominence. This data supports attempts at more complete transverse plane vertebral correction to assist in the correction of the rib hump deformity of thoracic scoliosis.



30. A Morphological Classification of 120 Cases in Young Idiopathic Scoliosis

Miao Yu, MD; Clement Silvestre, MD; Rami El Rachkidi; Lin Zeng, PhD; Tangyu Mouton; Pierre Roussouly, MD China

Summary: This article is focus on the relationship between the cervical and global spine alignment in young idiopathic scoliosis. A new morphological classification is based on the different global spine curves.

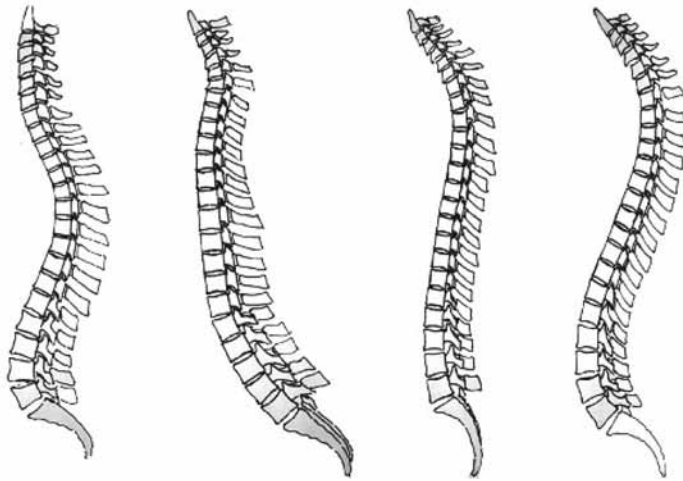
Introduction: A retrospective study of cervical sagittal alignment. To document global spinal and pelvic parameters in the sagittal plane in 120 idiopathic scoliosis. Due to the parameters measured in isolation without a respective etiological analysis in many literature, we attempted to devise a new method of analysis linking cervical kyphosis to thoracic and lumbar curves in idiopathic kyphosis.

Methods: The following values were measured and analysed in utilising KEOPS system: Pelvic Incidence (PI), Pelvic Tilt (PT), Sacral Slope (SS), Spinal Sacral Angle (SSA), Hip to C7/Hip to Sacrum, thoracic and lumbar curves; Roussouly sagittal classification, Lenke Type Curve and Lumbar Modifier; local cervical parameters, inclusive of vertebral plateau angles, height, width and inter-vertebral angles. All of the cases are categorized into four Groups according to their sagittal morphological characters of alignments. Cervical curves are classified as lordosis, straight, sigmoid and kyphosis which allow an analysis examining the relationship between the cervical sagittal curves and the overall global sagittal alignment.

Results: There was a correlation between the cervical and cervico-thoracic curves ($P < 0.05$). This was also reflected within the 4 different groups ($P < 0.05$) in the alignment of cervical spine. A statistical difference exists while comparing the cervical and cervico-thoracic curves, PT, SSA, lumbar lordosis, and thoracic kyphosis before surgery ($P < 0.05$) between the groups. There were statistical relationships between the 4 different cervical groups and the Lenke modifier ($P < 0.005$); the cervical kyphosis and wedging angles in vertebral bodies or intervertebral space ($P = 0.00$ respectively); the vertebral end plate angles and heights in the wedged and normal cervical vertebrae ($P < 0.05$); cervical curves in groups 2 and 3 were different ($P = 0.00$) and so was the thoracic kyphosis in groups 1 and 3 ($P = 0.01$ and 0.03 respectively) postoperatively.

Conclusion: In idiopathic scoliosis the cervical kyphosis plays a role in the presentation and evolution of the cervico-thoracic kyphosis. The cervical kyphosis is attributed to the wedging of the vertebral bodies. There are ameliorations of both cervical spine and thoracic spine curves after surgery.

Group 1 Group 2 Group 3 Group 4



31. The Importance of Sagittal Stable Vertebrae in Adolescent Idiopathic Scoliosis (AIS) Surgery

Wojin Cho, MD, PhD; David Essig, MD; Michael Faloon, MD; Gbolabo Sokunbi; Akilah B. King, BA; Matthew E. Cunningham, MD, PhD; Oheneba Boachie-Adjei, MD USA

Summary: Consecutive AIS patients (Posterior fusion, all pedicle screws, one surgeon, x-ray measurement in PACS, a single investigator) were reviewed for among PJK, DJK and control (C) groups. If the LIVs is located too anterior to the SSVL, the chance of PJK increases whereas if it is too posterior, the chance of DJK increases. Thus postoperative distance between LIV and SSVL can assist in predicting the possibility of PJK or DJK at follow-up.

Introduction: This Sagittal stable vertebra (SSV) has been advocated to be included in posterior spinal fusions for correction of hyperkyphosis. However, there are no studies regarding the importance of the SSV in AIS pts.

Methods: This retrospective review included 380 consecutive AIS pts who underwent the corrective surgery by a single surgeon using all pedicle screw constructs. 135 Pts were identified who had complete radiographic images stored in PACS. After excluding Lenke 5 curve patterns, ant. or combined surgeries, and hybrid constructs, 91 pts were selected. 3 groups were identified: Proximal Junctional Kyphosis (PJK), Distal Junctional Kyphosis (DJK), and Control (C). PJK was defined as > 10° angular change between the sup. endplate of UIV-2 to the inf. endplate of UIV between postop and the final f/u. DJK was defined as > 5° angular change between the sup. endplate of the LIV to the inf. endplate of LIV+1 between postop and final f/u. Regardless of whether or not PJK/DJK occurred before or after 2 yrs, all pts were included. In C, a subset of AIS pts with 2 yr f/u without complications was selected. Various anatomic parameters were measured and compared between the PJK, DJK and C to identify risk factors.

Results: After excluding other complication and short f/u less than 2yrs for C, 7 Pts in PJK (8%), 5 Pt in DJK (5%) and 21 in C remained. First notice of PJK was avg. 0.74 ± 0.56 yr, DJK was avg. 0.47 ± 0.44 yr. Younger age, lower Risser stage, smaller PT and MT curves had significantly more PJK, but not DJK. There was no significant difference among PJK, DJK and C in terms of preop thoracic kyphosis or its correction. However, the distance between LIV and Sagittal Sacral Vertical Line

(SSVL) in postop and final f/u was significantly different in both PJK and DJK compared to C. In contrast to hyperkyphotic pts, SSV was poorly defined in AIS because many pts had hypokyphosis preoperatively.

Conclusion: If LIV is located too anterior than SSVL, the chance of PJK increases. In contrast, if it is too posterior, the chance of DJK increases. The concept of SSV is difficult to apply to AIS. However, the postop distance between LIV and SSVL can predict the possibility of PJK or DJK during f/u.

	C (n=21)	PJK (n=7)	P-value	C (n=21)	DJK (n=5)	P-value
Sex (male=1, female=0)	0.29 ± 0.46	0.14 ± 0.38	0.23	0.29 ± 0.46	0.2 ± 0.45	0.36
Age at Surgery	15.86 ± 2.06	13.71 ± 1.79	0.01	15.86 ± 2.06	15.42 ± 3.01	0.35
Risser	3.83 ± 1.10	2.21 ± 1.68	0.00	3.83 ± 1.10	3.60 ± 1.52	0.35
PT Preop	27.86 ± 12.32	15.00 ± 11.46	0.01	27.86 ± 12.32	32.60 ± 5.73	0.21
MT Preop	56.57 ± 15.70	37.71 ± 11.50	0.00	56.57 ± 15.70	54.40 ± 3.78	0.38
TS-12 Preop	23.95 ± 12.11	29.14 ± 17.26	0.19	23.95 ± 12.11	24.20 ± 3.96	0.48
TS-12 Postop	23.24 ± 7.11	28.43 ± 8.75	0.06	23.24 ± 7.11	24.40 ± 2.07	0.36
TS-12 Final	24.14 ± 8.96	25.43 ± 10.37	0.38	24.14 ± 8.96	29.20 ± 8.29	0.13
TS-12 Postop-Preop	-0.71 ± 7.60	-0.71 ± 13.09	0.50	-0.71 ± 7.60	0.20 ± 4.76	0.40
TS-12 Final-Postop	0.90 ± 5.34	-3 ± 3.37	0.04	0.90 ± 5.34	4.80 ± 6.98	0.09
TS-12 Final-Preop	0.19 ± 8.82	-3.71 ± 14.19	0.20	0.19 ± 8.82	5.00 ± 7.42	0.14
LIV-SSVL Distance Preop	16.48 ± 17.37	22.86 ± 6.67	0.18	16.48 ± 17.37	5.8	0.11
LIV-SSVL Distance Postop	14.90 ± 19.87	29.43 ± 7.50	0.04	14.90 ± 19.87	-2.60 ± 16.79	0.04
LIV-SSVL Distance Final	10.10 ± 18.19	26.29 ± 10.11	0.02	10.10 ± 18.19	-11.6 ± 18.85	0.01

32. Analysis of the Scoliosis Research Society -22 Questionnaire Scores. Is There a Difference between a Child and Parent and does Physician Review Change That?

Adrian Gardner, BM, MRCS, FRCS (T&O); Paul Brewer, BSc, MB, ChB; David S. Marks, FRCS; Jonathan B. Spilsbury, FRCS(Orth); Alistair G. Thompson, FRCS; Fiona Berryman; Paul Pynsent, PhD United Kingdom

Summary: Comparing the SRS-22 scores for child and parent pre and post seeing a physician for the first time showed very little difference in the scores between either the child or parent when compared to themselves or each other. This shows the SRS-22 as a robust instrument and a true reflection of the child's deformity independent of when it is measured. This also shows that the parental assessment is very similar to that of the child.

Introduction: The SRS-22 outcome measure is in common use. However it is not clear whether the SRS score is altered by information from a physician or whether a parents assessment of the deformity is the same as the child.

Objective: 1. To assess whether at initial assessment information imparted by a physician changed the SRS score for a patient or parent scoring independently of the child. 2. To assess whether the SRS score should be assessed before or after consultation to achieve the most accurate representation of the patient. 3. To assess the differences between the patient and parent assessment of the scoliosis using the SRS questionnaire.

Methods: Study Design: Prospective sequential patient series

Subjects: 52 children with adolescent idiopathic scoliosis and their parents were given the SRS-22 questionnaire at first consultation prior to and after meeting the physician. Parents and patients completed the questionnaires in isolation.

Outcome measures: Statistical difference between SRS-22 questionnaire scores before and after first consultation, and between parent and patient.

Results: Assessment and discussion with a physician made

PAPER ABSTRACTS

no statistical difference to the SRS-22 scores for either the patient or the parents when comparing SRS-22 scores before and after consultation in almost all domains. Minimally statistically significant differences were found in a few cases. This was the case for the patient group before and after consultation for the function domain ($p=0.023$), the patient and parent groups before and after consultation for the pain domain ($p=0.025$ and 0.022 for patient and parent groups respectively), the patient and parent groups after consultation for self-image domain ($p=0.024$), and parent group before and after consultation for mental health domain ($p=0.018$). The differences in all these cases were, however, very low and not considered clinically important.

Conclusion: 1. The SRS-22 questionnaire is robust and a true reflection of the patients' assessment of their symptoms not influenced by meeting a physician
2. The assessment of the child by the parent is very similar to that of the patient themselves using the SRS-22 instrument
3. It makes no difference to the total SRS-22 score as to when it is measured in the clinic visit.

33. The Influence of BMI on the Clinical, Radiographic, and Functional Outcomes in Adolescents treated with a Posterior Fusion for AIS

Adriana De La Rocha, MS; Anna M. McClung, RN; Daniel J. Sucato, MD, MS
USA

Summary: In patients treated with a PSF for AIS, BMI influenced pre-operative and post-operative outcome scores, with Overweight group scoring lower in the Mental, Appearance, and Pain relief domains than patients in the Normal or Underweight groups. BMI did not affect the ability to achieve coronal correction, although overweight patients did have significantly higher pre and post-operative thoracic kyphosis.

Introduction: The proportion of underweight and overweight adolescents has increased in the last decade. Previous studies have reported the correlation of Body Mass Index (BMI) with non-spine surgical outcomes, however only a few reviewed the correlation of BMI to outcomes following spine surgery.

Methods: Retrospective review of all patients who underwent a PSF for AIS from 2002-2009 at a single institution. There were 3 categories: Underweight (UW) ($BMI < 18.5$), Normal (NML) ($BMI > 18.5-24.9$), and Overweight (OW) ($BMI > 25$); % correction of the Major curve was collected at 2 yrs post-op and SRS Patient Outcome scores were analyzed at pre-op and 2 yrs post-op. Differences between groups were analyzed using ANOVA with $p < 0.05$.

Results: 459 patients (380 females, 79 males) at an avg age of 15.0 yrs (10.0-21.3 yrs) treated with a PSF were included. The groups included 272 NML pts, 80 OW pts, and 107 UW pts. There were no significant differences between the groups with respect to blood loss and surgical/anesthesia time. There were no significant differences between pre-operative Cobb angles, although the OW group had a higher thoracic kyphosis (32) than the UW (24, $p=0.001$) and NML group (26, $p=0.003$). At 2 yrs, all groups achieved and maintained equal % correction with no differences between groups. Regarding pre-operative SRS Outcome scores, the OW group reported more pain than the NML ($p=0.002$) and the UW groups ($p < 0.001$) despite less reported activity than NML ($p=0.033$) and UW pts ($p=0.005$). The

total SRS score was also lower in the OW pts compared to NML pts ($p=0.009$) and the UW ($p=0.002$). At 2 yrs, the OW group reported more pain than the UW ($p=0.031$) and NML groups ($p=0.018$), and lower mental scores ($p=0.011$) and lower SRS Total scores ($p=0.005$) than the NML group.

Conclusion: Although pre-operative BMI did not influence the ability to achieve correction with a PSF in adolescents, it did affect self-reported patient outcome scores with OW adolescents reporting lower scores after surgery. This information may help with pre-operative counseling of OW pts by stressing that their own assessment of outcome is influenced by BMI which may help promote a healthy weight management program in this patient group.

34. Pedicle Screw Instrumentation Does Not Cause Hypokyphosis Following the Surgical Correction of AIS

Adam L. Wollowick, MD; Terry D. Amaral, MD; Elliot Harmon; Jonathan J. Horn; Preethi M. Kulkarni, MD; Yungtai Lo; Vishal Sarwahi, MD
USA

Summary: Pedicle screw instrumentation has been reported to produce hypokyphosis in the surgical treatment of AIS. This study analyzed a variety of patient, curve, and surgical factors to determine if pedicle screws truly cause hypokyphosis. The previously reported hypokyphosing effect was not seen in this study. Pedicle screws allowed maintenance of kyphosis as well as correction of pre-op hypokyphosis in 57% of cases.

Introduction: Pedicle screw instrumentation in AIS has been shown to produce hypokyphosis. Contributing factors may include rod size, rod material, and correction maneuvers. This study seeks to evaluate the ability of pedicle screws to maintain normal kyphosis or restore normal kyphosis in patients with preoperative hypokyphosis.

Methods: 110 AIS patients who underwent posterior spinal fusion utilizing pedicle screws between 2004 and 2009 were evaluated for kyphosis (T3-12), sagittal balance and proximal junction kyphosis ($> 10^\circ$). Preoperative, immediate post-op, one- and two-year post-op x-rays were reviewed. Charts were reviewed for patients and curve characteristics and intra-operative maneuvers, including DVR.

Results: 43 patients had a complete set of data at two year follow up. 63 patients (57%) had normal pre-op kyphosis. Immediately post-op, 72% of patients had normal kyphosis. This increased to 74% at one year and 69% at two years. The change was not statistically significant. Rod translation, rod derotation and DVR were not found to have a hypokyphosing effect. Patient and curve characteristics, length of fusion, LIV, and number of screws were not found to have a significant effect on kyphosis. Of the patients with 2 year follow-up, 67% had normal preoperative kyphosis. 83% of patients who started with normal pre op kyphosis maintained normal kyphosis at 2 years. 17 % of these patients had hypokyphosis post op and remained unchanged at two years. 57% of patients with preoperative hypokyphosis were restored to normal thoracic kyphosis which was maintained at two year follow up. Patients did not significantly change their sagittal balance over a two year follow up. High strength rods were utilized in 51% of patients. The use of high strength rods did not improve the ability to maintain or restore thoracic kyphosis. There was no significant incidence of PJK.

Conclusion: In this study, pedicle screws did not produce hypokyphosis as previously reported. No specific curve characteristics or surgical maneuver was found to reduce kyphosis in AIS patients. Pedicle screws allow the surgeon to maintain kyphosis in

patients with normal kyphosis at baseline. Further attention needs to be paid to patients with pre-op hypokyphosis as only 53% were normalized.

35. Does Anterior Release Prevent Adding-On following Thoracic Fusion for Lenke 1 Adolescent Idiopathic Scoliosis?

Steven D. Glassman, MD; B. Stephens Richards, MD; Lawrence G. Lenke, MD; Daniel J. Sucato, MD, MS; Kathryn J. McCarthy, MD; Leah Y. Carreon, MD, MSc
USA

Summary: In a study to determine whether anterior thoracic release alters risk for distal adding-on following posterior thoracic fusion for Lenke 1 AIS, the incidence of adding-on and radiographic and clinical outcomes was similar in matched Lenke 1A/1B AIS treated by anterior release/posterior fusion versus posterior fusion alone. Anterior release prior to a posterior thoracic fusion may not be a useful strategy to control distal adding-on for Lenke 1A/1B AIS.

Introduction: Distal adding-on after posterior thoracic fusion for Lenke 1 Adolescent Idiopathic Scoliosis (AIS) has recently been reported to be more common than previously recognized [Wang]. The study postulates loss of initial spontaneous compensatory lumbar curve correction to be the mechanism, and that lowest instrumented vertebrae (LIV) as the primary determinant. Although LIV may be pivotal, anterior release has been a common strategy to limit fusion levels and minimize risk of progression for thoracolumbar curves. The purpose of this study was to determine whether anterior thoracic release alters risk for distal adding-on following posterior thoracic fusion for Lenke 1 AIS.

Methods: A prospective cohort of surgically treated AIS patients was queried for Lenke 1A/1B cases treated by anterior release/posterior fusion (A/P). A cohort treated by posterior fusion only (PSF) was identified; matched by Lenke type, Cobb magnitude, age and LEV. Primary outcome measure was the incidence of adding-on (LIV minus LEV) at 1 and 2 years postop.

Results: There was no statistically significant difference in demographics, Cobb angle, LEV and pre-op SRS scores between groups. The LIV, the LIV in relation to the neutral vertebra and in relation to the CSL was also similar between groups. The proportion of patients having pedicle screws versus hooks was similar in both groups as well. The blood loss (A/P:1395 mL vs PSF:788 mL, $p=0.001$) and surgical time (A/P:409 mins vs PSF:269 mins, $p<0.0001$) was greater in the A/P group. The incidence of adding on was similar between the two groups at one year (A/P:10 vs PSF:6, $p=0.347$); more so at two years (A/P:7 vs PSF:6, $p=1.000$). The SRS scores at one and two years were also similar between groups.

Conclusion: Incidence of adding-on was similar in matched Lenke 1A/1B AIS treated by A/P versus PSF. Radiographic and clinical outcomes were also similar. The only observed differences between the groups were greater blood loss and surgical time in the A/P cohort. Anterior release prior to a posterior thoracic fusion may not be a useful strategy to control distal adding-on for Lenke 1A/1B AIS. Further study is needed to assess the impact of posterior releases on distal adding-on and maintenance of compensatory curve correction.

36. Preoperative Metal Allergy Testing for Adolescent Idiopathic Scoliosis Patients

Charles T. Mehlman, DO, MPH; Michelle B. Lierl, MD; Maureen Grady, RN; Cassie L. Kirby, BA, CCRP
USA

Summary: Routine preoperative metal allergy testing for a consecutive series of Adolescent Idiopathic Scoliosis (AIS) patients yielded a 32% positive rate.

Introduction: The purpose of our study was to perform metal allergy testing on all patients presenting to one surgeon for posterior spinal fusion (PSF) with instrumentation for AIS.

Methods: Over an 18 month period (3-08 through 9-09) all patients presenting for PSF for AIS underwent metal allergy testing as part of their preoperative assessment. Standard metal allergy patch testing was performed and interpreted by a Pediatric Allergist/Immunologist.

Results: Twenty-five patients underwent metal allergy testing. There were 21 females and 3 males. The average age of the patients was 14 years with a range from 12 years to 20 years. Eight out of 25 patients (32%) were found to have a metal allergy. Six were allergic to nickel, 1 was allergic to both nickel and cobalt, and 1 was allergic to chromium.

Conclusion: Routine preoperative metal allergy testing for a consecutive series of AIS patients yielded a 32% positive rate. Preoperative knowledge of a patient's metal allergy status is potentially very valuable information.

37. Clinical Complications following rhBMP-2 Use in a Minimally Invasive Transforaminal Lumbar Interbody Fusion

Kern Singh, MD; Miguel A. Pelton, BS; Thomas D. Cha, MD, MBA; Safdar N. Khan, MD
USA

Summary: Management and surgical treatment of these complications has a substantial cost for the patient and surgeon and needs to be considered with the off-label use of rhBMP-2.

Introduction: Recent reports of post-operative radiculitis, bone osteolysis, and symptomatic ectopic bone formation after rhBMP-2 use in transforaminal lumbar interbody fusions (TLIF) are a cause for concern.

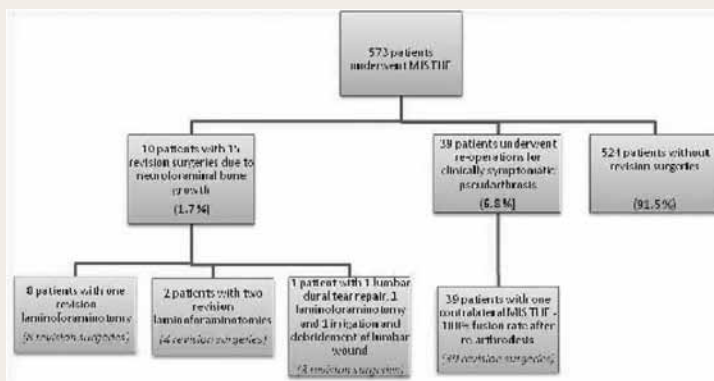
Methods: After IRB approval, a retrospective review of all patients undergoing an MIS TLIF (single surgeon) at our institution was performed. All patients underwent a minimally invasive laminectomy with bilateral facetectomy, single transforaminal lumbar interbody fusion cage, unilateral pedicle screw fixation and 12 mg (Large kit) or 4.2 mg (small kit) of rhBMP-2. The BMP-2 collagen-soaked sponge was placed anteriorly in the disc space, followed by local bone graft, and then the cage filled only with local bone and no BMP-2. Patients were evaluated at 6 months and 1 year with CT scan. CT scans demonstrating neuroforaminal bone growth, osteolysis or cage migration were reviewed and cost data including direct cost/procedure for both index and revision surgeries were collected.

Results: A total of 573 patients were identified that underwent MIS TLIF with rhBMP-2 (2007-2010) with at least 1 year of post-operative follow-up and CT imaging. The mean age was 48.7 (Range 27-82). Of the 573 patients, 10 (1.7%) required an additional 15 procedures based upon recalcitrant radiculopathy and CT evidence of neuroforaminal bone growth, vertebral body osteolysis, and/

PAPER ABSTRACTS

or cage migration. A total of 39 patients (6.8%) required re-operation for clinically symptomatic pseudarthrosis (Figure 1). Bone overgrowth was associated with nerve impingement and radiculopathy in all 10 patients (small kit, n=9; large kit, n=1). Osteolysis and cage migration occurred in 2 (18%) of these same 11 patients. Average total costs were calculated per procedure (\$19,224), and additional costs equaled \$14,785 per encounter. There were no cases of asymptomatic neuroforaminal bone growth or osteolysis.

Conclusion: Symptomatic ectopic bone formation, vertebral osteolysis and pseudarthrosis are recognized complications with the use of rhBMP-2 in minimally invasive transforaminal interbody fusions. Potential causes include improper dosage and a closed space that prevents the egress of the post-operative BMP-2 fluid collection.



The FDA has not cleared the drug and/or medical device for the use described in this presentation (i.e., the drug or medical device is being discussed for an 'off label' use).

38. Catastrophic Complications Following Minimally Invasive Lateral Lumbar Interbody Fusion

Armen R. Deukmedjian, MD; Juan S. Uribe, MD; Donald A. Smith, MD
USA

Summary: In this retrospective study, we examine all consecutively enrolled patients undergoing minimally invasive lateral lumbar interbody fusion from 2008-2011 for catastrophic injuries, including bowel or great vessel injury. None occurred in 425 cases. We believe it is important to report and discuss these injuries in order to better understand and prevent these complications from occurring. Based on our data, this procedure is a safe and reproducible technique for interbody fusion.

Introduction: The minimally invasive lateral retroperitoneal transpsoas approach for lumbar interbody fusion continues to gain in popularity. Complications of this increasingly utilized procedure need to be examined and reported. The objective of this study is to review the incidence of catastrophic complications encountered during minimally invasive lateral lumbar interbody fusion (MIS LLIF) in a single academic institution.

Methods: 425 patients underwent single and multi-level MIS LLIF (XLIF, Extreme Lateral Interbody Fusion, Nuvasive®, San Diego, CA) from 2008 to 2011. Patients were retrospectively evaluated for catastrophic complications unique to this approach. This included bowel perforation and major blood vessel injury (aorta, inferior vena cava, and common iliac vessels). Lumbar plexus injuries producing transient anterolateral thigh numbness, though common

with this approach, were not included as catastrophic complications. Intraoperative electromyographic monitoring was performed in all cases.

Results: Records of 425 consecutively enrolled patients (mean age 53.4, range 29-75) undergoing the MIS LLIF procedure were examined. Mean follow up was 14 months, ranging from 1-36 months. In this series of 425 patients, no catastrophic complications occurred. Although unlikely for a delayed bowel injury to manifest in one of the more recent surgeries, it is theoretically possible.

Conclusion: The minimally invasive lateral lumbar interbody fusion technique is technically demanding and has the potential for significant morbidity. Complications of this approach need to be reported and efforts to better understand and prevent these complications need to continue. Based on our experience, the MIS LLIF is a safe and reproducible alternative to other interbody fusion procedures with a low risk of catastrophic complications.

39. Outcomes of Three Different Techniques Using the Lateral Approach for Lumbar Interbody Arthrodesis

Michael R. Briseno, MD; Stefan A. Mindea, MD; Robert T. Arrigo, BS; Shashank Ravi; Navpreet Bains, BS; Todd F. Alamin, MD; Ivan Cheng, MD
USA

Summary: Outcomes data for the minimally invasive lateral approach to the lumbar spine is sparse. This is a retrospective review of 126 patients who underwent one of three variations to this approach. The rate of adverse events was 25.4% amongst all groups. This was felt to be secondary to psoas stretch intra-operatively. The transpsoas approach with neuromonitoring appears to have the lowest rate of adverse events when compared to the psoas retraction and the transpsoas under direct visualization groups.

Introduction: Historically, interbody arthrodesis for the lumbar spine has been performed through open surgical approaches. Recently, there has been substantial growth in the utilization of the minimally invasive lateral approach (LIF) with sparse outcomes data reported. This is a retrospective review performed with multiple surgeons from Orthopaedic and Neurosurgery spine backgrounds.

Methods: All patients at a single institution undergoing LIF from July 2008 until July 2011 were reviewed. Data extraction included demographics, peri-operative parameters as well as radiographic analysis of fusion as described by Eck, et al. Three different approach techniques were identified: 1) anterolateral (AL) with retraction of the entire psoas muscle, 2) shallow docking (SD) superficial to the psoas with directly visualized dissection through the psoas, and 3) traditional transpsoas (TP) dissection using neuromonitoring. Outcome measures included radiographic fusion, adverse event (AE) rate, revision surgery rate, Visual Analog Scale (VAS), and Oswestry Disability Index (ODI) scores.

Results: 126 patients were identified, 81 were male and 45 female. Average age was 61.8 years (22-86 years). 25.4% of patients had one or more AE. 13 patients (10.3%) had anterior/lateral thigh paresthesias, 9 had intractable radiculopathic pain, and 3 had post-operative weakness. There was one case each of graft/instrumentation failure, superficial wound infection, ileus, and three cases of stroke. Four patients returned to the OR. There was a 31.6% rate AE in the AL group (p<0.16), 31.0% rate with the SD group (p<0.21), and a 19.0% rate with TP group (p<0.28). 99.1% of patients had Grade A/B anterior fusion based on most current radiographs. VAS scores for back and leg pain improved from 6.3 to 3.7 (p<0.002)

and 5.9 to 3.7 ($p < 0.009$), respectively. ODI scores improved from 43.4 to 33.1 ($p < 0.17$).

Conclusion: In this study, 25.4% of patients sustained a post-operative AE following LIF. The episodes of paresthesias, weakness and radiculopathy were felt to be secondary to lumbar plexus stretch. The TP approach appears to have the lowest rate of AE when compared to other approaches.

40. Anterior vs. Posterior Procedure for Surgical Treatment of Thoraco-Lumbar Tuberculosis: A Retrospective Analysis

Pankaj Kandwal, MS (Ortho); Bhavuk Garg; Upendra Bidre, MS; Ankur Goswami, MS (Ortho); Arvind Jayaswal, MS (Ortho)

India

Summary: Tuberculous infection is still a "burning" problem in developing countries.

Introduction: Approach for surgical treatment of thoraco-lumbar tuberculosis has been controversial. The aim of present study is to compare the clinical, radiological and functional outcome of anterior versus posterior debridement and spinal fixation for the surgical treatment of thoracic and thoraco-lumbar tuberculosis.

Methods: 70 patients with spinal tuberculosis treated between Jan 1999 to Dec 2009 were part of the study. 34 patients (Group I) mean age 34.9 yrs (21-50 yr) underwent anterior decompression and spinal instrumentation by anterior transthoracic/ transpleural or transthoracic retroperitoneal diaphragm cutting approach, 36 patients (Group II) mean age 33.6 yrs (18-56 yr) were operated by posterolateral decompression and reconstruction with cage and posterior instrumentation. Average follow-up being 52 mths (range 24-128mth).

Results: Group I (Anterior group) The mean surgical time was 5hr 10min (3hr 45min-7hr 30min) while blood loss in Group I was 900ml (500- 1000ml). mean preoperative local Kyphosis was 44.6degree (25 - 58degree), which corrected to a mean of 21.29 degree (14- 26degree) in postoperative radiographs. Group II (Posterior group) mean surgical time was 4hr 50min (3hr 50min- 6hr 30min), while 1100ml (700-1800ml) blood loss. the mean preoperative kyphosis 74.6 degree (48 - 86degree) was corrected by a mean of 20.29degree (14 - 28degree).

All the patients in Group I showed fusion: while in Group II, fusion was seen in 97.22% ($n=35$), and no fusion in 2.77% ($n=1$) of patients. Injury to lung parenchyma was seen in one patient in Group I while the anterior procedure had to be abandoned in one case due to pleural adhesion.

There was no statistically significant difference in the outcome of the approaches as far as the fusion, blood loss, duration of procedure & recovery of neurology was concerned. Kyphosis correction in Anterior group (Group I) was 52.27% while in Posterior group (Group II) was 72.8% which was statistically significant.

Conclusion: Anterior approach is an equally good method for debridement and stabilization in TB spine but the kyphus correction is better with posterior instrumentation and posterior approach is associated with less morbidity and complications

41. Adverse Events in Emergent Oncologic Spine Surgery: A Prospective Analysis

Nicolas Dea, MD, FRCSC; John Street, MD, PhD; Michael Boyd, MD; Scott Paquette, MD, FRCSC; Brian K. Kwon, MD, PhD, FRCSC; Marcel F. Dvorak, MD, FRCSC; Charles G. Fisher, MD, MHS, FRCSC
Canada

Summary: Reporting on the morbidity and mortality of spine surgery in the literature has been primarily retrospective. We report on a prospective cohort of patients with

metastatic epidural compression. Adverse events occurred in half of our population. When collected in a rigorous prospective manner, metastatic spine surgery is associated with a higher morbidity than previously reported

Introduction: Reporting on the morbidity and mortality of spine surgery in the literature has been primarily retrospective. Emerging prospective analyses of adverse events (AE) demonstrate significantly higher rates, suggesting under reporting in retrospective and prospective studies without AE as a targeted outcome. Emergency oncologic spine surgeries are generally palliative, to improve pain, neurology and health related quality of life. With limited life expectancy, adverse events can have catastrophic implications; therefore an accurate AE incidence must be considered in the surgical decision making.

Methods: Prospective cohort study in a quaternary care referral center of consecutive patients between January 1, 2009 and December 31, 2010. Inclusion criteria were all patients undergoing emergency surgery for metastatic spine disease. AE data was reported and collected on standardized AE forms (SAVES) at weekly-dedicated M&M rounds attended by surgeons, house staff and nursing. AE, were categorized as major and minor based on a priori criteria.

Results: 45 patients met inclusion criteria, 24 males and 21 females. Data is complete in 100% (45 patients). Fifty percent had at least one adverse event. A total of 43 adverse events were noted in 16 patients. Three patients (9.4%) died during their admission. Intra operative surgical adverse events were observed in 12.5% of patients (3.1% incidental durotomy, 9.4% major blood loss above 2 liters). Neurologic deterioration occurred in 2 patients (6.3%). Cumulative incidence of infectious complications in the patient population was 37.6% (surgical site: 6.3%; systemic: 31.3%). Delirium complicated the postoperative period in 15.6% of cases.

Conclusion: When evaluated in a rigorous prospective manner, metastatic spine surgery is associated with a higher morbidity than previously reported. This AE incidence must be considered by the patient, oncologist and surgeon in determining appropriate management and preventative strategies to reduce AE in this fragile patient population.

42. Does Patient Diagnosis Predict Blood Loss during Posterior Spinal Fusion in Children?

Amit Jain; Dolores Njoku, MD; Paul D. Sponseller, MD
USA

Summary: Patient diagnosis, adjusting for extent of fusion and patient weight, is significantly related to intraoperative blood loss during posterior spinal fusion surgery for deformity correction in children. (Prognostic Level II)

Introduction: The purpose of this study was to assess the relationship between patient diagnosis and blood loss in children undergoing posterior spinal fusion surgery for deformity correction. To our knowledge, this relationship has not been well established in the literature.

Methods: Clinical records were reviewed for all patients 10 to 18 years old who underwent spinal fusion surgery (at least 5 levels) by the senior author from 2001 through 2011. Patients were excluded for: antifibrinolytic use, vertebral column resections, prior spinal surgery, non-pedicle screw instrumentation, cervical spine fusion, or anterior approaches.

PAPER ABSTRACTS

The 617 patients (with 37 diagnoses) were categorized into 5 groups: idiopathic scoliosis (IS), Scheuermann's kyphosis (SK), cerebral palsy, other neuromuscular disorders, and genetic and syndromic disorders. Multivariate regression analysis was used to assess differences in blood loss across the diagnostic groups. Normalized blood loss (NBL) was calculated by dividing blood loss by number of levels fused and by patient's weight; NBL differences between groups were analyzed using Bonferroni correction. Significance was set at $P < 0.05$.

Results: Blood loss differed significantly by diagnostic group, adjusting for extent of fusion and patient weight ($P < 0.01$). Patients with cerebral palsy had a significantly higher NBL than patients with IS ($P < 0.01$), SK ($P < 0.01$), other neuromuscular disorders ($P = 0.049$), and genetic and syndromic disorders ($P < 0.01$). Patients with other neuromuscular disorders had a significantly higher NBL than patients with IS ($P < 0.01$) and SK ($P < 0.01$). Patients with genetic and syndromic disorders also had a significantly higher NBL than patients with IS ($P < 0.01$) and SK ($P < 0.01$).

Conclusion: There is a significant relationship between patient diagnosis and blood loss during posterior spinal fusion surgery in children. Pediatric patients with cerebral palsy have significantly more blood loss than those with idiopathic scoliosis, Scheuermann's, and other neuromuscular, genetic and syndromic causes of spinal deformity. Surgeons should be cognizant of the relationship between patient diagnosis and blood loss when planning spinal deformity correction surgery.

43. EMG Alone Can Be Misleading For Assuring Safe Entry During Transpoas Access to the Lumbar Spine

Vidya Bhalodia; Shirivinda Wijesekera, MD; Anthony K. Sestokas, PhD; William C. Loftus, PhD; Judith L. Gorelick, MD; Patrick Tomak, MD; John M. Beiner, MD; Daniel M. Schwartz, PhD
USA

Summary: EMG testing has been promoted for assuring safe lateral access to the lumbar spine. Despite its popularity, results can be misleading. tceMEP monitoring is a viable adjunct to EMG alone for improved surgical decision-making during these lateral procedures.

Introduction: EMG mapping has been highly promoted by implant manufacturers to assure safe passage through the psoas muscle for lateral access to the lumbar spine. While there are no universal criteria for determining relative neural proximity based on depolarization threshold, a gross rule is that values ≤ 3 mA denote direct neural contact, 4-6 mA at least minimal working space for dilator access, 7-9 mA reasonably safe distance from nerve, and ≥ 10 mA no neural threat. There are increasing reports of post-operative weakness even when EMG suggested acceptable neural distance. tceMEP monitoring has proven efficacious in assessing functional neural integrity beyond EMG. This study evaluated the addition of tceMEP monitoring for aiding in surgical decisions about safe access during the transpoas approach.

Methods: EMG and tceMEP monitoring was performed on 44 consecutive patients. EMG was used to estimate neural proximity and mechanical irritation, and tceMEP functional integrity.

Results: 18 patients had EMG thresholds ≥ 10 mA and uneventful tceMEP monitoring; none had new neural deficit. EMG thresholds ≤ 3 mA were noted in 6 patients, 2 of these had marked tceMEP loss that improved on retractor removal. Absence of tceMEP change for the 4 others supported proceeding

without modification despite the EMG "red-alert". Of the remaining 20 patients, 5 had tceMEP loss that resolved in 4 upon retractor removal. The other patient awoke with quadriceps weakness. EMG suggested minimal safe workspace in 3 of these 5 patients and moderate safe passage in the remaining 2. Continuous spontaneous EMG was insensitive to nerve stretch effects.

Conclusion: Sole reliance on EMG monitoring to determine safe transpoas access to the lumbar spine can mislead the surgeon into altering the surgical course unnecessarily, or having a false sense of neural security. tceMEP monitoring is recommended as an EMG adjunct to guide transpoas decision-making.

44. Implant Survival After Deep Surgical Site Infection Following Instrumented Spine Surgery

Susana Núñez Pereira, MD; Ferran Pellise, MD; Dolores Rodríguez-Pardo, MD, PhD; Carles Pigrau, MD; Juan Bago, MD; Carlos Villanueva, MD, PhD; Enric Caceres
Germany

Summary: Survival analysis of 43 patients who developed surgical site infection (SSI), considering as terminal event the need for implant removal. Survival decreased progressively during the first two years of follow-up, showing that mid-long term consequences of SSI are probably underestimated.

Introduction: Deep SSI after instrumented thoracolumbar spine surgery is a major complication that can considerably affect the outcome of surgery. SSI treatment efficacy and its final consequences are under-reported. Our aim was to evaluate long-term implant survival after SSI, and associated risk factors.

Methods: 43 patients (mean age 52.1 y, SD 20.6; 60.5% women) operated at the same centre between January 2006 and December 2008, consecutively developed acute postoperative SSI. Preoperative diagnoses were: 15 degenerative lumbar disease, 13 scoliosis, 10 fractures, 6 tumours. All patients were properly treated under surveillance of the infectious diseases department with surgical debridement and antibiotic therapy for a minimum of 8 weeks, based on culture and antibiogram.

Kaplan-Meier survival analysis and Cox proportional risks analysis were performed. Terminal event was defined as implant removal (IR) or death related to SSI. The mean follow-up was 26 months.

Results: Ten patients (23.3%) presented terminal event: 4 patients had IR because of persistent SSI activity despite multiple debridements and antibiotics, 5 had IR because of recurrence after a symptom-free period, and 1 patient died from sepsis.

Survival rates after the first debridement were 90.7% at 6 months, 83% at 1 year, 73.2% at 2, 3 and 4 years. 4 of 9 patients required reinstrumentation after IR, with 2 SSI recurrences. One recurrence was observed after IR without reinstrumentation.

Patients who developed sepsis (HR 12.5; 95%CI: 2.6-59.9), needed more than one debridement (HR 3.78 95%CI: 1.05-9.4), had >3 segments fused (HR 4.5 95%CI: 1.25-24.05) or had late presentation (HR 1.02; 95%CI 1.005-1.026) had a higher risk of developing a terminal event ($p < 0.05$).

Conclusion: Implant survival is seriously compromised after properly treated SSI and decreases progressively over the first 24 months. 3 out of 9 patients had recurrences inspite of IR. Predictors of failure treatment are related with aggressiveness of infectious process (systemic sepsis, number of debridements needed) and with the magnitude of the index procedure (number of segments).

45. Rod Fracture after Long Construct Fusion in Spinal Deformity: Clinical and Radiographic Risk Factors

*Tsutomu Akazawa, MD; Toshiaki Kotani; Shohei Minami
Japan*

Summary: The purpose of this study was to analyze clinical and radiographic risk factors of rod fracture after long construct fusion in spinal deformity. Rod fracture occurred in 7 of 155 cases (4.5%). The most common fracture locations were near the distal fusion level and at the thoracolumbar junction. Preoperative severe scoliosis, obesity, gender, and rod material had no significant effect on rod fracture rate. Iliac screw fixation and small diameter rod were risk factors for rod fracture.

Introduction: The purpose of this study was to analyze clinical and radiographic risk factors of rod fracture after long construct fusion in spinal deformity.

Methods: The survey subjects were 155 consecutive cases who were diagnosed with spinal deformity and underwent correction and fusion surgery with long construct instrumentation (>3 levels, average 10.3 levels) between July 2004 and June 2010. The subjects comprised 32 males and 123 females with a mean age of 19.0 (range 8-78) years. The mean Cobb angle was 61.0 ± 16.1 degrees preoperatively and 25.7 ± 16.9 degrees postoperatively. The subjects included 95 adolescent idiopathic scoliosis, 15 congenital scoliosis, 8 neuromuscular scoliosis, 7 neurofibromatosis scoliosis, 13 adult spinal deformity, 11 early-onset scoliosis (final fusion), and 6 syndromic scoliosis patients. Logistic regression analysis was performed.

Results: Rod fracture occurred in 7 of 155 cases (4.5%). The mean period from surgery to rod fracture was 17.1 months (range 2-37). The most common fracture locations were near the distal fusion level (5/7) and at the thoracolumbar junction (2/7). Patients with preoperative kyphosis (>40 degrees) had a higher fracture rate than patients without kyphosis (21.1% vs. 2.2%, $p < 0.001$). Iliac screw fixations had a higher rate than the others (42.9% vs. 2.7%, $p < 0.001$). Small diameter rods (<6mm) had a higher rate than large diameter rods (15.0% vs. 0.9%, $p < 0.001$). Multiple surgery cases had a higher rate than single surgery cases (15.4% vs. 2.3%, $p = 0.003$). Preoperative severe scoliosis (>80 degrees), obesity, gender, and rod material had no significant effect on rod fracture rate. Logistic regression analysis of possible risk factors revealed that iliac screw fixation (odds ratio [OR]: 40.92, 95% confidence interval [CI]: 3.45-484.89, $p = 0.003$) and small diameter rod (OR: 26.76, 95%CI: 2.22-322.59, $p = 0.010$) were risk factors for rod fracture.

Conclusion: The incidence of rod fracture after long construct fusion in spinal deformity was 4.5%. Iliac screw fixation and small diameter rod were risk factors for rod fracture.

46. Improvement of Segmental Lordosis in Transforaminal Lumbar Interbody Fusion: A Comparison of Two Techniques

*John C. France, MD; James W. Rice, MD; Sanford E. Emery, MD, MBA; Scott D. Daffner, MD
USA*

Summary: This study compares radiographic outcomes of two different techniques for transforaminal lumbar interbody fusion. One group of patients received a kidney-shaped allograft placed as anteriorly as possible in the disc space, while the second group received a straight PEEK cage. At least one year follow up was required. Preoperative and postoperative values for segmental lordosis, segmental coronal alignment, and disc heights were compared. Statistically significant improvement in lordosis and disc height was seen in favor of the kidney-shaped allograft.

Introduction: Transforaminal Lumbar Interbody Fusion (TLIF) was introduced as an alternative to Posterior Lumbar Interbody Fusion for treating degenerative lumbar disorders. Different variations of the original TLIF technique are employed. Several studies have investigated the clinical outcomes of TLIFs, but few have evaluated the effect of technique on radiographic outcomes. The purpose of this study was to evaluate the relationship between TLIF technique, segmental alignment, and disc height.

Methods: A total of 127 levels (in 101 patients) fused via TLIF were retrospectively reviewed. Levels were divided into two groups based on technique. Group 1 received a curved allograft placed anteriorly in the disc space. Group 2 received a straight, PEEK cage packed with bone graft or bone substitute. Rod contouring and posterior compression were performed in each group. Group 1 contained 55 levels; Group 2 had 72. Segmental lordosis (SL), disc height (DH), and segmental coronal alignment (SC) were measured on standing lumbar radiographs at the preoperative visit, day of surgery (t0), first postoperative visit (t1), one-year follow-up (t2), and last follow-up (t3). Preoperative measurements were subtracted from subsequent values, yielding correction values (deltas) for each time point (t). Mean deltas were compared between groups using the student's t-test.

Results: Both groups improved SL at all time points, but correction decreased over time. Group 1 SL delta values were 7.8(t0), 6.5(t1), 5.6(t2), and 3.9(t3) degrees. SL delta values for Group 2 were 4.0(t0), 1.8(t1), 0.9(t2), and 0.1(t3) degrees. Findings were statistically significant at all time points ($p < 0.0001$). DH delta values were also greater in Group 1 versus Group 2: 5.6 vs 2.2 (t1), 4.5 vs 0.8 (t2), 3.6 vs. 0.2 (t3). Statistical significance ($p < 0.0001$) was present at all time points. Comparison of coronal alignment (SC) did not reach statistical significance at any time point.

Conclusion: Both techniques effectively correct hypolordosis and loss of disc height initially, but show a loss of correction over time. Radiographic outcomes favor the curved allograft technique at all time points. Further evaluation of this data is needed to determine if clinical outcomes correlate to radiographic outcomes.

47. Relationship Between Spino-Pelvic Parameters and QOL in Adult Spinal Deformity in Japanese Patients - Which Factor is Important for Better QOL in Treatment of Adult Spinal deformity?

*Yu Yamato; Yukihiko Matsuyama, MD; Manabu Ito, MD, PhD; Ken Yamazaki, MD; Hiroshi Taneichi, MD; Yutaka Nohara, MD; Mario Matsumoto, MD; Tanaka Masato; Nobumasa Suzuki, MD
Japan*

Summary: A multi-centered, cross sectional study to find out the impact of radiographic parameters on QOL in adult spinal deformity. Lumbar lordosis, pelvic parameters and sagittal global balance can affect lumbar and social function and low back pain. Coronal plane radiographic parameters are less critical.

Introduction: Adult thoraco-lumbar spinal deformity causes low back pain, gait disturbance and gastroesophageal reflux disease. No consensus exists on treatment of adult spinal deformity, decision-making and surgical planning. We investigated the relationship between spino-pelvic radiographic parameters and QOL measurements in Japanese adult spinal deformity patients.

Methods: One hundred six patients, who have spinal deformity without neurological deficit, underwent whole spine antero-posterior and lateral radiography in standing

PAPER ABSTRACTS

position and completed clinical questionnaire in 5 institutions. Radiographic measurements included curve type, curve location, curve magnitude, coronal alignment, sagittal alignment, pelvic position, incidence of vertebral fracture and antero-posterior and lateralolisthesis. Oswestry disability index (ODI), Japanese Orthopaedics Surgery Association Back Pain Evaluation Questionnaire (JOABPEQ) and Scoliosis Reserch Society (SRS-22) patient questionnaire were utilized for QOL evaluation.

Results: The mean age of the patients in this study was 67.8 years (range 20-87). Mean Cobb angle on coronal plane was 31.8 degree. Significant correlation was observed in sagittal plane parameters, global balance and pelvic parameters with QOL measurements. Lumbar lordosis (T12-S1) correlated with ODI, JOABPEQ (walking ability, social life function), SRS-22 (function, pain, self image and total). SVA correlated with ODI, JOABPEQ (lumbar function, walking ability, social life function) and SRS-22 (function, self image). Pelvic parameters (pelvic tilt and sacral slope) correlated with ODI, JOABPEQ (walking ability, social life function) and SRS-22 (function, self image) According to multiple logistic regression analyse, SVA conferred an odds ratio 1.012 (95%CI 1.004-1.021, p=0.003) for dysfunctional patients (ODI above 50). Coronal plane parameters and global balance revealed no significant correlation with function or pain.

Conclusion: Lumbar lordosis, pelvic parameters and sagittal global balance can affect lumbar and social function and low back pain. Coronal plane radiographic parameters are less critical. This study suggests planning of collection in adult spinal deformity should be considered for sagittal alignment and global balance.

48. The Contribution of Intraoperative Patient Positioning to Overall Correction of Coronal and Sagittal Deformity in Adults

Michael D. Daubs, MD; Brandon Lawrence, MD; Prokopis Annis, MD; Darrel S. Brodke, MD USA

Summary: We analyzed the preoperative standing, prone intraoperative, and postoperative standing PA and lateral radiographs of 79 adult deformity patients to determine the contribution of prone positioning to the overall deformity correction. A majority of the sagittal balance was achieved on the table by positioning alone.

Introduction: Multiple types of radiographs of the spine (bending, supine, traction) have been described in an attempt to determine the flexibility of coronal and sagittal deformities and determine the appropriate surgical procedure. It is our routine, to obtain prone, full-length, PA and lateral radiographs in all adult deformity cases following the induction of anesthesia. Intraoperative radiographs may change the planned procedure, especially when treating sagittal imbalance. The purpose of our study was to determine the magnitude of coronal and sagittal deformity correction obtained by simple prone positioning on the table under anesthesia.

Methods: We reviewed the preoperative PA and lateral standing, the intraoperative, prone, long-cassette PA and lateral, and the standing postoperative PA and lateral radiographs of 79 patients (mean age 60 years) undergoing surgery for adult deformity. We measured Cobb angles for the main thoracic, thoracolumbar/lumbar curves, thoracic kyphosis, lumbar lordosis, the C7 plumbline, and the C7 CSVL on each set of radiographs. The percent contribution of intraoperative positioning to the overall postoperative correction was determined for each of the measurements.

Results: Intraoperative positioning accounted for the majority

of the correction of sagittal deformity. 53% of lumbar lordosis, 69% of thoracic kyphosis, 59% of T/L kyphosis, and 63% of the C7 sagittal plumbline was corrected on the table. Intraoperative positioning had less effect on coronal deformity. The main thoracic curve was unchanged overall by positioning, and there was only 6% correction of the T/L curve on the table. Even though intraoperative positioning had less effect on correcting coronal deformity, the C7 CSVL (coronal balance) was corrected 100% on the table in our cases.

Conclusion: Intraoperative positioning on the table accounts for the majority (>50%) of the postoperative sagittal alignment correction. Coronal plane deformity is less affected by prone positioning, however, coronal balance is usually fully restored. Full-length, prone, intraoperative films under anesthesia may be helpful in determining how much sagittal alignment will be restored, and how much surgical correction may be necessary.

49. Impact of Radiographic Parameters on HRQoL in Adult Spinal Deformity. The Lordosis Gap Better than Lumbar Lordosis?

Ferran Pellise, MD; Montse Domingo-Sabat; Ahmet Alanay; Juan Bago, MD; Alba Vila-Casademunt; Carlos Villanueva, MD, PhD; Azmi Hamzaoglu, MD; Emre Acaroglu, MD Spain

Summary: The clinical relevance of mathematical formulas defining the ideal lumbar lordosis and the impact of the Lordosis Gap (LG), a patient-specific parameter defined as "Patient's Ideal Lordosis minus Patient's Real Lordosis", has not been evaluated in adults with spinal deformity. This study validates the predictive value of formulas determining ideal lordosis based on pelvic morphology. The LG expressing the amount of lordosis needed to achieve the "ideal lordosis" appears to have the highest impact on HRQoL in adult deformity patients.

Introduction: Studies in asymptomatic population show that pelvic incidence (PI) determines lumbar lordosis (LL). The clinical relevance of mathematical formulas defining the ideal lumbar lordosis and the impact of the Lordosis Gap (LG), a patient-specific parameter defined as "Patient's Ideal Lordosis minus Patient's Real Lordosis", has not been evaluated in adults with spinal deformity.

Methods: Cross-sectional study involving consecutive patients older than 18, evaluated in 3 centers, accomplishing at least one of the following inclusion criteria: scoliosis >20deg, sagittal vertical axis (SVA) >5cm, pelvic tilt (PT) >25deg or thoracic kyphosis (TK) >60deg.

Radiographic measurements included coronal (Cobb angle), sagittal spinopelvic (TK, LL, PT, PI, SS) and global balance (SVA, T1SPI) parameters. Patient's ideal lordosis was calculated according to the formula $Ideal L = 0.54PI + 32.56$.

HRQoL was assessed using the validated outcome measures ODI and SRS22.

Results: 181 patients (77.9% females, mean age 44.4y SD19.26) met the inclusion criteria. Mean values for radiographic parameters: coronal Cobb 47deg. SD24.5; TK 40.38deg. SD18.6; LL 50.3deg. SD17.9, PT 18.5deg. SD11.3, PI 54.4deg. SD14.11, SVA 18.95 SD60.77 and T1SPI -2.7deg. SD5.64. Lordosis Gap averaged 11.8deg. SD22.55.

Main mean values for HRQoL outcome measures were: ODI 30.6 SD23.38; SRS-22 subtotal 3.3 SD0.75; SRS22pain 3.2 SD0.99; SRS22appearance 3.0 SD0.88; SRS22activity 3.7 SD1.56; SRS22mental 3.3 SD0.84.

Coronal deformity was not correlated with ODI or SRS-22, whereas sagittal parameters (LL, PT, SVA and T1SPI) were correlated significantly ($p < 0.05$; $0.19 < r < 0.36$).

The LG correlated significantly with both ($r=0.25$, and $p=0.005$ for ODI and $r=0.28$, $p=0.001$ for SRS22), and demonstrated the highest correlation coefficients overall. Strongest correlation was found with SRS22 function ($r=0.40$) (Table).

Conclusion: This study validates and demonstrates the predictive value of mathematical formulas determining ideal lordosis based on pelvic morphology. The LG, a patient-specific parameter expressing the amount of lordosis needed to achieve the "ideal lordosis", appears to have the highest impact on HRQoL in patients with adult spinal deformity.

50. The Comprehensive Anatomical Spinal Osteotomy Classification

Frank Schwab, MD; Benjamin Blondel, MD; Edward Chay; Jason Demakakos; Lawrence G. Lenke, MD; Patrick Tropiano, MD; Christopher P. Ames, MD; Justin S. Smith, MD, PhD; Christopher I. Shaffrey, MD; Steven D. Glassman, MD; Robert W. Gaines, MD; Jean-Pierre C. Farcy, MD; Virginie Lafage, PhD USA

Summary: This study investigated the reliability of a proposed, anatomically based spinal osteotomy classification system. Reliability tests showed almost perfect intra- and inter-observer agreement. The proposed classification system may provide a practical framework for describing osteotomy resections and effective comparative analysis of the various treatments.

Introduction: In order to address rigid deformity patterns in the setting of ASD, the use of spinal osteotomies has seen a substantial increase in the clinical arena, and many different procedures have been described. Unfortunately, variations of established techniques and hybrid combinations of osteotomies have made comparisons of outcomes difficult. The aim of this study is to propose a universal classification system of spinal osteotomies, which is anatomically based, in order to provide a common language among spine specialists.

Methods: The proposed classification system is based on six anatomical grades of resection (1 through 6) corresponding to the extent of bone resection and increasing degree of destabilizing potential. In addition, an approach modifier is added to denote the surgical approach (A, P or A/P). Reliability of the classification system was evaluated by an analysis of 16 clinical cases, rated two times by eight different readers at a two week interval, and calculation of Fleiss' Kappa coefficients.

Results: Intra-observer reliability was classified as 'almost perfect'; Fleiss' Kappa coefficient averaged 0.96 (range 0.92-1.0) for resection type and 0.90 (0.71-1.0) for the approach modifier. Results from the inter-observer reliability for the classification were 0.96 for resection type and 0.88 for the approach modifier.

Conclusion: This proposed anatomically based classification system provides a consistent description of the various osteotomies performed in spinal deformity correction surgery. The reliability study confirmed that the classification is simple and consistent. Further development of its use will provide a common frame for osteotomy assessment and permit comparative analysis of different treatments.

51. Weight Change and Clinical Outcomes Following Adult Spinal Deformity Surgery in Overweight and Obese Patients

Addisu Mesfin, MD; Lawrence G. Lenke, MD; Keith H. Bridwell, MD; Jeremy L. Fogelson, MD; Stuart Hershman, MD; Han Jo Kim, MD; Linda Koester, BS USA

Summary: The role of spine surgery and subsequent weight loss or weight gain in overweight and obese spinal deformity patients is unknown. At latest f/u overweight and obese spinal deformity patients did not lose or gain a significant amount of

weight. However, both overweight and obese patients demonstrated significant improvements in ODI, SRS self-image and SRS scores.

Introduction: The impact of spine surgery on postop weight loss or weight gain in overweight and obese spinal deformity patients is unknown. Our objective was to 1) evaluate if overweight and obese spinal deformity patients experience weight loss or weight gain postop; 2) evaluate health-related quality of life outcomes in overweight and obese spinal deformity patients following surgery.

Methods: 104 adult patients (94 female/10 male) undergoing primary adult spinal deformity surgery at one institution were enrolled. All patients had a minimum of 2 yr f/u (avg 50.1 months). Preop and latest f/u BMI was collected along with ODI, SRS self-image and SRS scores.

Results: 66 pts were overweight (BMI >25-29.9; Avg 26.9; Group OW). 38 pts were obese (BMI >30; Avg 33.5; Group OB). Avg age was 54.5 in Group OW and 48.6 in Group OB ($p<0.01$). Avg instrumented levels were 11.6 for Group OW and 12 for Group OB ($p<0.5$). At latest f/u significant changes were not found in the BMI for Group OW, 27.2 (26.9 to 27.2; $p<0.39$) and the BMI for Group OB, 35 (33.5 to 35; $p<0.06$). Postop Group OW had significant improvement in ODI (36.1 to 21.8, $p<0.001$); SRS self-image (2.9 to 3.7, $p<0.001$) and SRS score (3.1 to 3.8, $p<0.001$). Postop Group OB also had significant improvement in ODI (44.1 to 24.4, $p<0.001$); SRS self-image (2.6 to 3.8, $p<0.001$) and SRS score (2.9 to 3.9, $p<0.001$).

Conclusion: This is the first study evaluating the impact of spinal deformity surgery on weight change and outcomes. Overweight and obese spinal deformity patients do not demonstrate significant weight gain or weight loss from preop to latest follow up. However, both overweight and obese patients had significant improvements in outcome scores at latest follow up.

52. Comparison of Pulmonary Function in Adults Younger and Older than Age 60 Undergoing Spinal Deformity Surgery

Ronald A. Lehman, MD; Daniel G. Kang, MD; Lawrence G. Lenke, MD; Jeremy J. Stallbaumer, MD; Brenda A. Sides, MA USA

Summary: We evaluated the impact of adult spinal deformity surgery on pulmonary function for patients over age 60, with minimum 2 year follow-up. We found older patients have no significant difference in %predicted PFTs compared to younger patients postoperatively, and no differences in the rate of clinically significant PFT decline ($\geq 10\%$ pred FEV1). However, older patients more frequently (23% v 12%) experience PFT impairment ($<65\%$ pred FEV1) after spinal deformity surgery.

Introduction: The objective of this study was to determine differences in pulmonary function in adult patients who are either younger (Y) or older (O) than age 60 following spinal deformity surgery. We hypothesize that older age may further exacerbate impairment of pulmonary function following spinal deformity surgery.

Methods: 128 consecutive adult deformity patients with idiopathic scoliosis undergoing surgical treatment were evaluated at a single institution with minimum 2 yrs F/U. Prospectively collected PFTs, clinical records and radiographs were analyzed.

Results: There were 102 patients in Y group (avg age 39.3+14.1

PAPER ABSTRACTS

Yrs) and 26 in O group (avg age 63.7±2.7 yrs), with similar F/U (Y=2.9 v O=2.6 yrs, p=0.27). There were no differences in average preop main thoracic (MT) curve magnitude (Y=50.0deg, O=54.8deg, p=0.27), however O patients had significantly greater # of lumbar (5.9 v 4.2, p=0.00), thoracic (9.1 v 7.3, p=0.00), and total (15.0 v 11.5, p=0.00) levels fused. We also found O patients had significantly lower absolute pre-op FEV1 (2.1 v 2.6L, p=0.02) and FVC (2.7 v 3.3L, p=0.05), but no differences in %pred PFTs. This relationship remained at 2 yrs, with lower absolute FEV1 (1.9 v 2.5L, p=0.00) and FVC (2.5 v 3.1L, p=0.00). A clinically significant decline in PFTs (≥10% pred FEV1) occurred in 8 (31%) O patients and 26 (25%) Y patients, which was not statistically different. (p=0.63). We also observed pre-op PFT impairment (<65%pred FEV1) in 1 (4%) O patient, which significantly increased to 6 (23%; p=0.02) O patients postoperatively, compared to Y group experiencing no change in the number of patients (n=12, 12%) with PFT impairment postoperatively

Conclusion: Despite age related reduction in PFTs, older patients (over age 60) had no significant difference in %pred PFTs compared to younger patients following spinal deformity surgery. While there was no difference in rate of clinically significant PFT decline, there was a significant increase in O patients with PFT impairment postoperatively.

53. Analysis of Health Related Quality of Life Improvements among Patients with Adult Spinal Deformity

Michael F. O'Brien, MD; Richard Hostin, MD; Ian McCarthy, PhD; Neil Fleming, PhD; Gerald Ogola; Rustam Kudyakov, MD, MPH; Kathleen M. Richter, MS, MFA, ELS; Rajiv Saigal, MD, PhD; Sigurd H. Berven, MD; Vedat Deviren, MD; Christopher P. Ames, MD; International Spine Study Group USA

Summary: Change in health related quality of life (HRQOL) is a critical component in assessing the cost-effectiveness of surgical treatment for adult spinal deformity (ASD). This study analyzes the magnitude and determinants of improvements in HRQOL for patients undergoing surgical treatment for ASD. Results indicate that demographic variables, including age and BMI, are relevant predictors of HRQOL improvement following surgical care, while improvements do not appear to be dependent on the diagnostic category of deformity.

Introduction: Understanding the economic impact of surgical treatment for ASD necessitates an understanding of the outcomes associated with the surgery. This study analyzes the impact of demographic variables and pathology of ASD on changes in HRQOL among patients receiving surgical treatment for four categories of ASD: Primary Idiopathic Scoliosis (PIS), Primary Degenerative Scoliosis (PDS), Primary Sagittal Plane Deformity (PSPD), and Revision (R).

Methods: Multi-center, retrospective analysis of 323 consecutive ASD patients (ages 18 to 85, with an average age of 54). Patients were assigned to one of four diagnostic categories based on pre-operative radiographs and history: PDS (n=59, 18%), PIS (n=102, 32%), PSPD (n=39, 12%), and R (n=123, 38%). HRQOL measures were based on the Medical Outcomes Study Short Form 36 (SF-36) physical and mental component scores (PCS and MCS, respectively), the Oswestry Disability Index (ODI), and the Scoliosis Research Society (SRS) questionnaires after at least one year following surgery.

Results: Patients reported significant improvement in all outcome

measures except for SRS mental health: SF-36 MCS (mean=2.80; p<0.01), SF-36 PCS (5.98; p<0.01), ODI (9.27; p<0.01), SRS functional activity (0.41; p<0.01), SRS self-image (1.08; p<0.01), and SRS pain (0.88; p<0.01). No significant differences in HRQOL improvements were observed across different categories of ASD. Results indicate a significant (p<0.05) positive relationship between changes in HRQOL and age. Similarly, analysis of a subset of patients with BMI data (n=139) showed a significant (p<0.05) positive relationship between changes in HRQOL and BMI.

Conclusion: Improvements in HRQOL do not appear to be dependent on the diagnostic category of deformity. Although results differ somewhat across HRQOL measures, the analysis indicates that older patients and patients with higher BMI may exhibit significantly more improvement relative to younger patients and those with lower BMI.

54. Reoperation Rates and Impact on Outcome in a Large Prospective Multicenter Adult Spinal Deformity Database

Christopher P. Ames, MD; Justin K. Scheer, BS; Justin S. Smith, MD, PhD; Eric Klineberg, MD; Robert A. Hart, MD; Gregory M. Munds, MD; Douglas C. Burton, MD; Richard Hostin, MD; Michael F. O'Brien, MD; Christopher I. Shaffrey, MD; Shay Bess, MD; Frank Schwab, MD; Khaled Kebaish, MD; Vedat Deviren, MD; International Spine Study Group USA

Summary: A retrospective analysis of a prospective, multicenter adult spinal deformity database was conducted investigating reoperation rates and indications within 1 year of surgery, as well the effect of reoperation on HRQOL scores at 1 year. 34/45 reoperations were conducted within 1 year of surgery and 13 were within 30 days. Reoperation patients were significantly older than those not requiring reoperation within the first year of surgery and, compared with non-reoperation patients, had significantly worse 1 year ODI and SRS scores.

Introduction: Adult spinal deformity is historically associated with relatively high rates of complications and need for reoperation. Reoperation within 30 days and 1 year may be important quality metrics that will require baseline rates at centers of excellence to set acceptable occurrence standards of these events. Analysis of the rates, timeframe and reasons for reoperation, and impact on clinical outcomes may identify potential areas for care improvement.

Methods: The rates of reoperation within 30 days and 1 year were assessed based on a large multicenter adult deformity database of 316 operative patients, 205 of which had minimum 1 year follow-up. Reasons for reoperation and its impact on the Oswestry Disability Index (ODI) and Scoliosis Research Society (SRS) outcomes measures at 1 year were assessed. Smoking history, Charlson, and ASA scores were also assessed.

Results: 45/316 patients (14%) had required reoperation at any time (11 >1 yr). 34 (17%) required reoperation within 1 yr of initial surgery, including 13 (6%) within 30 days following initial surgery. Reoperation indications included: instrumentation malposition/fracture (n=16), proximal junction failure (n=9), neurological compromise (n=6), pseudarthrosis (n=4), coronal imbalance (n=3), infection (n=3), distal junction failure (n=2), adjacent segment degeneration (n=1), and hematoma (n=1). Patients requiring reoperation were significantly older than those not requiring reoperation within the first year of surgery (62.6 vs 57.4 years, p=0.03). Compared with patients not requiring reoperation, those needing reoperation had worse outcomes measure at 1 year follow-up, including ODI (36 vs 23,

$p=0.017$) and SRS total score and all subscores ($p<0.05$) (Table). There were no significant differences between reop and nonreop pts for Charlson, ASA, or smoking hx.

Conclusion: The results show age may have an effect on the reoperation rate and that reoperation within 1yr does have an effect on health-related quality of life at 1 year. The most common indications for reoperation (instrumentation complications and radiographic failure) reinforce the importance of preoperative planning, intraoperative imaging and surgical technique.

55. A Randomized Trial of Balloon Kyphoplasty and Non-Surgical Management for Treating Acute Vertebral Compression Fractures Outcomes Vertebral Body Kyphosis Correction and Surgical Parameters

Douglas Wardlaw, MB, ChB, ChM, FRCSEd
United Kingdom

Summary: Adults with one to three VCF were randomized within 3 months from onset of pain to undergo bilateral BKP (n=149) or NSM (n=151). Kyphoplasty was associated with greater improvements in SF-36 PCS and TUG scores compared with NSM. At 24 months, the change from baseline in KA was statistically significantly improved in the kyphoplasty group (average 3.1 of correction for BKP versus 0.8 for NSM, $p=0.003$).

Introduction: Vertebral fractures (VCF) are often painful and lead to reduced quality of life (QOL). We compared the efficacy and safety of balloon kyphoplasty (BKP) to non-surgical management (NSM) over 24 months in patients with acute painful fractures.

Methods: Adults with one to three VCF were randomized within 3 months from onset of pain to undergo bilateral BKP (n=149) or NSM (n=151). Subjective QOL assessments (e.g., SF-36 PCS) and objective functional (Timed up and go [TUG]) and vertebral body kyphotic angulation (KA), were assessed over 24 months; we also report surgical parameters and adverse events temporally related to surgery (i.e. within 30-days).

Results: Kyphoplasty was associated with greater improvements in SF-36 PCS scores when averaged across the 24-month follow-up period, compared with NSM (overall treatment effect 3.24 points, 95% CI, 1.47-5.01; $p=0.0004$). Kyphoplasty resulted in greater functionality by assessing TUG (overall treatment effect -3.00 seconds, 95% CI, -1.0 to -5.1; $p<0.0043$). At 24 months, the change from baseline in KA was statistically significantly improved in the kyphoplasty group (average 3.1 of correction for BKP versus 0.8 for NSM, $p=0.003$). On average, IBT inflation pressures were 178 (left) and 180 (right) psi; IBT inflation volumes were consistent with cement volumes at 2.4 cc per side. The most common adverse events within 30-days were back pain (20 BKP, 10 NSM) new vertebral fracture (11 BKP, 7 NSM), nausea/vomiting (12 BKP, 4 NSM) and UTI (10 BKP, 3 NSM). Two device-related serious adverse events in the second year occurred at index vertebrae (a spondylitis and an anterior cement migration)

Conclusion: Compared with NSM, BKP improves patient function and QOL when averaged over 24-months and results in better improvement of index vertebral body kyphotic angulation.

56. Non-Neurological Complication Rate Following Surgical Treatment of Vertebral Fracture with Spinal Cord Injury; Does Surgical Timing Matter?

Jean-Marc Mac-Thiong, MD, PhD; Étienne Bourassa-Moreau; Cynthia Thompson, PhD; Stefan Parent, MD, PhD
Canada

Summary: A total of 415 adults who underwent surgery for traumatic SCI were retrospectively reviewed. The occurrence of non-neurological complications was studied. The rate of all complications, of pneumonia and pressure ulcer was significantly higher when surgery was performed more than 72h after the vertebral trauma.

Higher complication rates were also associated to more severe traumas, a greater amount of comorbidities, age, ASIA classification and tetraplegia.

Introduction: Optimal timing of surgery after traumatic spinal cord injury (SCI) is one of the most controversial subjects in spine surgery. It has been suggested that early surgical decompression can reduce the rate of non-neurologic post operative-complications. We wanted to assess the relation between surgical timing and the rate of non-neurological complications during acute hospital stay in SCI patients with vertebral trauma.

Methods: We retrospectively reviewed 415 patients who sustained a traumatic SCI and had their spinal stabilization at a single Level-I trauma center between April 2000 and March 2011. Patients diagnosed with a central cord syndrome, unknown neurological injury, or who sustained a spine injury below the L1-L2 disc were excluded. For each patient, post-operative complications that occurred during the acute hospitalisation phase (pulmonary embolus, pneumonia, urinary tract infection, pressure ulcers and other complications) were collected. We examined the occurrence of non-neurological complications during different intervals pertaining to the timing of the surgical intervention with respect to the spine trauma (<24h, <72h and >72h). The statistical analysis model was adjusted for co-variables such as age, vertebral level, ASIA classification, Injury Severity Score (ISS), Charlson Comorbidity Index (CCI) and Surgery Invasiveness (SI).

Results: The rate of occurrence of pneumonia and pressure ulcer was significantly higher when surgery was performed more than 72h after the vertebral trauma. Occurrence of other complications was not significantly associated with surgical timing. Higher complication rates were also associated to more severe traumas (ISS), a greater amount of comorbidities (CCI), age, ASIA classification and tetraplegia.

Conclusion: When controlling for confounding variables, surgical decompression performed within 72h after post-injury was associated with lower rates of non-neurological complications. In order to decrease the rate of complications, the authors recommend performing spinal decompression/stabilization as soon as the patients are stable enough to undergo surgery within the first 72 h after the trauma.

57. Comparison of Results of Surgical Treatments for Osteoporotic Vertebral Collapse

Naobumi Hosogane, MD; Shinjiro Kaneko; Hironobu Watanabe; Kenya Najiri; Kota Watanabe; Takashi Tsuji; Ken Ishii, MD, PhD; Hitoshi Kono, MD; Masaya Nakamura; Masanobu Shioda; Masafumi Machida, MD; Masashi Saito; Yoshiaki Toyama; Kazuhiro Chiba, MD, PhD; Morio Matsumoto, MD
Japan

Summary: We have compared the anterior spinal fusion (ASF; 34 patients), posterior shortening (PS;

PAPER ABSTRACTS

24 patients) and vertebroplasty-augmented posterior fixation (VPF; 12 patients) for the treatment of osteoporotic vertebral collapse.

The number of fused segments was smallest in ASF. Instrumentation failure was minimal in ASF and correction of local kyphosis was largest in PS, while surgical invasiveness increased in these two methods compared to VPF. There was no significant difference in the number of additional vertebral body fractures during follow-up period.

Introduction: Osteoporotic vertebral collapse can be treated either by anterior spinal fusion (ASF), posterior shortening (PS) or vertebroplasty-augmented posterior fixation (VPF). There are few reports that compared these surgical methods. The purpose of this study was to compare the surgical outcomes of these three surgical methods.

Methods: Seventy patients with osteoporotic vertebral collapse patients (13 males, 57 females, mean age; 70.0 years) treated surgically were included in this study. 34 patients underwent ASF (mean age; 68.1 years, mean follow-up; 4.1 years), 24 patients PS (mean age; 69.6 years, mean follow-up; 2.5 years) and 12 patients VPF (mean age; 70.0 years, mean follow-up; 2.1 years). Surgical invasiveness and radiological parameters including fusion levels, kyphosis angle, loss of correction, additional vertebral fractures and instrumentation failure were evaluated.

Results: Surgical invasiveness assessed by surgical time (ASF 234 min., PS 240 min., VPF 190 min.) and blood loss (ASF 824 ml, PS 666 ml, VPF 324ml) was smallest in VPF. The number of fused segments was smallest in ASF (ASF 2.1, PS 4.3, VPF 3.8). Preoperative local kyphosis angle was tended to be larger in PS (ASF 22.6°, PS 30.0°, VPF 20.7°). While the correction angle of kyphosis after surgery was largest in PS (ASF 7.6°, PS 32.8°, VPF 10.0°), the correction loss of kyphosis during a follow-up period was not statistically different (ASF 4.0°, PS 8.2°, VPF 5.8°). Instrumentation failure was observed in 11 patients in PS (46%), 3 patients in VPF (25%) and none in ASF. There was no significant difference in the number of additional vertebral body fractures during follow-up period (ASF 1.1, PS 0.46, VPF 0.67).

Conclusion: Our results suggest that ASF can minimize the number of fusion segments and instrumentation failure, while it may increase the surgical invasiveness. PS exhibited the largest correction of kyphosis, although surgical invasiveness also increased as much as ASF. VPF showed the smallest surgical invasiveness.

Surgical treatment for osteoporotic vertebral collapse in elderly patients should be chosen considering these advantages and disadvantages of each procedure.

58. Perioperative Complications in Open vs. Percutaneous Treatment of Spinal Fractures in Patients with an Ankylosed Spine

Charbel D. Moussallem, MD; Ahmad Nassr, MD; Quanqi Cui, MD; Bradford L. Currier, MD; Michael J. Yaszemski, MD, PhD; Paul M. Huddleston, MD; Peter S. Rose, MD; Mark Pichelmann, MD; Mark B. Dekutoski, MD
USA

Summary: Perioperative complication, morbidity and mortality is compared between open versus percutaneous treatment of fractures in patients with ankylosed spine. The percutaneous group had less complications and mortality rates

Introduction: Ankylosing Spondylitis AS and Diffuse Idiopathic

Skeletal Hyperostosis DISH are disorders characterized by a pathologic stiffness and ossification of the spine predisposing to spinal fractures. Traditional open treatment is complex and may be associated with high morbidity and mortality. In this study we compare open versus percutaneous fixation techniques

Methods: A retrospective review of patients known to have AS and DISH treated for spinal fractures between 1995 and 2011 was performed. Patients were analyzed by the type of fixation: percutaneous group (PG) and open group (OG). Pre and post-operative data was analyzed

Results: The OG consisted of 16 male patients (8 AS, 8 DISH) having a mean age of 74.1y (52-92) and a mean BMI of 29.7 (20.56-40.53). Mean ISS was 10.55+/-7.76. Mean operative time was 334.6 minutes (161-518), mean intraoperative estimated blood loss (EBL) was 1240.3 ml (200-2840), mean post-operative EBL was 404.5 ml (0-1020) and the mean blood transfusion volume was 639.6 ml (0-3500). The mean time to discharge was 16.2 days (3-43). 5 (31%) patients died within one year. 14 patients (87.5%) had post-operative complications; two developing postoperative paraplegia, while three underwent revision surgery during their hospital stay (1 for epidural hematoma decompression, 1 for wound revision, 1 for implant repositioning). Average follow up was 23 weeks. The PG consisted of 25 patients (18 AS, 7 DISH) including 6 females and 19 males having a mean age of 75.7y (54-90) and a BMI of 29.9 (13.27-39.67). ISS averaged 10 +/- 7.83. Mean operative time was 254 minutes (77-580), mean intraoperative EBL was 166.8 ml (10-900), mean post-operative EBL was 21.8 (0-350) and the mean blood transfusion volume was 178.32 ml (0-660). The mean time to discharge was 9.5 days (3-22) with 44% experiencing post-operative complications. One patient had revision decompression for weakness. Two (8 %) patients died within one year of surgery. Average follow up was 18 weeks

Conclusion: Percutaneous stabilization was associated with lower blood loss, shorter operative times, decreased transfusion, shorter hospitalization and lower perioperative complications and mortality. While long term follow up is needed we believe this is a promising technique

59. Return to Play and Cervical Spine Injury, What Level of Play and How Soon?

John C. France, MD; Andrew T. Dailey, MD; James S. Harrop, MD
USA

Summary: A survey of 25 level 1 trauma spine surgeons to determine the level of sports participation that they would allow following 12 different case scenarios of cervical injury.

Introduction: Numerous cervical spine fractures are treated each year and much is written about treatment methods but the literature guiding return to function, especially sports, is scant. This study was designed to identify the maximum level of sporting activity that a consensus group of spine trauma surgeons would allow patients to participate in after recovery.

Methods: Twenty-five spine surgeons in the Spine Trauma Study Group, all from level 1 trauma centers who consider spine trauma to be a significant component of their practice were surveyed. Each was presented 12 case scenarios involving cervical injuries and asked to identify the level of sports play they would allow. Because this study focused on cervical injury the levels of contact were stratified by the frequency and severity of head/neck impact. In full contact one would expect frequent blows to the head or twisting of the neck as part of the sport (eg. football or wrestling), as

opposed to intermediate contact where the potential for head/ neck impact exists but is not an integral part of that sport (eg. basketball or baseball). In the noncontact sport the likelihood of head/neck impact is no greater than that in normal daily activity (eg. cycling or running).

Results: Fourteen Orthopaedic and eleven Neurosurgeons were surveyed. The results were statistically the same between the 2 groups so the data was analyzed as one group. A brief synopsis of each scenario and level of play recommendation is shown in table 1.

Conclusion: Decisions about return to play following cervical injury can be difficult with a variety of juxtaposed forces in play such as the patient's desires and medico-legal implications. Other than for cervical neuropraxia there is almost no literature to determine an appropriate strategy for return to sports following cervical injury. Although this study will not completely answer the question it establishes a reasonable reference based on expert opinion of surgeons with a large experience to guide the treating physician involved in similar case scenarios. It can also set a basis upon which future prospective, multi-center studies can be performed to confirm or disprove current dogma.

60. A Randomised Control Trial of Neurological Outcome with Different Treatment Modalities in Acute Thoracolumbar Spinal Injuries and Complete Paraplegia - A Preliminary Report

*Rajeshwar N. Srivastava, MD; Saloni Raj
India*

Summary: A randomised control trial of neurological outcome with different treatment modalities in acute thoracolumbar spinal injuries

Introduction: To evaluate neurological recovery in acute thoracolumbar injuries managed by different treatment modalities.

Methods: Patients of either gender {age 16 - 60 years} with unstable acute thoracolumbar spine injury (TLISS Score>4) between T9 -L2 vertebra with complete paraplegia {AIS -A} were randomized in five groups

Results: The study is ongoing and report of 69 patients who were enrolled and followed for >6 months is being presented.

Gp I. Out 15 patients in whom surgical fixation of spine was done; neurological recovery was noticed in one case - AIS A - AIS E in 6 months time.

Gp II - Out of 13 patients, surgical fixation of spine & autologous stem cell infusion was done;. 2 patients showed recovery reaching upto AIS E in 6 months time.

Gp III- Out of 11 cases, surgical fixation of spine was done with omentum transposition; 3 patients showed recovery - in which 1 patient reached AIS -C score in 9 months and 1 patient reached AIS B in 6 weeks. 1 patient took 10 months in achieving AIS B score. It is worth noting that no patients with omentoplasty alone (without stem cell) achieved scores higher than AIS C.

Gp IV - Of 24 patients, 4 showed recovery - 2 reached AIS E and 2 AIS D; 4 patients of AIS D within 6 months time, 2 reached AIS E in 18 months and other 2 have not reported in follow up. Group V (Conservative) - Only 6 patients did not undergo surgical intervention. In this group, 1 patients showed partial sensory recovery from AIS A - AIS B

Conclusion: 1. Neurological outcomes have no relation with gender, mode of injury, level of fracture, and timing of surger.

2. Most of the patients who improved up to ASIA D & E had received stem cell infusion. So it can safely be proposed that stem cell along with fracture fixation must be offered/taken in all patients pertaining to availability of paraphernalia at operating centre.

4) However of all the improved patients (12) - 6 were those who had received omental transposition along with stem cell infusion and fixation. Patients who had received both stem cell and omentum fared better of all the improved patients. .

61. Survival Analysis of the Spinal Metastases Patients with Different Breast Cancer Subtypes

*Miao Wang, MD; Cody E. Bunker; Benny Dahl, MD, PhD, DMSci
Denmark*

Summary: We conducted one retrospective study to analysis the influence of the breast cancer subtypes to the survival rate of the spinal metastases patients in order to improve the preoperative prediction. We found the breast cancer subtypes did not influence the survival rates. Surgeons do not need to distinguish the breast cancer subtype to predict the prognosis.

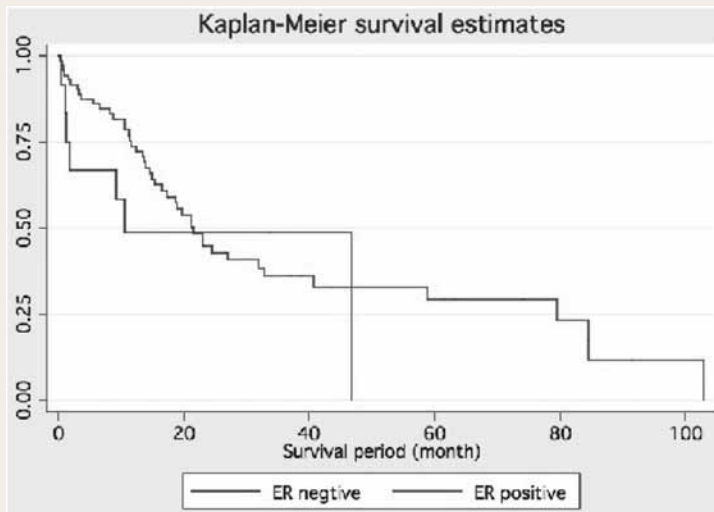
Introduction: Preoperative prognosis of the spinal metastases patients is a challenge for the spine surgeon to choose optimal treatments. Now the popular scoring systems (such as Tokuhashi score) are only focusing on the primary site. Breast cancer is one of the most common tumors that involve the spine. The subtypes could significantly influence the survival period of the breast cancer patients. Estrogen receptor (ER) and Progesterone receptor (PR) status are the key factors of the subtypes. The aim of this study was to investigate the influence of breast cancer subtypes for the survival of the breast cancer spinal metastases patients in order to improve the preoperative prognosis.

Methods: Eighty-four patients with breast cancer spinal metastases underwent surgical treatments since 1997 to 2011 were analyzed. The ER and PR status data were retrieved from the Danish Breast Cancer Group. We used survival analysis, created the Kaplan-Meier curves and run Log-rank test to compare the survival outcomes. All the data were calculated by using the STATA software. The P value less than 0.05 was considered significant.

Results: In the ER subtypes, 72 patients were positive, 12 patients were negative. Fifty-two patients were dead, and 32 patients were alive. The result from the Log-rank test showed that the difference of survival rates between the ER+ and ER- was not significant ($p=0.44$). Forty-seven patients had PR results. In the PR subtypes, 28 patients were positive, 19 patients were negative. Twenty-three patients were dead, and 24 patients were alive. The mortality rates had no significant difference ($p=0.22$) between PR+ and PR- subtypes.

Conclusion: The mortality rate between each subtype did not show any significant differences. The subtypes of the breast cancer do not influence the prognosis of the spinal metastases patients. Spine surgeons do not need to distinguish the breast cancer subtypes to predict the prognosis

PAPER ABSTRACTS



62. Neurological Function and Survival Outcome of Aarhus Algorithm in Patients with Spinal Solitary Plasmacytoma or Multiple Myeloma

Miao Wang, MD; Cody E. Bunger
Denmark

Summary: We conducted a prospective cohort study of 33 surgically treated patients with Solitary plasmacytoma (SP) or multiple myeloma (MM) in spine from Aarhus Spinal Tumor Database. We found the survival rate of the SP and MM did not have significant difference. Aarhus Algorithm could improve the neurological function.

Introduction: Solitary plasmacytoma and multiple myeloma are the most frequent malignant spinal tumors, and they are most frequently localized in the spinal vertebral body. Patients often suffered from severe back pain, pathological fracture, and cord compression. The aim of this study was to describe the neurological status and survival outcome after surgical intervention in patients with spinal solitary plasmacytoma and multiple myeloma based on Aarhus Algorithm.

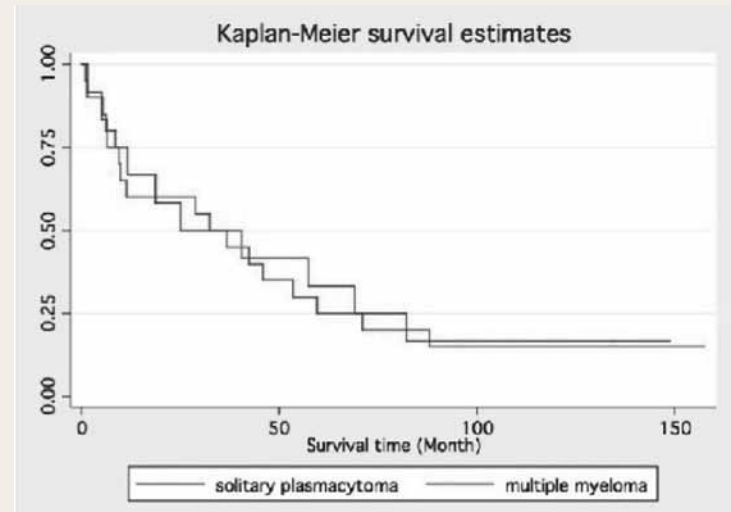
Methods: This study included 33 patients (19 men, 14 women, mean age of 59 years, range from 30 to 84 years). The solitary plasmacytoma group contained 12 patients; multiple myeloma group contained 21 patients. All the patients underwent surgical treatment after complete diagnostic evaluation during December 1994 to November 2009 at the Aarhus University Hospital in Denmark. All the information was prospectively collected into the Aarhus Spinal Tumor Database. We use survival analysis and created the Kaplan-Meier curve. The Log-rank test was used to compare the survival outcomes. All the data were calculated by using the STATA software. The p value less than 0.05 was considered significant.

Results: Thirty patients (91%) had local symptoms before operation with mean duration of 129 ± 182 days. Twenty-five patients (82%) had radicular symptoms with mean duration of 32 ± 45 days. Twenty-one of the cases (64%) were identified as Tomita Type 7 (Multiple lesions). Ten patients (30%) were located between Tomita Type 4 to 6 (Extra-compartmental). Thirteen of the cases (39%) had chemotherapy, and 5 Patients (15%) had radiotherapy prior to surgery. Operation duration was 181 ± 95 minutes. Blood loss was 2271 ± 1745 ml.

The neurological status was improved in 14 Patients out of 24 patients (58%), maintained in 16 cases and decreased in 3 patients.
At the end of study, 29

patients died. The mean survival duration was 25 ± 20 months (range from 1.4 month to 72 months).

Conclusion: The surgical treatment of spinal solitary plasmacytoma and multiple myeloma based on Aarhus Algorithm is an effective method of treatment with respect to neurological function.



63. Posterior Column Reconstruction with Titanium Lamina Mesh after Total En bloc Spondylectomy of Spinal Tumor

Jae Yoon Chung; Hyoung-Yeon Seo, MD; Sung-Kyu Kim; Whoan Jeang Kim
Republic of Korea

Summary: Titanium lamina mesh for the posterior column reconstruction during total en bloc spondylectomy was a easy and useful method that provided permanent posterior column stability.

Introduction: To investigate the usefulness of titanium lamina mesh for posterior column reconstruction after total en bloc spondylectomy in patients with spinal tumor and evaluate the clinical and radiological outcomes of this method.

Methods: The subjects of this study were 8 patients who underwent total en bloc spondylectomy with posterior column reconstruction using titanium lamina mesh and bone graft for treating a spinal bone tumor. The mean age at the time of surgery was 50.6 years (range, 16.5-70.9 years) and the mean follow up duration was 38.5 months (range, 14.0-59.5 months). The pathologic lesions were located from the T2 to L1 vertebrae. There were 4 cases of primary tumor and four cases of metastatic tumor. All the surgeries were performed by a single posterior approach, and we used a titanium cage for reconstructing the anterior and middle columns. For the posterior column reconstruction, titanium lamina mesh was used and bone graft was applied over the lamina mesh. To evaluate the clinical outcomes, we used McAfee's 4 point scale and neurologic assessment by Frankel's classification. The postoperative plain radiographs and computed tomography scans were used to investigate the displacement of the lamina mesh and fusion of the grafted bone above the lamina mesh.

Results: All the clinical outcomes were improved compared to the preoperative data. At the postoperative 6 months follow up, complete bone union between titanium lamina mesh and adjacent lamina was observed on the computed tomography. On the last follow-up, there was no collapse or displacement of titanium lamina mesh, and we did not observe any instability and malalignment of the spinal column.

Conclusion: Titanium lamina mesh for the posterior column reconstruction during total en bloc spondylectomy was a useful method that provided permanent posterior column stability and protection for the spinal cord and convenience to control the size easily.

64. Cervical Alignment Parameters as Part of Global Sagittal Balance

Jayme R. Hiratzka, MD; Michael D. Daubs, MD; Prokopis Annis, MD; Justin B. Hohl, MD; Brandon Lawrence, MD; Darrel S. Brodke, MD
USA

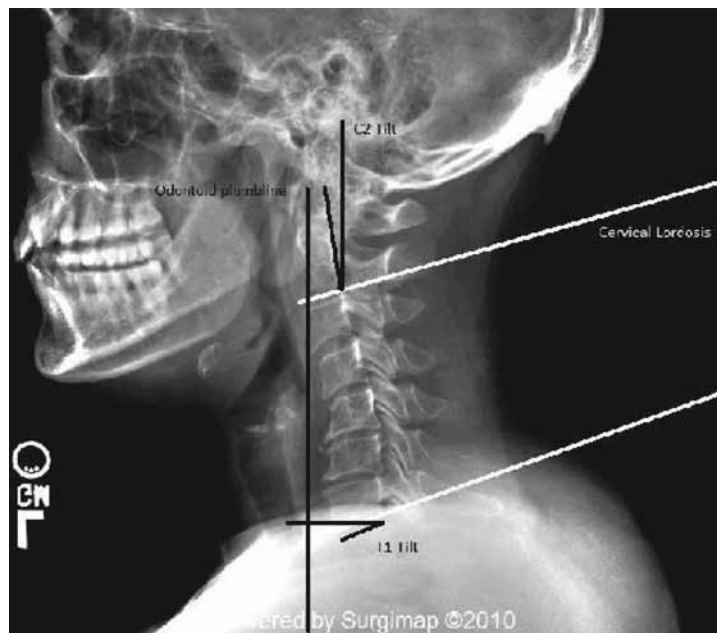
Summary: Reliable and reproducible parameters for the evaluation of cervical spine alignment have not been established. This study defines radiographic parameters of cervical alignment in 99 adult patients without sagittal imbalance. This information will be useful in future studies addressing the effects of global sagittal imbalance and corrective surgeries on the cervical spine.

Introduction: In the past, significant emphasis has been placed on thoracic and lumbar alignment as it relates to global sagittal balance. There has been less focus on the cervical component of spinal balance. This is in large part because there are no agreed upon parameters to evaluate sagittal alignment of the cervical spine. The purpose of our study was to define cervical sagittal alignment parameters as they relate to global spinal balance in an adult population with normal thoracolumbar sagittal alignment, using reliable and reproducible radiographic landmarks.

Methods: We identified 99 patients (mean age 62 years, range 22-85) from our database with degenerative lumbar conditions who had full-length scoliosis films including the skull base and hip joints on a single lateral view. All patients had normal sagittal balance as defined by a C7 plumbline <5cm from the posterior aspect of the L5-S1 disc. The distance from a plumbline dropped from the tip of the odontoid to the posterior aspect of the L5-S1 disc was used as a proxy for the position of the head relative to the lumbosacral junction. Other parameters included C2 tilt, measured as the angle of the back of the posterior aspect of the odontoid/C2 body from vertical, and T1 tilt, measured as the angle of the superior endplate of T1 from the horizontal (Figure 1). Cervical lordosis (C2-7), pelvic tilt, sacral slope and pelvic incidence were measured using previously described techniques

Results: Mean sagittal balance measured by C7 plumbline was +1.8 cm (95%CI 1.4 to 2.3). Mean odontoid tip plumbline was +4.4 cm (95%CI 3.8 to 5.0). Mean cervical lordosis was -16° (95%CI -18 to -13), while T1 tilt and C2 tilt measured 30° (95%CI 28 to 32) and 7° (95%CI 5 to 9), respectively. Pelvic tilt (23°), sacral slope (37°), and pelvic incidence (57°) were similar to previously defined normal values.

Conclusion: This study is the first to attempt to define normal cervical alignment parameters in relation to global balance in adult patients with degenerative lumbar disease and normal sagittal balance. These measurements may be useful when evaluating the effects on the cervical spine of sagittal imbalance and its' surgical management.



65. The Impact of Standing Regional Cervical Sagittal Alignment on Outcomes in Posterior Cervical Fusion Surgery

Jessica A. Tang, BS; Justin K. Scheer, BS; Justin S. Smith, MD, PhD; Vedat Deviren, MD; Shay Bess, MD; Robert A. Hart, MD; Virginie Lafage, PhD; Christopher I. Shaffrey, MD; Frank Schwab, MD; Christopher P. Ames, MD
USA

Summary: Sagittal malalignment of the spine has been linked to disability and unfavorable health related quality of life scores in previous studies. This study is the first to evaluate the relationship between cervical sagittal alignment and postoperative outcomes for patients receiving multi-level cervical fusion. Our findings demonstrate that, similar to the thoracolumbar spine, the severity of disability increases with positive sagittal malalignment following surgical reconstruction.

Introduction: Sagittal malalignment of the spine has been previously linked to disability and unfavorable health related quality of life (HRQOL) scores. To date, no study has evaluated the relationship between cervical sagittal alignment and postoperative HRQOL scores for patients receiving multi-level cervical fusion. This study aims to evaluate the relationship between sagittal alignment of the cervical spine and patient-reported HRQOL scores following multi-level posterior cervical fusion.

Methods: From 2006-2010, 113 patients (M/F=61/52; 59±12 y.o.) received multi-level cervical fusion for cervical stenosis, myelopathy, and kyphosis. Average postoperative follow-up was 187 days. Radiographic measurements included lordosis measurements for C1-C2 and SVA (sagittal vertical axis) measurements for C2-C7, CGH (center of gravity of head)-C7, and C1-C7 SVA (distance between plumb line and C7). HRQOL included neck disability index (NDI) and SF-36 physical component (PCS) scores. Pearson product-moment correlation coefficients were calculated between pairs of radiographic measures and HRQOL scores.

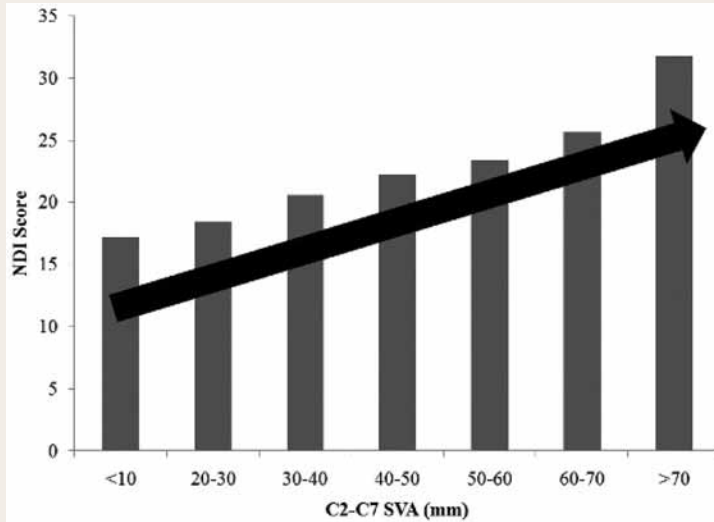
Results: Both C2-C7 SVA and CGH-C7 SVA negatively correlated with PCS ($r=-0.43$, $p<0.001$, and $r=-0.36$, $p=0.005$, respectively). C2-C7 SVA positively correlated with NDI scores ($r=0.20$, $p=0.036$).

PAPER ABSTRACTS

C1-C2 lordosis constituted $76.0 \pm 15.8\%$ of total cervical lordosis (sum of C1-C2 and C2-C7 lordosis). C2-C7 SVA positively correlated with C1-C2 lordosis ($r=0.33$, $p=0.0003$).

For significant correlations between C2-C7 SVA and NDI scores, regression models predicted a threshold C2-C7 SVA value of approximately 40mm, beyond which correlations were most significant.

Conclusion: Positive cervical sagittal malalignment, measured by C2-C7 SVA, negatively affects HRQOL scores following multi-level cervical fusion at intermediate follow-up. This study proposes that a C2 plumb line greater than approximately 40 mm from the posterior superior aspect of C7 suggests a clinical concern of cervical sagittal malalignment that may negatively impact HRQOL. Our findings demonstrate that, similar to the thoracolumbar spine, the severity of disability increases with positive sagittal malalignment following surgical reconstruction.



66. The Crucial Role of Cervical Alignment in Regulating Sagittal Spino-Pelvic Alignment in Human Standing Posture

Benjamin Blondel, MD; Frank Schwab, MD; Christopher P. Ames, MD; Jean-Charles Le Huec, MD, PhD; Justin S. Smith, MD, PhD; Christopher I. Shaffrey, MD; Shay Bess, MD; Jason Demakakos; Bertrand Moal, Master of Science; Patrick Tropiano, MD; Jean-Pierre C. Farcy, MD; Virginie Lafage, PhD USA

Summary: Radiographic analysis of asymptomatic adult volunteers to assess alignment relationships throughout the mobile axial spine and pelvis needed to maintain optimal sagittal position demonstrates interactions occur along the entire spine and pelvis. Understanding the alignment interactions and compensatory mechanisms that occur along the entire mobile axial spine to maintain upright posture is essential to effectively evaluate and treat adults with pathological conditions of the spine.

Introduction: Individuals maintain specific alignment relationships from the skull to the pelvis to maintain painless upright posture. **Purpose:** evaluate alignment correlations from the cervical spine to the pelvis to determine regional postural adaptations needed to maintain optimal sagittal position and maintenance of horizontal gaze.

Methods: Adult volunteers (n=55; 27 men, mean age 45 years; range 20-77) without history of chronic low back

pain or back surgery were evaluated by full-length standing radiographs using a standardized protocol. Measurements included: C2-C7 cervical lordosis (CL), T4-T12 thoracic kyphosis (TK), L1-S1 lumbar lordosis (LL), pelvic tilt (PT), sagittal vertical axis (SVA), pelvic incidence (PI) and difference between PI and LL (PI-LL). Study cohort was stratified by age (20-39, 40-59 and ≥ 60 years). Lordosis was denoted positive, kyphosis denoted negative.

Results: Average (SD) regional sagittal parameters were: CL= $+11.7^\circ$ (11), TK= -39.5° (12), LL= $+59.6^\circ$ (11), PI= 53.3° (10), PT= 14.2° (7) and SS= 39.1° (9). Average (SD) global alignment parameters were: SVA= -12 mm (41), PI-LL= -6.4° (10) and T1-slope= 24.2° (9). A chain of correlation from the pelvis to the cervical spine was identified: PI and LL ($r=0.52$, $p<0.001$), LL and TK ($r=0.34$, $p=0.011$) and TK and CL ($r=0.51$, $p<0.001$). In addition, PT correlated with CL ($r=0.310$, $p=0.021$) and CL correlated with SVA ($r=0.305$, $p=0.024$). Comparison between age groups demonstrated patients ≥ 60 years had larger CL (22.2°) than patients 20-39 years (9.4° ; $p<0.05$) and patients 40-59 years (CL= 6.6° ; $p<0.05$). Older patients had higher SVA (22.4 mm vs. -28.5 , $p<0.001$) and T1-slope (-31.6° vs. -22° , $p=0.001$), compared to 20-39 year age group. No significant differences were found between the two younger groups.

Conclusion: A global understanding of sagittal alignment interactions for a wide age range of asymptomatic patients is essential to accurately evaluate and treat adult spinal deformity patients. This study reveals global interactions of the regional curvatures along the entire axial spine including the pelvis in an adult volunteer population.

67. Concomitance of Adult Spinal Deformity and Cervical Spondylosis

William Schairer; Alexandra Carrer, MD; Kyle A. Mitsunaga, MD; Michael Lu, MD; Sigurd H. Berven, MD; Vedat Deviren, MD; Dean Chou, MD; Bobby Tay, MD; Christopher P. Ames, MD; Serena S. Hu, MD USA

Summary: We used a hospital-based administrative claims database in our large referral spine center to assess the incidence of symptomatic cervical pathology as well as adult thoracolumbar spine deformity. We found that patients with either diagnosis were more likely to have a second spinal diagnosis compared to the general population. This confirms a recent study using a national administrative claims database, where it was found that patients with either diagnosis are at increased risk for having a concomitant spine disease.

Introduction: Cervical spondylosis and TL deformity typically present with upper and lower extremity symptoms, respectively, but both can cause similar symptoms. The purpose of this study was to explore the relationship of symptomatic cervical spondylosis and TL deformity.

Methods: This retrospective study at a large referral spine center utilized an administrative claims database from 2006 to 2011. Logistic regression was performed using diagnosis, radiographic, and surgical procedure utilization to evaluate predictive value and increased risk of co-diagnosis between cervical spondylosis and TL deformity.

Results: There were 54,249 patients seen by the orthopaedic service at our institution between 2006 and 2011. There were 6,195 (11.4%) with a diagnosis of TL deformity and 6,756 (12.5%) with a cervical spondylosis; 1,589 (2.9%) patients had both diagnoses. Controlling for age, patients with cervical spondylosis were 2.82 times more likely to have TL deformity than patients without cervical spondylosis. Similarly, TL deformity patients were 2.77 more likely to have spondylosis than

patients without deformity. Adding radiographic and surgical utilization to the model revealed additive risk of spondylosis in the deformity population, but narrowed the risk of deformity in the spondylosis population to receiving a cervical fusion (Table 1).

Conclusion: Adult deformity and cervical spondylosis are associated with increased risk of having concomitant diagnoses. In patients with TL deformity, increased risk of spondylosis was found with each progressive diagnostic or therapeutic option. In patients with spondylosis, the increased risk TL deformity appears mainly linked to patients who receive a cervical fusion. The cause of the association of these two conditions remains to be investigated.

68. Scoliosis with Cervical Spine Pathologies

Mehmet B. Balioglu, MD; Can H. Yildirim, MD; Erol - Tasdemiroglu; Aytac Akbasak, MD Turkey

Summary: We retrospectively reviewed scoliotic patients using cervical MRI. Cervical spinal pathologies vary according to scoliosis type. The most common occurring pathology was syringomyelia.

Introduction: The aim of this study was to evaluate any cervical spine pathologies in patients with scoliosis using MRI.

Methods: We retrospectively reviewed scoliotic patients using MRI. Patients were diagnosed with idiopathic, congenital, neuromuscular and syndromic scoliosis. All patients were examined for cervical spinal pathologies.

Results: Of 402 patients 290 were diagnosed with idiopathic scoliosis (IS) (72%) 48 congenital (12%), 44 neuromuscular (11%) and 20 syndromic (5%). The cervical spines of all patients were evaluated with MRI. Results revealed pathologies in the cervical spine for every group. IS - 10 patients (8 female, 2 male) mean age 14.9; pathologies: 6 syringomyelia, 1 cerebellar tonsillar hernia, 2 posterior vertebral fusion, 1 cervical arachnoid cyst. Congenital scoliosis: 13 (10 female, 3 male) age 15; pathologies: 8 congenital vertebra anomalies, 4 syringomyelia, 2 cerebellar tonsillar hernia, 1 vertebral hipoplasia, 1 split cord, 1 neuroenteric cyst. Neuromuscular scoliosis: 17 patients (12 female, 5 male) age 15.3: 7 syringomyelia, 7 cerebellar tonsillar hernia 2 atlantoaxial dissociation, 4 congenital vertebral anomalies, 2 arachnoid cyst, 1 myelomalasia, 1 diastometamyelia, 1 decrease in the cranioservical angle. Syndromic scoliosis: 4 patients (4 male) age 14; pathologies: 2 syringomyelia, 1 atlantoaxial dissociation, 1 dermoid cyst. Of all patients 44 (11%) had cervical spine pathologies. The most common pathologies: 19 syringomyelia (4.7%), 12 congenital vertebral anomalies (2.9%), 10 cerebellar tonsillar hernia (2.4%). 69.7% of all patients were female and 30.3% were male, average age was 15.

Conclusion: Cervical spinal pathologies vary according to scoliosis type. Only 3.4% of 290 IS patients were diagnosed with cervical spinal pathologies but the percentage was much higher for neuromuscular patients - 38.6%, 44 patients. The most common occurring pathology was syringomyelia, followed by congenital vertebral anomalies and cerebellar tonsillar hernia. Preoperative MRI scan can provide vital information regarding cervical spinal pathologies.

69. Radiological and Clinical Outcome of the Operated and Adjacent Segments Following Cervical Arthroplasty after a Minimum 24-Month Follow-Up: A Single Surgeon-Center Experience

Murat Siriki; Meric Enercan; Sinan Kahraman; Mercan Sarier; Ibrahim Ornek; Levent Ulusoy; Alauddin Kochai; Cagatay Ozturk, MD; Ahmet Alanay; Azmi Hamzaoglu, MD Turkey

Summary: Cervical disc arthroplasty provides satisfactory results with low complication rate in treatment of cervical degenerative disc disease in young adults.

Introduction: The purpose of this retrospective study was to determine the radiological outcome at the index and adjacent levels and clinical outcome of cervical total disc arthroplasty (TDA) after a minimum 24 months follow-up at a single center

Methods: 86 levels of 59 (28 F, 31M) cases with minimum 2 years f/up were included in this study. Younger patients with radicular pain, with no facet joint arthrosis and with preserved disc height >50% were selected for TDA. All patients had Prodisc-C as TDA. Radiological parameters including disc level height at the operated and adjacent levels, global cervical lordosis, segmental lordosis, range of motion, subsidence, facet arthrosis, adjacent segment degeneration (ASD) and heterotopic ossification were analysed. All surgeries were done by a single surgeon. All patients had prophylactic indomethasin for 6 weeks after surgery

Results: Av. age was 39,5 (27-56) and av. f/up was 33,6 (24-81) month. Operated levels were C3-4 (%4,6), C4-5 (%16,3), C5-6 (%48,8), C6-7 (%26,8), C7-T1 (%3,5). All patients had clinical improvement. NDI was improved from 46 to 9. There was a significant improvement in segmental kyphosis, global lordosis and disc height at the operated level with no significant change at the final f/up (table 1). There was no radiographic facet joint arthrosis at the index and adjacent levels 4 (%6,7) patients had radiographic signs of ASD at the cranial adjacent level while 5 (%8,4) patients had ASD at the caudal adjacent level. Heterotopic ossification (HO) was observed in 4 patients (%6,7) with a complete fusion in one patient

Conclusion: This study demonstrates a satisfactory radiographic and clinical outcome after TDA with a minimum 24-month follow-up

70. Lessons Learned on Cervical Total Disc Replacement after Eight Years Follow-Up

Luis Marchi, MSc; Leonardo Oliveira, BSc; Rodrigo A. Amaral; Carlos A. Castro; Thiago Coutinho; Etevaldo Coutinho; Luiz Pimenta, MD, PhD Brazil

Summary: Here we show our 8 years experience with PCM total disc replacement.

Introduction: Various studies demonstrate that single-level ACDF procedures do alter spinal kinematics and multilevel procedures compromise global spinal motion. Arthroplasty technology was developed to maintain movement and reduce adjacent segment stress and degeneration.

Methods: We studied radiographs of 270 levels in 158 patients treated with cervical TDR using the PCM device between C3-4 and C7-T1. Radiological and clinical outcomes were collected preoperatively, 1 week and 1, 3 and 6 months and annually.

Results: Using the four grade classification, the majority of patients belong to grade I and II. We didn't find

PAPER ABSTRACTS

relationship between the CT scan facet degeneration and clinical results in these stages, except in grade III and IV that outcomes scales had a worsening. 21 (7.7%) revealed some level of HO. Of these, 10 levels were rated to be grade I (47.6%), 7 to be grade II (33.3%), 3 to be grade III (14.28%) and 1 to be grade IV (4.76%). The affected disc level was part of a multi-level procedure in 41.6%, and 58.4% in a single level construction. In 92% of patients that developed HO, preoperative radiographs showed incipient osteophytes. Painful adjacent level disease occurred in 5.7% of patients.

Conclusion: Our experience in cervical TDR has revealed valuable clinical and radiological data when compared to ACDF. The good clinical results also corroborate with the superiority of cervical TDR in comparison to ACDF results described on the literature.

71. Anterior Cervical Discectomy and Fusion vs. Cervical Disc Arthroplasty: Cost-Utility Analysis-Based on an Institutional Financial Data Economic Model

Tate M. Andres, BS; Daniel T. Warren, MD; Pedro A. Ricart Hoffiz, MD, MS; Christian Hoelscher, BS; Virginia Lafage, PhD; Jeffrey A. Goldstein, MD; John A. Bendo, MD
USA

Summary: This study describes a cost-utility analysis of Anterior Cervical Discectomy and Fusion and Cervical Disc Arthroplasty using institutional financial data.

Introduction: Patients with single-level cervical disc herniations are traditionally treated with Anterior Cervical Discectomy and Fusion (ACDF), but Cervical Disc Arthroplasty (CDA) has recently been shown to result in similar clinical outcomes. A cost-utility analysis with institutional financial data has not yet been reported.

Methods: We reviewed single institution data from a randomized controlled trial (RCT) comparing 28 patients of either single-level ACDF or CDA. Data collected included demographics, HRQOL outcome scores (NDI and SF-36) and utility scores. The financial records of a separate cohort of 28 patients were reviewed to estimate hospital cost, charge and payment data for each procedure. QALYs were calculated at 1 and 2 years after surgery, allowing for cost/QALY assessments and incremental cost-effectiveness ratios (ICER) utilizing both types of outcome scores.

Results: RCT and financial cohort patients undergoing ACDF or CDA were not significantly different in their demographic data. At two years, total QALYs gained when using NDI scores were 0.37 and 0.27 for ACDF and CDA, respectively; with SF-36 scores, total QALYs gained after two years were 0.47 and 0.32 for ACDF and CDA. The total costs of these procedures, including surgeons and anesthesiologist fees, were \$19,811 and \$18,440, respectively. Total Cost/QALY at 2 years using NDI scores was \$53,543 for ACDF and \$68,295 for CDA; Total Cost/QALY at 2 years using SF-36 scores was \$42,151 and \$57,624. The incremental cost-effectiveness ratio (ICER) of ACDF versus CDA at 2 years was \$1,043 with NDI scores and \$695 with SF-36.

Conclusion: Both ACDF and CDA demonstrate cost-effectiveness. The additional QALYs gained by ACDF suggest a more cost-effective profile for this procedure at two years; ICERs suggest that the added benefit via ACDF comes at a reasonable cost. In comparison with our previously reported findings using a Medicare-based financial model, the ICERs are significantly lower when using hospital costs; this highlights the way in which cost-effectiveness research is influenced by the chosen financial model. Long-term follow-up may show greater cost-effectiveness via

CDA due to lower hospital costs, reduced adjacent segment degeneration and less frequent revision surgery.

72. Does Cervical Disc Arthroplasty Reduce Adjacent Segment Disease and Other Complications in Comparison to Anterior Cervical Discectomy and Fusion? A Meta-Analysis of Randomized Controlled Trials

Dino Samartzis, DSc, PhD (C), MSc; Patrick Vavken; Hitesh N. Modi, MS, PhD; Keith D. Luk, MD; Kenneth M. Cheung, MBBS(UK), FRCS(England), FHKCOS, FHKAM(Orth)
China

Summary: A meta-analysis of the literature was performed to assess the development of adjacent segment degeneration/disease between cervical disc arthroplasty (CDA) to that of anterior cervical discectomy and fusion (ACDF) at 2 and 4 year follow-up periods. Due to weaknesses in study design, heterogeneity in management, and relatively high withdrawal/drop-out rates, robust conclusions supporting the advocacy of CDA over ACDF cannot be made at this stage.

Introduction: To reduce the risk of adjacent segment disease and other procedure-related complications following anterior cervical discectomy and fusion (ACDF), cervical disc arthroplasty (CDA) has been advocated for one-level cervical disc disease. However, it remains unknown whether CDA decreases the occurrence of such complications. As such, the following study addressed a meta-analysis of randomized controlled trials assessing the efficacy of CDA in reducing adjacent segment disease and other complications in comparison to ACDF.

Methods: Three reviewers performed a literature search for randomized controlled trials comparing CDA to ACDF for radiculopathy and/or myelopathy for one-level cervical disc disease. Studies with 2 years or greater follow-up were selected. Adjacent segment disease, secondary surgery (i.e. revision, reoperation, instrumentation/graff removal), and adverse events were assessed and pooled for analyses.

Results: Eight studies were included for review. Due to limitations with study design, studies presented with Level II evidence. CDA exhibited a decrease risk for reoperation attributed to adjacent segment disease, but was not statistically significant ($p>0.05$). Additional procedure-related complications did not statistically differ between groups ($p>0.05$).

Conclusion: Up to 4 year follow-up, CDA does not significantly reduce the risk of adjacent segment disease and other complications in comparison to ACDF. Due to the lack of blinding, variation in surgical management, and relatively high withdrawal/drop-out rates among studies at 2 and 4 year follow-up, robust conclusions supporting the advocacy of CDA over ACDF cannot be made at this stage. High-quality studies are needed to properly assess the true efficacy of such interventions.

73. A Randomized Control Trial Evaluating Effectiveness of a Synthetic B2A Peptide in Achieving Lumbar Interbody Fusion: Twelve-Month Results of a Multicenter, Blinded Canadian Study

Zeeshan Sardar, MD, CM; Peter Jarzem, MD; Eugene K. Wai, MD, MSc, CIP, FRCSC; D. Greg Anderson, MD
Canada

Summary: This is a multicenter, prospective, randomized, blinded control trial (Evidence Level: I) comparing effectiveness of B2A Peptide Enhanced Ceramic Granules (Prefix) and Iliac crest autograft (Control) in achieving fusion in patients undergoing Transforaminal Lumbar Interbody Fusion (TLIF). Our results indicate that at 12 months, the higher concentration of prefix achieved higher fusion rate than control

and was equivalent to control in terms of functional scores. Prefix groups had less morbidity at 6 weeks and did not have any lasting complications.

Introduction: Single level TLIF is a commonly performed procedure due to the high prevalence of degenerative disc disease (DDD). Fusion failure is a challenging problem that can lead to ongoing back pain, dependence on pain medication and inability to return to work. The current graft standard (iliac crest) is associated with increased morbidity. B2A is a 45 amino acid synthetic active fragment of the BMP-2 molecule that has proven efficacy in achieving fusion in animal models and may have a better safety profile compared to other BMPs.

Methods: Patients were randomized to 3 groups: iliac crest bone graft, Prefix concentration 150µg and Prefix concentration 750µg. 24 patients (9 Control, 8 Prefix 150, 7 Prefix 750) with DDD at L2-S1 requiring TLIF were enrolled between 2009 - 2010. The patients had preoperative screening low back pain or leg pain of at least 6cm using a 10cm visual analog back pain scale (VAS) and had at least 20 points (40%) on the Oswestry Disability Index (ODI). Outcome measures included ODI, VAS, and fusion outcome as assessed by CT and dynamic flexion and extension x-rays (interpreted by an independent, blinded radiologist). Patients were evaluated at 6 weeks, 3, 6 and 12 months after surgery.

Results: Mean blood loss during surgery was higher ($p=0.038$) in the control group (569ml) than both Prefix 150 (364ml) and Prefix 750 (314ml). There was no difference in length of hospital stay between the 3 groups. Prefix 750 had the highest fusion rate (100%) compared to control (78%) and Prefix 150 (50%) at 12 months. At 6 weeks, the mean ODI was 41 for control, 27.7 for Prefix 750 and 32.2 for Prefix 150. While, at 12 months, the mean ODI was 24.4 for control, 31.1 for Prefix 750 and 29.7 for Prefix 150. 100% of patients maintained or improved neurological scores in Prefix 750 compared with 89% for control and 50% for Prefix 150. 2 patients had transient elevation of liver enzymes and 1 had wound infection. Complications were evenly distributed amongst the groups.

Conclusion: Prefix provides a safe alternative to iliac crest bone graft. Prefix 750 showed superior fusion rate to autograft at 12 months for TLIF and avoids the initial morbidity associated with iliac crest graft. Prefix and control were equivalent in improving ODI at 12 months.

The FDA has not cleared the drug and/or medical device for the use described in this presentation (i.e., the drug or medical device is being discussed for an 'off label' use).

74. Two Year Bone Morphogenetic Protein Clinical Effects after Lumbar Fusion in Degenerative Disc Disease

Andriy Noshchenko, PhD; Evalina L. Burger, MD; Christopher M. Cain, MD; Emily M. Lindley, PhD; Vikas V. Patel, MD
USA

Summary: A meta-analysis of 18 clinical trials found that BMP use is not associated with significant improvements in clinical outcomes or fusion rate at 24-48 months after lumbar fusion in patients with DDD.

Introduction: Several prospective randomized controlled clinical trials (RCT) have reported that BMP significantly improves lumbar fusion clinical outcomes and fusion rates at 12 months postoperative, particularly in patients with spondylolisthesis. However, other relatively small studies have reported higher complication rates after BMP use. The purpose of the present meta-analysis study was to evaluate the effects of BMP on long-term lumbar fusion clinical outcomes in patients with DDD.

Methods: The Cochrane database of randomized controlled trials (RCT), Cochrane Database of Systematic Reviews, Pubmed, Medline, Embase, ClinicalTrial.gov, and published reviews were used to search for published studies that met our inclusion/exclusion criteria. Inclusion criteria were: 1) age >18 years, 2) lumbar DDD with or without: stenosis, grade I-II degenerative spondylolisthesis, disk herniation, and other disk pathology, 4) follow up ≥ 24 month for clinical outcomes and fusion rate, 5) use of Oswestry disability index (ODI), back and/or leg pain Visual analog scale (VAS), and/or SF-36 questionnaire, 6) not less than 2 year postoperative complication rate, 7) published between 2000 and 2010, 9) English language. Exclusion criteria: scoliosis, trauma, isthmic spondylolisthesis, tumors, radiculopathy. A meta-analysis was performed to assess pooled treatment effect size, heterogeneity, and the risk of publication bias. The data were grouped by whether or not BMP was used. Data pooling was performed by randomized effect model.

Results: A total of 18 studies from 7 countries met the inclusion/exclusion criteria: 14 RCT, 3 cohort studies, and 1 retrospective case series. Pooled data showed significant improvements in disability, pain, and physical health status after lumbar fusion regardless of whether or not BMP was used, (Table). Fusion rates were relatively high and approximately similar for both BMP and non-BMP groups. BMP was not associated with an increased complication rate. The risk of publication bias was not significant ($p<0.001$).

Conclusion: Fusion outcomes at 24-48 months postoperative for lumbar DDD are not significantly improved by the use of BMP. This result suggests that the potential benefits of BMP are limited to the early stages of fusion

75. Can Decompression Surgery Relieve Low Back Pain in Patients with Lumbar Spinal Stenosis Combined with Degenerative Lumbar Scoliosis?

Ryohei Kagotani, MD; Shunji Tsutsui; Hiroshi Yamada, MD, PhD; Hiroshi Hashizume, MD, PhD; Akihito Minamide, MD, PhD; Yukihiko Nakagawa, MD, PhD; Masaki Kawai, MD; Hiroshi Iwasaki, MD; Keiji Nagata; Yuyu Ishimoto; Munehito Yoshida
Japan

Summary: Patients with lumbar spinal stenosis (LSS) combined with degenerative lumbar scoliosis (DLS), who underwent decompression surgery and had a minimum follow-up of at least one year, were retrospectively reviewed to evaluate whether or not low back pain (LBP) could be alleviated postoperatively and to clarify predictors of postoperative residual LBP. Although approximately 60% of patients with LBP preoperatively were relieved from LBP postoperatively, the relief of LBP was significantly associated with the severity of apical vertebral rotation in preoperative radiograph.

Introduction: In surgical planning for lumbar spinal stenosis (LSS) with degenerative lumbar scoliosis (DLS), decompression and fusion has been usually recommended. However, elderly patients with LSS and DLS often have other comorbidities, and surgical treatment should be performed in a safe and effective way. The aim of this study was to investigate whether or not decompression surgery could alleviate low back pain (LBP) and to clarify predictors of postoperative residual LBP in patients with LSS combined with DLS.

Methods: All patients included in this study underwent decompression surgery for LSS combined with DLS ($\text{Cobb} \geq 10^\circ$) and had a minimum follow-up of one year and were retrospectively reviewed using the Japanese Orthopaedic Association (JOA)

PAPER ABSTRACTS

scoring system for the assessment of lumbar spinal diseases. Radiographic measurements included coronal and sagittal Cobb angles, apical vertebral rotation (Nash-Moe), and anteroposterior and lateral spondylolisthesis. Logistic regression analysis with the relief of LBP at one year after surgery as an objective factor was performed to investigate predictors of postoperative residual LBP.

Results: 75 patients (33 males and 42 females) with a mean age of 71.8 years (range, 53-86 years) were analyzed. 49 of 75 patients suffered from LBP preoperatively. In 29 (59.1%) of 49 patients with LBP preoperatively, LBP was alleviated after surgery. Logistic regression analysis demonstrated that the apical vertebral rotation in preoperative radiograph (odds ratio; 8.16, 95% confidence interval; 1.55-83.81, $p=0.011$) was significantly related to the postoperative residual LBP. Age, gender, coronal and sagittal Cobb angles and anteroposterior and lateral spondylolisthesis were not associated with the residual LBP after surgery.

Conclusion: Approximately 60% of patients with LSS combined with DLS were relieved from LBP after decompression surgery. The relief of LBP was significantly associated with the severity of apical vertebral rotation in preoperative radiograph.

76. National Trends in the Use of Interbody Fusion Techniques to Treat Degenerative Spondylolisthesis: Data from the American Board of Orthopaedic Surgeons (ABOS)

Christopher K. Kepler, MD, MBA; Alexander R. Vaccaro, MD, PhD; Alan S. Hilibrand, MD; D. Greg Anderson, MD; Jeffrey A. Rihn, MD; Todd J. Albert, MD; Kris Radcliff, MD USA

Summary: The ABOS database was queried to study the type of surgical procedures performed on patients with degenerative spondylolisthesis over the past 13 years. The rate of interbody fusion has increased dramatically while the rate of posterolateral fusion has declined. There is significant regional variation in treatment patterns. Despite a lack of evidence suggesting an optimal treatment strategy for degenerative spondylolisthesis, there has been dramatic change in treatment patterns raising questions regarding potential drivers of changing treatment patterns.

Introduction: Spinal stenosis associated with degenerative spondylolisthesis (DS) is commonly treated with decompression and fusion but little is known about the optimal type of fusion technique. During a 6 month period, candidates for the Step II ABOS examination compile and subsequently submit lists of procedures that they perform; these lists have been stored in an electronic database since 1999.

Methods: The ABOS database was retrospectively queried to identify all patients who underwent surgery for DS from 1999-2011. Patients were included if they underwent one of the following procedures: uninstrumented fusion, fusion with posterior instrumentation, fusion using interbody device, or decompression without fusion. Utilization of these four procedures was analyzed by year and geographic region.

Results: The study period included 5639 DS cases; the annual number of cases doubled over the period of study. The percentage of cases treated with interbody fusion (IF) increased significantly throughout the study period, averaging 13.6% over the first three years (1999-2001) and 32% over the last three years (2009-2011) ($p<0.001$). The percentage of DS cases treated with posterolateral fusion peaked in 2003 then decreased as the rate of IF increased. In 2011, the rates of posterolateral fusion (40%) and posterolateral fusion with

IF (37%) were nearly identical. The Northwest had the highest rate of IF (41%), >10% higher than any other region ($p<0.001$) and >23% higher than the Southeast ($p<0.001$).

Conclusion: Despite a lack of evidence regarding optimal fusion strategy for patients with DS, national treatment patterns have changed dramatically over the past 13 years. The rapid adoption of interbody fusion and substantial regional variation in treatment utilization patterns raises questions about drivers of change which may include changes in perceptions about associated fusion rates, the importance of sagittal balance and differential reimbursement based on procedure performed.

77. Predictive Factors for the Use of Cell Saver Infusion in Lumbar Spinal Surgery

Roger K. Owens, MD; Charles H. Crawford, MD; Mladen Djurasovic, MD; Chelsea E. Canan, MPH; Lauren O. Burke, MPH; Kelly R. Bratcher, RN, CCRP; Kathryn J. McCarthy, MD; Leah Y. Carreon, MD, MSc USA

Summary: In a study of 285 patients who underwent posterolateral fusion, Body Mass Index (OR=1.06), number of levels fused (OR=2.50), and number of TLIFs performed (OR=2.41) were independent risk factors for the use of cell saver infusion. Use of cell saver infusion did not reduce the requirement for intraoperative or postoperative transfusion.

Introduction: Due to the potential for significant intraoperative blood loss in lumbar spinal surgery, cell saver has commonly been used in an attempt to minimize allogeneic blood transfusion. Conflicting reports exist, which call into question the efficacy of cell saver use. This study aimed to identify risk factors for cell saver infusion in lumbar spinal surgery and determine if the use of a cell saver infusion affected transfusion rates during or after surgery.

Methods: We reviewed inpatient medical records of 285 randomly selected patients who underwent posterolateral fusion (PSF) with or without transforaminal interbody fusion (TLIF) from July 2010 to June 2011. Intraoperative and postoperative transfusion rates as well as transfusion related complications were examined. Binary logistic regression was performed to identify independent risk factors for use of cell saver infusion.

Results: There were 178 females and 107 males with a mean age 57.2 ± 13.2 years. Of the 285 cases, 39 had no cell saver available, 147 had cell saver but was not infused and 99 had a cell saver infusion (mean volume = 319mL). Patients who had cell saver infusion had a significantly higher rate of intraoperative allogeneic blood transfusion (52%) compared to those who did not (22%, $p=0.000$). There was no significant difference in the rate of postoperative transfusions between patients who did (24%) and did not (16%, $p=0.080$) have cell saver infusion. There was no significant difference in the rate of transfusion reactions between patients who did (9%) and did not (6%, $p=0.470$) have cell saver infusion. Patient's age, smoking status, ASA grade, use of anticoagulation pre-op, primary or revision surgery, ICBG harvest, anesthesiologist and surgeon had no significant effect on cell saver infusion. Body Mass Index (OR=1.06, CI:1.03-1.08, $p=0.004$), number of PSF levels fused (OR=2.50, CI:2.03-3.09, $p=0.000$), and number of TLIFs performed (OR=2.41, CI:1.88-3.09, $p=0.000$) were independent risk factors for the use of cell saver infusion.

Conclusion: Body Mass Index, multi-level fusion and TLIF result in increased use of cell saver infusion in lumbar spinal surgery. Use of cell saver infusion did not reduce the requirement for intraoperative or postoperative transfusion.

78. Differentiating Minimum Clinically Important Difference for Primary and Revision Lumbar Fusion Surgeries

Leah Y. Carreon, MD, MSc; Mladen Djurasovic, MD; Kelly R. Bratcher, RN, CCRP; Chelsea E. Canan, MPH; Lauren O. Burke, MPH; Steven D. Glassman, MD
USA

Summary: MCID values are similar for Revision compared to Primary cases. They were also very similar to values previously reported in the literature. This simplifies interpretation of clinical improvement, as thresholds are similar in patients having Primary compared to Revision surgery. The results of our study further validates the use of patient reported outcomes to measure clinical effectiveness, as previous experience with care does not seem to affect an individual's perception of clinical improvement.

Introduction: Validated patient based outcome measures have become standards for clinical assessment. Previous studies reported on the Minimum Clinically Important Difference (MCID), a threshold of improvement that is clinically relevant for lumbar degenerative disorders. Recent studies have shown that pre- and post-op outcome measures vary among patients with different diagnostic etiologies. There is also concern that a patient's previous care experience may affect one's perception of clinical improvement. This study determined if MCID values for ODI, SF-36PCS, Back and Leg Pain are different between primary and revision lumbar fusion cases.

Methods: Prospectively collected pre- and one-year post-op patient reported outcomes in lumbar spine fusion patients were analyzed. Outcome measures included ODI, SF36PCS and Numeric Rating Scales (0 to 10) for Back (BP) and Leg Pain (LP). Patients were grouped into either Primary or Revision cases. Primary cases were patients with no previous lumbar surgery. Revision cases included patients with nonunion, adjacent level disease and post-discectomy instability. As the most widely accepted MCID values were calculated from the Minimum Detectable Change (MDC), this method was used to determine MCID.

Results: There were 722 Primary and 333 Revision patients. There was no statistically significant difference in demographics between the two groups. Each group had a statistically significant improvement at one year post-op compared to baseline. MDC derived MCID for the Primary group was 1.16 for BP, 1.36 for LP, 12.40 for ODI and 5.21 for SF36PCS. The MCID values for the Revision group was 1.21 for BP, 1.28 for LP, 11.79 for ODI and 4.90 for SF36PCS. These values are very similar to values previously reported in the literature: 1.16 for BP, 1.64 for LP, 12.81 for ODI and 4.93 for SF36PCS.

Conclusion: MCID values are similar for Revision compared to Primary cases. This simplifies interpretation of clinical improvement, as thresholds are similar in patients having Primary compared to Revision surgery. The results of our study further validates the use of patient reported outcomes to measure clinical effectiveness, as previous experience with care does not seem to affect an individual's perception of clinical improvement.

79. Lumbar Arthrodesis Instrumentation with and without Postoperative Brace

Hani Mhaidli, MD, PhD; Tito Fernandez
Spain

Summary: A prospective study of 50 patients with lumbar degenerative pathology who underwent posterolateral arthrodesis instrumentation surgery with pedicle screws was carried out. Clinical, functional and radiological results were compared between two groups of patients: with and without a rigid lumbar brace.

Introduction: There is controversy regarding the use of post-operative rigid lumbar brace in patients with lumbar fusion and pedicle screws.

Methods: The patients were divided into two groups of 25 patients each by means of a systematic random sampling. In group A there were 12 men and 13 women. Average age of 49 years, five patients with previous lumbar surgery. In group (B) there were 12 men and 13 women with an average age of 47 years, 6 patients had previous lumbar surgery.

Visual Analogical Scale (VAS), health questionnaire SF-36, and Oswestry Disability Index (ODI) in pre-operative and postoperative periods., A-P, lateral, X-Rays, in preop., post-op., six months and annually.

No brace was prescribed for the group (A) during the immediate postoperative period, and a B.O.B brace was prescribed for the group (B) for a period of three months. Average follow-up 36 months (24 - 48).

Results: The preoperative and postoperative ODI in group A was 79.24 and 28.68 ($p < 0.0001$), and in group B was 75.28 and 25.80 ($p < 0.0001$); no significant differences were found between both groups ($p = 0.915$). In Group A there was a preoperative VAS value of 8.36 and postoperative of 3.6 ($p < 0.0001$), and in group B of 8.52 and 2.88 respectively ($p < 0.0001$), with an average VAS improvement of 4.76 in Group A and 5.6 in Group B ($p = 0.247$). 96% rate of fusion is observed in both groups ($p = 0.637$). Similar clinical improvement is evidenced in both groups.

Conclusion: In this study we did not find significant differences in terms of clinical, functional and radiological results between patients with or without a rigid lumbar brace in the immediate postoperative period of lumbar fusion with pedicle screws. Based on this study, we do not recommend the use of a post-operative rigid brace in the immediate postoperative period of lumbar fusion with pedicle screws.

80. Spinal Instrumentation Surgery for Diabetes Patients: Predisposing Factors for Surgical Site Infection

Kotaro Satake, MD; Tokumi Kanemura, MD; Akiyuki Matsumoto; Yoshimoto Ishikawa
Japan

Summary: A retrospective review was performed with 110 diabetes mellitus (DM) patients who underwent spinal instrumentation surgery to determine predisposing factors for surgical site infection (SSI). Preoperative proteinuria is a significant predisposing factor for SSI.

Introduction: Although DM itself is known as an important risk factor for SSI, it is unclear which DM-related parameters have stronger influence on SSI.

Methods: 110 DM patients (66 males and 44 females) who underwent spinal instrumentation surgery were enrolled in this study. For each patient, the following preoperative or intraoperative parameters were reviewed; age at surgery, body mass index (BMI), ASA classification, glucose and protein in urine (1+>), serum creatinine and BUN, diabetologist consultation history, the preoperative hospitalization days for glycemic control, insulin dependence, HbA1c, serum glucose level of the morning before the surgery, operation time and estimated blood loss (EBL). Patients were divided into SSI group and non-SSI group according to the post-operative course. Each parameter was compared between these two groups with univariate and multivariate analyses to determine predisposing factor for SSI.

PAPER ABSTRACTS

Results: The SSI group consisted of 11 patients (10%), and the non-SSI group of 99 patients (90%). Univariate analysis revealed that preoperative proteinuria ($p=0.003$), operation time ($p=0.04$) and estimated blood loss ($p=0.02$) were significantly higher in the SSI group compared to the non-SSI group. Multivariate logistic regression identified preoperative proteinuria as a statistically significant predictor of SSI (OR: 6.28, 95%CI:1.58-25.0, $p=0.009$).

Conclusion: Proteinuria is a significant predisposing factor for SSI in spinal instrumentation surgery for DM patients. DM patients with proteinuria who is likely to suffer nephropathy as well as general vascular compromise have a potential risk for SSI. Less invasive surgery is recommended for the spinal instrumentation for DM patients with proteinuria. Preoperative glycemic control condition was not significantly different between two groups and less likely to be influential on SSI.

81. Fusion vs. Non-Fusion Technology for Meyerding Grade I Degenerative Spondylolisthesis Patients: Four-Year Follow-Up Outcomes

Justin Boey; Benjamin Tow, MBBS, MMED(Orth), FRCS (Orth)
Singapore

Summary: This matched-pair analysis of prospectively collected data investigates the efficacy of Fusion versus non-fusion technology for Grade I degenerative spondylolisthesis patients. At 4 years follow-up, there was no significant difference in the outcome scores and range of motion between DIAM and TLIF patients ($p>0.05$). Therefore, non-fusion technology is comparable to fusion for Grade I degenerative spondylolisthesis patients

Introduction: This matched-pair analysis of prospectively collected data investigates the efficacy of Fusion versus non-fusion technology for Grade I degenerative spondylolisthesis patients

Methods: Patient sample: Inclusion criteria: L4/5 Lumbar Spinal Stenosis secondary to Meyerding Grade I spondylolisthesis with minimum 3 months of failed conservative management. Exclusion criteria: previous lumbar spine surgery, infections, malignancy.

Informed consent was taken from patients who underwent single-level, unilateral L4/5 decompression hemi-laminectomy with transforaminal interbody lumbar fusion (TLIF) or Dynamic Interspinous Assisted Motion (DIAM) (Medtronic, Minnesota, USA). Ethics approval was obtained. 59 TLIF patients were retrospectively matched with 59 other DIAM patients for age, gender and co-morbidities.

Outcome measures: Clinical outcome scores: Short-form-36 questionnaire (SF-36), Neurogenic symptom score (NSS), Oswestry Disability Index (ODI), Visual Analogue Score (VAS). Clinical lumbar range of motion was also measured. Surgical complications include blood loss, dural tears, recurrence of symptoms and re-operations. Implant-related complications include implant failure and infection.

Methods: Outcomes were prospectively measured by an independent agency blinded to study groups pre-operatively, 1 month, 6 months, 2 years and 4 years post-operatively. Data were analyzed using the Mann-Whitney U test on SPSS 16.0 statistical software

Results: There were no early surgical or implant-related complications. There was improvement in clinical outcome scores between pre-operative and 4 years post-operative

($p<0.05$). At 4 years follow-up, there was no significant difference in the outcome scores and range of motion between DIAM and TLIF patients ($p>0.05$).

Both study groups had 2 patients each with recurrence of ipsilateral symptoms. None required revision surgery

Conclusion: At 4 years, non-fusion technology is comparable to fusion for Grade I degenerative spondylolisthesis patients

The FDA has not cleared the drug and/or medical device for the use described in this presentation (i.e., the drug or medical device is being discussed for an 'off label' use).

82. Comparison of Direct Pars Repair Techniques of Spondylolysis: Pedicle Screw-Rod-Hook vs. Laminar Pars Compression Screw

Ali F. Karatas; Alfred Atanda, MD; Laurens Holmes, PhD, DrPH; Kenneth J. Rogers, PhD; Peter G. Gabos, MD; Suken A. Shah, MD
USA

Summary: Direct pars repair with a minimally invasive technique using cannulated laminar/pars screws results in similar healing rates and return to sports compared to a pedicle screw/rod/hook construct but with distinct advantages of improved function and pain relief, decreased blood loss and OR time with less complications.

Introduction: Spondylolysis is a nonunion defect of the pars interarticularis. Direct repair of the lysis preserve the function of the segment. This study aimed to compare the clinical and radiographic outcomes of patients with spondylolysis who were treated with intra-segmental pars fixation by pedicle screw, rod and laminar hook (PSRH) or laminar/pars compression screw (LS).

Methods: 16 patients were identified who underwent direct pars repair by using PSRH (7) or LS (9) constructs retrospectively. Clinical outcome was assessed from the Oswestry Disability Index (ODI) and MacNab criteria. Independent sample t-test and chi-squared statistics were used to analyze the data (SPSS, Inc, v17, Chicago, IL).

Results: Patients with PSRH had significantly longer surgical time ($p<0.001$) and increased estimated blood loss ($p=0.01$) relative to LS patients. Radiographs and CT scans revealed healing in all cases. The healing time was similar in both groups: PSRH (6.2 months, SD=1.2); LS (6.5 months, SD=1.1). Patients with PSRH (5.9 months, SD=2.3) were more likely to return to sports earlier relative to patients with LS (7.7 months, SD=2.5). There were a few complications (3/7) observed in PSRH, one with mild sensory deficit and two with superficial wound infections, but none in LS, $p<0.001$. The MacNab criteria showed an excellent or good outcome that were comparable in the two groups; PSRH (86%) and LS (91%). The mean ODI scores were 15.3 (SD=18.2) in PSRH patients and 6.8 (SD=9.8) in LH patients.

Conclusion: Clinical and radiological evaluation of pars fixation of spondylolytic defects with LS showed better outcomes: improved function and pain relief, decreased blood loss and surgical time, with fewer complications. Healing time and return to sports was similar.

83. Superior Articulating Facet Violation: Percutaneous vs. Open Techniques

Sean M. Jones-Quaidoo, MD; Mladen Djurasovic, MD; Roger K. Owens, MD; Leah Y. Carreon, MD, MSc
USA

Summary: In a matched case-control study, the use of a percutaneous method to insert pedicle screws resulted in a statistically significantly higher incidence of facet joint violation, even if only proximal screws are considered. Further studies are

needed to determine if this leads to a higher incidence of symptomatic adjacent level disease.

Introduction: Recent studies have reported the incidence of superior facet joint violation using percutaneous techniques. This has not been compared to the incidence of facet joint violation using the open midline approach. An increased incidence of superior facet violation may lead to degeneration, likely producing adjacent segment disease. This study evaluated the extent of superior facet violation with percutaneously placed pedicle screws versus midline approach open placement.

Methods: Patients who underwent a single-level posterolateral fusion using a percutaneous approach from L1 to S1 who had a CTscan within one year after surgery were identified. A cohort who had an open posterolateral fusion matched by level of surgery was identified. Standard demographic and surgical data were collected. All CTscans were reviewed twice by three fellowship trained spine surgeons two weeks apart who determined the degree of facet violation. The final categorization for each screw was based on the most frequent reading. Intra- and inter-observer reliability was assessed using the Kappa coefficient. Fisher's test was used to determine the association of facet violation with approach: Open versus Percutaneous.

Results: There were 66 patients in each group. Patients in the Percutaneous group were younger (42.5 yrs) compared to the Open group (57.8 yrs, $p < 0.001$). There was no statistically significant difference in sex distribution, surgical levels fused or time between surgery and CT scan between the two groups. 36 of 264 screws in the Percutaneous and 16 of 263 screws in the Open group were in the facet joint ($p = 0.005$). Of these, 17 of the 132 proximal screws in the Percutaneous and 7 of the 131 in the Open group were in the facet joint ($p = 0.052$). Intra-rater Kappa for identifying a screw in the facet was 0.485 demonstrating moderate agreement. Inter-rater kappa ranged from 0.512 to 0.659 demonstrating moderate to substantial agreement.

Conclusion: The use of a percutaneous method to insert pedicle screws results in a statistically significantly higher incidence of facet joint violation, even if only proximal screws are considered. Further studies are needed to determine if this leads to a higher incidence of symptomatic adjacent level disease.

84. Outcomes in Minimally Disruptive Lateral Interbody Fusion: 24- Month Minimum Follow-Up in 268 Patients

William B. Rodgers, MD; Edward J. Gerber, PA-C; Jeff A. Lehmen, MD; Jody A. Rodgers, MD, FACS; William D. Smith, MD
USA

Summary: This study presents the largest series of patients treated with minimally invasive lateral interbody fusion (MI-LIF) with long-term outcomes to date.

Introduction: The MI-LIF approach provides a minimally disruptive alternative to anterior column access that allows for large graft placement, disk height restoration, and indirect decompression. In addition, the MI-LIF approach avoids resectioning complications common to the anterior approach, namely vascular and reproductive, while preserving the anterior and posterior longitudinal ligaments..

Methods: Prospective treatment, complication, functional outcome, and radiographic data on 1093 consecutive MI-LIF patients were reviewed. Of these, 268 were eligible for and completed 24 month follow-up. Patients were 63% female with a mean age of 62.2 years and BMI of 31.3. Baseline comorbidities included CAD (48%), smoking (31.5%), DM (24.2%), and prior spine surgery (38.3%). The

most common primary indications included stenosis (46.4%), spondylolisthesis (17.7%), and DDD (11.3%). A total of 318 levels were treated with MI-LIF and supplemental internal fixation was used in all but 5 (2%) cases.

Results: In these 268 patients, 19 (7.1%) complications occurred. Complications related to the procedure included 3 hardware failures (posterior), 1 nerve injury (quadriceps weakness), 4 vertebral body (VB) complications, and 1 incisional hernia.

Pain (VAS) improved 65.7% from pre-op to 24 months (8.69 to 2.98, respectively). Disk height improved from 6mm pre-op to 10.3mm immediately post-op, settling at 8.9mm at 24 months. Slip was reduced from 4.5mm pre-op and was corrected and maintained by 83% through 24 months (0.85mm). Mean Lenke fusion at 3, 6, 12, and 24 months progressed from 2.03, 1.42, 1.17, to 1.12, respectively. At 24 months, 87% of patients were "very" or "somewhat satisfied" with their outcome, 81.1% of patients would be "definitely" or "very likely" redo the surgery, and 79.5% were considered excellent or good outcomes by the surgeon.

Conclusion: These data show satisfactory 2 year clinical outcomes in patients receiving MI-LIF for degenerative spinal conditions. VAS scores improved, disk height was restored and maintained, and slip was adequately reduced while patient and surgeon satisfaction scores are encouraging. This study, to date, represents the largest series of long-term outcomes following MI-LIF.

85. Use of Robotic Assisted Pedicle Screw Placement in Deformity and Revision Spine Surgery

Isador Lieberman, MD, MBA, FRCS; Xiaobang Hu, PhD
USA

Summary: The result of 95 consecutive spine surgeries with the use of robotic assisted pedicle screw placement was analyzed. The rates of screw malposition range from 0.71% to 2.94% in deformity and revision surgery groups. The use of robotic assisted placement of pedicle screws in deformity and revision spine surgery appears to be better as the historical figures.

Introduction: Placement of implants during spinal surgery is challenging especially in patients with deformity or under revision circumstances. Robotic assisted spine surgery has shown some promising results by increasing the accuracy of spinal instrumentation, reducing potential complications and reducing radiation exposure. However, the benefits of robotic assisted pedicle screw placement during deformity and revision surgery has not as yet been established.

Methods: Ninety five patients who underwent robotic assisted pedicle screw placement from June 2010 to December 2011 were classified into four different groups: patients who did not have a deformity or previous spine surgery (group 1); patients who have a deformity but no previously spine surgery (group 2); patients who had previous spine surgery but no deformity (group 3); patients who had both spinal deformity and previous spine surgery (group 4). Chi square tests and fisher's exact test were used to analyze categorical variables (gender, age, BMI and surgery route). ANOVA test and tukey's test were used to analyze the results of robotic assisted pedicle screw placement.

Results: There were 10 patients in group 1 (median age: 54 years), 36 patients in group 2 (median age: 38 years), 12 patients in group 3 (median age: 61

PAPER ABSTRACTS

years) and 37 patients in group 4 (median age: 59 years). The patients' deformities in group 4 were less severe than group 2. More patients had minimally invasive or percutaneous surgeries in group 1 (80%) and group 3 (50%) compared with group 2 (8.3%) and group 4 (13.5%). The rate of successfully placed pedicle screws was: group 1 (96.08%), group 2 (85.82%), group 3 (89.71%) and group 4 (87.87%) ($p < 0.05$). The rate of malpositioned screws was not significantly different among all four groups (group 1: 3.92%, group 2: 0.71%, group 3: 2.94%, group 4: 0.74%). There were no significant differences for the screws that were manually placed and the screws that were not placed among the four groups.

Conclusion: The published rates of pedicle screw malposition in spinal deformity range from 4.2% to 15.7%. The use of robotic assisted placement of pedicle screws in deformity and revision spine surgery appears to be better as the historical figures.

86. Minimally Invasive Lateral Interbody Fusion in the Morbidly Obese

William D. Smith, MD; William B. Rodgers, MD; Edward J. Gerber, PA-C; Jeff A. Lehmen, MD; Jody A. Rodgers, MD, FACS
USA

Summary: This study demonstrates outcomes of a large series of Minimally Invasive Lateral Interbody Fusion (MI-LIF) procedures in obese or morbidly obese patients and presents a safe and effective minimally invasive alternative for spinal fusion for this challenging patient group.

Introduction: Minimally invasive procedures are challenging in obese patients whose body habitus may decrease the accessibility of the spine to the instruments necessary to perform these procedures. The MI-LIF procedure, however, is performed in the lateral decubitus position, minimizing the difficulty of the pannus as it falls away from the exposure

Methods: In our single-site prospective series of 1093 MI-LIF patients, 576 were identified as obese ($BMI > 30$) and 192 of those were morbidly obese ($BMI > 38$). Comorbidities, surgical details, hospital stay, complications, pain scores, changes in disk height and alignment, and fusion were assessed.

Results: In all morbidly obese patients, no surgery could not be successfully completed due to body habitus. The heaviest patient to date weighed 427 lbs (193.7 kgs); the largest BMI was 61.8. Age ranged from 22-83yrs. Comorbidities included smoking (34%), prior spine surgery (47%), diabetes (41%), CAD (37%), COPD (3%). 244 levels were treated in these 192 patients: 150 1-levels, 33 2-levels, 8 3-levels and 1 4-level; the majority at L4-5. All but 2 surgeries included supplemental fixation. There were 3 transfusions and no infections. Complications included 2 MI's at 4 and 6 wks, 3 atrial fibrillation, pneumonia requiring intubation for 5 days, one other respiratory distress requiring re-intubation, one pulmonary embolism, two posterior hardware failure/rod fracture at 6 and 18 mos, and one fracture of vertebral osteophytes and a vertebral body fracture at 2 months requiring reoperation. Hospital stay averaged 1.54 days. From pre-op to 24 month follow-up: disk height increased an average 3.0mm; slip decreased an average 3.6mm in spondylolisthesis patients; and VAS pain scores decreased from 8.7 preop to 3.1 at 24 mos. Lenke scores were 2.1 at 3 mos, 1.2 at 12 mos, and 1.1 at 24 mos.

Conclusion: Our results demonstrate the usefulness and safety of the MI-LIF technique in treating morbidly obese patients minimally

invasively. Complications are minimal, procedures timely, and outcomes similar to non-obese patients.

87. Fluid Resuscitation using Enteral Route is a Safe and Effective Alternative to Parental Resuscitation in Patients Undergoing Major Elective Surgery

Kavita Baghel, MSc; Saloni Raj; Abhijit Chandra, MD; Rajeshwar N. Srivastava, MD
India

Summary: It has been reported that equal volumes of IV saline or plasma were often less effective than enteral administration of saline as an oral (gastric) bolus would enter the circulation over time, while an IV bolus might cause acute hemodynamic overload. Post operative complications are quite common in patients following major surgery and thus require effective prophylaxis. In major surgical patients, we found that adequate preoperative fluid resuscitation can be successfully achieved using enteral route and fluid through enteral route may be helpful in improving the blood pressure, reducing postoperative septic complications and endotoxemia.

Introduction: A convenient and easy alternative to intravenous fluid administration is to drive fluids through the normal functioning gut. Though not common, this practice has significance in mass casualties and some elective situations. This study determines the feasibility of enteral resuscitation as an alternative to standard intravenous therapy in hydration of patients undergoing major surgery and its effect on endotoxemia

Methods: 60 patients underwent major surgery were randomized into three equal groups A, B and C. Group A received 4 liters of fluid through enteral route and group B received 4 liters through intravenous route for 48 hours. Group C received no extra fluid other than usual oral liquid diet. Vital parameters, urine output, serum bilirubin, serum creatinine, creatinine clearance rate, electrolytes and endotoxin levels were monitored.

Results: Significant improvement in blood pressure was observed in groups undergoing fluid resuscitation (groups A & B). None had any evidence of renal failure prior to intervention and the renal functions remained within normal limits post intervention. The average urine output with group C was significantly less than other two groups (A&B). Febrile events and electrolyte abnormalities were found more in group B using intravenous route, however statistically insignificant. Significant decrease was observed in endotoxin concentrations in all groups, although the decrease was maximum in enteral group (A).

Conclusion: In major surgical patients, we found that adequate preoperative fluid resuscitation can be successfully achieved using enteral route and fluid through enteral route may be helpful in improving the blood pressure, reducing postoperative septic complications and endotoxemia.

88. A New Thoracic Reconstruction Technique "Transforaminal Thoracic Interbody Fusion (TTIF)"

Yasutsugu Yukawa, MD; Fumihiko Kato, MD; Keigo Ito; Masaaki Machino; Shunsuke Kanbara; Daigo Morita
Japan

Summary: We developed transforaminal thoracic interbody fusion (TTIF), applying transforaminal lumbar interbody fusion. Twenty patients with thoracic lesions associated with neurological deficits were included in this study. Local sagittal alignment were corrected from 16.8 degrees kyphotic preoperatively to 9.3 degrees kyphotic

PAPER ABSTRACTS

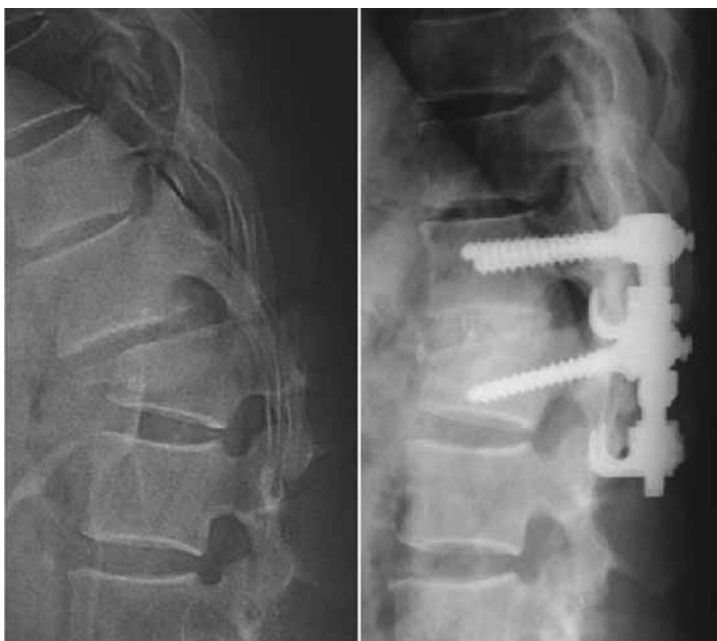postoperatively. Fusion was observed in all cases. TTIF procedure provides strong interbody fusion and 270 degrees' decompression using posterior single approach.

Introduction: In recent, transforaminal lumbar interbody fusion (TLIF) which was reported as posterior lumbar interbody fusion (unilateral PLIF) of one side approach has become to be used widely as minimally invasive surgery. Such reconstructive procedure was not reported in thoracic spine. The purpose of this study was to introduce a new reconstructive procedure of thoracic spine; transforaminal thoracic interbody fusion (TTIF) and to evaluate its surgical outcomes.

Methods: Twenty patients with thoracic lesions associated with neurological deficits were included in this study. There were 13 males and 7 females and their mean age was 52 years. Thoracic lesions included thoracic disc herniation, spinal trauma, spinal tumor and etc. We investigated surgical complications and clinical outcomes such as operative time, blood loss, and sagittal alignment. The neurological severity was evaluated using Japanese orthopedic Association (JOA) score (full score=11 points). The bony fusion was judged using plane X-ray and CT scans.

Results: The mean operative time was 188 min and the mean operative bleeding was 470 ml. All patients were ambulated within 2 days after surgery. The mean follow-up period was 29 months. The average JOA score was 6.0 preoperatively and improved to 9.6 postoperatively. Local sagittal alignment was 16.8 degrees kyphotic preoperatively and 9.3 degrees kyphotic postoperatively. Fusion was observed in all cases. There were no serious complications such as neural deficit or infection.

Conclusion: TTIF procedure provides safe interbody fusion and 270 degrees' decompression using posterior single approach. TTIF can be a useful reconstructive method for thoracic lesions associated with neurological deficits.



preoperative and postoperative X-ray of TTIF procedure

89. A Novel Rod Link Reducer System Provides Stability and Ease of Correction during Posterior Vertebral Column Resection in an Angular Kyphosis In-Vivo Pig Model

Hong Zhang, MD; Daniel J. Sucato, MD, MS; David Ross, MFA; Karen D. Standefer, BS; Xuhui Zhou, MD USA

Summary: An average 53 degree angular kyphosis was created via an anterior tethering in five one-month-old pigs. The deformity was corrected via PVCR using a novel rod link reducer system. The correction rate was 75%. Four of 5 animals ambulated while 1 animal had leg movement but did not regain ambulation due to an inadequate resection. The new implant system provides rigid stability during the resection and provides outstanding control of the spine segments during the correction to minimize neurologic risk to the spinal cord common in PVCR surgery.

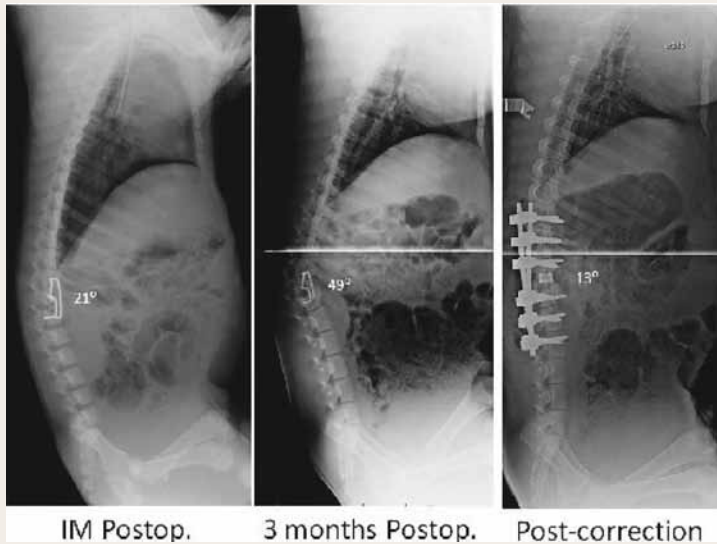
Introduction: The purposes of this study were to 1) create an angular kyphosis in an immature growing pig model; 2) determine the safety and efficacy of a new rod link reducer system during posterior vertebral column resection (PVCR) correction strategy using this system.

Methods: Five one-month-old pigs underwent bilateral tethering using custom anterior staples placed over 3 levels (T14-L1) to create angular kyphosis. At 3 months, the deformity was corrected via PVCR using the rod link system. A novel pedicle screw that can receive provisional and final rods was fixed 3-levels above and below the resected-vertebra (T15). The rod link reducer stably linked the provisional rods during the resection and was used to correct the deformity following complete resection. Following correction, the system allowed for the final rods to be placed while the provisional rods remained. These were then removed after the final rods were secured. All animals were followed up 1-week with a neurologic assessment

Results: The average pre-PVCR kyphosis was 53 degree. Following the PVCR the average kyphosis measured 13 degree (75% correction). The mean operative time was 4.9 hours and the average blood loss was 523.5 ml. The rod link rigidly stabilized the spine during the resection of the vertebra and provided an outstanding control of the resection-gap during the correction maneuvers. Four of 5 animals moved their legs spontaneously and ambulated while 1 animal had leg movement but did not regain ambulation. At sacrifice, evaluation of the spine demonstrated cord compression secondary to inadequate resection.

Conclusion: The rod link reducer system provides rigid stability during the resection and provides outstanding control of the spine segments during the correction. This minimizes neurologic risk to the spinal cord common in PVCR surgery including distraction, compression, deformation, and repeated manipulation of the unstable vertebral column during a PVCR in an angular kyphosis. This novel implant system is especially useful in challenging patients who have the most severe spinal deformities which need PVCR for the correction.

PAPER ABSTRACTS



The FDA has not cleared the drug and/or medical device for the use described in this presentation (i.e., the drug or medical device is being discussed for an 'off label' use).

90. Long Posterior Spinopelvic Fusions using Single vs. Multiple-Screw Iliac Constructs in Major Scoliotic Deformities. The Challenge of Ambulatory Patients

Jesús J Burgos Flores, PhD; Eduardo Hevia, MD; Luis Miguel Antón-Rodríguez, PhD; Carlos Barrios, MD, PhD
Spain

Summary: Two series of scoliotic patients operated on by long posterior spinopelvic fusions using one or multiple iliac screws were compared. Radiological complications were compared with more than 2-year follow-up. Spinopelvic anchorage with two screws in each iliac wing was more effective than single-screw constructs. However, in ambulatory patients, this construct showed a high rate of rod ruptures. The supplementation of L5-S1 interbody cages and/or two more rods at the lumbosacral junction seems to prevent these complications in ambulatory patients.

Introduction: Spinopelvic fixation is often required for correction of large spinal deformities. Iliac screws prevent premature complications and reoperations for fixation failure of previous lumbosacral fusions. The use of double iliac screws provided even more rigid fixation of the sacropelvic unit. In this study, two different constructs using either single or multiple bilateral screw fixations were radiologically compared.

Methods: A total of 44 patients (average age: 26 years; range, 11-67) with long posterior spinal fusion using pedicle screws and fixation to the pelvis were followed up for more than two years. Series A comprised 24 cases operated on with one single iliac screw on each side. Series B included 20 cases who underwent spinopelvic fixation with multiplescrew constructs (2 or more screws in each side). Both series were matched in terms of etiology and type of deformity, severity of the main curve, pelvic tilt and fusion levels. Radiographic outcomes were assessed using plain radiographs, and computed tomographic scans. The parameters analyzed for comparison were the type and rate of complications, the lumbosacral fusion rate, the occurrence of radiolucent areas around the screws and the final reoperation rate.

Results: Patients with multiple-screw constructs exhibited lower post-

operative complications rate and greater pelvic tilt correction. There was no case of screw loosening in this series. However, revision surgery because of rod rupture was more frequent in cases with multiple-screw pelvic fixation (see table). Complications related with the implant were more often seen in ambulatory (53.5%) than non-ambulatory patients (15.5%). Ambulatory cases operated on by adding L5-S1 intersomatic cages and/or two more supplementary rods at lumbosacral junction were free from complications.

Conclusion: Spino-pelvic anchorage with multiple screws in each iliac wing was more effective than single-screw constructs as to pelvic tilt correction. However, it seems that higher stable constructs involved a higher rate of lumbosacral non-union leading to rod rupture and reoperations. The supplementation of L5-S1 interbody cages and/or two more rods at the lumbosacral junction seems to overcome complications in ambulatory patients

91. 3D Kinematic Analysis of Regional Chest Wall Motion and Volume Changes During Respiration in Healthy Children

Patrick K. Do; Lee A. Taylor, MD; Jing Feng, PhD; Rosemary Pierce, BS; Michael Aiona, MD; Charles R. d'Amato, MD, FRCS
USA

Summary: Conventional spirometry is only able to analyze pulmonary function as a whole and unable to show the contributions from specific regions of the chest wall. This study established values in the normally developing pediatric population for relative contributions of different regions of the thorax through the use of optoelectronic plethysmography (OEP). These values will be important for later studies that are aimed at observing differences between the typically developing children and children with spinal abnormalities.

Introduction: 3D kinematic motion analysis of the chest wall can be performed in a Motion Analysis Laboratory by placing reflective markers on a subject's torso and analyzing the markers' trajectories during breathing maneuvers. However, to the best of our knowledge, OEP has never been performed on children.

This study (1) compares OEP to spirometry in typically developing children under 13 years old (2) establish baseline values for regional contributions and contributions from left and right side to total forced vital capacity (FVC) in typically developing children.

Methods: Subjects were included if they were: (1) under 13 years old, (2) in good health, (3) no known respiratory disease or musculoskeletal problems, and (4) no history of chest wall trauma.

Twelve subjects were recruited.

Three trials were performed by each subject with simultaneous collection with the motion capture system and a spirometer.

Results: The mean FVC for all subjects was 2.07 ± 0.44 L by spirometry and 2.08 ± 0.42 L by OEP. Paired T-test showed no statistical difference between OEP and spirometry ($p = .62$).

The contributions of each region are shown in Table 1. Other studies have shown that more proximal fusion of the thoracic vertebrae further decreases pulmonary functions. The results of this study support those findings by showing higher contribution at the upper thorax than the lower thorax region. Paired T-test showed that there was no statistical differences between the contribution made to FVC between the right and left side in typically developing children ($p = 0.21$).

Conclusion: OEP has the ability to accurately separate the chest wall into different compartments and sides to observe the contributions of each section to total FVC in the pediatric population. This technique will be important for future studies of chest wall motion in spine deformity. Lung function is influenced by the chest wall motion in multiple dimensions and cannot be easily ascertained by other methods.

TABLE 1. OEP data. V_{UT} = volume of upper thorax; V_{LT} = volume of lower thorax; V_{AB} = volume of abdomen; V_{TOT} = total volume. ($n = 12$)

Section	V_{UT}	V_{LT}	V_{AB}	V_{TOT}
FVC (Liters)	0.65 ± 0.14	0.41 ± 0.18	1.02 ± 0.26	$2.08 \pm .44$
FVC (Percent Volume)	31	20	49	100

92. Hybrid Vertebral Body Augmentation (KIVA) Plus Short Pedicle Screw Instrumentation with MIS for Fresh Thoracolumbar Burst and Severe Compression Fractures

Panagiotis Korovessis, MD, PhD; Thomas Repantis, MD, PhD; Vasilis Vitsas, MD; Konstantinos Vardakastanis
Greece

Summary: Twenty five consecutive patients, with single thoracolumbar (Th10-L4) burst and severe compression fresh fractures were studied for an average of 14 months (8-18 months) postoperatively, to evaluate the efficacy and safety of a novel vertebral augmentation system made of PEEK (KIVA) and PMMA combined with short pedicle screw fixation, using MIS technique for reduction of fresh thoracolumbar fractures. The results showed that hybrid KIVA and short-segment fixation provided excellent immediate reduction of post-traumatic vertebral body deformity, improved spinal canal encroachment and showed excellent PMMA containment.

Introduction: Vertebral augmentation in addition to short pedicle screw fixation is currently used for thoracolumbar fracture stabilization. Failure of vertebral body restoration is often reported.

This study aims to evaluate the efficacy and safety of short pedicle screw fixation combined with a novel vertebral augmentation device made of PEEK (KIVA) and PMMA using MIS technique for reduction of fresh thoracolumbar fractures.

Methods: 25 consecutive patients, aged 56 ± 21 years, with single thoracolumbar (Th10-L4) burst and severe compression fresh fractures were included. On admission, 3 (12%) of 25 patients had incomplete neurologic impairment. Segmental kyphosis (SKA), anterior (AVBhr), middle (MVBhr) and posterior vertebral body height ratio (PVBhr), and spinal canal encroachment (SCE) were calculated before to after surgery. All patients underwent within 24 hours after admission unilateral KIVA implantation and 3-vertebrae pedicle screw instrumentation and posterolateral fusion using a MIS approach between Multifidus and Longissimus) to reduce segmental kyphosis and restore vertebral body height. VAS and SF-36 were used to evaluate functional outcome.

Results: All patients were followed for an average 14 months (8-18 months) postoperatively. Operating time and blood loss averaged 45 minutes and 56 mL, respectively. VAS and SF-36 were significantly improved after surgery. Both patients with incomplete neurologic impairment lesions improved, whereas no patient deteriorated postoperatively. Postoperatively surgery restored: AVBhr from 0.64 ± 0.16 to 0.8 ± 0.11 ($P=0.0001$); MVBhr from 0.57 ± 0.17 to 0.84 ± 0.1 ($P<0.000$); PVBhr from 0.9 ± 0.1 to 0.9 ± 0.05 ($P = 0.019$). SCE and SKA were reduced from $28 \pm 27\%$ to $11 \pm 17\%$ ($P = 0.013$) and from $12 \pm 7^\circ$ to $6 \pm 5^\circ$ ($P=0.0046$) postoperatively respectively. Two screws were medially misplaced without sequelae. PMMA

leakage was observed anteriorly or to the adjacent superior disc in 3 vertebrae without clinical sequelae. Fusion occurred 6-8 months postoperatively.

Conclusion: Hybrid KIVA and short-segment fixation via MIS provided excellent immediate reduction of post-traumatic vertebral body deformity, improved SCE and showed excellent PMMA containment.

The FDA has not cleared the drug and/or medical device for the use described in this presentation (i.e., the drug or medical device is being discussed for an 'off label' use).

93. Accuracy of Intraoperative CT-Based Navigation for Placement of Percutaneous Pedicle Screws

Jason C. Eck, DO, MS; Jeffrey Lange, MD; John Street, MD, PhD; Anthony S. Lapinsky, MD; Patrick J. Connolly, MD; Christian P. DiPaola, MD
USA

Summary: The accuracy of computer navigated percutaneous pedicle screws were assessed in a cadaveric model. The use of CT-based navigation for placement of lumbar percutaneous pedicle screws appears to be safe, but we cannot recommend its use for placement of thoracic percutaneous pedicle screws.

Introduction: Previous studies on fluoroscopically guided percutaneous pedicle screws have demonstrated a cortical breach rate of approximately 25%. The purpose of this study was to evaluate the accuracy of an intraoperative CT-based navigation system for placement of percutaneous pedicle screws in a cadaveric model.

Methods: Two cadaveric specimens were utilized. CT images were obtained using an O-Arm (Medtronic, Memphis, TN) and were coupled to the Stealth navigation system (Medtronic, Memphis, TN). Computer navigation was used for placement of percutaneous pedicle screws. Screws were placed bilaterally from T5-S1 and from T6-S1 respectively. Post insertion CT scans were obtained. Pedicle breach was assessed and classified accordingly (I: none, II: <2 mm, III: 2-4 mm, or IV: >4 mm) along with direction of breach.

Results: Thirty thoracic screws were placed with 3 (10%) medial breaches and 17 (56.7%) lateral breaches (all grade III). Out of twenty lumbar there were 0 medial breaches and 2 (10%) lateral breaches (one grade III and one grade IV). Four sacral screws were placed without breaches. The real-time computer-aided navigation tool ("simulated screw") was limited in identifying a pedicle breach. Manipulation of the surgeon's hand or driver could change the orientation of the navigation tool without changing the trajectory of the screw.

Conclusion: The use of CT-based navigation for placement of percutaneous pedicle screws appears to be safe for the lumbar spine. Thoracic breaches laterally appeared commonly but were not felt to be clinically significant. The 10% rate of medial thoracic breach was cause for concern. Based on the results of this study we cannot recommend the use of CT-guided navigation for placement of thoracic percutaneous pedicle screws. Further study is warranted to define the roles and limits of this technology as factors such as body habitus and pedicle morphology may limit its use in percutaneous spinal surgery.

94. MRI in Spinal Trauma - A Predictor of Neurological Recovery?

Rajeshwar N. Srivastava, MD; Umesh Parashri
India

Summary: Use of Magnetic Resonance Imaging appears to be of great

PAPER ABSTRACTS

help in diagnosing spinal trauma & correlating it with clinical profile & neurological outcome because of better contrast resolution, absence of bony artifacts, multiplanar imaging and choice of pulse sequences. In cases of spinal cord ischemia, hemorrhage, edema, and contusion, MRI findings may serve as prognostic indicators

Introduction: To correlate MRI findings with neurological recovery and functional outcome as predictor of recovery in spinal cord injury

Methods: 62 patients of acute spinal trauma were evaluated by MRI and correlated with clinical findings at admission & discharge. Four types of MR signal patterns were seen in association with spinal cord injury- cord edema / non haemorrhagic cord contusion (CC), severe cord compression (SCC), cord hemorrhage (CH) and epidural hematoma (EH). In cord contusion we further subdivided the group into contusion of size < 3 cm and contusion of size > 3 cm to evaluate any significance of length of cord contusion. In cord hemorrhage involving >1cm of the cord, focus was said to be sizable

Results: There was a definitive correlation of cord contusion(CC) involving <3cm & > 3cm of cord. In >3cm chances of improvement was 5.75 times lesser than in patients with CC involving <3cm of cord (odds ratio = 5.75 (95% CI: 0.95, 36), Fisher's exact p = 0.0427 (p<.05). Presence of sizable focus of haemorrhage (HC) in cord (>1cm) was most strongly associated with the poor outcome. The risk of retaining a complete cord injury at the time of follow up for patients who initially had significant haemorrhage in cord was more than 6 folds with patients without initial haemorrhage (odds ratio 6.97 and p= .0047). It was noted that the patients in which epidural hematoma (EH) was present, no improvement was seen, however, by statistical analysis it was not a risk factor and was not related with the outcome (odds ratio - 0.5 and p = 0.22). Presence of severe cord compression(SCC) was a risk factor for poor outcome(odds ratio - 4.90 and p = 0.0143)

Conclusion: On multiple logistic regression for estimating prognosis, sizable focus of hemorrhage was most consistently associated with poor outcome. In severe cord compression the risk of poor outcome was more, however was not statistically significant. Presence of cord oedema / non haemorrhagic contusion was not associated with poor outcome. The risk of retaining a complete cord injury at the time of follow up for patients who initially showed evidence of significant haemorrhage in cord was more than 6 folds with patients without initial haemorrhage.

95. Better Understanding Postoperative Changes in Adolescent Idiopathic Scoliosis using 3D Reconstructions of 2D Radiographs

Krishna Cidambi, MD; Shoji Seki, MD; Carrie E. Bartley, MA; Maty Petcharaporn, BS; Burt Yaszay, MD; Peter O. Newton, MD
USA

Summary: 3D reconstructions of 2D radiographs permit improved analysis of deformity and correction in AIS.

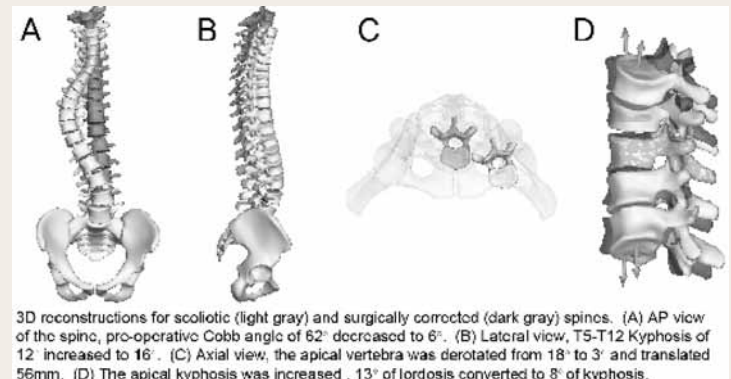
Introduction: To analyze the effect of surgical correction in three-dimensions (3D) in AIS patients treated with segmental pedicle screw instrumentation using a biplanar, slot-scanning image acquisition and reconstruction system.

Methods: AIS patients with main thoracic scoliosis were scanned in the EOS system pre- and post-operatively. 3D spine models were created using EOS (EOS, Paris, France) software and analyzed using custom MATLABM

software to obtain the data of interest: Cobb angle, apical vertebral rotation, translation of the apical vertebra, and apical kyphosis. The orientation vectors of the vertebra 2 levels above and below the apex were projected into a sagittal plane through the apex to define the local plane for apical kyphosis. Student t-test was used to compare parameters.

Results: Thirty patients (5 male, 25 female, mean age 15.2y) with main thoracic scoliosis were studied. The pre-operative Cobb angle was $54.9 \pm 9.7^\circ$ and corrected to $4.9 \pm 5.6^\circ$ ($p < 0.001$). The apical kyphosis increased from $1.3 \pm 11.0^\circ$ (-16.1-21.0) pre-operatively to $14.6 \pm 5.1^\circ$ (6.4-27.7) post-operatively ($p < 0.001$). The apical vertebral rotation decreased from $12.7 \pm 5.0^\circ$ (4.8-22.7) to $3.2 \pm 4.6^\circ$ (-5.1-14.8), ($p < 0.001$). Following correction, the apical vertebra was translated an average of 55.3 ± 14.0 mm (27.4-82.7).

Conclusion: Pre- and post-op spine reconstructions permit improved analysis of deformity and correction in 3D. In this series, patients showed decreased apical vertebral rotation, improved apical kyphosis, and decreased coronal Cobb angle.



96. In Vivo Assessment of Mechanotransduction of AIS patients

Guoruey Wong, BSc, MSc; Carl-Éric Aubin, PhD, PEng; Alain Moreau, PhD
Canada

Summary: Differential mechanotransduction impairments were demonstrated in vivo in AIS patients. Osteopontin (OPN), a mechanosensitive molecule, was used as readout and its level was inversely correlated with AIS severity. Indeed, after a standardized biomechanical stimulation of 90 minutes, healthy controls exhibited a plasma OPN level variation of 187 ± 62 ng/ml, while AIS patients with moderate and severe curves showed a decreased response with 146 ± 65 ng/ml and 96 ± 34 ng/ml respectively.

Introduction: Previously, we have demonstrated a strong association of increased circulating OPN levels and concomitant decreased levels of sCD44 (a known OPN decoy receptor) with the risk of induction/progression of scoliotic curves. The mechanotransductive sensitivity of OPN prompted us to develop a clinical test to assess the functionality of mechanotransduction pathways in AIS.

Methods: 38 test subjects have been recruited (9 to 17 years), each of whom fall into one of four subject groups: i) AIS presurgical cases (Cobb angle > 45°) (n=9), ii) moderately affected AIS cases (Cobb angle 10 to 44°) (n=13), iii) controls (n=10), or iv) asymptomatic children at risk of developing scoliosis matched for age and gender against healthy controls (n=6). An initial blood sample was taken from each subject to establish a baseline value of circulating OPN and sCD44. One of the arms from each subject was then wrapped with an inflatable cuff which applied a

dynamic, pulsatile, compressive pressure of variable amplitude from 0 to 4 psi at 0.006 Hz to the arm for a period of 90 minutes. At intervals of 30 minutes after the start of force application, additional blood samples were taken in order to monitor circulating OPN and sCD44 levels in subjects. Plasma OPN and sCD44 levels were measured by ELISA.

Results: Average circulating OPN levels of all four experimental groups increased over the course of the 90 minutes of mechanical stimulation. Interestingly, there was a trend found, that patient grouping and OPN were strongly significantly correlated (one way ANOVA $p=0.003$), with average group OPN declining as the group curve severity increased. No correlation was found between patient grouping and sCD44, however (one way ANOVA $p=0.542$).

Conclusion: A useful method to discriminate between patient strata using the behavior of plasma OPN levels in response to mechanical loading was developed. We quantifiably characterized the differences in normal subjects and AIS patients of varying severities in terms of the circulating OPN response. In vivo biomechanical testing represents a promising clinical method of predicting the risk of developing scoliosis among asymptomatic children and of spinal deformity progression in AIS patients (patent pending).

97. Assessment of Skeletal Maturity: A New Classification Scheme Using Distal Radius and Ulna Radiographs

Keith D. Luk, MD; Lim Beng Saw, MS Orth; Samuel Grozman, MD; Kenneth M. Cheung, MBBS(UK), FRCS(England), FHKCOS, FHKAM(Orth); Dino Samartzis, DSc, PhD (C), MSc
China

Summary: Our study describes a new classification scheme to assess skeletal maturity by utilizing the distal radius and ulna radiographs. This classification demonstrates a relationship with adolescent growth spurt and cessation of growth.

Introduction: The progression of the curve in adolescent idiopathic scoliosis has always been associated with pubertal growth spurt. The commonly used clinical or radiological methods are still deficient in predicting this growth peak among adolescents and bone age is too complicated to apply. To address these concerns, we describe a new classification scheme using the distal radius and ulna radiographs to assess skeletal maturity.

Methods: We retrospectively analyzed 145 series of hand radiographs from a scoliosis cohort. We identified various stages of radius and ulna epiphysis maturity, which were regarded as R1-R11 for the radius and U1-U9 for the ulna. The bone age, sexual character development, standing height, sitting height, arm span, radius length and tibia length were studied at the each stage of these epiphysis changes.

Results: The standing height, sitting height and arm span growth were at their peak during stage R7 (mean, 11.4 years old) and U5 (mean, 11 ± 1.4 years old). The long bone growths also demonstrated a common peak at R7 and U5. The growth in height and arm span stopped completely after stage R10 (mean, 15.6 years old) and one year after U9 (mean, 17.3 years old).

Conclusion: The new distal radius and ulna classification can provide the maturation status from juvenile age to completion of maturity. The classification scheme provides close relationship with adolescent growth spurt and cessation of growth.

98. Measurement Discrepancy of Sagittal Parameters Between Plain Radiography and 3D CT in Thoracolumbar and Lumbar Fractures

Yong Min Kim, MD, PhD; Seung Myung Choi, MD; Dong Soo Kim
Republic of Korea

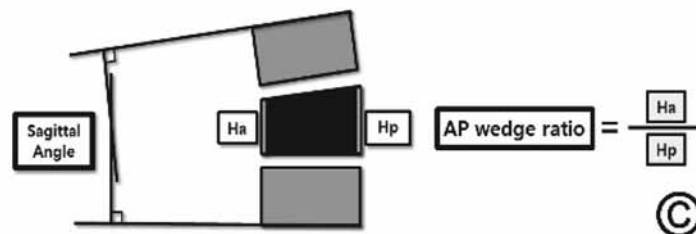
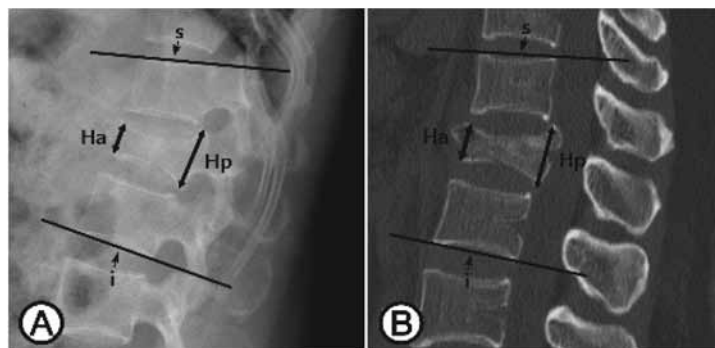
Summary: Significant discrepancies were observed in sagittal features of fractured vertebra between plain radiography and 3D CT. Measured values of plain radiography showed more kyphotic features of the fractured body.

Introduction: Decision making in the management of vertebral fractures, such as operations, sagittal parameters like Cobb angle and wedge compression ratio are important. Plain radiography had been the only image tool for measuring such parameters until 3D CT became popular recently. In this study, we investigated the measurement discrepancy between plain radiography and 3D CT.

Methods: Plain radiography and 3D CT of 45 thoracolumbar and lumbar fracture patients (male=21, female=24) were evaluated. We measured sagittal angle and vertebral height on lateral radiography and sagittal CT. Sagittal angle was measured between the upper body and lower body of fractured vertebrae. Anterior and posterior heights were measured to assess AP (anterior-posterior) wedge ratio.

Results: The sagittal angle of plain radiography ($13.1 \pm 14.3^\circ$) was significantly larger than that of 3D CT ($8.2 \pm 13.0^\circ$) by 4.9° ($p < 0.001$). AP wedge ratio of plain radiography was on average $65 \pm 17\%$, which was significantly lower than the 3D CT ($73 \pm 17\%$) by 8% ($p < 0.001$). The severer the initial kyphotic deformity, the more discrepancy of results between the two methods was observed.

Conclusion: Significant discrepancies were observed in sagittal features of fractured vertebra between plain radiography and 3D CT. Measured values of plain radiography showed more kyphotic features of the fractured body.



Measurement method of sagittal angle and AP wedge ratio in plain radiography (A), mid-sagittal plane of 3D CT (B) and schematic illustration (C). Sagittal angle is Cobb angle between upper end plate of upper body and lower end plate

PAPER ABSTRACTS

of lower body. AP wedge ratio is anterior body height divided by posterior body height (Ha/Hp) of fractured vertebra.

99. How Many Motor Pathways to the Target Muscle can be Monitored by Transcranial Motor Evoked Potentials during Spinal Surgery?

Shunji Tsutsui, Hiroshi Yamada, MD, PhD; Hiroshi Hashizume, MD, PhD; Akihito Minamide, MD, PhD; Yukihiko Nakagawa, MD, PhD; Masaki Kawai, MD; Hiroshi Iwasaki, MD; Ryohei Kagotani, MD; Masatoshi Teraguchi, MD; Munehito Yoshida
Japan

Summary: Triple stimulation technique was employed intraoperatively to quantify the degree of motor pathways which can be monitored by Transcranial motor evoked potentials (TcMEPs). Only 20% of motor pathways to the target muscle were activated with currently used transcranial stimulation technique under general anesthesia. There have been some previous reports regarding the false positive and negative cases in TcMEPs monitoring. Multimodal intraoperative neuromonitoring is highly recommended to prevent neurological complications in spinal surgery.

Introduction: Transcranial motor evoked potentials (TcMEPs) have been widely introduced to monitor the patient's motor function during spinal surgery. However, TcMEPs are much smaller and more variable in amplitude than responses evoked by peripheral nerve stimulation, and it is still difficult to recognize the critical change of TcMEPs intraoperatively. This suggests that a limited number of spinal motor neurons to the target muscle may be excited by transcranial stimulation. The aim of this study is to quantify the degree of motor pathways which can be monitored by TcMEPs.

Methods: In twenty patients (six males and fourteen females; age range, 12-81 years) who underwent thoracic and/or lumbar spinal surgery with TcMEP monitoring, triple stimulation technique (TST; described by Magistris, et al.) were applied to patients' unilateral upper arm intraoperatively. Muscle relaxant was given only at anesthetic induction to facilitate tracheal intubation. Trains of four stimuli were delivered with the intensity of 200mA (maximum output of the stimulator used) and with an inter-stimulus interval of 1.5ms. TST responses were recorded from the abductor digiti minimi, and the negative peak amplitude and area were measured and compared between the TST test (two collisions between transcranial and proximal and distal peripheral stimulation) and control response (two collisions between two proximal and one distal peripheral stimulation).

Results: The highest degree of superimposition of the TST test and control responses was chosen from an average of 3.1 TST trials per patient. The average ratios (test : control) were 17.1% (range, 1.8% to 38%) for the amplitudes and 21.6% (range, 2.9% to 40%) for the areas.

Conclusion: There have been some previous reports regarding the false positive and negative cases in TcMEPs monitoring. When using TcMEPs, approximately 80% of motor pathways are not monitored with currently used transcranial stimulation technique under general anesthesia. Multimodal intraoperative neuromonitoring is highly recommended to prevent neurological complications in spinal surgery.

100. National Trends, Hospital Costs and Complications of Spinal Fusion for Scheuermann's Kyphosis: Analysis of 2,796 Patients

Amit Jain; Paul D. Sponseller, MD; Addisu Mesfin, MD
USA

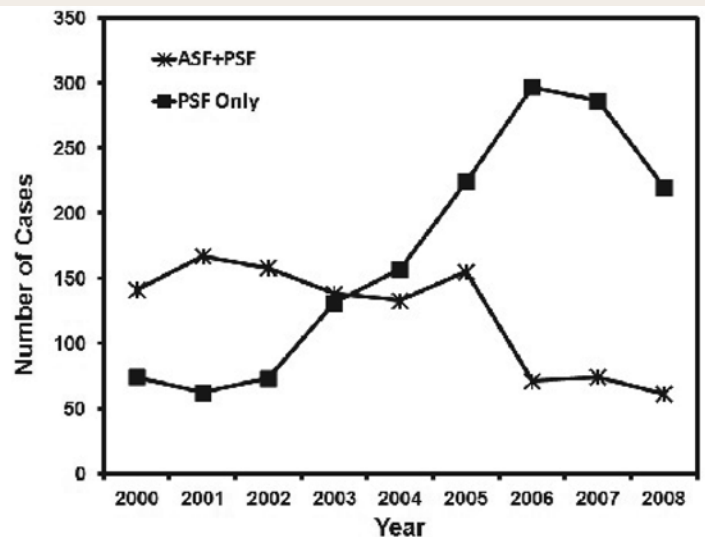
Summary: Nationwide treatment for Scheuermann's kyphosis has shifted to a posterior-only approach. Posterior-only fusion is associated with shorter hospital stay and lower complication rate compared to circumferential fusion.

Introduction: National trends and complications of surgical management of Scheuermann's Kyphosis (SK) are not known. The aim of our study was to provide a national perspective on trends, hospital costs and complications associated with spinal fusion surgery for SK.

Methods: Using the Nationwide Inpatient Sample (NIS) database, we identified SK patients from 2000 - 2008 that had spinal fusion. We collected patient and hospital stay characteristics and in-hospital complications. Linear and logistic regression tests were used to analyze trends.

Results: 2,796 pts in the United States had spinal fusion surgery for SK from 2000 to 2008. Avg age at surgery was 18 y/o, 40% were 15-20 y/o and 66% were male. 58% had posterior-only fusion and 42% had anterior-posterior fusion. There was a 137% increase/yr in the posterior-only fusion (33% in 2000 to 74% in 2008; $P < 0.01$). Mean length of hospital stay was 6.9 days. Mean hospitalization cost increased by \$11,258/yr over the study period ($P < 0.01$), from \$75,892 in 2000 to \$169,272 in 2008. There was no significant difference in total charges by approach ($P = 0.8$). In-hospital rate of major and minor complications after surgery was 21.6%. Complications were: pulmonary 11.5%, gastrointestinal 4.4%, hemorrhagic 4.0%, urinary/renal 1.8%, cardiac 1.3%, infectious/wound 1.2%, neurological 1.1% and DVT/PE 0.5%. Complication rate was not significantly related to patient age ($p = 0.9$), gender ($p = 0.2$) and hospital teaching status ($p = 0.6$). Patients receiving anterior-posterior fusion were 2.1 times more likely to develop complications compared to posterior-only fusion ($p < 0.01$).

Conclusion: Nationally surgical treatment of SK has shifted towards an all posterior approach. Posterior-only fusion is associated with shorter hospital stay and lower complication rate compared to circumferential fusion.



101. Neurological Recovery in Patients of Old Healed Tubercular Rigid Kyphosis with Myelopathy Treated with Transpedicular Decancellation Osteotomy (TDO)

Saamyajit Basu, MD; Sreeramalingam Rathinavelu, MS; Jay D. Ghosh, MBBS, MS(Ortho); Agnivesh Tikoo, MS (Ortho); Amitava Biswas, MS (Orth)

India

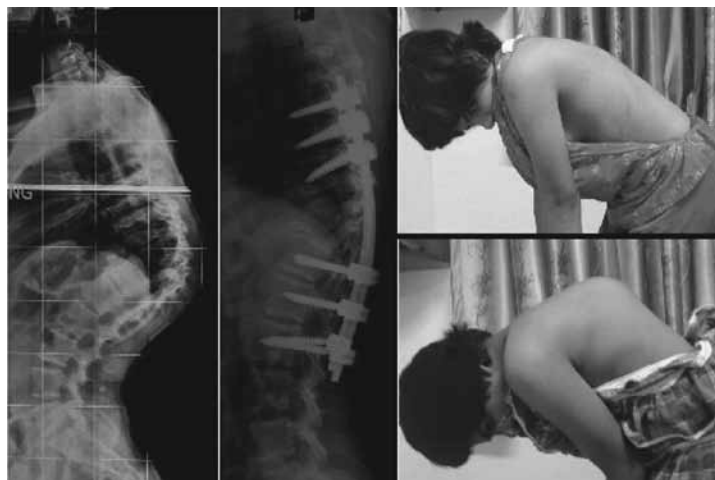
Summary: 17 patients who underwent TDO for late onset myelopathy in old healed dorsal caries spine with rigid kyphosis were prospectively studied with regards to neurological recovery (ASIA grade). 16 (94 %) patients with ASIA C and ASIA D had at least one grade improvement with maximum improvement seen in the first 3 months without much improvement after 6 months. Preoperative MRI changes, cord compression and preoperative duration of myelopathy were not predictive of the final neurological outcome after surgery.

Introduction: There are many papers regarding deformity correction for old healed dorsal tuberculosis but not much on neural recovery of those patients who had preoperative myelopathy. The purpose of the study is to find out if TDO is recommendable for neurological recovery in these patients. We have analyzed the pattern of recovery seen after the surgery and also made an effort to correlate the neurological recovery with preoperative clinical and radiological features.

Methods: The clinical parameters used were 1) ASIA impairment scale for motor and sensory function 2) sphincter dysfunction score 3) time duration from the onset of myelopathy till the date of surgery 4) SRS 30 outcomes questionnaire. Radiological parameters used were 1) Cobb's angle in standing / sitting radiographs 2) levels of gibbus 3) cord changes in sagittal T2 MRI images 4) percentage of cord compression. Assessment was done preoperatively and at 1 month, 3 months, 6 months, 1 year and at 2 years post operatively

Results: 17 patients were included. The follow up period was 2 years. We had 1 patient in ASIA A, 9 patients in ASIA C and 7 patients in ASIA D. 4 patients with ASIA C presented with mild sphincter disturbance (score 2) and 1 presented with severe disturbance (score 1). The ASIA A patient had complete retention (score 0). The ASIA impairment scale improved after surgery, with maximum improvement at 3 months and improvement continuing up to 6 months. 16 (94 %) patients had improvement in lower limb function and 5 (83 %) patients had improvement of sphincter function. 94% patients had neurological recovery after the operation. The neurological recovery reached a plateau at 6 months after the operation with no significant improvement in the further follow-up. Preoperative MRI changes, cord compression and duration from onset of myelopathy to day of surgery were not predictive of the final neurological outcome after surgery

Conclusion: TDO gives good results in late onset myelopathy in caries spine with rigid kyphosis, with at least one grade improvement in the neurological status of patients with ASIA C and ASIA D. Maximum improvement in the neurology is seen in the first 3 months and up to 6 months from the date of surgery, without much improvement there after.



Pre and Postoperative clinical picture and standing Xrays

102. Guidelines for Choosing the Lower Instrumented Vertebra in Scheuermann's Kyphosis: Revisited

Muayad Kadhim, MD; Suken A. Shah, MD; Baron S. Lonner; Harry L. Shufflebarger, MD; Paul D. Sponseller, MD; Peter O. Newton, MD; Harms Study Group
USA

Summary: The outcome of posterior fusion with instrumentation was satisfactory whether the distal instrumentation included the SSV or was proximal to it, except when the LIV was proximal to the FLD. As several factors contributed to DJK, LIV selection may be influenced by multiple factors that deserve consideration, such as lumbar lordosis, pelvic parameters, the location of the kyphotic apex and any coronal plane deformity.

Introduction: Other authors have advocated that the lower instrumented vertebra (LIV) in patients with Scheuermann's kyphosis (SK) should be distal to the first lordotic disk (FLD) and include the sagittal stable vertebra (SSV). The hypothesis of this study is that there may be an increased complication rate or inferior outcomes in patients who were fused and instrumented proximal to the FLD level and/or SSV.

Methods: There were 105 patients queried from a multicenter SK database, 66 boys (63%) and 39 girls (37%). Mean age at surgery was 16.2 ± 2.0 yrs (range 7.6 to 22.3 years). All of the patients had 1st erect postop follow up, and 46 patients had minimum follow up > 2yrs, mean follow up was 2.3 yrs. Radiographic indices were measured, and LIV, FLD and SSV were determined for each patient. Two groups of patients were identified. Group I (33 patients) had an LIV that was proximal to SSV, and group II (72 patients) with an LIV that was at or distal to SSV. Six patients were instrumented proximal to FLD. LIV was at L1 in 7 patients, L2 in 43 patients, L3 in 53 patients, and L4 in 2 patients.

Results: Kyphosis and lumbar lordosis were larger in Group I compared to Group II ($p=0.001$). Nonetheless, both patients groups improved significantly in kyphotic curve magnitude and sagittal spine alignment after surgery at 2 yrs follow up (see Table for values). All radiographic parameters were significantly improved at two year follow up in both groups. The rates of PJK and DJK did not differ significantly. Development of DJK was significantly affected if the LIV was proximal to the FLD ($p=0.008$) or the level of the kyphotic apex was

PAPER ABSTRACTS

near the thoracolumbar junction ($p=0.048$). However, DJK was unaffected if the LIV was 1 level proximal to the SSV (Group I).

Conclusion: Guidelines for the choice of distal fusion level in SK need further clarification, as multiple factors are related to the development of DJK after surgery for SK. The outcome of PSF was satisfactory whether the distal instrumentation included the SSV or was proximal to it, except when the LIV was proximal to the FLD. LIV selection may be influenced by multiple factors, such lumbar lordosis, pelvic parameters, the location of the kyphotic apex and any coronal plane deformity.

Table 1. Radiographic measurements stratified and compared between two groups of patients with Kyphosis.

Radiographic indices	Shorter than SSV Mean, (SD)	At or longer than SSV Mean, (SD)	P*
T2 – T12 Kyphosis angle			0.0001
Preoperative	72.6, (10.0)	67.1, (8.0)	
Direct post operative	42.7, (8.8)	42.3, (8.8)	
2 years Follow up	44.1, (11.6)	44.0, (10.7)	
Major Kyphotic curve			0.0001
Preoperative	79.5, (9.2)	71.4, (9.2)	
Direct post operative	44.2, (10.4)	42.6, (8.9)	
2 years Follow up	45.4, (11.8)	44.3, (10.5)	
Kyphosis apex translation			0.0001
Preoperative	10.1, (7.0)	9.1, (2.5)	
Direct post operative	-4.8, (3.1)	-4.8, (2.5)	
2 years Follow up	-5.4, (3.4)	-4.8, (2.3)	
Lumbar apex translation			0.108
Preoperative	1.9, (0.5)	2.6, (0.9)	
Direct post operative	1.8, (0.4)	2.4, (0.8)	
2 years Follow up	1.8, (0.4)	2.3, (0.7)	
EIV – CSVL translation			0.0001
Preoperative	2.2, (1.7)	0.3, (1.1)	
Direct post operative	-0.7, (1.6)	1.7, (1.3)	
2 years Follow up	-0.4, (1.7)	0.8, (1.4)	
Proximal junctional kyphosis (PIK)			0.0001
Preoperative	0.6, (2.9)	-0.1, (5.8)	
Direct post operative	4.7, (3.9)	5.3, (5.1)	
2 years Follow up	7.1, (5.4)	8.4, (7.3)	
Distal Junctional Kyphosis (DJK)			0.0001
Preoperative	-14.1, (4.6)	-18.5, (5.6)	
Direct post operative	-3.2, (3.8)	-8.6, (6.9)	
2 years Follow up	-5.4, (7.1)	-7.2, (7.1)	
Lordosis T12 – S1			0.0001
Preoperative	-52.1, (14.5)	-67.5, (12.9)	
Direct post operative	39.2, (8.7)	50.5, (12.5)	
2 years Follow up	-47.7, (9.1)	-54.4, (11.4)	
Sacral Slope			0.004
Preoperative	26.7, (6.7)	36.9, (9.1)	
Direct post operative	24.5, (7.4)	32.2, (9.7)	
2 years Follow up	29.2, (8.8)	35.2, (9.6)	

* P value was calculated based on repeated measure ANOVA.

103. Scheuermann's Kyphosis: What Patient Factors Cause Transition from Non-Operative to Surgical Management?

David W. Polly, MD; Beverly E. Diamond, PhD; Charles Gerald T. Ledonio, MD; Hubert Labelle, MD; Daniel J. Sucato, MD, MS; John B. Emans, MD; Michael T. Hresko, MD; Michael G. Virale, MD, MPH; A. Noelle Larson, MD
USA

Summary: Careful analysis of a prospective series of 150 Scheuermann's kyphosis patients reveals that patients requiring surgery had increased age, BMI, and spinopelvic radiographic measures compared to the nonoperative cohort. Currently it is difficult to discern the surgical threshold for Scheuermann's kyphosis.

Introduction: Vertebral wedging in Scheuermann's kyphosis leads to accommodative changes throughout the spine. Symptoms, progression, and magnitude of sagittal deformity have

classically guided surgical treatment. We sought to compare demographic, clinical and radiographic findings between operative and nonoperative cohorts of patients with Scheuermann's kyphosis to determine the patient factors that prompt physicians transition to surgery.

Methods: This is a multi-center, prospective, as treated, parallel cohort study of 73 operative and 77 nonoperative patients presenting with Scheuermann's kyphosis. An independent observer measured radiographic parameters. Univariate and multivariate analysis were used to compare preoperative findings to clinical findings in the nonoperative cohort.

Results: It is a Caucasian predominant disease (143/150). Compared to the 77 nonoperative patients, the 73 operative patients had statistically significantly higher values for T2-T12 kyphosis ($71^\circ \pm 14^\circ$ vs. $61^\circ \pm 12^\circ$, $p<0.001$, see Table). Operative patients had increased pelvic incidence ($46^\circ \pm 14^\circ$ vs. $41^\circ \pm 10^\circ$, $p=0.03$) and pelvic tilt ($10^\circ \pm 10^\circ$ vs. $3^\circ \pm 8^\circ$, $p=0.03$). Surgical patients were older (16.3 years ± 2.0 vs. 15.1 ± 2.2 , $p=0.0004$) with increased BMI (26.3 ± 7.2 vs. 22.7 ± 6.5 , $p=0.003$) and had poorer total SRS scores, mainly from appearance and activity domain contributions (3.5 ± 0.6 vs. 3.8 ± 0.5 , $p=0.0003$) and poorer SAQ Appearance scores (2.0 ± 0.9 vs. 1.6 ± 0.5 , $p=0.0005$) The final model of the multivariate analysis showed that increased age and BMI and popliteal angle were more frequent in the surgical cohort.

Conclusion: Although statistically significant differences were found in pelvic and radiographic measures, the parameters most closely associated with operative treatment included BMI and age. Currently it is difficult to define the surgical threshold in Scheuermann's kyphosis.

104. Key Radiographic Parameters Correlate to Life Quality with Sagittal Imbalance in AS Kyphosis

Yonggang Zhang, PhD; Kai Song
China

Summary: The correlations between kyphotic spinal alignment including pelvic positional parameters and HRQOL were previously reported, but little AS cases were included and all studies lacked postoperative research. Some others evaluated the radiological outcomes after PSO, but no self-report inventory was involved. So, AS, which is considered to have the most severe positive sagittal imbalance, remains unknown, especially in postoperation.

Introduction: This is a study about outcomes after pedicle subtraction osteotomy (PSO) for fixed thoracolumbar kyphotic deformity caused by ankylosing spondylitis (AS). It focus on pre and postoperative correlations between radiological spinopelvic parameters and health related quality of life (HRQOL). Finally, this researcher demonstrated that backward pelvic rotation causes erect disability, and PT, PRA and SS are the key evaluations.

Methods: 20 patients were included in the research. Pre and postoperative radiological parameters, CobbT1-S1, pelvic incidence (PI), pelvic tilt (PT), pelvic rotation angle (PRA), sacral slope (SS), sagittal vertical axis (SVA) and PSO angle were measured. Corresponding ODI, SRS-22 were collected as well by questionnaire. Statistical correlation analysis was pursued to determine correlation (Partial Correlation) between radiographic parameters and overall or domain specific scores of HRQOL instruments.

Results: No matter whether the patients had sufficient PSO, their life quality and related radiological spinopelvic parameters were improved significantly after surgery. Though CobbT1-S1 and SVA have partial correlation coefficients with ODI walking ($r=0.86$ ($P<0.01$), 0.53 ($P<0.05$)) and ODI standing ($r=0.63$ ($P<0.01$), 0.63 ($P<0.05$)) preoperatively, no statistical significance were found postoperatively. On the other side, PT and PRA not only have partial correlation coefficients with ODI preoperatively (ODI walking $r=0.72$ ($P<0.01$), 0.72 ($P<0.01$)); ODI standing $r=0.57$ ($P<0.01$), 0.56 ($P<0.01$)), but also do postoperatively (ODI total scores $r=0.52$ ($P<0.05$), 0.53 ($P<0.05$)); ODI walking $r=0.54$ ($P<0.05$), 0.56 ($P<0.05$)); ODI standing $r=0.77$ ($P<0.01$), 0.77 ($P<0.01$)). In addition, PSO impacts PT and PRA ($r=-0.56$ ($P<0.05$), -0.53 ($P<0.05$)) more sensitively than SVA (no significance).

Conclusion: This study shows that although CobbT1-S1 and SVA can assess spinal kyphosis shape in AS, they are not so meaningful for upright activities in extremely odd spinal deformity after PSO. Backward pelvic rotation causes erect disability, PT, PRA and SS are the key evaluations. In addition, PRA is easier and more convenient in clinical application than PT and SS for surgeons.

105. Sagittal Spinopelvic Parameters in Scheuermann's Kyphosis: A Preliminary Study

Patrick J. Cahill, MD; Baron S. Lonner; Peter O. Newton, MD; Suken A. Shah, MD; Amer F. Samdani, MD; Paul D. Sponseller, MD; Harry L. Shuffelbarger, MD
USA

Summary: This is the first study reporting pelvic parameters and correlations with spinopelvic sagittal indices in Scheuermann's kyphosis (SK). In SK, the average pelvic incidence is 42 degrees, the average pelvic tilt is 7.3 degrees, and the average sacral slope is 35 degrees. Upon comparisons of these parameters with AIS and normal controls, they are similar to normals and do not correlate with the magnitude of kyphosis, whereas in AIS the parameters are significantly different and do correlate with thoracic kyphosis.

Introduction: The interplay of sagittal spinopelvic parameters (SSPs) is vital to the maintenance of energy-efficient global sagittal balance. These parameters have been shown to impact health-related quality of life outcomes in spinal deformity pre- and postoperatively. Little data exist on the average SSPs for the most common cause of sagittal malalignment of the spine, Scheuermann's kyphosis (SK). The purpose of this study was to assess SSPs in patients undergoing surgery for SK and their relationship to sagittal spinal contour, comparing them to AIS and normal controls.

Methods: 47 of 96 patients enrolled in a prospective study of operative SK who had adequate radiographic images were compared to 719 patients from a prospectively collected operative AIS database and retrospectively collected data of 50 normal controls (NC). Assessment of kyphosis, lordosis, pelvic incidence (PI), pelvic tilt (PT), and sacral slope (SS) was performed and compared in these groups. The correlation of these parameters within each group was also evaluated. ANOVA and Bonferroni comparisons were used.

Results: Mean age for SK, AIS and NC were 16.1, 14.7, 13.5 years respectively ($p<0.001$). In SK, the average PI, PT and SS are 42, 7.3, and 35 degrees, respectively. T5-T12 kyphosis was different for all groups and was smallest in AIS ($p<0.001$). Kyphosis and lordosis were significantly greater in SK compared to the other groups ($p = 0.002$). PI, PT, SS, were significantly greater for AIS than the other groups ($p<0.001$). PI, PT, and SS were not significantly different between SK

and NC. PI directly correlated with lordosis in all groups ($p<0.005$). T5-T12 kyphosis correlated with lordosis in AIS ($p<0.001$) and NC ($p=0.03$). Kyphosis in SK did not correlate with PI or lordosis ($p<0.05$).

Conclusion: SSPs for SK, AIS, and NC have been defined. There is a disconnect in SK from the influence of lordosis on kyphosis that is seen in NC and AIS. Further understanding of the interplay of spinal and pelvic parameters may assist in operative planning and corrective strategies influencing ultimate clinical outcomes. Unlike in AIS, pelvic parameters in SK are similar to normals and do not correlate with the magnitude of kyphosis.

106. Segmental Spinal Dysgenesis. A Report of 13 Cases

Rodrigo G. Remondino, MD; Carlos A. Tello, MD; Ernesto Bersusky, MD; Alejandra Francheri, MD; Mariano A. Noel, MD; Eduardo Galaretto, MD
Argentina

Summary: The purpose of this paper is to emphasize surgery for this complex congenital anomaly.

Introduction: Segmental spinal dysgenesis is a congenital spine malformation, is characterized by focal spinal stenosis, kyphosis, spinal subluxation and absent of nerve root at the level of the lesion. Neurologic function ranges from normal to complete paraplegia. The progression deformity and neurologic deterioration is a rule.

Methods: This was a retrospective study of 13 patients with segmental spinal dysgenesis between 1998 and 2008, at a single institution, with average follow up 7+6 years (2-20). The investigation was performed by independent spinal surgeon who reviewed the clinical, images, treatment and result of all cases.

Results: Thirteen patients (8 male 5 female) were the study cohort. The average age at the time of diagnosis was 1+3 years (0+3-3+7); the average age at surgery was 2+1 years (0+5-4+9). The kyphosis was the most common deformity 9 cases, kyphoscoliosis 2 cases; scoliosis 1 case and 1 anterior subluxation. The dysgenesis involved an average of 2.7 vertebral levels (1-5), the upper thoracic region was the most common 7 cases, followed thoracolumbar 4 cases, lumbar and cervical 1 case each one. Ten cases presented severe spinal canal stenosis, 3 cases moderate stenosis less than 50%. At the time of surgery 8 patients had paraparesis, 2 paraplegia and 3 normal neurologic exams. Eleven patients had associated anomalies.

Six patients have undergone double approach (3 PSF-3 PSSI), 4 ASF, 2 PSSI and 1 patient PSF. Decompression was performed in 10 patients (4 anterior, 4 double approach 2 posterior). A total of 26 surgeries were performed, average 1.9 procedures (1-5) to obtain a solid arthrodesis. Three patients had an improvement in neurologic function, 3 had deterioration previous status and 7 without change. Six complications, 3 related surgery and 3 clinical problem one of them the patient dead.

Conclusion: We recommend prompt surgical treatment, decompression and fusion must be indicated as soon as possible to preserve and prevent neurologic deterioration. However a high rate of patients may deteriorate after surgery or not recover its neurological status.

PAPER ABSTRACTS

107. Occipital-Cervical Instability in Morquio-Brailsford's Disease (MPSIV): A Cohort of 16 Patients Treated in the SpineHope/Casa de Colombia Global Outreach Clinic

Matthew J. Geck, MD; Craig A. Kuhns, MD; Steven M. Mardjetko, MD, FAAP; Anthony S. Rinella, MD; Devender Singh, PhD
USA

Summary: Morquio-Brailsford's disease (MPSIV) is a rare congenital connective tissue disorder that is characterized by dysplastic dwarfism, joint laxity and deformities in the extremities, spinal deformities, and occipital-cervical (OC) instability. This paper reports the treatment of 15 patients treated in a global outreach clinic in Cali, Colombia

Introduction: Morquio's is a congenital connective tissue disorder characterized by dysplastic dwarfism, joint laxity and deformities in the extremities, spinal deformities, and occipital-cervical (OC) instability. Patients can die in childhood or early adult life from neurologic disability if OC instability is untreated. This paper reports the treatment of 16 patients with OC instability treated in a global outreach clinic in Cali, Colombia.

Methods: Patients with Morquio-Brailsford's disease confirmed on geneticist evaluation were prospectively enrolled and entered into a research database in conjunction with a global outreach clinic. Films, charts, and database were reviewed retrospectively. Minimum 24-month follow up was required.

Results: 16 patients over 10 years met inclusion criteria. Follow up ranged from 36 ~ 112 months. 1 patient (5y8m) presented with advanced quadraparesis for 5 months and respiratory insufficiency died 2 months later. Of 15 patients who received surgery (Mean age 6y2m, Range 32-131months), 10 presented with neurologic decline and were stabilized. 3 neurologically stable declined during follow up requiring stabilization. 2 were fused "prophylactically". 12 had occiput-C2 instrumentation and fusion with iliac crest onlay bone graft. Each had successful fusion confirmed on CT scan at 6 or 24 months and improved or stabilized neurologically. 2 were wired and fused with iliac crest graft and halo fixation but developed nonunion and pain. They were revised using OC instrumentation. 1 patient had index C2/3 fusion with later further neurologic decline and revision to OC reconstruction.

Conclusion: OC instability in MPSIV can cause major morbidity and mortality. Surgical treatment of the OC junction with modern internal fixation and iliac onlay graft was successful in all 12 patients initially attempted in terms of halting or preventing neurologic decline and obtaining fusion. 3 patients treated in other manners required reoperation and had major complication. The occiput to C2 should be included in index surgical treatment in all patients, with distal levels operated on as indicated by stenosis, instability, and anchor availability. Internal fixation was safe and effective.

108. The Four Rib Construct for Severe Early Onset Thoracic Kyphosis

AlaaEldin A. Ahmad, MD; Zeke J. Walton, MD; Richard H. Gross, MD
Occupied Palestinian Territory

Summary: A novel 4 rib construct has proven effective for management of 7 patients with severe early onset thoracic kyphosis, with average 110 degrees preop and 75 postop followup ranged from 19-51 months. The construct allows for cantilever correction, has minimal neurologic risk, and was effective in 3 patients with documented osteoporosis.

Introduction: Current standard methods (VEPTR, Growing Rods) are not reliable for treatment of thoracic kyphosis. We present results of an alternate method for management of thoracic kyphosis, using bilateral hook fixation on ribs 2-5, which allows cantilever correction of kyphosis.

Methods: 7 patients with thoracic kyphosis who underwent rib construct fixation were studied.

Average age at initial surgery 10+1, range 8+2-13. Diagnoses included VATER and Coffin-Siris syndromes, spastic quadriplegia, neurofibromatosis, juvenile osteoporosis, and an unidentified syndrome. Surgery was performed at the Medical University of South Carolina or Nablus Specialty Hospital, Nablus, West Bank, Palestine.

Results: Minimum followup 18 months, maximum 51 months. Results: preop scoliosis 98 (degrees), postop 55. Preop thoracic kyphosis 110, postop 75. 3 cases with > 100 degrees initial kyphosis and >36 months followup had documented osteoporosis. Complications included 2 superior hook displacement, 1 delayed wound infection with removal of instrumentation with subsequent replacement, and 1 death of ventilator dependent patient at 33 mos postop. There was no proximal junctional kyphosis.

Conclusion: Documented advantages of the rib construct over current standard methods include: 1) minimal neurologic risk, as distraction is not necessary for kyphosis correction, and gentle compression of rib hooks reduces kyphogenic effect, 2) reliable correction of >100 degree kyphosis without anterior release, 3) ability to correct coronal plane malalignment by manipulation of the construct, 4) improved alignment of previously fused thoracic spine without osteotomy, and 5) osteoporosis is not a contraindication to instrumentation with the rib construct.

109. Posterior Only Spinal Fusion without Rib Head Resection in Treating Type I Neurofibromatosis with Intra-Canal Rib Head Dislocation

Jianzhong Xu, MD; Dong Sun, PhD; Fei Dai
China

Summary: Scoliotic patients of type I neurofibromatosis had rib head protrusion into spinal canal from the convex side. Posterior only spinal fusion without intra-canal rib head resection was done. Significant correction was achieved without complication.

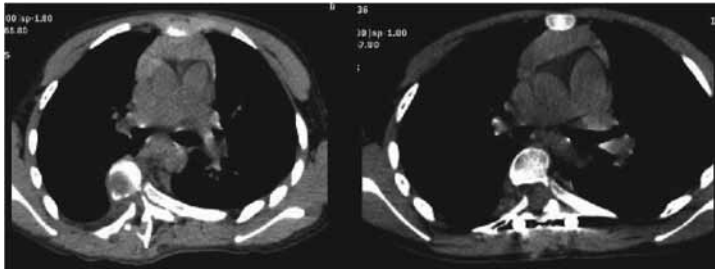
Introduction: Current treatment of Type I neurofibromatosis (NF-1) scoliosis with intra-canal rib head protrusion is combined anterior and posterior spinal fusion with rib head amputation, which leads to prolonged surgery time and more invasive procedures. We performed posterior only spinal fusion and reduction without intra-canal rib head resection and evaluated the surgical outcomes.

Methods: Six patients of type I neurofibromatosis (NF-1) underwent surgery for scoliosis with rib head dislocation into spinal canal from the convex side. We measured the distance between the intra-canal rib head tip and the line bisecting the canal on CT scan before and after surgery, with rib head tip passing the line being recorded as positive, Cobb angle, apex rotation and kyphosis were also evaluated.

Results: Posterior only spinal fusion with instrumentation was done. Pre-operative coronal Cobb angle was 76.6 ± 20.2 , sagittal kyphosis was 58.8 ± 26.2 and axial apex rotation was 18.2 ± 6 . Pre-operative distance between intra-spinal rib head tip and the line bisecting the canal was (cm): 3.3, -3.1, 1, 2.5, -3 and 2.4. There were no signs of spinal cord compression or neurofibromatosis in pre-operative MRI. Post-operative Cobb angle was 40.6 ± 21.5 , sagittal kyphosis was 24.8 ± 4.3 and

the apex rotation was $10.2^{\circ} \pm 2.5$. Distance between intra-spinal rib head tip and the line bisecting canal was (cm): -5, -6.5, -2.5, -5, -6 and -4. The correction rate of Cobb angle was 47.4%, kyphosis 58.6% and apical rotation 44.4%. Distance of rib head being moved out of canal with the reduction maneuver was (cm): 5.18 ± 2.06 . No post-operative complication was reported.

Conclusion: NF-1 patients with rib head dislocation into the canal could be treated by posterior only spinal fusion and direct correction without rib head resection. The distance between the intra-canal rib head tip and the line bisecting canal is able to demonstrate the severity of rib head dislocation and could be used in patient evaluation.



Pre-and post-operation CT shows rib head has been retracted out of the canal.

110. Use of Sublaminar Polyester Bands in Treatment of Neuromuscular Scoliosis

Michael C. Albert, MD

USA

Summary: Sublaminar bands in the treatment of neuromuscular scoliosis provides another tool for the spinal deformity surgeon: This technique is a superior sublaminar implant with low risk of neural damage and infection, along with easier and safer removal than wires. It is superb in correction of neuromuscular scoliosis and kyphosis and is an excellent choice in osteoporotic bone.

Introduction: Numerous studies have been published on the use of sublaminar wires in the treatment of scoliosis since Eduardo Luque first described his technique in 1976. This is the first series reporting the use of polyester woven bands in the treatment of neuromuscular scoliosis.

Methods: A retrospective study on 115 pediatric spinal deformity surgical cases from 2008-2010 at a single center cared for by a single surgeon were performed with an average of a 2 year follow up. 52 patients we identified had insertion of sublaminar polyester bands as part of a hybrid construct in which 29 were classified as neuromuscular deformity. (See table.) Intraoperative and post-op complications were reviewed and classified as minor (those not requiring a return to the operating room and temporary) versus major (those requiring return to operating room or permanent). Radiographs were reviewed pre-op and post-op and percent corrections and mean loss of correction were calculated in the coronal and sagittal planes.

Results: The pre-op average coronal curve magnitude was 71° (range 43° - 119°) compared to post-op coronal magnitude of 24° (0° - 55°). The percent coronal correction of major curves was 69% and there was no mean loss of correction at last follow-up. The sagittal balance results revealed that 97% of patients c-7 plumbline to the sacrum was within ± 20 mm. Lordosis correction was 48% with mean loss of correction at final follow-up of 3%. Kyphosis correction was 51% with mean loss of correction at last follow up of 2%. There were 2 intra-operative clamp failures (1 bone failure and 1 band failure). No post-op implant failures and no post-op neurologic complications were

observed. Overall, there were 9 complications in 7 patients with 22% minor complications (2 superficial wound dehiscence, 3 GI issues, 1 respiratory issue, 1 UTI) and 7% major complications (1 prominent iliac screw and 1 deep wound infection).

Conclusion: The use of sublaminar polyester bands in the treatment of neuromuscular scoliosis shows an overall lower complication rate and improved correction in comparison to other sublaminar techniques used in treatment of neuromuscular scoliosis. Adherence to pre-op nutrition as well as infection protocols can further lower complication rates.

111. One-Stage Posterior Surgery Assisted with Halo-Femoral Traction for the Treatment of Scoliosis with Chiari I Malformation

Hongqi Zhang, MD; Mingxing Tang; Shaohua Liu; Yuxiang Wang, MD
China

Summary: Most scholars support two-stage surgery for the treatment of scoliosis with Chiari I malformation. Those patients underwent posterior suboccipital decompression firstly, and then underwent the scoliosis correction with posterior instrumentation 3 to 6 months later. In China, the first stage surgery is unacceptable for some patients without neurologic symptom, because the aim of the patient is deformity correction. Several studies have described the effects of one stage Posterior surgery assisted with halo-femoral traction for the treatment of scoliosis with Chiari I malformation without neurologic symptom, and showed that it was safe and effective. Recently we report the results of 11 cases that treated in this method.

Introduction: The aim of this study is to determine the safety and effectiveness of the use of Posterior surgery assisted with halo-femoral traction for the treatment of scoliosis with Chiari I malformation without neurologic symptom.

Methods: From January 2006 to January 2011, 21 patients of scoliosis with Chiari I malformation without neurologic symptom were divided into two group randomly. 11 patients in group A, 9 of them companied with syringomyelia, and the average age at initial surgery was $15.2(12-18)$ years, and the mean of the major curve was 68.7 ± 13.2 degrees($51-96$ degrees). Before the posterior instrumentation, all patients underwent halo-femoral traction for 2-4 weeks. There were 10 patients in group B, and 8 of them companied with syringomyelia, and the average age at initial surgery was $14.8(12-17)$ years, and the mean of the major curve was 71.3 ± 17.5 degrees($54-98$ degrees). All patients underwent suboccipital decompression firstly, and then underwent posterior deformity correction 3 to 6 months later.

Results: Mean follow-up was 38 months (range, 12 to 71 mo) in group A. The mean of the major curve improved to an average of 28.2 ± 8.7 degrees(17 to 42 degrees) after initial surgery, yielding an over all correction of 59.0% and was maintained at an average of 30.5 ± 9.2 degrees(19 to 45 degrees) with the most recent correction of 55.6% at the latest follow up. Mean follow-up was 41 months (range, 24 to 68 mo) in group B. The mean of the major curve improved to an average of 42.7 ± 11.5 degrees(26 to 63 degrees) after initial surgery, yielding an over all correction of 40.1% and was maintained at an average of 46.5 ± 12.7 degrees(29 to 67 degrees) with the most recent correction of 34.8% at the latest follow up. There was no neurological disturbances in any of the 21 patients during the treatment period.

Conclusion: The One-stage Posterior surgery assisted with halo-femoral traction for the treatment of

PAPER ABSTRACTS

scoliosis with Chiari I malformation without neurologic symptom is safe and effective. It can reduce surgery trauma and get good correction.

112. Scoliosis Surgery in Rett Syndrome - Can We Monitor These Patients and What Complications They Get?

Tim Hammett, MRCS; Anna Harris; Ben Boreham, MB, BCh, FRCS(Orth); Hossein Mehdian, MD, MS(Orth), FRCS(Ed)
United Kingdom

Summary: We present our experience with Rett syndrome patients undergoing scoliosis surgery. We were able to achieve spinal cord monitoring in all patients it was attempted in. 8/11 patients suffered at least one complication following surgery.

Introduction: Rett syndrome is a progressive neurodevelopmental disorder that nearly universally affects girls, with a high incidence of autism, scoliosis and epilepsy. There is little published work about spinal cord monitoring in these patients during surgery, or the rate of complications.

Methods: We reviewed the records of 11 patients with Rett syndrome who underwent surgical correction of scoliosis at our institution between 2004 and 2010.

Results: 11 patients underwent successful correction of their scoliosis at an average age of 12 years. 8 of the patients had useful leg function and underwent successful spinal cord monitoring with Sensory Evoked Potentials. 3 patients had no useful lower limb function or continence and so after careful discussion no monitoring was used. There were no observable neurological deficits post operatively. 8/11 patients suffered at least one complication. The most common complications were wound infection (4) and post operative pneumonia (4).

Conclusion: Previous work has established the problems of neuromuscular (NM) scoliosis surgery, including difficulty in achieving monitoring and frequent complications. Our evidence analyses the largest published UK experience of surgery in Rett syndrome and confirms the high rate of complications, but that cord monitoring is entirely possible in this population.

Rett syndrome patients, like all NM patients require careful discussions with parents and carers prior to surgery. Parents should be warned to expect a bumpy post operative course. Our practice, where only those patients with limb function or continence to lose are monitored, is sensible and has been accepted by the all the parents of patients we have operated on.

113. Gastrointestinal Complications after Surgical Correction of Neuromuscular Scoliosis

Tuomas Jalanko, MD; Antti Koivusalo, MD, PhD; Katariina Korhonen; Mikko P. Pakarinen, MD, PhD; Päivi M. Salminen; Risto Rintala; Ilkka Helenius, MD, PhD
Finland

Summary: The incidence, severity and predisposing factors of gastrointestinal complications after neuromuscular scoliosis surgery are unknown. We enrolled 86 consecutive patients in a prospective study to evaluate significant gastrointestinal complications and how they relate to the preoperative patient demographics, type and extent of spinal surgery and gastric emptying measurements. The results showed that gastrointestinal complications occurred in 13 % of patients and were usually reversible. The most important risk factor was the extent of preoperative main curve rigidity.

Introduction: The

incidence, severity and predisposing factors of gastrointestinal (GI) complications after surgical correction of neuromuscular scoliosis (NMSC) are unknown.

Methods: In total, 86 consecutive patients (35 % males; 40 % CP, 32 % syndromic and 28 % other diagnoses) underwent NMSC at our institution in 2000-2009 and were included in a prospective study. The age at surgery averaged 14 (SD 3.5) years and follow-up time 4.9 (SD 2.3; min 2) years. Operative method was combined anteroposterior (41 %; 35/86) or posterior only (59 %; 51/86) instrumented fusion. Gastric emptying scintigraphy (GES; n=50) was measured preoperatively. Patient records were evaluated for significant gastrointestinal complications and related to the type and extent of scoliosis and corrective surgery, GES and patient demographics.

Results: The main curve averaged preoperatively 81 (SD 27) ° and 29 (SD 17) ° at final follow-up. Significant GI complications occurred in 13 % (11/86) and these included gastroparesis (n=1), dysphagia (requiring re-hospitalization or gastrostoma; n=5) and prolonged paralytic ileus (n=6). 10/11 of these complications were reversible. No operative mortality occurred. After adjusting for age, gender and diagnosis, more rigid scoliosis (≤ 25 % main curve correction in preoperative traction radiograph) carried higher relative risk for GI complications (OR = 29 [95 % CI 3.2-270]; p=0.003) while main curve magnitude, operative method, instrumentation, blood loss during surgery and delayed gastric emptying before surgery had an insignificant effect.

Conclusion: Significant gastrointestinal complications occurred in 13 % of patients undergoing NMSC, but most of these were reversible. The extent of preoperative scoliosis rigidity is the most significant risk factor for gastrointestinal complications after NMSC.

114. Is Curve Direction Correlated with the Side of Dominant Displacement of Cerebellar Tonsil and Syrinx Deviation in Thoracic Scoliosis Secondary to Chiari Malformation Type I and Syringomyelia?

Ze Zhang Zhu; Tao Wu; Xu Sun; Yang Yu; Xin Zhen; Bangqing Qian; Feng Zhu; Yong Qiu
China

Summary: This is a retrospective study investigating the imaging association amongst asymmetrically displaced tonsil, eccentrically located syrinx and scoliosis. It was found that the thoracic scoliosis in these patients was usually convex not only to the dominant side of asymmetrically displaced tonsils, but also to the side of eccentrically located syrinx, indicating that the asymmetry of tonsillar displacement and syrinx location might be involved in the decision of curve direction.

Introduction: In patients with syringomyelia (SM) secondary to Chiari Malformation Type I (CMI), curve patterns were reported to be different from those in patients with adolescent idiopathic scoliosis. In addition, curve direction in these patients was found to be on the same side as the dominant side of tonsillar displacement or the deviated side of syrinx location in several small-sample studies. Even so, this issue was still contradictory in literatures. Herein, a large-sample study of patients with single thoracic scoliosis secondary to CMI and SM was performed to validate these findings.

Methods: Thirty-nine patients with single thoracic scoliosis secondary to CMI and SM were included. The general data, curve direction, the dominant side of tonsillar displacement and the deviated side of syrinx location were recorded. The concordance among asymmetrically displaced tonsil, eccentrically located syrinx and direction of thoracic scoliosis were analyzed.

Results: 80% subjects showed concordance between the deviated side of eccentrically located syrinx and the dominant side of asymmetrically displaced tonsil. In 86% patients with asymmetrically displaced tonsil, the convex side of thoracic curve was concordant with the dominant side of tonsillar displacement. In 68% of patients with eccentrically located syrinx, the convex side of thoracic curve was consistent with the deviated side of syrinx location.

Conclusion: Asymmetrically displaced tonsils and eccentrically located syrinx are common imaging presentations in patients with SM secondary to CMI. The thoracic scoliosis in these patients usually convex not only to the dominant side of asymmetrically displaced tonsils, but also to the side of eccentrically located syrinx, indicating that the asymmetry of tonsillar displacement and syrinx location might be involved in regulating the curve direction.

115. Prevalence of Complications in Neuromuscular Scoliosis Surgery. A Meta-Analysis of the Literature From the Last 15 Years

*Shallu Sharma, MPT; Thomas Andersen, MD, PhD; Ebbe S. Hansen, MD, DMSc; Cody E. Bunker; Efe L. Aras
Denmark*

Summary: Neuromuscular scoliosis (NMS) is commonly managed with scoliosis correction surgery. The surgery is associated with high risk of various peri- and postoperative complications. Such complications have a detrimental effect on the final outcome of surgery. Although many follow-up reports on outcomes of surgery in these patients have been published, there has been no systematic review and meta-analysis on the associated complications.

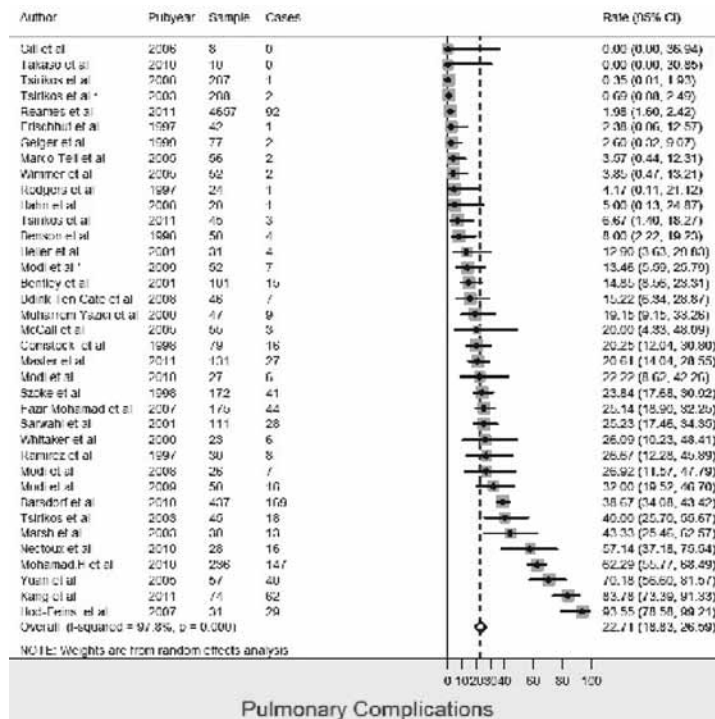
Introduction: Neuromuscular scoliosis (NMS) induces a complex situation to surgical intervention. The progressive spinal curve worsens the cardiopulmonary status which in combination with declining functional level are indications for the surgery. Scoliosis surgery promises improvement in functional level, cosmesis, respiratory status, pain, health status and overall quality of life. In contrast to these gains, scoliosis surgery is associated with high risk of peri- and postoperative complications.

Methods: Methods. PubMed and Embase databases were searched for studies published from 1997 to May 2011, reporting the outcomes and complications of NMS surgery. We excluded articles dealing with adolescent idiopathic scoliosis and focused only on NMS as defined by Scoliosis Research Society's classification. We also excluded case reports and case series, as they had insufficient data.

Results: Meta-analysis was performed for 68 studies with a total of 15218 patients. The mean age of patients was over 10 yrs at the time of surgery. Pulmonary complications were the most commonly reported (22.71%) in NMS surgery followed by implant complications (12.51%), infections (10.91%), neurological complications (3.01%) and pseudoarthrosis (1.88%). Revision, removal and extension of implant for; infection, implant breakage, prominence, and excessive tightness had the highest prevalence of 7.87%. The included studies had a moderate to high levels of variability. The studies were heterogeneous in methodology and outcome types; likely reasons for the variability in estimates of individual studies. Sensitivity analysis with respect to age at surgery and sample size of the study, partly explain the variability

Conclusion: Pulmonary complications have the highest PE of 22.71 % followed by implant complications, infections, neurological complications and pseudoarthrosis. The most consistent of these pooled estimates are for neurological complications and pseudoarthrosis. The results should serve a twofold purposes; making available the

concise information on complications and also emphasize a stronger need for higher quality literature. We propose; these figures will assist the surgeon's knowledge of "What and how much to expect" when operating on these complex patients



Forest Plot : The individual study rates and pooled rates of pulmonary complications (PR) with 95% confidence intervals.

116. Longitudinal Analysis of Radiation Exposure During the Course of Growing Rod Treatment for Early Onset Scoliosis

*Gregory M. Mundis, MD; Edward K. Nomoto, MD; Michael W. Hennessy, MD; Jeff Pawelek; Burt Yaszay, MD; Behrooz A. Akbaria, MD
USA*

Summary: Patient age at time of initial spine-related ionizing radiation (IR) correlated significantly with IR exposure, with younger patients receiving more total IR than older patients during the radiographic period. Patients who had at least one revision surgery also had significantly more IR than non-revision patients.

Introduction: Health hazards related to ionizing radiation (IR) have been well studied; however, IR exposure in growing rod surgery (GR) for early onset scoliosis (EOS) has not been reported. GR surgery with periodic spinal lengthening requires multiple IR imaging studies during the treatment course. The purpose of this study was to quantify spine-related IR in GR pts.

Methods: A consecutive single center series of GR pts were retrospectively reviewed. Of 28 GR pts, 24 had minimum 2-year follow-up from initial evaluation and complete records available for analysis. All spine-related IR imaging studies excluding intra-op fluoro were tabulated and IR estimated based on historical controls in millisieverts (mSv).

Results: 24 pts underwent initial x-ray evaluation for scoliosis at mean age of 4.0 years (range: birth to 9.7). Mean

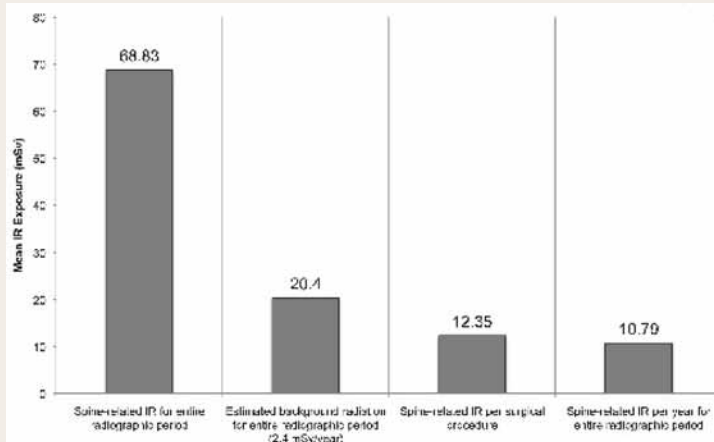
PAPER ABSTRACTS

study period was 8.5 years (range: 2.2 to 19.4). There was a statistically significant inverse correlation between patient age at time of initial IR and total mean IR ($p < 0.05$). Total IR was 3.4 times greater than that of estimated background radiation (2.4 mSv per year) during the study period (Fig 1).

The mean age at index GR surgery was 6.7 years (range: 1.7 to 10.8). Mean IR prior to index surgery and during the 1st post-op year were 22.41 mSv and 10.78 mSv, respectively. Annual IR after the 1st post-op year averaged 7.02 mSv (range: 2.25 to 13.45 mSv). Pts who underwent at least one revision surgery (16/24) experienced significantly higher IR than non-revision pts (79.953 vs. 46.583 mSv; $p < 0.05$). For the 9 "final" fusion pts, annual IR averaged 7.173 mSv after spinal fusion.

Total IR from initial spine x-ray to 1 year after index surgery was greatest in congenital pts (63.220 mSv; $n=2$) followed by syndromic (34.560 mSv; $n=8$), idiopathic (28.590 mSv; $n=6$) and neuromuscular (27.769 mSv; $n=8$). 89% of total IR was attributed to x-rays and 11% from CT.

Conclusion: Pts undergoing GR treatment had 3.4x more IR than estimated background radiation. Among this group younger pts and those undergoing revision surgery were exposed to significantly higher IR doses. Etiology seemed to play a role in IR exposure, however, larger cohorts are needed to make comparisons between etiologies.



The FDA has not cleared the drug and/or medical device for the use described in this presentation (i.e., the drug or medical device is being discussed for an 'off label' use).

117. Vertebral Body Stapling for Juvenile and Early Adolescent Idiopathic Scoliosis: Indications, Results, and Complications

David B. Bumpass, MD; Sara K. Fuhrhop, BS; Scott J. Luhmann, MD
USA

Summary: Vertebral body stapling (VBS) was performed in 36 patients w/ mean age 10.4 yrs. Four pts required subsequent fusions. Minor short- or long-term complications occurred in 8 pts (22%). Mean change in coronal Cobb at >2yr f/u was 4.3 degrees of correction.

Introduction: VBS is a growth-modulation technique to correct moderate idiopathic scoliosis (IS) while avoiding fusion. We present indications, outcomes, and early/late complications of this technique.

Methods: All IS pts who underwent VBS at 1 institution were included. Pre- and post-op radiographs, pulmonary function testing, and physical exam measurements were serially recorded.

Results: We studied 28 female and 8 male pts, w/ mean age 10.4 yrs (range 7.0-14.6 yrs). There were 27 thoracic and 12 thoracolumbar curves, w/ mean pre-op coronal Cobb for the stapled curves of 29.7 deg. Preop Risser score was 0 in 33 pts, 1 in 1 pt, and 2 in 3 pts. Mean surgical time was 2.1 hrs (range 1.0-4.5 hrs), w/ mean estimated blood loss of 64 ml (range 10-350 ml). Proportional nitinol staples were used in all cases. Thoracoscopy was used for 29 curves, a mini-open retroperitoneal approach for 5 curves, and a hybrid approach for 5 curves. Mean post-op hospital stay was 3.8 days (range 3-6 days). A mean of 4.6 motion segments were stapled per curve (range 2-7). No major immediate post-op complications were encountered; 5 pts (14%) developed small pneumothoraces, one of which was contralateral.

Twenty-one pts (23 curves) had minimum 2 yr f/u (mean 39.4 mo, range 24-64 mo), and 14 pts (15 curves) have <2 yr f/u (mean 12.8 mo, range 6-21 mo). One pt was lost to f/u. Four pts (11%) required subsequent surgery: 3 fusions for progression (mean 22 deg), and one for staple removal/fusion after over-correction (-97 deg). Two other pts slightly over-corrected but are being observed (-31 and -38 deg). Two pts (6%) had broken staples, both at T12-L1, and 1 pt (3%) had loosening of her L2-L3 staple. For pts with >2 yr f/u (23 curves), mean coronal Cobb change was 4.3 deg of correction (range -97 to +26 deg). Seventeen of these curves (74%) had correction or progressed <6 deg. Pulmonary function at >2yr f/u showed small reductions in % predicted values of FVC -10.9% ($p=0.02$) and FEV1 -3.9% ($p=0.57$).

Conclusion: VBS is an effective technique for stabilizing juvenile and early adolescent idiopathic scoliosis, and is an acceptable alternative to bracing. There is a low rate of both reoperation and minor complications. Regular f/u at 6-12 month intervals is essential during growth.

The FDA has not cleared the drug and/or medical device for the use described in this presentation (i.e., the drug or medical device is being discussed for an 'off label' use).

118. Pulmonary Function Following Adult Spinal Deformity Surgery: Minimum Two-Year Follow-Up

Ronald A. Lehman, MD; Daniel G. Kang, MD; Lawrence G. Lenke, MD; Jeremy J. Stallbaumer, MD; Brenda A. Sides, MA
USA

Summary: We performed the largest study to date evaluating pulmonary function tests (PFTs) following surgery in 164 adult spinal deformity patients with minimum 2-year follow-up. Our results demonstrate significant decline in all measures of pulmonary function following deformity surgery, with a clinically significant decline ($\geq 10\%$ pred FEV1) in pulmonary function in 27% of patients. However, we found patients with pre-op pulmonary impairment (<65% pred FEV1) may actually benefit from deformity correction surgery. Revision surgery more frequently (35% v 23%) results in a clinically significant decline in PFTs.

Introduction: Pulmonary function following adult spinal deformity remains uncertain. We hypothesized patients with pre-op PFT impairment (<65% pred FEV1) and those undergoing revision surgery may be at risk for exacerbated decline in pulmonary function.

Methods: PFTs were prospectively collected on 164 adult spinal deformity patients (150F, 14M, avg age 45.9) undergoing surgical treatment at a single institution, with minimum 2 yr follow-up (avg 2.81). There were 100 (61%) primary and 64 (39%) revision surgery patients, and the majority had posterior only surgery (77%). Radiographs for 154 patients were analyzed for main thoracic (MT) and sagittal T5-T12 (Sag) curve magnitude/correction.

Results: For all patients, there was a significant change in MT Cobb from 47.4 to 24.9 deg (avg -22.5, $p=0.00$), and Sag Cobb from 35.5 to 30.0 deg (avg -5.41, $p=0.00$). We also found a significant decline in absolute and %pred PFT, with %pred FEV1 and %pred FVC decreasing 5.26% ($p=0.00$) and 5.74% ($p=0.00$), respectively. A clinically significant decline ($\geq 10\%$ pred FEV1) was observed in 27% of patients. PFT impairment increased from 14 (8%) patients pre-op to 23 (14%) patients after surgery, but was not statistically significant ($p=0.31$). Interestingly, patients with pre-op PFT impairment had a significant improvement in absolute and %pred FEV1 after surgery compared to those without pre-op impairment (2.8% v -6.19%, $p=0.03$), with no significant differences in MT/Sag curve correction between the two groups. Revision surgery patients had no difference in post-op %pred PFTs, however there were significantly more patients with a clinically significant decline in PFTs [23 (35%) v 22 (22%), $p=0.03$].

Conclusion: We performed the largest study to date evaluating pulmonary function tests in adult deformity patients, and found a significant decline in all measures of pulmonary function at 2 years following surgical correction. Surprisingly, patients with pre-op PFT impairment had improvement in absolute and %pred PFTs postoperatively. Revision surgery more frequently results in a clinically significant decline in PFTs.

119. Perioperative Complications of Pedicle Subtraction Osteotomy

Michael D. Daubs, MD; Prokopis Annis, MD; Brandon Lawrence, MD; Darrel S. Brodke, MD USA

Summary: We evaluated the perioperative complications on all patients who underwent a PSO at one institution. The major complication rate was 15% and the minor complication rate was 23%. The most common major complication was neurologic deficit 6.2%. The complication rate did not change with increased surgeon experience.

Introduction: Pedicle subtraction osteotomies (PSO) are now commonly performed to correct significant sagittal imbalance. The complications and outcomes of this complex procedure have been reported largely from the few major centers instrumental in perfecting and teaching the technique. The purpose of our study was to describe the perioperative complications (0-90 days) associated with PSO's performed at a tertiary spine center that has more recently adopted the technique.

Methods: We reviewed all 65 patients (47 females and 18 males, mean age of 60 years (range(r) 24-80)) that underwent a PSO at our institution. Descriptive data and analysis of complications were limited to the perioperative time - within 90 days of surgery. Therefore, no patients were excluded for lack of long-term follow up to accurately report all complications. Data analyzed included: OR time, length of stay (LOS), EBL, blood products, comorbidities, neurologic complications, and medical complications. Complications were analyzed as major and minor. Radiographic data were also analyzed.

Results: The PSO was performed at L1(2), L2(18), L3(34), L4(9), and L5(2). The mean sagittal C7 plumb line improved from 118mm to 53mm. The mean OR time

was 438 minutes (r 256-768), mean EBL 2371 cc (r 450-9000), mean LOS 7.6 days (r 3-24), mean ICU stay 1 day (r 0-5), and mean patient comorbidities 1.78(r 0-5). Ten patients (15.4%) had a major complication, and 15 (23%) had a minor complication. There were 3 perioperative deaths. The most common major complication was neurologic deficit 6.2% (4/65), 3 with a permanent foot drop, and one with paraplegia secondary to postoperative hematoma. There seemed to be no differences between patients with and without a major complication in regard to age, gender, comorbidities, OR time, number of levels fused, and EBL ($p>0.05$). Patients with a major complication had a longer ICU stay ($p=0.04$). There was no difference in the rate of major complications between the initial and later cases performed.

Conclusion: The pedicle subtraction osteotomy major complication rate was 15% and the minor complication rate was 23%. The most common major complication was neurologic deficit 6.2%. The complication rate did not change with increased surgeon experience.

120. Outcomes and Complications of Sacro-Pelvic Fixation Using S2 Alar-Iliac (S2AI) Fixation in Adult Deformity Patients Fused to the Sacrum: A Prospective Study with Minimum 2-Year Follow-Up

Khaled Kebaish, MD; Mostafa H. El Dafrawy, MD; Hamid Hassanzadeh, MD; Philip Neubauer, MD; Roosevelt Offoha; Eric W. Tan, MD; Paul D. Sponseller, MD USA

Summary: A prospective study to evaluate the clinical and radiographic outcome of the S2 Alar-Iliac (S2AI) technique for sacropelvic fixation in adult deformity patients following long posterior fusions to the sacrum

Introduction: Adult deformity patients requiring long posterior fusions to the sacrum often require supplemental pelvic fixation in order to avoid fixation failure and nonunion. There are many techniques available for fixation to the pelvis, some are technically difficult & require complex connectors, and separate incisions

Methods: We prospectively reviewed 146 patients undergoing long fusion to the Sacrum using (S2AI) technique. This method uses a starting point in the sacral ala between the S1 and S2 foramina. This starting point and trajectory allows these screws to be placed in line with the cephalad instrumentation, without the need for additional connectors or dissection. Clinical and radiographic outcomes, as well as complications were prospectively collected. We included patients with a 2 yr follow-up 48.5 months average (25-88)

Results: The mean age was 59 yrs (21-80), 108 females, and 38 males, 35% had multiple medical co-morbidities. At two year follow up 95% of the patients showed radiographic fusion From L4-S1. Four patients had removal of the S2AI instrumentation after one year, 2 as a second planned procedure, and 2 for painful instrumentation. There were 8 (S2AI) screw fractures in 5 patients; only one of which required revision surgery. Two screws were replaced in the perioperative period for malposition. Minimal loosening occurred in 16 screws (3 bilateral and 10 on one side), with no screw showing evidence of moderate loosening. One screw detached from the rod. Twelve patients underwent reoperation for problems not related to pelvic fixation: 3 due to pseudoarthrosis proximal to L4 and 5 for proximal junctional kyphosis, 3 underwent revision decompression and one for pseudoarthrosis at L4-L5. At final follow up there was a significant improvement from the baseline

PAPER ABSTRACTS

ODI score ($p=0.02$) and SRS scores in following domains; self image ($p=0.001$), satisfaction ($p=0.001$) and pain ($p=0.007$) (see table).

Conclusion: S2 Alar-iliac (S2AI) fixation is a safe and effective method to achieve sacropelvic fixation. Complications related to the technique are rare with a lower revision rate compared to other available techniques

121. Preliminary Experience with Clinical Use of a DNA Prognostic Test for Adolescent Idiopathic Scoliosis in 234 Patients

Suken A. Shah, MD; Petya Yorgova, MS; Geraldine I. Neiss, PhD; Peter G. Gabos, MD; J. Richard Bowen, MD
USA

Summary: A prospective series of patients who underwent prognostic AIS genetic testing is described. 46% of patients tested low risk for progression to a severe curve and had smaller curve magnitudes, a longer period between follow-up visits and a lower incidence of bracing compared to intermediate and high-risk patients.

Introduction: A commercially available saliva-based prognostic DNA test has been developed which utilizes a panel of 53 single nucleotide polymorphisms to predict the risk of progression in pts with mild AIS to a severe curve ($>40^\circ$).

Methods: 234 skeletally immature patients with mild AIS underwent this test in a prospective, consecutive fashion over 3 years. Scores were reported in a range of 1 to 200, stratified as follows: Low risk (LR) 1-50, Intermediate risk (IR) 51-179 and High risk (HR) 180-200.

Results: 108 pts (46.2%) tested LR; 113 pts (48.3%) tested IR; and 13 pts (5.6%) tested HR. Mean age was 11.8 yrs. The mean Cobb angle (MCA) at testing was 16.8° , and was significantly different between groups: the MCA at testing was 13.7° in LR, 19.0° in IR, and 23.1° in HR ($p<0.001$). Pts with curves less than 20° tested LR 59.4% of the time. So far, 165 pts had a 1st f/u, mean interval (MI) of 7.2 months and a MCA of 18.5° . The length of 1st f/u significantly differs: 4.9 months for HR, 6.7 for IR, and 8.3 for LR ($p<0.05$). 91 pts had 2nd f/u at a MI of 7.3 months with a MCA of 21.0° . 77 pts had 3rd f/u visit at a MI of 7.1 months with a MCA of 24.6° . 50 pts had 4th f/u at a MI of 6.9 months with a MCA of 24.6° . 22 pts had 5th f/u at a MI of 6.6 months with a MCA of 28.7° . One pt in the HR group progressed to 73° and had surgery. 50 pts overall (21.4%) are being treated with a brace: 62% pts in HR, 32% in IR, and 6% in LR ($p<0.001$).

Conclusion: A prospective series of patients who underwent prognostic AIS genetic testing is described. 46% of patients tested low risk, had smaller initial curves, a longer period between visits, and a lower incidence of bracing. Follow up to skeletal maturity is required to make statements about test validation. Proportions of AIS prognostic test results in our practice are different than those described by the developers of the test; it may be that our high acuity practice does not reflect a school screening population. This is important for clinicians in similar situations since it affects recommendations for anticipatory guidance.

122. Revision vs. Primary Vertebral Column Resection for Severe Spinal Deformities

Yasushi Oshima, MD, PhD; Lawrence G. Lenke, MD; Linda Koester, BS
Japan

Summary: In revision vs. primary VCR correction and complication rates, we found revision VCRs to be inferior to primary; however, no severe spinal cord deficits occurred in either group.

Introduction: The ability to treat severe spinal deformities through an all-posterior vertebral column resection (VCR) has obviated the need for a circumferential approach. However, it is technically demanding, especially in a revision setting. We examined correction rates and complications comparing revision vs. primary VCR patients.

Methods: Between 2002 and 2009, 55 patients underwent a posterior-only revision VCR using pedicle screws, anteriorly positioned cages and intraoperative spinal cord monitoring (SCM). Diagnoses included severe scoliosis (SS) ($n=3$), kyphoscoliosis (KS) ($n=29$), global kyphosis (GK) ($n=13$) and angular kyphosis (AK) ($n=10$). Radiographic findings and complications were compared with 38 patients who underwent a primary VCR during the same period. All patients had a minimum 2-year follow-up (2-6 years).

Results: The mean numbers of VCR levels were 1.6 in revision vs. 1.2 in primary cases, which was statistically significant ($p=0.004$). In the SS and KS groups, the major coronal curve correction was 48% in revision vs. 63% in primary cases, which was statistically significant ($p=0.001$). In the KS, GK and AK groups, the major sagittal curve correction was 52% in revision vs. 57% in primary cases ($p=0.27$). Preoperative ($p=0.02$) and postoperative ($p=0.002$) sagittal imbalance was significantly greater in the revision groups. There were no spinal cord-related complications, but 6 (11%) patients having revision and 3 (8%) with primary VCRs temporarily lost intraoperative neuromonitoring data or failed wake-up tests, none of whom had a permanent neurological deficit. Six (11%) patients with revision VCRs required operative revision owing to implant failure (5 pts) or delayed deep wound infection (1 pt), vs. only 1 (3%) patient with a primary VCR.

Conclusion: Although correction rates were inferior and complication rates were greater in revision vs. primary VCR procedures, there were no severe spinal cord deficits. Revision VCRs are more technically demanding than primary VCRs but can be safely performed in conjunction with intraoperative spinal cord monitoring.

123. Modified Lenke Classification System for Infantile and Juvenile Idiopathic Scoliosis

Takuya Mishiro, MD, PhD; Lawrence G. Lenke, MD; Linda Koester, BS; Keith H. Bridwell, MD; Scott J. Luhmann, MD
USA

Summary: No classification system currently exists for IIS and JIS that is universally accepted. Therefore, we developed a system by modifying the current Lenke Classification System for AIS. The frequency of curve patterns is remarkably similar to the AIS patient population. The ultimate goal of this modified system is to allow for the inclusion and organization of IIS and JIS curve patterns and objectively evaluate various treatment modalities.

Introduction: There is no universally acceptable system for the classification of infantile (IIS: age 0 to 2+11) and juvenile (JIS: age 2+11 to 9+11) idiopathic scoliosis.

We developed a system for the classification of IIS & JIS by modifying the Lenke Classification System for adolescent idiopathic scoliosis (AIS).

Methods: 115 IIS/JIS patients (67 operative/48 nonoperative; 86 females/29 males) were included in our review. The proximal thoracic (PT), main thoracic (MT) and thoracolumbar/lumbar (TL/L) regions were designated as the major curve (largest Cobb measurement, always structural) or as minor curves which are then determined to be structural or nonstructural. Minor curve criterion for the MT curve is where the apex is completely off the plumbline, and criterion for the TL/L curve is where the apex is completely off the center sacral vertical line. Structural characteristics of the PT curve are designated by a Cobb angle of $\geq 35^\circ$ and the height of the bilateral 1st ribs (1st rib opposite the MT curve ≥ 3 mm elevation for PT Cobb angle between 10-35 $^\circ$). If the PT Cobb angle is $< 10^\circ$, the curve is always nonstructural regardless of the 1st rib height.

Results: This produced the triad classification of curve types (1-6) combined with coronal lumbar (A, B, C) and sagittal thoracic modifiers (-, N, +) similar to the AIS classification system. Type 1 MT curves were found in 43.5% of patients (n=50), type 2 DT in 23.5% (n=28), type 3 DM in 2.6% (n=3), type 4 TM in 4.4% (n=5), type 5 TL/L in 20.9% (n=24), type 6 TL/L-MT in 4.3% (n=5). Coronal lumbar A modifier was found in 64.3% of patients, modifier B in 17.4%, modifier C in 18.3%. Sagittal lumbar modifier "-" was found in 11.3% of patients, "N" in 82.6%, "+" in 6.1%. The 5 most common classifications were 1AN (27.0%), 2AN (16.5%), 5AN (7.8%), 5CN (7.8%), 1A- (7.0%).

Conclusion: This classification system of IIS & JIS is based on the Lenke Classification System allowing for the classification from only upright AP and lateral x-rays, side-bending x-rays are not needed. The frequency of curve patterns is remarkably similar to the AIS population. The ultimate goal of this modified system is to allow the inclusion and organization of IIS & JIS curve patterns and objectively evaluate various treatments.

124. Prevalence and Risk Factors for Proximal Junctional Kyphosis Following Realignment Surgery by Pedicle Subtraction Osteotomy: A Multicenter Review

Virginie Lafage, PhD; Frank Schwab, MD; Christopher P. Ames, MD; Bertrand Moal, MS; Richard Hostin, MD; Praveen V. Mummaneni, MD; Khaled Kebaish, MD; Justin S. Smith, MD, PhD; Vedat Deviren, MD; Christopher I. Shaffrey, MD; Eric Klineberg, MD; Aaron R. Ducoffe, BS; Shay Bess, MD; International Spine Study Group USA

Summary: PJK is a known complication of osteotomy surgery for adult spinal deformity. The radiographic prevalence of PJK following PSO in adult deformity patients was 39% at 2 years but few require surgical revision (4%). Risk factors for PJK included UIV alignment, age and lumbar lordosis correction. Further work refining the definition and treatment of PJK appears warranted.

Introduction: This study analyzes the prevalence and risk factors for the development of PJK following lumbar PSO. The hypothesis was that PJK would develop early in the post operative period at high rates in this population undergoing dramatic sagittal plane realignment, and that risk factors based on baseline and follow up radiographs would emerge.

Methods: This multi-center, consecutive retrospective analysis was based on patients undergoing PSO surgery for ASD. The rate of patients developing PJK was identified based on 54 cases with 2 years follow up standing radiographs and at least 1 follow

up at 6 months or 1 year. Risk factors of developing a PJK were investigated on 75 patients with 6 months follow up and short fusion (T10-L2). PJK was radiographically defined as post-operative kyphosis of at least 10degrees (between UI and UIV+2) and a change in alignment from pre-op of more than 10degrees.

Results: The analysis of patients with 2y radiographs revealed a high rate of PJK (39%), without any significant difference between short and long fusions. In 82% of PJK cases, PJK was present at earlier follow up points. The rate of surgical revisions was 15%, with 4% occurring due to PJK. For patients with 6months follow-up and short fusion, significant risk factors for PJK were identified: neutral/kyphotic alignment at UIV/UIV+2, age > 55 , lumbar lordosis ideal correction or overcorrection. For patients with at most one of these risk factors 0% PJK was noted, while patients with 3 risk factors developed PJK in 42%.

Conclusion: New appearance of PJK after 6 months seems uncommon. The prevalence of PJK following PSO occurs at a high rate radiographically (39% at 2 years) but few require surgical revision (4%). Risk factors for PJK following short fusion that have emerged include UIV alignment, age and lumbar lordosis correction. Further work will assess the impact of radiographic PJK on HRQOL in order to refine the definition of this entity and make it clinically more relevant.

125. Identification of Decision Criteria for Revision Surgery among Patients with Acute Proximal Junctional Failure following Surgical Treatment for Spinal Deformity

Richard Hostin, MD; Michael F. O'Brien, MD; Ian McCarthy, PhD; Christopher P. Ames, MD; Khaled Kebaish, MD; Douglas C. Burton, MD; Virginie Lafage, PhD; Frank Schwab, MD; Christopher I. Shaffrey, MD; Justin S. Smith, MD, PhD; Kirkham B. Wood, MD; Robert A. Hart, MD; Breton Line, BSME; Vedat Deviren, MD; International Spine Study Group USA

Summary: The purpose of this study is to analyze the decision criteria for revision surgery among patients with Acute Proximal Junctional Failure (APJF) following surgical treatment for spinal deformity. Factors that appear to influence the decision to perform revision surgery include the source of APJF, the time from surgery to development of APJF, the number of levels fused, location of upper instrumented vertebra (UIV), and the patient's gender.

Introduction: Revision rates for patients with APJF remain relatively high, yet the decision criteria for performing revision surgeries is not uniform and is often patient-specific. This study aims to identify demographic and radiographic characteristics that influence the decision to perform revision surgery among patients with APJF.

Methods: Multi-center, retrospective analysis of 68 consecutive patients who suffered APJF within six months of surgery (average of 11.4 weeks from surgery to APJF). Patients ranged from 26 to 82 years of age (mean=63). APJF was identified based on: 15 $^\circ$ post-operative increase in kyphosis between UIV and UIV+2; fracture of UIV or UIV+1; or need for proximal extension of fusion. Twenty-eight patients underwent revision surgery following index.

Results: Patients who sustained trauma were more likely to have a revision (of 6 patients sustaining trauma, 5 received revision; $p < 0.03$) as were patients with early APJF (9 weeks to APJF for patients with revision versus 13 weeks for patients without revision; $p < 0.05$). Similarly, longer fusions, higher proximal junctional

PAPER ABSTRACTS

kyphosis (PJK) angulation, and fusions with upper thoracic UIV were significantly more likely to receive revisions ($p < 0.05$), while sagittal vertical axis (SVA), pelvic tilt (PT), age, and incidence of fracture generally showed no significant relationship with rate of revision.

Conclusion: The decision to perform revision surgery is often complicated and patient-specific. This study attempted to identify observable patient and radiographic characteristics that appear to affect the decision to perform revision surgery. Factors that appear to influence this decision include the source of APJF, the time from surgery to development of APJF, the number of levels fused, location of UIV, PJK angulation, and the patient's gender. Some factors that were expected to influence revision had no statistical effect, including SVA, PT, incidence of fracture, and age.

126. Can Minimally Invasive Surgical Strategies for Deformity Correction Avoid the Need for Routine Osteotomies in Moderate to Severe (>50 degrees) Adult Scoliosis?

Neel Anand, MD; Babak Khandehroo, MD; Sheila Kahwaty, PA-C; Eli Baron, MD
USA

Summary: Patient age, comorbidities and blood loss may be limiting factors when considering surgical correction of scoliosis. Spinal osteotomy as a well-known procedure for correction of severe scoliosis is associated with significant morbidities and complications and blood loss. A combination of Minimally invasive surgical techniques may introduce a useful modality for correction of severe scoliosis with achieving comparable radiological outcomes and lower morbidity and complication rate which may obviate the need for routine osteotomy.

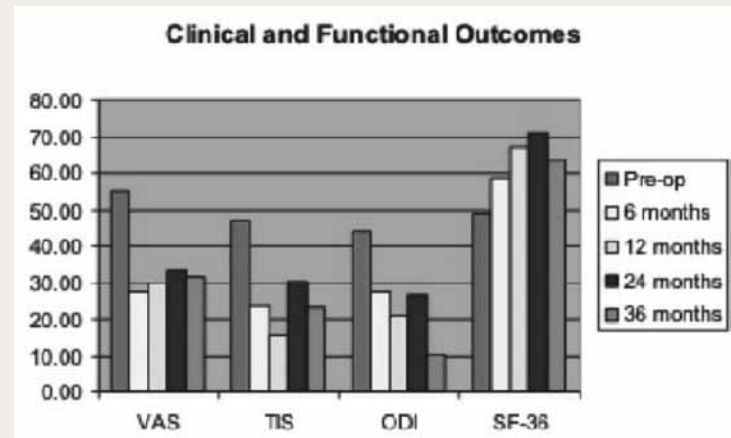
Introduction: Spinal osteotomy is a well-known surgical option to accomplish realignment of severe rigid scoliosis. However it is associated with considerable morbidity and blood loss. MIS has previously been shown to achieve comparable deformity correction but lower morbidity and complication in mild cases of scoliosis. This study assesses MIS techniques' efficacy in more severe scoliosis without performing any osteotomies.

Methods: This is a retrospective study of 40 consecutive patients with significant thoracolumbar scoliosis (COBB angle $> 30^\circ$) who underwent MIS correction. Deformities included Idiopathic Scoliosis (20), Degenerative Scoliosis (18) and Iatrogenic Scoliosis (2). All underwent a combination of 3 MIS techniques: Segmental Multilevel Percutaneous Pedicle Screw Fixation (40), DLIF (32) and AxialLIF (16). None of our patients underwent any kind of osteotomies for deformity correction.

Results: Mean age was 58yrs (20-81). Mean Follow-up was 28months (9-58). Patients with one-stage same day surgery had a mean blood loss of 592ml and a mean surgical time of 333min. Patients with two-stage surgery had a mean blood loss of 320ml and a surgical time of 192min for DLIF and a mean blood loss of 435ml and a mean surgical time of 257min for Posterior Instrumentation and AxialLIF. The pre-op COBB angle was 41 (30-74.7) and corrected to 16.6 (4- 42.8). The pre-op coronal balance was 33.09mm (5.5-143) and corrected to 15 mm (0-31). The pre-op sagittal balance was 44.3mm (-47 to 160) and corrected to 1.3mm (-99 to 88). The pre-op lumbar AVT was 41.7mm (11.7-90.4) and corrected to 17.9mm (2.7-33). 7 patients had adverse events requiring intervention: 3 with L5-S1 pseudarthrosis, 1 with stenosis and radiculopathy, 1 with delayed

onset adjacent osteomyelitis, 1 with sacral wound dehiscence, 1 with proximal screw prominence.

Conclusion: In this study, patients with significant thoracolumbar scoliosis undergoing MIS correction had outstanding cosmetic and radiological improvement and a considerably lower morbidity and complication rate at both early and long term follow up. Therefore MIS may obviate the need for routine osteotomies which are associated with significant morbidities such as major blood loss, dural tear, acute and delayed neurological deficits and epidural hematoma.



The FDA has not cleared the drug and/or medical device for the use described in this presentation (i.e., the drug or medical device is being discussed for an 'off label' use).

127. Long-Term Two to Five Year Clinical and Functional Outcomes of Minimally Invasive Surgery (MIS) for Adult Spinal Deformity

Neel Anand, MD; Babak Khandehroo, MD; Sheila Kahwaty, PA-C; Eli Baron, MD
USA

Summary: Surgical correction of adult spinal deformity is traditionally done through open thoraco-abdominal and posterior approaches. This involves considerable morbidity especially blood loss and a high complication rate. The application of different minimally invasive strategies represents a newer method for correction of spinal deformity. This study assesses the long term clinical, functional and radiological outcomes of these MIS techniques in adult scoliosis.

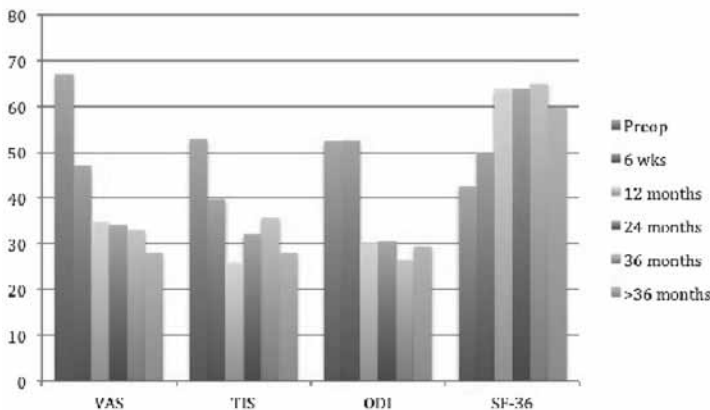
Introduction: Traditional surgical approaches for Adult Spinal Deformity are associated with significant blood loss and morbidity, in a population that is often elderly with multiple medical comorbidities. MIS represents a newer method of achieving similar long-term outcomes but considerably lower morbidity and complication rates.

Methods: This is a retrospective study of 76 consecutive patients who underwent MIS correction of spinal deformity with fusion of 2 or more levels. Deformities included Degenerative scoliosis (58), Idiopathic scoliosis (12), and Iatrogenic scoliosis (6). All underwent deformity correction using a combination of 3 MIS techniques: DLIF (69), AxialLIF (35) and posterior instrumentation (72). 38 patients were staged with DLIF done first followed by the posterior instrumentation including AxialLIF done later. Radiographs and clinical and functional outcomes were assessed preoperatively and at each postoperative visit.

Results: Mean age was 64 years (20 to 84). Mean Follow-up was 40 months (26-60) with greater than 3yrs follow-up in 43 patients. Patients with one-stage same day surgery (38) had a mean blood loss of 541ml and a mean surgical

time of 277min. Patients with two-stage surgery(38) had a mean blood loss of 290ml and surgical time of 185min for DLIF and 336ml and 238min respectively for posterior instrumentation including AxiaLIF. Mean hospital stay was 7.8 days (2-27). The mean Pre-op Cobb angle was 24 (range: 6-61), which corrected to 10.4(range:0.6-28.8). The pre-op Coronal balance was 25.5mm (5.2-85.4), which corrected to 12.4mm (0-41). The mean pre-op sagittal balance was 31.3mm(-64.8 to 151), which corrected to 14.7mm(-91.7 to 93.4). The pre-op lumbar AVT was 23 mm(6.7-57), which was corrected to 11.9mm (0-40.7). 12 patients had adverse events requiring intervention: 4 patients with Psuedoarthrosis, 4 with stenosis, 1 required screw removal, 1 with osteomyelitis, and 2 with wound dehiscence.

Conclusion: A combination of 3 Novel MIS techniques allows comparable correction of Adult Spinal Deformity with low pseudarthrosis rates, significantly improved functional outcomes, excellent clinical and radiological improvement, but considerably lowers morbidity and complication rates at early and at long term follow-up.



Clinical and Functional Outcomes

The FDA has not cleared the drug and/or medical device for the use described in this presentation (i.e., the drug or medical device is being discussed for an 'off label' use).

128. Sagittal Spinal Profile And Spinopelvic Balance In Parents Of Scoliotic Children, As Compared to Normal Controls

Michiel Janssen, PhD; Koen L. Vincken, PhD; Tomaz Vrtovec, PhD; Bastiaan Kemp, BSc; Max A. Viergever, DSc; Lambertus W. Bartels; Rene M. Castelein, MD, PhD Netherlands

Summary: To test the hypothesis that the well-known familial trend in AIS may be explained by the inheritance of a sagittal spinal profile, we prospectively analyzed free-standing lateral radiographs of parent couples of girls with severe progressive AIS and age-matched controls. The sagittal spinal profile of the fathers of scoliotic children was significantly flatter than the sagittal spinal profile of fathers of non-scoliotics, indicating that fathers may contribute through their sagittal spinal profile to the inheritance of AIS.

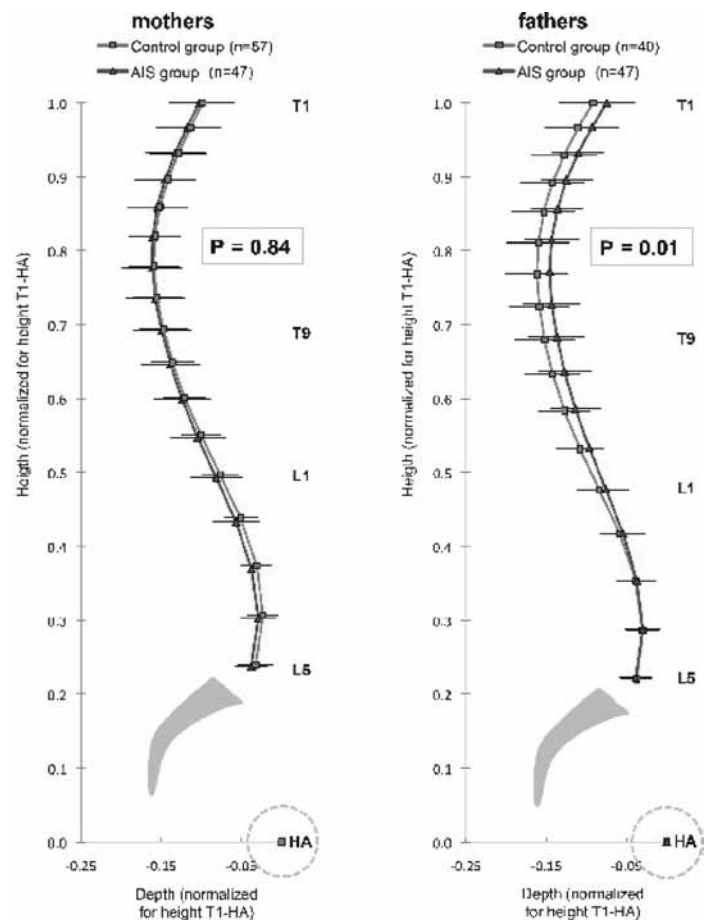
Introduction: It has been suggested that the sagittal spinal profile is partly hereditary. The relationship between the sagittal spinal profile and spinal biomechanics has also been established. In this study we test the hypothesis that the well-known familial trend in AIS may be explained by the inheritance of a sagittal spinal profile, that has been shown to make the spine less resistant to rotatory forces.

Methods: Freestanding lateral radiographs of 51 parent couples of girls with severe progressive AIS (AIS group) and 102 age-matched controls (control group) were taken.

Parents with manifest spinal deformities or spinal pathology were excluded, to avoid distorted sagittal images with unreliable measurements. Parameters of sagittal spinal profile and spinopelvic balance were semi-automatically calculated, and analyzed between the fathers of both groups, and between the mothers of both groups.

Results: In the fathers of the AIS group, the plumb line of T4 was significantly less posteriorly positioned relative to the hip axis, vertebrae T11-L2 were significantly less backwardly inclined, and a significantly flatter spine was found as compared to the fathers of the control group. No statistically significant difference was observed between the mothers of both groups. (Fig. 1)

Conclusion: The sagittal spinal profile of the fathers of scoliotic children was significantly flatter than the sagittal spinal profile of fathers of non-scoliotics. No difference was found in the sagittal spinal profile of the mothers of scoliotics as compared to mothers of nonscoliotics, possibly due to an inevitable normalization of the study population (exclusion of parents with spinal pathology) mainly in the mothers. Although, it is well known that scoliotic mothers have an increased risk of getting scoliotic offspring, this study indicates that fathers may contribute as well through their sagittal spinal profile to the inheritance of AIS.



Mean sagittal spinal profile in the mothers and fathers in both groups. Profiles were normalized in height and depth, based on the vertical distance of the midpoint of T1-hip axis (HA), and the HA was set as origin.

PAPER ABSTRACTS

129. The Effect of Complications on Health Outcomes Among Patients Undergoing Three-Column Osteotomy Surgery

Michael F. Obrien, MD; Richard Hostin, MD; Ian McCarthy, PhD; Christopher P. Ames, MD; Justin S. Smith, MD, PhD; Munish C. Gupta, MD; Robert A. Hart, MD; Douglas C. Burton, MD; Christopher I. Shaffrey, MD; Shay Bess, MD; Frank Schwab, MD; Virginie Lafage, PhD; Khaled Kebaish, MD; Vedat Deviren, MD; International Spine Study Group
USA

Summary: Complications may have important negative effects on the outcomes of surgical treatment for adult spinal deformity (ASD). This study analyzes the impact of different categories of complications on health related quality of life (HRQOL) for patients undergoing Pedicle Subtraction Osteotomy (PSO) surgery. An unexpected return to the OR prior to discharge was the only specific complication for which patients consistently reported lower HRQOL improvements, the effects of which varied based on the patient's age.

Introduction: This study analyzes the impact of complications on HRQOL among patients undergoing PSO surgery for ASD. The hypothesis is that patients who experience complications report significantly lower HRQOL improvements relative to patients without complications.

Methods: Multi-center, retrospective analysis of 98 consecutive patients undergoing PSO surgery for whom collection of HRQOL measures was attempted and for whom complications were recorded for up to six weeks following discharge (ages 20 to 78, average of 53). HRQOL measures were based on the Medical Outcomes Study Short Form 36 (SF-36), the Oswestry Disability Index (ODI), and the Scoliosis Research Society (SRS) questionnaires after at least one year following surgery.

Results: Paired t-tests and multivariate regressions generally showed no significant differences in HRQOL improvements between patients with versus without complications ($p > 0.05$). One exception is for patients with an unexpected return to the OR prior to discharge ($n=24$). On average, such patients reported lower improvements in SRS pain (0.39 versus 0.89; $p < 0.03$) and SRS mental health (0.01 versus 0.37; $p < 0.05$) relative to patients without a return to the OR. Patients aged 60 years or more with an unexpected return to the OR also reported lower average improvements in SRS self-image (0.60 versus 1.41; $p < 0.03$) and SRS functional activity (0.02 versus 0.77; $p < 0.02$).

Conclusion: While most complications after PSO surgery for ASD do not significantly impact average improvement in HRQOL, complications resulting in a return trip to the OR prior to discharge do tend to generate significantly lower HRQOL improvements. There is also evidence that complications have heterogeneous effects on HRQOL, with older patients more negatively affected by a return trip to the OR than younger patients.

130. Increased Utilization of Fusion with Instrumentation and BMP in the Medicare Patient Population Over Time

Jacob M. Buchowski, MD, MS; Nicholas J. White, MPH; Margaret A. Olsen, PhD, MPH
USA

Summary: Analysis of Medicare claims data demonstrated increased utilization of fusion with instrumentation over a 6-year time span from 22.2% in men and 28.7% in women in 2000 to 37.5% in men and 47.1% in women in 2005. In comparison to surgical decompression-only, the

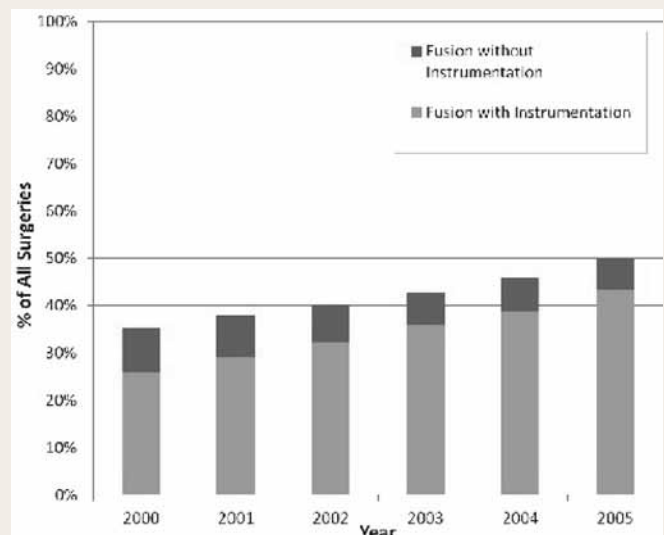
odds of fusion with instrumentation increased almost 2-fold from 2000 to 2005. BMP utilization also progressively increased from 4.0% in men and 5.4% in women in 2003 to 18.1% in men and 22.2% in women in 2005.

Introduction: Healthcare expenditures in the United States have grown from \$1.4 trillion in 2000 to \$2.6 trillion in 2010. Relatively little is known about the utilization of decompression procedures and fusion with and without instrumentation and the use of BMP over time. We analyzed the trends in utilization of decompression procedures, fusion with and without instrumentation and BMP in Medicare beneficiaries from 2000 to 2005.

Methods: We used 5% Medicare claims data (Chronic Condition Warehouse) to identify Medicare beneficiaries >65 years of age who had claims for spinal decompression or fusion and with both professional and inpatient facility claims. To improve the accuracy of the claims algorithm to identify spinal operations we required either concurrent claims for spinal anesthesia or a spine-related diagnosis. Operations due to motor vehicle accidents were excluded. Multivariate logistic regression was used to analyze surgical trends over time, controlling for patient demographics and diagnosis.

Results: During the 6-year time period there were 18,704 inpatient admissions coded for decompression-only, 2,484 admissions coded for fusion without instrumentation and 11,353 coded for fusion plus instrumentation. The proportion of surgeries coded as fusion with instrumentation in men increased from 22.2% in 2000 to 37.5% in 2005 and in women from 28.7% in 2000 to 47.1% in 2005. In comparison to decompression surgery only and controlling for female gender, race, age and spinal diagnoses, the odds of fusion with instrumentation increased almost 2-fold from 2000 to 2005. Women were 19% more likely than men to have fusion with instrumentation compared to decompression only ($p < 0.001$) after controlling for underlying spinal diagnosis. In addition to increased number of fusions over time, there has been increased utilization of BMP since 2003. The proportion of surgeries in which BMP was utilized in men increased from 4.0% in 2003 to 18.1% in 2005 and in women from 5.4% in 2003 to 22.2% in 2005.

Conclusion: Analysis of Medicare claims data demonstrated a 2-fold increase in the utilization of fusion with instrumentation from 2000 to 2005 compared to decompression surgery. In addition, a 5-fold increase in the utilization of BMP was seen from 2003 to 2005.



131. Does Preoperative Narcotic use Persist after Spinal Deformity Surgery? A Comparison of Non-Narcotic and Narcotic Using Groups

Addisu Mesfin, MD; Lawrence G. Lenke, MD; Keith H. Bridwell, MD; Usman Akhtar, BA; Jennifer M. Jupitz; Jeremy L. Fogelson, MD; Stuart Hershman, MD; Han Jo Kim, MD; Linda Koester, BS USA

Summary: Preop narcotic use significantly decreases following spinal deformity surgery. Postop both groups (NoNarc & Narc) had significant improvement in outcome scores. However a higher degree of SRS pain score improvement was seen in the Narc group.

Introduction: The role of preop narcotic use and its influence on outcomes following spinal deformity surgery is unknown. Our objectives were to evaluate: 1) if preop narcotic use persists following spinal deformity surgery; 2) if outcomes of spinal deformity are adversely affected by preop narcotic use.

Methods: 253 adult patients (230 female/23 male) undergoing primary spinal deformity surgery were enrolled. Preop, 2yr postop and latest f/u pain medication use was collected along with ODI, SRS pain and SRS scores. Preop insurance status was also collected. All patients had a minimum 2 yr f/u (avg 47.4 month).

Results: 168 patients (Group NoNarc) were taking no pain meds/NSAIDs only preop. 85 patients (Group Narc) were taking mild/moderate/heavy narcotics preop. Avg age was 48.2 for Group NoNarc and 53.6 for Group Narc ($p < 0.005$). Insurance status (Private/Medicare/Medicaid) was similar between the groups ($p = 0.39$). At latest f/u, 137/156 (88%) prior NoNarc pts were still not taking any narcotics while 48/79 (61%) prior Narc pts were now not taking any narcotics ($p < 0.001$). Postop Group NoNarc had significant improvements in ODI (26 to 15.9, $p < 0.001$), SRS pain (3.36 to 3.9, $p < 0.001$) and SRS score (3.36 to 4, $p < 0.001$). Group Narc also had significant improvements in ODI (44 to 29.5, $p < 0.001$), SRS pain (2.3 to 3.38, $p < 0.001$) and SRS score (2.78 to 3.68, $p < 0.001$). A comparison of change in outcome scores between the two groups showed a higher improvement in SRS pain score for Group Narc compared to NoNarc ($p < 0.001$).

Conclusion: Narcotic use significantly decreases following spinal deformity surgery. All outcome scores significantly improved postop in both groups. However, the Narc group had significantly greater improvement in SRS pain scores compared to the NoNarc group.

132. The Role of Minimally Invasive Lateral Retroperitoneal Transposas Interbody Fusion for Sagittal and Coronal Alignment Correction in Adult Lumbar Scoliosis Patients

Yoon Ha, MD, PhD; Weber Michael, MD, PhD; Sassan Keshavarzi; Gregory M. Munds, MD; Vedat Deviren, MD Republic of Korea

Summary: LIF has become a more popular approach to address ASD. Little data exists on the isolated effects of LIF on radiographic outcomes. LIF reliably improved the major Cobb by 40%, had little effect on SVA and improved LL by 15 o. Rigid lumbosacral curves in light of coronal neutral or imbalance contralateral to the concavity experienced coronal plane decompensation after LIF and required PSFI to correct the deformity.

Introduction: LIF is an alternative method to address coronal and sagittal alignment. Few studies have analyzed its effect on coronal and sagittal plane correction. No study has isolated the effect of LIF on overall deformity correction with subsequent

posterior spinal fusion with instrumentation (PSFI). The aim of this study is to investigate the role of LIF on radiographic changes in coronal and sagittal alignment in adult spinal deformity (ASD).

Methods: A multicenter retrospective review of radiographic and clinical parameters of 32 patients with ASD undergoing LIF between 2008-2010 was performed. All patients underwent PSFI to maintain or achieve desired correction. Standing AP and LAT 36" radiographs were obtained: preoperatively, after LIF, and after open PSFI. Segmental, regional, and global coronal and sagittal alignment was measured at each stage and analyzed. The mean pre- and post-operative clinical outcomes (ODI, SRS-22, SF-36) were compared.

Results: Preoperative Cobb angle averaged 46o (range: 23-79 o) and improved by 40% to 28o (range: 3-53°) after LIF and to 15o (range: 2-39 o) after PSFI. (67%). Fractional curve (L4-S1) angle was 21o (range: 2 - 35°) preop and improved to 14o (range: 1 - 24°) after LIF and to 8o (range: 0-16 o) after PSFI. The L1-L5 lordosis improved from 30° (range 1 - 65°) preoperatively to 46° (range 17 - 71°) after LIF ($p < 0.01$) and to 51° (range 23-75 °) after PSFI. Sagittal vertical axis (SVA) decreased from 7.3 cm (range 0.1 - 15.2 cm) to 6.9 cm (range 0.72- 18.3 cm) after LIF ($p > 0.05$) and to 3.2 cm (range -5.5- 11.3cm) after PSFI ($p < 0.01$). Only the group with coronal imbalance contralateral to the concavity 5.7cm (range 2.3- 8.7 cm) had improvement in balance after LIF 1.6cm (range 0.4- 4.3cm).

Conclusion: LIF with PSFI improves segmental and global plane alignment in patients with ASD. LIF alone improves the segmental Cobb angle and regional lumbar lordosis. However, the rigid lumbosacral fractional curve and thoracic compensatory curves may lead to coronal decompensation in patients with coronal plane. These patients require additional correction at the time of posterior stabilization.

133. Five-Year Results of Selective Single-Level Artificial Lumbar Disc Replacement in the Presence of an Adjacent Degenerate Level

John Nathaniel M. Ruiz, MD, MRCS; Joseph Thambiah, FRCS; Hee-Kit Wong Singapore

Summary: We present the results of a prospective follow-up of all patients with lumbar degenerative disc disease (DDD) enrolled in a bioethics-approved artificial disc replacement (ADR) investigation from a single-centre. Two patient populations were identified based on pre-op MRI lumbar spine morphology; single-level DDD and double-level DDD. Single-level ADR using ProDisc-L was done at either L4L5 or L5S1 and clinical results were analysed. Selective single-level ADR in double-level disc degeneration results in improvement of symptoms compared to pre-op, but are significantly inferior to ADR in single-level DDD. Selectively single-level ADR does not appear to be protective of the adjacent degenerate level from becoming symptomatic in 23% of our patients.

Introduction: Specific indications for ADR in multi-level DDD are lacking despite reports of multi-level ADR. Not all degenerate discs may be symptomatic. We aim to describe clinical outcomes of selective single-level ADR in the presence of adjacent degenerate discs compared to those of single-level ADR in single-level DDD.

Methods: 48 patients with 5yrs follow-up after single-level ADR were assessed using xrays, VAS, ODI, & SF36 at pre-op, and at 6, 12, 24 months, & 5 yrs post-op. 26 patients had 1 level DDD at L4L5 or L5S1 and underwent

PAPER ABSTRACTS

single-level ADR (S-ADR). The remaining 22 patients had >1 level DDD and also underwent single-level ADR at L4L5 or L5S1 after provocative discography identified only 1 painful disc (SS-ADR). Statistical analysis using a general linear model for repeated measures was used ($p < .05$).

Results: There were time-dependent trends towards improvement in VAS, ODI, and SF-36 for both S-ADR and SS-ADR ($p < .0001$) and were maintained until 5 yrs. S-ADR showed trends toward better scores. This divergent pattern reached significance at 6 months for ODI ($p < .001$); by 12 months for VAS ($p < .01$), bodily pain ($p < .001$), physical ($p < .01$), & social function ($p < .05$); and at 24 months for general health ($p < .0001$). Bodily pain, social function, and general health scores of SS-ADR deteriorated after 24 months, with general health returning to pre-op levels. 5 patients in the SS-ADR group became symptomatic in their adjacent degenerative level >14 months post-op (confirmed by discography) of which 2 underwent adjacent level surgery. 37/48 devices had motion $\geq 5^\circ$ by 5 years (17 S-ADR vs 20 SS-ADR). There was no significant difference on subgroup analysis of VAS, ODI, and SF36 within S-ADR & SS-ADR groups with respect to device motion ($\geq 5^\circ$ vs $< 5^\circ$ motion).

Conclusion: ADR in the presence of an adjacent degenerative level will result in outcomes similar to that of single-level ADR until 12 months, after which, outcomes tend to diverge towards inferiority that persists until 5 yrs post-op. It is difficult to predict if selective single-level ADR had any effect on the natural history of a non-symptomatic adjacent degenerate disc, but our results show that SS-ADR may not protect an adjacent segment that is already degenerate from becoming symptomatic in 5/22 (23%) of patients.

134. PLF vs. TLIF in the Treatment of Degenerative Lumbar Scoliosis

Fangcai Li, PhD
China

Summary: Forty patients of degenerative lumbar scoliosis treated with TLIF and PLF were studied prospectively. TLIF is helpful in improving lumbar lordosis and sagittal balance when compared with PLF, and thus better clinical outcomes are obtained. For patients without significant loss of lumbar lordosis and with good spinal sagittal balance preoperatively, PLF is still an option.

Introduction: The operative management of degenerative lumbar scoliosis is still under controversy, and little consensus has been achieved on surgical approach and fusion technique of lumbar spine. The purpose of this study is to compare the safety and efficacy of posterolateral lumbar fusion (PLF) and transforaminal lumbar interbody fusion (TLIF) in the treatment of degenerative lumbar scoliosis (DLS).

Methods: Forty DLS patients with Cobb angles of 20-60° were randomized into PLF and TLIF groups. The patients were followed up for 2-5 years. Operative time, intraoperative blood loss, imaging results, and clinical outcomes were compared.

Results: Complete information was available for 37 patients, including 18 patients in the PLF group and 19 in the TLIF group. There were significant differences between the two groups with regard to the operative time ($P = 0.002$) and the intraoperative blood loss ($P = 0.048$). The occurrence rates of early complications in the 2 groups were 11.1% and 26.3%. There were no significant difference of the recovery rates in the Cobb angle and the spinal coronal balance between the two group. However, the recovery rates of the lumbar lordotic

angle and spinal sagittal balance were significantly different (36.7% vs 62.5% and 44.8% vs 64.1%, respectively). In various domains of SRS-22, the scores for pain and satisfaction with the treatment showed significant differences between PLF and TLIF group ($P = 0.033, 0.006$, respectively). As to the function, self-image, and mental health scores, there were no significant differences.

Conclusion: TLIF helps to improve lumbar lordosis and sagittal balance, thus, TLIF group shows better clinical efficacy. For patients without significant loss of lumbar lordosis and with good spinal sagittal balance preoperatively, PLF is still an option.

135. Does the Use of Pelvic Screws Decrease the Revision Rate of Long Spinal Fusions to the Sacrum

Christopher DeWald, MD; Isaac L. Moss, MDCM, MASc, FRCSC
USA

Summary: A review of consecutive long spinal fusions to the sacrum utilizing S1 screws and interbody fusions compared to those with the adjunct fixation of bilateral iliac screws was performed at one institution from 2000-2010. 75 patients underwent long fusions to the sacrum with iliac fixation and 20 had fusions to S1 without iliac screws. Results revealed comparable revision rates including lumbosacral junction. Surprisingly, the rate of pseudarthrosis requiring revision in the mid lumbar spine was much higher.

Introduction: A retrospective review of long spinal fusions from the thoracic spine to the sacrum was performed at one institution from 2000-2010. 95 patients were found to fit the study criteria. 75 patients had fusions from the thoracic spine to the sacrum utilizing bilateral iliac screws. 20 patients had fixation to S1 with interbody grafts without iliac screws. Revision surgical rates and complications were reviewed.


Methods: All clinical office charts and radiographic records were reviewed. Revision surgeries were evaluated for etiology and complication.

Results: 37 of the patients underwent revision surgery. 10 had iliac screws removal. 13 patients with fixation to the pelvis had mid lumbar pseudos requiring revision surgery. L5-S1 pseudarthroses occurred in both groups however the number of sacral fractures were higher in the patients fused to sacrum without iliac fixation.

Conclusion: Iliac fixation helps to prevent sacral fractures and severe L5-S1 failures but did not prevent pseudarthroses or revision surgeries.



E-POSTER INDEX



The Scoliosis Research Society gratefully acknowledges Orthofix, Inc.
for support of the IMAST E-Newsletter.



E-POSTER INDEX

E-Posters may be viewed at specialized kiosks, adjacent to the Exhibit Hall, as well as on the CD-ROM included with your registration materials, supported, in part, by a grant from K2M.

E-Poster Categories	E-Poster Numbers	E-Poster Categories	E-Poster Numbers
Adolescent Idiopathic Scoliosis	201-324	Etiology/Genetics	586-590
Adult Spinal Deformity	325-410	Innovative Methods	591-632
Basic Science	411-449	Kyphosis	633-646
Cervical Deformity	450-456	Lumbar Degenerative	647-689
Cervical Reconstruction	457-464	Miscellaneous	690-727
Complications/Infections	465-527	Natural History	728-731
Congenital Deformity	527-531	Neuromuscular Deformity	732-747
Diagnostic Methods	532-554	Spondylolisthesis	748-756
Disc Replacement/Dynamic Stabilization	555-561	Trauma	757-784
Early Onset Scoliosis	562-585	Tumor	785-791

Adolescent Idiopathic Scoliosis

201. A Novel Technology For Measuring Cobb Angles

Christopher Kestner, MD; Patrick J. Cahill, MD
USA

A new technology on a free iPhone app allows one to accurately and reliably measure cobb angles on hard copy x-rays digital radiographs.

The FDA has not cleared the drug and/or medical device for the use described in this presentation (i.e., the drug or medical device is being discussed for an 'off label' use).

202. Scoliosis in the 22Q11 Deletion Syndrome

Dino Colo, BSc; Denis S. Drummond, MD; Rene M. Castelein, MD, PhD
Netherlands

The 22q11 deletion syndrome (22q11DS) is a frequently occurring multisystem disorder, in which scoliosis may also occur. In our retrospective analysis we found that 15% of these patients have a scoliosis, with 14% requiring surgery. The true prevalence may even be higher. It can represent a clinically significant problem and therefore a proactive approach towards the diagnosis and management of scoliosis in 22q11DS is recommended.

204. Correction of Severe Rigid Scoliosis (Cobbs>90 degree) by Anterior Release & Posterior Osteotomies

Upendra Bidre, MS; Bhavuk Garg; G. Raghavan, MS (Ortho); Arvind Jayaswal, MS (ortho); Pankaj Kandwal, MS (Ortho)
India

The Key to good surgical correction is a good & extensive release of contracted anterior & posterior soft tissues as well as bony resection (osteotomies if required) along with judicious use of instrumentation.

205. Is There Any Role for the Five-Degree Rule?

Patrick J. Cahill, MD; Jane S. Hoashi, MD, MPH; Randal R. Betz, MD; Tracey Bastrom, MA; Michelle C. Marks, PT, MA; Harms Study Group; Amer F. Samdani, MD
USA

The original Lenke classification system had a caveat that a secondary curve should be considered to be structural if it was within 5 degrees of the primary curve regardless of its flexibility. We compare cases that fall under this rule in two treatment subsets (selective and non-selective fusions) to similar cases with flexible curves 5 to 10 degrees less than the primary. We found little difference in outcomes. The "within 5 degrees rule" does not and probably should not influence surgical planning.

206. Active SRS Members Demonstrate Huge Variation in Implant Density when Planning Routine Adolescent Idiopathic Scoliosis Constructs

Carl-Éric Aubin, PhD, PEng; A. Noelle Larson, MD; Franck Le Naveaux; Hubert Labelle, MD; Peter O. Newton, MD; David W. Polly, MD; Minimize Implants Maximize Outcomes Study Group
Canada

We documented significant heterogeneity of screw density strategies among 13 surgeons evaluating the same 5 AIS cases. Between 7 and 14 levels were instrumented and the preferred number of implants ranged between 12 and 26 (mean 1.81 implant/level; range 1.18-2). All surgeons found some variation in implant density acceptable for clinical treatment. Alternate acceptable screw density configurations ranged from 0.78 to 2.0. Further biomechanical investigation and analysis of clinical outcomes are needed to determine the impact of anchor density on correction and safety.

208. The Use of a Subcutaneous Pain Pump Lowers Narcotic Use and Length-of-Stay in Patients Undergoing Posterior Spinal Fusion for Adolescent Idiopathic Scoliosis

M. W. Shrader, MD; John S. Jones, MD; Judson W. Karlen, MD; Gregory R. White, MD; Lee S. Segal
USA

This retrospective study demonstrated that the use of a subcutaneous pain pump lowered narcotic use and length-of-stay in patients with adolescent idiopathic scoliosis undergoing posterior spinal fusion.

E-POSTER INDEX

209. Adding-On Phenomenon in Selective Posterior Thoracic Fusion for Lenke Type 1A Curve Pattern: Are There Some Risk Factors?

Mario Di Silvestre, MD; Georgios Bakaloudis; Francesco Lollo

Italy

Adding-on phenomenon can occur after selective fusion in thoracic scoliosis.

We retrospectively reviewed 37 adolescents affected by a single thoracic Lenke 1A (King type III, IV) curve.

At a mean follow-up of 4.2 years the thoracic curve presented a correction of 58.4%, and the lumbar curve of 52.4%. In 7 cases (18%) an "adding on" phenomenon occurred. All patients presented a Lenke 1A-King IV curve with the distal fusion level being two or more levels proximal to the SV.

210. Which Factors Predict Shoulder Asymmetry in Patients with Lenke Type 1 Curves Following Pedicle Screw Instrumentation?

Meric Enercan; Sinan Kahraman; Cagatay Ozturk, MD; Alauddin Kochai; Mehmet B. Balioglu, MD; Tunay Sanli, MA; Azmi Hamzaoglu, MD; Ahmet Alanay

Turkey

Shoulder asymmetry was more commonly observed in pts who had incomplete fusion of PT, higher % correction of MT. TT, Cla and SH measured in TRUGA were correlated with shoulder asymmetry.

211. Assessing Spinal Motion at Different Fusion Levels in Adolescents with Idiopathic Scoliosis

Mary Riordan, BA; Sahar Hassani, MS; Adam Graf; Joseph Krzak, PT; Peter Sturm, MD; Kim Hammerberg, MD; Purnendu Gupta, MD; Gerald F. Harris, PhD

USA

3D motion capture was used to study the impact of spinal fusion on range of motions in adolescents with idiopathic scoliosis. Significant range of motion was lost in all three planes. Fusions to L4 caused greater range of motion loss in forward/backward bending than those who were fused to L3 or L2 and above. This information can be useful in determining the last instrumented vertebrae.

212. Surgery for Adolescent Idiopathic Scoliosis (AIS): Two Steps Forward, One Step Back for Coronal Plane Correction

Umit Guler, MD; Yasemin Genc, PhD; Emre Acaroglu, MD

Turkey

This study aimed to analyze the results of controlled trials (CT) on surgical treatment of AIS published over 30 years, and compare the results of these CTs with each other for coronal correction.

215. Pelvic Tilt and Trunk Inclination: New Predictive Factors in Curve Progression During the Milwaukee Bracing for Adolescent Idiopathic Scoliosis

Jing Guo; Zhen Liu; Feng Lv; Zezhang Zhu; Bangping Qian; Xing Zhang; Xiaolong Lin; Xu Sun; Yong Qiu

China

A retrospective radiographic and clinical study to evaluate the relation between initial spinopelvic morphology and the success of treatment of adolescent idiopathic scoliosis with the Milwaukee brace.

216. Correlates of Height Loss and Surgical Height Gain in Adolescent Idiopathic Scoliosis

Saihu Mao; Leilei Xu; Zhen Liu; Xu Sun; Bangping Qian; Zezhang Zhu; Jacky Cheng; Yong Qiu

China

Height loss secondary to scoliosis and surgical height gain are seldom evaluated previously. This retrospective study identified that Cobb angle, CL, and NVC are strong determinants of the height loss in AIS, and meanwhile proved that previous height correction equations employing only Cobb angle are relatively unreasonable and inaccurate in determining the total height loss. In addition, the major determinant for surgical height gain is pre-op Cobb angle and reduced magnitude of Cobb angle, but not correction rate.

217. The Height Gain in Scoliotic Deformity Correction: Assessed by New Predictive Formula

Ahmet Y. Sarlak, MD; Halil Atmaca, MD; Resul Musaoglu, MD; Elsen V. Veliev, PhD

Turkey

There have been previous formulas curvilinearly correlating trunk height loss to the angulation of the primary curve. None of these formulas however had been confirmed clinically with respect to height gain in surgically corrected curves to our knowledge. The purpose of this study is to analyze a new formula to predict height gain after scoliotic deformity correction taking into account the contribution of new variables (apical vertebral translation, number of instrumented segments, disc heights) to increase accuracy which has not been used on previous formulas.

218. Return to Sports After Surgery to Correct Adolescent Idiopathic Scoliosis: A Survey of the Spinal Deformity Study Group

Ronald A. Lehman, MD; Daniel G. Kang, MD; Lawrence G. Lenke, MD; Daniel J. Sucato, MD, MS; Spinal Deformity Study Group

USA

Participation in sports and athletic activities by children and adolescents has become an important aspect of society, and is a frequent question following surgery for adolescent idiopathic scoliosis. We found that modern posterior instrumentation allows surgeons to recommend earlier return to sports, with the majority allowing non-contact and contact sport at 6 months and collision sports at 12 months.

219. Proximal Adding-On phenomenon after Anterior Selective Fusion for Lenke type 5C Idiopathic Scoliosis: Incidence and Risk Factors

Ding Qi; Yong Qiu; Xu Sun; Bin Wang; Zezhang Zhu; Yang Yu; Feng Zhu
China

The present study is to investigate the incidence and related risk factors of proximal adding-on phenomenon after anterior selective fusion for Lenke type 5C adolescent idiopathic scoliosis (AIS).

220. Radiation Exposure in the Modern Treatment of Adolescent Idiopathic Scoliosis

Steven M. Presciutti, MD; Mark C. Lee, MD
USA

Radiation exposures for scoliosis patients differ significantly between treatment groups. Operative patients have strikingly greater radiation exposures than non-operatively treated patients and receive almost 99% of their radiation exposure during surgery.

221. Bending vs. Fulcrum vs. Traction X-Ray under General Anesthesia (TRUGA) for Evaluation of Flexibility of Curves and Prediction of Correction in Patients with Adolescent Idiopathic Scoliosis: Which is Better ?

Meric Enercan; Cagatay Ozturk, MD; Levent Ulusoy; Sinan Kahraman; Alauddin Kochai; Ahmet Alanay; Tunay Sanli, MA; Azmi Hamzaoglu, MD
Turkey

TRUGA reflects flexibility in severe MT curves better than F and BXR. TRUGA also has higher agreement with postoperative results.

222. Short Fusion Strategy using Pedicle Screw Constructs for Lenke Type 5 Adolescent Idiopathic Scoliosis

Eijiro Okada, MD; Eijiro Okada, MD; Morio Matsumoto, MD; Kota Watanabe; Naobumi Hosogane, MD; Yoshiaki Toyama
Japan

Retrospective study was conducted to assess the fusion area of posterior correction and fusion using pedicle screw constructs for the treatment of AIS patients with Lenke type 5. Since radiographic parameters and SRS 22 were equivalent between the two groups, selection of UIV at one level below EV can be a reasonable alternative to the conventional end-to-end fusion strategy in posterior correction surgery for Lenke type 5 curves.

223. Is DVR a Myth? Direct Vertebral Rotation vs. Simple Rod Rotation in Treatment of Rigid Scoliosis

Arvind Jayaswal, MS (Ortho); Pankaj Kandwal, MS (Ortho); Upendra Bidre, MS; G. Raghavan, MS (Ortho); M. Subhash, MS (Ortho)
India

Traditionally Rod Rotation technique has been a favored technique used for achieving deformity correction.

224. Single Center Analysis of Anterior Scoliosis Surgery for Selective Thoracic Fusion in >250 AIS. Analysis of Efficacy, Restoration of Thoracic Kyphosis and Prediction of Spontaneous Lumbar Curve Correction

Heiko Koller, MD; Oliver Meier, MD; Heidrun Albrecht; Juliane Zenner, MD; Michael Mayer, MD; Wolfgang Hitzl, PhD, MSc
Germany

A single-center radiographic and clinical study on the efficacy of anterior instrumented scoliosis correction and fusion (AISF) for selective thoracic fusion of AIS was performed. Results in 273 pts show that AISF is an efficient treatment for the correction of scoliosis and restoration of sagittal balance in AIS patients: At follow-up, only 6% of patients showed hypokyphotic thoracic alignment, spontaneous lumbar curve correction is predictable and complication rate is low.

225. Shoulder Balance after Corrective Fusion Surgery for Thoracic Adolescent Idiopathic Scoliosis: How can we Prevent Shoulder Imbalance?

Kei Watanabe, MD, PhD; Toru Hirano; Tomohiro Izumi; Atsuki Sano; Naoto Endo, MD, PhD; Kazuhiro Hasegawa, MD, PhD
Japan

Shoulder balance of patients with T-AIS was evaluated after scoliosis surgery with a minimum 2-year follow-up. T-AIS patients demonstrated a tendency of left shoulder elevation after corrective surgery, which was affected by massive correction of main thoracic curve and the balance of curve magnitude between upper and main thoracic curve.

226. Are More Screws Better? A Systematic Review of the Implant Density and Curve Correction in AIS

A. Noelle Larson, MD; Carl-Éric Aubin, PhD, PEng; David W. Polly, MD; Charles Gerald T. Ledonio, MD; Baron S. Lonner; Suken A. Shah, MD; Daniel J. Sucato, MD, MS; Lawrence G. Lenke, MD; B. Stephens Richards, MD; Mark A. Erickson, MD; John B. Emans, MD; Stuart L. Weinstein, MD; Minimize Implants Maximize Outcomes Study Group
USA

Wide variability exists in the number of implants used for AIS surgery, ranging from 1.04 to 2.0 anchors per level fused. Studies reporting on high- vs. low-density screw constructs are underpowered to detect a difference in curve correction and have not demonstrated improved curve correction or patient-reported outcomes with high screw density patterns.

227. Use 1/2 body Weight Push-Traction Film (PTF) to Assess Flexibility in Adolescent Idiopathic Scoliosis in Structural Thoracic and Thorocolumbar/Lumbar Curves and Compensary Curves

Ming Li; Zi-Qiang Chen, MD; Chuan-Feng Wang
China

A perspective study for the use of 1/2 body weight PTF to assess flexibility in adolescent idiopathic scoliosis comparing with Supine side bending, Suspension and Fulcrum bending film.

E-POSTER INDEX

228. EOS 3D Analysis of Adolescent Idiopathic Scoliosis Treated by Posteromedial Translation

Brice Ilharreborde, MD; Wafa Skalli, PhD; Keyvan Mazda

France

Low-dose biplanar radiographs are now available in routine clinical use. They provide 3D reconstructions that can help analyzing the postoperative correction in children with AIS. Posteromedial translation with concave sublaminar bands successfully restored sagittal alignment and allowed substantial detorsion of the main curves, while leaving the adjacent unfused segments in appropriate position.

229. Posterior Spinal Fusion (PSF) for Adolescent Idiopathic Scoliosis (AIS) using Low Implant Density Index (IDI) based on a New Surgical Algorithm: Validation & Review of 177 Cases with Minimum Follow-Up of Two Years

Nanjundappa S. Harshavardhana, MS(Orth), Dip. SICOT; Fady S. Sedra; Farhaan Altaf, MBBS, BSc, MRCS; Babur Mahmood, MSc, MRCS; Hazem B. Elsebaie, FRCS, MD; Hilali H. Noordeen, FRCS
United Kingdom

Posterior spinal fusion (PSF) using Lenke's classification (& its 54 curve variations) is popular in treatment of AIS. A simple algorithm with just 6 curve types that also aided in choosing fusion levels and which also addressed shoulder balance was used in 177 consecutive AIS patients. The surgical results with a minimum follow-up of two years with special reference to implant and cost density indices (IDI&CDI) are presented. Reduced implant density with significant cost savings did not compromise our clinical results.

230. Restoring Thoracic Kyphosis by Simultaneous Translation on Two Rods and the Impact on Spinal Alignment

Dennis P. Devito, MD; Andrew G. King, MBChB, FRACS; Mark B. Willits, MD; Afshin Aminian, MD; Virginie Lafage, PhD

USA

Surgical correction of the spinal deformity in AIS via Simultaneous Translation on 2 Rods (ST2R) restores thoracic kyphosis.

231. Can Kyphosis Type be a Predictor for Axial Plane Correction in AIS?

Dennis P. Devito, MD; Andrew G. King, MBChB, FRACS; Mark B. Willits, MD; Afshin Aminian, MD; Virginie Lafage, PhD

USA

Analysis of 3D surgical correction in 53 AIS patients revealed less axial correction of the apical vertebra when thoracic hypo-kyphosis was present preoperatively.

232. Optimism: A Key to Post Operative Pain Management in Adolescent Idiopathic Scoliosis

Felipe Rossel, MD; Jean A. Ouellet, MD; Neil Saran, MD, MHSc, FRCS; Teresa Valois Gomez, MD

Canada

Using the validated Children's Attribution Style Questionnaire, we prospectively explored the association between preop optimism and post op pain in 21 patients with AIS undergoing posterior spinal fusion. We found a significant inverse correlation between levels of optimism and PCA consumption. Identifying patient related factors in the pre-operative period that have an impact in post-operative outcomes provides new areas for the development of interventions (coping strategies, analgesia tutorials) to help patients in the peri operative period.

233. Abnormal Bone Quality in Osteopenic Adolescent Idiopathic Scoliosis Girls - A Case-Control Study

Wing Sze Yu, Bachelor of Science; Ka Yan Chan; Fiona WP Yu, BSc (Advanced); Kwong Man Lee, PhD; Bobby KW Ng, MD; King Lok Liu; Tsz-ping Lam, MB, BS; Jack C. Cheng, MD; Zezhang Zhu
China

Adolescent Idiopathic Scoliosis was associated with osteopenia. In this study, we evaluate bone quality and compare their correlation with osteopenia in AIS and non-AIS controls. It is found that the bone quality in osteopenic AIS patients was uniquely different from that of osteopenic non-AIS controls. Alterations in the trabecular compartment in association with osteopenia were only present in AIS subjects, including lower measurements in trabecular vBMD, bone volume to tissue volume and trabecular thickness.

234. Screening MRI in AIS Patients Should be Standard of Care

Edgar D. St. Amour, MSc; Richard E. McCarthy; Jason M. Rogers, MD

USA

We reviewed screening MRI for neuro-axis (N-A) abnormality in 248 consecutive patients with AIS that underwent spinal deformity correction. 15% of all of these patients had an MRI diagnosed N-A abnormality, which is significant since 34% of those with anomalies (5% of all patients) required neurosurgical (NSGY) intervention. Therefore, this study provides strong evidence that screening MRI should be a standard of care for all patients.

235. Sagittal & Coronal Plane Decompensation: Comparison of 52 Lenke 1 AIS Patients Treated with Second Generation ASF vs. PSF Techniques Two Years Post-Op

Lynn J. Leitko, MD; Michael Ruf, MD; Jurgen Harms, MD

Germany

Initial coronal plane correction is equivalent using 2nd generation ASF and PSF operative techniques to treat Lenke 1 AIS. Thoracic sagittal plane correction was statistically greater in the anterior group. There was no statistically significant difference in sagittal or coronal plane decompensation between the 2 groups after comparison of first erect (FE) x-rays to 2 yr follow-up. Change in FE to 2 year post-op proximal junctional kyphosis (PJK) was statistically significant between the group. The anterior group became more lordotic proximally.

236. Low Pre-Operative SRS-22 Scores Predict Poor Post operative Outcome in AIS

Jahangir Asghar, MD; Harry L. Shufflebarger, MD; Timothy D. Uschold, MD; Robert P. Norton, MD; Rafaela Solano, RN
USA

Using a multi-center prospective database, an analysis of 921 patients assessing predictors for poor SRS-22 outcome scores, defined as 2 Standard deviations below the mean in each domain, was performed. Our study found that lower pre-operative SRS score and a high BMI were associated with poor post-operative outcomes. Given this finding, pre-operative counseling to this cohort may be indicated.

237. In Mature Patients with Primary Thoracolumbar AIS, Does the 50 Degree Operative Threshold Apply?

Burt Yaszay, MD; Tracey Bastrom, MA; Carrie E. Bartley, MA; Peter O. Newton, MD; Harms Study Group
USA

Patients with major thoracolumbar curves frequently undergo surgical treatment with curves below the traditional 50 degree threshold. Patients who choose surgery with a curve <50 were compared to a group of non-op patients with curves <50 and an operative group with curves of 50-60 degrees. Surgical cases with a curve <50 have larger preop trunk shift with less balanced thoracic and lumbar curves resulting in a lower self-image outcome scores.

239. Is There Influence of Preoperative Brace Treatment on the Correction Results in Female Adolescent Idiopathic Scoliosis?

Bin Yu, MD; Yipeng Wang, MD; Jianguo Zhang, MD; Jianxiang Shen, MD; Guixing Qiu
China

We compare the correction results of 2 matched groups of AIS patients, one with preoperative brace treatment and the other not. The results showed that there was no significant difference between the 2 groups. So, we made the conclusion that preoperative brace treatment didn't have obvious influence on the correction results of the MT curve in female AIS patients.

240. Does Proximal Implants Cause Junctional Kyphosis In Adolescent Idiopathic Scoliosis?

Ali Sehirlioglu; Omer Ersen; Serkan Bilgic, MD; Erbil Oguz; Burak Bilekli; Tolga Ege
Turkey

In this study, we aimed to assess the incidence of junctional kyphosis caused by implants at proximal instrumentation levels and which kind of implants cause junctional kyphosis in adolescent idiopathic scoliosis patients. 129 patients with at least two years of follow up radiographies were included to the study. Hooks were used at 54 patients (41 female, 13 male) and screws were used at 57 patients (43 female, 14 male) at the most proximal level. Using transpedicular screws at most proximal instrumentation levels can be addressed as a risk factor for junctional kyphosis in adolescent idiopathic scoliosis patients.

241. The True Patho-Anatomy of the Rib Hump in Adolescent Idiopathic Scoliosis

Silpa Reddy; Robert M. Campbell, MD; Sriram Balasubramanian, PhD
USA

CT scan analysis of normal and scoliotic thoraces supports the hypothesis that the rib hump in AIS is mostly a positional deformity of the ribs, not a posterior angular deformity of individual ribs. This suggests that alternatives to thoracoplasty should be considered that address the true patho-anatomy of the rib hump, improving thoracic appearance, volume, and function.

242. Are Pedicle Screw Constructs Really More Expensive than Hybrid Constructs?

Christopher Lee, BS; David L. Skaggs, MD; Le-qun Shan, MD; Lindsay Andras, MD; Karen S. Myung, MD, PhD
USA

In order to judge if new technology is worth increased initial expense, a financial analysis of complications over time should be assessed. In our opinion, the markedly decreased revision rate with all pedicle screw constructs compared to hybrid constructs are worth a 7.2% increase in spinal implant charges.

The FDA has not cleared the drug and/or medical device for the use described in this presentation (i.e., the drug or medical device is being discussed for an 'off label' use).

243. Thoracic Volume Predicts Pulmonary Function Recovery in Scoliosis Patients

David W. Polly, MD; Benjamin Rosenstein, B.Bm.E; Charles Gerald T. Ledonio, MD; Charles E. Johnston, MD; David J. Nuckley, PhD
USA

Computational modeling of thoracic volumes in AIS patients was found to be correlated with improved PFTs after surgical correction of spine deformity.

244. Outcomes of Adolescent Idiopathic Scoliosis Using Pedicle Screw Only Constructs with a Minimum of Five Years of Follow-Up

Steven W. Hwang, MD; Amer F. Samdani, MD; Michelle C. Marks, PT, MA; Tracey Bastrom, MA; Hitesh Garg, MD; Baron S. Lonner; Joshua M. Pahys, MD; Suken A. Shah, MD; Firoz Miyani, MD, FRCSC; Harry L. Shufflebarger, MD; Peter O. Newton, MD; Randal R. Betz, MD
USA

Five year follow-up on 117 patients with pedicle screw only constructs displayed maintenance of radiographic improvement. Similarly, SRS scores of self-image and satisfaction were maintained at 5 years. However, SRS total scores were slightly lower between 2 and 5 years due to decreases in the domains of pain and mental health. Overall, improvements in SRS and radiographic parameters were maintained at 5 years of follow-up.

E-POSTER INDEX

245. Amount of Coronal Correction in AIS Patients following Posterior Column Osteotomies: An Intraoperative Radiographic Study

Yang Xu, MD, PhD; Lawrence G. Lenke, MD; Michael P. Kelly, MD; Linda Koester, BS; Brenda A. Sides, MA
USA

We reviewed 23 AIS patients undergoing PCOs with a minimum 2-year follow-up. Intraoperative radiographic analysis showed an average of 22% of the total coronal Cobb correction was from the PCOs, 31% from prone positioning, and 47% from actual instrumentation placement.

247. Assessment of Spinal Curvature Flexibility by Traction in Adolescent Idiopathic Scoliosis (AIS)

Ken Yamazaki, MD; Takemi Shimaya
Japan

This study investigated factors that affect flexibility of the spinal curvature in AIS. This study evaluated a total 113 consecutive patients with AIS. Standing and traction radiographs were obtained before surgery. The traction flexibility rate (TFR) was significantly lower in male patients, those over 18 years old, types 2 and 3 on Lenke's classification, and in those with a pre-op Cobb angle over 70 degrees. Post-op correction rate (CR) was obviously higher than the pre-op TFR.

248. Decomensation after Posterior Selective Thoracic Fusion in Lenke type B,C Lumbar Modifier Adolescent Idiopathic Scoliosis: Is it Frequent?

Mario Di Silvestre, MD; Georgios Bakaloudis; Francesco Lalli
Italy

We retrospectively reviewed 45 patients affected by AIS (Lenke type 1, 2, 3, 4) with lumbar modifier B (24 cases) and C (21) to determine the efficacy of posterior selective thoracic fusion.

Our result showed that thoracic fusion in Lenke type B,C curves (pedicle screw only instrumentations) ensures satisfactory results. Lumbar spontaneous correction occurs mainly due to upper lumbar vertebra's tilt amelioration. A mild decomensation of the lumbar secondary curve (20% of cases) has been found to be well tolerated.

249. Clinically Orientated Classification for the Surgical Treatment of Adolescent Idiopathic Scoliosis

Farhaan Altaf, MBBS, BSc, MRCS; Zaher Dannawi, FRCS (Tr & Orth); Hazem B. Elsebaie, FRCS, MD; Hilali H. Noordeen, FRCS
United Kingdom

We describe a classification for adolescent idiopathic scoliosis with two components which include the curve type and shoulder level and accordingly suggest a treatment algorithm. No previously described classification system has taken shoulder imbalance into account, despite its importance as a clinical parameter and outcome measure.

250. Posterior, Single Approach, Two or Three incision Mini Open Correction and Fusion for AIS

Matthew J. Geck, MD; Devender Singh, PhD; Dana Hawthorne, BS, MPAS; Anthony S. Rinella, MD; Eric Truumees, MD
USA

Minimally invasive surgical (MIS) techniques have expanded to include correction of scoliosis. At one institution, outcomes of MIS/mini-open techniques for adolescent (AIS) reconstruction were evaluated at 6-36 month follow up.

251. Radiological Results of Derotation using All Pedicle Screw Constructs in Adolescent Idiopathic Scoliosis

Yutaka Sasao, MD, PhD; Yoshiaki Torii; Atsushi Kojima; Shigeta Marioka
Japan

Thirty-two cases of adolescent idiopathic scoliosis (AIS) were corrected with direct vertebral derotation (DVR) using all pedicle screw (APS) constructs and a 5.5-mm titanium alloy rod without using linked constructs. Correction rates for the main Cobb angle and apical vertebra body (AVB) were excellent. However, the correction rate for apical vertebral rotation (AVR) was not as good as Suk et al's data.

253. Bone Density Values Compared with Cobb Angles in AIS Patients: Does the Use of a Brace have an Effect on Bone Density?

Mehmet B. Balioglu, MD; Can H. Yildirim, MD; Aytac Akbasak, MD; Erol - Tasdemiroglu
Turkey

We investigated the relationship between Cobb angles and bone density in AIS patients and the use of a brace in treatment.

254. Risk Factors of Postoperative Shoulder Asymmetry in Lenke I Adolescent Idiopathic Scoliosis Following Posterior All Pedicle Screws Instrumentation and Fusion

Ming Li; Chuan-Feng Wang; Zi-Qiang Chen, MD
China

To analyze risk factors of postoperative shoulder asymmetry (PSA) in Lenke I adolescent idiopathic scoliosis (AIS) following posterior all pedicle screws instrumentation and fusion.

E-POSTER INDEX

255. Determining Optimal Post-operative Coronal Parameters for Selective Thoracic Fusion

Burt Yaszay, MD; Jahangir Asghar, MD; Tracey Bastrom, MA; Amer F. Samdani, MD; Peter Sturm, MD; Randal R. Betz, MD; Harry L. Shufflebarger, MD; Peter O. Newton, MD; Harms Study Group
USA

Recommendations for selective thoracic fusion should be developed with optimal post-op parameters set as the desired goal. These parameters as derived from data query and surgeon survey and supported by SRS outcomes scores include a lumbar Cobb $< 26^\circ$, balanced within 2 cm, a DFQ of 4, a lumbar correction $> 37\%$ and a trunk shift within 1.5 cm.

256. Do Pedicle Screws Really Save a Level in AIS? An Analysis of the Contemporary Surgical Treatment of Lenke 1 Curves and the Trend to Fuse More Proximal Levels

Suken A. Shah, MD; Tracey Bastrom, MA; Baron S. Lonner; Burt Yaszay, MD; Peter O. Newton, MD; Harms Study Group
USA

This study demonstrated a significant movement to a higher UIV over time as surgeons recognized the consequence of better correction of the main thoracic curve was aggravation of shoulder balance.

257. Does the Intra-Operative Tranexamic Acid Decrease Operative Blood Loss During Posterior Spinal Fusion for Treatment of Adolescent Idiopathic Scoliosis?

Mitsuru Yagi, MD, PhD; Shinjiro Kaneko; Kentaro Fukuda; Masafumi Machida, MD
Japan

High dose TXA treatment for the posterior spinal fusion to the patient with adolescent idiopathic scoliosis lost significantly less blood and received significantly fewer blood transfusions than the control groups without significant differences in intra- and post-operative complications. A multicenter randomized prospective comparative analysis will provide additional information of the efficacy and safety of TXA.

258. Cervical Spine Sagittal Alignment in Adolescent Idiopathic Scoliosis and Impact of Surgical Correction of Thoracic Hypo Kyphosis

Jean-Luc Clement, MD; Martin Schramm, MD; Anne M. Geoffroy, MD; Fatima Yagoubi, MSc
France

Scoliotic patients are more likely to present an abnormal cervical sagittal alignment which is correlated with their preoperative thoracic kyphosis (TK). The correction of the thoracic kyphosis may help the restoration of a cervical lordosis.

259. Sagittal Alignment of the Cervical Spine in Adolescent Idiopathic Scoliosis Treated by Posteromedial Translation

Brice Ilharreborde, MD; Wafa Skalli, PhD; Keyvan Mazda
France

Posteromedial translation using sublaminar bands safely and effectively restores thoracic kyphosis, and significantly improves cervical sagittal alignment. To the authors' knowledge, this is the first study reporting significant change in the postoperative sagittal alignment of the cervical spine, which might not be as rigid as previously suggested in AIS.

261. Evaluation of Patients' Outcomes using SRS Outcomes Instrument (SRS-22), Short Form-36 (SF-36), Beck Depression Second Edition (BDI-2) and Radiologic Results in Idiopathic Scoliosis (AIS) Patients

Takemi Shimaya; Ken Yamazaki, MD
Japan

112 AIS patients (age ≥ 18 , follow-up period ≥ 2 years) completed SRS-22, SF-36, and BDI-2 surveys. It is noted that both correction of spinal deformity and evaluation of depressive states with subsequent psychological treatment could improve patients' outcomes.

262. A Comparative Study between Thoracoscopic Surgery and Posterior Surgery using All-Pedicle-Screw Constructs in the Treatment of Adolescent Idiopathic Scoliosis

Chongsuh Lee, MD, PhD; SeJun Park; Sungsoo Chung; Kyung-Chung Kang; Jun Hee Kang; Jong hyuk Lee; Philsoo Kim
Republic of Korea

Thoracoscopic scoliosis correction has more frequent perioperative pulmonary complications and fixation problems compared to posterior pedicle screw fixation. Thus, it should be utilized in selected cases particularly in cases of patient's strong need for minimally invasive surgery.

263. Efficacy of Anterior Scoliosis Correction and Fusion in the Treatment of Main Thoracic Curves and Restoration of thoracic Kyphosis. A Study of 273 Patients with AIS

Heiko Koller, MD; Juliane Zenner, MD; Oliver Meier, MD; Heidrun Albrecht; Michael Mayer, MD; Wolfgang Hitzl, PhD, MSc
Germany

Failure to restore sagittal balance in adult deformity surgery was shown to have adverse impact on clinical outcomes. Accordingly, interest in the restoration of a physiologic sagittal alignment in treatment of AIS increased. The current study focused on restoration of thoracic kyphosis using anterior instrumented correction and fusion. At follow-up > 24 months, TK had improved from $19 \pm 12.6^\circ$ to $27 \pm 11^\circ$ at follow-up. No pt showed a symptomatic PJK. AISF is an efficient treatment for selective fusion of AIS, particularly regarding restoration of sagittal balance.

E-POSTER INDEX

264. Anterior Arthrodesis with Autologous Rib Grafting after Thoracoscopic Fusion & Instrumentation for Adolescent Idiopathic Scoliosis (AIS): Evaluation of 55 Patients Followed Up For a Minimum of Two Years

Lalit Sharma, MS (Ortho); Gabriel Liu, MSc, FRCS(Orth); Hee-Kit Wong
Singapore

We report the long term radiographic results of thoracoscopic anterior instrumented fusion for Adolescent Idiopathic Scoliosis (AIS) using autologous ribs as graft material in 367 disc spaces of 55 patients, followed up for average 41.7 months. A scoring system for interbody fusion based on the presence of bridging trabeculi and the magnitude of endplate reaction is described. Better fusion was observed in the central part of the curve and fusion rates improved with longer follow-up.

265. Evaluation of the Sagittal Profile in Patients with Thoracic Adolescent Idiopathic Scoliosis (AIS) Lenke Type 1 Following Posterior Correction

Michael Akbar, MD; Bernd Wiedenhofer, MD
Germany

The evaluation of patients with thoracic adolescent idiopathic scoliosis after posterior correction shows that the sagittal profile needs to be addressed by adding techniques for lengthening of thoracic column such as Ponte osteotomies.

266. The Ponte Osteotomy Improves Coronal and Sagittal Plane Correction in Thoracic Adolescent Idiopathic Scoliosis

Suken A. Shah, MD; Arjun A. Dhawale, MD; Jon E. Oda, MD; Petya Yorgova, MS; Geraldine I. Neiss, PhD; Laurens Holmes, PhD, DrPH; Peter G. Gabos, MD
USA

The role of multilevel Ponte osteotomies (PO) in achieving correction of major thoracic curves in adolescent idiopathic scoliosis (AIS) with pedicle screw instrumentation (PSI) has not been well described. We report the results in 87 patients who underwent PO and PSI for major thoracic AIS curves. Coronal and sagittal Cobb correction improved. In hypokyphotic curves, a mean 10° increase in kyphosis was observed. But, the surgeon should be prepared for possible increased operative time, blood loss and neuromonitoring signal changes.

267. Superior Mesenteric Artery Syndrome in Scoliosis Idiopathic

Mariano O. Reynier, MD; Carlos A. Tello, MD; Ida Alejandra Francheri Wilson, MD; Mariano A. Noel, MD; Eduardo Galaretto, MD; Maria Selva Vallejos Arce, MD; Romina Corrado, MD; Gaston Eljore, MD; Nicolas Coombes, MD; Ernesto Bersusky, MD
Argentina

To sonographically assess the pre and post-op mesenteric aortic angle in patients with idiopathic scoliosis, and look for changes after the surgical correction.

268. Should a Hand Radiograph be Added to the Systematic Follow up of AIS?

Marie-Lyne Nault, MD, MSc; Jean-Marc Mac-Thiong, MD, PhD; Marjolaine Roy-Beaudry, MSc; Isabelle Turgeon; Hubert Labelle, MD; Stefan Parent, MD, PhD
Canada

A prospective cohort of 113 AIS patients was followed for 33 months. Different bone age measurements on hand and spine radiographs failed to identify a specific stage associated to the rapid curve progression phase. A systematic hand radiograph is not recommended for AIS follow up.

269. Fusion to L3 vs. L4 for Double Major Adolescent Idiopathic Scoliosis: Predictive Factors for a Successful Result Are Dependent on Both Preoperative and Postoperative Parameters

Daniel J. Sucato, MD, MS; Anna M. McClung, RN; Christine Masuda
USA

This study analyzes a single institution experience with double major AIS and the ability to determine whether the distal fusion level should be L3 or L4 and demonstrates some defineable criteria to assist in correction fusion level selection to achieve a successful result.

270. Pre-Operative Magnetic Resonance Imaging of the Lumbar Spine in Adolescent Idiopathic Scoliosis: The Incidence of Pre-existing Degenerative Changes

Firoz Miyani, MD, FRCSC; Michael D. Selby, MBBS FRACS; Sumit K. Gupta, MD, FRCSC; Amer F. Samdani, MD; Peter O. Newton, MD
Canada

Low back pain in AIS is a relatively common complaint, however limited data exists on the radiological incidence of pre-operative degenerative disc disease in this population. This cross-sectional, observation study demonstrated that the rate of lumbar spine degenerative changes as evaluated on MRI in AIS pre-operatively is low (19.6%) despite back pain being a common indication for the scanning. The implications of adjacent segment concerns following a spinal fusion for deformity therefore should be cautiously observed.

271. Post-Operative Pain Management after Spinal Fusion Surgery

Julie Legakis, PhD; Jillian Tweedie; YoungKey Chung, MA; Patricia BeVier; Ronald L. Thomas, PhD; Suresh T. Thomas, MD; Richard A. Reynolds, MD
USA

The results of a three-year retrospective analysis of patients who underwent spinal fusion surgery for correction of scoliosis curvature are described, evaluating whether addition of continuous infusion of local anesthetics (CILA) to a multimodal pain management protocol reduces pain and opioid use of adolescent idiopathic scoliosis (AIS) surgery patients. Specifically, we found that patients additionally treated with CILA experience less pain and use less opioid analgesics, compared with those without local anesthetic infusion.

272. The Effect of Anterior Mobilization in a Two-Stage Correction of Rigid Idiopathic Thoracic Scoliosis*Michael Ruf, MD; Lynn J. Letko, MD; Thomas Welk, MD; Jurgen Harms, MD**Germany*

The anterior release increases mobility and restores the balance between anterior and posterior column length. A spontaneous correction of scoliosis as well as hypokyphosis even in rigid curves was observed following the anterior release. The results of the second surgery (posterior instrumentation and fusion) in cases of marked rigidity and hypokyphosis are improved.

273. Posterior Correction of Thoracic AIS with Pedicle Screw Instrumentation. Clinical and Radiological Results of 50 Patients with a Ten Year Follow-Up*Kan Min, MD; Christoph Szzy, MD; Mazda Farshad, MD, MPH**Switzerland*

Posterior correction of thoracic AIS with pedicle screw instrumentation (n=50) achieves a stable long-term (10y) correction with a good patient satisfaction.

274. Sagittal Alignment after Corrective Fusion Surgery for Adolescent Idiopathic Scoliosis: Can Cervical Lordosis be Achieved?*Kei Watanabe, MD, PhD; Toru Hirano; Tomohiro Izumi; Atsuki Sano; Naoto Endo, MD, PhD; Kazuhiro Hasegawa, MD, PhD**Japan*

The sagittal plane change including cervical contour of AIS patients was evaluated after scoliosis surgery with a minimum 2-year follow-up. AIS patients definitely demonstrated cervical malalignment pre- and postoperatively. Scoliosis surgeon pay attention to also sagittal plane restoration postoperatively especially for thoracic kyphosis, which may allow to achieve cervical lordosis.

275. Gender Differences on Curve Pattern and Other Radiographic Characteristics in Adolescent Idiopathic Scoliosis*Weijun Wang; Zezhang Zhu; Feng Zhu; Zhiwei Wang; Xu Sun; Yong Qiu**China*

Radiographic characteristics were compared between male and female AIS. Male patients showed higher incidence of atypical curve patterns, and higher risk of main thoracic curve progression than females. In major thoracic AIS with typical curve patterns, males had larger curve severity, thoracic kyphosis and lower average flexibility, than females.

276. Clinical Outcomes of Bracing for Idiopathic Scoliotic Patients undergoing Pubertal Growth Spurt*Saihu Mao; Yong Qiu; Xu Sun; Zhen Liu; Zezhang Zhu; Bangping Qian; Feng Zhu**China*

Bracing for IS patients undergoing pubertal growth spurt was seldom reported previously. This prospective longitudinal study evaluated the linear growth and bracing effectiveness of pre-pubertal IS patients. The results revealed that timing of PHV, Risser 0 with semi-closed or closed triradiate cartilage and Risser 1 are highly associated with the curve acceleration phase in IS, which was in line with higher ratio of failed brace treatment observed.

277. Evaluation of 3D Reconstruction of the Rib Cage for Scoliotic Patients*Aurélien Courvoisier, MD MSc; Brice Ilharborde, MD; Barbara Constantinou; Benjamin Aubert, MSc; Raphael Vialle, MD, PhD; Jean Dubousset; Wafa Skalli, PhD**France*

Evaluation of the rib cage clinical parameters would be helpful for the management of spinal deformities. 3D reconstruction of the rib cage by means of the EOS-System has been recently validated in non scoliotic patients.

278. Thoracic Pedicle Screw Placement Using Preoperative CT-Based Navigation in Consecutive 80 Patients with Idiopathic Scoliosis*Yujiro Takeshita; Katsushi Takeshita, MD; Takashi Ono, MD**Japan*

The accuracy of thoracic pedicle screw placement using preoperative CT-based navigation (CTBN) was evaluated from reconstructed CT in 80 consecutive idiopathic scoliosis patients. Out of the total 843 screws, 780 (92.6%) screws were placed in acceptable position.

279. Prediction of Spontaneous Lumbar Curve Correction after Selective Thoracic Fusion of AIS. An Outcome Study in 273 Patients using Anterior Instrumented Scoliosis Correction and Fusion*Heiko Koller, MD; Juliane Zenner, MD; Michael Mayer, MD; Oliver Meier, MD; Heidrun Albrecht; Wolfgang Hitzl, PhD, MSc**Germany*

The authors performed a radiographic study on 273 pts undergoing selective thoracic fusion using anterior instrumented correction and spinal fusion for the treatment of main thoracic AIS. The large single-center data assessment allowed calculation of multivariate models yielding for an improved prediction of spontaneous lumbar curve correction. Stratification of the study sample in lumbar curves $</>20^\circ$ at follow-up and application of a clinically suitable model yielded in a high accuracy in prediction of SLCC ($1\pm 4.5^\circ$) in an independent test sample.

E-POSTER INDEX

280. Is Interval Halo-Femoral Traction Safe and of Measurable Benefit in Staged Scoliosis Correction Surgery?

Sean G. Grannum, MBBCh; FRCS; Adrian Gardner, BM, MRCS, FRCS (T&O); Jonathan B. Spilsbury, FRCS(Orth); David S. Marks, FRCS
United Kingdom

The use of staged anterior spinal release, interval halo-femoral traction and posterior correction for severe scoliosis has proven to be a safe, reproducible technique with good maintenance of correction and no neurological deficits during either traction or posterior correction.

281. The Effect of Proximal Thoracic Curve on Selective Thoracic Fusion with Video-Assisted Thoracoscopic Surgery in Adolescent Idiopathic Scoliosis

Do Yeon Kim, MD; Sang-Bum Kim; Eun-Su Moon, PhD; Jin Oh Park, MD, PhD; Hyon Su Chong; Jea-Woo Lim; Mary Ruth A. Padua, MD; Hak-Sun Kim, MD
Republic of Korea

To evaluate the effect of the proximal thoracic curve on not only shoulder imbalance but also T1 tilt aggravation in video-assisted thoracoscopic surgery in selective thoracic fusion of adolescent idiopathic scoliosis with VATS.

282. Hooks vs. Screws at the UIL of a Construct: What is the Impact on Sagittal and Axial Corrections?

Dennis P. Devito, MD; Andrew G. King, MBChB, FRACS; Mark B. Willits, MD; Afshin Aminian, MD; Virginie Lafage, PhD
USA

Hooks at the upper instrumented level (UIL) of the construct may have positive effects on the post-op sagittal profile, especially for hypo-kyphotic patients.

283. Pedicle Screw Instrumentation with Rod Derotation, Direct Vertebral Rotation(DVR) and Stiff Rod Results in Restoration of Thoracic Kyphosis in Single Thoracic Adolescent Idiopathic Scoliosis (AIS)

Se-Il Suk, MD; Jin-Hyok Kim; Sung-Soo Kim, MD; Dong-Ju Lim; Tai-Wan Kim
Republic of Korea

Pedicle screw instrumentation with rod derotation and DVR using stiff rods restored and maintained thoracic kyphosis in single thoracic AIS.

284. Validation of TAASQ, the Truncal Anterior Asymmetry Scoliosis Questionnaire

Baron S. Lonner; Courtney Toombs, BS; Suken A. Shah, MD; Tracey Bastrom, MA; Phedra Penn, MS; Kristin Bright, PhD; Carrie Scharf Stern, MD; Marjolaine Roy-Beaudry, MSc; Marie Beausejour; Stefan Parent, MD, PhD
USA

Evaluation of the impact of scoliosis on anterior trunk shape has been inadequately assessed, despite its importance to the patient. The Truncal Anterior Asymmetry Scoliosis Questionnaire (TAASQ) was developed and distributed to female, AIS surgical patients along with the SRS and SAQ. The TAASQ is a reliable and valid measure of concerns and behavioral modification related to anterior truncal appearance in adolescent female AIS patients.

285. A Comparative Analysis of Perioperative Complications in Patients Undergoing Spinal Fusion for Adolescent Idiopathic Scoliosis and Adolescent Scheuermann's Kyphosis

Dennis R. Knapp, MD; Karl E. Rathjen, MD; Raymund Woo, MD; Mark D. Rahm, MD; Terry R. Trammell, MD; Robert W. Gaines, MD; W. F. Hess, MD; Hani Mhaidli, MD, PhD; Francisco Javier Sánchez Pérez-Grueso; Thomas Ross, MS, RN; Mitsuru Yagi, MD, PhD; Oheneba Boachie-Adjei, MD; Complex Spine Study Group
USA

A retrospective analysis from a prospective multi-center database was done to compare perioperative complications of patients undergoing surgical management of Adolescent Idiopathic Scoliosis and Adolescent Scheuermann's Kyphosis.

286. Is There a "July Effect" in Surgery for Adolescent Idiopathic Scoliosis?

Jane S. Hoashi, MD, MPH; Patrick J. Cahill, MD; Randal R. Betz, MD; Tracey Bastrom, MA; Harms Study Group; Amer F. Samdani, MD
USA

The annual "changeover" of medical trainees has been shown to negatively impact patient care. As patient safety is of paramount importance in AIS surgery, we analyzed whether outcomes for AIS are affected by trainee involvement as first assistants as a function of the time of year. Surgical and clinical outcomes were consistent for all months, suggesting that during July and August, the months of resident transitioning, yields equal safety and outcomes as the other months.

287. Resource Utilization in AIS Surgery: Is There Opportunity for Cost-Savings?

Baron S. Lonner; Courtney Toombs, BS; Suken A. Shah, MD; Harry L. Shufflebarger, MD; John M. Flynn, MD; Peter O. Newton, MD
USA

Understanding variability in resource utilization by surgeons performing surgery for Adolescent Idiopathic Scoliosis may provide opportunity for increasing uniformity of care, thereby decreasing cost and increasing value. A multicenter, retrospective study of AIS surgical cases matched for age and gender revealed significant differences in resource utilization between surgeons, despite equivalent outcomes. Opportunities for cost-savings include implant usage, metal type, LOS and transition to IV analgesics.

288. CHAD Fragmentation as a Bio-Marker for Early Disc Degeneration in Scoliosis

Lisbet Haglund; Bashar Alkhatib; Peter J. Roughley; Jean A. Ouellet, MD
Canada

CHAD fragmentation is associated with disc degeneration in scoliosis.

This presentation is the result of a project funded, in part, by an SRS Research Grant.

289. Is There an Hypokiphotic Effect of Direct Vertebral Derotation in Posterior Fusion for Thoracic Adolescent Idiopathic Scoliosis?

Mario Di Silvestre, MD; Francesco Lalli; Georgios Bakaloudis; Francesco Vommaro; Angelo Toscano
Italy

52 patients affected by AIS, treated by posterior fusion, were reviewed to compare the effect on thoracic kyphosis of vertebral rotation correction. In 27 case (Pre-Rod group) the direct derotation procedure was done before inserting both rods, in 25 (Post-Rod group) the derotation was done after concave rod C-D rotation. The hypokyphotic effect of derotation procedure was avoided doing derotation after concave rod rotation.

290. Analysis of Risk Factors for Loss of Lordosis in Patients Who Had Surgical Treatment with Segmental Instrumentation for Adolescent Idiopathic Scoliosis

Per D. Trobisch, MD; Amer F. Samdani, MD; Randal R. Betz, MD; Tracey Bastrom, MA; Joshua M. Pahys, MD; Patrick J. Cahill, MD
USA

The study identified important risk factors for decrease of lumbar lordosis in patients who had surgical treatment for adolescent idiopathic scoliosis (AIS) with segmental pedicle screw instrumentation, including a high preoperative lumbar lordosis, surgical decrease of thoracic kyphosis, and factors attributable to a particular operating surgeon that were not quantified in this study.

291. Postoperative Dexmetomidine Improves Pain Control and Lowers Length of Stay in Patients Undergoing Posterior Spinal Fusion for Adolescent Idiopathic Scoliosis

M. W. Shrader, MD; John S. Jones, MD; Judson W. Karlen, MD; Gregory R. White, MD; Lee S. Segal
USA

This retrospective study demonstrated that the use of Dexmetomidine lowered narcotic use and length-of-stay in patients with adolescent idiopathic scoliosis undergoing posterior spinal fusion.

292. Deformity Correction Maneuvers (Rod Translation, Rod Derotation, and DVR) Do Not Produce Hypokyphosis in AIS Patients Treated with Pedicle Screw Instrumentation

Adam L. Wallowick, MD; Elliot Harmon; Jonathan J. Horn; Terry D. Amaral, MD; Yungtai Lo; Vishal Sarwahi, MD
USA

Previous studies have suggested that the use of pedicle screws in the surgical correction of AIS causes a loss of thoracic kyphosis. This study found that specific deformity correction maneuvers do not lead to hypokyphosis in AIS patients. The cause of hypokyphosis following AIS correction using pedicle screws is likely multifactorial, and other factors, such as rod bending, needs to be evaluated.

293. 3D Analysis of Brace Treatment in Idiopathic Scoliosis

Aurélien Courvoisier, MD, MSc; Xavier Drevelle; Raphael Vialle, MD, PhD; Jean Dubouset; Wafa Skalli, PhD
France

The effect of bracing in scoliosis has been evaluated in heterogeneous series and essentially in the frontal plane. However, the different curve topology and severity, different brace conceptions and designs should not be analysed together as it leads to controversial conclusions. There is lack of knowledge of the specific effect bracing on the 3D shape of the scoliotic curves.

294. Motion Analysis can Accurately Describe Curve Characteristics in Patients with Scoliosis

Matthew J. Solomito, MS; Mark C. Lee, MD
USA

Motion capture technology can accurately reproduce the SVA, CVA and major Cobb angle over a marker region in patients with adolescent idiopathic scoliosis (AIS) when compared to standing plain radiographs. Such technology may offer a radiationless method for both diagnosing and following scoliosis in patients with AIS.

295. Does Surgery and Surgical Technique Affect Patient Outcome in Thoracic Idiopathic Scoliosis?: Comparison of Anterior and Posterior Surgery with Non-Operated and Normal Controls

John Nathaniel M. Ruiz, MD, MRCS; Gabriel Liu, MSc, FRCS(Orth); Hee-Kit Wong
Singapore

Comparisons between posterior and thoracoscopic instrumentation for thoracic scoliosis, as well as with scoliosis and normal control groups were done to determine if surgery and surgical technique has any effect on patient-derived outcomes.

296. The Effect of Sport, Exercise and Lifestyle Factors on AIS Patients

Wendy Bertram; Emma M. Clark; Matthew Stenning, MBBS, MPhil, FRCS (T&O); Ian J. Harding, BA, BM, BCh, FRCS(Orth); Ian W. Nelson, MB, BS, MCh, Orth, FRCS
United Kingdom

It is unknown whether there is an association between sport/exercise and Cobb angle. Patients in the Bristol Secondary Care Scoliosis Cohort were asked about their attitude toward and participation in sport and exercise activities. Most participants had a positive attitude towards sport/exercise and participated at least once a week. Participation in swimming before the age of three showed a significantly lower Cobb angle compared with starting after age three or not swimming at all.

E-POSTER INDEX

297. Selection of Fusion Levels in Adolescent Idiopathic Scoliosis (AIS) using the Fulcrum Bending Radiograph Prediction: Verification Based on Pedicle Screw Strategy

Kenneth M. Cheung, MBBS(UK), FRCS(England), FHKCOS, FHKAM(Orth); Yee Leung, BSc(Hons), MB ChB, FRCS (Tr&Orth); Hideki Shigematsu; Wai Yuen Cheung, MD; Yatwa Wong; Keith D. Luk, MD; Dino Samartzis, DSc, PhD (C), MSc

China

Utilizing the fulcrum bending radiographic technique to assess curve flexibility to aid in the selection of fusion levels, a prospective radiographic study was performed to assess the safety and effectiveness of pedicle screw fixation with alternate level screw strategy (ALSS) for thoracic AIS. This study suggests that ALSS obtains greater deformity correction than hook and hybrid systems, and improves balance without compromising fusion levels.

298. MRI-Based Analysis of Cerebral Cortical Thickness in Patients with Adolescent Idiopathic Scoliosis and Normal Controls

Winnie C. Chu, FRCR, FHKAM, MD; Lin Shi, PhD; Defeng Wang, PhD; Zezhang Zhu; Jack C. Cheng, MD

China

The objective of this study is to investigate brain maturation by cerebral cortical thickness (CCT) among Adolescent Idiopathic Scoliosis (AIS) and Normal Control (NC). Fifty AIS patients and Forty age-matched NC underwent T1W MRI. Focal CCT was significantly different in AIS patients compared with healthy controls in areas involved in motor and vestibular functions as well as object recognition. This study suggested that the CCT in AIS patients have a different thinning pattern than that from NC.

299. Factors Influencing the Selection of Optimal Fusion Level in Lenke 5C Curves

Ahmet Y. Sarlak, MD; Halil Atmaca, MD; Resul Musaoglu, MD

Turkey

Posterior segmental pedicle screw instrumentation has been shown to be safe and effective in the surgical correction of TL-L curves with a short fusion length. The purpose of this study is to analyze Lenke 5C curves with respect to pre and postoperative coronal-sagittal-axial plane characteristics to help to determine the factors influencing the selection of optimum fusion level by posterior pedicle screw instrumentation.

300. Selective Anterior Thoracolumbar or Lumbar Fusion for Adolescent Idiopathic Scoliosis: The Influence of the Selection of the Lowest Instrumented Vertebrae on Radiographic Changes

Yoshihiro Matsumoto, MD, PhD; Katsumi Harimaya; Kenichi Kawaguchi; Seiji Okada; Toshio Doi; Yukihide Iwamoto

Japan

Selective anterior thoracolumbar or lumbar fusion (TL/L-ASF) for adolescent idiopathic scoliosis (AIS) of Lenke type 5/6 with solid rod instrumentation is effective, however, in cases of lowest instrumented vertebrae (LEV) was excluded in the fusion level, wedging of the disc of distal to lowest instrumented vertebrae (LIV) increased postoperatively and this disc wedging could result in the disc degeneration, including loss of disc height and posterior slip of LIV.

301. Vertebral Rotation and Position of the Aorta in Adolescent Thoracic Scoliosis: Comparison of Pre- and Intra-operative CT Scans

Shigeru Soshi, MD, PhD; Keishi Marumo, MD, PhD; Takeshi Inoue, MD; Yoshikuni Kida; Chikara Ushiku, MD; Akira Shinohara; Kurando Hashimoto; Kei Shinohara

Japan

In 18 patients with thoracic scoliosis, we evaluated for positional correlation between the aorta and vertebrae comparing pre- and intra-operative CTs. In some cases, the intra-operative aorta got closer to the long axis of the pedicle and/or the screw entry point in prone position. Therefore, the intra-operative risk of aortic injury might be higher than pre-operative estimation when screws breach the pedicle.

302. Sagittal Plane Analysis of Selective Posterior Thoracic Spinal Fusion in Adolescent Idiopathic Scoliosis: A Comparison Study of all Pedicle Screw and Hybrid Instrumentation

Tie Liu; Yong Hai, MD; Jianxiang Shen, MD; Guixing Qiu

China

To comprehensively compare sagittal profiles of selective posterior thoracic instrumentation with segmental pedicle screws instrumentation and hybrid (hook and pedicle screw), an retrospective cohort study was conducted. There was no statistically significant difference comparing the sagittal parameter of the 2 groups, while pedicle screw and hybrid in TK correction have differences. If used properly, both kinds of instrumentation can result in acceptable sagittal profiles when selective thoracic fusions were performed.

303. Adjunctive Pain Control Methods for Patients Lowers Narcotic Use and Pain Scores for Patients with Adolescent Idiopathic Scoliosis Undergoing Posterior Spinal Fusion

M. W. Shrader, MD; John S. Jones, MD; Judson W. Karlen, MD; Gregory R. White, MD; Lee S. Segal

USA

This retrospective, multivariate analysis demonstrated that the use of a subcutaneous pain pump lowers narcotic use and pain scores in patients with adolescent idiopathic scoliosis undergoing posterior spinal fusion.

304. Distal Level Of Fusion For Structural Lumbar Curve In Adolescent Idiopathic Scoliosis*Hani Mhaidli, MD, PhD; Tito Fernandez**Spain*

A retrospective study of prospectively collected data of 29 patients with Adolescent idiopathic scoliosis. 24 women, 5 men, average age 16 years (12-18), average follow-up 52 months (24-96). 14 type 3 curve, 4 type 4, 2 type 5, and 9 type 6 curves on the Lenke classification.

306. Exploding the Learning Curve Myth: Does Surgical Experience Influence Degree of Curve Correction in AIS?*Vishal Sarwahi, MD; Adam L. Wallowick, MD; Preethi M. Kulkarni, MD; Meredith Steinman; Yungtai Lo; Terry D. Amaral, MD**USA*

Previous studies have shown a learning curve associated with the use of pedicle screws in the surgical correction of AIS. This study analyzes the effect of increasing surgeon experience on the ability to provide three dimensional deformity correction in AIS. Over time, three-dimensional correction of spine deformity in AIS did not change with improvement in surgical efficiency, but a significant increase in the number of screws inserted and the number of levels fused was seen.

307. The Curve Decompensation after Anterior Instrumentation of Scoliosis by VDS - Minimal Follow-Up of Ten Years*Mirza Bisevic, PhD; Azmi Hamzaoglu, MD; Amir Zjakic; Cagatay Ozturk, MD; Ahmet Alanay; Dragica Smrke; Barbara U. Rejec Smrke**Bosnia and Herzegovina*

Thirty nine consecutive AIS patients have been treated by VDS (1997-2002), and followed minimally during next 10 years. At thirty two patients we noted hardware failure (screw pull out or rod breakage) (82,0%), and six of them (15,4%) had an indication for revision surgery. Proper patient selection and surgical techniques are essential for a good long-term outcome after anterior scoliosis surgery.

308. A Clinical Study of Postoperative Complications in 120 Adolescent Idiopathic Scoliosis Patients*Hirooki Endo; Ken Yamazaki, MD; Daisuke Yamabe; Satoshi Yoshida; Hideki Murakami; Tadashi Shimamura**Japan*

Complications after posterior corrective fusion with spinal instrumentation in AIS patients is often requires prolonged medical and surgical management. The reported prevalence of postoperative complications following corrective surgery for AIS range from 10.2% to 15.4%.

309. Avoiding Spinal Fusion: Is it Time to Revisit Conservative Therapy?*Dan Tobert; Hiroko Matsumoto; Joshua E. Hyman, MD; Benjamin D. Roye, MD, MPH; David P. Roye, MD; Michael G. Vitale, MD, MPH**USA*

The growing popularity of conservative techniques such as Schroth therapy for treatment of AIS in the United States necessitates sound evidence regarding its efficacy. Patient preference was assessed regarding a trial comparing Schroth therapy to standard of care and our results indicate a high percentage of patients and caregivers would be willing to participate.

310. Trunk Shift and Shoulder Height Difference after Surgery for Adolescent Idiopathic Scoliosis*Nuno M. Batista; Noel Peter; Alpesh Kothari; Nikolaos Pyrovolou; Stephen McGillion, BSc(Hons) MBBS MRCS(Eng); Colin Nnadi, FRCS(Orth)**United Kingdom*

Goals: 1. Assess the incidence of pre-operative and post-operative trunk shift and shoulder height 2. Assess the degree of improvement of pre-existing trunk shift and shoulder height asymmetry within the first year of surgery.

311. Scoliosis (AIS) correction with Minimally Invasive Technique: Preliminary Results of Deformity Correction with Percutaneous Pedicle Screws*Arvind Jayaswal, MS (Ortho); Pankaj Kandwal, MS (Ortho); Bhavuk Garg; Upendra Bidre, MS**India*

With encouraging results of minimally invasive techniques in spine surgery especially low grade listhesis and trauma etc, various surgeons are spreading their indication in the field of deformity correction.

312. Proximal Thoracic Curve with Posterior Spinal Fusion in Lenke Type 1 Idiopathic Scoliosis*Kanichiro Wada; Noriaki Kawakami, MD, DMSc.; Taichi Tsujii; Toshiki Saito; Ayato Nohara; Tetsuya Ohara; Kazuyoshi Miyasaka, MD**Japan*

We evaluated the characteristics of the preoperative proximal thoracic curve (PT) in Lenke type 1 idiopathic scoliosis (IS) undergoing PSF, in which UIV were the first vertebrae above the upper EV of main thoracic curve. In Lenke type 1 IS, preoperative T1 tilt and PT flexibility may affect the spontaneous PT correction and the shoulder balance after surgery.

E-POSTER INDEX

313. The Adolescent Idiopathic Scoliosis International Disease Severity Study: Does Presentation For Surgery Vary by Country?

Baron S. Lonner; Akil Fazal, MD; Oheneba Boachie-Adjei, MD; Courtney Toombs, BS; Ferran Pellise, MD; Mohamed O. Ramadan, MD, MSc; Wael Koptan, MD; Yasser ElMiligui, MD, FRCS; Harry L. Shufflebarger, MD
USA

Severity of disease at the time of surgical treatment may reflect access to care and infrastructure and may impact outcomes. This study assessed the severity of AIS prior to surgery in patients from six international sites. All surgical parameters, including curve magnitude, operative time and blood loss, varied significantly across countries. Increased/more severe complications were found in developing countries.

314. Analysis of the Outcomes of the Surgical Treatment in Single Thoracic Adolescent Idiopathic Scoliosis(AIS) with Preoperative TLSO brace

Se-Il Suk, MD; Jin-Hyok Kim; Sung-Soo Kim, MD; Dong-Ju Lim; Tai-Wan Kim
Republic of Korea

Preop TLSO brace treatment showed no negative postop effect in single thoracic AIS patients.

315. Is Intraoperative Prone Radiograph Helpful to Predict Radiographic Result for Lenke Type 1 and 3 Patients Treated By Selective Fusion ?

Sinan Kahraman; Meric Enercan; Cagatay Ozturk, MD; Levent Ulusoy; Alauddin Kochai; Mehmet B. Balioglu, MD; Mercan Sarier; Tunay Sanli, MA; Azmi Hamzaoglu, MD; Ahmet Alanay
Turkey

Intraoperative prone x-rays reflect postoperative and f/up results for Lenke type 1 and type 3 patients treated by selective thoracic fusion.

316. Risk Factors for the Postoperative Clavicle Balance Restoration

Dennis P. Devito, MD; Andrew G. King, MBChB, FRACS; Mark B. Willits, MD; Afshin Aminian, MD; Virginie Lafage, PhD
USA

A treatment of thoracic curves in the presence of small lumbar Cobb angle can lead to post-operative clavicle angle imbalance.

317. Thoracic Hypokyphosis Following Posterior Spinal Fusion With All Pedicle Screw Construct in Adolescent Idiopathic Scoliosis

Ali A. Ugras, MD; Murat Yilmaz; Ibrahim Sungur; Ibrahim Kaya; Ercan Cetinus
Turkey

With all pedicle screw constructs, excellent coronal plane correction is readily achieved but sagittal plane thoracic hypokyphosis may be seen postoperatively. Clinical complications and radiographic results of thoracic hypokyphosis is studied.

318. Difference Between Spinecor Brace And Rigid Brace During Treatment

Omer Ersen; Burak Bilekli; Serkan Bilgic, MD; Erbil Oguz; Ali Sehirlioglu
Turkey

The aim of this study is to evaluate differences between rigid brace and SpineCor brace in terms of curve progression, spinal height increase and SRS-22 questionnaire during treatment. Patients height, T1-Coccyx distance, gibbosity, Cobb angles were documented at the beginning of the treatment and last control. At last visit SRS-22 questionnaire applied to the patients to evaluate clinical effect of braces. Cobb angle decreased 1,5 degrees in spinecor group and increased 1,1 in rigid brace group ($p=0,137$). Gibbosity decreased 0,6 degrees in spinecor group and increased 0,3 in rigid brace group ($p=0,086$). According to SRS-22 questionnaire spinecor brace patients pain, self image and activity/function scores were statistically better than rigid brace patients scores while mental health and and satisfaction from treatment scores were similar.

319. Use of Transforaminal Interbody Fusion in the Surgical Management of Adolescent Idiopathic Scoliosis

Kaveh Barami; Todd Lincoln, MD
USA

This retrospective review of 10 patients who underwent TLIF (transforaminal interbody fusion) at the disc above the LIV (lowest instrumented vertebra) during surgical correction for AIS (adolescent idiopathic scoliosis) shows that TLIF can be used in select patients to preserve mobile segments with acceptable complication and revision rates.

320. Evaluation of Outcomes Using SRS-22 in Surgically Treated Patients with Idiopathic Scoliosis

Tomoko Tetsunaga; Masato Tanaka, MD; Yoshihisa Sugimoto; Tomoyuki Takigawa; Toshifumi Ozaki, MD
Japan

We evaluated radiographic and clinical parameters correlate with Scoliosis Research Society-22 (SRS-22) questionnaire. Thirty patients with idiopathic scoliosis were assessed, and all patients were treated by posterior fusion with thoracic pedicle screw technique. Radiographic measures and clinical parameters were analyzed for correlation with SRS-22. Correlation was found between pain and mental health domain. There was not significant correlation between preoperative Cobb angle and SRS-22. Multiple regression analysis showed only postoperative duration was the predictor of mean SRS-22.

321. Vertebral Rotation Corrected by Posterior Pedicle Screw Technique of Adolescent Thoracic Idiopathic Scoliosis

Masato Tanaka, MD; Yoshihisa Sugimoto; Tomoyuki Takigawa; Tomoko Tetsunaga
Japan

A retrospective study was performed on 54 consecutive patients with AIS, who underwent selective thoracic fusion with different surgical techniques. The patients were classified into group H (hybrid, n=16) and group S (screws, n=38). Compared with the use of hooks and the wires (hybrid), vertebral rotation in AIS is effectively corrected by posterior pedicle screw fixation.

322. Resumption of Bowel Function In Postoperative AIS Compared to Adolescent Hip Surgery Patients

Anna M. McClung, RN; Daniel J. Sucato, MD, MS; Scott Paradise; David Wilkes, MD; Trudi Jubenville, ADN; Amy Keefover-Hicks
USA

Postoperative constipation is felt to be a particular concern in the AIS population. A comparison was made between postoperative AIS and adolescent hip patients. Neither group was considered constipated by a radiologic scoring method; however 56% of patients had not resumed normal bowel function by discharge. Increased intravenous fluids, ≥ 1 rescue medication and the use of rectal rescue medications was associated with decreased incidence of constipation.

323. Selection of Distal Instrumentation Level in Posterior Segmental Screw Fixation in the Correction of Adolescent Idiopathic Scoliosis

Jonathan A. Clamp, FRCS (Tr&Orth); Ben Boreham, MB BCh FRCS(Orth); Tim Hammett, MRCS; Nasir A. Quraishi, FRCS; Hossein Mehdian, MD, MS(Orth) FRCS(Ed)
United Kingdom

The choice of lowest instrumented level in AIS treated with 100% metal density constructs remains uncertain. Our experience will add to the growing knowledge base for this procedure.

324. Analysis of 60 AIS Patients' Immediate Post-Op Correction Shows no Superiority of CoCr Rods over Titanium(Ti) Rods

Dennis P. Devito, MD; Andrew G. King, MBChB, FRACS; Mark B. Willits, MD; Afshin Aminian, MD; Virginie Lafage, PhD
USA

Different rod materials are used for the correction of AIS. This study evaluates the difference of correction and pre-op patient profiles for Ti and CoCr rods.

Adult Spinal Deformity**325. Meta-Analysis of Adult Degenerative Scoliosis Surgical Treatment Outcomes**

Charles Gerald T. Ledonio, MD; David W. Polly, MD; Sue Duval, PhD; Charles H. Crawford, MD; Sharon C. Yson, MD; A. Noelle Larson, MD; Edward Rainier G. Santos, MD; Jonathan N. Sembrano, MD; Jacob M. Buchowski, MD, MS; Justin S. Smith, MD, PhD
USA

Systematic literature review and meta-analysis of outcomes after surgical treatment for adult degenerative scoliosis were conducted. Despite significant heterogeneity among studies, random-effects meta-analysis models did show significant improvements in Cobb angle, coronal balance, VAS and ODI after surgical treatment.

This presentation is the result of a project funded, in part, by an SRS Research Grant.

329. Comparison of Long Term (Five Year) Reoperation Rates and Outcomes for Long Fusions to the Sacrum for Adult Deformity: Primary vs. Revision Surgery

David Essig, MD; Michael Faloon, MD; Woojin Cho, MD, PhD; Gbolabo Sokunbi; Thomas Ross, MS, RN; Matthew E. Cunningham, MD, PhD; Bernard A. Rawlins, MD; Oheneba Boachie-Adjei, MD
USA

This review compares reoperation rates (RO) between primary (PS) and revision (RS) surgery for adult spinal deformity (ASD) at a minimum 5 yr f/u. Despite better patient reported outcomes, no difference was seen in the RO between groups.

330. Radiographic Outcomes of Spinal Deformity Correction in Adult Patients: A Critical Analysis of Variability and Failures Across Deformity Patterns

Bertrand Moal, MS; Frank Schwab, MD; Christopher P. Ames, MD; Justin S. Smith, MD, PhD; Praveen V. Mummaneni, MD; Gregory M. Mundis, MD; Jamie S. Terran, BS; Eric Klineberg, MD; Robert A. Hart, MD; Oheneba Boachie-Adjei, MD; Christopher I. Shaffrey, MD; Virginie Lafage, PhD; International Spine Study Group
USA

For 161 operative patients with ASD, the effectiveness in restoring alignment of the spino-pelvic was evaluated at 1 year follow-up. The frequency of inadequate sagittal plane correction is high (50%); pelvic tilt is least likely to be well corrected. Preoperative analysis is not enough to achieve adequate spinal realignment. The high rate of alignment failure indicates a need for better preoperative planning, intra-operative imaging, and perhaps the need for increased angular correction in the sagittal plane.

331. Are Clinical Outcomes Favorable following of Posterior Vertebral Column Resection (PVCR) for Severe Adult Spinal Deformity?

Woo-Kie Min, MD, PhD; Lawrence G. Lenke, MD; Michael P. Kelly, MD; Han Jo Kim, MD; Yutaka Nakamura, MDPhD; Dong-Ho Lee, MD, PhD; Moon Soo Park, PhD; Brenda A. Sides, MA
Republic of Korea

31 PVCRs with minimum 2-year follow-up were reviewed in the treatment of severe adult spinal deformity. Patients had overall favorable radiographic and clinical outcomes with only one (2.3%) major neurologic deficit, despite high risks of complications in these very challenging patients.

332. Clinical Tolerance to Sagittal Imbalance Varies with Age

Ferran Pellise, MD; Montse Domingo-Sabat; Ahmet Alanay; Juan Bago, MD; Alba Vila-Casademunt; Carlos Villanueva, MD, PhD; Azmi Hamzaoglu, MD; Emre Acaroglu, MD
Spain

Self-reported disability increases with loss of lumbar lordosis (LL) and anterior sagittal balance. The effect of age in the clinical impact of loss of lumbar lordosis and sagittal imbalance is still unknown. Our study shows that clinical tolerance to sagittal imbalance and loss of LL varies with age. Older people (with weaker compensatory mechanisms) show greater impact and disability. The importance of achieving an ideal lordosis as a part of treatment increases with the patients' age.

E-POSTER INDEX

334. Minimally Invasive Treatment of Adult Scoliosis with XLIF: Radiographic Outcomes from a Prospective Multicenter Study

Frank M. Phillips, MD
USA

This study presents 24mo radiographic results of adult degenerative scoliosis patients treated with XLIF.

The FDA has not cleared the drug and/or medical device for the use described in this presentation (i.e., the drug or medical device is being discussed for an 'off label' use).

335. RhBMP-2 is Superior to Iliac Crest Bone Graft for Long Construct Sacropelvic Fusions in Adult Spinal Deformity: Four to 14-Year Follow-Up

Han Jo Kim, MD; Jacob M. Buchowski, MD, MS; Lukas P. Zebala, MD; Linda Koester, BS; Stuart Hershman, MD; Addisu Mesfin, MD; Jeremy L. Fogelson, MD; Keith H. Bridwell, MD
USA

BMP is superior to ICBG in fusion rates. The efficacy is dose dependent with doses $\geq 5\text{mg/level}$ having the highest rates for fusion, suggesting a dose related effectiveness for achieving solid fusions. We did not see an increased cancer risk associated with its use.

The FDA has not cleared the drug and/or medical device for the use described in this presentation (i.e., the drug or medical device is being discussed for an 'off label' use).

336. Do Preoperative Curve Magnitude and Major Thoracic Deformity Correction Correlate with Pulmonary Function following Adult Deformity Surgery?

Ronald A. Lehman, MD; Daniel G. Kang, MD; Lawrence G. Lenke, MD; Jeremy J. Stallbaumer, MD; Brenda A. Sides, MD
USA

We evaluated the relationship of pre-op curve magnitude and deformity correction with pulmonary function in 76 adult patients following spinal deformity surgery. Pre-op major thoracic (MT) curve magnitude correlated negatively with pre-op pulmonary function, and MT deformity correction correlated negatively with %pred PFTs. This suggests that a greater MT deformity correction may result in significantly less decline in pulmonary function than smaller curve corrections. Sagittal curve magnitude/deformity correction and pulmonary function did not demonstrate a significant relationship.

338. Natural History of Coronal Spinal Balance in Patients with Long Spinal Fusions: A Two-Year Follow-Up Study

Avraam Ploumis, MD, PhD; Kirkham B. Wood, MD; Thomas D. Cha, MD, MBA
Greece

In a retrospective 2-year follow up study of patients treated by long fusions for spinal deformities, radiographic parameters, demographic data and operative factors and bracing were analyzed. At six weeks postoperatively there was a deterioration in coronal balance compared to preoperatively, however, balance improved at 2-years follow-up but was still worse than preoperatively. Preoperative sagittal imbalance was the most important factor associated with coronal imbalance postoperatively.

339. Early Failures following Surgical Treatment for Spinal Stenosis with Lumbar Deformity

Darrel S. Brodke, MD; Prokopis Annis, MD; Brandon Lawrence, MD; Justin B. Hohl, MD; Jayme R. Hiratzka, MD; Michael D. Daubs, MD
USA

Symptomatic lumbar stenosis associated with degenerative deformity is most commonly treated with laminectomy and fusion. Laminectomy alone and more recently Interspinous Process Spacers (ISP), have been utilized in this group of patients, though no studies have compared these procedures. This study found that early failure with recurrent stenosis was significantly more common in patients treated with an ISP device, while adjacent segment degeneration was more common with laminectomy and fusion. Laminectomy alone had the highest rate of survival.

340. Perioperative Complications of Posterior Vertebral Column Resection of the Thoracic Spine

Michael D. Daubs, MD; Brandon Lawrence, MD; Prokopis Annis, MD; Darrel S. Brodke, MD
USA

We analyzed the perioperative complications of pVCR performed in the thoracic spine. Our major complication rate was 19% and the minor complication rate was 31%. There were no neurologic complications.

341. Long Term Clinical and Radiographic Outcomes of Pedicle Subtraction Osteotomy for Fixed Sagittal Imbalance: Does Level of Proximal Fusion Affect The Outcome? Minimum Five Years Follow-Up

Mitsuru Yagi, MD, PhD; Matthew E. Cunningham, MD, PhD; Akilah B. King, BA; Oheneba Boachie-Adjei, MD
Japan

Despite an increased SVA and high complication rate, PSO provided good sagittal balance and favorable clinical outcomes in both short fusion and long fusion groups in the long term follow-up. The data suggests that loss of sagittal balance can be attributed to increase kyphosis in short fusion groups and should be monitored for long term outcomes.

342. Adult Lumbar Degenerative Scoliosis Less than 40°: Outcomes with Minimum Two-Year Follow-Up

Justin Park, MD; Leah Y. Carreon, MD, MSc; Steven D. Glassman, MD
USA

Some adult lumbar degenerative scoliosis patients have curves less than 40°. Although these curves do not need correction, the curve may alter the treatment paradigm for associated back and leg pain; requiring fusion to achieve adequate decompression and prevent progression of the deformity. Our results show that patients with curves less than 40° had statistically significant improvement at 2 years after decompression and instrumented fusion.

343. Is an Atrophy of the Paraspinal Muscle Related to Sagittal Spinal Imbalance?*Atsushi Kojima, MD, PhD; Yutaka Sasao, MD, PhD; Yoshiaki Torii; Shigeta Morioka*

Japan

Vertebral body and facet joints, intervertebral disc, spinal ligament and paravertebral muscle (PVM) play an important role in maintain the spinal column. These elements for stabilization are well known to change in elderly. To find the role of PVM for the spinal column, we examined to measure functional cross section area (FCSA) of PVM and iliopsoas in lumbar type adult scoliosis. We concluded that an atrophy of PVM correlated strongly with decrease positive SVA.

344. Pelvic Fixation after Lumbar Pedicle Subtraction Osteotomy for Correction of Adult Spinal Deformity is Associated with Improved Radiographic Correction: Multi-center Radiographic Analysis*Khaled Kebaish, MD; Eric Klineberg, MD; Mostafa H. El Dafrawy, MD; Virginie Lafage, PhD; Christopher I. Shaffrey, MD; Frank Schwab, MD; Munish C. Gupta, MD; Shay Bess, MD; Richard Hostin, MD; Michael F. Obrien, MD; Oheneba Boachie-Adjei, MD; Christopher P. Ames, MD; International Spine Study Group*

USA

The amount of distal fixation necessary to achieve and maintain post-operative deformity correction is still unclear. This is a multicenter radiographic analysis of the association of sacropelvic fixation in adult patients undergoing PSO for correction of lumbar deformities. We compare patients with instrumentation extended to the ilium to those patients fused to the Sacrum. Iliac fixation is associated with more favorable radiographic correction at 6 weeks, 6 months and one year.

345. Time to Maximum Improvement on Patient Reported Outcomes Following Staged Adult Spinal Deformity Surgery*Richard L. Skolasky, ScD; Mostafa H. El Dafrawy, MD; Hamid Hassanzadeh, MD; Khaled Kebaish, MD*

USA

For patients undergoing staged anterior/posterior surgical treatment for adult spinal deformity, realistic expectations of time to recovery following surgery may lead to improved satisfaction.

346. Analysis of Proximal Junctional Kyphosis in Patients receiving Spinal Fusions to Proximal Levels of T9, T10, or T11 with and without Vertebroplasty*Jamal McClendon, MD; Patrick A. Sugrue, MD; Timothy R. Smith, MD, PhD, MPH; Josh Abecassis; Brian A. O'Shaughnessy, MD; Sara E. Thompson, BA; Tyler Koski, MD*

USA

Proximal junctional kyphosis (PJK) is an important complication seen in long instrumented fusions. Few studies have discussed cement augmentation with vertebroplasty at the upper instrumented vertebra (UIV). Our study examines the proximal junctional Cobb angle in patients instrumented to the lower thoracic spine with and without vertebroplasty.

The FDA has not cleared the drug and/or medical device for the use described in this presentation (i.e., the drug or medical device is being discussed for an 'off label' use).

347. Focal and Global Correction Following Three Column Osteotomies of the Lumbar Spine in Adult Deformity Patients: A Comparative Radiographic Analysis between Pedicle Subtraction Osteotomy and Vertebral Column Resection*Mostafa H. El Dafrawy, MD; Hamid Hassanzadeh, MD; Amit Jain; Philip Neubauer, MD; David B. Cohen, MD; Khaled Kebaish, MD*

USA

Similar focal and global correction in the sagittal plane can be achieved using either PSO or VCR; VCR should be reserved for the more severe focal kyphotic deformities

348. Does Minimally Invasive Surgical (MIS) Treatment of Adult Spinal Deformities Affect the Incidence of Proximal Junctional Kyphosis?*Neel Anand, MD; Babak Khandehroo, MD; Eli Baron, MD; Sheila Kahwaty, PA-C*

USA

MIS has previously been shown to achieve comparable deformity correction in both sagittal and coronal plane. This study shows that MIS correction for spine deformities decreases the incidence of PJK as a potential side effect.

The FDA has not cleared the drug and/or medical device for the use described in this presentation (i.e., the drug or medical device is being discussed for an 'off label' use).

349. Adult Deformity: A Very Large Population of Patients with Different Needs*Emre Acaroglu, MD; Montse Domingo-Sabat; Umit Guler, MD; Sule Yakici; Azmi Hamzaoglu, MD; Ahmet Alanay; Ferran Pellise, MD*

Turkey

155 adult deformity(AD) patients were evaluated by HRQL measures at presentation and results were compared by age and diagnosis. Our results suggest that AD patients in different age groups and diagnoses present with very different problems and expectations. There is a distinct need to stratify AD as early and late presentation AD and/or by diagnosis.

350. Comparison of Outcomes in Three Different Lumbar Osteotomy Techniques for Correction of Deformity in Ankylosing Spondylitis*Hossein Mehdian, MD, MS(Orth) FRCS(Ed); Ben Boreham, MB BCh FRCS(Orth); Ranganathan Arun, FRCS(Tr&Orth), DM, MRCS*

United Kingdom

Surgery for deformity in Ankylosing Spondylitis is a relatively uncommon, with very serious potential risks. We have compared three techniques for lumbar osteotomy and our conclusion will help in the decision making process for surgeons undertaking these procedures.

E-POSTER INDEX

351. Four-Rod Technique Helps Achieve And Maintain Greater Correction In Lumbar Pedicle Subtraction Osteotomies

Vivek Mohan, MD, MS; Eric Klineberg, MD; Rolando F. Roberto, MD; Joshua P. Ellwitz, MD; Munish C. Gupta, MD
USA

We performed pedicle subtraction osteotomies on 29 consecutive patients and retrospectively analyzed their radiographic and clinical data. Achieving an average osteotomy angle of nearly 40°, with minimal neurological complications.

352. Effect of Upper Instrumented Vertebra (UIV) on Adult Spinal Deformity (ASD) Correction, Maintenance of Correction, and Health Related Quality of Life (HRQOL) Following Lumbar Pedicle Subtraction Osteotomy (PSO)

Christopher P. Ames, MD; Justin K. Scheer, BS; Vedat Deviren, MD; Justin S. Smith, MD, PhD; Shay Bess, MD; Richard Hostin, MD; Eric Klineberg, MD; Robert A. Hart, MD; Gregory M. Mundis, MD; Michael F. Obrien, MD; Christopher I. Shaffrey, MD; Virginie Lafage, PhD; Khaled Kebaish, MD; Frank Schwab, MD; International Spine Study Group
USA

Retrospective analysis of LPSO procedures from a large, multi-center adult spinal deformity (ASD) osteotomy database demonstrated that UIV in upper thoracic spine (UT; T2-T5) had better early sagittal alignment, better maintenance of sagittal correction and better maintenance of sagittal vertical axis <5cm than patients with UIV in the thoracolumbar (TL; T9-L1) region at 2 year follow up. HRQOL values were similar between UT and TL. Long term evaluation will determine if these differences impact HRQOL values, complication and revision rates.

353. Validity of Failure Classification for Pelvic Fixation Used in Long Construct Fusions in Adult Deformity Patients

Woojin Cho, MD, PhD; Jonathan R. Mason, MD; Adam Wilson, MD; Christopher I. Shaffrey, MD; Francis H. Shen, MD; Adam L. Shimer, MD; Wendy Novicoff, PhD; Kai-Ming Fu, MD, PhD; Joshua E. Heller, MD; Vincent Arlet
USA

This study analyzed SRS and ODI scores of adult deformity patients with failure of pelvic fixation. It validates minor failure as expected loosening or breakage of pelvic screws due to motion at SI joints following solid fusion in long constructs used for adult deformity. It defined major failure as radiographic evidence of pseudarthrosis or prominent screws and supported these definitions with clinical outcome scores.

354. Effect of Severity of Rod Contour on Posterior Rod Failure in Setting of Lumbar Pedicle Subtraction Osteotomy (PSO): A Biomechanical Study

Jessica A. Tang, BS; Jeremi M. Leasure, MEng; Jennifer Buckley, PhD; Dimitriy Kondrashov, MD; Christopher P. Ames, MD
USA

The results of this study suggest that contouring rods for posterior spinal fixation constructs significantly lowers the fatigue life of the rods and weakens the entire construct. In the setting of PSO, the fatigue life of posterior spinal fixation rods depends largely on the severity of the rod angle used to maintain the vertebral angle created by the PSO.

355. Minimally Invasive Pedicle Screw Instrumentation and Fusion for Adult Scoliosis - Functional and Radiological Outcomes

Neel Anand, MD; Babak Khandehroo, MD; Sheila Kahwaty, PA-C; Eli Baron, MD
USA

Patient age, comorbidities, blood loss, morbidity and complication rate may be limiting factors when considering surgical correction for adult spinal deformities. Minimally invasive surgical approaches may allow for significantly less blood loss and complication rate than open techniques and may achieve comparable outcomes. The FDA has not cleared the drug and/or medical device for the use described in this presentation (i.e., the drug or medical device is being discussed for an 'off label' use).

356. Focal Correction and Sagittal Balance in Adult Deformity Patients Undergoing Pedicle Subtraction Osteotomy: Radiographic Comparison with and without Cages

Mostafa H. El Dafrawy, MD; Hamid Hassanzadeh, MD; Philip Neubauer, MD; Emmanuel N. Menga, MD; David B. Cohen, MD; Khaled Kebaish, MD
USA

We compared adult deformity patients undergoing pedicle subtraction osteotomy of the lumbar spine with the use of mesh cages for anterior to patients without cages. PSO with and without cages allows for equal correction of focal kyphosis and sagittal balance, patients with cages have less loss of focal correction over time which trended toward significance.

357. Sagittal Decompensation Following Anterior-Posterior Spinal Fusion with or without Lumbar Pedicle Subtraction Osteotomy for Adult Patients with Partially flexible Degenerative Sagittal Imbalance

Yongjung J. Kim, MD; Gene Cheh, MD; Seung-Chul Rhim, MD; Kyoungham Kim, MS; Sally Pak, RN, BSN
USA

A radiographic and clinical assessment of 62 adult patients (average 64.1 years) with sagittal imbalance who underwent anterior-posterior spinal fusion (APSF) with or without lumbar pedicle subtraction osteotomy (LPSO) with a minimum of 2-year follow-up showed 32 % sagittal decompensation. APSF without osteotomy and poor restoration of lumbar lordosis during surgery were risk factors.

358. Clinical Outcomes of Pedicle Subtraction Osteotomy in Revision Adult Deformity Surgery

Xuesong Zhang, MD; Yonggang Zhang, PhD; Yan Wang, MD
China

few study has analyzed the clinical outcome of PSO in revision adult spinal deformity surgery, and how to evaluate the occurrence of a major complication in PSO and the ultimate clinical outcome

359. Adult Degenerative Scoliosis Treated by XLIF: Clinical Results of a 24-Month Multi-Center Prospective Study

William D. Smith, MD; Frank M. Phillips, MD; Antoine G. Tohmeh, MD; William B. Rodgers, MD
USA

This report summarizes the longitudinal clinical results from a prospective multicenter study on the treatment of adult degenerative scoliosis with the extreme lateral interbody fusion (XLIF) approach.

The FDA has not cleared the drug and/or medical device for the use described in this presentation (i.e., the drug or medical device is being discussed for an 'off label' use).

360. Changes of Spinopelvic Parameter following Lumbosacral Fusion with and without Iliac Fixation in Patients with Sagittal Deformity

Whoan Jeang Kim; Jae Yoon Chung, MD; Kun Young Park
Republic of Korea

The iliac screw fixation increases the rigidity of the lumbosacral fusion and reduces the pseudoarthrosis rate at L5-S1 in sagittal deformity correction. However, the effectiveness of iliac screw on the spinopelvic parameter have not been investigated yet.

361. Radiographic and Clinical Outcomes of Posterior Column Osteotomies in Adult Spinal Deformity Correction: Analysis of 128 Patients

Ian G. Darward, MD; Lawrence G. Lenke, MD; Keith H. Bridwell, MD; Woojin Cho, MD, PhD; Linda Koester, BS; Brenda A. Sides, MA
USA

We reviewed 128 patients undergoing PCO with at least 2-year follow-up. Average kyphosis correction was 8.8° per PCO, but varied significantly by the region of the spine in which PCOs were used. PCOs did not cause increased complications, and were associated with improved SRS and ODI outcomes scores.

362. Long-Term Outcomes of Long Fusions to the Sacrum for Adult Scoliosis: A Comparison of Unilateral, Bilateral Iliac, or Sacral Screws Alone

Michael Faloan, MD; David Essig, MD; Woojin Cho, MD, PhD; Gbolabo Sokunbi; Matthew E. Cunningham, MD, PhD; Bernard A. Rawlins, MD; Oheneba Boachie-Adjei, MD
USA

This retrospective review compares long fusions in adult spinal deformity (ASD) patients by comparing return to OR (RTO) rates between distal instrument fixations. While no significant differences were seen in early or late RTO rates between instrumentation groups, the unilateral iliac screws had less RTO complications than SS at long term.

363. The Effect of Low Dose Bone Morphogenic Protein (RhBMP-2) on Posterolateral Fusion in Adult Spinal Deformity Surgery

Justin B. Hohl, MD; Michael D. Daubs, MD; Jayme R. Hiratzka, MD; Prokopis Annis, MD; Brandon Lawrence, MD; Darrel S. Brodke, MD
USA

Bone morphogenic protein-2 (BMP) has been used in adult spinal deformity surgery to increase fusion rates but the minimum dosage needed for successful fusion is not known. Low dose BMP-2 used for posterolateral fusion in adult spinal deformity surgery appears to be effective at 2 year follow-up with a fusion rate of 87%. Patients with nonunion had less improvement in VAS back pain scores and a trend toward lower function.

The FDA has not cleared the drug and/or medical device for the use described in this presentation (i.e., the drug or medical device is being discussed for an 'off label' use).

364. The Effect of Pedicle Subtraction Osteotomy on Cervical Lordosis

Jayme R. Hiratzka, MD; Michael D. Daubs, MD; Prokopis Annis, MD; Justin B. Hohl, MD; Brandon Lawrence, MD; Darrel S. Brodke, MD
USA

The effects of pedicle subtraction osteotomy (PSO) on cervical alignment have not been well studied. This study evaluates the changes in cervical alignment in patients with sagittal imbalance undergoing PSO when compared to control patients with normal sagittal balance. The sagittal imbalance group showed increased cervical lordosis, T1 tilt and C2 tilt prior to surgery. Postoperatively, sagittal balance and T1 tilt improved, but cervical lordosis remained unchanged. C7 plumbline and odontoid tip showed high correlation among all groups.

365. Pedicle Subtraction Osteotomies: Critical Analysis of Geometric Parameters

Vivek Mohan, MD, MS; Eric Klineberg, MD; Rolando F. Roberto, MD; Joshua P. Ellwitz, MD; Munish C. Gupta, MD
USA

In our retrospective geometrical analysis of 29 patients who underwent pedicle subtraction osteotomies, we have confirmed Rose et al mathematical findings as well as having developed a simple formula to estimate overall correction in sagittal balance.

366. Surgical Characteristics, Perioperative and Early Post-Operative Complications in Adult Idiopathic Scoliosis and Adult Scheuermann's Kyphosis: A Prospective Multi-Center Study

Oheneba Boachie-Adjei, MD; W. F. Hess, MD; Raymund Woo, MD; Mark D. Rahm, MD; Robert W. Gaines, MD; Terry R. Trammell, MD; Hani Mhaidli, MD, PhD; Francisco Javier Sánchez Pérez-Gruoso; Thomas Ross, MS, RN; Mitsuru Yagi, MD, PhD; Complex Spine Study Group
USA

Previous studies have indicated a higher surgical complication rate in kyphotic deformities compared to idiopathic scoliosis. This retrospective review showed that Adult Idiopathic Scoliosis patients may have higher perioperative complications compared to Adult Scheuermann's Kyphosis despite similar fusion levels, OR time, BMI, EBL and length of stay. The long term implications of the perioperative complications and revision surgeries are yet to be defined.

E-POSTER INDEX

367. A Comparison of Fusion to the Upper Thoracic vs. Thoracolumbar Spine in Lumbar Pedicle Subtraction Osteotomy Cases

Vedat Deviren, MD; Urvij M. Modhia, MD; William Schairer, Alexandra Carrer, MD; Anuj Prasher, MD; Sigurd H. Berven, MD; Praveen V. Mummaneni, MD; Shane Burch, MD; Serena S. Hu, MD; Dean Chou, MD; Bobby Tay, MD; Christopher P. Ames, MD
USA

We compared radiographic correction and complication rates in a cohort of patients with long and short fusions to the pelvis combined with a pedicle subtraction osteotomy (PSO) for positive sagittal balance. When combined with a PSO, long fusion to upper thoracic spine achieved better sagittal correction compared to short fusion to thoracolumbar spine at the cost of longer operations with more blood loss. There was no significant difference in complication rates.

368. Longitudinal Radiographic Assessment of Maintenance of Sagittal Plane Deformity Correction Following Three-Column Spinal Osteotomy

Mostafa H. El Dafrawy, MD; Virginie Lafage, PhD; Richard Hostin, MD; Christopher P. Ames, MD; Justin S. Smith, MD, PhD; Jamie S. Terran, BS; Vedat Deviren, MD; Michael F. O'Brien, MD; Frank Schwab, MD; Khaled Kebaish, MD; International Spine Study Group
USA

Achieving sagittal spino-pelvic alignment (SPA) correlates with favorable outcomes in adult spinal deformity, but maintenance of restored SPA can be challenging. 42 adults with sagittal plane deformity treated with 3 column spinal osteotomy were reviewed radiographically to assess maintenance of sagittal alignment correction following surgery. Those patients achieving ideal global alignment (SVA) at 6w mostly maintain this at 1yr post-op (92%). Patients with suboptimal correction tend to maintain or improve their correction, although over 27% worsen by one grade.

369. Radiographic Parameters Related to Sagittal Balance for Adult Spinal Deformity. Which Parameter is Most Important?

Tatsuya Yasuda; Tomohiko Hasegawa; Yu Yamato; Sho Kobayashi, PhD; Daisuke Togawa, MD, PhD; Yukihiko Matsuyama, MD
Japan

Radiographic retrospective study to find out the factor that affect to sagittal balance for adult spinal deformity. T12 posterior tilt was reflecting both pelvic and lumbar, and correlated with sagittal balance.

370. Adult Kypho Scoliosis Thoracic to Pelvis Fusions a Single Surgeon Series 2001-2010

Anant Kumar, MD; Mayanka Kumar
USA

This single surgeon series of Adult scoliosis (greater than 30 degrees) fusions to pelvis includes 74 fusions to upper thoracic spine and 85 to lower thoracic spine performed from 2001-2010. There were 5 deaths during postop follow up(8 months to 4 yrs). Anterior lumbar fusions (xlif /Alif)was performed in 139/159 patients.Tlif was performed in 20/159 patients.Sameday anterior/posterior surgery was performed in 73/159 and 66 anterior and posterior surgery were staged 48 hours apart.Two patients with lower thoracic fusions were extended due to adjacent level fractures.

371. The Impact of Restored Global Sagittal Alignment on Outcomes of Three-Column Osteotomy

Richard Hostin, MD; Michael F. O'Brien, MD; Ian McCarthy, PhD; Christopher P. Ames, MD; Justin S. Smith, MD, PhD; Munish C. Gupta, MD; Robert A. Hart, MD; Douglas C. Burton, MD; Christopher I. Shaffrey, MD; Shay Bess, MD; Frank Schwab, MD; Virginie Lafage, PhD; Vedat Deviren, MD; Khaled Kebaish, MD; International Spine Study Group
USA

This study analyzes the impact of global sagittal alignment (GSA) on outcomes for patients undergoing Pedicle Subtraction Osteotomy (PSO) surgery for adult spinal deformity (ASD). Although there are agreed-upon thresholds to identify GSA from a radiographic perspective, results indicate that alternative thresholds are needed to distinguish patients in terms of health related quality of life (HRQOL) improvements. Results also find that increased PT corrections may not offer significant quality of life improvements relative to more mild PT corrections.

372. Biomechanical Study of the Effect of Long Spine Fusion on Sacral Screw Stress

Ming Li; Guo-you Zhang; Chuan-Feng Wang
China

This in vitro biomechanical study evaluates the effect of long spine fusion on S1 screw stress.

373. Inclination in Free-Standing Posture in Patients with Severe Thoracolumbar Kyphosis Secondary to Ankylosing Spondylitis

Bangping Qian; Xinqiang Wang; Yong Qiu; Jun Jiang; Zezhang Zhu; Yang Wang
China

The influence of pedicle subtraction osteotomy (PSO) on the position of acetabulum has not been previously reported in ankylosing spondylitis (AS) patients with severe thoracolumbar kyphosis. In this retrospective study, the preoperative and postoperative radiographic parameters were compared in AS patients. The results revealed that the acetabular inclination (AI) significantly decreased in AS patients with thoracolumbar kyphosis after PSO.

374. V-Y Vertebral Body Osteotomy for the Correction of Fixed-Flexion Deformity of the Lumbar Spine

Hossein Mehdian, MD, MS (Orth) FRCS(Ed); Ben Boreham, MB BCh FRCS (Orth); Tim Hammett, MRCS; Nasir A. Quraishi, FRCS; Ranganathan Arun, FRCS(Tr&Orth), DM, MRCS
United Kingdom

The new V-Y vertebral body osteotomy technique is a safe and effective alternative to pre-existing Smith-Petersen and Pedicle Subtraction Osteotomies. This provides a significant correction at one level and incorporates features of both SPO and PSO techniques.

375. Gastroesophageal Reflux Disease in Degenerative Lumbar Kyphoscoliosis

Naobumi Hosogane, MD; Akio Iwanami; Kota Watanabe; Mitsuru Yagi, MD, PhD; Shinjiro Kaneko; Takashi Tsuji; Ken Ishii, MD, PhD; Hitoshi Kono, MD; Masaya Nakamura; Masanobu Shioda; Masafumi Machida, MD; Masashi Saito; Yoshiaki Toyama; Kazuhiro Chiba, MD, PhD; Morio Matsumoto, MD

Japan

Gastroesophageal reflux disease (GERD) symptoms were evaluated in 75 degenerative lumbar kyphoscoliosis (DLKS) patients using Quest (Questionnaire for the diagnosis of reflux disease). Eighteen patients had Quest score ≥ 6 (P group) and 57 patients had Quest score ≥ 5 (N group). Both lumbar curve and thoracic curve were significantly larger in P group and lumbar lordosis tended to be smaller in P group.

GERD symptoms should also be taken into consideration in the treatment of adult spinal deformity.

376. Quality of Life Differential in Adolescent vs. Adult Patients Undergoing Surgery for Scheuermann's Kyphosis

Lawrence Karlin, MD; James W. Dewberry, MD; Raymond Woo, MD; Mark D. Rahm, MD; Terry R. Trammell, MD; Robert W. Gaines, MD; W. F. Hess, MD; Hani Mhaidli, MD, PhD; Francisco Javier Sánchez Pérez-Gruoso; Thomas Ross, MS, RN; Mitsuru Yagi, MD, PhD; Oheneba Boachie-Adjei, MD; Complex Spine Study Group

USA

A multi-center database was used to compare the quality of life scores between adult and adolescent patients with Scheuermann's Kyphosis who were treated surgically.

377. Lordosis Restoration after Anterior Longitudinal Ligament Release and Placement of Lateral Hyperlordotic Interbody Cages During the MIS Lateral Transpoas Approach: A Radiographic Study in Cadavers

Juan S. Uribe, MD; Donald A. Smith, MD; Elias Dakwar, MD; Ali A. Baaj; Gregory M. Mundis, MD; Alexander W. Turner, PhD; G. Bryan Cornwall, PhD; Behrooz A. Akbarnia, MD

USA

A cadaveric study examining the effect of lordotic implants at 10°, 20°, and 30° at impacting sagittal imbalance when placed through a lateral transpoas approach.

Segmental and global lordosis were increased through the use of lordotic implants, with greater correction following placement of increasingly lordotic cages. Release of the anterior longitudinal ligament further increased lordosis.

The FDA has not cleared the drug and/or medical device for the use described in this presentation (i.e., the drug or medical device is being discussed for an 'off label' use).

378. Early Changes in Health State Utility Score Following Revision of Pseudarthrosis in Adult Spinal Deformity

Peter D. Angevine, MD, MPH

USA

In this small, retrospective study of seven patients with symptomatic nonunion after thoracolumbar spinal deformity surgery, a large mean improvement in health state utility was found at early follow-up. Further study will be necessary to determine if these findings apply to larger populations and to establish the long-term utility changes associated with revision of symptomatic pseudarthrosis.

379. A Two-Years Minimum Follow-Up of Short Segment Surgery in the Treatment of Degenerative Lumbar Scoliosis: A La Carte Surgical Approach

Gabriel Liu, MSc. FRCS(Orth); Sambhav Shah, MS; Hee-Kit Wong; John Nathaniel M. Ruiz, MD, MRCS

Singapore

This study demonstrates the possibility of using short segment surgery (a la carte approach) focused mainly on neurological symptomatic relief and not spinal deformity correction as a treatment option in patient with small coronal Cobb angle and without preoperative flatback.

380. Intraoperative Neurophysiological Monitoring in Anterior Lumbar Interbody Fusion (ALIF) Surgery

Ilker Yaylali, MD, PhD; Jung U. Yoo, MD; Alexander C. Ching, MD; Robert A. Hart, MD

USA

Somatosensory evoked potential (SSEP) and motor evoked potentials (MEP) have both proven useful in assessment of the functional integrity of the spinal cord. Anterior lumbar interbody fusion (ALIF) is frequently performed for degenerative, traumatic and deforming conditions of the lumbar spine. The current study is a retrospective review of our experience using IONM for ALIF.

381. Risk Factors in Predicting Early Post-Operative Coronal Imbalance in Adult Spinal Deformity Patients: A Multicenter Analysis

Gregory M. Mundis, MD; Jamie S. Terran, BS; Vedat Deviren, MD; Christopher P. Ames, MD; Munish C. Gupta, MD; Douglas C. Burton, MD; International Spine Study Group

USA

Correction of adult spinal deformity must be achieved in multiple planes. Coronal balance correction has long been studied in the Adult Spinal Deformity (ASD) population and has been found to have a significant impact on HRQOL. Twenty percent of patients developed a new coronal imbalance and 50% failed to be corrected. Preoperative planning is essential to ensure adequate correction of coronal imbalance in this population.

382. The Relationship Between Sacral Kyphosis and Pelvic Incidence

Ian J. Harding, BA BM BCh FRCS(Orth); Georgina Dempster; Wendy Bertram

United Kingdom

There is a strong correlation between sacral kyphosis (SK) and pelvic incidence (PI). Patients with a higher PI tend to have a higher SK, although outliers not following this pattern were noted. Patients that have a relatively high SK compared to PI have a potentially unfavourable sacral slope to pelvic tilt (SS/PT) ratio.

E-POSTER INDEX

383. Radiological and Clinical Results in Adult Lumbar and Thoracolumbar Scoliosis

Yutaka Sasao, MD, PhD; Yoshiaki Torii; Atsushi Kojima; Shigeta Marioka

Japan

We examined whether there was a relationship between lumbar and thoracolumbar scoliosis in the elderly with leg-length discrepancy (LLD) and low back pain and spinal alignment. Sagittal imbalance and pelvic obliquity with LLD were found to be risk factors for pain.

384. What Percentage of Adult Deformity Patients Have Cancellous Pedicle Channels?

Fernando E. Silva, MD; Lawrence G. Lenke, MD

USA

Pedicle channels in the scoliosis population have been classified as Type A - large cancellous channel; Type B - small cancellous channel; Type C - only a cortical channel; Type D - slit-like or absent channel. We radiographically reviewed a cohort of adult deformity patients consisting of various types of scoliosis as well as other deformities. Based on intraoperative assessment, determined the percent of pedicle types as well as their laterality, concave vs convex.

385. Primary Myopathy as an Underrecognized Cause of Adult Spinal Deformity

Anuj Prasher, MD; Sigurd H. Berven, MD

USA

The purpose of this paper is to present a series of cases of adult spinal deformity in which primary myopathy is the cause of deformity. This study is a descriptive study design with a case series of patients with atypical primary thoracolumbar scoliosis and evidence of paraspinal muscle atrophy and denervation.

386. Comparison of Clinical and Radiological Outcomes of Three Surgical Techniques in Scheuermann's Kyphosis

Ben Boreham, MB BCH FRCS(Orth); Ranganathan Arun, FRCS (Tr&Orth), DM, MRCS; Hossein Mehdian, MD, MS(Orth) FRCS(Ed)

United Kingdom

In all groups the compensatory lumbar curve reduced postoperatively, associated with a decrease in SI. This method of compensation, without causing junctional kyphosis, has not previously been reported.

387. Anterior-Posterior Spinal Fusion vs. Anterior-Posterior Fusion with Lumbar Pedicle Subtraction Osteotomy for Sagittal Imbalance due to the Degenerative Lumbar Kyphosis

Yongjung J. Kim, MD; Gene Cheh, MD; Seung-Chul Rhim, MD; Kyoungnam Kim, MS; Sally Pak, RN, BSN

USA

A clinical and radiographic assessment of 62 adult degenerative lumbar kyphosis patients who underwent APSF with LPSO (n=28) or without LPSO (n=34) from T9-L3 to S1 demonstrated that APSF with LPSO showed better restoration and maintenance of SVA in correcting partially flexible sagittal imbalance despite the longer operation time and larger blood loss without differences in SRS-outcome score.

388. Comparison of Radiographic Correction Between Schwab Type-3 and Type-4 Three-Column Osteotomies for Global Sagittal Imbalance

William Schairer; Alexandra Carrer, MD; Christopher P. Ames, MD; Vedat Deviren, MD

USA

Sagittal imbalance has been proven to cause major disability. Numerous osteotomy techniques can be utilized to restore neutral sagittal balance. A pedicle subtraction osteotomy (PSO) can be performed without (Schwab-3) or with (Schwab-4) suprajacent discectomy; type-4 has a theoretical advantage to achieve more correction. In this study, Schwab Type-3 and Type-4 osteotomies both resulted in similar correction of sagittal parameters, and no differences in blood loss or operative time.

389. Sagittal Spinopelvic Alignment Change after Anterior-Posterior Lumbar Spinal Fusion with or without Pedicle Subtraction Osteotomy for Sagittal Imbalance due to the Degenerative Lumbar Kyphosis: A Multicenter Analysis of 62 Patients without Revision Surgery

Yongjung J. Kim, MD; Gene Cheh, MD; Seung-Chul Rhim, MD; Sally Pak, RN, BSN; Kyoungnam Kim, MS

USA

62 adult patients with degenerative sagittal imbalance due to the degenerative lumbar kyphosis who underwent anterior and posterior spinal fusion with or without osteotomies from T9-L3 to S1 with a minimum of 2-year follow up demonstrated a significant improvement in radiographic parameters and functional outcome score.

390. Does Interbody Fusion at the Adjacent Disc Levels Reduce the Pseudoarthrosis Rate of Thoracolumbar and Lumbar PSO?

Meric Enercan; Alauddin Kochai; Sinan Kahraman; Cagatay Ozturk, MD; Ibrahim Ornek; Levent Ulusoy; Ahmet Alanay; Azmi Hamzaoglu, MD

Turkey

Pedicle subtraction osteotomy combined with interbody fusion at the adjacent disc levels provides satisfactory results and prevents pseudoarthrosis and implant failure.

E-POSTER INDEX

391. Pre-Operative Health-Related Quality of Life (HRQOL) in Scheuermann's Kyphosis Patients and Idiopathic Scoliosis Patients who underwent Surgical Fusion as an Adult

Raymund Woo, MD; Brian P. Hasley, MD; Mark D. Rahm, MD; Terry R. Trammell, MD; Robert W. Gaines, MD; W. F. Hess, MD; Hani Mhaidli, MD, PhD; Francisco Javier Sánchez Pérez-Gruoso; Thomas Ross, MS, RN; Mitsuru Yagi, MD, PhD; Oheneba Boachie-Adjei, MD; Complex Spine Study Group
USA

A multi-center retrospective review was done to evaluate the pre-operative health-related quality of life (HRQOL) of adult patients with Scheuermann's kyphosis and idiopathic scoliosis who underwent spinal fusion.

393. Expandable vs. Non-expandable Cage for Thoracic Vertebral Body Resection Performed through a Posterior Approach

Krzysztof Siemionow, MD; Sergey Neckrysh, MD
USA

Using an expandable cage during posterior thoracic VBR results in superior anterior column restoration and may reduce implant subsidence.

394. Radiographic Findings from a Single Site Investigating the Use of Extreme Lateral Interbody Fusion as a Treatment for Degenerative Lumbar Deformity at One-Year Follow-Up

Jim A. Youssef, MD; Douglas G. Omdorff, MD; Katie A. Patty, MS; Morgan A. Scott, MS
USA

Little evidence exists supporting the use of XLIF as an effective treatment for spinal deformity.

395. Combined Anterior-Posterior Fusion with Pedicle Subtraction Osteotomy for Degenerative Sagittal Imbalance

Yongjung J. Kim, MD; Gene Cheh, MD; Seung-Chul Rhim, MD; Kyoungnam Kim, MS; Sally Pak, RN, BSN
USA

Combined antero-posterior fusion with lumbar pedicle subtraction osteotomy for 28 patients with severe degenerative sagittal imbalance (SVA>8cm) demonstrated significantly better correction (15.7 cm) and maintenance (2.3cm loss) of SVA at the ultimate follow-up as well as SRS-22 outcome score without nonunion or revision surgery compared to previous studies.

396. Revision Surgery after Long Fusion for Adult Spinal Deformity

Hiroki Hirabayashi; Mark Weidenbaum, MD
Japan

Thirteen patients from a group of 35 patients undergoing long fusion for adult spinal deformity were studied. Reoperation rates and reasons for revision surgery in this adult deformity population were consistent with previous studies. Fusions ending at T2 proximally or L4 distally went on to require more revisions than when fusions ended at other levels. These risk factors may affect adjacent level problems, pseudoarthrosis, and implant-related problem.

397. Multimodality Spinal Cord Monitoring in Adult Deformity Surgery

Tim Hammett, MRCS; Ben Boreham, MB BCh FRCS(Orth); Hossein Mehdian, MD, MS(Orth) FRCS(Ed)
United Kingdom

The majority of literature available on Spinal Cord monitoring (SCM) relates to its use in Adolescent deformity surgery. We present our experience of SCM in the adult population. SCM is feasible but of reduced reliability in this population.

398. The Patient's Perspective on the Outcome of Surgery for Lumbar Degenerative Scoliosis

Frank S. Kleinstueck, MD; Peter Buddenberg, MD; Tamas F. Fekete, MD; Urs M. Mutter; Francois Porchet; Dezsoe J. Jeszenszky, MD; Anne F. Mannion, PhD
Switzerland

Few studies have evaluated patient-orientated outcomes after surgery for lumbar degenerative scoliosis; most examine outcome only from clinical and radiological perspectives. In this study of 176 consecutive patients (undergoing decompression ± fusion), despite the high complexity of the disease patient-orientated outcomes at 12 months postoperatively (70-80% successful, using multidimensional outcome instruments) were similar to those reported for conditions such as lumbar stenosis and degenerative spondylolisthesis. Further analyses are warranted to identify baseline variables predicting the 20-30% cases with poor outcome.

399. Modified Pedicle Subtraction Osteotomy in Management of Angular Kyphosis

Ketan S. Khurjekar, MBBS, MS (Ortho), MCh
India

In this prospective study the correction achieved by modification of pedicle subtraction osteotomy in managing angular kyphosis is assessed. Doing one stage modified subtraction osteotomy correction at the apex for angular kyphosis results in good clinical and functional outcome. Neurological complications were low with above technique. Radiological kyphosis angle correction was 65% although long term follow-up to assess loss of correction will be essential.

E-POSTER INDEX

400. Anterior Longitudinal Ligament Release Using the Minimally Invasive Lateral Retroperitoneal Transpoas Approach: Cadaveric Anatomic Study and Report on Four Clinical Cases

Armen R. Deukmedjian, MD; Juan S. Uribe, MD
USA

The purpose of this study is to demonstrate the feasibility and early clinical experience of anterior longitudinal ligament release for sagittal imbalance during the lateral retroperitoneal transpoas approach, as well as to describe its surgical anatomy in the lumbar spine. The structures at most immediate risk are the aorta, inferior vena cava, common iliac vessels, and sympathetic plexus. 4 clinical cases are examined including pre- and post-operative images and outcomes.

401. A Novel Method for Sacroiliac Fixation in the Treatment of Adult Degenerative Scoliosis

Ali H. Mesiwala, MD; John J. DeVere, PA-C
USA

Sacroiliac pain is a common problem following fusions that cross the lumbosacral junction. The use of traditional pelvic instrumentation does not protect against degenerative sacroiliitis. We present a technique that uses triangular-shaped, coated titanium implants to fixate and fuse the sacroiliac joint at the time of the initial deformity correction surgery.

402. Stand Alone Interbody Fusion through Lateral Approach for Adult Scoliosis Correction: Two Years Follow-Up

Luis Marchi, MSc; Leonardo Oliveira, BSc; Rodrigo A. Amaral; Carlos A. Castro; Thiago Coutinho; Etevaldo Coutinho; Luiz Pimenta, MD, PhD
Brazil

The purpose of this paper is to present the clinical and radiographic results of minimally invasive approach for the treatment of adult scoliosis

403. Quantitative Analysis of Key Muscles of the Thoraco Lumbar Spino-Pelvic Complex: 3D Geometry and Homogeneity

Bertrand Moal, MS; Frank Schwab, MD; Jose G. Raya; Benjamin Blondel, MD; Erwan Jolivet; Virginie Lafage, PhD; Wafa Skalli, PhD
USA

Using MRI with the Dixon methods, the fat infiltration and 3D reconstruction of the muscles involved in the thoraco lumbar spino-pelvic complex was obtained for two volunteers. Reproducibility study was achieved with 3 operators and 3 sessions. Data demonstrated the reconstruction's accuracy with Dixon images and an excellent inter- and intra reliability. It will therefore be possible to apply this protocol to characterize the role of muscles in postural balance and to evaluate the impact of spine surgery on muscle.

404. Sagittal Alignment Correction following Minimally Invasive Lateral Fusion with Hyperlordotic Cages

Luis Marchi, MSc; Leonardo Oliveira, BSc; Rodrigo A. Amaral; Carlos A. Castro; Thiago Coutinho; Etevaldo Coutinho; Luiz Pimenta, MD, PhD
Brazil

The purpose of this paper is to present a lateral retroperitoneal minimally invasive option for the treatment of iatrogenic or degenerative sagittal imbalance.

405. MIS Surgical Technique Combined Mini-ALIF Technique in Correction of Adult Degenerative Scoliosis

Xuesong Zhang, MD; Yonggang Zhang, PhD; Yan Wang, MD
China

Adult degenerative scoliosis is a condition with increasing prevalence and medical and socioeconomic importance. Surgery is fraught with a significant complication rate in an elderly multimorbid patient population.

406. Far-Lateral Interbody Fusion (FLIF): A Less Invasive Muscle Sparing Technique for Complex Degenerative Scoliosis

Laury A. Cuddihy, MD; Joel Gorenstein, R-PAC; Jeffery M. Schwartz, MD; Allison Rovillos, RN, CNOR; Claire D. Butz; M. Darryl Antonacci, MD
USA

The Far-Lateral Interbody Fusion technique (FLIF) provides for a novel and innovative approach to complex degenerative scoliosis. It takes advantage of a modified-Wiltse less invasive, muscle-sparing approach which results in excellent surgical correction as well as decreased hospital length of stay, decreased surgical time and decreased blood loss vs. traditional subperiosteal paraspinous techniques.

407. Accuracy of Robotic Guidance for S2-Alar-Iliac Screws in Spinal Deformity Correction

S. Samuel Bederman, MD, PhD, FRCSC; Peter Hahn, BS; Vincent Colin, MD
USA

For pelvic fixation involving long constructs in adult deformity cases, we showed that accuracy of S2AI screws under robotic guidance in long spinal constructs is acceptable and robotic guidance may be a useful tool for screw insertion.

408. Non-Fusion Dynamic Stabilization in Addition to Decompressive Laminectomy for Spinal Stenosis with Degenerative Lumbar Scoliosis

Soo Eon Lee; Tae-Ahn Jahng, MD, PhD
Republic of Korea

To analyze surgical outcomes after non-fusion stabilization in addition to decompressive laminectomy for spinal stenosis with a mild to moderate degree of degenerative lumbar scoliosis

409. Correction in the Sagittal Plane and Spinopelvic Parameters Following Standard Multilevel Lateral Lumbar Interbody Fusion*Luis Marchi, MSc; Leonardo Oliveira, BSc; Rodrigo A. Amaral; Carlos A. Castro; Thiago Coutinho; Etevaldo Coutinho; Luiz Pimenta, MD, PhD**Brazil*

Here we present the correction in the sagittal plane and spinopelvic parameters following stand-alone multilevel lateral lumbar interbody fusion.

410. Minimally Invasive Access for Thoracolumbar Vertebral Body Fractures - Corpectomy with Expandable Cage with Wide Endplate Contact Area*Luis Marchi, MSc; Leonardo Oliveira, BSc; Rodrigo A. Amaral; Carlos A. Castro; Thiago Coutinho; Etevaldo Coutinho; Luiz Pimenta, MD, PhD**Brazil*

The objective of this study was to describe and exemplify a MIS lateral option for the treatment of traumatic or osteoporotic thoracic and lumbar fractures.

Basic Science**412. Vitamin A Deficiency Induces Congenital Spinal Deformities In Rats***Zheng Li; Jianxiang Shen, MD**China*

To investigate the effect of maternal vitamin A deficiency on the formation of congenital spinal deformities in the offspring.

413. Coupled Symmetry and Proportional Expansion of the Ribs through Adolescence*Richard M. Schwend, MD; Laurel C. Blakemore, MD; Behrooz A. Akbarnia, MD; Julie L. Reigrot, MS; John A. Schmidt, PhD; Complex Spine Study Group**USA*

31 pediatric specimens (722 ribs) of various ages from the Hamann-Todd Human Osteology Collection were photographed to evaluate rib growth during childhood. Costal length and projected area defined by the shape of the rib were measured. Costal length showed constant linear growth while projected area growth accelerated throughout childhood. The middle ribs 4-8 had the fastest overall growth, with the greatest growth rate seen in the projected area of ribs 7 and 8 compared to rib 1.

414. Osteomalacia vs. Osteopenia in AIS*Guangquan Sun; Tsz-ping Lam, MB, BS; Kwong Man Lee, PhD; Bobby KW Ng, MD; Ling Qin; Yong Qiu; Jack C. Cheng, MD; Zezhang Zhu**Hong Kong*

This is the first study showing decreased bone matrix mineralization in AIS. Its associated low bone mineral density (BMD) can be related to an osteomalacic process.

415. Caudal Pedicle Screw Compression Optimizes Thoracic Kyphosis Correction: A Micro CT and Biomechanical Analysis of Pedicle Morphology and Screw Failure*Ronald A. Lehman, MD; Anton E. Dmitriev, PhD; Adam J. Bevevino, MD; Daniel G. Kang, MD; Melvin Helgeson, MD; Haines Paik, MD; Rachel E. Gaume, BS; Lawrence G. Lenke, MD**USA*

The results of our radiographic and biomechanical analysis illustrate the caudal pedicle to have a higher bone density and ability to withstand higher loads, before screw failure, during simulated cantilever bending. Therefore, consideration should be made to load the caudal pedicle during deformity correction.

416. Mitigating the Spinal Cord Distraction Injury: The In-Vitro effect of Durotomy in Decreasing Cord Interstitial Pressure (CIP)*Waleed Awwad, MD, FRCSC; Peter Jarzem, MD; Jean A. Ouellet, MD**Canada*

Spinal cord distraction may cause spinal cord injury through a Laplace's law elevation of cord interstitial pressure during cord tensioning. We determined that durotomy is effective in lowering the CIP and may be a useful intervention to restore function of the distraction injured spinal cord. Further work is required before using this technique clinically.

417. Bipedality as a Major Factor in Accelerated Intervertebral Disc Degeneration in Mice*Nadir Yalcin; Ozgur Dede, MD; Ibrahim Akel, MD; H Gokhan Demirkiran, MD; Emre Acaroglu, MD; Ralph Marcucio, PhD**Turkey*

Effects of bipedality on the histomorphological parameters of vertebral bodies and IVDs were investigated on a bipedal C57BL6 mice model, with a quadrupedal control group. Our findings suggest that bipedality may accelerate the age-related degenerative changes in the disc, but does not affect the vertebral histomorphology. These may form the basis of new treatment modalities overcoming the effects of bipedality and may provide a better understanding of pain syndromes in posture related conditions of the spine.

418. Functional Roles of HIF-1 α in Intervertebral Disc*Dong-Eun Shin, PhD**Republic of Korea*

In vitro study with Human's NP cells, HIF-1 α increased ATP generation and aggrecan gene expression whereas, the rate of apoptosis is reduced. In vivo study with rabbits, degenerative changes in HIF-1 α insertion group were less severe than in control group on MR image and histologic study. We expect that degenerative changes of the inter-vertebral discs would be reduced by injecting HIF-1 α into the inter-vertebral discs.

E-POSTER INDEX

419. Effect of Pedicle Screw on Spinal Canal Development in an Immature Porcine Model

Xuhui Zhou, MD; Hong Zhang, MD; Daniel J. Sucato, MD, MS; Charles E. Johnston, MD
USA

It is still controversial regarding the effect of the pedicle screw on spinal canal development in an immature spine. In an immature porcine model, the pedicle screw which crossed the neurocentral synchondrosis (NCS) resulted in a 56% decrease of the hypertrophic zone and a 33% decrease of the hypertrophic cell height to create a 97% NCS fusion rate. These caused a 25% decrease in spinal canal dimension.

420. Effect of Anterior Vertebral Body Screw Placement on Development of Spinal Canal in an Immature Porcine Model

Xuhui Zhou, MD; Hong Zhang, MD; Daniel J. Sucato, MD, MS
USA

Anterior vertebral body screws can damage the neurocentral synchondrosis (NCS) and may cause a decrease in the spinal canal dimension. In an immature growing porcine model, the anterior vertebral body screw which crossed the NCS resulted in a 39% decrease of the hypertrophic zone and a 22% decrease of the hypertrophic cell height to create a 71% NCS fusion rate. These caused a 17% decrease in the spinal canal dimension.

421. Substance P Stimulates Production of Inflammatory Cytokines in Human Disc Cells

Christopher K. Kepler, MD, MBA; Dessimilava Z. Markova, PhD; Alan S. Hiltbrand, MD; Alexander R. Vaccaro, MD, PhD; Todd J. Albert, MD; D. Greg Anderson, MD
USA

Substance P (SP), a nociceptive neurotransmitter, regulates inflammation in other parts of the body but its role in the intervertebral disc has not been characterized. We demonstrated expression of SP and its receptors in human disc cells. Treatment of disc cells with SP caused upregulation of cytokines and other inflammatory mediators. SP influences the inflammatory phenotype of disc cells; Substance P may provide a medium for "crosstalk" between disc cells and neurons in the intervertebral disc.

422. Does BMP-2 Really Cause Cancer? A Systematic Review of the Literature

Samuel K. Cho, MD; Steven M. Koehler, MD
USA

Of 93 studies that examined the role of BMP-2 in cancer, there was no evidence of BMP-2 causing cancer de novo. However, 46% of studies suggested BMP-2 enhances tumor function, motivating further research on this clinically important topic.
The FDA has not cleared the drug and/or medical device for the use described in this presentation (i.e., the drug or medical device is being discussed for an 'off label' use).

423. Decompressive Facetectomies and Lumbar Instability: When do we Need to Instrument? A Computational Study

Divya V. Ambati, MS; Ronald A. Lehman, MD; Anton E. Dmitriev, PhD; Daniel G. Kang, MD
USA

Decompressive facetectomy exceeding 75% on one or both sides of the joint leads to segmental instability in torsional loading and posterior extension. When extensive facet resection is required, the use of supplemental fixation should be considered to improve operative level biomechanics.

424. Nucleus Pulposus Cells in 3D Culture in Cell-Responsive Poly(ethylene glycol) Hydrogels Exhibit Enhanced Phenotypic Gene Expression Compared to 2D Culture

Dominique A. Rothenfluh, MD, PhD; Kan Min, MD; Esin Rothenfluh
Switzerland

Analysis of gene expression of nucleus pulposus cells cultured in 3D cell-responsive PEG-hydrogels show enhanced gene expression vs. 2D culture, but dedifferentiation compared to the native phenotype.

425. Pedicle Subtraction Osteotomy and Anterior Lumbar Interbody Fusion in Lumbosacral Levels: An In-Vitro Biomechanical Evaluation

Benny Dahl, MD, PhD, DMSci; Manasa Gudipally, MS; Mark Moldavsky, MS; Saif Khalil, PhD
Denmark

The present study evaluated the biomechanical effect of lumbar pedicle subtraction osteotomy and anterior interbody fusion. A pedicle subtraction osteotomy was performed at L3 and anterior interbody spacers were inserted at L4/5 and L5/S1 levels with posterior instrumentation from T12-S1. The study concluded that adding interbody spacers to the long posterior instrumentation, after osteotomy has little impact on the biomechanical stability.

The FDA has not cleared the drug and/or medical device for the use described in this presentation (i.e., the drug or medical device is being discussed for an 'off label' use).

426. Reliability of the Thoracolumbar Injury Classification and Severity Score Among Orthopedic Surgeons at Different Levels of Training

Ronald A. Lehman, MD; Adam J. Bevevino, MD; Daniel G. Kang, MD; John P. Cody; Husain Bharmal; Patrick Jones, MD
USA

The Thoracolumbar Injury Classification and Severity Score demonstrated moderate to excellent reliability results when tested on orthopedic physicians at all levels of training.

427. Biomechanical Evaluation of 4 Different Foundation Constructs Commonly Used in Growing Spine Surgery: Are Rib Anchors Comparable to Spine Anchors?

Behrooz A. Akbarnia, MD; Burt Yazsay, MD; Muharrem Yazici, MD; Nima Kabirian, MD; Kevin Strauss, ME; Diana A. Glaser, PhD; Complex Spine Study Group
USA

In an in-vitro, porcine study, comparing four different upper foundations, posteriorly applied loads showed Rib Hook anchors and Spine Screws failed at the highest ultimate loads. Despite having lower ultimate loads, Spine Hook anchors showed less variable results.

The FDA has not cleared the drug and/or medical device for the use described in this presentation (i.e., the drug or medical device is being discussed for an 'off label' use).

428. Do Ponte Osteotomies Affect the Biomechanical Consequences of Rod Reduction in the Thoracic Spine?

Daniel G. Kang, MD; Ronald A. Lehman, MD; Adam J. Bevevino, MD; Rachel E. Gaume, BS; Melvin Helgeson, MD; Joseph P. Hoppel; Anton E. Dmitriev, PhD
USA

The use of a rod persuasion device has been found to decrease pedicle screw fixation strength. We hypothesized Ponte osteotomies to increase segmental flexibility may offset forces from rod-screw manipulation. Despite Ponte osteotomies, there was a significant decrease in pedicle screw pullout strength following the rod reduction technique.

429. Isolation of Mesenchymal Stem Cells Expressing BMPs from Vertebra and Iliac Crest during Spinal Fusion

Tung T. Nguyen, MD; Gary D. Fleischer, MD
USA

Mesenchymal stem cells were obtained in vertebra and iliac crest bone marrow. These cells were able to differentiate into osteoblasts, and expressed BMP-2 and BMP-7.

430. Rib Asymmetry in an Experimental Idiopathic-Like Scoliosis Model

Xuhui Zhou, MD; Hong Zhang, MD; Daniel J. Sucato, MD, MS
USA

A single right thoracic scoliosis was created via hemi-epiphysiodesis of the vertebral neurocentral synchondrosis in a growing pig model. The dimension of the rib was measured at the different stage of the scoliosis. There were no differences in the rib between the concavity and convexity at the early stage of the scoliosis (35°). The rib asymmetry was seen at the late stage of the scoliosis (46°) in which the rib dimension was 4-15% greater on the concavity. The rib asymmetry is secondary to the scoliosis rather than playing a primary role in the etiology of the scoliosis.

431. Histological Characterization of the Cartilaginous Endplate in the Infant Spine

Ryan P. Farmer, MSc; Rachel C. Paietta; Virginia Ferguson, PhD; Evalina L. Burger, MD; Vikas V. Patel, MD
USA

The purpose of this study was to characterize the compositional gradients between bone and cartilage within the osteochondral interface region of developing thoracic and lumbar spine segments using immunohistochemistry techniques and scanning electron microscopy.

432. Micro-CT Analysis of Porcine Scoliosis Model Induced by Unilateral Tendon Tethering

Richard E. McCarthy; Michael H. McCarthy, BA; Dong Sun
USA

Scoliosis was produced in a porcine model using a unique tendon tethering technique with vertebral remodeling noted at the apex. We analyzed these vertebrae with micro-CT and noted increased volume of bone density along the concave side.

433. A Novel Spinal Cord Injury Model for Distractive Forces Occurring During a Vertebral Column Resection

Daniel J. Sucato, MD, MS; Jennifer E. Bell, BS; Jennifer Seifert, PhD; Mario I. Romero-Ortega, PhD
USA

This study demonstrates the establishment and characterization of an in vivo model of distraction spinal cord injury (SCI) that closely duplicates the IONM changes that occur during vertebral column resection (VCR).

434. Biomechanical Review of the Rod-Screw Interphase in withstanding Rotational Torque - A Comparison between Different Spinal Systems

Chris Yin Wei Chan, MS (Orth); Premganesha Ganaisan, MB, BS; Lim Beng Saw, MS (Orth); Mun Keong Kwan, MS (Orth); Chung Chek Wong, MS (Orth)
Malaysia

Derotation techniques in scoliosis surgery rely on stability of the screw bone interface or the rod screw interface. This is a biomechanical investigation into six different spinal systems and was tested for the ability of the rod screw interface in withstanding rotational torque. Significant differences exist between the systems. Spinal systems utilizing 6.0mm rods fared better in withstanding rotational torque compared with systems utilizing 5.0mm rods. A curved locking nut design was found to contribute towards higher rotational stability.

435. Psychological Aspects of Scoliosis Surgery in Children

Ryszard Tomaszewski; Magdalena Janowska
Poland

The purpose of the study is to estimate the strength of individual beliefs conditioning the management of pain (internally), the influence of staff on the management of pain (the influence of others) as well as accidental factors. Also, the objective is to estimate the level of internal and external expression of anger and to estimate the mood of a child before and after the surgery.

E-POSTER INDEX

436. Effects of Pilot Hole Diameter on Pedicle Screw Pull Out Strength

Khaled Kebaish, MD; Mark D. Rahm, MD; Julie L. Reigrot, MS; John A. Schmidt, PhD; Complex Spine Study Group
USA

Pedicle screws were inserted into seven pilot hole sizes in three densities of ASTM standard foam then tested for axial pull out failure. Nonlinear regression analyses were completed on insertion torque and maximum pull out load measurements for each test. Pull out strength consistently displayed a parabolic relationship with pilot hole diameter. Results suggest there is an optimal pilot hole diameter for a given screw diameter and that oversized and undersized pilot holes can decrease holding power.

437. The Biomechanical Consequences of Rod Reduction Following Facetectomy in the Lumbar Spine

Ronald A. Lehman, MD; Adam J. Bevevino, MD; Daniel G. Kang, MD; Melvin Helgeson, MD; Rachel E. Gaume, BS; Joseph P. Happel; Anton E. Dmitriev, PhD
USA

This human cadaveric biomechanical analysis demonstrated that use of a rod reduction tool in the lumbar spine decreased the pull out strength of pedicle screws.

438. The Association Study between the Polymorphism of SNAP23 Gene and Degenerative Disc Disease of the Lumbar Spine in Northern China

Yipeng Wang, MD; Bin Yu, MD; Guixing Qiu
China

We performed a study on the association between SNAP23 polymorphic phenotype and lumbar degenerative disc disease (DDD), and the results showed that genetic variants of SNAP23 gene may be associated with lumbar DDD in a northern Chinese Han population.

439. Porcine Scoliosis Model Induced by Allograft Tether via Pedicle Rib Interval

Richard E. McCarthy; Dong Sun; Raghu H. Ramakrishnaiah, MBBS, FRCS; Michael H. McCarthy, BA
USA

A novel treatment for early adolescent scoliosis has been tested on pigs where an allograft tendon was placed in the pedicle rib interval (PRI) to act as a tether. Scoliosis was produced without creating lordosis or violation of the chest cavity. X-rays and CT analysis confirmed the findings.

440. Biomechanical Evaluation of Screw Strain Concentration in the Cephalad Screw in a Posterior Fusion Construct

Gary D. Fleischer, MD; Tung T. Nguyen, MD; Andrew L. Freeman, MS; Lisa Ferrara, PhD; James Malcolm, MD
USA

This study investigated the strain concentrating effect of varying length posterior fixation with regard to the cephalad screw in the construct. The pedicle screws at L4, L5, and S1 were instrumented with strain gages to measure bending moments in 6 different treatment groups consisting of progressively shorter fusion constructs from L2-S1 posterior fixation + threaded axial rod (TAR). Data were analyzed to determine the concentrating effect on bending moments in the cephalad screw and correlated to ROM quantified between the vertebral bodies.

441. Improvement of Intertrochanteric Bone Quality in Osteoporotic Female Rats after Injection of PLGA/Col Microspheres Combined with BMSCs

Zhengrong Yu; Cody E. Bunger; Shalu Sharma, MPT
Denmark

The current bone-repair and bone-substitute materials that can promote the reconstruction of trabecular bone and improve the mechanical strength of osteoporotic site are few. In this research we produced PLGA/Col micro-spheres combined with BSCs. We found this material could repair bone defect more quickly, promote the trabecular reconstruction and improve the bone quality in osteoporotic rats.

442. Use of Standardized Materials in Biomechanical Comparisons of Pedicle Screws

Mark D. Rahm, MD; Khaled Kebaish, MD; Julie L. Reigrot, MS; John A. Schmidt, PhD; Complex Spine Study Group
USA

Variation in bone density between specimens can project a linear correlation between pull out strength and insertion torque that may not exist if screws were tested in a standardized material. Seven unique pedicle screws were tested for axial pull out in various densities of ASTM standard foam. When a range of material densities is tested there is little variability in the pull out strength/insertion torque correlation between screw types. When a single density is chosen, there is a notable difference.

443. Experimental Lumbar Spine Fusion with Beta Tricalcium Phosphate Ceramic Composite Graft and Bone Marrow Aspirate

Matthew E. Cunningham, MD, PhD; Paul D. Kiely, MCh FRCS (Tr&Orth); Fadi Taher, MD; Celeste Abjomson, PhD; Frank P. Cammisa, MD
USA

Experimental rabbit fusion model using synthetic Beta Tricalcium Phosphate Ceramic Composite Graft and Bone Marrow Aspirate demonstrated comparable fusion to autologous bone graft (ABG).

444. Characterization of Lumbar Vertebral Calcified Fibrocartilage before and after Intervertebral Fusion Preparation

Sarina Sinclair, PhD; Michael D. Daubs, MD; Brandon Lawrence, MD; Darrel S. Brodke, MD; Alpesh A. Patel, MD
USA

Calcified fibrocartilage (CFC) is a distinct tissue layer found throughout the body at the junctions between bone and soft tissues. There is limited information on this tissue layer of the spine. This study showed that the CFC layer was thickest at the most anterior and posterior areas of the vertebrae within the native lumbar spine. The data also demonstrated that while current endplate preparation techniques decreased the amount of CFC, it was not efficiently removed with standard techniques.

445. Biomechanical Comparison of Short-Segment Fixation Methods to Treat Thoracolumbar Burst Fractures

Jacob M. Buchowski, MD, MS; Hani Mhaidli, MD, PhD; Julie L. Reigrot, MS; John A. Schmidt, PhD; Complex Spine Study Group
USA

A repeatable vertebral column model was built to test short-segment fixation methods for thoracolumbar burst fractures. Three model types were tested to collect a variety of axial and torsional characteristics. Results indicate that index-level pedicle screws affect the short-segment constructs, particularly in peak torque and maximum compressive load. In terms of construct stiffness, index-level screws do not have a statistically significant impact. The models implemented are thought to be a viable option for future biomechanical testing.

446. Intralaminar Fixation in the Lower Lumbar Spine as a Biomechanically Sound Alternative to Pedicle Screws

Divya V. Ambati, MS; Ronald A. Lehman, MD; Anton E. Dmitriev, PhD; Daniel G. Kang, MD
USA

The current computational study utilized a validated finite element model (FEM) of the human lumbar spine to study post-reconstruction kinematics afforded by intralaminar fixation across L4-5 vs. pedicle screws. Our results indicate that, from the biomechanical perspective, intralaminar screw anchoring presents a viable alternative to transpedicular fixation, and may be most promising in patients with low BMD

447. Hoes Does Posterior Lumbar Surgery Affect the Paravertebrae Muscles? Cellular and Histochemistry Study

Angel Escamez-Perez; Cesar Hernandez-Garcia; Francisco Gil-Cano; Rafael Latorre-Reviriego
Spain

The aim of this cellular and histochemistry study is to clarify the muscular tissue condition after a posterior approach surgery to treat a degenerative disease in the lumbar spine.

448. Cadaveric Evaluation of Percutaneous Lumbar Pedicle Screw Placement using Oblique View vs. Lateral

Antoine G. Tohmeh, MD
USA

A laboratory evaluation of bi-cortical screw placement and the use of CT imaging for accuracy

449. In vivo Lumbar Facet Joint Articular Morphology using NURBS-Based Geometry Modelling: A Feasibility Study

Vikas Kaul, MS; Jwalant S. Mehta, FRCS (Orth); Hassan Serhan, PhD; Robert W. Gaines, MD; Vijay K. Goel, PhD
USA

This study was to performed to determine the feasibility of the process of measuring facet articular area. A 3D models of an object, the analogue facet joint, and the human facet joint were generated. Next, the software (3D-Doctor) was used to create 3D objects in the facet joint articular space. The accuracy of the dimensions of the regular object was < 1%. Surface area and volume of the analogue facet joint articular spaces were then computed.

Cervical Deformity**450. Spinopelvic Balance and Cervical Alignment: Analysis of Occipitocervical and Spinopelvic Interdependence and Implications for Clinical Use**

Susana Núñez Pereira, MD; Wolfgang Hitzl, PhD, MSc; Luis Ferraris, MD; Oliver Meier, MD; Juliane Zenner, MD; Michael Mayer, MD; Heiko Koller, PD Dr.med
Germany

Interdependencies between suboccipital, subaxial cervical spine sagittal parameters and spinopelvics alignment were studied in 145 patient's x-rays. Significant correlations were found between C0-C2, C2-C7 and C7-slope. C7 slope correlated with sacral slope grossly reflecting the given spinopelvic balance.

451. Can Long Fusions Crossing the Cervicothoracic Junction Have Good Outcomes at a Minimum Two Years Follow-Up?

Han Jo Kim, MD; Lawrence G. Lenke, MD; Addisu Mesfin, MD; Stuart Hershman, MD; Jeremy L. Fogelson, MD; Brenda A. Sides, MA
USA

When indicated, fusions which extend across the cervicothoracic junction can lead to excellent correction of spinal deformities with significant improvement in SRS outcome scores and relatively low complication rates.

E-POSTER INDEX

452. Cervical Spine Fusion in Patients with Rheumatoid Arthritis: A US Experience from 1992 to 2008

Benjamin E. Stein, MD; Hamid Hassanzadeh, MD; Amit Jain; Mesfin Lemma, MD; David B. Cohen, MD; Richard L. Skolasky, ScD; Khaled Kebaish, MD
USA

The need for spine surgery is a marker of disease severity in rheumatoid arthritis. In tandem with the improvement of medical management of RA with biologics, there has been a relative decrease in the rate of atlantoaxial and posterior cervical fusion compared to patients without RA.

453. Cervical Fusion in Children: A Fifteen Year Experience

Jonathan H. Phillips, MD; Patrick B. Wright, MD
USA

Cervical fusion for treatment of pediatric cervical instability or deformity.

454. Predictive Formula for Calculation of Reciprocal Changes in Cervical Spine Alignment after Corrective Thoracolumbar Deformity Surgery

Yoon Ha, MD, PhD; Christopher I. Shaffrey, MD; Justin S. Smith, MD, PhD; Virginie Lafage, PhD; Frank Schwab, MD; Gregory M. Mundis, MD; Christopher P. Ames, MD
Republic of Korea

The purpose of this study is to develop a predictive formula which may be beneficial in planning the effect of thoracolumbar realignment surgery on the cervical spine. We identified the formula that postoperative cervical lordosis (C2-7 angle) = $11.851 + 0.440 * \text{preopC2-7 angle}(O) - 0.290 * (\text{pelvic tilt [PT]-25}) - 0.072 * \text{preopSVA}(\text{mm}) + 0.260 * \text{preopT1 slope}(O)$.

This equation can predict postoperative cervical spine sagittal alignment with reasonable accuracy and may be useful for preoperative planning.

455. Rotatory Atlanto-axial Subluxations in Children: A Study of 15 Cases

Sandip Chatterjee, FRCS(SN), MNAMS(NS)
India

This is a study of 15 cases of rotatory atlantoaxial subluxations in the paediatric age group from January 2000 till June 2011. All these cases were evaluated clinicoradiologically by means of CT and MRI scans and diagnosis was made using the criteris laid out by Li and Pang in 1994. Only 5 of our patients had any significant trauma, 7 had tuberculous infections, and 3 presented after ENT procedures.

456. Minimally Invasive Treatment of the Aneurismal Bone Cyst of C2

Paulo José S. Ramos, MD; Francisco S. Godinho, MD; Ricardo P. Meirelles, MD; Andre Luiz L. Barcellos, MD
Brazil

We present three giant aneurismal bone cyst of C2 sucessfully treated with calcitonin and prednisolone injections in regard to neurological and mechanical stability and recurrence of the disease after a maximum of 11 years follow-up.

The FDA has not cleared the drug and/or medical device for the use described in this presentation (i.e., the drug or medical device is being discussed for an 'off label' use).

Cervical Reconstruction

457. Anterior Cervical Pedicle Screw and Plate Fixation – Clinical Outcomes, Complications and Screw Placement

Yasutsugu Yukawa, MD; Fumihiko Kato, MD; Keigo Ito; Masaaki Machino; Shunsuke Kanbara; Daigo Morita
Japan

Anterior procedures in the cervical spine are feasible in cases of anterior neural compression and/or kyphotic deformity. Conventional anterior plates are used, but not adequately durable. We have, therefore, developed a new anterior pedicle screw and plate fixation procedure using the fluoroscope-assisted pedicle axis view imaging technique. This procedure provided good clinical outcomes and accurate screw placement. Anterior pedicle screw and plate fixation is not considered as a routine surgical procedure but useful in selected cases of multi-segmental anterior reconstruction of cervical spine.

The FDA has not cleared the drug and/or medical device for the use described in this presentation (i.e., the drug or medical device is being discussed for an 'off label' use).

458. Surgical Cervical Reconstruction with Pedicle Screw Fixation for Traumatic Cervical Instability

Masashi Uehara, MD; Jun Takahashi, MD
Japan

Summary (80 words): Cervical reduction and fixation are required in cases of cervical fracture-dislocation with instability. We evaluated the surgical results of cervical pedicle screw (CPS) fixation using a computed tomography (CT)-based navigation system for the treatment of traumatic cervical instability. This method improved clinical and radiological results in patients with traumatic cervical instability, without instrument-related neurovascular complications. We could demonstrate that this method is an effective surgical procedure for patients with traumatic cervical instability.

459. Stand Alone Cage vs. Graft-Plate Construction in Anterior Cervical Fusion

Mohamed F. Alhashash, MD; Joseph W. Iskander; Heinrich Boehm

Germany

40 patients randomized in a prospective study comparing 2 fusion techniques. 20 patients had anterior cervical fusion with graft and plate and 20 patients had stand alone cages with minimally invasive harvested iliac graft. Mean follow up of 25.5 months, there were no significant radiological differences. Intraoperative profile was significantly better with cages (OP time and bleeding). Iliac graft pain was significantly more in the graft and plate group

460. Direct Posterior Distraction for Unreducible Cranial Settling, Surgical Technique and Review of Case Series

Krzysztof Siemionow, MD; Sergey Neckrysh, MD

USA

Direct posterior distraction between occiput and C2 screw offers a safe and reproducible way of restoring occipito-cervical alignment in patients with cranial settling who failed preoperative traction.

The FDA has not cleared the drug and/or medical device for the use described in this presentation (i.e., the drug or medical device is being discussed for an 'off label' use).

461. Adjacent Segment Degeneration after Posterior Fusion of the Cervical Spine

Andrew S. Lee, MD, PhD; Wellington Hsu, MD; Jeffrey S. Earhart, MD; Daniel L. Cherkassky

USA

This retrospective, radiographic review to examine development of adjacent segment degeneration after posterior fusion of the cervical spine revealed that radiological degradation of adjacent segment may affect in a certain portion of patients in years after the procedure.

462. Does Maintenance/Restoration of Cervical Lordosis Improve Outcome after ACDF?

Isador Lieberman, MD MBA FRCSC; Xiaobang Hu, PhD

USA

The results of 54 one or two level anterior cervical discectomy and fusion (ACDF) surgeries were reviewed and the relationship between cervical lordosis maintenance/restoration and patients' clinical outcome was analyzed. We found that maintenance/restoration of cervical lordosis does not significantly contribute to one or two level ACDF patients' clinical outcome.

463. Novel Anterior Decompression and Fixation Technique ("Hybrid Technique") vs. Plated Three-Vertebrae Corpectomy for the Four-Segment Cervical Myelopathy

Seiichi Odate, MD; Jitsuhiko Shikata, MD, PhD; Hiroaki Kimura, MD, PhD; Tsunemitsu Soeda, MD, PhD

Japan

Multilevel corpectomy weakens the initial stability of the fixed segment, and reported to have a high complication rate. The study compared the outcomes of two different anterior procedures for four-segment cervical myelopathy. We successfully applied a hybrid technique (plated two-vertebrae anterior cervical corpectomy combined with adjacent one-level discectomy and stand-alone intervertebral cage fixation) to 39 patients who required four-segment cervical decompression and fusion with the extreme low complication rate comparing with plated three-vertebrae corpectomy.

464. En Bloc Cervical Laminoplasty Using Trans-laminar Screw (T-laminoplasty): New Procedure of Cervical Laminoplasty

Soo Eon Lee; Tae-Ahn Jahng, MD, PhD

Republic of Korea

The authors have newly developed an en bloc cervical laminoplasty procedure using a trans-laminar screw (T-laminoplasty) to preserve the posterior midline structures so as to maintain spinal stability and minimize postoperative axial pain and postoperative kyphotic deformity.

Complications/Infections**466. SRS Outcome Scores are Sensitive to Both the Occurrence and Resolution of a Complication in the Surgical Treatment of AIS**

Burt Yazbay, MD; Tracey Bastrom, MA; Carrie E. Bartley, MA; Michelle C. Marks, PT, MA; Peter O. Newton, MD; Harms Study Group

USA

The SRS questionnaire appears to be sensitive to complications. At 2 years post-op, those patients experiencing a complication have worse results than those who had no complication or a complication that has resolved. Patients who had a complication resolve have similar outcome scores to those who never had a complication.

467. Recurrent Stenosis Following Transforaminal Interbody Fusion (TLIF) Using Bioresorbable Cages and Bone Morphogenic Protein

Jeffrey D. Coe, MD; Michael W. Cluck, MD, PhD

USA

The use of BMP is associated with heterotopic bone formation and post-operative complications. In this study, we followed patients treated with TLIF procedures and ICBG or BMP for a minimum of 2 years post op to determine the reoperation rate. Nearly 20% of patients treated with TLIF and BMP required revision surgery for repeat stenosis at the previously operated level(s). Conversely, no patients treated with TLIF and ICBG required repeat surgery for recurrent stenosis.

The FDA has not cleared the drug and/or medical device for the use described in this presentation (i.e., the drug or medical device is being discussed for an 'off label' use).

E-POSTER INDEX

468. Use of Percutaneous Pedicle Screw Fixation in Spine Infections: Clinical Outcome Assessments

Ahmed Mohamed Abdelhai, MS Orth; Chee Kidd Chiu, MBBS, MSOrth; Chris Yin Wei Chan, MS Orth; Lim Beng Saw, MS Orth; Mun Keong Kwan, MS (Orth); Abdul Malik Mohamed Hussein, MBBS(MAL), FRCS Sudan

Twenty patients with spinal infection associated with instability and neurological deficit, treated with debridement through a minimally invasive approach followed by percutaneous pedicle screw stabilization were reviewed. The postoperative clinical results including the neurological recovery were significantly better with a good union rate. Percutaneous pedicle screw stabilization with debridement through a minimally invasive approach is a feasible technique in the management of spinal infection.

469. Analysis of Demographic and Surgical Factors Influencing the Incidence of Infection Following Spinal Surgery

Tate M. Andres, BS; Richelle C. Takemoto, MD; Pedro A. Ricart Hoffiz, MD, MS; Virginia Lafage, PhD; Thomas Errico; Baron S. Lonner USA

Surgical site infection (SSI) is a constant concern for clinicians in the context of spine surgery. Following a prospective, randomized comparison of two prophylactic antibiotic protocols, data was evaluated to identify possible demographic and surgical risk factors for infection.

470. The Difference of Surgical Site Infection According to the Methods of Spinal Fusion Surgery

Dongki Ahn, MD; Dae-Geun Kim Republic of Korea

Reviewing the 10 year cases of spinal fusion surgeries, the rate of surgical site infection was higher in PLIF(1.37%) than PF or PLF(0.3%). The major type of infection in PLIF was deep osteomyelitis around interbody cages while wound infection was dominant in PF or PLF. The higher risk of infection in PLIF was attributable to contamination of auto-local bone and interbody space where irrigation could not reach.

471. Routine Sectioning of the C2 Nerve Root and Ganglion for C1 Lateral Mass Screw Placement in Children: Surgical and Functional Outcomes

Steven W. Hwang, MD; Akash Patel, MD; Loyola V. Gressot, MD; Jerome Boatey, MD; Alison Brayton, RN; Andrew Jea, MD USA

We report the functional outcomes and complications following routine sectioning of the C2 nerve root and ganglion in a pediatric cohort. No patient reported new onset occipital neuralgia or numbness in the C2 distribution that would interfere with daily living. This technique may be responsible for favorable operative times, EBL, and LOS in children undergoing C1 lateral mass screw insertion. Sectioning of the C2 nerve root and ganglion did not negatively affect functional outcome in these patients.

473. A Novel Targeting Therapy for Paraspinal Muscle MRSA Infection by Vancomycin-Included Nanocarrier

Tetsuya Kuramoto; Ken Ishii, MD, PhD; Shigenori Nagai; Haruki Funao; Masahiko Hirai; Aya Sasaki; Yoshiomi Kobayashi; Mamoru Aizawa, PhD; Yasunori Okada; Kazuhiro Chiba, MD, PhD; Shigeo Koyasu; Yoshiaki Toyama; Morio Matsumoto, MD Japan

Sialyl Lewis X on the leukocytes recognizes its ligand E-selectin, resulting in the leukocytes migration to the extravascular infection sites. Utilizing this mechanism, we have established a drug delivery system using E-selectin targeted liposome encapsulating vancomycin (VC-Lip). In vivo, mice with MRSA infection in the paraspinal muscle received VC, VC-Lip (approximately 1/1000 smaller dose than VC), or Lip (no VC) intravenously. VC-Lip was effective for suppression of infection. This therapeutic strategy can be a safe, effective alternative to standard administration of VC.

474. Consideration of Pedicle Screw Misplacement on a Per Patient Basis: Can We Better Delineate Surgical Risk?

Vishal Sarwahi, MD; Preethi M. Kulkarni, MD; Beverly Thornhill, MD; Jonathan J. Horn; Terry D. Amaral, MD; Adam L. Wallowick, MD USA

Evaluation of screw placement using a novel classification system found 40% of patients with potentially significant screw misplacement. A discrepancy exists between the estimated 10% screw misplacement rate and the number of patients with potential screw related morbidity.

475. The Effects of Obesity on Deformity Correction in Adolescent and Juvenile Idiopathic Scoliosis

Christina Hardesty, MD; Jochen P. Son-Hing, MD, FRCSC; Connie Poe-Kochert, BSN; George H. Thompson, MD USA

Increased body mass index (BMI) in adolescents and juveniles undergoing spinal deformity surgery is associated with increased preoperative kyphosis, number of postoperative complications, and difficulty with administration of spinal anesthesia.

476. Proximal Junctional Fracture with Neurologic Deficit Following Adult Deformity Surgery

Mark D. Rahm, MD; Khaled Kebaish, MD; Robert W. Gaines, MD; Hani Mhaidli, MD, PhD; Complex Spine Study Group USA

Proximal junctional fracture with neurologic injury is a devastating complication following adult deformity surgery. This retrospective case series reviews 8 patients with this injury. All were treated surgically with improvement of neurologic deficit, however 50% of patients had further proximal junctional fracture.

477. A Five to Nine-Year Review of 121 Post-instrumented Adolescent Idiopathic Scoliosis Patients: Complications and Risk Factors Analysis

Gabriel Liu, MSc. FRCS(Orth); John Nathaniel M. Ruiz, MD, MRCS; Hee-Kit Wong
Singapore

This study reviewed 121 pts who underwent surgical treatment for AIS after a minimum 5 year follow up. It shows surgical treatment provides satisfactory results with acceptable complications. A trend towards more complications & increased op time is seen with anterior approach; however it may offer less blood loss and more scoliosis correction when compared to posterior surgical group. Patient aged 12 years or less was found to be a statistical significant risk factor for postop complications.

478. Is Anterior Surgery Essential for ACTIVE Dorsal and Dorsolumbar Caries Spine with Neurodeficit not Responding to Anti-TB Treatment

Saumyajit Basu, MD; Jay D. Ghosh, MBBS, MS(Ortho); Farid H. Malik, MBBS, MS(Ortho); Sreeramalingam Rathinavelu, MS; Agnivesh Tikoo, MS (Ortho); Amitava Biswas, MS(Ortho)
India

Surgical treatment of active dorsal and dorsolumbar spinal tuberculosis with neurodeficit was done by single stage posterior approach with transpedicular decompression and short segment fixation with or without supplemental anterior support. Result analysis showed complete healing of lesion, correction of deformity and improvement of neurodeficit with this surgery.

479. Survey of Cause of Death in the Patients with Thoracic Insufficiency Syndrome

Shiro Imagama, MD; Noriaki Kawakami, MD, DMSc.; Taichi Tsuji; Ryoji Tauchi, MD; John B. Emans, MD; John M. Flynn, MD; Norman Ramirez; Shohei Minami; Toshiaki Kotani, MD, PhD; Haruhisa Yanagida, MD; Toru Hirano; Naoki Ishiguro; The Japanese TIS Study Group; Chest Wall and Spine Deformity Study Group
Japan

We collected 16 patients with Thoracic Insufficiency Syndrome (TIS) who have died due to TIS to investigate the cause of death using questionnaire survey in multicenter study. The mean degree of main scoliosis curve at first visit was 73.6 degrees and thoracic kyphosis at first visit was 57.3 degrees. TIS classification indicated 3 cases of type II, 1 of type IIIa, and 3 of type IIIb. The cause of death in 9 cases (9/16; 56%) was respiratory dysfunction.

480. Complications of Pedicle Screws in Children Ten Years or Less

Yaser M. Baghdadji, MD; A. Noelle Larson, MD; Anthony A. Stans, MD; Amy L. McIntosh, MD; William J. Shaughnessy, MD; Mark B. Dekutoski, MD
USA

Complications associated with pedicle screw placement in children are rare (0.33%), and rates are similar for children 10 years or less and a matched cohort greater than age 10. No neurologic complications resulted from pedicle screw use.

The FDA has not cleared the drug and/or medical device for the use described in this presentation (i.e., the drug or medical device is being discussed for an 'off label' use).

481. The Ability to Avoid Major Screw Misplacements in Spine Deformity Does Not Improve with Time and Experience

Vishal Sarwahi, MD; Beverly Thornhill, MD; Adam L. Wollowick, MD; Yungtai Lo; Preeti M. Kulkarni, MD; Jonathan J. Horn; Terry D. Amaral, MD
USA

Pedicle screw misplacements were analyzed on CT scans in 114 deformity patients. Despite increasing ability to place more screws in a shorter period of time with less blood loss, the rate of major misplacements did not improve.

482. In the World of Pay-for-Performance, How Do We Evaluate Baseline Risk? An Innovative Risk Assessment Tool for Spine Surgery

Nathan L. Hartin, MD; Amir A. Mehbod, MD; Siddharth B. Joglekar; Ensor E. Transfeldt, MD
USA

The Fusion Risk Score is introduced to objectively assess the risk of spine surgery preoperatively. The score is the sum of two components - one arises from risks unique to the individual patient (Patient Score) and the other from the planned surgery (Procedure Score). With knowledge of the Patient Score, the surgeon may plan intervention (Procedure Score) that appropriately controls risk.

483. Anti-Emesis after Spine Surgery: Does a Single Pre-Operative Dose of Aprepitant Reduce Nausea and Vomiting?

David T. Anderson, MD; Timothy Dilorio, MD; Mark F. Kurd, MD; Mitchell Maltenfort, PhD; Jeffrey A. Rihn, MD
USA

Post-operative nausea and vomiting (PONV) due to anesthetic agents and opioid-based IV patient-controlled analgesia interferes with early mobilization, hospital discharge, and ultimately causes considerable patient distress. We performed a retrospective case control study to evaluate the efficacy of a single pre-operative dose of Aprepitant in reducing PONV. Seventy-four patients who received a pre-operative dose of Aprepitant (Study Group) were matched to 61 patients who did not receive a dose (Control Group) from a group of patients undergoing cervical arthrodesis, lumbar arthrodesis, or lumbar decompression. Aprepitant reduced the percentage of patients with PONV, the average number of episodes of PONV, and increased the number of sessions with physical therapy leading to more early mobilization. The use of Aprepitant did not affect the length of hospital stay.

484. Efficacy of Antibiotic and Surgical Treatments of Postoperative Wound Infections Following Spine Surgery

Tate M. Andres, BS; Richelle C. Takemoto, MD; Pedro A. Ricart Hoffiz, MD, MS; Virginie Lafage, PhD; Thomas Errico; Baron S. Lonner
USA

Clinicians may implement a variety treatment options for surgical site infections (SSIs); such treatment should be carefully planned to prevent an excess of financial, emotional and physical stress to patients and caregivers. The treatment of a series of SSIs at a single institution are evaluated and discussed.

E-POSTER INDEX

485. Surgical Treatment of Vertebral Infections via a Posterior Approach in Elderly Patients with Cardio-Pulmonary Comorbidities

Sinan Kahraman; Meric Enercan; Ahmet Alanay; Alauddin Kochai; Cagatay Ozturk, MD; Zehra Cagla Karakoc; Azmi Hamzaoglu, MD

Turkey

Posterior vertebral column resection (PVCR) for vertebral infections in elderly patients with pulmonary comorbidity is an efficient alternative to anterior approach.

486. The Use of Autologous Platelet-Poor Plasma (PPP) Gel as a Barrier to Prevent Ectopic Bone Formation Following Lumbar Fusion with BMP

Jim A. Youssef, MD; Douglas G. Orndorff, MD; Katie A. Patty, MS; Morgan A. Scott, MS

USA

Recombinant human bone morphogenetic protein-2 (rhBMP-2) (Infuse; Medtronic Sofamor Danek, Memphis, TN) is commonly used in off-label surgical applications. The safety of its use in has not been conclusively demonstrated, evidence of ectopic bone formation has caused clinical issues such as radiculopathy, recurrent stenosis and persistent pain.

The FDA has not cleared the drug and/or medical device for the use described in this presentation (i.e., the drug or medical device is being discussed for an 'off label' use).

487. Incidence and Outcomes of CSF Leak in Open vs. Minimally Invasive Lumbar Surgery

Nicholas P. Slimack, MD; Patrick Shih, MD; Timothy R. Smith, MD, PhD, MPH; John C. Liu, MD; Albert P. Wong, MD; Richard G. Fessler, MD, PhD; Tyler Koski, MD

USA

To compare the rate and clinical impact of CSF leak in traditional "open" discectomy, foraminotomy, or laminectomy with that of a minimally invasive surgical (MIS) technique

488. Precautions Against Surgical Site Infection in Spine Surgeries Based on Types and Risk Factors

Dongki Ahn, MD; Dae-Geun Kim

Republic of Korea

Five precautions against surgical site infection in spine surgery were established (irrigation method reformation, delayed opening of instruments, changing of gowns before instrumentation, local bone irrigation and limited application of interbody fusion). Preliminary study for risk factors verification and epidemiology of contamination rout was carried out before the set-up. And prospective study was performed after implementation to appraise its value.

489. Impact of Body Mass Index on Hospital Stay and Complications at One and Two-Years Follow-Up After Major Spinal Surgery

Tyler Koski, MD; Sara E. Thompson, BA; Jamal McClendon, MD; Timothy R. Smith, MD, PhD, MPH; Frank L. Acosta, MD; Patrick A. Sugrue, MD; Brian A. O'Shaughnessy, MD

USA

Obesity is a major risk factor for health disability. Patients with a higher BMI have lower functional status, increased pain, and worse physical condition than those at ideal weight. Our goal was to determine associations between BMI categories on patient outcomes after major spinal surgery.

490. Cervical Corpectomies Ultra-Low Dose Recombinant Human Bone Morphogenetic Protein-2 in High Risk Patients: Complications and Outcomes

Sina Pourtaheri, MD; Arash Emami, MD; Jesse Allert, MD; Ki S. Hwang, MD; Kumar Sinha

USA

Recent work has shown the increase incidence of swelling complications with anterior cervical discectomy and fusion (ACDF) and low dose rhBMP-2. There are no detailed reports that describe the use of rhBMP-2 with cervical corpectomies, or ultra-low dose rhBMP-2 with anterior cervical surgery.

The FDA has not cleared the drug and/or medical device for the use described in this presentation (i.e., the drug or medical device is being discussed for an 'off label' use).

491. Nasal Screening for Patients Scheduled for Spine Surgery: Is it Cost Effective?

Shirvinda Wijesekera, MD; Anne R. Moore, DNP

USA

All elective patients of one spine surgeon were screened preoperatively for Staphylococcus aureus using nasal cultures and analyzed.

492. Complications after Surgical Treatment of Adult Idiopathic Scoliosis

Ferran Pellise, MD; Ahmet Alanay; Juan Bago, MD; Emre Acaroglu, MD; Alba Vila-Casademunt; Montse Domingo-Sabat; Meric Enercan; Azmi Hamzaoglu, MD

Spain

Less information is available concerning postop complications in adult idiopathic (age>20) scoliosis (AdIS) vs adolescents. Our study shows that the relatively high (14% major medical and 21.5% mechanical) complication and (19%) reintervention rates after surgery for AdIS do not modify patient's perceived effect of surgery. Pedicle screw constructs reduce the risk of mechanical complications and should be recommended.

493. Accuracy of Neuromonitoring in Predicting Acute vs. Delayed Onset C5 Palsy In Cervical Spine Surgery

Vidya Bhalodia, MD; Shirvinda Wijesekera, MD; Isaac Goodrich, MD; Anthony K. Sestokas, PhD; Gary Bloomgarden, MD; Thomas J. Arkins, MD; Patrick Tomak, MD; Judith L. Gorelick, MD; John M. Beiner, MD; Daniel M. Schwartz, PhD
USA

Accuracy of tceMEP and EMG monitoring for predicting acute vs. delayed onset deltoid weakness was evaluated in 229 patients who underwent cervical spine surgery involving C4 and C5. Deltoid weakness manifested acutely in 5 patients but was delayed > 24 hrs. in 7. Risk for C5 injury was highest for dual C4 and C5 corpectomies compared to other surgery types. tceMEPs were effective for predicting acute deltoid weakness, but EMG was not. Neither modality could predict delayed onset weakness.

494. Microbiological Culture Result for Autogenous Local Bones Used in Posterior Lumbar Interbody Fusion and Its Relationship with Postoperative Spinal Infection

Chongsuh Lee, MD, PhD; Sung Soo Chung; Kyung-Chung Kang; Se Jun Park; Jong Ho Park
Republic of Korea

During PLIF, a contamination rate of the autogenous local bones was not low and a special attention and proper treatment should be followed in case of positive culture results of local bones. A microbiological culture of local bones will be helpful for the control of postoperative spinal infection.

495. Use of Vancomycin Powder is Not Associated with Increased Systemic Vancomycin or Creatinine Levels in Patients with Adolescent Idiopathic Scoliosis

Krzysztof Siemionow, MD; Anis Mekhail, MD; Yazeed Gussous, MD; David F. Elmashat, BS; Sergey Neckrysh, MD; Steven M. Mardjetko, MD, FAAP
USA

Vancomycin powder applied to the surgical site is safe in pediatric patients with AIS

496. Anterior Lumbar Spine Fusion Using a Free Vascularized Fibula Strut Graft within an Expandable Titanium Cage

Justin M. Dazley, MD; Marc A. Agulnick, MD; Benjamin R. Cohen, MD; Thomas A. Davenport, MD; Ryan Vellinga
USA

We present a series of three patients with recalcitrant vertebral osteomyelitis treated with vascularized fibular grafts placed within expandable cages. No postoperative complications developed in any patient, and all ambulated prior to discharge. One patient died of unrelated causes, but at an average follow up of fourteen months all patients' status was unchanged and evidence of fusion was appreciated. This technique is a novel treatment option for these complex patients, providing enhanced structure and vascularity.

497. What's the Evidence? - Systematic Literature Review of Risk Factors and Preventive Strategies for Surgical Site Infections following Pediatric Spine Surgery

Michael Glotzbecker, MD; Matthew D. Riedel, BA; Michael G. Vitale, MD, MPH; Hiroko Matsumoto, MA; David P. Roye, MD; Mark A. Erickson, MD; John M. Flynn, MD
USA

SSI prevention protocols vary due to evolving evidence & literature interpretation, as well as individual physician experience. This study formally & systematically reviews the literature for pediatric spine SSI. Database searches were conducted in December 2011. 458 relevant studies resulted. Pediatric spine SSI prevention studies (57/458) were independently rated for evidence level by 3 pediatric spine surgeons. Little evidence exists supporting pediatric spine SSI prevention methods. Higher evidence strategies exist in non-pediatric literature, which warrants consideration for use in pediatrics.

498. Complications Associated with Pedicle Screws for the Treatment of Scoliosis in Young Children (<Eight Years)

Jiaming Liu, MD; Jianxiang Shen, MD
China

Nowadays, pedicle screw instrumentation was widely been used to correct the scoliosis in young children, and resulting in a good deformity correction effect. However, the complications associated with pedicle screws for the treatment of scoliosis in young children were not clearly till now.

499. Betadine Wash and Usage of Absorbable Vancomycin / Tobramycin Beads Reduces Infection in Adult Scoliosis Patients Undergoing Anterior Posterior Thoraco-Lumbar Spine Fusions to Pelvis

Anant Kumar, MD; Mayanka Kumar
USA

In this prospective consecutive series of Anterior posterior thoraco-lumbar spine fusions for adult scoliosis above 30 degrees (30-104 degrees) we had 1 infection in 157 patients (higher risk) fused to pelvis after a betadine wash and installation of absorbable antibiotic beads impregnated with 2 grams of Vancomycin and 2.8 grams of tobramycin. We had 4 infections in 112 patients undergoing thoraco-lumbar spine fusions not including the pelvis after a wash out with saline .

All infections were due to staphylococcus Aureus and there were no late infections in this series.

501. Treatment and Related Complications for Patients with Early Onset Scoliosis

Mehmet B. Balioglu, MD; Temel Tacal, MD
Turkey

In this study we evaluated the results and related complications of early onset scoliosis (EOS) patients which received non-fusion techniques and surgical intervention in order to plan better treatment.

E-POSTER INDEX

502. Complications with rhBMP-2 in Lateral Approach Spine Surgery

William D. Smith, MD; Chris Brown; Luiz Pimenta, MD, PhD; Luis Marchi, MSc; Leonardo Oliveira, BSc; Juan S. Uribe, MD
USA

rhBMP-2 has been shown in some studies to have a unique complication profile, mostly during the early inflammatory phase. This study examines BMP complications specific to lateral approach surgery. Six cases were identified at four institutions, three of delayed onset nerve injuries and three cases of significant ectopic bone formation. *The FDA has not cleared the drug and/or medical device for the use described in this presentation (i.e., the drug or medical device is being discussed for an 'off label' use).*

504. Pleural Effusion Following All Pedicle Screw Instrumentation in Posterior Spinal Fusion for Adolescent Idiopathic Scoliosis

Lee S. Segal, MD; M. W. Shrader, MD; Judson W. Karlen, MD; Gregory R. White, MD
USA

Pleural effusion after posterior spinal fusion with all screws is a rare but potential complication, especially when treating severe, stiff curves. Patients with postoperative respiratory difficulties should be assessed for pleural effusion and treated accordingly.

505. Towards Quality and Safety in Spinal Deformity Surgery: Use of a Multicenter Database Registry for Quality Improvement

Suken A. Shah, MD; Michelle C. Marks, PT, MA; Maty Petcharaporn, BS; Baron S. Lonner; Peter O. Newton, MD; Harms Study Group
USA

A multicenter adolescent idiopathic scoliosis (AIS) database registry was utilized to provide peer benchmark comparison data which can be used for process improvement and ongoing performance feedback.

506. Risk Factors for Implant Subsidence after Stand-Alone Lateral Lumbar Interbody Fusion

David Essig, MD; Woojin Cho, MD, PhD; Andrew S. Lee, MD, PhD; Alex Hughes, MD; Russel C. Huang, MD; Andrew A. Sama, MD; Federico P. Girardi, MD; Frank P. Cammisia, MD
USA

This retrospective, radiographic review seeks to identify risk factors for implant subsidence after stand-alone Lateral Lumbar Interbody Fusion (LLIF). Advanced age, osteoporosis, and facet orientation were identified as significant risk factors for subsidence.

507. Perioperative Infection Rate After Minimally Invasive Lateral Lumbar Interbody Fusion

Armen R. Deukmedjian, MD; Fernando L. Vale, MD; Donald A. Smith, MD; Juan S. Uribe, MD
USA

In this retrospective study, we examine all consecutively enrolled patients undergoing minimally invasive lateral lumbar interbody fusion from 2008-2011 for surgical site infections. Only one occurred in 425 cases (0.2%). We believe it is important to report and discuss this data in order to better understand and prevent these complications from occurring. Based on our data, this procedure is a safe and reproducible technique for inter body fusion with a low incidence of infection.

508. Peri- and Postoperative Complications of Surgery for Adult Spinal Deformity

Takashi Namikawa, MD, PhD; Hiroshi Taneichi, MD; Satoshi Inami; Daisaku Takeuchi; Chizuo Iwai; Nakayuki Kato, MD; Yutaka Nohara, MD
Japan

We retrospectively reviewed 71 consecutive patients who undergone the surgery for adult spinal deformity. Patient-based complication rate was 42% (30/71 patients). Most common complication was adjacent segment breakdown (15%). Elderly, medical comorbidity and long operation time increased perioperative complications. Surgeries for adult spinal deformity are becoming common even though high risk procedure. The therapeutic strategy should be planned which maximized the benefit with minimizing the risks.

509. Cardiovascular Performance Evaluation and Troponin Elevation in Patients Undergoing Major Spinal Fusion

Jamal McClendon, MD; Timothy R. Smith, MD, PhD, MPH; Patrick A. Sugrue, MD; Brian A. O'Shaughnessy, MD; Sara E. Thompson, BA; Tyler Koski, MD
USA

Myocardial infarction (MI) is the most common major peri-operative vascular complication in non-cardiac surgery. The physiologic stress of major spinal surgery and its association with cardiac performance with long-term follow-up has not been studied.

510. Subsidence and Lumbar Sagittal Alignment Following Lateral Lumbar Interbody Fusion

Edward K. Nomoto, MD; Paul Stanton, DO; Nima Kabirian, MD; James D. Bruffey, MD; Jeff Pawelek; Gregory M. Mundis, MD; Behrooz A. Akbarnia, MD; Robert K. Eastlack, MD
USA

23 adult patients with a total of 31 levels underwent lateral lumbar interbody fusion. Radiographic subsidence occurred in 22% of patients and 19% of all levels. Disc heights were significantly decreased by subsidence; however, this did not affect intervertebral segmental angle, lumbar lordosis and fusion rate. Subsidence was found to occur within the first three months postoperatively with minimal change thereafter.

511. Assessment of Deep Wound Infections Following Pediatric Scoliosis Surgery

Sina Pourtaheri, MD; Freeman Miller, MD; Kirk W. Dabney, MD; Suken A. Shah, MD; Susan Dubow, BS; Laurens Holmes, PhD, DrPH
USA

Prevention of surgical site infection (SSI) in pediatric spine deformities surgery is a crucial task. Recent data have shown antibiotic-loaded allograft and proper pre-operative antibiotics to incision time decrease SSI's. However, there remain controversies over the appropriate pre-operative antibiotic selection.

512. Retrospective Analysis of the Effect of Plastic Surgery Closure on Peri-Operative Infection Rates in Orthopedic Spine Surgeries

Tate M. Andres, BS; Andrew Yoo; Dina Shah, MS; Edward Chay; Manal Abouelrigal; Virginie Lafage, PhD; Michael Margiotta, MD; Thomas Errico
USA

Given the dramatic extent to which surgical site infections (SSIs) affect spine patients, a wide variety of measures have been implemented as techniques for prevention. The following is an investigation into whether or not having a plastic surgeon perform surgical wound closure is an effective method for reduction the influence of SSIs.

513. Clinical and Radiological Consequences of Interbody Cage Subsidence

Luis Marchi, MSc; Leonardo Oliveira, BSc; Rodrigo A. Amaral; Carlos A. Castro; Thiago Coutinho; Etevaldo Coutinho; Luiz Pimenta, MD, PhD
Brazil

The main goal of this work is to describe a new grading system, describe when and how the subsidence occurs.

514. Prognostic Factors for the Need of Perioperative Blood Transfusion in Spinal Fusion Surgery with Instrumentation

Vicente Ballesteros, MD; Sergio Ramirez, MD; Alberto Telias, MD; Bartolome Marre, MD; Ratko Yurac, MD; Jose Fleiderman, MD; Juan J. Zamorano, MD; Milan Munjin, MD; Alejandro Urzua, MD; Francisco Ilabaca, MD; Miguel Lecaros, MD
Chile

Nested case-control series including 179 patients with normal preoperative hemoglobin who underwent spinal fusion with instrumentation (follow up-9-24 months). Thirty-two patients required a blood transfusion (cases) while the rest were considered as the control group. Collected data was statistically analyzed with Chi2 and a multivariate logistic regression model. Surgery duration >5 hours was identified as a risk factor while the anterior approach determined a protective factor for the need of perioperative blood transfusion (OR 6.7 and 0.21 respectively).

515. Risk Factors for the Development of Thromboembolic Complications After Surgical Stabilization in Patients with Spine Fractures

Vicente Ballesteros, MD; Alberto Telias, MD; Aleksandar Munjin; Sergio Ramirez, MD; Juan J. Zamorano, MD; Jose Fleiderman, MD; Bartolome Marre, MD; Ratko Yurac, MD; Francisco Ilabaca, MD; Milan Munjin, MD; Alejandro Urzua, MD; Miguel Lecaros, MD
Chile

Nested case-control series including 88 patients with surgically stabilized spine fractures (minimum follow-up 6 months). Six patients presented a thromboembolic event during follow-up (cases), while the rest were considered as the control group. After statistical analysis, using the Fisher's exact test and a multivariate logistic regression model, we determined that a perioperative blood transfusion is a risk factor for a thromboembolic event in these patients.

516. Adjacent Segment Degenerative Disease in Lumbar Spine - Natural Course of Degenerative Disease or Fusion-Associated Phenomenon?

Jun Young Yang, MD, PhD; June Young Park; Ho Jin Lee
Republic of Korea

Radiologic adjacent segment change was found to be greater than at non-adjacent segments. But, no significant difference was observed between two groups in terms of the incidence of symptomatic disease. So, we conclude that single level fusion has little effect on the development of adjacent segment disease.

517. Correlation Between Measured Arterial Blood Pressure and Estimated Blood Loss During Lumbar Surgery

Hrishikesh C. Gogineni, BS; Ernest Y. Young, MS; Nicholas U. Ahn, MD
USA

A strong correlation was found between blood pressure and intraoperative blood loss during high blood loss cases, strongly suggesting that measured arterial blood pressure strongly influences blood loss.

518. A comparison of Hemodynamics in the Iliac Artery between a Flat and Hyperextended Position for Anterior Lumbar Interbody Fusion

Joshua Herzog; Avraam Ploumis, MD, PhD; Justin M. Dazley; Kirkham B. Wood, MD
USA

The purpose of this study is to assess the change in caliber and blood flow of the iliac arteries during anterior lumbosacral spine surgery.

519. Is Rod Fracture Always a Sign of Pseudoarthrosis in Patients with a Long Posterior Spinal Fusion (PSF)?

Hamid Hassanzadeh, MD; Mostafa H. El Dafrawy, MD; Thomas J. Kim, MD; John A. Carrino, MD, M.P.H.; Khaled Kebaish, MD
USA

Unilateral rod fracture after long PSF appears to not always indicate the presence of pseudoarthrosis. We are presenting on 9 patients who developed a unilateral rod fracture who has either clear evidence of solid fusion and/or remained clinically asymptomatic.

E-POSTER INDEX

520. Weak or Absent Ankle Dorsiflexion: The Most Sensitive and Specific Indicator of Neurologic Injury

Lindsay Andras, MD; Kristin Louie; David L. Skaggs, MD

USA

This study evaluates the most sensitive and specific physical exam finding for neurologic injury after spinal deformity surgery. In this large review of over a 1000 cases, ankle dorsiflexion was the most sensitive and specific test for motor function following spinal deformity surgery both for immediate and delayed neurologic deficits.

521. Prophylactic Antibiotic Administration in Spinal Instrumentation Surgery for Patients with Risk Factors for Surgical Site Infection

Kota Watanabe; Naobumi Hosogane, MD; Akio Iwanami; Takashi Tsuji; Ken Ishii, MD, PhD; Masaya Nakamura; Yoshiaki Toyama; Kazuhiro Chiba, MD, PhD; Morio Matsumoto, MD

Japan

The effectiveness of teicoplanin (TEICO) as antimicrobial prophylaxis (AMP) for patients with high risk factor for surgical site infection (SSI) was evaluated in 820 consecutive patients who underwent in spinal instrumentation surgeries. The infection rate of the high risk group significantly decreased from 13.8% to 3.5% ($p=0.018$). The administration of TEICO as AMP may be effective for prevention of SSI in patients with high risk factors for SSI in spinal instrumentation surgery.

522. Do We Comply? - Antibiotic Prophylaxis in Pediatric Spine Surgery

Matthew D. Riedel, BA; Hiroko Matsumoto, MA; Meghan Murray; Lisa Covington, RN, MPH; Lisa Covington, RN, MPH; Benjamin D. Roye, MD, MPH; Joshua E. Hyman, MD; David P. Roye, MD; Michael G. Vitale, MD,

MPH

USA

Peri-operative antibiotics are a modifiable factor affecting SSIs, and it is important to determine how compliant physicians are with established regimens. This study reviews compliance with established pediatric spine antibiotic prophylaxis protocol at a tertiary children's spine program. This retrospective review included all patients undergoing spine surgery from January 2009 through September 2011. 507 spine surgeries were identified and included. Compliance results are in the attached table. Efforts to increase compliance are necessary to improve modifiable risk factors for SSIs.

523. The Pitfalls of Calculating Readmissions Based Solely on Nonvalidated Administrative Datasets

Praveen V. Mummaneni, MD; Beejal Amin, MD; Steven Takemoto, PhD; Dean Chou, MD; Christopher P. Ames, MD; Vedat Deviren, MD; Sigurd H. Berven, MD

USA

UHC inappropriately included staged procedures, surgery cancelled for unpredictable reasons, and non-spine surgery readmissions into the readmissions rate calculation. These cases accounted for 25% of total spine readmissions.

524. Reported Complications Associated with the Off-Label use of Recombinant Human Bone Morphogenetic Protein-2 in Anterior Lumbar Interbody Fusion with Minimum One-Year Follow-Up

Jim A. Youssef, MD; Douglas G. Orndorff, MD; Hannah Price; Morgan A. Scott, MS; Katie A. Patty, MS

USA

Many surgeons have found the off-label use of recombinant human bone morphogenetic protein (rhBMP)-2 very effective in achieving arthrodesis in a variety of spinal fusion surgeries. Recent literature has reported an increased number of adverse events with the off-label use of rhBMP-2 specifically rates of resorption, subsidence, osteolysis, retrograde ejaculation and cage migration.

The FDA has not cleared the drug and/or medical device for the use described in this presentation (i.e., the drug or medical device is being discussed for an 'off label' use).

525. Radiographic Aggravation after Indirect Posterior Decompression with Fusion for Ossification of Posterior Longitudinal Ligament of the Thoracic Spine

Kei Ando; Shiro Imagama, MD; Zenya Ito; Kenichi Hirano, MD; Ryoji Tauchi, MD; Akio Muramoto, MD; Naoki Ishiguro, MD, PhD

Japan

We investigated radiographic changes of indirect posterior decompression with corrective fusion. 7/40 patients had radiological changes. Three had compression fracture at a distal end of fusion, one had the screw loosening of a distal end, and three had kyphotic changes of distal adjacent area. When examining a fusion area, the alignment after surgery need to be maintained as well as the indirect decompression of the spinal cord. The necessity for extending fusion area and apex was reconfirmed.

526. Reduction of Postoperative Wound Infection Rates Following Instrumented Posterior Cervical Fusion Using Vancomycin Powder with Multiple Drains

Samuel A. Joseph, MD

USA

Instrumented posterior cervical surgery has a high infection rate. In the present study, the use of vancomycin powder in both the bone graft and wound, with multiple drains, was able to reduce the infection rate to zero (0/21). There were no vancomycin associated complications.

The FDA has not cleared the drug and/or medical device for the use described in this presentation (i.e., the drug or medical device is being discussed for an 'off label' use).

Congenital Deformity

527. Obstructive Lung Disease in Patients with Congenital and Syndromic Scoliosis

Gary L. Mcphail, MD; Robert E. Wood, MD; R Paul Boesch, DO, MS; Viral Jain, MD; Steven Agabegi, MD; Eric Wall, MD; Alvin H. Crawford, MD; Peter Sturm, MD
USA

This study reviews the prevalence of obstructive lung disease (OLD) in congenital and syndromic scoliosis. We queried a local database for children with scoliosis who had pulmonary function testing (PFT) from 2004-2009. Patients with congenital or syndromic thoracolumbar scoliosis with Cobb angles > 40 degrees were included. The prevalence of obstructive lung disease was 27%. Review of flexible bronchoscopy videos and CT scans indicated that mainstem airway compression from anterior spine rotation was a common mechanism of disease.

528. Mid-Term Follow-Up of Vertebral Column Resection for Severe Pediatric Spinal Deformity

Todd Lincoln, MD; Kaveh Barami
USA

Excellent clinical and radiographic results for patients presenting with severe deformity can be achieved with VCR at mid-term follow-up with an acceptable rate of complication and high patient satisfaction

529. Clinical and Radiographic Outcomes Using Posterior Vertebral Column Resection (PVCR) in Spinal Congenital Deformities (SCD)

Luis Eduardo C. da Silva; Luis Antonio M. Moliterno; Antônio E. Araújo; André L. Barcellos; Bernardo M. Chaves, MD
Brazil

The records of 20 consecutive patients who had undergone to PVCR with segmental posterior instrumentation in the treatment of SCD were reviewed. Patients had overall favorable radiographic and clinical outcomes.

530. "Clinical Triad" Findings in Klippel-Feil Patients

Dino Samartzis, DSc, PhD (C), MSc; Prakasam Kalluri, MD; John P. Lubicky, MD; Francis H. Shen, MD
China

It has been propagated that Klippel-Feil Syndrome (KFS) is associated with the clinical triad findings (CTF) of short neck, low posterior hairline, and limited range of motion. This study noted that CTFs are not consistently noted in KFS patients. KFS patients with extensive congenitally fused cervical segments were more likely to exhibit one of the components of CTF.

531. Teriparatide Improves Lumbar Spine Bone Mineral Density in Two Adolescent Boys with Severe Kyphoscoliosis Prior to Spinal Fixation Surgery

Ewa Oberdorfer, DO, MPH; David W. Polly, MD; Katie M. Larson-Ode, MD; Deborah Smith-Wright, MD; Kenneth J. Guidera, MD; Joseph Neglia; Lynda Polgreen, MD, MS
USA

This case report illustrates the potential of teriparatide to increase LS-BMD in children with low BMDs.

The FDA has not cleared the drug and/or medical device for the use described in this presentation (i.e., the drug or medical device is being discussed for an 'off label' use).

Diagnostic Methods

532. Multimodal Intraoperative Neurophysiologic Monitoring in Young Children

Alpaslan Senkoylu; Murat Zinnuroglu; Alp Borcek; Irfan Gungor; Necdet S. Altun
Turkey

Defining success rate and performance of multimodal intraoperative neurophysiological monitoring in two different age groups of children (0-5 years and 5-11 years) were aimed. Standard anesthesia protocol was given to both groups. SSEP and MEP's were recorded in all patients. Ten serious events were observed in both groups. Kyphosis was found as the most important risk factor for the serious events. MIONM can be performed successfully in younger ages of childhood with a specified anesthesia procedure.

533. The Role of Adjustable Scout Lines in Advanced Spinal Imaging

Matthew Kang, MD; Brian W. Hill, MD; Bowei Song
USA

This study compares the effect of measuring the axial central canal diameter of the cervical spine using a traditional fixed CT scout line vs. a user-adjustable scout line parallel to the endplate. The results demonstrate the large discrepancies in canal diameter between axial images generated from standard scout line vs. user-adjustable scout lines in the most common levels for degenerative cervical spine disease.

534. Neurofibromatosis Type I with Dystrophic Scoliosis: A Multicenter Inter-Observer Reliability Study of Radiographic Characteristics

Charles Gerald T. Ledonio, MD; David W. Polly, MD; Ann M. Brearley, PhD; Alvin H. Crawford, MD; Daniel J. Sucato, MD, MS; Leah Y. Carreon, MD, MSc; A. Noelle Larson, MD; David Stevenson; Michael G. Vitale, MD, MPH; Christopher L. Moertel, MD
USA

This multicenter radiographic assessment study has shown that there is good reliability to detect dystrophic scoliosis in NF1 patients by assessing radiographic characteristics of dystrophic modulation.

E-POSTER INDEX

535. Analysis of Radiation Exposure Reduction After Implementing Multidetector CT in an Early Onset Scoliosis (EOS) Treatment Algorithm

Ajeya Joshi; Heather Brandfellner, DO; Alicia A. DiGiammarino, BA; John J. Doski, MD; Robert Fajardo, PhD; Hope Trevino, AA; James W. Simmons, DO, PhD; Robert M. Campbell, MD
USA

Children with Early Onset Scoliosis and Thoracic Insufficiency Syndrome who have been treated using Vertical Expandable Prosthetic Titanium Rib are routinely exposed to radiation through frequent radiographic studies. Limiting radiation exposure in children with significant medical illness and comorbidities is an important patient safety concern that can be addressed by using newer volume CT scanning with up to 320-detectors per rotation and through selective use of radiographic imaging.

536. The Diagnostic Accuracy of Diffusion Tensor Imaging for Spinal Cord Injury: Preliminary Analysis of Sensitivity and Specificity

Mary Jane Mulcahey, PhD; Feroze B. Mohamed, PhD; John Gaughan; Nadia Barakat; Amer F. Samdani, MD
USA

This study sought to determine the accuracy of diffusion tensor imaging (DTI) as a diagnostic tool for spinal cord injury (SCI). There is a difference in mean DTI values between subjects with and without SCI which is seen both above and below the MRI-defined level of injury. Specificity and sensitivity of DTI for MRI and the ISNCSCI (International Standards for the Neurological Classification of SCI) motor abnormal level was high, providing preliminary evidence of DTI accuracy for diagnosing SCI.

537. Analysis of Sagittal Balance of Ankylosing Spondylitis using Spinopelvic Parameters

Jung Sub Lee, MD, PhD; Jeung Il Kim; Jong Min Lim; Tae Sik Goh; Shi Hwan Park
Republic of Korea

The aim of this study was to determine differences between ankylosing spondylitis (AS) patients and normal controls using sagittal spinal alignment and pelvic orientation and to identify relationships between sagittal spinopelvic parameters and AS.

538. Comparison of Right and Left-sided EOS System Incidences in the Evaluation of Rib Hump Prominence in AIS

Anna-Maria Preziosi, MD; Benjamin Léger St-Jean, MD; Marjolaine Roy-Beaudry, MSc; Davide Sassi, fellow; Stefan Parent, MD, PhD
Canada

The EOS system is used for clinical evaluation in AIS. Its lateral incidence is right sided unlike conventional radiography. Most rib humps being right-sided, it was hypothesised that significant difference existed between right and left sided EOS incidences. Mainly, rib hump prominence (RH) of AIS patients was measured from standard right and control left lateral EOS incidences by two observers. Statistically significant differences in RH were seen in this study. Clinically, this could result in artefactual amplification of RH.

539. Diagnostic Accuracy of SPECT/CT Imaging in Detection of Nonunion after Lumbar Spinal Fusion

Koroush Kabir, MD; Robert Pflugmacher; Hajjat Ahmadzadehfar, MD
Germany

The goal of this study was to investigate the diagnostic value of SPECT/CT, and of CT alone in symptomatic patients after lumbar spinal fusion. The Imaging data were correlated to the intraoperative findings. For evaluation of loosening pedicle screws had SPECT no additional advantages compared to CT alone, but SPECT/CT in combination was superior regarding the evaluation of non-union intervertebral segments. SPECT/CT could be a valuable diagnostic tool to evaluate the fusion and loosening screw after spinal fusion surgery.

540. Detecting Small Changes in Spinal Deformity Using Surface Topography

Patrick T. Knott, PhD, PA-C; Theresa Micke; Jessica Woodworth; Brigitte Peterson; Tracy Zibera; Steven M. Mardjetko, MD, FAAP
USA

Surveillance of adolescents with scoliosis is important, but can expose them to too much x-ray. To reduce this, surface topography has been employed to evaluate spinal deformity. The Formetric 4D has been tested for reproducibility and accuracy with favorable results. This study assesses the machine's ability to detect small changes in spine position, as seen during AIS surveillance. Results showed a strong correlation between an imposed change from a heel lift and the measured change detected by the topography model.

541. Inappropriate Use of Antibiotics is Highly Associated with Drug Resistant Spinal Infections

Ken Nagahama; Manabu Ito, MD, PhD; Kuniyoshi Abumi, MD
Japan

Spinal infections with drug resistant organisms are getting popular in developed countries. This study analyzed the causative factors of drug resistant spinal infections and found out that inappropriate use of the third or fourth generation Cephalosporins and MRSA drugs was one of causative factors of drug resistant spinal infections.

542. MRI-Changes of the Multifidus Muscle in Lumbar Radicular Compression. Relation to Severity and Duration of Compression and Need for Surgical Decompression

Mazda Farshad, MD, MPH; Christian Gerber, MD; Viviane Laufer-Molnar, MD; Nadja A. Amacker, MD; Tobias J. Dietrich, MD; Kan Min, MD
Switzerland

The extent of atrophy of the multifidus muscle on the affected side in comparison with the contralateral side does neither correlate with the severity nor the duration of nerve root compression in the lumbar spine, but severe asymmetry with substantial multifidus atrophy is highly predictive for the decision to surgical decompression.

543. Validation of a Simple Computerized Tool for Measuring Spinal and Pelvic Parameters

Chi Heon Kim, MD, PhD; Chun Kee Chung, MD, PhD
Republic of Korea

We devised a tool that provides computerized measurements of the sagittal vertical axis and pelvic parameters in a picture archiving and communication systems.

544. SCIWORA in Adults - A Case Series

Rajeshwar N. Srivastava, MD; Saloni Raj
India

First described by Rang & Wilberger, SCIWORA was initially defined as a syndrome of traumatic myelopathy without vertebral column disruption as visualized on plain spine films, flexion-extension films, myelography or CT. The mean incidence was reported to be around 40% with majority (two thirds) in young child less than 8 to 10 years of age, less commonly in adolescents and rare in adults. With improved imaging capability and increased use of MRI the true incidence is likely to be 15 - 20%. We initiated a study to evaluate the incidence, prevalence and outcome of SCIWORA in adults
In literature, spinal cord injury without radiological abnormality is rare in adults.

545. Neurofibromatosis Type I and Scoliosis: A Multicenter Study to Determine Radiographic Predictors of Dystrophic Scoliosis

Charles Gerald T. Ledonio, MD; David W. Polly, MD; Ann M. Brearley, PhD; A. Noelle Larson, MD; Daniel J. Sucato, MD, MS; Alvin H. Crawford, MD; Leah Y. Carreon, MD, MSc; David Stevenson; Michael G. Vitale, MD, MPH; Christopher L. Moertel, MD
USA

Dystrophic scoliosis in NF1 patients can be best predicted by the following radiographic findings - vertebral wedging, rotation, rib penciling, and atypical curve location. If all four factors are present, there is a 51 times increased risk of a dystrophic curve.

546. Accuracy and Reliability of Central Sacral Vertical Line (CSVL) on Scoliosis Radiographs

Dinesh Thawrani, MD; Steven Agabegi, MD; Emily Eismann, MS; Peter Sturm, MD
USA

In clinical practice, although physicians are not highly reliable in drawing CSVL, its influence on selecting SV or determining LM is not affected.

547. Comparison of Radiation Exposure During Thoracolumbar Fusion Using Fluoroscopic Guidance vs. Anatomic Placement of Pedicle Screws

Natalie M. Egge, MD; Jeffrey Lange, MD; Hanbing Zhou, MD; Christian P. DiPaola, MD; Anthony S. Lapinsky, MD; Patrick J. Connolly, MD; Jason C. Eck, DO, MS
USA

Many techniques for placement of thoracolumbar pedicle screws exist. The aim of this study is to evaluate the difference in radiation exposure imparted using a fluoroscopic-guided technique compared to anatomic placement of pedicle screws. 185 adult patients with posterior non-percutaneous instrumented fusions were reviewed retrospectively and the average seconds per screw inserted was determined. There was a significant increase in radiation exposure to patients undergoing fusion using the fluoroscopic-guided technique, reaching 6.5 times the amount imparted using an anatomic technique.

548. The Reproducibility of Surface Topography Measurements of the Trunk in Patients With Normal and Elevated Body Mass Index (BMI)

Patrick T. Knott, PhD, PA-C; Steven M. Mardjetko, MD, FAAP; Marcel Betsch, MD; Robyn Hund
USA

Surface Topography measurements to evaluate spinal deformity were evaluated based on the BMI of the patient. We found that the reproducibility of the measurements was good, even in patients with a BMI up to 43.

549. Neurofibromatosis Type I and Dystrophic Scoliosis: A Multicenter Study of Accuracy of Surgeons' Radiographic Assessment

Charles Gerald T. Ledonio, MD; David W. Polly, MD; Ann M. Brearley, PhD; A. Noelle Larson, MD; Daniel J. Sucato, MD, MS; Leah Y. Carreon, MD, MSc; Alvin H. Crawford, MD; David Stevenson; Michael G. Vitale, MD, MPH; Christopher L. Moertel, MD
USA

Experienced spine surgeons reviewed 122 scoliosis radiographs of NF1 patients and to establish the predictive value of 8 factors classically associated with a dystrophic scoliosis. All 8 factors were significantly associated with dystrophism, some more sensitive or more specific than others.

550. Radiographic Measurement Reliability of Lumbar Lordosis in Ankylosing Spondylitis

Jung Sub Lee, MD, PhD; Jeung Il Kim; Jong Min Lim; Tae Sik Goh; Shi Hwan Park
Republic of Korea

We evaluated the inter- and intra-observer reliability of six specific measures of global lumbar lordosis in patients with ankylosing spondylitis (AS). The findings in this study demonstrated that the Cobb L1-L5 method is reliable for measuring the global lumbar lordosis in AS.

551. Correlation Between Significant Cortical Signal Changes on Intraoperative Spinal Cord Monitoring and Blood Pressure During Lumbar Surgery

Hrishikesh C. Gogineni, BS; Ernest Y. Young, MS; Nicholas U. Ahn, MD
USA

No correlation was found between SSEP recordings and BP measurements in this retrospective chart review, indicating that controlled hypotension is effective and safe for patients undergoing lumbar surgery.

E-POSTER INDEX

552. Cholecystectomy is a Risk Factor for Vitamin D Deficiency in Adults Undergoing Spine Surgery

Jacob M. Buchowski, MD, MS; Geoffrey E. Stoker, BS
USA

As many as 57% of patients undergoing spine surgery may have Vitamin D insufficiency. We analyzed risk factors in 313 consecutive patients and found that spine patients who have had a cholecystectomy have a 2-fold increase in the risk of Vitamin D deficiency. Other risk factors include dark skin tone, latitude, no supplementation, and obesity.

553. Comparison of Manual and Office PACS-Based Digital Methods for Cobb Angle Measurements in Patients with Spinal Deformity

Jason Sparks, DO; Isador Lieberman, MD, MBA, FRCSC; Xiaobang Hu, PhD; Donna D. Ohnmeiss, MD; Richard D. Guyer, MD; Jack E. Zigler, MD
USA

The expanding use of PACS imaging systems in spine clinics creates eliminates measuring Cobb angles from traditional x-ray films. This study investigated the reliability of using an angle measurement tool in the digital system to measurements on film. Both methods were found to have high intra-rater repeatability as well as between the two methods.

554. The Utility of Magnetic Resonance Myelography for Adult Lumbar Scoliosis Patients

Atsushi Kojima; Yutaka Sasao, MD, PhD; Yoshiaki Torii; Shigeta Marioka; Moroe Beppu, MD
Japan

Most clinicians often was struggled to identify injured nerve root in adults scoliosis (Ads) with radiculopathy, because these symptoms was not only typicality but also not detect a neural element in radiological image. To find to compare a symptom and nerve root finding in AdS, we report a utility of the magnetic resonance myelography (MRM) in patients of AdS with lumbar radicular pain.

Disc Replacement/Dynamic Stabilization

555. Lumbar Total Disc Replacement with a Ball and Socket Metal on Metal Device. Up to 60 Months Follow-Up

Luis Marchi, MSc; Leonardo Oliveira, BSc; Rodrigo A. Amaral; Carlos A. Castro; Thiago Coutinho; Etevaldo Coutinho; Luiz Pimenta, MD, PhD
Brazil

Placement of a TDR device from a true lateral approach offers a less invasive access to the disc space and also preserves the stabilizing ligaments.

556. Laser Surface Topography to Assess Wear and Deformation in Retrieved Total Disc Replacements

Fadi Taher, MD; Darren R. Lebl, MD; Frank P. Cammisia, MD; Timothy Wright, PhD; Celeste Abjornson, PhD
USA

There is a paucity of data on in vivo polyethylene (PE) wear and deformation of total disc replacements (TDR). PE surfaces of twelve retrieved TDRs were examined by laser scanning. Average dimensional changes were greater (0.069 ± 0.162 vs. 0.024 ± 0.099 mm; $p=0.037$) and affected a larger surface area in lumbar compared to cervical TDRs (63.1 ± 22.8 vs. $30.7 \pm 14.0\%$; $p=0.025$). Observed "back-to-front" deformation patterns are potentially related to eccentric device positioning. This is the first study of in vivo PE deformation of ProDisc TDRs.

557. Lessons Learned After Nine-Year Follow-Up on Eight Different Lumbar Total Disc Replacement Devices

Luis Marchi, MSc; Leonardo Oliveira, BSc; Rodrigo A. Amaral; Carlos A. Castro; Thiago Coutinho; Etevaldo Coutinho; Luiz Pimenta, MD, PhD
Brazil

Clinical experience on eight different lumbar total disc replacement devices after 9 years follow up.

558. Pre-op Anatomical FEA Templating for Patient Selection and Optimizing Range of Motion in TDR

Christopher M. Cain, MD; Matthew Lafleur; Milind Rao; Justin Hollenbeck; Paul Rullkoetter, PhD
USA

N/A

559. The Role of Load Absorption in Lumbar Arthroplasty - Elastomeric Total Disc Replacement 48 Months after Surgery

Luis Marchi, MSc; Leonardo Oliveira, BSc; Rodrigo A. Amaral; Carlos A. Castro; Thiago Coutinho; Etevaldo Coutinho; Luiz Pimenta, MD, PhD
Brazil

Lumbar arthroplasty aims maintenance of movement but clinical and biomechanical results have indicated the need of load absorption.

560. Hybrid Dynamic Stabilization Adjacent to Lumbar Spine Fusion

Ewy-Ryang Chung, PhD; Sang-Ho Lee, MD, PhD
Republic of Korea

The ILF (interspinous locker tension band fixation) represents a hybrid dynamic stabilization immediately above a fusion that allows for the coupling of arthrodesis with dynamic stabilization at adjacent level. Based on results in 10 patients, the ILF holds promise as an alternative to multilevel lumbar arthrodesis while potentially decreasing the risk of ASD following lumbar arthrodesis.

The FDA has not cleared the drug and/or medical device for the use described in this presentation (i.e., the drug or medical device is being discussed for an 'off label' use).

E-POSTER INDEX

561. Prospective Evaluation of a Dorsal Decompression and Posterior Dynamic Flexion-Limiting Stabilization in Patients with Spinal Stenosis and Degenerative Disc Disease: Twelve-Months Follow-Up

Rahel Bornemann; Tom R. Jansen; Lucia A. Otten; Moritz C. Deml, MD; Robert Pflugmacher
Germany

The dynamic posterior spinal stabilization system LimiFlex (Simpirica Spine Inc, CA, USA) has been developed to limit flexion of the segment, thereby reducing forces borne by the disc, addressing the low back pain and stabilizing segments without the need for fusion.

The FDA has not cleared the drug and/or medical device for the use described in this presentation (i.e., the drug or medical device is being discussed for an 'off label' use).

Early Onset Scoliosis**562. Incidence, Magnitude and Classification of Pedicle Screw Migration**

Hazem B. Elsebaie, FRCS, MD; Hilali H. Noordeen, FRCS; Behrooz A. Akbarnia, MD
Egypt

A retrospective review of radiographs of 23 patients treated with single growing rods with a minimum of 4 distractions. We found that the change of screws position toward a more caudal direction in relation to the vertebral body after serial distractions is a frequent occurrence in the distal pedicle screws. Reviewing radiographs of these cases we could identify 3 types of pedicle screw migration.

The FDA has not cleared the drug and/or medical device for the use described in this presentation (i.e., the drug or medical device is being discussed for an 'off label' use).

563. Magnetic Resonance Imaging Findings of Patients with Early Onset Scoliosis

Mehmet B. Balioglu, MD; Temel Tacal, MD; Secil S. Sakizlioglu, MD; Can H. Yildirim, MD
Turkey

The evaluation of Congenital scoliosis (CS) is different from the evaluation of more common idiopathic (IS) or neuromuscular (NS) and syndromic scoliosis (SS) because maternal influences may play a significant role in related deformities and pathologies. Careful magnetic resonance imaging (MRI) analysis allows us to better understand spinal and concomitant anomalies.

564. Are Proximal Rib Anchors Protective Against Rod Breakage in Distraction-Based Growing Rods?

Kent T. Yamaguchi, BA; David L. Skaggs, MD; Karen S. Myung, MD, PhD; Shaun Mansour; Muharrem Yazici, MD; Charles E. Johnston, MD; George H. Thompson, MD; Paul D. Sponseller, MD; Behrooz A. Akbarnia, MD; Michael G. Vitale, MD, MPH
USA

This comparative survival analysis of rod breakage between distraction-based growing rods with proximal spine anchors vs. proximal rib anchors shows that proximal spine-anchored rods have 3.6x increased risk of rod breakage compared to proximal rib-anchored growing rods. High preoperative Cobb angles are also associated with an increased risk of rod breakage.

The FDA has not cleared the drug and/or medical device for the use described in this presentation (i.e., the drug or medical device is being discussed for an 'off label' use).

565. Does Growing Rod Cause Degeneration and Secondary Deformity in the Adjacent Segment?

Caglar Yilgor; Serdar Arıtan, PhD; H Gokhan Demirkiran, MD; Kenan Daglioglu; Kemal Kosemehmetoglu, MD; Muharrem Yazici, MD
Turkey

Although some degeneration occurs with growing rod in the adjacent segment discs and facet joints and motion capability decreases to some degree, it is significantly lower than the changes caused by instrumented fusion. Growing rod is closer to normal physiology even after several lengthening procedures.

566. Limited Anterior Spinal Fusion: An Effective Strategy in Controlling Progressive Early Onset Scoliosis

Shoji Seki, MD; Carrie E. Bartley, MA; Burt Yaszay, MD; Peter O. Newton, MD
Japan

A retrospective review of EOS patients who underwent a short, early ASF to slow progression of their scoliosis (as an alternative to growing rods) was conducted. The ASF successfully delayed the need for a definitive spinal fusion and may be considered in managing patients with EOS prior to the age of definitive fusion.

The FDA has not cleared the drug and/or medical device for the use described in this presentation (i.e., the drug or medical device is being discussed for an 'off label' use).

567. Quantifying the Severity of Thoracic Deformity in Early-Onset Scoliosis: The Spinal Penetration Index

Ryan D. Muchow, MD; Daniel J. Sucato, MD, MS; Anna M. McClung, RN; Richard H. Browne, PhD; Charles E. Johnston, MD
USA

The spinal penetration index is an objective measure of the endothoracic deformity present in early-onset scoliosis. It can be utilized to monitor progression of the deformity and guide treatment.

568. Posterior Vertebral Column Resection in Early Onset Spinal Deformity

Dezsoe J. Jeszenszky, MD; Daniel Haschtmann, MD; Martin Sutter, MD; Andreas Eggspuehler; Frank S. Kleinstueck, MD; Tamas F. Fekete, MD
Switzerland

The authors report on a case series with posterior vertebral column resections (VCR) and clinical outcome for surgical treatment of severe early onset spinal deformities (EOS).

E-POSTER INDEX

569. Is There a Significant Increase in Thoracic Height after Growing Rod Surgery for Early Onset Scoliosis?

Behrooz A. Akbarnia, MD; Nima Kabirian, MD; Jeff Pawelek; Daniel Zhang, BS; Greg Redding, MD; John B. Emans, MD; Suken A. Shah, MD; Charles E. Johnston, MD; Growing Spine Study Group
USA

Growing rod surgery for early onset scoliosis has been shown to significantly increase thoracic height. The majority of growing rod patients reached an adequate thoracic height based on their age after a minimum of three spinal lengthenings.

The FDA has not cleared the drug and/or medical device for the use described in this presentation (i.e., the drug or medical device is being discussed for an 'off label' use).

570. A Preliminary Study on Sleep-Disordered Breathing in Children with Thoracic Insufficiency Syndrome

Takashi Ono, MD; Katsushi Takeshita, MD; Haruhisa Yanagida, MD; Taichi Tsuji; Noriaki Kawakami, MD, DMSc
Japan

A retrospective review was conducted involving 25 children with thoracic insufficiency syndrome (TIS) underwent overnight oximetry in multiple medical care facilities. Twelve children who underwent overnight oximetry demonstrated nadir oxyhemoglobin saturation <90%. Echocardiographic evidences of pulmonary hypertension were observed in children with TIS and co-morbid congenital heart disease. In conclusion, children with TIS are apt to have sleep-disordered breathing. Children both with TIS and co-morbid congenital heart disease should be checked up on the cardiopulmonary function.

571. Decision-Making as Vertical Expandable Prosthetic Titanium Rib (VEPTR) Patients Near Maturity: A Survey of the Chest Wall and Spinal Deformity Study Group (CWSD-SG)

Ajeya Joshi; Jahangir Asghar, MD; Amer F. Samdani, MD; Tricia St. Hilaire, BS; Joshua M. Pahys, MD; Robert M. Campbell, MD; John M. Flynn, MD
USA

Decision-making for patients completing VEPTR treatment has not been standardized. In a survey of surgeons in the CWSD-SG, final treatment decisions in current practice take into consideration several variables, including curve stiffness, coronal and sagittal balance, and patient diagnosis. Concerns with observation and with fusion have been identified. An intention to observe the majority of skeletally mature VEPTR patients is not reflected by actual current practice. Further prospective analysis is needed to develop evidence-based guidelines in this area.

572. What do Coronal Flexibility Films Really Tell us About the Treatment of Idiopathic Early-Onset Scoliosis Patients using Growing Rods?

Burt Yaszay, MD; Nima Kabirian, MD; Jeff Pawelek; Tracey Bastrom, MA; John B. Emans, MD; George H. Thompson, MD; Gregory M. Mundis, MD; Behrooz A. Akbarnia, MD; Growing Spine Study Group
USA

In idiopathic early-onset scoliosis, flexibility films underpredicted the amount of curve correction obtained from index growing rod surgery and do not appear to correlate well with patient age or curve size.

The FDA has not cleared the drug and/or medical device for the use described in this presentation (i.e., the drug or medical device is being discussed for an 'off label' use).

573. Using Growth Guided Rods in Scoliosis Surgery. Preliminary Report

Koltowski Krzysztof; Menartowicz Piotr
Poland

Study design. Authors presents initial results of scoliosis surgery using growth guided rods -'Shilla like'

574. The Use of Rib-Based Distraction in the Treatment of Early Onset Scoliosis in Patients with Arthrogryposis Multiplex Congenita

Nelson Astur, MD; John M. Flynn, MD; John M. Flynn, MD; Michael Glotzbecker, MD; Harold J. van Bosse, MD; Jane S. Hoashi, MD, MPH; Charles R. d'Amato, MD, FRCS; Derek M. Kelly, MD; William C. Warner, MD; Jeffrey R. Sawyer, MD
USA

Rib-based distraction is an effective method of treatment of early onset scoliosis (EOS) and thoracic insufficiency syndrome (TIS) in patients with arthrogryposis multiplex congenita in terms of deformity correction. While the complication rate is high, it is similar to the use of rib-based distraction in other conditions causing EOS and TIS.

575. Characterization of a Scoliosis Model in FGFR3^{-/-} Mice

Neil Saran, MD, MHSc, FRCS; Ali Esmael, MD; Michael B. Sullivan, BSc; Janet E. Henderson, PhD; Jean A. Ouellet, MD
Canada

Fibroblast growth factor receptor (FGFR) 3 deficient mice develop a characteristic kyphoscoliosis between 4 to 8 weeks of age. Radiographic and Micro-CT morphometric data confirm vertebral wedging, disc wedging as well as decreased bone density of vertebral bodies in comparison to wild type mice as seen in human scoliosis. Such a model may prove useful in testing the effects of growth factors on the development and progression of scoliosis.

576. Single Growing Rod with Halo-Femoral Traction for the Treatment of Severe Early Onset Scoliosis

Hongqi Zhang, MD; Yuxiang Wang, MD; Chaofeng Guo
China

The treatment of severe early onset scoliosis remains a challenge for spinal deformity surgeons. The goal of treatment is to control an often rapidly progressing deformity while continuing to allow for an increase in spinal growth. The aim of this study is to determine the safety and effectiveness of the use of single growing rod technique with halo-femoral traction in severe early onset scoliosis.

577. High Accuracy in Placement of Pedicle Screws in Children \leq Ten Years Using Navigation and Intraoperative CT

David W. Polly, MD; A. Noelle Larson, MD; Kenneth J. Guidera, MD; Cary H. Mielke, MD; Edward Rainier G. Santos, MD; Jonathan N. Sembrano, MD; Charles Gerald T. Ledonio, MD
USA

83 navigated pedicle screws were placed in 9 children \leq 10 years with a 98.8% accuracy rate and no peri-operative screw-related complications. This is higher than the reported accuracy of predominantly non-navigated pedicle screws in adults.

The FDA has not cleared the drug and/or medical device for the use described in this presentation (i.e., the drug or medical device is being discussed for an 'off label' use).

578. Surgical Treatment for Early Onset Scoliosis Associated with Rare Diseases

Tiziana Greggì, Head; Francesco Lolli; Elena Maredi; Mario Di Silvestre, MD; Francesco Vommaro; Konstantinos Martikas, MD; Stefano Giacomini; Alfredo Cioni
Italy

Early onset scoliosis is the most common deformity in the field of rare diseases. 11 patients affected by EOS in rare syndrome and surgically treated with growing spinal implants were reviewed. At a mean follow-up of 24 months, thoracic curve correction averaged 50%. A total of 8 complications occurred. Our results showed the effectiveness and safety of growing spinal implants in the treatment of early-onset scoliosis in rare syndromes. An accurate preoperative planning is mandatory.

579. Operative Idiopathic Early Onset Scoliosis and AIS Curves Have Different Characteristics

Mark McElroy, MS; Paul D. Sponseller, MD; Sara K. Fuhrhop, BS; Colin Russell; Peter O. Newton, MD; Michelle C. Marks, PT, MA; James O. Sanders, MD; Muharrem Yazici, MD; Jeff Pawelek; Behrooz A. Akbarnia, MD; Harms Study Group; Growing Spine Study Group
USA

Preoperative radiographs were compared between 60 patients with idiopathic early onset scoliosis (IEOS, normal MRI when indicated) and 1,537 patients with AIS. They differed in T2-T12 kyphosis, stable vertebra, and primary curve parameters (apex, magnitude, direction, thoracic LEV). With a modified Lenke system, distribution differed ($p=0.001$).

581. Non-Fusion Technique Of Growth Guidance For The Treatment Of Early Onset Scoliosis

Daniel Haschtmann, MD; Bettina Kaiser; Tamas F. Fekete, MD; Frank S. Kleinstueck, MD; Dezsö J. Jeszenszky, MD
Switzerland

A case series of 19 children with EOS that were treated with non-fusion growing rod growth sparing technique involving repeated distraction procedures is described. Clinical and radiological outcome and associated complications are demonstrated.

582. Scoliosis Surgical Treatment Before Age Ten

Eugenio Dema, MD; Stefano Cervellati, MD; Matteo Palmisani, MD; Massimo Girardo; Marco Meli, MD; Daniela Zammarchi
Italy

In early onset scoliosis often the non-operative options (casting or/and bracing) are not indicated or fail. The dual growing rod surgical technique continue to develop and are primarily directed at curve correction while simultaneously preserving and/or stimulating spine and chest wall growth.

583. Comparative Study of Relationship between the Fixation Patterns and the Complications of Dual Growing Rod Technique in the Treatment of Early-Onset Scoliosis

Qiyi Li; Jianguo Zhang, MD; Jianxiong Shen, MD; Yipeng Wang, MD; Guixing Qiu
China

Treatment of rapidly progressing scoliosis in young children is challenging. Dual growing rod technique can be effective in curve correction as well as in allowing spinal growth for the treatment of early-onset scoliosis (EOS). But mechanical risk factors may increase complications and the need for repeated surgical procedures. There were few studies on the relationship between the fixation patterns and complications.

584. Effects of the Growing Rod on the Discs and Facet Joints of the Unfused Intermediate Segments

H Gokhan Demirkiran, MD; Caglar Yilgor; Mehmet Ayvaz, MD; Kemal Kosemehmetoglu, MD; Kenan Daglioglu; Muharrem Yazici, MD
Turkey

Although some degenerative changes are observed in the intermediate discs when compared to normal spines growing rod does not cause spontaneous fusion. Growing rod is closer to normal physiology even after several lengthening procedures. Growing rod preserves the disc and facet joints of the intermediate segments and is a "fusionless" procedure.

585. Mortality and Morbidity in Early Onset Scoliosis Surgery

Jonathan H. Phillips, MD; Dennis R. Knapp, MD; Jose A. Herrera-Soto, MD
USA

Surgical treatment of Early Onset Scoliosis is associated with high mortality.

E-POSTER INDEX

Etiology/Genetics

586. How do Tamoxifene (TMX) and Raloxifene (RLX) Affect Scoliosis in Bipedal Scoliotic Cice?

Nadir Yalcin; Ibrahim Akel, MD; H Gokhan Demirkiran, MD; Ozgur Dede, MD; Z Deniz Olgun, MD; Ralph Marcucio, PhD; Emre Acaroglu, MD
Turkey

Efficacy of TMX and RLX in preventing the progression of scoliosis (radiology), and possible mechanism associated with it (histomorphometry) were investigated on a C57BL6 mice model. It was found that RLX is as effective as TMX in preventing progression of scoliosis. Both drugs do not reduce the incidence of scoliosis but the curve magnitudes over time were reduced. These findings suggest that the mechanism associated with this is the early maturation of growth plates. This is important as it suggests the possibility of a medical treatment for the prevention of progression in AIS.

587. Low Vitamin D Levels are Associated with Cervical Disc Herniation in Adults Undergoing Spine Surgery

Geoffrey E. Stoker, BS; Jacob M. Buchowski, MD, MS; Christopher Chen, BA; Han Jo Kim, MD; Moon Soo Park, PhD; K. Daniel Riew, MD
USA

We performed a retrospective, cross-sectional analysis of 91 adult spine surgery patients with cervical MRI and preoperative vitamin D measurement. On multivariate analysis, vitamin D deficiency was associated with increased number of cervical disc herniations per patient ($P=0.023$) and the likelihood of herniation per disc ($P=0.005$).

588. Parental Age at Birth Evaluated in Relation to Trunkal Back Shape Asymmetry in a Large Sample of Schoolchildren: An Epigenetic Mechanism?

Theodoros B. Grivas, MD, PhD; Constantinos Mihas, MD, MSc PhD; Christina Mazioti; Samantha C. Sakellaropoulou; Nikolaos Zisis, MD; Antonios Akriotis; Richard G. Burwell, MD, FRCS
Greece

We evaluate parental ages at birth in relation to trunkal asymmetry in a large sample of school children. Maternal and paternal age are each associated with trunkal asymmetry in males and possibly also in females, more by younger than older parents. We suggest the underlying mechanism involves epigenetics.

589. Comparison between Prader-Willi Syndrome (PWS) and Idiopathic Patients for Characteristics of Scoliosis: Analysis of 58 Scoliosis Patients with PWS

Yutaka Nakamura, MD, PhD; Toshiro Nagai; Takahiro Iida, MD; Satoru Ozeki; Yutaka Nohara, MD
Japan

The purpose of this study was to compare the characteristics of scoliosis in Prader-Willi syndrome patients (Group PWS) vs. idiopathic patients (Group I). We investigated 114 patients (58 Group PWS, 56 Group I). Most PWS patients had a lumbar or thoracolumbar curve. On the other hand, IP patients typically had thoracic scoliosis. There was no statistically significant difference between the two groups with respect to either curve angle or BMI. All patients of PWS had the mental retardation.

590. The Evaluation of Balance in Adolescents with Scoliosis

Patrick T. Knott, PhD, PA-C; Joseph Musto; Samantha Thompson, BS; Steven M. Mardjetko, MD, FAAP
USA

Much investigation has focused on the etiology of adolescent scoliosis. This study looked for a relationship between balance (using a quantitative Romberg test) and the magnitude of spinal deformity (using 3D spinal models created by surface topography). One hundred thirty adolescents were measured, and there was not a significant correlation found between any of the balance parameters and the magnitude of the curve dimensions in the deformity.

Innovative Methods

591. Recapping Laminoplasty for Lumbar Intra-Canal Disorders using T-Saw and Lamina Screw: Approach to the Hidden Zone

Norihide Sha; Masaho Yosikawa; Koji Okamoto; Michihiko Manabe
Japan

This is a retrospective review of 55 patients with intra-spinal canal lesions treated with the recapping laminoplasty (RL). There are few reports, except from Japan, about such a convenient approach of osteoplastic laminotomy in lumbar region.

592. Economic Impact of Minimally Invasive Spine Surgery Open vs. MIS Spinal Fusion Costs in the Perioperative Period (First 45 Days)

William D. Smith, MD; William B. Rodgers, MD; Brent Vanconia, M.BA; John Lucio, DO; Kevin J. Deluzio, PhD
USA

A retrospective hospital cost analysis is performed comparing the costs of a series of two-level minimally invasive spinal fusions to traditional open spinal fusion. Results indicate an overall reduction of costs of MIS two level procedures compared to traditional open approaches

593. Early Relapse after Discectomy of Herniated Lumbar L5-S1 Discs: Fissure Fragmentectomy and Sealing Procedure for a Percutaneous Endoscopic Interlaminar Approach

Hyeon Sung Kim, MD, PhD; Se Jin Jeong, MD, PhD; Hyeong Jun Ahn; Ki Hyun Jeon; Woo Jin Choi; Kwan Tae Kim, MD, PhD; Chang Il Ju, MD, PhD; Seok Won Kim, MD, PhD; Seung Myung Lee, MD, PhD;
Chang Il Ju, MD, PhD
Republic of Korea

Percutaneous discectomy of L5-S1 herniated lumbar discs via an interlaminar approach has a higher relapse rate compared to microscopic open lumbar discectomy in early periods after operation. Using the fissure fragmentectomy and sealing procedure, the early relapse rate of L5-S1 herniated lumbar discs decreased significantly.

594. A Clinical Study of Internal Fixation, Debridement and Interbody Thoracic Fusion to Treat Thoracic Tuberculosis via Posterior Approach

Hongqi Zhang, MD; Mingxing Tang
China

Patients with thoracic spinal tuberculosis were often suffered from severe spinal cord damage and kyphotic deformity and often needed surgical treatments. Anterior debridement and bone graft and either anterior or posterior internal fixation were performed by many researchers as an effective treatment for thoracic spinal tuberculosis. However, this procedure may bears risk of cardiopulmonary complications and prolong recovery time, as well as exposure of the two thoracic vertebrae remains the great challenging to surgeons. Orthopedic operations should be well tolerated, required minimal invasion and minor postoperative complication. The purpose of this study was to evaluate the clinical efficacy and feasibility of one-stage surgical treatment of thoracic tuberculosis by internal fixation, debridement and interbody bone graft via posterior-only approach

595. Six Months Follow-Up of Patients After Lumbar Fusion Surgery Using a New Expandable Pedicle Screw System; A Prospective Study

Ory Keynan, MD.; Elad Sapir, BSc; Orna Popper, MSc; Mark M. Levy, MD, ScD
Israel

A prospective study of spinal fusion patients is presented to assess the safety and feasibility of a new expandable pedicle screw system aimed at improving implant fixation in patients with degenerative disorders, trauma, and pseudoarthrosis following failed lumbar fusion. The patients are followed for 12 months after successful implantation, immediate construct stability and lack of implant-related complications. VAS, ODI and SF36 scores improved after 6 months follow-up. A similar group treated with standard pedicle screws was used as controls.

The FDA has not cleared the drug and/or medical device for the use described in this presentation (i.e., the drug or medical device is being discussed for an 'off label' use).

596. Use of Ultrasonic BoneScalpel in Spine Surgeries: Experience from the First 58 Patients

Isador Lieberman, MD, MBA, FRCSC; Xiaobang Hu, PhD
USA

We retrospective reviewed 58 consecutive patients who underwent spine surgeries with the use of the ultrasonic BoneScalpel. The operation time, blood loss and intraoperative complications were recorded. In all instances the BoneScalpel was able to efficiently create the needed osteotomies to facilitate the surgical procedure without any percussion on the spinal column or injury to the underlying nerves.

597. Use of Bipolar Sealer Device Reduces Blood Loss and Transfusions in Posterior Spinal Fusion for Adolescent Idiopathic Scoliosis

Zachary L. Gordon, MD; Jochen P. Son-Hing, MD, FRCSC; Connie Poe-Kochert, BSN; George H. Thompson, MD
USA

Use of a bipolar sealer device in posterior spinal surgery (PSS) for idiopathic scoliosis (IS) significantly reduces blood loss and transfusions.

598. Dual Motor Monitoring Using Transcranial Motor Evoked Potentials and Neurogenic MEP's During Vertebral Column Resection Prevents Neurologic Deficit

Daniel J. Sucato, MD, MS; Anna M. McClung, RN; Steven Sparagana, MD; Patricia Rampy, MS, REPT, CNIM; Elizabeth M. Van Allen, MS
USA

Dual motor monitoring using transcranial MEP and neurogenic MEP was reviewed in a series of 15 VCR patients with severe spinal deformity demonstrating complimentary identification of critical changes resulting in no permanent neurologic deficits.

599. Significantly Reduced Incidence of Postoperative Thigh Symptoms and Nerve Injury During Transpsaos Approach to Lateral Interbody Lumbar Fusion with a Direct Visualization Surgical Strategy

Joe Kearns; May Bellisle; Tung T. Nguyen, MD; Mitchell A. Hardenbrook, MD; Gary D. Fleischer, MD
USA

This study demonstrated the reduced incidence of postoperative thigh symptoms after transpsaos lateral interbody lumbar spine fusion utilizing a novel retractor system that allows direct visualization of the psoas muscle during the surgical approach. Previous studies have demonstrated an incidence of thigh symptoms around 60%. With this novel visualized approach, it was reduced to around 20%.

600. One-Stage Surgical Treatment for Upper Thoracic Spinal Tuberculosis by Internal Fixation, Debridement and Combined Interbody and Posterior Fusion via Posterior-Only Approach

Hongqi Zhang, MD; Mingxing Tang
China

Patients with upper thoracic spinal tuberculosis were often suffered from severe spinal cord damage and kyphotic deformity and often needed surgical treatments. Anterior debridement and bone graft and either anterior or posterior internal fixation were performed by many researchers as an effective treatment for thoracic spinal tuberculosis. However, this procedure may bears risk of cardiopulmonary complications and prolong recovery time, as well as exposure of the upper two thoracic vertebrae remains the great challenging to surgeons. Orthopedic operations should be well tolerated, required minimal invasion and minor postoperative complication. The purpose of this study was to evaluate the clinical efficacy and feasibility of one-stage surgical treatment of upper thoracic tuberculosis by internal fixation, debridement and interbody bone graft via posterior-only approach.

E-POSTER INDEX

601. Too hot to Handle? - Heat Generation in Spinal Instrumentation during Magnetic Resonance Imaging

Brian Hsu, MB BS, FRACS; Chester E. Sutterlin, MD; Dane Dabirrahmani, PhD; Ronald M. Gillies, PhD
Australia

It is reported that the magnetic radiofrequency (RF) fields applied in magnetic resonance imaging examinations that induce electrical currents in metallic implants. The eddy currents have been reported to heat up the implants and thus may, in part, be capable of causing localised tissue heating. The purpose of this study was to assess ferromagnetism and heating for various spinal fixation devices exposed to a 1.5T and 3T MRI system.

602. Surgical Treatment for Atlantoaxial Osteoarthritis (AAOA): A Prospective Study of 27 Patients

Jan Stulik; Jan Kryl; Tomas Vyskocil; Michal Barna; Petr Nesidal
Czech Republic

The aim of this prospective study was to evaluate the first 27 AAOA patients treated at our department.

603. Results and Complications after AxiaLIF 2 Levels. Minimum Two-Year Follow-Up

Luis Marchi, MSc; Leonardo Oliveira, BSc; Rodrigo A. Amaral; Carlos A. Castro; Thiago Coutinho; Etevaldo Coutinho; Luiz Pimenta, MD, PhD
Brazil

The purpose of this article is to report results and complications of axiaLIF 2-level with a minimum of 24-month follow-up.

604. A Comparative Study On Cage Subsidence Following Standalone Lateral Interbody Fusion

Luis Marchi, MSc; Leonardo Oliveira, BSc; Etevaldo Coutinho; Luiz Pimenta, MD, PhD
Brazil

The influence of the cage width on indexes of surgical goals and complications is yet unknown and it is the main goal of this work.

606. Indications and Treatment Protocols for Halo Gravity Traction in Severe Pediatric Scoliosis: A Survey of the Experts

Joshua M. Pahys, MD; Patrick J. Cahill, MD; Charles R. d'Amato, MD, FRCS; Jahangir Asghar, MD; Randal R. Betz, MD; Chest Wall and Spine Deformity Study Group; Amer F. Samdani, MD
USA

A group of 30 surgeons with extensive experience in halo gravity traction (HGT) responded to a survey evaluating indications, treatment protocols, and management of complications of HGT in severe spinal deformity. There was extensive variability in surgeon responses with only a few statements reaching >70% agreement amongst the group. A prospective study on HGT is needed to establish treatment guidelines for HGT use.

607. The Role of Universal Clamps in the Treatment of Neuromuscular and Syndromic Scoliosis

Christina Hardesty, MD; Jochen P. Son-Hing, MD, FRCS; Connie Poe-Kochert, BSN; George H. Thompson, MD
USA

Universal clamps can be useful in neuromuscular and syndromic scoliosis, and other deformities with a large curve and osteopenic bone.

608. Facet Joint Violation in Pedicle Screw Placement with Intraoperative 3-Dimensional CT (O-Arm) Image-Guidance

Sharon C. Yson, MD; Jonathan N. Sembrano, MD; Peter C. Sanders, MD; Edward Rainier G. Santos, MD; David W. Polly, MD
USA

In a review of 188 cases of 3D image-guided lumbar pedicle screw instrumentation, cranial facet joint violation rate was 18.9%. Percutaneous technique has a significantly lower violation rate than open technique.

609. Posterior-Only Extracavitary Resection and Cage Placement for Lumbar Spinal Metastases: A Three-Center Experience

David B. Bumpass, MD; Jacob M. Buchowski, MD, MS; Brian C. Werner, MD; Addisu Mesfin, MD; Francis H. Shen, MD; Khaled Kebaish, MD
USA

In a multi-center study, 21 patients w/ metastatic tumors of the lumbar spine underwent resection via a posterior-only extracavitary approach. The spinal column was reconstructed with an interbody cage. The only neurologic complication was a single nerve root injury. While operative times were long and intra-op transfusion was needed in most cases, stable constructs were achieved after tumor resection without use of an anterior approach.

610. The Impact of a Constrained Double-Screw Anchor on Resistance to Cyclic Loading and Holding Strength in Anterior Scoliosis Surgery

Heiko Koller, MD; Alexander Auffarth; Wolfgang Hitzl, PhD, MSc; Herbert Resch.; Juliane Zenner, MD; Michael Mayer, MD
Germany

In a biomechanical study three vertebral body fixation types, used for anterior instrumented correction and fusion (AISF) of AIS, were compared. 111 instrumented vertebrae were subjected to a different protocol including stress tests mimicking the in-vivo correction maneuvers used clinically before cyclic loading and pullout test were performed. Results show that a novel constrained double-screw fixation system yields highest resistance to cyclic loads & pullout forces if compared to non-constrained and single-screw systems. The new vertebral anchor type can improve mechanical shortcomings of AISF.

611. Posterior Thoracic Interbody Fusion (PTIF) for Thoracic Disc Herniation (TDH)

Ryoji Yamasaki; Shinya Okuda; Takafumi Maeno; Takamitsu Haku; Motoki Iwasaki, MD DMSc; Takenori Oda, MD
Japan

This study demonstrated that the various types and levels of TDH were treated and sufficient stability of the spine was obtained by PTIF. PTIF with total facetectomy enabled to provide the safe decompression and the sound interbody bone grafting without neurological complication.

612. Application of Intraoperative Computed Tomography with or without Navigation System in Surgical Correction of Spinal Deformity - A Preliminary Result of 59 Consecutive Human Cases

Geng Cui; Yan Wang, MD; Yonggang Zhang, PhD; Songhua Xiao
China

iCT navigation system has been shown to improve accuracy and safety in posterior instrumentation. It not only decreased the operation time but also prevent excessive radiation exposure to medical staff. To date, there are only few reports about the application of the iCT navigation system in spinal deformity surgery.

613. Balloon Kyphoplasty (BK) vs. KIVA Vertebral Augmentation for Osteoporotic and Metastatic Vertebral Fractures

Panagiotis Korovessis, MD, PhD; Thomas Repantis, MD, PhD; Vasilis Vitsas, MD; Konstantinos Vardakastanis
Greece

Kiva vertebral augmentation system is designed to treat osteoporotic or osteolytic vertebral fractures via a minimal invasive procedure, offering at the same time increased safety by reducing PMMA leakage. This prospective randomized study compares the efficacy in vertebral height restoration and cement leakage safety of balloon kyphoplasty (BK) vs. KIVA and the conclusion is that KIVA restores in a better amount vertebral body deformity and is followed by significantly fewer and harmless PMMA leakage than BK.

The FDA has not cleared the drug and/or medical device for the use described in this presentation (i.e., the drug or medical device is being discussed for an 'off label' use).

614. Biomechanical Assessment of Favored Angle Screws with Reduction Tabs and Polyaxial Screws during Scoliosis Correction

Mark Driscoll, BEng, PhD; Jean-Marc Mac-Thiong, MD, PhD; Hubert Labelle, MD; Michael Slivka, MSc; Shawn Stad, MSc; Stefan Parent, MD, PhD
Canada

This computational biomechanical analysis demonstrated reduced scoliosis correction forces provided by a new pedicle screw technology having a favored angle bias and reduction tabs that enables a modified technique to better distribute loads over the spinal construct.

615. Peri-Operative Complications of AxialLIF in Long Fusions to the Sacropelvis in Adult Spinal Deformity

Gbolabo Sokunbi; Michael Faloan, MD; Woojin Cho, MD, PhD; Thomas Ross, MS, RN; Matthew E. Cunningham, MD, PhD; Bernard A. Rawlins, MD; Oheneba Boachie-Adjei, MD
USA

Complications observed with long fusion constructs are many and varied with some being approach and technique related, whilst others are secondary to inherent qualities unique to individual patients and scenarios. The trans-sacral approach provides an alternative method for anterior column support with specific biomechanical advantages.

617. Predictors of Early Postoperative Discharge Following Minimally Invasive Lateral Interbody Fusion (MI-LIF)

William D. Smith, MD; William B. Rodgers, MD; Edward J. Gerber, PA-C; Jeff A. Lehmen, MD; Jody A. Rodgers, MD, FACS
USA

This study examines the characteristic predictors of early postoperative discharge following MI-LIF.

618. The Use of Chewing Gum in Reducing Post-Operative Ileus and Gastrointestinal Complications in Pediatric Scoliosis Patients

Joseph G. Khoury, MD; Shawn R. Gilbert, MD; John S. Doyle, MD; Michael J. Conklin, MD
USA

This is a randomized prospective study designed to evaluate the use of chewing gum to reduce the severity of gastrointestinal complaints and delayed return of bowel function after scoliosis surgery.

619. Cement Augmentation of Screw Fixation

Patrick J. Cahill, MD; Amer F. Samdani, MD; Wenhai Wang, PhD; Randal R. Betz, MD; George Baran, PhD
USA

Cement augmentation of pedicle screw fixation may be used to increase implant fixation strength to allow spinal deformity surgeons to apply greater corrective forces. Little data exist on the biomechanics of this technique. We utilize a finite element model to demonstrate that cement augmentation can improve screw pull-out forces by as much as 156%.

The FDA has not cleared the drug and/or medical device for the use described in this presentation (i.e., the drug or medical device is being discussed for an 'off label' use).

E-POSTER INDEX

620. Can Transsacral AxialIF Fixation at the Bottom of a Long Construct Avoid the Need for Iliac Bolt?

Neel Anand, MD; Babak Khandehroo, MD; Sheila Kahwaty, PA-C; Eli Baron, MD

USA

This study evaluates the role of transsacral AxialIF fixation at the bottom of a long construct in reducing the need for routine placement of iliac screws in all such surgeries. The clinical data supports the notion that excellent results can be obtained without complications with the transsacral fixation and no iliac screws. *The FDA has not cleared the drug and/or medical device for the use described in this presentation (i.e., the drug or medical device is being discussed for an 'off label' use).*

621. Posterior Microendoscopic Laminotomy for Cervical Myelopathy

Takuya Mishiro, MD, PhD; Hirofumi Kosaka, MD, PhD

Japan

Patients who underwent traditional surgeries had to accept some postoperative complications such as adjacent problems or axial neck pain. Clinical results of 29 patients with cervical myelopathy underwent CMEL were reviewed. All patients had good results of JOA scores and less postoperative complications were detected. CMEL is very safe and effective surgery as a minimally invasive procedure for patients with cervical myelopathy.

623. Variations and Accuracy in Readmission Rate Following Spine Fusion Using Administrative Claims Databases

William Schairer, Alexandra Carrer, MD; Beejal Amin, MD; Praveen V. Mummaneni, MD; Lumine Na, MS; Steven Takemoto, PhD; Vedat Deviren, MD; Dean Chou, MD; Shane Burch, MD; Serena S. Hu, MD; Aenor J. Sawyer, MD; Bobby Tay, MD; Christopher P. Ames, MD; Sigurd H. Berven, MD

USA

Unplanned readmissions are an indicator of quality of care and healthcare value, and may affect reimbursement rates. Alternatives to fee-for-service reimbursement include not paying for avoidable re-hospitalizations. Here we demonstrate the potential shortcomings of financial databases to identify unplanned readmissions.

624. Nerve Protection in Extreme Lateral Interbody Fusion

Fernando G. Diaz, MD, PhD; Kristophe J. Karami, DO, MS; Christina Cook, PhD; Risa Tyo, Pharm D

USA

EMR/CT guidance allows the spine surgeon to safely locate the lumbar plexus during surgery, and permits its safe dissection and protection.

625. High Sacral Slope Spondylolisthesis can be Safely Reduced with Anterior Lumbar Interbody Fusion via a Transperitoneal Approach

Jean-Christophe Leveque, MD; Rajiv K. Sethi, MD; Vishal Gala, MD MPH; William C. McQuinn, MD

USA

Patients with L5/S1 spondylolisthesis often have a steep sacral slope. This deformity can be safely corrected by a transperitoneal approach which allows for reduction of the deformity even in patients with a sacral slope up to 60 degrees.

626. Posterior Cervical Fusion - A Novel Method with Preliminary Results in 60 Patients

Bruce McCormack, MD; Edward Eyster

USA

This is a description of a novel posterior fixation construct with follow up results in 60 patients at six months, and 41 patients at one year. *The FDA has not cleared the drug and/or medical device for the use described in this presentation (i.e., the drug or medical device is being discussed for an 'off label' use).*

627. Circumspinal Decompression through a Single Posterior Incision to Treat Thoracolumbar Disc Herniation

Zhongqiang Chen, MD

China

This paper described a new approach for the treatment of thoracolumbar junction disc herniation.

628. Spine Surgery in Developing Countries: A New Model for Equipment Procurement and Capacity Building

Dheera Ananthakrishnan, MD; Gilbert Cavilan; Luigi Sabal; Robert Varner; James Kercher, MD; Steven M. Mardjetko, MD, FAAP

Philippines

A project for ameliorating orthopaedic and spine care in developing countries using idle equipment is outlined, including results from the pilot site in the Philippines.

629. Efficacy of C2-Screw Fixation using an Electrical Conductivity Device (Pediguard): First Report of Accuracy in a Consecutive Series of 40 Patients

Heiko Koller, MD; Luis Ferraris, MD; Juliane Zenner, MD; Oliver Meier, MD

Germany

The Pediguard is an electrical conductivity device. It mimics a pedicle awl and by signaling it enables real-time navigation in vertebral bone and anticipation of pedicle breaches. We performed an analysis of accuracy in 40 pts who had posterior cervical spine fusion and instrumentation using C2-screws. CT-scans showed that insertion accuracy was high and stressed that the Pediguard is a useful adjunct to the surgeons armamentarium, particularly in the more challenging cases w/ difficult, small or distorted anatomy.

630. Treatment of kyphosis in Mucopolysaccharidosis using VEPTR*Naveed Yasin, FRCSEd (Tr&Orth); Neil Oxborrow, MD FRCS (Tr&Orth)*

United Kingdom

To evaluate the use of VEPTR (Vertical Expandable Prosthetic Titanium Rib) for the treatment of kyphosis in children with mucopolysaccharidosis.

631. Lumbar Fixation using Pedicle Screws with a Cortical Bone Trajectory Through a Minimally Invasive Portal*Charles Branch, MD; Wesley Hsu; Matthew Neal, MD*

USA

We describe an early clinical experience of a novel technique in 26 patients using a minimally invasive portal for placement of lumbar and sacral transpedicular screws with a medial to lateral trajectory, termed "cortical bone trajectory" (CBT). This technique offers the theoretical advantages of improved cortical bone purchase and decreased soft tissue disruption with a more medial insertion site compared to a traditional trajectory along the anatomical axis of the pedicle facilitating the minimally invasive midline approach in de novo and add-on lumbosacral constructs.

632. Far-Lateral Interbody Fusion (FLIF): A Technique for Post-Harrington Rod Revision Surgery. Converting a Revision into a Primary Surgery*Laury A. Cuddihy, MD; Joel Gorenstein, R-PAC; Jeffery M. Schwartz, MD; Allison Rovillos, RN, CNOR; Claire D. Butz; M. Darryl Antonacci, MD*

USA

The Far-Lateral Interbody Fusion technique, which takes advantage of a modified-Wiltse less invasive, muscle-sparing approach for post-harrington rod revision results in decreased hospital length of stay, surgical time and blood loss vs. traditional subperiosteal paraspinal techniques.

Kyphosis**633. A Modified Technique to Prevent PJK Following Surgical Treatment of Scheuermann's Disease***Meric Enercan; Cagatay Ozturk, MD; Sinan Kahraman; Alauddin Kochai; Ahmet Alanay; Azmi Hamzaoglu, MD*

Turkey

In this study, we have defined a surgical strategy to prevent PJK after surgery for Scheuermann's Disease.

634. Posterior Vertebral Column Resection for Kyphosis Correction in Juveniles from West Africa: Intra-Operative, Early & Two-Year Outcomes and Complications*Michael Faloon, MD; Dennis S. Meredith, MD; Woojin Cho, MD, PhD; Akilah B. King, BA; Baron S. Lonner; Ferran Pellise, MD; Michael J. Mendelow, MD; Elias C. Papadopoulos, MD; W. F. Hess, MD; Kenneth J. Paonessa, MD; Francisco Javier Sánchez Pérez-Gruoso; Oheneba Boachie-Adjei, MD; Focos Organization*

USA

This is a retrospective review of outcomes and complications of posterior vertebral column resection for kyphotic deformity in juvenile patients treated at a single facility in West Africa. This series demonstrates that PVCR is a safe and effective technique for correction of kyphosis that is tolerated fairly well in juveniles.

635. Long-Term Follow-Up Results Following Laminectomy for Cervical Ossification of the Posterior Longitudinal Ligament*Soo Eon Lee; Chun Kee Chung, MD, PhD*

Republic of Korea

We analyzed the changes in the cervical curvature after laminectomy and subsequent changes in neurological status in treating ossification of the posterior longitudinal ligament (OPLL) of the cervical spine.

636. Prediction of Postoperative Height Increase after Deformity Correction in Scheuermann's Kyphosis*Patrick J. Cahill, MD; Amer F. Samdani, MD; Hitesh Garg, MD; Joshua M. Pahys, MD; Baron S. Lonner; Randal R. Betz, MD; Harms Study Group*

USA

Patients with Scheuermann's kyphosis are interested in the potential increase in height following surgery. We studied the correlation between various clinical and radiographic factors and postoperative gain in height. Our results indicate that the magnitude of deformity in the sagittal plane is the only significant preoperative factor associated with changes in height after posterior surgery for Scheuermann's kyphosis.

637. Clinical and Radiographic Evaluation of Posterior Surgical Correction for Treatment of Moderate to Severe Post-Tubercular Kyphosis*Zhongqiang Chen, MD; Yan Zeng, MD; Qiang Qi, MD; Zhaoqing Guo, MD; Weishi Li, MD; Chuiguo Sun, MD*

China

Post-tubercular kyphosis of thoracolumbar spine can result in severe back pain or neurological deficit of lower extremities. The surgical correction of this focal deformity is full of risk and challenge. We performed the decompression and correction of kyphosis through a single posterior approach, and got an average corrective rate of 67%. The two surgical techniques (mPSO and VCR) demonstrated comparable radiographic and clinical results.

638. Proximal Junctional Kyphosis in Patients after Scheuermann's Kyphosis Surgery Using all Pedicle Screw Construct*Dinesh Thawrani, MD; Viral Jain, MD; Alvin H. Crawford, MD; Peter Sturm, MD*

USA

This study shows 27% incidence of PJK after surgical correction of Scheuermann's Kyphosis using pedicle screw instrumentation, with or without transverse process hooks at the top end of the construct. There were no preoperative or intraoperative predictors for PJK.

E-POSTER INDEX

639. Number of Segments that Should Undergo Ponte Osteotomy during Corrective Surgery for Scheuermann's Kyphosis (SK)

Dinesh Thawrani, MD; Viral Jain, MD; Alvin H. Crawford, MD; Emily Eismann, MS; Peter Sturm, MD
USA

The current study shows that an average four levels of PO accompanied with a cantilever correction maneuver is adequate to bring the curve of SK to within the normal range of thoracic kyphosis.

641. Analysis of Pain and Function in Relation to Radiographic Parameters in Patients with Scheuermann's Kyphosis

Per D. Trobisch, MD; Amer F. Samdani, MD; Joshua M. Pahys, MD; Peter O. Newton, MD; Randal R. Betz, MD; Baron S. Lonner; Patrick J. Cahill, MD
USA

When looking at the correlation between pain or decreased function and radiographic parameters in patients with Scheuermann's kyphosis, it was determined that relative hypolordosis was found to correlate with increased pain.

642. Clinical Study of Safe-Control of Spinal Osteotomy System in Posterior Spinal Osteotomy of Severe Angular Spinal Kyphosis

Yonggang Zhang, PhD; Kai Song
China

The incidence of neural complication is still very high during spinal osteotomy procedure in severe spinal kyphosis patients. Spinal subluxation and over-shortening of spinal cord were regarded as the two main mechanisms of neurologic complication.

643. Hilus Pulmonis as the Gravity Center for AS Thoracolumbar Kyphosis and Deformity Planning

Yonggang Zhang, PhD; Kai Song
China

Since SVA was proofed a meaningful measurement and widely used for evaluating sagittal balance, it has been considered as a design standard for surgery, including most AS kyphotic deformity plannings. However, recent researchs indicate that C7 plumbline actually is not the gravity line. Therefore, for AS thoracolumbar kyphosis, whether there exists a better radiological marker as gravity center of the trunk is still unknown.

644. Severe Rigid Spinal Kyphosis due to Chronic Osteoporotic Compression Fractures is High Risk Factor of Gastro Esophageal Reflux Disease

Tomohiko Hasegawa; Yu Yamato; Sho Kobayashi, PhD; Daisuke Togawa, MD, PhD; Tatsuya Yasuda; Yukihiko Matsuyama, MD
Japan

We investigated the frequency of gastro esophageal reflux disease (GERD) and another gastric disease with severe kyphosis due to chronic vertebral fractures. Fifteen severe kyphosis patients underwent Esophagogastroduodenoscopy before spinal operation, 27% patients had esophagogastric hiatus hernia and 6 (40%) had mucosal inflammation by GERD.. We found that severe spinal kyphosis due to osteoporotic vertebral compression fracture have higher risk of GERD and esophagogastric hiatus hernia. Correction of kyphosis by posterior vertebral column resection (PVCR) could improve the GERD symptoms.

645. Scheuermann Kyphosis Correction: Is there a Correlation with Instrumentation Density?

Mario Di Silvestre, MD; Francesco Lolli; Francesco Vommaro; Angelo Toscano; Tiziana Greggi
Italy

27 patients surgically treated by posterior only instrumented fusion for Scheuermann kyphosis were reviewed to identify if there's a correlation between kyphosis correction and instrumentation density. Patients were divided into 2 groups, according to the type of instrumentation used (pedicle screws only or pedicle screws/hooks). The overall % correction of kyphosis was 31.1%, 34.8% with screws, 25.7% with screws/hooks. Even in absence of statistical significance, there was a better kyphosis correction using pedicle screws and with implant density >50%.

646. Successful Brace Treatment of Scheuermann's Kyphosis in Skeletally Mature Patients and Severe Kyphosis

Kent T. Yamaguchi, BA; Lindsay Andras, MD; Christopher Lee, BS; David L. Skaggs, MD
USA

This study retrospectively reviews patients treated for Scheuermann's kyphosis at a single center with a minimum of 2-year follow-up, and shows successful brace treatment in skeletally mature patients and severe kyphosis.

Lumbar Degenerative

647. Decompression laminectomy with DIAM augmentation for lumbar spinal stenosis: 4 years follow-up outcomes

Justin Boey; Benjamin Tow, MBBS, MMED(Orth), FRCS (Orth)

Singapore

Device for Intervertebral Assisted Motion (DIAM) (Medtronic, Minnesota, USA) system acts as an inter-spinous dynamic non-fusion fixation system by providing compressibility between vertebrae. This study investigates long-term outcomes of DIAM as an augment in hemi-laminectomy for treatment of unilateral lumbar spinal stenosis (LSS). Clinical outcome scores show no difference between DIAM and control group at 6 months, 2 years and 4 years post-operation ($p > 0.05$). There is no long-term clinical value of inserting DIAM as an augment to hemi-laminectomy for treatment of single-level unilateral symptomatic LSS.

The FDA has not cleared the drug and/or medical device for the use described in this presentation (i.e., the drug or medical device is being discussed for an 'off label' use).

648. Neurologic Complications in Extreme Lateral Interbody Fusion (XLIF): A Comparative Analysis of Levels L2-3, L3-4, and L4-5

William D. Smith, MD

USA

Nerve safety is a primary concern during the lateral approach for anterior lumbar interbody fusion (XLIF). In a series of 252 patients, anterior thigh sensory changes/pain and lower extremity motor deficits seen postoperatively following XLIF are reported. The adherence to advanced neuromonitoring assists in motor nerve injury avoidance, but more anterior docking may result in increases thigh sensory deficits, as sensory nerves run more anteriorly and cannot be monitored with EMG.

The FDA has not cleared the drug and/or medical device for the use described in this presentation (i.e., the drug or medical device is being discussed for an 'off label' use).

649. Transforaminal vs. Posterior Interbody Fusion: A Comparison of Outcomes and Economics

Katharine Cronk, MD, PhD; Laura Snyder, MD; Samuel Kalb, MD; Luis Perez-Oribe, MD; Nicholas Theodore, MD, FACS

USA

We present a comparative analysis of 611 consecutive patients who underwent lumbar fusion using either PLIF or TLIF procedure in order to evaluate the clinical or economic advantage of one technique over the other. Surgical outcomes were evaluated based on complications, symptomatic improvement, re-operation incidence, hospitalized days, costs of procedure, and postoperative clinical outcomes. Results showed no significant advantage of one technique over another. However, the cost of PLIF was significantly higher.

650. A Peri-Operative Cost and Charge Analysis Following Single Level Minimally Invasive vs. Open Transforaminal Lumbar Interbody

Kern Singh, MD; Frank M. Phillips, MD; Miguel A. Pelton, BS

USA

Although hospital reimbursements appear higher in the open group over the MIS group, shorter surgical times and length of stay days in the MIS TLIF technique provide opportunities for hospitals to reduce utilization of resources and to increase surgical case volume.

652. Clinically Important Deterioration in Lumbar Spine Surgery Patients: A Choice of Methods Using the Oswestry Disability Index, MOS Short Form 36, and Pain Scales

Jeffrey L. Gurn, MD; Steven D. Glassman, MD; Leah Y. Carreon, MD, MSc

USA

A threshold for clinical deterioration was difficult to identify. This may be due to the small number of patients reporting being worse after surgery and the variability across methods to determine deterioration thresholds. The most widely used MCID values were from the MDC. The MDC for deterioration in this sample were 1.5 points for ODI, 0.7 points for SF36PCS, and 0.2 points for back and leg pain. Overall, it appears that patients may interpret the absence of change as deterioration.

653. Clinical Review of Lumbar Spine Fusion for Chronic Low Back Pain due to Degenerative Disc Disease

Frank M. Phillips, MD; Paul J. Slosar, MD; Jim A. Youssef, MD; Gunnar B. Andersson; Frank Papatheofanis, MD, MPH, PhD

USA

A comprehensive systematic literature review of surgery for discogenic chronic low back pain shows clinically important improvements in patient-reported clinical outcomes following lumbar fusion.

654. Stand Alone Anterior Lumbar Interbody Fusion for Degenerative Disc Disease of the Lumbar Spine: Results with a Two-Year Follow-Up

John Lammi, MD; Camden Whitaker, MD; Alan Moskowitz, MD; Jennifer Duong, BA; Elizabeth Ablah, PhD, MPH; Frank Dong, PhD; Paul H. Wooley, PhD; Lara N. Felts; Geoffrey Konye, BS Nursing; Brent Adams, MD

USA

The purpose of this retrospective study was to report the radiographic, clinical, and functional outcomes of a consecutive series of patients diagnosed degenerative disc disease between L4 and S1 treated with stand alone anterior lumbar interbody fusion (either 1- or 2-level) and use of recombinant human bone morphogenetic protein (rhBMP-2).

The FDA has not cleared the drug and/or medical device for the use described in this presentation (i.e., the drug or medical device is being discussed for an 'off label' use).

E-POSTER INDEX

655. Correlations between the EQ-5D, the Oswestry Disability Index, and Pain Numeric Rating Scales

Benjamin Mueller, MD, PhD; Leah Y. Carreon, MD, MSc; Lauren O. Burke, MPH; Chelsea E. Canan, MPH; Steven D. Glassman, MD
USA

Data from 8385 patients with low back pain showed strong correlations between EQ-5D and ODI and back pain scores; and moderate correlations between the EQ-5D and leg pain scores. Increasing disability, as measured by ODI, produced lower EQ-5D scores. The EQ-5D, a commonly used, easily administered, brief, and simple utility measure, can serve spine surgeons as an effective measure of clinical outcome and economic impact.

656. Clinical Outcomes following Silicate-Substituted Calcium Phosphate use in a Minimally Invasive Transforaminal Lumbar Interbody Fusion

Miguel A. Pelton, BS; Kern Singh, MD
USA

Silicate substituted calcium phosphate was associated with a significantly lower rate of arthrodesis as compared to BMP-2 in the setting of a MIS TLIF. The FDA has not cleared the drug and/or medical device for the use described in this presentation (i.e., the drug or medical device is being discussed for an 'off label' use).

657. A Prospective Evaluation of Minimally Disruptive Lateral Interbody Fusion in the Treatment of Spondylolisthesis: Mid-Term Clinical and Radiographic Outcomes

Kaveh Khajavi, MD, FACS; Alessandria Y. Shen, BA; Anthony L. Hutchison, MSN
USA

Minimally-invasive lateral approaches for anterior lumbar interbody fusion (XLIF) are increasingly being used as an alternative to open direct anterior ALIF. In this series of 60 patients who underwent XLIF for spondylolisthesis correction, mid-term results showed significant improvements in clinical and radiographic outcomes.

The FDA has not cleared the drug and/or medical device for the use described in this presentation (i.e., the drug or medical device is being discussed for an 'off label' use).

659. The Use of a Novel Minimally Invasive Interspinous Spacer for the Treatment of Moderate Lumbar Spinal Stenosis: One-year Outcomes of a Multicenter, Randomized, Controlled FDA IDE Trial

Edward J. Dohring, MD; Peter G. Whang, MD; W. Daniel Bradley, MD; Douglas G. Orndorff, MD; Larry E. Miller, PhD; Jon E. Block, PhD
USA

One-year results of a prospective, multi-center, randomized study demonstrate clinical improvements in axial and extremity pain as well as functional outcomes of patients treated with the Superion Interspinous Spacer for moderate lumbar spinal stenosis (LSS).

The FDA has not cleared the drug and/or medical device for the use described in this presentation (i.e., the drug or medical device is being discussed for an 'off label' use).

660. Minimally Invasive Transforaminal Lumbar Interbody Fusion: The Surgical Learning Curve

Kern Singh, MD; Miguel A. Pelton, BS
USA

The MIS TLIF procedure presents a significant learning curve to the practicing spine surgeon with regards to intra- and peri-operative parameters of surgical time, EBL, IV fluids and duration of anesthesia

661. MIS Lumbar Fusion in an Ambulatory Surgery Center (ASC): Safety, Treatment Outcomes, and Comparison with Inpatient Lumbar Fusion

William D. Smith, MD; Ginger M. Christian, BS
USA

Outpatient spine surgery is becoming more frequent as modern minimally disruptive approaches decrease associated morbidity and allow for hastened postoperative recovery. In a series of 54 consecutive patients treated with a minimally invasive lateral approach lumbar interbody fusion at an ambulatory surgery center, patients were discharged an average of 5 hours and 46 minutes postoperatively with a 3.7% rate of readmission.

The FDA has not cleared the drug and/or medical device for the use described in this presentation (i.e., the drug or medical device is being discussed for an 'off label' use).

663. 600 Cases Comparing Clinical Outcomes between Posterior Lumbar Fusion and Posterior Lumbar Interbody Fusion

Katharine Cronk, MD, PhD; Ali M. M. Elhadi M., MD; Samuel Kalb, MD; Laura Snyder, MD; Nicholas Theodore, MD, FACS
USA

We present a comparative analysis of 600 consecutive patients who underwent lumbar fusion using either conventional screw-rod or PLIF procedure in order to evaluate the clinical advantage of one technique over the other. Surgical outcomes were evaluated based on complications, symptomatic improvement, re-operation incidence, hospitalized days, and postoperative clinical outcomes. No statistical difference was seen in the clinical outcomes between PLF and PLIF patients. However, PLF cases showed a significant increase in the incidence of re-operation when compared to PLIF.

664. Long-Term Clinical Outcomes of Surgical Treatment of Lumbar Spinal Stenosis

Yakiv Fishchenko, MD, PhD; Oleg Perepechay
Ukraine

Surgical treatment of patients with lumbar spinal stenosis (LSS) includes many ways of decompression of the spinal canal and stabilization of the vertebrae. Along with the classical methods of the multi-level laminectomy in recent decades have been increasingly used selective and microsurgical methods of decompression with or without multi-level posterior spinal instrumentation and fusion (PSIF).

665. Comparison of Clinical Outcomes following Interspinous Process Distractor (X-STOP) Implantation or Interlaminar Lumbar Instrumented Fusion (ILIF) for Lumbar Spinal Stenosis

Charles Milchteim, MD; Joseph R. O'Brien, MD, MPH; Michael T. Benke, MD; Matthew R. Livingood; Warren D. Yu, MD
USA

A clinical comparison of the X-STOP and Interlaminar Lumbar Instrumented Fusion (ILIF) was undertaken. Both procedures resulted in similar clinical improvement therefore the addition of interlaminar fusion in the short to mid-term follow-up does not appear to afford significant advantages. Long term follow-up is needed to validate this conclusion.

666. Dynamic Fixation without Fusion in the Treatment of Degenerative Lumbar Diseases. Can it Prevent Junctional Complications?

Mario Di Silvestre, MD; Francesco Lalli; Konstantinos Martikos, MD; Francesco Vommaro; Tiziana Greggi
Italy

Dynamic fixation has been introduced in order to avoid some complications of posterior fusion, such as junctional degeneration. We retrospectively reviewed 175 patients affected by degenerative lumbar disease and treated with dynamic fixation. At a minimum follow-up of 3.1 years, 40 complications occurred in 38 patients (21.7%). Revision surgery was necessary in 20 cases (11.4%). The protective effect vs. junctional disease seemed to be confirmed, with an incidence of 4%. Questionnaires showed a statistically significant improvement of clinical outcome at final follow-up.

668. Early 24-Month Results of Lumbar Fusion (TLIF) with Cellular Allograft or BMP-2: Evaluation of Radiographic and Patient Outcomes

Ashok B. Biyani, MD
USA

This, single-center, institutional review board-approved study aims to compare the 24-month clinical and radiographic outcomes of cellular allograft (Osteocele® Plus, NuVasive, Inc., San Diego, CA) and recombinant bone morphogenetic protein (rhBMP-2) (INFUSE®, Medtronic, Inc. Minneapolis, MN) when used in instrumented transforaminal lumbar interbody fusion (TLIF) procedures.

As this study is currently ongoing, this abstract serves as an interim report of the clinical outcomes and fusion results at 24-months.

The FDA has not cleared the drug and/or medical device for the use described in this presentation (i.e., the drug or medical device is being discussed for an 'off label' use).

669. ALIF vs. AxialLIF for L5-S1 Interbody Fusion: A Retrospective Cohort Study

Jeffrey S. Fischgrund, MD; Lisa Ferrara, PhD
USA

Assess safety and efficacy of AxialLIF compared to ALIF at 24 months.

670. A Comparison of Open vs. MIS TLIFs in a Worker's Compensation Patient Population

Kern Singh, MD; Miguel A. Pelton, BS; Frank M. Phillips, MD
USA

Contrary to popular belief immediate outcomes and hospitalizations between non-WC and WC populations did not differ regardless of surgical technique (MIS/open).

671. How Does Design and Implantation Technique Effect Load Distribution for Different Lateral Spinal Implants?

Baron S. Lonner; Robert Banco, MD; Robert D. Paxson, MS; Lawrence M. Boyd, PhD
USA

In this in vitro study, we evaluated the load capacity and pressure distribution for two different implant designs using three different testing modalities. Polymer implants were created in two configurations: solid spacer and dual-chamber cage designs. Implants were oriented transversely. Both contact dye film and a pressure transducer film were used to evaluate surface contact and pressure. Contact area/pressure values were similar for both implants although contact area tended to be greater for the spacer.

672. Radiographic Findings from a Single Site Investigating the use of XLIF as a Treatment for Adjacent Segment Disease at One-Year Follow-Up

Jim A. Youssef, MD; Douglas G. Orndorff, MD; Katie A. Patty, MS; Morgan A. Scott, MS
USA

Little evidence exists supporting the use of XLIF as an effective treatment for ASD.

673. Preventing Facet Degeneration after Discectomy with a Partial Disc Endoprosthesis: Correlations with Clinical Outcomes at Two Years

Milorad Vilendecic; Darko Ledic; Gerrit J. Bouma, MD, PhD; Martin Barth; Sandro Eustacchio; Shlomit Stein
Germany

Facet joint health was evaluated in lumbar discectomy patients and then compared with patients who had received both a discectomy and the Barricaid, an endoprosthesis aimed at reducing reherniation rate and maintaining disc biomechanics. Both a lower rate and lower severity of facet degeneration was observed in Barricaid patients. However, clinical outcomes at two years were not significantly different between patients who had exhibited facet degeneration and those who had not.

The FDA has not cleared the drug and/or medical device for the use described in this presentation (i.e., the drug or medical device is being discussed for an 'off label' use).

E-POSTER INDEX

674. Radiographic and Clinical Outcomes in Extreme Lateral Interbody Fusion: An Interim Analysis

Antoine G. Tohmeh, MD; Xavier J. Zielinski, MD; Blake Watson, MD; William D. Smith, MD
USA

This work reports clinical and radiographic outcomes using XLIF in a series of 39 patients with at least 12 months follow-up showing generally favorable clinical and radiographic results.

The FDA has not cleared the drug and/or medical device for the use described in this presentation (i.e., the drug or medical device is being discussed for an 'off label' use).

675. Comparative Study of Lateral and Posterior Lumbar Interbody Fusion in Patients with Degenerative Lumbar Spondylolisthesis

Abhijit Pawar, MD; Alex Hughes, MD; Darren R. Lebl, MD; Fadi Taher, MD; Kristaps Bokums; Andrew A. Sama, MD; Federico P. Girardi, MD; Frank P. Cammisa, MD
USA

This study compared 78 matched patients with degenerative lumbar spondylolisthesis (DS) treated by the Lateral (LLIF) and the posterior lumbar interbody fusion (PLIF) with segmental posterior spinal instrumentation (SSI). The average blood loss and incidence of dural tears was significantly lower in the LLIF group. The restoration of disc height, foraminal height and segmental lumbar lordosis was significantly better in the LLIF group. The improvement in patient outcome scores was similar in both groups.

676. Predictors of Quality of Life and Physical Function after Surgical Treatment of Lumbar Spinal Stenosis

Natalie M. Egge, MD; Anthony S. Lapinsky, MD; Daniel Mandell, BS; Hanbing Zhou, MD; Jason C. Eck, DO, MS; Christian P. DiPaola, MD; Jeffrey Lange, MD; Patrick J. Connolly, MD; Patricia Franklin, MD, MBA, MPH
USA

Lumbar stenosis is common in adults and evidence-based information regarding optimal patient selection for surgery is limited. This study aims to identify predictors of quality of life and physical function following operative management. SF36 health surveys were reviewed and post-operative MCS and PCS scores were analyzed by multivariate linear regression analysis. In general, patients reported substantial improvement in both quality of life and physical function post-operatively. Predictive factors associated with poor MCS scores include revision surgery and mental health disorders.

677. Prospective Efficacy Study of Caudal and Transforaminal Epidural Steroid Injections in Patients with Lumbar Sciatica

Avraam Ploumis, MD, PhD; Christodoulou Pavlos; Dimitrios Varvarousis; Ioannis Gelalis; Vasilios Vragalas; Alexander E. Beris
Greece

The aim of this study is to evaluate prospectively the efficacy of caudal and transforaminal steroid injections in patients with lumbar sciatic pain. Both caudal and transforaminal steroid injections achieved adequate remission of symptoms for at least six months even though transforaminal injections were more effective.

678. Preventing Reherniations with a Partial Disc Endoprosthesis

Gerrit J. Bouma, MD, PhD; Martin Barth; Milorad Vilendecic; Darko Ledic; Ronald H. Bartels, MD, PhD
Netherlands

In a high reherniation risk patient population, the reherniation rate of patients implanted with the Barricaid endoprostheses was determined and compared to other investigations. High risk patients were identified by annular defects whose widths were greater than 6mm, indicating poor annular competence. With a mean latest follow-up of 18.2 months, the symptomatic reherniation rate was 1.5% in Barricaid patients, statistically different ($p=0.009$) than 27.3%, as reported in the literature for patients meeting the same annular defect width criterion.

The FDA has not cleared the drug and/or medical device for the use described in this presentation (i.e., the drug or medical device is being discussed for an 'off label' use).

679. Radiographic Comparison of Direct Lateral Transpoas Lumbar Interbody Fusion and Transforaminal Lumbar Interbody Fusion

Patrick A. Sugrue, MD; Nicholas P. Slimack, MD; Timothy R. Smith, MD, PhD, MPH; Jamal McClendon, MD; John C. Liu, MD; Tyler Koski, MD; Richard G. Fessler, MD, PhD
USA

Both direct lateral transpoas and transforaminal lumbar approaches are used to achieve interbody fusion. No study has analyzed the radiographic differences between the two approaches. This study shows that there is no statistically significant difference between direct lateral transpoas lumbar interbody fusion (DLIF) and transforaminal lumbar interbody fusion (TLIF) in anterior and posterior disc height, foraminal height, local sagittal and coronal disc angle, and lumbar lordosis.

680. Is Type of Compensation a Predictor of Outcome for Lumbar Fusion?

Jeffrey L. Gum, MD; Steven D. Glassman, MD; Leah Y. Carreon, MD, MSc
USA

Patients receiving compensation are perceived to have poor clinical outcomes after lumbar fusion. However, patients receiving compensation such as long-term disability or government-supported insurance not on worker's compensation have not been studied independently. Our study shows that the type of compensation influences outcome. Worker's compensation has a clear, isolated, negative influence on outcome when compared to controls; while, well-selected patients receiving disability-type compensation seem more likely to benefit from lumbar fusion.

681. In Vitro Study of Rotatory Olisthesis in the Lumbar Spine: An Experimental Model

Avraam Ploumis, MD, PhD; Amir A. Mehbod, MD; Ioannis Gelalis; Kirkham B. Wood, MD; Ensor E. Transfeldt, MD
Greece

An in vitro biomechanical study of rotatory olisthesis in the lumbar spine with a synthetic model is described. Different centers of rotation and various angles of lumbosacral lordosis were tested for the production of rotatory olisthesis. The radiological finding of rotatory scoliosis was exacerbated with the center of rotation lying in the posterior column and with normolordotic or hyperlordotic lumbosacral spine.

682. Minimally Invasive Lateral Interbody Fusion (Mi-LIF) in Smokers

William B. Rodgers, MD; Edward J. Gerber, PA-C; Jeff A. Lehmen, MD; Jody A. Rodgers, MD, FACS
USA

In a large single-site series of Mi-LIFs, 356 patients smoked at the time of surgery. Overall clinical and radiographic outcomes and are reported

683. Minimally Invasive Treatment of Adjacent Segment Degeneration via the Lateral Approach

William D. Smith, MD; William B. Rodgers, MD; Edward J. Gerber, PA-C; Jeff A. Lehmen, MD; Jody A. Rodgers, MD, FACS
USA

In a large single-site series of Minimally Invasive Lateral Interbody Fusions (Mi-LIF), 335 patients were treated for ASD. Overall clinical and radiographic outcomes and are reported; results were encouraging.

684. Predictors of Improved Pain after Surgical Treatment of Lumbar Spinal Stenosis

Natalie M. Egge, MD; Anthony S. Lapinsky, MD; Daniel Mandell, BS; Jason C. Eck, DO, MS; Hanbing Zhou, MD; Christian P. DiPaola, MD; Jeffrey Lange, MD; Patrick J. Connolly, MD; Patricia Franklin, MD, MBA, MPH
USA

Degenerative lumbar stenosis is common in adults and evidence-based information regarding optimal patient selection for surgery is limited. This study aims to identify predictors of pain relief following operative management. SF36 health surveys of adults treated surgically for lumbar stenosis were retrospectively reviewed and post-operative pain scores were analyzed by multivariate linear regression analysis. In general, patients reported substantial improvement in both pain and physical function. Predictive factors associated with poor pain relief include smoking, diabetes, instrumentation, and re-operation.

685. Twelve-Month Clinical and Radiographic Results from an Ongoing Prospective, Multicenter Evaluation of Interlaminar Lumbar Instrumented Fusion (ILIF)

Hyun Bae, MD
USA

This interim report of a prospective multicenter study supports ILIF as an alternative to pedicle screw-based instrumented posterior fusion that results in posterior bone growth, yields improvements in patient-reported outcomes and high satisfaction.

686. Presacral L5-S1 Interbody Fusion: Prospective Longitudinal Study of 24 Patients with Up to Two-Year Follow-Up

Frederik Pennings, MD, PhD; George Malcolmson; John Weaver, MD
USA

Axialif is a minimally invasive transsacral approach to stabilize the lumbosacral segment. Little prospective clinical and radiographic data exist with long term follow-up using this technique in patients suffering from back pain with or without radiculopathy. We present prospectively collected data using the Axialif method in 24 patients and demonstrate that this minimally invasive surgical technique provides a safe, fast and reliable access to the lumbosacral segment with good clinical and radiographical outcome.

687. Platelet-Rich Fibrin Matrix in Posterolateral Lumbar Spine Fusion

Antonio Breceovich, BA; Robert M. Brenner, MS; Celeste Abjornson, PhD; Frank P. Cammisa, MD
USA

A retrospective review of 19 consecutive patients who underwent posterolateral lumbar fusion (PLF) with platelet-rich fibrin matrix (PRFM). Twenty-four month follow-up data includes radiographic findings that demonstrate significant and consistent fusion rates.

688. Foraminal Dimensions in Patients with Degenerative Lumbar Scoliosis and Radiculopathy due to Foraminal Stenosis

Shunji Tsutsui; Hiroshii Yamada, MD, PhD; Hiroshi Hashizume, MD, PhD; Akihito Minamide, MD, PhD; Yukihito Nakagawa, MD, PhD; Masaki Kawai, MD; Hiroshi Iwasaki, MD; Munehito Yoshida
Japan

Patients with degenerative lumbar scoliosis (DLS) and radiculopathy due to foraminal stenosis (FS) sometimes need surgical treatment. Retrospective review of CT scans of such patients demonstrated that posterior disc bulging and ligamentum flavum hypertrophy may contribute to FS irrespective of scoliosis. Patients with DLS and radiculopathy due to FS might be treated by decompression alone including the resection of posteriorly bulged disc and hypertrophic ligamentum flavum.

E-POSTER INDEX

689. Presacral L5-S1 Interbody Fusion (AxialIF) for Obese Patients: A Prospective Observational Study with Two-Year Clinical and Radiographic Results

George Malcolmson; Frederik Pennings, MD, PhD; John Weaver, MD
USA

Axialif is minimally invasive transsacral approach to stabilize the lumbosacral segment. Excellent clinical and radiographical results have been published in the general population suffering from back pain with or without radiculopathy. We present prospectively collected data using the Axialif method in (morbid) obese patients and demonstrate that this minimally invasive surgical technique provides a safe, fast and reliable access to the lumbosacral segment in (morbid) obese patients with good clinical and radiographical outcome.

Miscellaneous

690. Occipitocervical Fusion Surgery: Clinical Outcomes of a Single Institution Single Surgeon Experience

Mark A. Mahan, MD; Samuel Kalb, MD; Nikolay Martirosyan; Nicholas Theodore, MD, FACS
USA

We reviewed 70 patients who underwent OC fusion. An overall complication rate was 12.9%. Clinical outcomes according to the modified Japanese Orthopaedic Association scale (mJOA) scale improved from 14.19 (preoperative) to 16.5 (postoperative) with a recovery rate of 43%. Postoperative improvement was associated with the number of levels fused, where shorter constructs showed better outcomes compared to longer fusions. OC fusion is a safe and effective technique, though shorter fusion constructs appear to be better tolerated.

691. Comparative Analysis of Sagittal Spinopelvic Parameters between Young & Old Aged Groups

Youngbae B. Kim, MD, PhD; Yongjung J. Kim, MD; Young-Jun Ahn, MD; Seong-Rok Oh; Seo-Yeon Yoon, RN
Republic of Korea

Thoracic kyphosis and lumbar lordosis, especially lower lumbar lordosis were significantly increased in older male compared to younger ones with a similar sagittal vertical axis and sacral slope.

692. Patient Perceptions of Physician Reimbursement for Spine Surgery

Neil Badlani; Miguel A. Pelton, BS; Jared R. Foran, MD; Kern Singh, MD; Frank M. Phillips, MD; R. Todd Allen, MD, PhD
USA

Patients believe that orthopaedic surgeons who perform spine surgery should be compensated over ten times more than current Medicare reimbursement rates.

693. Ten Percent of Patients With AIS Have an Abnormal Number of Thoracic or Lumbar Vertebrae: A Red Flag for Wrong Site Surgery

David A. Ibrahim, BA; Karen S. Myung, MD, PhD; Lindsay Andras, MD; David L. Skaggs, MD
USA

In this study, an abnormal number of thoracic or lumbar vertebrae were found in 10% of patients with adolescent idiopathic scoliosis (AIS). To prevent wrong site surgery or choosing incorrect levels for spine fusion, we recommend that the surgeon count the number of thoracic and lumbar vertebrae as part of a preoperative routine. Lumbosacral transitional vertebrae are common and may affect the choice of lowest instrumented vertebra. The radiologist report usually missed the abnormally numbered vertebrae and cannot be relied upon.

694. Factors Associated with Use of Bone Morphogenetic Protein During Pediatric Spinal Fusion Surgery: An Analysis of 3,924 Patients

Amit Jain; Paul D. Sponseller, MD
USA

There has been an increasing trend toward off-label use of BMP during pediatric spinal fusion surgery. Rates of BMP use are as high as 8.1%, and are related to patient age, diagnosis, surgical approach, bone graft use, insurance status, hospital size, hospital teaching status and location. (Prognostic Level II).

The FDA has not cleared the drug and/or medical device for the use described in this presentation (i.e., the drug or medical device is being discussed for an 'off label' use).

695. Clinical Results and Functional Outcomes after Direct Intralaminar Screw Repair of Spondylolysis

Emmanuel N. Menga, MD; Khaled Kebaish, MD; Paul D. Sponseller, MD
USA

Nonsurgical management remains the mainstay of treatment for spondylolysis. Direct intralaminar screw fixation of spondylolysis for patients for whom nonoperative management fails offers a low profile fixation with successful clinical outcome and a low complication rate.

696. Symptomatic Degenerative Change of Adjacent Discs after Anterior Fusion of Cervical Spine: Minimal Ten Years Follow-Up

Jae Yoon Chung; Hyoung-Yeon Seo, MD; Sung-Kyu Kim; Whoan Jeang Kim
Republic of Korea

In long term outcome of anterior cervical discectomy and fusion, radiographic adjacent segment degeneration was common, but the rate of symptomatic degeneration or secondary surgery was very low.

697. Anterior Cervical Discectomy and Fusion vs. Cervical Disc Arthroplasty: Cost Analysis of Peri-Operative and Operating Room Related Costs

Tate M. Andres, BS; Daniel T. Warren, MD; Pedro A. Ricart Hoffiz, MD, MS; Christian Hoelscher, BS; Virginie Lafage, PhD; Jeffrey A. Goldstein, MD; John A. Bendo, MD
USA

While Anterior Cervical Discectomy and Fusion (ACDF) has long been the traditional treatment for cervical disc herniation and radiculopathy, Cervical Disc Arthroplasty (CDA) has been shown to result in similar clinical outcomes, with the possibility of lower revision rates and reduced adjacent segment degeneration. An itemized breakdown of hospital costs associated with the two procedures is discussed.

698. One of New Alarm Point in Intraoperative Spinal Cord Monitoring: Relationship between Waveform Changes and Reduction in MMT

Zenya Ito; Yukihiko Matsuyama, MD; Kinichi Shinomiya; Kazuhiko Satomi; Toshikazu Tani
Japan

A total of 7,158 cases of monitoring were compiled. The relationship between CMAP waveform changes and MMT reduction shows a low correlation, and an intraoperative amplitude drop to 25% or less of the control waveform amplitude suggests MMT reduction of 2 or more.

699. International Variations in the Clinical Presentation and Management of Cervical Spondylotic Myelopathy. One-Year Outcomes of the AOSpine Multicenter Prospective CSM-I Study

Michael Fehlings, MD, PhD, FRCS; Branko Kopjar; Shashank S. Kale, MCh Neurosurgery; Helton Defino, MD; Giuseppe Barbagallo; Ronald H. Bartels, MD, PhD; Qiang Zhou; Paul Arnold; Mehmet Zileli, MD; Gamaliel Tan, MBBS; Osmar Moraes; Yasutsugu Yukawa, MD; Manuel A. Alvarado, MD; Massimo Scerrati, Head of Neurosurgery, Ancona; Tomoaki Toyone, MD
Canada

International Variations in the Clinical Presentation and Management of Cervical Spondylotic Myelopathy. One Year Outcomes of the AOSpine Multicenter Prospective CSM-I Study.

700. Spinal Appearance Questionnaire (SAQ): Lack of Surgeon Agreement on Its Intent

Patrick J. Cahill, MD; Amer F. Samdani, MD; Lisa Merenda, RN, MSN; Kimberly M. Costello, RN; Anna Marie Santangelo, RNBSN; Randal R. Betz, MD; Mary Jane Mulcahey, PhD; Harms Study Group
USA

Cognitive testing of Spinal Appearance Questionnaire (SAQ) items among surgeons suggests that items are open to multiple interpretations. Item structure should be rewritten to achieve clarity and avoid misinterpretation.

701. Laminar Screw Fixation of the Axis in the Pediatric Population - A Series of Eight Patients

Bhishampal Singh; Andrew K. Cree, MD; Brian Hsu, MB BS, FRACS; Corinne Bridge, Nurse Practitioner
Australia

We report a series of eight paediatric patients (mean age 7 years) who underwent intralaminar screw fixation of the axis as part of their operative procedure. Seven patients had underlying dysplasia.

The FDA has not cleared the drug and/or medical device for the use described in this presentation (i.e., the drug or medical device is being discussed for an 'off label' use).

702. Osteoconductive Bone Graft Extenders In Posterolateral Thoracolumbar Spinal Fusion: A Systematic Review

Khalid Alsaleh, FRCS; Caroline Tougas; Darren M. Roffey; Eugene K. Wai, MD, MSc, CIP, FRCS
Saudi Arabia

Osteoconductive bone graft extenders (BGE) are widely utilized in spinal fusion surgery. High quality evidence supporting their use is lacking. A systematic review of studies comparing BGEs with the current gold standard of iliac crest bone graft (ICBG) was performed. The results show that osteoconductive BGEs -combined with local spine auto-graft and/or bone marrow aspirate- have comparable fusion rates, similar functional outcomes, lower complication rates and a lower risk of donor site pain compared to ICBG.

703. Cranial Traction for Prolonged Prone Positioning in Thoracolumbar Surgical Reconstruction

Eric Hooley
USA

Cranial traction for prolonged prone positioning is safe and effective.

704. Complications from Halo Use in Children

Maria Selva Vallejos Arce, MD; Carlos A. Tello, MD; Eduardo Galaretto, MD; Mariano A. Noel, MD; Ida Alejandra Francheri Wilson, MD; Romina Corrado, MD; Mariano O. Reynier, MD; Nicolas Coombes, MD; Gaston Eljure, MD; Ernesto Bersusky, MD
Argentina

Goals: To evaluate the complications resulting from the use of halo in children. Study design: Descriptive, retrospective, transversal and observational

705. Cross-linking Posterior Segmental Instrumentation in Adolescent Idiopathic Scoliosis Has No Demonstrable Clinical or Radiographic Effect

Arjun A. Dhawale, MD; Suken A. Shah, MD; Petya Yorgova, MS; Geraldine I. Neiss, PhD; Douglas Layer; Kenneth J. Rogers, PhD; Peter G. Gabos, MD; Laurens Holmes, PhD, DrPH
USA

Surgeons continue to debate the need for cross-links in posterior spinal instrumentation constructs in adolescent idiopathic scoliosis. A clinical comparative study of 75 patients treated with posterior segmental instrumentation (25 with cross-links and 50 without cross-links) showed no difference in radiological maintenance of curve correction and vertebral rotation and SRS outcomes over two year follow-up.

E-POSTER INDEX

706. Evaluation of Kyphosis Correction and Correction Loss by Anterior Spinal Fusion for the Patients of Tubercular Spondylitis

Shinjiro Kaneko; Masafumi Machida, MD; Masakazu Takemitsu; Kentaro Fukuda; Mitsuru Yagi, MD, PhD; Shingo Iizuka; Narihito Nagoshi; Atsushi Hasegawa; Masanobu Shiota
Japan

We evaluated kyphosis correction and correction loss by anterior spinal fusion (ASF) for the patients of tubercular spondylitis (TBS). Correction loss was more obvious in the cervico-thoracic junction level and upper thoracic level compared with other levels. However, any complaint from the patients related to the correction loss was not observed.

707. Role of Intraoperative Skeletal Traction in the Surgical Management of Severe Scoliosis (>80 degrees)

Sambhav Shah, MS; Arvind Kulkarni, MS, D-orth
India

Treatment of high magnitude curves is challenging due to the rigidity of the deformity. In this study we have used intra-operative skeletal traction with posterior only surgery in severe scoliosis.

708. Cervical Spinal Cord Compression (SCC) in Young Children with Type VI Mucopolysaccharidosis (MPS VI)

Luis Eduardo C. da Silva; Alderico G. Barros; Vinicius M. Rocha
Brazil

SCC is a known complication of MPS VI. We studied 6 children with MPS VI which 4 were diagnosed with SCC after the introduction of enzyme replacement therapy (ERT). We believe these patients may illustrate the previously undetected risk of increased joint mobility caused by ERT which may have contributed to increase cervical instability by loosening the joint, thus leading to or unmasking SCC.

709. Survival Analysis of Cervical Epidural Steroids in Degenerative Disc Disease

Alejandro Urzua, MD; Sergio Ramirez, MD; Alberto Telias, MD; Vicente Ballesteros, MD; Ratko Yurac, MD; Bartolome Marre, MD; Francisco Ilabaca, MD; Milan Munjin, MD; Juan J. Zamorano, MD; Jose Fleiderman, MD; Miguel Lecaros, MD
Chile

Retrospective cohort of 82 patients with cervicobrachial pain due to a cervical disc herniation diagnosed with MRI, treated with a cervical epidural steroid injection. Thirteen patients (15%) required surgery during follow-up (treatment failure). The accumulated surgery-free survival rate at the end of the follow-up, determined with the Kaplan-Meier method, was 82.8%. Most of the treated patients were satisfied with the procedure.

710. Generation of a Patient Specific Model of the Normal Sagittal Alignment of the Spine

Krishna Cidambi, MD; Josh Doan, MEng; Peter O. Newton, MD
USA

This study describes a 3D model of the normal adolescent spine that accurately predicts sagittal contour as a function of a patient's pelvic incidence and sagittal offset.

711. Pelvic Incidence in Patients with Hip Osteoarthritis

Ibrahim J. Raphael; Mohammad R. Rasouli, MD; Christopher K. Kepler, MD, MBA; Todd J. Albert, MD; Javad Parvizi, MD, FRCS; Kris Radcliff
USA

We assessed the relationship between pelvic incidence (PI) and the presence of hip osteoarthritis (HOA). Using pelvis CT scans, 2 independent physicians measured the PI angle in 100 patients with advanced HOA and compared them to the PI angles of 87 patients without HOA. The study was adequately powered. There was no difference in PI angles between the two groups. HOA is not associated with PI angle, refuting the hypothesis that elevated PI contributes to the future development of HOA.

712. Interbody Cages with Wide Contact Area in Lateral Interbody Fusion - Biomechanics, Clinical and Radiological Features

Luis Marchi, MSc; Leonardo Oliveira, BSc; Rodrigo A. Amaral; Carlos A. Castro; Thiago Coutinho; Etevaldo Coutinho; Luiz Pimenta, MD, PhD
Brazil

In this work we present a biomechanical study and preliminary clinical and radiological results.

713. Does MIS TLIF Surgery Cause Less Muscular Damage Than Standard Surgery? CK-MM Prospective Analytical Study

Cesar Hernandez-Garcia; Angel Escamez-Perez
Spain

The aim of this study is to analyze the muscular injury caused by lumbar posterior surgery and to compare the level of this damage between MIS surgery and open standard surgery.

715. The Pelvic Lordosis: An Essential Adaptation in Human Evolution, and a Determinant of Spinopelvic Alignment

Michiel Janssen, PhD; Tomaz Vrtovec, PhD; Franjo Pernuš; F. C. Öner, MD, PhD; Evie E. Vereecke; Anthony Channon; Max A. Viergever, DSc; Koen L. Vincken, PhD; Rene M. Castelein, MD, PhD
Netherlands

In the course of evolution, the human pelvis developed a lordotic curvature, which is a prerequisite for human upright bipedalism, and characteristic for the human upright spinopelvic alignment. In this study, a novel pelvic parameter is introduced which describes this pelvic lordosis, and measurements of this and other pelvic parameters were semi-automatically performed in a total of 348 normal subjects. A strong correlation was observed between the pelvic lordosis and pelvic incidence.

E-POSTER INDEX

716. Changes in Sagittal Spinopelvic Parameters According to Pelvic Incidence; Influence on Global Sagittal Balance and Orientation of Lumbar Lordosis

Youngbae B Kim, MD; Yongjung J. Kim, MD; Young-Jun Ahn, MD; Kyu-Bok Kang, MD; Seong-Rok Oh; Seo-Yeon Yoon, RN
 Republic of Korea

Subjects having larger PI demonstrated the larger lumbar lordosis with the most forward transition of trunk among asymptomatic volunteers. However they did not show the difference of thoracic kyphosis and T12 lower end plate - horizontal angle among three groups

717. The Effect of Cycling on Thoracic and Lumbar Spine Posture: An Introduction to the Back Posture Index (BPI)

Agbolahan A. Sofela, Bsc Hons; Alysha Shetye, BSc; Barbara W. Webb
 United Kingdom

The popularity of cycling, both as a sport and as a means of transportation has seen a dramatic increase in the United Kingdom over the past decade. Cycling is known to have positive effects on general body fitness and cardiovascular health, but the effects of cycling on the musculoskeletal system and joint structure & function are unknown.

718. Long-Term Narcotic Usage Following Spinal Surgery

Daniel L. Gaffney, MD; Michael D. Daubs, MD; Darrel S. Brodke, MD; Brandon Lawrence, MD; Alpesh A. Patel, MD; Thomas Higgins, MD
 USA

We evaluated 117 patients that underwent spine surgery to evaluate the number of patients that continued the use of narcotic medications postoperatively longer than 3 months. 44% of patients continued taking narcotics greater than 3 months following surgery. The chronic use of narcotics preoperatively predicted postoperative use.

719. Blood Salvage Produces Higher Total Blood Product Costs in Single-Level Lumbar Spinal Surgery

Chelsea E. Canan, MPH; Roger K. Owens, MD; Charles H. Crawford, MD; Mladen Djurasovic, MD; Lauren O. Burke, MPH; Kelly R. Bratcher, RN, CCRP; Kathryn J. McCarthy, MD; John Myers, PhD; Leah Y. Carreon, MD, MSc
 USA

Infusing autologous cell saver blood during surgery does not reduce the need for allogeneic blood transfusions in patients undergoing a single-level lumbar PSF. The total cost for blood is higher for surgeries that used cell saver compared to surgeries without cell saver. The high cost of cell saver in combination with the low complication rate of allogeneic blood transfusions suggest that cell saver is unnecessary for patients undergoing a single-level lumbar PSF.

720. Human Involvement Improves Yield of Electronic Data Capture of Health Related Quality of Life (HRQL) Surveys of Adult Spine Patients

Spencer G. Dauer, BA; Thomas D. Cha, MD, MBA; Kerrie Flynn, FNP; Joseph Schwab, MD, MS; Kirkham B. Wood, MD
 USA

Our study will determine the necessity of human input for electronic data capture of quality of life data measured through yield of completed HRQOL surveys for new patients.

721. Percutaneous Fluoroscopic Pedicle Screw Placement Technique in Thoracic and Lumbar Spine. A Clinical Safety Assessment using CT Scan

Mun Keong Kwan, MS (Orth); Lim Beng Saw, MS Orth; Chris Yin Wei Chan, MS Orth
 Malaysia

A radiological assessment using CT scan of 45 patients, undergone posterior stabilization surgery of the thoracolumbar spine using percutaneous fluoroscopic technique with a total of 304 screws were reviewed. There were no critical medial perforation (Grade 2 or 3) noted. The overall perforation rate was 12.2% (37/304) with the medial grade 1 perforation rate of 6.5% (20/304). In conclusion, the percutaneous fluoroscopic pedicle screw placement in thoracic and lumbar spine is safe.

723. Surgical Management of Thoracic Disc Herniation. Single Surgeon-Single Institute Experience

Omer Aslan; Meric Enercan; Sinan Kahraman; Alauddin Kochaj; Ibrahim Ornek; Mercan Sarier; Ahmet Alanay; Azmi Hamzaoglu, MD; Cagatay Ozturk, MD
 Turkey

This retrospective study compared ATDF with PDF for the treatment of thoracic disc herniation. Pts. treated by PDF had better JOA scores and less complications than pts.

724. Results of Vertebral Column Resection for Correction of Severe Spinal Deformity Performed in a Small Hospital Setting

Charles I. Jones, MD, MS; Richard E. McCarthy
 USA

Retrospective chart review for patients undergoing vertebral column resection (VCR) by a single surgeon in a small hospital (361 beds) setting.

725. A Comprehensive Nomenclature for Standardized Radiographic Measurements of Vertebral Morphology

Raymund Woo, MD; Laurel C. Blakemore, MD; Terry R. Trammell, MD; Jennifer Moore, MS; Burt Yazsazy, MD; Glen M. Ginsburg, MD; Francisco Javier Sánchez Pérez-Grueso; Shyam Kishan, MD; Oheneba Boachie-Adjei, MD; Behrooz A. Akbarnia, MD; Kevin Strauss, ME; Complex Spine Study Group
 USA

A new descriptive, easily abbreviated nomenclature system was developed to allow standardized radiographic measurements of vertebral morphology.

726. Fracture Dislocation of Lower Cervical Spine at Birth

Gaston Eljure, MD; Romina Corrado, MD; Carlos A. Tello, MD; Eduardo Galaretto, MD; Mariano A. Noel, MD; Maria Selva Vallejos Arce, MD; Nicolas Coombes, MD; Mariano O. Reynier, MD; Ida Alejandra Francheri Wilson, MD; Ernesto Bersusky, MD
 Argentina

the goal is to show three cases of severe cervical during labor

E-POSTER INDEX

727. Inter-Body Fusion for Pseudoarthrosis Repair in Ankylosing Spondylitis with TLIF Cage - Is Anterior Surgery Required?

Saumyajit Basu, MD; Jay D. Ghosh, MBBS, MS(Ortho); Farid H. Malik, MBBS, MS(Ortho); Agnivesh Tikoo, MS (Ortho); Sreeramalingam Rathinavelu, MS; Amitava Biswas, MS(Ortho)
India

This small case series tries to demonstrate that anterior surgery for Pseudoarthrosis repair is not necessary in treating Anderson lesion in Ankylosing Spondylitis. All 6 patients underwent posterior stabilization, unilateral facetectomy, posterolateral approach to the lesion which was cleared out. Local bone grafts were put followed by appropriate sized TLIF cage packed with local bone chips. All patients became pain free and radiologically all of them fused.

Natural History

728. Long-Term (Ten-Year) MRI Follow-Up of Paraspinal Muscle Quality After Posterior Fusion for Adolescent Idiopathic Scoliosis

Michael Faloon, MD; Daniel W. Green, MS, MD, FACS; Anthony Chang, MD; Roger F. Widmann, MD; John S. Blanco, MD; Matthew E. Cunningham, MD, PhD; Bernard A. Rawlins, MD; Oheneba Boachie-Adjei, MD
USA

Patients surgically corrected with open posterior muscle stripping fusions for AIS had very little fatty degeneration of lumbar para-spinal musculature seen on MRI at 10-yrs f/u. Both grade 4 Goutallier degenerative changes were unilateral and limited to the spinalis muscle which could be attributed to excessive rod length.

729. Is it Safe to Assess the Tri-Radiate Cartilage and Risser Sign off the Scoliosis vs. a Dedicated Pelvis X-Ray?

Senthilnathan Thirugnanasambandam, MD; Eric Wall, MD; Emily Eismann, MS; Viral Jain, MD; Peter Sturm, MD; Alvin H. Crawford, MD
USA

The triradiate cartilage and risser sign are used by spine surgeons to determine the treatment of scoliosis in children. In this study we compare the tri-radiate cartilage and risser sign on a scoliosis film vs. pelvis film taken at the same time. We found that a dedicated pelvis film is more reliable than the scoliosis film in assessing triradiate cartilage and risser sign.

730. Spinal Deformity in Russell-Silver Syndrome

Kent T. Yamaguchi, BA; Jennifer B. Salem, MA; Karen S. Myung, MD, PhD; Antonio N. Romero, MD; Lindsay Andras, MD; David L. Skaggs, MD
USA

This is the largest reported study of scoliosis and kyphosis in patients with Russell-Silver Syndrome (RSS) derived from responses from a national RSS survey. Of the 155 RSS respondents, we found a 25% prevalence of physician-diagnosed scoliosis and/or kyphosis in RSS patients, suggesting a significant prevalence of spinal deformity in this population.

731. Evaluation of Syndromic Spinal Deformities

Mehmet B. Balioglu, MD; Can H. Yildirim, MD
Turkey

Clinical and radiological examinations of syndromic patients were reviewed to assess related anomalies.

Neuromuscular Deformity

732. Are We Undermedicating Patients with Neuromuscular Scoliosis after Posterior Spinal Fusion?

M. W. Shrader, MD; Mandy Nowlin, PA-C; John S. Jones, MD; Gregory R. White, MD; Lee S. Segal, MD
USA

In this retrospective series of patients undergoing posterior spinal fusion, patients with adolescent idiopathic scoliosis received more than twice the amount of narcotics compared to a cohort of patients with neuromuscular scoliosis.

733. Health-Related Quality of Life and Low Back Pain of Patients Surgically Treated for Scoliosis with a Minimum 21-Year Follow-Up: Comparison Among Non-Idiopathic Scoliosis, Idiopathic Scoliosis, and Healthy Subjects

Tsutomu Akazawa, MD; Shohei Minami; Toshiaki Kotani; Kazuhisa Takahashi
Japan

We reported on HRQOL, low back pain, and marital status in healthy subjects, and non-idiopathic and idiopathic scoliosis patients 21 years or more after surgery. The non-idiopathic and idiopathic scoliosis patients had similar HRQOL and low back pain. The non-idiopathic scoliosis patients had a particularly low marriage rate at 39.6%.

734. Spinal Cord Monitoring in Neuromuscular Patients during Scoliosis Surgery

Tim Hammett, MRCS; Ben Boreham, MB BCH FRCS(Orth); Hossein Mehdian, MD, MS(Orth) FRCS(Ed)
United Kingdom

We present a review of 109 consecutive patients who underwent corrective surgery for neuromuscular scoliosis between 2005-2010, examining the use of intraoperative spinal cord monitoring (SCM). During this period, the use of SCM was of very limited use in reducing spinal cord injury.

735. Ventriculoperitoneal Shunt Failure Following Extradural Spinal Surgery in the Pediatric Spina Bifida Population*Michael Conklin, MD; Chevis N. Shannon, MBA, MPH, DrPH; Betsy D. Hopson; Jeffrey Blount, MD*
USA

Spinal deformity and shunted hydrocephalus frequently coexist in patients with spina bifida. We undertook a retrospective institutional review to determine if extradural spinal surgery such as deformity correction was predictive of shunt failure within the first post-operative year. We retrospectively reviewed 174 electronic medical records to identify 20 shunted spina bifida patients who underwent 33 extradural spinal procedures between the years 2001 and 2008. Four patients (20%) required shunt revision within one year. This did not reach statistical significance.

736. Effectiveness of Bracing in Patients with Scoliosis Secondary to Chiari Malformation after Posterior Fossa Decompression: A Comparison with Patients Treated by Observation Alone*Yong Qiu; Shifu Sha; Zezhang Zhu; Xu Sun; Tao Wu; Xin Zhen; Zhen Liu*
China

The current study investigated the efficacy of brace treatment in 26 patients with Chiari malformation-associated scoliosis (CMS) after posterior fossa decompression (PFD). Fourteen patients treated with observation alone were also evaluated as a comparison. By last follow-up, 18 patients (69.2%) were treated successfully with bracing. While for patients treated by observation, only 5 patients (35.7%) met the criteria for success. The success rate of the braced group was significantly higher than that of the non-braced group. For patients with CMS, bracing treatment is effective after PFD.

737. The Efficacy of Intraoperative Gardner-Wells Skull Tongs -Unilateral Femoral Traction in Correction of Pelvic Obliquity in Non-Ambulatory Cerebral Palsy Patients; A Retrospective Comparative Study*Zaid T. Al-Aubaidi, MD; David E. Lebel, MD, PhD; Andrew Howard, MD, MSc, FRCS; Benjamin Alman, MD; Reinhard D. Zeller, MD, FRCS; Unni G. Narayanan, MBBS, MSc, FRCS(C); Clifford Lin, MD MASc; Stephen J. Lewis*
Denmark

The use of intraoperative Halo-femoral traction is well described and well practiced. In patients with idiopathic scoliosis, to the best of our knowledge this is the first report describing the use of Gardner-Wells tongs and unilateral femoral traction intraoperatively. This study could not confirm that the use of intraoperative skull-femoral traction can end with better correction. However the use of intraoperative skull femoral traction as an adjunct in the treatment of patients with scoliosis and pelvic obliquity should be left to the discretion of the surgeon. In cases where traction is considered, our results support the use of a simplified technique using Gardner-Wells tongs.

738. Effectiveness of Universal Clamps on Controlling Both Coronal and Sagittal Profile in Patients Affected by Neurological Scoliosis: A Five-Year Follow-Up Study*Guido La Rosa, MD; Giancarlo Giglio, MD; Leonardo Oggiano, MD*
Italy

The aim of this retrospective study was to demonstrate the ability of Universal Clamps to control the sagittal profile in a consecutive series of patients affected by neurological scoliosis. The hybrid construct using Universal Clamps appears effective in neurological scoliosis treatment, providing a good correction of the deformity in both coronal and sagittal plane.

739. Sagittal Profiles in Patients with Thoracic Scoliosis Secondary to Chiari Malformation: A Comparison Between the Left and the Right Curves*Shifu Sha; Zezhang Zhu; Tao Wu; Zhen Liu; Yong Qiu*
China

The current study investigated the sagittal profiles in patients with thoracic scoliosis secondary to Chiari malformation. The TK and LL of patients with left curve were found to be larger than those of patients with right curve. Hyperkyphosis in patients with left thoracic curve might result in the increase of lumbar lordosis as a compensation.

740. The Survival of Intrathecal Baclofen Pumps in Neuromuscular Scoliosis Surgery*Tim Hammett, MRCS; Ben Boreham, MB BCh FRCS(Orth); Hossein Mehdian, MD, MS(Orth) FRCS(Ed)*
United Kingdom

Intrathecal Baclofen (ITB) therapy has been used to control spasm in cerebral palsy (CP) patients via an implanted reservoir, pump and catheter. Our retrospective review demonstrates that these systems are at high risk during corrective surgery for scoliosis, with an 80% failure rate following operation.

741. REACTS: A Simple Scoring System to Stratify Risks for Patients with Neuromuscular Scoliosis Undergoing Posterior Spinal Fusion*M. W. Shrader, MD; Mandy Nowlin, PA-C; Gregory R. White, MD; Lee S. Segal, MD*
USA

REACTS is a proposed grading system that assesses risk for postoperative complications for patients with severe neuromuscular scoliosis undergoing posterior spinal fusion. Early results demonstrate the scoring system is effective in predicting complications.

E-POSTER INDEX

742. Treatment Results of Severe Neuromuscular Scoliosis in Juvenile Age by Using Growing Rods

Martin Repko, PhD
Czech Republic

To postpone of the definitive surgery with spondylodesis and allowing of the growth are the main goals in treatment of severe juvenile neuromuscular scoliosis. Growing rods allow immediate three dimensional correction as well as they assure spinal growth. This study reports about results of surgical treatment of 11 patients by using growing rods. The average rate of immediate correction was 72%.

743. Surgical correction in Type 1 Neurofibromatosis with Scoliosis - Analysis of 18 Cases

Krishna Kumar Ramachandran Nair, MBBS, MNAMS, DO, DNB
India

NF1 patients can have dystrophic or non dystrophic scoliosis. This paper describes the analysis of 18 cases over past 10 years in a single centre

745. Factors Associated with a Loss of Correction in Spinal Cord Injury-Related Scoliosis Treated with Pedicle Screw Constructs

Steven W. Hwang, MD; Amer F. Samdani, MD; Joshua M. Pahys, MD; Andrew H. Jea, MD; Jeff S. Kimball; Alexander S. Rothkrug; Robert J. Ames, BA; Randal R. Betz, MD
USA

Our result suggest that greater post-op sagittal imbalance, longer constructs, and greater coronal Cobb correction may be associated with loss of correction over time in pediatric patients with spinal cord injury. Longer follow-up is required to better determine which patients may develop more objective evidence of pseudarthrosis.

746. Treatment of Spinal Deformity Associated with Myelomeningocele in Young Children with use of the Four-Rib Construct

AlaaEldin A. Ahmad, MD
Occupied Palestinian Territory

The bilateral percutaneous rib-to-pelvis 4 rib construct technique represents one new approach to the management of EOS in myelomeningocele as an alternative to growing rods, VEPTR or other techniques. This procedure is simple, minimally invasive, and does not exclude alternative treatment if there is failure of the technique. The incidence of adverse events associated with this technique compares favorably to other growing techniques.

747. Spinal Deformity and Pulmonary Dysfunction in Patients with Spina Bifida

Toru Hirano; Kei Watanabe, MD, PhD; Noriaki Kawakami, MD, DMSc; Yoshitaka Suzuki; Haruhisa Yanagida, MD; Takashi Namikawa, MD, PhD; Hiroshi Taneichi, MD; Toshiaki Kotani; Shohei Minami; Kota Watanabe; Morio Matsumoto, MD
Japan

Restrictive lung pattern was common in spina bifida patients with spinal deformity and severe pulmonary dysfunction may cause respiratory symptoms such as frequent pneumonia. However, single radiographic parameter regarding spinal deformity did not correlate with pulmonary function parameters except for space available for lung, which correlated well with actual FVC. Several other factors such as level of paralysis and level of daily activity may also contribute pulmonary dysfunction in spina bifida patients.

Spondylolisthesis

748. Spino-Pelvic Alignment following Surgical Correction of Developmental Spondylolisthesis: A Prospective Study

Jesse Shen; Hubert Labelle, MD; Jean-Marc Mac-Thiong, MD, PhD; Julie Joncas; Stefan Parent, MD, PhD
Canada

This study is a prospective analysis of spino-pelvic sagittal alignment of 35 patients following surgical correction for L5-S1 developmental spondylolisthesis in order to evaluate the effectiveness of surgical reduction as a method of treatment. Spinal and pelvic alignment were measured on standing lateral digitized x-rays. The results showed a significant increase for sacral slope and decrease for pelvic tilt along with improvements in SRS-30 and SF-12 health outcome scores. This study supports the contention that surgical reduction can be indicated.

749. Minimally Invasive Lateral Interbody Fusion (Mi-LIF) for Grade II Spondylolisthesis at L4-5: The "Worst Case" Scenario

William D. Smith, MD; William B. Rodgers, MD; Edward J. Gerber, PA-C; Jeff A. Lehmen, MD; Jody A. Rodgers, MD, FACS
USA

Because of concerns about neural complications with the lateral approach to the L4-5 level where significant anterolisthesis at this level exacerbates this risk, outcomes from a series of these "worst case scenario" patients treated with Mi-LIF are reported.

750. The Importance of L5 Incidence Measurement in High-Grade Spondylolisthesis

Rami El Rachkidi; Marion Burnier; Pierre Roussouly, MD
France

The correlation between the L5 incidence (L5I) and other traditional parameters was studied in 184 high-grade spondylolisthesis cases. The L5I and its components (the L5 tilt and the L5 superior slope) showed much better correlation with the pelvic retroversion, the slip percentage, the lumbar lordosis and the tilt of lumbar spine than any of the traditional parameters such the pelvic incidence, the sacral slope and the Dubousset angle.

751. Spontaneous Reduction of Low-Grade Spondylolisthesis by Positioning on the Operating Table: Does it Really Occur?

Mostafa H. El Dafrawy, MD; Philip Neubauer, MD; Hamid Hassanzadeh, MD; Amit Jain; Michael Alapat, MD; Khaled Kebaish, MD
USA

The role of slip reduction for low grade degenerative spondylolisthesis remains controversial. Various reduction techniques have been reported with some authors noting that low grade degenerative slips reduce spontaneously with surgical prone positioning. We compared the effect of prone positioning on change in radiographic parameter in 52 patients.

752. Low-Grade Degenerative Spondylolisthesis Treated by Stand-Alone Lateral Interbody Fusion

Luis Marchi, MSc; Leonardo Oliveira, BSc; Rodrigo A. Amaral; Carlos A. Castro; Thiago Coutinho; Etevaldo Coutinho; Luiz Pimenta, MD, PhD
Brazil

The purpose of this paper was to investigate the stand-alone lateral interbody fusion as a minimally invasive for the treatment of low-grade degenerative spondylolisthesis.

753. Analysis of Transpoas Lateral Lumbar Interbody Fusion (LLIF) for the Treatment of Adult Lumbar Degenerative Spondylolisthesis (DS): A Radiographic Review

Paul Stanton, DO; Edward K. Nomoto, MD; Nima Kabirian, MD; James D. Bruffey, MD; Gregory M. Mundis, MD; Behrooz A. Akbarnia, MD; Robert K. Eastlack, MD
USA

This retrospective review examined the radiographic 2-year durability of reduction and maintenance of adult lumbar degenerative spondylolisthesis (DS) using a transpoas approach for lateral lumbar interbody fusion (LLIF). Our study demonstrated durable improvement in anterolisthesis, but less favorable results for overall lumbar lordosis.

754. The Use of OP-1 (rhBMP-7) in Surgical Treatment of Pediatric Patients Affected by Symptomatic Grade I Isthmic Spondylolisthesis: A Seven-Years Follow-Up Study

Guido La Rosa, MD; Leonardo Oggiano, MD
Italy

Osteogenic protein-1 (rhBMP-7) is a member of the transforming growth factor-beta superfamily of extracellular proteins involved in bone growth and formation. This is the first report on use of OP-1 in paediatric spinal surgery. Fourteen patients affected by symptomatic grade I isthmic spondylolisthesis were treated by intertrasversary in situ fusion. spinal arthrodesis was achieved in 85% of paediatric patients by a short operative time, low bleeding and reduced postoperative pain, with a mild incidence of seroma at 3-month follow-up (21%).

755. High Grade Spondylolisthesis. Is Reduction Beneficial?

Laurent Bedes; Franck Accadbled, MD, PhD; Laurent Maubisson; Jerome Sales de Gauzy, PhD
France

14 high grade spondylolisthesis with partial surgical reduction vs. 18 without reduction were analysed using SRS 30 and Oswestry score. At a mean follow-up of 107 months, SRS 30 and Oswestry were significantly better in the reduction group suggesting that reduction can improve the final clinical result.

756. Operative Treatment of Spondylolysis and Low Grade Spondylolisthesis in Children and Young Adults: A Meta-Analysis of Observational Studies

Guy Klein, DO; Charles T. Mehlman, DO, MPH; Dietrich Schlenzka, MD, PhD
USA

In summary, operative treatment has shown a high rate of success when measured by clinical outcome. The use of pars repair in contrast to fusion does not appear to influence this outcome.

Trauma**757. Thoracolumbar and Lumbar Multifidus Innervation and Muscle Assessment Post Spinal Surgery**

Derek T. Cawley, MMedSc MCh MRCSI; Michael Alexander, MD; Seamus Morris, MD, FRCS
Ireland

This study evaluates innervation and cross-sectional area of the multifidus muscle in the thoraco-lumbar/lumbar spine post-surgery for vertebral fracture in 12 patients without spinal-cord injury. The first 6 consecutive minimally-invasive spinal surgery patients done in our institution and 6 random age-/sex- matched patients who previously had open spinal surgery. Innervation was severely affected in 3/6 post-open surgery vs. mild changes in four minimally-invasive cases. Mean cross-sectional muscle area was significantly greater at 2.35cm²/2.31cm² for minimally-invasive than 1.25cm²/1.12cm² for open surgery (p<0.05).

758. What is the Economical Impact of Performing Early Surgery in Adults with a Traumatic Spinal Cord Injury?

Jean-Marc Mac-Thiong, MD, PhD; Cynthia Thompson, PhD; Étienne Bourassa-Moreau, MD; Stefan Parent, MD, PhD
Canada

The optimal timing to perform a spine surgery in people who sustained a traumatic spinal cord injury is controversial. This retrospective study, which included 497 adults with a traumatic SCI, showed that patients operated within the first 24h post-injury had a shorter length of stay in the acute care hospital, which represented lower costs for the healthcare system.

E-POSTER INDEX

759. The Role of Magnetic Resonance Imaging in Acute Cervical Spine Fractures in the Elderly

Sina Pourtaheri, MD; Arash Emami, MD; Eiman Shafa, MD; Kumar Sinha; Michael Faloan, MD; Laurens Holmes, PhD, DrPH; Ki S. Hwang, MD
USA

There are no studies clearly defining the role of MRI in cervical spine fractures, except in cases with neurologic deficits. Controversy remains regarding the use of MRI in at risk patients, including the obtunded and elderly patients.

760. Conservative Treatment vs. Vertebroplasty in Osteoporotic Vertebral Fractures

Konstantinos Martikos, MD; Francesco Lalli; Alfredo Cioni; Stefano Giacomini; Francesco Vommaro; Mario Di Silvestre, MD; Tiziana Greggi
Italy

Vertebral fractures represent probably the most frequent type of low energy trauma in osteoporotic elderly population.

761. Spinal Instability Predicting Score (SIPS) for Subsequent Fractures after Vertebroplasty in Patients with Osteoporotic Vertebral Compression Fractures

Hyeun Sung Kim, MD, PhD; Se Jin Jeong, MD, PhD; Hyeong Jun Ahn; Ki Hyun Jeon; Woo Jin Choi; Kwan Tae Kim, MD, PhD; Chang Il Ju, MD, PhD; Seok Won Kim, MD, PhD; Seung Myung Lee, MD, PhD; Chang Il Ju, MD, PhD

Republic of Korea

The purpose of this study was to evaluate the spinal instability factors related to subsequent fractures after vertebral augmentation procedures. According to the SIPS, we can calculate predicting scores and can predict subsequent fractures. If the SIPS is high, the patients have a greater chance for subsequent fractures.

762. Civilian Gunshot Injuries to the Spine: An Update on Surgical Indications, Long-Term Outcomes, and Complications

David B. Bumpass, MD; Jacob M. Buchowski, MD, MS; Andrew Park, MD; Benjamin L. Gray, MD; Lukas P. Zebala, MD; Neill M. Wright, MD
USA

Of 159 civilian spinal gunshot wounds (GSWs), 149 were treated non-operatively and 10 merited surgical intervention. Neurologic improvement of at least one ASIA grade was seen in 25% of patients with cord injury. The morbidity from these injuries is significant, both in the short- and long-term.

763. Motor Segmental Recovery in Spinal Cord Injury - A Blessing in Disguise!

Rajeshwar N. Srivastava, MD; Saloni Raj
India

Our knowledge regarding neurological recovery following spinal cord injury is like a tip of an iceberg. Spinal cord does not regenerate once damaged but nerve roots do so if an optimum environment is provided. Although distal neurological recovery is unlikely in ASIA Impairment Scale A (complete lesions), root recovery at the site of injury can occur. ASIA has recognized Zone of partial preservation & Zonal segmental recovery below the neurological level. Such a recovery in motor functions (Motor segmental recovery-MSR) of lumbar roots in paraplegia may make all the difference in final outcome of ambulation & functional status of the patient.

764. Indirect Decompression using Posterior Longitudinal Ligament Ligamentotaxis in Thoracolumbar Burst Fractures: Is it Effective at High Grade in Load-Sharing Classification?

Woo-Kie Min, MD, PhD; Won-ju Jeong; Byoung-joo Lee
Republic of Korea

The efficiency of ligamentotaxis of PLL and short fusion in the load-sharing classification has not been proved yet. In our study, indirect decompression using PLL ligamentotaxis is useful technique at high grade group in the load-sharing classification.

765. Spinal Injuries in Professional American Football Players

Benjamin L. Gray, MD; Jacob M. Buchowski, MD, MS; David B. Bumpass, MD; Nathan A. Mall, MD; Matthew J. Matava, MD
USA

Spine injuries represented 7% of all injuries sustained by professional American football players. The cervical spine was most commonly affected. Muscle and nerve root injuries were the most common type of injury. Spinal cord injuries, while rare, caused the most lost time from play.

766. Fractures of the Atlas

Miguel Lecaras, MD; Vicente Ballesteros, MD; Celmira Martinez, MD; Juan J. Zamorano, MD; Francisco Ilabaca, MD; Bartolome Marre, MD; Ratko Yurac, MD; Alejandro Urzua, MD; Jose Fleiderman, MD; Milan Munjin, MD
Chile

Atlas fractures account for more than 25% of atlanto-axoid injuries. We report a retrospective cohort of 25 patients, managed with either a Miami type collar or a halo-vest. We observed that both time out of work and disability compensation are mainly influenced by the presence and magnitude of associated injuries.

767. Reliability of the CT Scout in Traumatic Head Injury in Predicting Significant Type II Odontoid Fractures

Matthew Kang, MD; Brian W. Hill, MD; Robert A. Morgan, MD
USA

This study describes the utility of using the scout image of the head CT as a valuable, cost-effective resource for detecting type II odontoid fractures.

768. A New Classification for Complex Lumbosacral Injuries

Ronald A. Lehman, MD; Daniel G. Kang, MD; Carlo Bellabarba, MD
USA

The optimal classification for complex lumbosacral injuries, in particular high-energy sacral fractures and lumbosacral dissociation injuries, remains controversial. We developed a new classification termed the Lumbo-Sacral Injury Classification System (LSICS) with a composite injury severity score to guide clinical decision making.

769. Combat Burst Fracture - A Military Specific Injury Mechanism

Brett A. Freedman, MD; Keith Jackson, MD; Brian Cameron; Chris J. Neal, MD
USA

The purpose of this study is to report a specific spine injury pattern seen in soldiers injured when up-armored military vehicles were attacked by IEDs.

770. Is a Formal Fusion Necessary During Instrumented Surgical Stabilization of Thoracolumbar Spine Fractures?

John R. Dimar, MD; Charles G. Fisher, MD, MHS, FRCSC; Marcel F. Dvorak, MD, FRCSC; Michael Fehlings, MD, PhD, FRCSC; Y. Raja Rampersaud, MD, FRCSC; David O. Okonkwo, MD, PhD; Alexander R. Vaccaro, MD, PhD
USA

Patients with thoracolumbar spine fractures, stratified into ASIA A and ASIA E, treated with instrumented stabilization alone were compared to those who had a concomitant formal fusion procedure. ASIA E patients who had instrumentation only without fusion tended to be younger males with lower ISS. These differences were not seen in ASIA A patients. In both ASIA subgroups, no significant differences in surgical parameters, clinical outcome measures, complications and instrumentation failures between the Fused and Non-fused cohorts were found.

771. Minimally Invasive Percutaneous Pedicle Screw Fixation for the Treatment of Flexion-Distraction Type Spine Fractures Without Neurologic Deficit in Morbidly Obese Patients

Armen R. Deukmedjian, MD; Juan S. Uribe, MD
USA

In this study, we describe 5 morbidly obese patients with very difficult to treat acute thoracolumbar Chance fractures and the increasing role of minimally invasive treatments in these cases, including multi segmental percutaneous pedicle screw fixation.

772. Can we Prevent Posttraumatic Kyphosis Effectively by Using Pedicle Fixation at the Level of the Fractured Vertebra Body with Short Fusion in Unstable Thoracolumbar Burst Fractures?

Woo-Kie Min, MD, PhD; Won-ju Jeong; In-hoo Ra
Republic of Korea

Posttraumatic kyphosis (PTK) is the thoracolumbar (TL) spine deformity affecting functional result. The bilateral pedicle fixation at the level of the fractured vertebra body is a useful method for preventing PTK in our study

773. Non-Fusion, Fracture Vertebral Augmented, Percutaneous Short Segment Transpedicular Screwing after Postural Reduction and Percutaneous Implant Removal in Neurologically Intact Unstable Thoracolumbar Burst Fractures

Hyeun Sung Kim, MD, PhD; Se Jin Jeong, MD, PhD; Hyeong Jun Ahn; Ki Hyun Jeon; Woo Jin Choi; Kwan Tae Kim, MD, PhD; Chang Il Ju, MD, PhD; Seok Won Kim, MD, PhD; Seung Myung Lee, MD, PhD; Chang Il Ju, MD, PhD
Republic of Korea

The aim of this study was to evaluate the non-fusion percutaneous screwing and implant removal for methods of preservation of motion segment and reducing the kyphotic deformity. Using the postural reduction and fracture vertebral augmentation, non-fusion percutaneous screwing was effective methods of kyphotic deformity correction for the unstable burst and preserving the motion segment.

774. Incidence of Pressure Injuries in Patients with Unstable Thoracolumbar Spine Fractures Transported from Afghanistan: Results of a Process Improvement Project

James M. Mok, MD; Keith Jackson, MD; Raymond Fang, MD; Brett A. Freedman, MD
USA

Current military operations in Afghanistan require prolonged immobilization of evacuees with spinal trauma. The purpose of this study is to examine the effects of immobilization with the vacuum spine board in service members injured in Afghanistan.

775. Anterior Spinal Reconstruction Surgery with Iliac Autograft for Osteoporotic Vertebral Collapse for Patients with Adjacent Old Vertebral Fractures

Shinjiro Kaneko; Masanobu Shioda; Masafumi Machida, MD; Masakazu Takemitsu; Kentaro Fukuda; Mitsuru Yagi, MD, PhD; Kanehiro Fujiyoshi; Shingo Iizuka; Narihito Nagoshi; Atsushi Hasegawa; Morio Matsumoto, MD
Japan

There have been a few reports regarding surgical outcomes of anterior spinal reconstruction surgery (ASRS) using iliac autograft for osteoporotic vertebral collapse (OVC). Our results from 42 cases indicated that ASRS is a favorable surgical procedure for OVC even in patients with adjacent old vertebral fracture(s).

E-POSTER INDEX

776. The Effect of Stabilization on Vertebral Augmentation Procedures after a First Event, Single Level Osteoporotic Vertebral Compression Fractures in the Early Old Aged Patients

Hyeun Sung Kim, MD, PhD; Se Jin Jeong, MD, PhD; Hyeon Jun Ahn; Ki Hyun Jeon; Woo Jin Choi; Kwan Tae Kim, MD, PhD; Chang Il Ju, MD, PhD; Seok Won Kim, MD, PhD; Seung Myung Lee, MD, PhD; Chang Il Ju, MD, PhD

Republic of Korea

Subsequent fractures after vertebral augmentation procedures often deteriorate the patient's lifestyle seriously. The purpose of the current study was to evaluate the significance of stabilization on augmentation procedures and to evaluate the effectiveness of vertebral augmented transpedicular screw stabilization (VATSS) for patients with osteoporotic vertebral compression fractures (VCFs). According to the results, we expect that the stabilization of unstable spinal segments may reduce subsequent fractures.

777. Reliability of the Subaxial Cervical Spine Injury Classification System for Orthopedic Surgeons at Different Training Levels

Daniel G. Kang, MD; Ronald A. Lehman, MD; Adam J. Bevevino, MD; Robert W. Tracey, MD; Donald N. Hope, MD; Alpesh A. Patel, MD; Scott Wagner

USA

The Subaxial Cervical Spine Injury Classification System (SLICS) demonstrated moderate to excellent reliability results between orthopedic physician at varying levels of training.

778. The Extreme Lateral Approach: A Minimally Invasive Alternative for Corpectomies

Alexander A. Theologis, MD; Abbey Kennedy; Robert T. McClellan, MD; Murat Pekmezci, MD

USA

To present outcome data of patients who have undergone corpectomy and cage placement via an extreme lateral approach for thoracic and lumbar vertebral body fractures at a Level I Trauma Center.

779. Incidence and Morbidity of Concomitant Spine Fractures in Combat Related Amputees

Ronald A. Lehman, MD; Adam J. Bevevino, MD; Daniel G. Kang, MD; Scott M. Tintle, MD; Theodora C. Dworak, BA; Benjamin K. Potter, MD

USA

This retrospective review of combat related amputees illustrates that spine fractures occur in 13% of amputees. However, the presence of a spine fracture does not appear to negatively affect functional outcome.

780. Posterior Percutaneous Instrumentation Plus Thoracoscopically-Assisted Interbody Fusion in Management of Incomplete Burst Fractures

Ahmed Shawky; Mohamed El-Meshtawy; Hasan Salheen; Heinrich Boehm

Germany

The best treatment of Post-traumatic kyphotic deformities is primary prevention through optimal management of spinal fractures. Thoracoscopically-assisted interbody fusion combined with percutaneous transpedicular stabilization as two minimal invasive techniques make primary intervention in cases of incomplete burst fracture a good tool of definitive treatment with minimal associated morbidities. Thirty patients with incomplete burst fractures or intervertebral disc injuries were operated using the above mentioned technique. Fusion rate at final follow up was 97%, While mean ODI was 6.

781. Interobserver Evaluation of TLICS Classification in the Thoracolumbar Fractures Treatment

Luis Eduardo C. da Silva; Luis Cláudio Schettino; Bernardo M. Chaves, MD; Antônio E. Araújo; Renato H. Tavares; André L. Barcellos; Ricardo P. Meirelles, MD; America Limoeiro; Vinícius M. Rocha; Luis Antonio M. Moliterno; Alderico G. Barros; Marcel Nascimento; Aline Depianti

Brazil

The author's intentions were to evaluate the interobserver agreement and compare the results (and indications) of this new classification to their own experiences (using authors' own favorite classification), assessing the importance of MRI for this new classification of thoracolumbar fractures as well as discussing its proposals, applications and critics.

782. Transoral Approach on the Treatment of Nonunion in Unstable Jefferson Fractures

Luis Eduardo C. da Silva; Alderico G. Barros; Vinícius M. Rocha; Renato H. Tavares; Luis Cláudio Schettino

Brazil

The transoral approach for unstable Jefferson fractures is a treatment capable of preserving the mobility of the atlantoaxial joint. We performed this approach in two patients with nonunion in isolated unstable Jefferson fractures, and the results were promising.

783. Evaluation of Clinical and Radiological Outcomes after Pedicle Screw Fixation of Unstable Thoracic Spine Fractures

Efe L. Aras; Shalu Sharma, MPT; Ebbe S. Hansen, MD, DMSc; Cody E. Bunker

Denmark

Early stabilization of unstable thoracic spine fractures plays an important role in the management of polytraumatized patients. Posterior surgical approach is fast and effective method for to correct and prevent further instability.

784. Traumatic Spondylolisthesis of the Lumbar Spine: A Case Series

Benjamin Mueller, MD, PhD; Jean-Marc Mac-Thiong, MD, PhD; Roger K. Owens, MD; John R. Dimar, MD
USA

Traumatic spondylolisthesis of the lumbar spine is a rare injury that occurs after high energy mechanisms. Diligent diagnostic workup is necessary, as the injury can be missed easily, especially in patients who are unable to cooperate in exam or undergo advanced imaging. We recommend the surgical treatment of all patients with this injury, as non-operative treatment is unlikely to be sufficient for this unstable injury.

Tumors**785. Complications and Consequences in Total Enbloc Spondylectomy for Malignant Spinal Tumors**

Morio Matsumoto, MD; Kota Watanabe; Naobumi Hosogane, MD; Akio Iwanami; Takashi Tsuji; Ken Ishii, MD, PhD; Masaya Nakamura; Yoshiaki Toyama
Japan

Complications associated with total enbloc spondylectomy for malignant spinal tumors were investigated. Of 30 patients, 14 (47%) developed complications during surgery in 2, early after surgery in 6 and late after surgery in 6. Complications included vascular injuries, deep infection, and instrumentation failures, most of which were successfully managed.

786. Outcome of Posterior Minimal Invasive Surgery in Advance Spinal Metastasis

Lim Beng Saw, MS (Orth); Chris Yin Wei Chan, MS (Orth); Mun Keong Kwan, MS (Orth)
Malaysia

Thirty cases of spinal metastasis; twenty three with pathological fracture and neurological deficit while seven with only pathological fracture treated with percutaneous pedicle screw fixation and decompression. On average 11 months follow up, all patients had at least one Frankel grade improvement in neurology and able to ambulate using wheel chair. No single case encountered complication such as wound infection or implant loosening.

787. Readmission Rate for Patients with Surgical Treatment of Primary and Metastatic Tumors of the Spine

William Schairer; Alexandra Carrer, MD; David Sing; Vedat Deviren, MD; Dean Chou, MD; Praveen V. Mummaneni, MD; Sigurd H. Berven, MD; Shane Burch, MD; Serena S. Hu, MD; Bobby Tay, MD; Christopher P. Ames, MD
USA

Resection of spinal tumors can improve quality of life for metastatic disease and facilitate cure of primary spine tumors. Rising costs are stimulating effort to maximize value of care provided. Unplanned hospital readmissions are costly. Baseline rates from high volume centers are necessary to help establish quality standards. This study investigates readmission rates and risk factors for readmission after spine surgery for neoplastic disease.

788. The Survival Analysis of the Breast Cancer Spinal Metastases in the Last Two Decades

Ming Sun, MD; Miao Wang, MD; Cody E. Bunger
Denmark

We conducted one retrospective study of 103 surgical treated patients with spinal metastases originated from breast cancer. All the patients were divided into two groups: group 1: operation before 2002; group 2 operation after 2001. The results showed that the mortality rates have no significant differences between the two groups.

790. Total Spondylectomy of C2 - Report of Three Cases


Jan Stulik; Jan Kryl; Zdenek Klezl, MD; Tomas Vyskocil; Michal Barna; Petr Nesnidal
Czech Republic

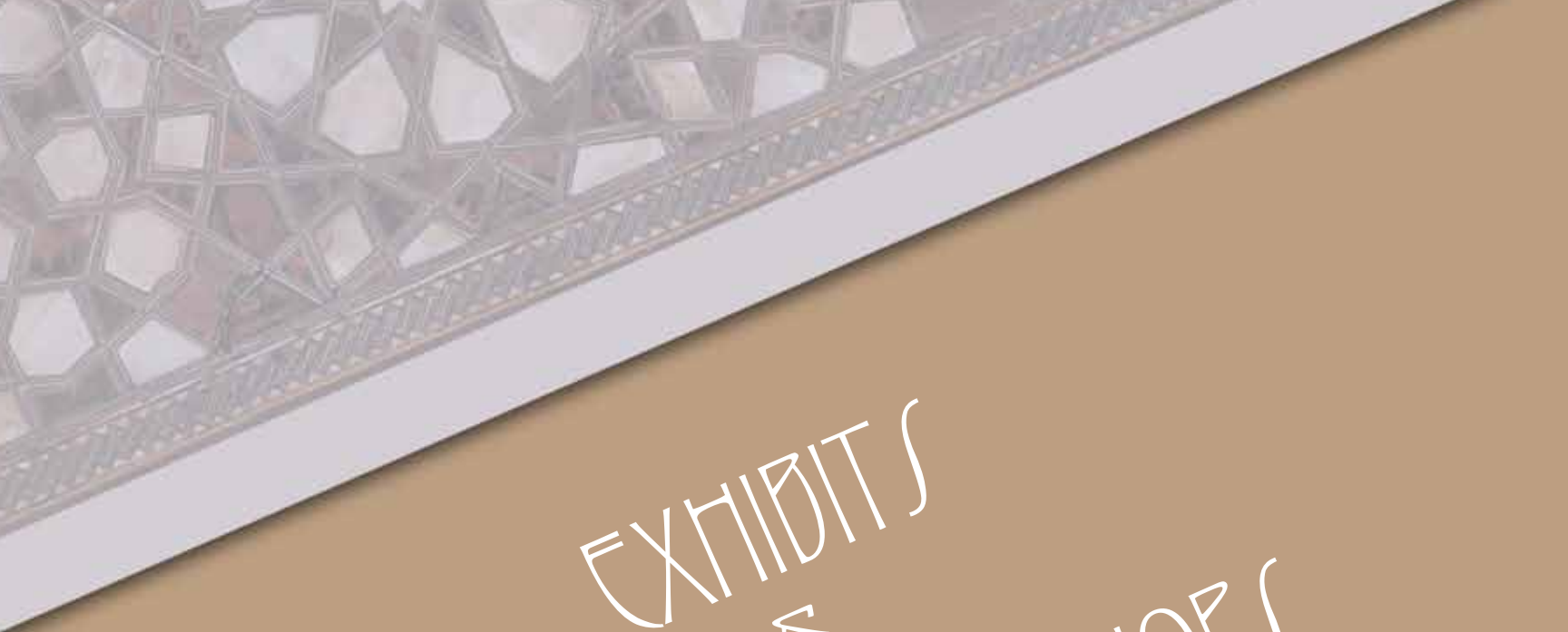A report on 3 patients undergoing total spondylectomy of the C2 vertebra for tumor and the technique for C1-3 reconstruction. Objective was to illustrate the feasibility of complete resection of the C2 vertebra with preservation of the vertebral arteries and cervical nerve roots.

791. Scoliosis Due to Osteoid Osteoma and Osteoblastoma: Surgical Treatment without Instrumentation


Mehmet B. Balioglu, MD; Temel Tacal, MD
Turkey

Three patients were diagnosed with scoliosis with pain due to Osteoid Osteoma (OO) (2 patients) and Osteoblastoma (OB) (1 patient). According to our study complete en-block resection of these lesion areas was a successful treatment.





EXHIBITS
&
HANDS-ON WORKSHOPS

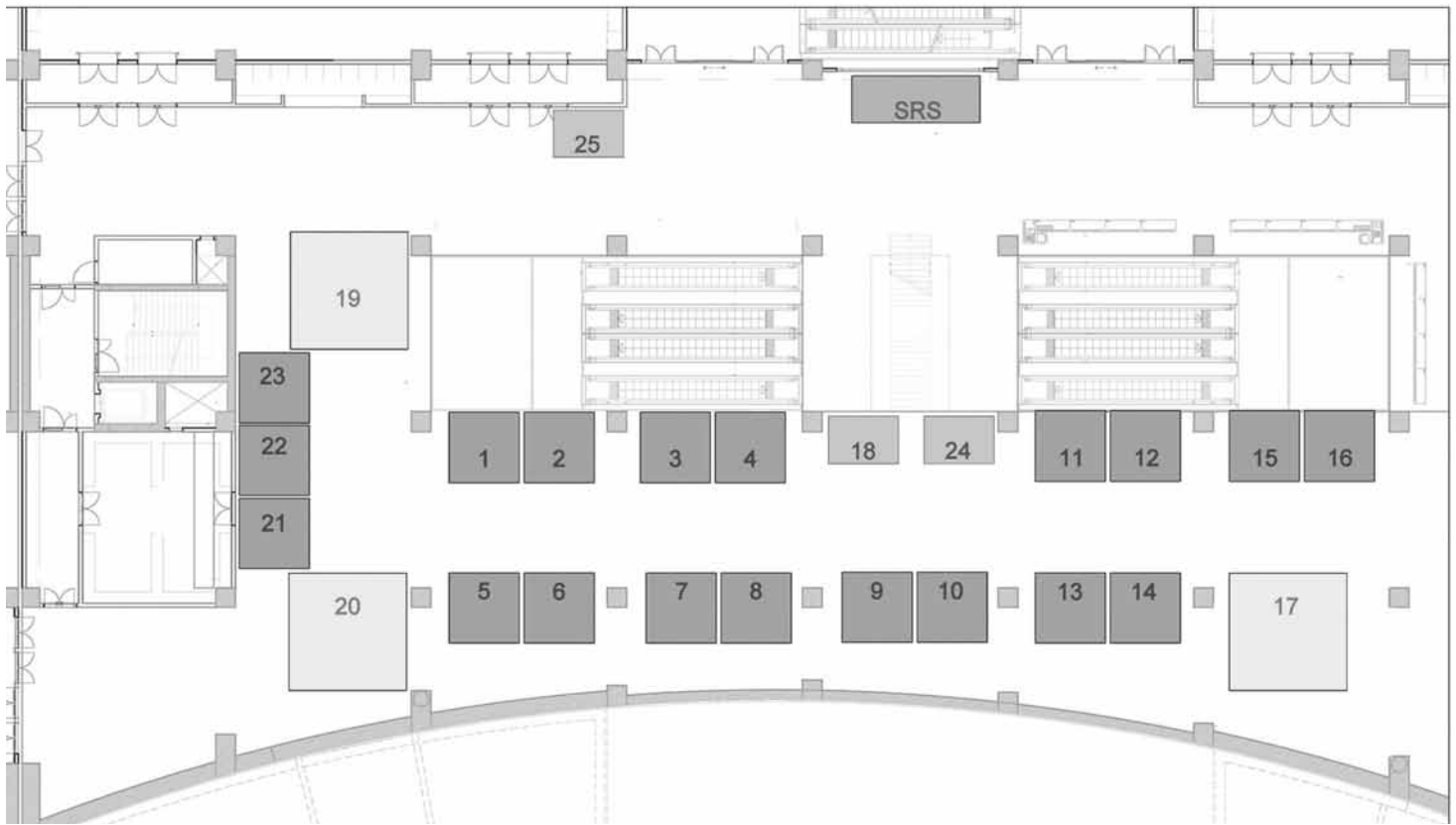


The Scoliosis Research Society gratefully acknowledges Synthes Spine for their support of the Welcome Reception and overall support of the 19th IMAST.



EXHIBITS

Exhibit Hall Floorplan



Company	Booth #
Beijing Fule Science & Technology Development Co., Ltd.	23
Biomet Spine	3
DePuy Spine	17
Ellipse Technologies, Inc.	10
Elsevier	25
EOS Imaging	8
Globus Medical	20
K2M	19
L&K Biomed	16
Lanx	7
Medtronic	5/6
Mixonix	14

Company	Booth #
NuTech	4
Nuvasive	11/12
Orthofix, Inc.	21/22
Paradigm Spine	1
Spineguard, Inc.	9
Stryker	18
Synthes GmbH	13
TranSI, Inc.	2
Zimmer Spine	24
Zyga Technologies	15

EXHIBITS

Beijing Fule Science & Technology Development Co., Ltd.

No. 50
Manfang West Industrial Zone
Pingqu District
Beijing 201204
CHINA
Tel: +86-1060999867
Fax: +86-1060999862131
www.fulekeji.com

Beijing Fule Science & Development Co., Ltd. is one of the greatest companies in China manufacturing orthopaedic products: Spine system, traumatology and another prosthesis lines besides chemical products. Our whole line of products has International Certificates - ISO and CE Marks. For 17 years, we have been selling our products to a lot of Chinese hospitals and we have started to sell overseas. And our relationship with our distributors is essential to promote and offer the best service in China and overseas. You will find the instruments which currently we are producing & offering to our valued customers. Also you will find the details of DHS, DCS, Mini Fragment, Small Fragment, Large Fragment instruments set. Additionally, we can manufacture your customized instruments models according to your specified sizes, which is currently not in our brochure.

Biomet Spine

100 Interpace Parkway
Parsippany, NJ 07054
USA
Tel: +1-973-299-9300
Fax: +1-973-299-0391
www.biometspine.com

Applying today's most advanced engineering and manufacturing technologies, we've developed our product line to offer surgeons a comprehensive approach for a wide variety of surgical applications for the spine. Our portfolio of products features breadth of line and depth of experience across all segments of spine applications including: Thoracolumbar, Deformity, Cervical, Interbody, Minimally Invasive Surgery & Bone Growth Technologies. Biomet Spine continues to build strong relationships with surgeons around the world and we invite you to visit our exhibit booth to learn more about our products while discovering how we can address individual surgeon concerns promptly, with an outstanding level of service.

DePuy Spine

325 Paramount Drive
Raynham, MA 02767
USA
Tel: +1-508-828-2820
Fax: +1-508-828-3027
www.depuyspine.com

DePuy Spine, the world's second largest spine company, has built a foundation by collaborating with clinicians to develop concepts and technologies to advance spine surgery. The company works with spine surgeons and other clinical experts to develop professional education offerings to meet the needs of healthcare professionals worldwide. The company is focused bringing forward procedural solutions that are built upon the latest technologies to treat deformity, degenerative and other pathologies and has been a leader in advancing minimally invasive surgery.

Ellipse Technologies, Inc.

13844 Alton Parkway #130
Irvine, CA 92618
USA
Tel: 1-949-837-3664 ext. 20
Fax: 1-949-837-3664
www.ellipse-tech.com

Ellipse Technologies, Inc., an innovative company focused on developing implantable technology to treat a broad spectrum of spinal and orthopedic applications, has developed a new remote control spinal distraction system called MAGEC™ (MAGnetic Expansion Control). Following a minimally invasive procedure to implant the MAGEC Rod, the implant can now be lengthened "non-invasively" in the office by using the MAGEC ERC (External Remote Controller), thereby eliminating the need for additional unnecessary surgeries.

Elsevier

360 Park Avenue South
New York, NY 10010-1710
USA
Tel: +1-212-989-5800
Fax: +1-212-633-3990
www.elsevier.com

EOS Imaging

10 Rue Nercœur
Paris 75011
FRANCE
Tel: +33-155-25-6060
Fax: +33-155-25-6061
www.eos_imaging.com

EXHIBITS

Globus Medical, Inc.

2560 General Armistead Avenue
Audubon, PA 19403
USA
Tel: 1-610-930-1800
Fax: 1-610-930-2042
www.globusmedical.com

Globus Medical, the world's largest privately held spinal company, is driving significant technological advancements across a complete suite of spinal products. Founded in 2003, Globus' single-minded focus on advancing spinal surgery has made it the fastest growing company in the history of orthopedics. There are three fundamental pillars that serve as the foundation for Globus Medical:

- **Delivering Innovation**
Globus has created a "Spine Innovation Engine" that yields better and more refined products so patients can resume their lives as soon as possible.
- **Exceptional Response**
Our willingness to actively listen and quickly respond with high quality solutions separates us from our industry peers. This exceptional response is at the core of our culture.
- **Advancing Patient Care**
Globus partners with and supports local and worldwide communities to advance spine care by working with educators, researchers, surgeons and volunteers to advance knowledge, understanding and delivery of spine care through education, research and outreach.

K2M, Inc.

751 Miller Drive, SE
Leesburg, VA 20175
USA
Tel : +1-866-K2M-4171 (866-526-4171)
Fax : +1-866-862-4144
www.K2M.com

K2M, Inc. is an innovative spinal device company committed to the research, development, and commercialization of simplified solutions for the treatment of complex spinal pathologies and procedures. The company is recognized as a worldwide leader in providing unique technologies for the treatment of deformity, degenerative, trauma, and tumor spinal patients. K2M's complete portfolio of next generation products includes: spinal stabilization systems, minimally invasive systems, and other advancing technologies such as motion preservation, annular repair, and nucleus replacement. K2M's dedication to the advancement of science in the area of complex spinal pathologies is represented by its development and support of the Complex Spine Study Group (CSSG), a research team of surgeon thought leaders dedicated to advancing patient care in the complex spine arena. For additional information on K2M, please visit www.K2M.com.

L&K Biomed

Room 1104
Ace High End Tower
371-50 Gasan-dong, Geumcheon-ga
Seoul 153-787
KOREA
Tel: +82-2-2624-1475
Fax: +82-2-2624-1477
www.lnkbiomed.com

L&K Biomed is a Korean developer and manufacturer, specialized in spinal fusion market. We are growing rapidly in spite of our short history. L&K now has a full product line up from lumbar to cervical. Our systems are designed very simple and easy to use. We are ready to be a leader to provide high-quality products in global medical device market with innovative technology. Product Line:

- Venus Thoracolumbar Fixation System
- Venus Lumbar Interbody Fusion System (PLIF, ALIF, TLIF)
- Focus MIS System
- Lexus Posterior Cervical Fixation System
- Lexus Anterior Cervical Plate System

Lanx, Inc.

310 Interlocken Parkway
Suite 120
Broomfield, CO 80021
USA
Tel: +1-303-443-7500
Fax: +1-303-501-8444
www.lanx.com

Surgeon-founded in Colorado, LANX[®] partners with leading orthopedic and neuro spine surgeons around the world to develop unique, cutting-edge spinal solutions designed to provide improved care through less invasive procedures. LANX offers a comprehensive, continually expanding portfolio of innovative, rapidly deployed solutions backed by state-of-the-art engineering and sound clinical evidence. LANX is one of the largest privately held global spine companies. More information on LANX and its spinal surgery products can be found at www.lanx.com.

EXHIBITS

Medtronic

2600 Sofamor Danek Drive
Memphis, TN 38132
USA
Tel: +1-901-396-3133
Fax: +1-901-399-2012
www.medtronic.com

At Medtronic, we're committed to innovating for life by pushing the boundaries of medical technology and changing the way the world treats chronic disease. Driven by our deep understanding of the human body and our collaboration with physicians, we're transforming technology to treat patients across the entire care continuum. Our innovations help physicians diagnose diseases earlier, treat patients with the least amount of disruption possible, and help alleviate symptoms throughout the patient's life. Today, we're improving the lives of millions of people worldwide each year across numerous conditions - including heart disease, diabetes, neurological disorders, spinal conditions, and vascular diseases. But it isn't enough. So we're innovating beyond products. We're breaking down barriers, challenging assumptions, and looking beyond the status quo - to continually find more ways to help people live better, longer.

Misonix

1938 New Highway
Farmingdale, NY 11735
www.misonix.com

Misonix, Inc. is a world leader in developing ultrasonic surgical devices for hard and soft tissue removal. The Misonix BoneScalpel™ is a novel ultrasonic osteotome for tissue-selective bone dissection that encourages en-bloc bone removal while sparing elastic soft tissue structures. Most users report that the surgical field is relatively bloodless and clean. Loss of viable bone is minimal and controllable. The BoneScalpel has been used extensively for bone removal in the cervical, thoracic and lumbar spine and including deformity surgery. Please visit us at IMAST 2012 at booth # 14 for more information.

NuTech

2641 Rocky Ridge Ln.
Birmingham, AL 35216
Tel: +1-209-290-2158

NuTech Spine offers a full line of spinal implants to address any spinal disorder as well as proprietary Spinous Allograft Implants, including the established NuFix I Facet Fusion Allograft Dowel and the soon-to-be-released NuFix II Facet Fusion Dowel and NuFix SPIF Spinous Process Allograft.

NuVasive

7475 Lusk Blvd
San Diego, CA 92121
USA
Tel: +1-858-909-1800
Fax: +1-858-909-2000
www.nuvasive.com

NuVasive® is a medical device company focused on developing minimally disruptive surgical products and procedures for the spine. NuVasive's principal product offering is based on its Maximum Access Surgery (MAS®) platform, which delivers the benefits of minimally invasive surgery while providing maximum surgical access. The company offers more than 65 products spanning lumbar, thoracic and cervical applications.

Orthofix, Inc.

3451 Plano Parkway
Lewisville, TX 75056
USA
Fax: +1-214-937-2730
www.orthofix.com

Orthofix is a diversified, global medical device company constantly striving to create effective, clinical pathways that satisfy the needs of the people we serve. Whether they are patients, surgeons, hospitals or employees, our goal is to provide comprehensive and innovative solutions that will evolve with the ever changing healthcare environment. We are FOCUSED on people, we are DRIVEN to deliver exceptional performance and RESPONSIVE to the needs of the lives we touch.

Paradigm Spine

Eisenbahnstrasse 84
Wurmlingen, 78573
GERMANY
Tel: +49-7461-963599-0
Fax: +49-7461-963599-20
www.paradigmspine.com

Paradigm Spine is a provider of non-fusion spinal implant solutions that serves to address the unmet clinical needs of spine surgeons and their patients. Starting with the coflex™ interlaminar implant technology Paradigm Spine develops a full non-fusion product portfolio of motion preserving tissue sparing technologies. The company presents the DCI™ implant for cervical dynamic stabilization, the DSS™ implant for lumbar dynamic stabilization, the coflex-F™ implant as a minimally invasive solution as an adjunct to fusion and the GSP™ system for early onset spinal deformities (TIS).

EXHIBITS

Spineguard, Inc.

301 Howard Street
Suite 970
San Francisco, CA 94105
Tel : +1-415-512-2506
Fax : +1-415-512-8004
www.spineguard.com

PediGuard is the world's first and only handheld device capable of alerting surgeons to potential pedicular or vertebral breaches. Real-time feedback is provided to surgeons via audio and visual signals, giving them new additional information. The PediGuard technology is available in 3 different tips; Classic PediGuard, Curved PediGuard and now the new Cannulated PediGuard. The primary objective of SpineGuard is to establish PediGuard® as the standard of care for safer pedicle screw placement to the benefit of patients, surgeons and health care providers. The company has offices in San Francisco and Paris. For further information, visit www.spineguard.com.

Stryker Spine

2 Pearl Court
Allendale, NJ 07401
USA
Tel: +1-866-987-7463
www.stryker.com

Stryker is one of the world's leading medical technology companies and is dedicated to helping healthcare professionals perform their jobs more efficiently while enhancing patient care. Stryker Spine invents, manufactures, and sells a full range of spinal implants for use in spinal surgeries worldwide. Stryker Spine began internationally in the mid 1990's and has rapidly become a major participant in the global spine instrumentation market. Operations are based in three locations; Bordeaux, France; Neuchatel, Switzerland and Allendale, NJ. Stryker Spine's ISO compliant manufacturing facilities in Switzerland and France produce implants for the global market while its headquarters in Allendale, NJ serves as the nexus for R&D and Marketing. At Stryker Spine, we are proud of our collaboration with spinal surgeons and other health care professionals throughout the world to help bring patients innovative solutions. www.stryker.com

Synthes GmbH

Eimattstrasse 3
Oberdorf 4436
SWITZERLAND
Tel: +41-6195-6111
Fax: +41-61965-6600
www.synthes.com

TranS1

301 Government Center Drive
Wilmington, NC 28403
USA
Tel: +1-910-332-1700
Fax: +1-910-332-1701
www.trans1.com

AxialIF Systems: TranS1® offers an innovative, pre-sacral approach to lumbar surgery. A mini-open access and fusion system enables lumbar arthrodesis to be performed with preservation of the annulus and all paraspinal soft tissue structures. AxialIF Legacy/AxialIF 2L+ technologies result in high fusion rates and low complication rates. Lateral System: The TranS1® VEO™ Lateral Access and Interbody Fusion System offers a two stage lateral retraction system. VEO is designed for direct visualization of the psoas muscle prior to accessing the disc space and implanting an interbody cage as well as clear radiographic lateral imaging of the spine

Zimmer Spine

23 Parvis des Chartrons
Bordeaux 33080
FRANCE
USA
Tel: +33-5600-1820
Fax: +33-556-001821
www.zimmerspine.eu

Zyga Technology, Inc.

700 10th Avenue South
Suite 20
Minneapolis, MN 55415
USA
Tel: +1-612-455-1061
Fax: +1-612-455-1064
www.zygatech.com

Zyga Technology®, Inc. markets the Slimmetry® Sacroiliac Join Fusion System™ which uniquely combines standard of care fusion principles and minimally invasive spine techniques to achieve a true arthrodesis of the SI joint. Slimmetry consists of two titanium cannulated implants designed to transfix the sacrum and the ilium and to create an environment for a bony fusion.

HANDS-ON WORKSHOPS

Wednesday, July 18, 2012 – Premium Workshops

15:00 – 17:00

Cocktails & snacks will be provided.

Rail 4D™ Technology for Sagittal Balance Restoration

Presented by: K2M
Room: Emirgan 1
Instructors: TBD

Breakthrough technology with a revolutionary “beam –like” design providing enhanced rigidity to aid in the restoration of sagittal balance, while maintaining a low-profile.

Put the Power in Your Deformity Case!

Presented by: Medtronic
Room: Emirgan 2
Instructors: Sigurd H. Berven, MD

Thursday, July 19, 2012 - Morning Hands-On Workshops

7:00 – 8:00am

Breakfast will be provided.

Expanding the Limits of MIS: Complex Correction Techniques with VIPER 3D and COUGAR LS

Presented by: DePuy Spine
Room: Hamidiye
Instructors: D. Greg Anderson, MD and Frank Philips, MD

This session is designed for surgeons experienced with MIS procedures who want to learn new MIS techniques and advance their expertise in this area. This session will include a discussion on techniques for deformity correction through percutaneous fixation and an overview of the lateral approach to interbody fusion with the DePuy Spine MIS Lateral Platform.

Surgical Techniques in Osteotomies

Presented by: Globus Medical
Room: Camlica
Instructors: Benny Dahl, MD and Sigurd H. Berven, MD

This hands-on workshop will feature case presentations and technique reviews for corrective osteotomies used in the treatment of complex spinal deformity. The course will also offer surgeons the opportunity to evaluate the Globus Medical Corrective Osteotomy Set and the unique features that ideally position the platform to treat complex cases.

Rail 4D™ Technology for Small Stature Patients

Presented by: K2M
Room: Emirgan 1
Instructors: TBD

Breakthrough technology with a revolutionary “beam –like” design providing enhanced rigidity to aid in the restoration of sagittal balance, while maintaining a low-profile for small stature patients

Advanced Posterior Cervical Facet Distraction and Fusion Techniques

Presented by: Medtronic
Room: Emirgan 2
Instructors: Vincent Traynelis, MD

Thursday, July 19, 2012 - Afternoon Hands-On Workshops

15:30 – 16:30

Cocktails and snacks will be provided.

Correction Techniques in Adult Deformity

Presented by: DePuy Spine
Room: Hamidiye
Instructors: TBD

This hands-on-workshop is designed for surgeons experienced with open deformity procedures who want to learn new techniques for instrumented deformity correction utilizing the Favored Angle Screw. The session will include a technique discussion with case examples as well as hands-on demonstration.

MIS Meets Complex Spine

Presented by: K2M
Room: Emirgan 1
Instructors: TBD

Rigid fixation to the spine platform for transpoas muscle splitting approach. Innovative design departure from the tubular retractors, provides tremendous adaptability to both patient anatomy and surgeon technique.

XLIF® for Anterior Column Realignment

Presented by: Nuvasive
Room: Camlica
Instructors: Behrooz A. Akbarnia, MD
Luiz H. Pimenta, MD, PhD
William Smith, MD
Juan Uribe, MD

HANDS-ON WORKSHOPS**VEO Lateral Access System: Seeing is Believing**

Presented by: Trans1
 Room: Emirgan 2
 Instructors: James Manzanaras, MD

See the possibilities in this hands-on, clinical overview presenting the clear and direct visualization offered by VEO in lateral fusion procedures. Through a combination of direct psoas visualization and unobstructed fluoroscopic views, VEO delivers an enlightened approach via a radiolucent, two-stage retractor system. Come see the possibilities.

Friday, July 20, 2012 - Morning Hands-On Workshops

7:00 – 8:00am
Breakfast will be provided.

Advanced Techniques in Treating AIS

Presented by: DePuy Spine
 Room: Hamidiye
 Instructors: Harry Shufflebarger, MD
 Peter O. Newton, MD
 Amer Samdani, MD

This workshop is designed for surgeons who want to learn about advanced techniques in treating AIS from an expert panel. This case based session will include an overview of the latest available technology and techniques for treating complex deformity in the adolescent population

Innovative Instrumentation Alternatives

Presented by: K2M
 Room: Emirgan 1
 Instructors: TBD

Learn new and revisit efficacious techniques to manage complex deformity reconstruction. You won't want to miss this workshop!

MIS Approaches for the Complex Spine

Presented by: Medtronic
 Room: Emirgan 2
 Instructors: Neel Anand, MD and Mark B. Dekutoski, MD

Posterior Approaches for Complex Spinal Deformity Correction

Presented by: Orthofix
 Room: Camlica
 Instructors: Rajiv Sethi, MD

This session will include a review of a modular pedicle screw system for addressing complex spinal deformity correction from a posterior approach. The session will include a review of clinical strategy and how to avoid complications.

Friday, July 20, 2012 - Afternoon Hands-On Workshops

15:00 – 16:00
Cocktails and snacks will be provided.

Introducing the Translation™ Screw Technology, A New Platform for Optimal Screw Placement

Presented by: Biomet Spine
 Room: Hamidiye
 Instructors: Christopher I. Shaffrey, MD

Biomet Spine will be introducing the Translation™ Screw Technology, which allows the screw head to translate medial/lateral relative to the screw shaft. This unique multi-axial screw platform is designed to encourage optimal screw placement, allowing for less rod manipulation, thus simplifying rod introduction and procedural efficiency.

Direct Vertebral Rotation: Single Rod or Dual Rod?

Presented by: K2M
 Room: Emirgan 1
 Instructors: TBD

Poised to address the most difficult correction maneuvers for complex spinal pathologies. Top-loading, low-profile spinal system featuring Zero-Torque Technology offering a variety of screw types coupled with revolutionary instrumentation.


Direct Vertebral Body Maneuver Techniques

Presented by: Stryker Spine
 Room: Camlica
 Instructors: TBD

The hands-on workshop will offer participants an opportunity to evaluate new corrective derotation techniques for the treatment of deformity. Participants will also assess the applications of deformity implants and how they impact the decision-making process. Featuring Xia®3, Suk™ DVR, Ilios and Revision systems.


AxiaLIFT: The Next Generation of Lumbosacral Fusion

Presented by: Trans1
 Room: Emirgan 2
 Instructors: Khaled Kebaish, MD





AUTHOR INDEX



The Scoliosis Research Society gratefully acknowledges the following companies
for their support of the Hands-On Workshops:

Biomet Spine
DePuy Spine
Globus Medical
K2M
Medtronic
Nuvasive
Orthofix, Inc.
Stryker Spine
Trans1

AUTHOR INDEX

Abdelhai, Ahmed Mohamed	468	Alvarado, Manuel	699
Abecassis, Josh	346	Amacker, Nadja	542
Abelin-Genevois, Kariman	213	Amaral, Rodrigo	70, 402, 404, 409, 410, 513, 555, 557, 559, 603, 712, 752
Abjornson, Celeste	443, 556, 687	Amaral, Terry	28, 34, 292, 306, 474, 481
Ablah, Elizabeth	654	Ambati, Divya	423, 446
Abouelrigal, Manal	512	Ames, Christopher	Comp3, Debate1, Debate4, 1, 5, 11, 50, 53, 54, 65, 66, 124, 125, 129, 330, 344, 352, 354, 367, 368, 371, 381, 388, 454, 523, 787
Abumi, Kuniyoshi	51	Ames, Robert	745
Acaroglu, Emre	2D, 4D, 49, 212, 332, 349, 417, 492, 586	Amin, Beejal	523, 623
Accadbled, Franck	213, 755	Aminian, Afshin	230, 231, 282, 316, 324
Acosta, Frank	489	Anand, Neel	4C, Debate1, 126, 127, 348, 355, 620
Adams, Brent	654	Ananthakrishnan, Dheera	628
Agabegi, Steven	527, 546	Andersen, Thomas	115
Agulnick, Marc	496	Anderson, D. Greg	3B, Debate4, 76, 421, 483
Ahmad, Alaa El-Din	108, 746	Anderson, Paul	7
Ahmadzadehfar, Hojjat	539	Andersson, Gunnar	653
Ahn, Dongki	470, 488	Ando, Kei	525
Ahn, Hyeong Jun	593, 761, 773, 776	Andras, Lindsay	646
Ahn, Nicholas	517, 551	Andres, Tate	71, 469, 484, 512, 697
Ahn, Young-Jun	691, 716	Angevine, Peter	378
Aiona, Michael	91	Annis, Prokopis	48, 64, 119, 339, 340, 363, 364
Aizawa, Mamoru	473	Antonacci, M. Darryl	406, 632
Akazawa, Tsutomu	45, 733	Anton-Rodrigalvarez, Luis Migu	90
Akbar, Michael	265	Aras, Efe	115, 783
Akbarnia, Behrooz	1D, 3D, 4C, 1, 4, 19, 26, 116, 377, 413, 427, 510, 562, 564, 569, 572, 579, 725, 753	Araujo, Antonio	529, 781
Akbasak, Aytac	68, 253	Aritan, Serdar	565
Akel, Ibrahim	24, 417, 586	Arkins, Thomas	493
Akhtar, Usman	131	Arlet, Vincent	353
Akriotis, Antonios	588	Arnold, Paul	699
Alamin, Todd	18	Arrigo, Robert	39
Alanay, Ahmet	1D, 24, 49, 69, 210, 221, 307, 315, 327, 332, 349, 390, 485, 492, 633, 723	Arun, Ranganathan	350, 374, 386
Alapatt, Michael	751	Asghar, Jahangir	27, 236, 255, 571, 606
Al-Aubaidi, Zaid	737	Aslan, Omer	723
Albert, Michael	110	Astur, Nelson	574
Albert, Todd	1B, 2B, 5B, 76, 421, 711	Atanda, Alfred	82
Albrecht, Heidrun	224, 263, 279	Atilla, Pergin	24
Alexander, Michael	757	Atmaca, Halil	217, 299
Alhashash, Mohamed	459	Aubert, Benjamin	277
Alkhatib, Bashar	288	Aubin, Carl-Eric	20, 96, 206, 226
Allen, R. Todd	692	Auffarth, Alexander	610
Allert, Jesse	490	Awwad, Waleed	416
Alman, Benjamin	737	Ayvaz, Mehmet	584
Alsaleh, Khalid	702		
Altaf, Farhaan	229, 249		
Altun, Necdet	532		

Presentation Number Key

IC, 2E, etc. = Instructional Course Lectures Debate# = Debates

Comp# = Complications Series 1-135 = Paper/Podium Presentations 200+ = E-Posters

AUTHOR INDEX

Bacaj, Ali	377	Bess, Shay	1, 5, 54, 65, 66, 124, 129, 344, 352, 371
Badlani, Neil	692	Betsch, Marcel	548
Bae, Hyun	685	Betz, Randal	19, 27, 205, 244, 255, 286, 290, 606, 619, 636, 641, 700, 745
Baghdadi, Yaser	480	Bevevino, Adam	415, 426, 428, 437, 777, 779
Baghel, Kavita	14, 87	Bevier, Patricia	271
Bago, Juan	44, 49, 332, 492	Bhalodia, Vidya	43, 493
Bains, Navpreet	39	Bharmal, Husain	426
Bakaloudis, Georgios	209, 248, 289	Bidre, Upendra	40, 204, 223, 311
Balasubramanian, Sriram	241	Bilekli, Burak	240, 318
Balioglu, Mehmet	68, 210, 253, 315, 501, 563, 731, 791	Bilgic, Serkan	240, 318
Ballesteros, Vicente	514, 515, 709, 766	Biscevic, Mirza	307
Banco, Robert	671	Biswas, Amitava	101, 478, 727
Barakat, Nadia	536	Biyani, Ashok	668
Barami, Kaveh	319, 528	Blakemore, Laurel	19, 413, 725
Baran, George	619	Blanco, John	728
Barbagallo, Giuseppe	699	Block, Jon	659
Barcellos, Andre	456, 529, 781	Blondel, Benjamin	3, 50, 66, 403
Barna, Michal	602, 790	Bloomgarden, Gary	493
Baron, Eli	126, 127, 348, 355, 620	Blount, Jeffrey	735
Barrios, Carlos	90	Boachie-Adjei, Oheneba	3C, 1, 5, 31, 285, 313, 329, 330, 341, 344, 362, 366, 376, 391, 615, 634, 725, 728
Barros, Alderico	708, 781, 782	Boatey, Jerome	471
Bartels, Lambertus	128	Boehm, Heinrich	459, 744, 780
Bartels, Ronald	678, 699	Boesch, R Paul	527
Barth, Martin	673, 678	Boey, Jia Jun Justin	81, 647
Bartley, Carrie	29, 95, 237, 466, 566	Bokums, Kristaps	675
Bastrom, Tracey	29, 205, 237, 244, 255, 256, 284, 286, 290, 466, 572	Borcek, Alp	532
Basu, Saumyajit	101, 478, 727	Boreham, Ben	112, 323, 350, 374, 386, 397, 734, 740
Batista, Nuno	310	Bornemann, Rahel	561
Beausejour, Marie	284	Bouchard, Sarah	23
Bederman, S. Samuel	407	Bouma, Gerrit	673, 678
Bedes, Laurent	755	Bourassa-Moreau, Etienne	56, 758
Beiner, John	43, 493	Bowen, J. Richard	121
Bekmez, Senol	24	Boyd, Lawrence	671
Bell, Jennifer	433	Boyd, Michael	41
Bellabarba, Carlo	768	Bradley, W. Daniel	659
Bellisle, May	599	Branch, Charles	631
Bendo, John	71, 697	Brandfellner, Heather	535
Benke, Michael	665	Bratcher, Kelly	77, 78, 719
Beppu, Moroe	554	Brayton, Alison	471
Beris, Alexander	677	Brearley, Ann	534, 545, 549
Berryman, Fiona	32	Brecevich, Antonio	687
Bersusky, Ernesto	106, 267, 704, 726	Brenner, Robert	687
Bertram, Wendy	296, 382	Brewer, Paul	32
Berven, Sigurd	1C, 2C, 3A, 5A, 53, 385, 523, 623, 787	Bridge, Corinne	701

Presentation Number Key

1C, 2E, etc. = Instructional Course Lectures Debate# = Debates
Comp# = Complications Series 1-135 = Paper/Podium Presentations 200+ = E-Posters

AUTHOR INDEX

- Bridwell, Keith 51, 131, 335, 361
Bright, Kristin 284
Briot, Jerome 213
Briseno, Michael 39
Brodke, Darrel 48, 64, 119, 339, 340, 363, 364, 444, 718
Brown, Christopher 502
Bruffey, James 510, 753
Buchowski, Jacob 2A, Comp4, 3, 130, 325, 335, 445, 552, 587, 609, 762, 765
Buckley, Jennifer 354
Buddenberg, Peter 398
Bumpass, David 117, 609, 762, 765
Bunger, Cody 61, 62, 115, 441, 783, 788
Burch, Shane 367, 787
Burger, Evalina 74, 431
Burgos Flores, Jesus 90
Burke, Lauren 77, 78, 655, 719
Burnier, Marion 750
Burton, Douglas 1, 5, 54, 125, 129, 371, 381
Burwell, Richard 588
Butz, Claire 406, 632
Byrd, J. Abbott 4C
Caceres, Enric 44
Cahill, Patrick 105, 201, 205, 286, 290, 606, 619, 636, 641, 700
Cain, Christopher 74, 558
Cameron, Brian 769
Cammissa, Frank 443, 506, 556, 675, 687
Campbell, Robert 241, 571
Canan, Chelsea 77, 78, 655, 719
Carragee, Eugene 18
Carreon, Leah 7, 35, 77, 78, 83, 342, 534, 545, 549, 652, 655, 680, 719
Carrer, Alexandra 67, 367, 388, 623, 787
Carrino, John 519
Castelein, Rene 128, 202, 715
Castro, Carlos 70, 402, 404, 409, 410, 513, 555, 557, 559, 603, 712, 752
Cauilan, Gilbert 628
Cawley, Derek 757
Cervellati, Stefano 582
Cetinus, Ercan 317
Cha, Thomas 37, 720
Chan, Chris Yin Wei 12, 434, 468, 721, 786
Chan, Ka Yan 233
Chandra, Abhijit 87
Chang, Anthony 728
Channon, Anthony 715
Chatterjee, Sandip 455
Chaves, Bernardo 529, 781
Chay, Edward 50, 512
Cheh, Gene 357, 387, 389, 395
Chen, Christopher 587
Chen, Zhongqiang 627, 637
Chen, Zi-Qiang 227, 254
Cheng, Ivan 18, 39
Cheng, Jack 233, 298, 414
Cheng, Jacky 216
Cherkassky, Daniel 461
Cheung, Jason Pui Yin 26
Cheung, Kenneth MC 4A, 26, 72, 97, 297
Cheung, Wai Yuen 26, 297
Chiba, Kazuhiro 57, 375, 473, 521
Ching, Alexander 380
Chiu, Chee Kidd 468
Cho, Samuel 422
Cho, Woojin 31, 329, 353, 361, 362, 506, 615, 634
Choi, Seung Myung 98
Choi, Woo Jin 593, 761, 773, 776
Chong, Hyon-Su 6, 281
Chou, Dean 367, 523, 623, 787
Christian, Ginger 661
Chu, Winnie 298
Chung, Chun Kee 543, 635
Chung, Ewy-Ryong 560
Chung, Jae-Yoon 63, 360, 696
Chung, Sungsoo 262, 494
Chung, Youngkey 271
Cidambi, Krishna 29, 95, 710
Cioni, Alfredo 578, 760
Clamp, Jonathan 323
Clark, Emma 296
Clement, Jean-Luc 258
Cloutier, Marc 23
Cluck, Michael 467
Cody, John 426
Coe, Jeffrey 3, 467
Coffman, Amanda 2
Cohen, Benjamin 496
Cohen, David 347, 356, 452
Colin, Vincent 407

Presentation Number Key

IC, 2E, etc. = Instructional Course Lectures Debate# = Debates

Comp# = Complications Series 1-135 = Paper/Podium Presentations 200+ = E-Posters

AUTHOR INDEX

Colo, Dino	202	Dean, Thomas	9
Conklin, Michael	618, 735	Dede, Ozgur	417, 586
Connolly, Patrick	93, 547, 676, 684	Defino, Helton	699
Constantinou, Barbara	277	Deinlein, Donald	3
Cook, Christina	624	Dekutoski, Mark	4C, 5C, Debate2, 58, 480
Coombes, Nicolas	267, 704, 726	Deluzio, Kevin	592
Cornwall, G. Bryan	377	Dema, Eugeni	582
Corrado, Romina	267, 704, 726	Demakakos, Jason	3, 50, 66
Costello, Kim	700	Demirkiran, Gokhan	24, 417, 565, 584, 586
Courvoisier, Aurelien	277, 293	Deml, Moritz	561
Coutinho, Etevaldo	70, 402, 404, 409, 410, 513, 555, 557, 559, 603, 604, 712, 752	Dempster, Georgina	382
Coutinho, Thiago	70, 402, 404, 409, 410, 513, 555, 557, 559, 603, 712, 752	Depianti, Aline	781
Covington, Lisa	522	Deukmedjian, Armen	38, 400, 507, 771
Crawford, Alvin	527, 534, 545, 549, 638, 639, 729	Devere, John	401
Crawford, Charles	77, 325, 719	Deviren, Vedat	11, 53, 54, 65, 124, 125, 129, 132, 352, 367, 368, 371, 381, 388, 523, 623, 787
Cree, Andrew	701	Devito, Dennis	230, 231, 282, 316, 324
Cronk-Bendett, Katharine	649, 663	Dewald, Christopher	3, 135
Cuddihy, Laury	406, 632	Dewberry, James	376
Cui, Geng	612	Dhawale, Arjun	266, 705
Cui, Quanyi	58	Di Silvestre, Mario	209, 248, 289, 578, 645, 666, 760
Cunningham, Matthew	31, 329, 341, 362, 443, 615, 728	Diamond, Beverly	103
Currier, Bradford	58	Diaz, Fernando	624
Da Silva, Luis Eduardo	529, 708, 781, 782	Dierdorf, Stephen	21
Dabirrahmani, Dane	601	Dietrich, Tobias	542
Dabney, Kirk	511	Digiammarino, Alicia	535
Daffner, Scott	46	Diorio, Timothy	483
Daglioglu, Kenan	565, 584	Dimar, John	3A, Comp1, 770, 784
Dahl, Benny	1A, 425	Dipaola, Christian	93, 547, 676, 684
Dai, Fei	109	Djurasovic, Mladen	77, 78, 83, 719
Dailey, Andrew	59	Dmitriev, Anton	415, 423, 428, 437, 446
Dakwar, Elias	377	Do, Patrick	91
Damato, Charles	27, 91, 574, 606	Doan, Josh	411, 710
Dannawi, Zaher	249	Dohring, Edward	659
Dastous, Jacques	20	Doi, Toshio	300
Dattilo, Jonathan	4	Domingo, Montse	49, 332, 349, 492
Daubs, Michael	48, 64, 119, 339, 340, 363, 364, 444, 718	Dong, Frank	654
Dauer, Spencer	720	Dorward, Ian	361
Davenport, Thomas	496	Doski, John	535
Dazley, Justin	496, 518	Doyle, John	618
De La Rocha, Adriana	33	Drevelle, Xavier	293
Dea, Nicolas	41	Driscoll, Mark	614
		Drummond, Denis	202
		Dubousset, Jean	277, 293
		Dubowy, Susan	511
		Duong, Jennifer	654

Presentation Number Key

1C, 2E, etc. = Instructional Course Lectures Debate# = Debates
Comp# = Complications Series 1-135 = Paper/Podium Presentations 200+ = E-Posters

AUTHOR INDEX

Duval, Sue	325	Felts, Lara	654
Dvorak, Marcel	41, 770	Feng, Jing	91
Dworak, Theodora	779	Ferguson, Virginia	431
Earhart, Jeffrey	461	Fernandez, Tito	79, 304
Eastlack, Robert	510, 753	Ferrara, Lisa	440
Eck, Jason	10, 93, 547, 676, 684	Ferraris, Luis	450, 629
Ege, Tolga	240	Fessler, Richard	487, 679
Egge, Natalie	547, 676, 684	Fischgrund, Jeffrey	669
Eggspuehler, Andreas	568	Fishchenko, Yakiv	664
Eismann, Emily	546, 639, 729	Fisher, Charles	41, 770
El Dafrawy, Mostafa	120, 344, 345, 347, 356, 368, 519, 751	Fleiderman, Jose	514, 515, 709, 766
El Miligui, Yasser	313	Fleischer, Gary	429, 440, 599
El Rachkidi, Rami	30, 750	Fleming, Neil	53
El Sebaie, Hazem	229, 249, 562	Flynn, John	19, 27, 287, 479, 497, 571, 574, 574
Elhadi, Ali	663	Flynn, Kerrie	720
Eljure, Gaston	267, 704, 726	FOCOS Organization	634
Ellwitz, Joshua	351, 365	Fogelson, Jeremy	16, 51, 131, 335, 451
Elmashat, David	495	Foley, Genevieve	20
El-Meshtawy, Mohamed Abdelhay	780	Foran, Jared	692
Emami, Arash	490, 759	France, John	46, 59
Emans, John	103, 226, 479, 569, 572	Francheri Wilson, Ida Alejandr	267, 704, 726
Emery, Sanford	46	Francheri, Alejandra	106
Endo, Hirooki	308	Franklin, Patricia	676, 684
Endo, Naoto	225, 274	Freedman, Brett	769, 774
Enercan, Meric	69, 210, 221, 315, 327, 390, 485, 492, 633, 723	Freeman, Andrew	440
Erickson, Mark	226, 497	Fu, Kai-Ming	353
Errico, Thomas	469, 484, 512	Fuhrhop, Sara	117, 579
Ersen, Omer	240, 318	Fujiyoshi, Kanehiro	775
Escamez-Perez, Angel	447, 713	Fukuda, Kentaro	257, 706, 775
Esmaeel, Ali	575	Funao, Haruki	473
Essig, David	31, 329, 362, 506	Gabos, Peter	82, 121, 266, 705
Eustacchio, Sandro	673	Gaffney, Daniel	718
Eyster, Edward	626	Gaines, Robert	50, 285, 366, 376, 391, 449, 476
Fajardo, Robert	535	Gala, Vishal	9, 625
Faloon, Michael	31, 329, 362, 615, 634, 728, 759	Galaretto, Eduardo	106, 267, 704, 726
Fan, Yung	10	Ganaisan, Premganesch	434
Fang, Raymond	774	Gardner, Adrian	32, 280
Farcy, Jean-Pierre	50, 66	Garg, Bhavuk	40, 204, 311
Farmer, Ryan	431	Garg, Hitesh	244, 636
Farnsworth, Christine	411	Garg, Sumeet	27
Farshad, Mazda	273, 542	Gaughan, John	536
Fazal, Akil	313	Gaume, Rachel	415, 428, 437
Fehlings, Michael	2B, 4B, 5B, Comp1, Comp4, 699, 770		
Fekete, Tamas	398, 568, 581		

Presentation Number Key

IC, 2E, etc. = Instructional Course Lectures Debate# = Debates

Comp# = Complications Series 1-135 = Paper/Podium Presentations 200+ = E-Posters

AUTHOR INDEX

Geck, Matthew	107, 250	Gungor, Irfan	532
Gelalis, Ioannis	677, 681	Guo, Chao Feng	576
Genc, Yasemin	212	Guo, Jing	215
Geoffray, Anne	258	Guo, Zhaoqing	637
Gerber, Christian	542	Gupta, Munish	5, 129, 344, 351, 365, 371, 381
Gerber, Edward	84, 86, 617, 682, 683, 749	Gupta, Purnendu	211
Ghosh, Jaydeep	101, 478, 727	Gupta, Sumit	270
Giacomini, Stefano	578, 760	Gussous, Yazeed	495
Giglio, Giancarlo	738	Guyer, Richard	553
Gilbert, Shawn	618		
Gil-Cano, Francisco	447	Ha, Yoon	132, 454
Gillies, Ronald	601	Haglund, Lisbet	288
Ginsburg, Glen	725	Hahn, Peter	407
Girardi, Federico	506, 675	Hai, Yong	302
Girardo, Massimo	582	Haku, Takamitsu	611
Glaser, Diana	411, 427	Halm, Henry	2C, 3A
Glassman, Steven	3A, 7, 35, 50, 78, 342, 652, 655, 680	Hammerberg, Kim	211
Glitzbecker, Michael	497, 574	Hammett, Tim	112, 323, 374, 397, 734, 740
Godinho, Francisco	456	Hamzaoglu, Azmi	4A, 49, 69, 210, 221, 307, 315, 327, 332, 349, 390, 485, 492, 633, 723
Goel, Vijay	449		
Gogineni, Hrishikesh	517, 551	Hanscom, David	500
Goh, Tae Sik	537, 550	Hansen, Ebbe	115, 783
Gokaslan, Ziya L	2A, 5C, Comp4	Happel, Joseph	428, 437
Goldstein, Jeffrey	71, 697	Hardenbrook, Mitchell	599
Golish, S.	18	Hardesty, Christina	475, 607
Goodrich, Isaac	493	Harding, Ian	5A, 296, 382
Gordon, Zachary	597	Harimaya, Katsumi	300
Gorelick, Judith	43, 493	Harmon, Elliot	34, 292
Gorenstein, Joel	406, 632	Harms, Jurgen	235, 272
Goswami, Ankur	40	Harris, Anna	112
Grady, Maureen	36	Harris, Gerald	211
Graf, Adam	211	Harrop, James	59
Grannum, Sean	280	Harshavardhana, Nanjundappa	229
Gray, Benjamin	762, 765	Hart, Robert	1, 5, 54, 65, 125, 129, 330, 352, 371, 380
Green, Daniel	728	Hartin, Nathan	482
Greggi, Tiziana	578, 645, 666, 760	Haschtmann, Daniel	568, 581
Gressot, Loyola	471	Hasegawa, Atsushi	706, 775
Grivas, Theodoros	588	Hasegawa, Kazuhiro	225, 274
Gross, Richard	108	Hasegawa, Tomohiko	369, 644
Grozman, Samuel	97	Hashimoto, Kurando	301
Gudipally, Manasa	425	Hashizume, Hiroshi	75, 99, 688
Guidera, Kenneth	531, 577	Hasley, Brian	391
Guler, Umit	212, 349	Hassani, Sahar	211
Gum, Jeffrey	652, 680	Hassanzadeh, Hamid	120, 345, 347, 356, 452, 519, 751
		Hawthorne, Dana	250
		Helenius, Ilkka	113

Presentation Number Key

1C, 2E, etc. = Instructional Course Lectures Debate# = Debates

Comp# = Complications Series 1-135 = Paper/Podium Presentations 200+ = E-Posters

AUTHOR INDEX

Helgeson, Melvin	415, 428, 437	Hwang, Ki Soo	490, 759
Heller, Joshua.	353	Hwang, Steven.	244, 471, 745
Henderson, Janet	575	Hyman, Joshua	309, 522
Hennessy, Michael	116		
Hernandez-Garcia, Cesar	447, 713	Ibrahim, David	693
Herrera-Soto, Jose	585	Ibrahim, Kamal.	Comp2
Hershman, Stuart	16, 51, 131, 335, 451	Iida, Takahiro	589
Herzog, Joshua	518	Ilabaca, Francisco	514, 515, 709, 766
Hess, W. Fred.	285, 366, 376, 391, 634	Ilharreborde, Brice.	259, 277
Hevia, Eduardo	90	Imagama, Shiro	25, 479, 525
Higgins, Thomas	718	Inami, Satoshi	508
Hilibrand, Alan	76, 421	Inoue, Takeshi	301
Hill, Brian	533, 767	Ishiguro, Naoki.	479, 525
Hipps, Sarah	9	Ishii, Ken	57, 375, 473, 521, 785
Hirabayashi, Hiroki	396	Ishikawa, Yoshimoto	80
Hirai, Masahiko	473	Ishimoto, Yuyu	75
Hirano, Kenichi	525	Iskander, Joseph.	459
Hirano, Toru	25, 225, 274, 479, 747	Ith, Agnes	18
Hiratzka, Jayme	64, 339, 363, 364	Ito, Keigo	88, 457
Hitzl, Wolfgang	224, 263, 279, 450, 610	Ito, Manabu.	25, 47, 51
Hoashi, Jane	205, 286, 574	Ito, Zenya	525, 698
Hoelscher, Christian.	71, 697	Iwai, Chizuo.	508
Hohl, Justin	64, 339, 363, 364	Iwamoto, Yukihide	300
Hollenbeck, Justin.	558	Iwanami, Akio	375, 521, 785
Holmes, Laurens.	82, 266, 511, 705, 759	Iwasaki, Hiroshi	75, 99, 688
Hooley, Eric	703	Iwasaki, Motoki	611
Hope, Donald.	777	Izuka, Shingo.	706, 775
Hopson, Betsy	735	Izumi, Tomohiro	225, 274
Horn, Jonathan.	28, 34, 292, 474, 481		
Hosogane, Naobumi	57, 222, 375, 521, 785	Jackson, Keith	769, 774
Hostin, Richard.	1, 5, 53, 54, 124, 125, 129, 344, 352, 368, 371	Jahng, Tae-Ahn	408, 464
Howard, Andrew.	737	Jain, Amit	42, 100, 347, 452, 694, 751
Hresko, Michael	103	Jain, Viral	527, 638, 639, 729
Hsu, Brian	601, 701	Jalanko, Tuomas.	113
Hsu, Wellington	461	Janowska, Magdalena.	435
Hsu, Wesley.	631	Jansen, Tom.	561
Hu, Serena	67, 367, 623, 787	Janssen, Michiel	128, 715
Hu, Xiaobang.	85, 462, 596	Jarzem, Peter.	73, 416
Huang, Russel	506	Jayaswal, Arvind.	40, 204, 223, 311
Huddleston, Paul	58	Jea, Andrew.	471, 745
Hughes, Alex	506, 675	Jenson, Robin.	21
Hui, Hua	8	Jeon, Ki Hyun.	593, 761, 773, 776
Hund, Robyn	548	Jeong, Se Jin	593, 761, 773, 776
Hussein, Namath	500		
Hussin, Paisal.	12		
Hutchison, Anthony	657		

Presentation Number Key

IC, 2E, etc. = Instructional Course Lectures Debate# = Debates

Comp# = Complications Series 1-135 = Paper/Podium Presentations 200+ = E-Posters

AUTHOR INDEX

Jeong, Won-Ju	764, 772	Kawai, Masaki	75, 99, 688
Jeszenszky, Dezsoe	398, 568, 581	Kawakami, Noriaki	25, 312, 479, 570, 747
Jiang, Jun	373	Kaya, Ibrahim	317
Joglekar, Siddharth	482	Kearns, Joe	599
Johnston, Charles	19, 20, 243, 419, 564, 567, 569	Kebaish, Khaled	54, 120, 124, 125, 129, 344, 345, 347, 352, 356, 368, 371, 436, 442, 452, 476, 519, 609, 695, 751
Jolivet, Erwan	403	Keefover-Hicks, Amy	322
Joncas, Julie	748	Kelly, Derek	574
Jones, Charles	724	Kelly, Michael	245, 331
Jones, John	208, 291, 303, 732	Kemp, Bastiaan	128
Jones, Patrick	426	Kennedy, Abbey	11, 778
Jones-Quaidoo, Sean	83	Kepler, Christopher	76, 421, 711
Joseph, Samuel	526	Kercher, James	628
Joshi, Ajeya	27, 535, 571	Keshavarzi, Sassan	132
Ju, Chang Il	593, 593, 761, 761, 773, 773, 776, 776	Kestner, Christopher	201
Jubenville, Trudi	322	Keynan, Ory	595
Jupitz, Jennifer	131	Khajavi, Kaveh	657
Kabir, Koroush	539	Khalil, Saif	425
Kabirian, Nima	427, 510, 569, 572, 753	Khan, Safdar	37
Kadhim, Muayad	102	Khandehroo, Babak	126, 127, 348, 355, 620
Kagotani, Ryohei	75, 99	Khoury, Joseph	618
Kahraman, Sinan	69, 210, 221, 315, 327, 390, 485, 633, 723	Khurjekar, Ketan	399
Kahwaty, Sheila	126, 127, 348, 355, 620	Kida, Yoshikuni	301
Kaiser, Bettina	581	Kiely, Paul	443
Kalb, Samuel	649, 663, 690	Kim, Chi Heon	543
Kale, Shashank	699	Kim, Do Yeon	6, 281
Kalluri, Prakasam	530	Kim, Hak-Sun	6, 281
Kanbara, Shunsuke	88, 457	Kim, Han Jo	16, 51, 131, 331, 335, 451, 587
Kandwal, Pankaj	40, 204, 223, 311	Kim, Hyeun Sung	593, 761, 773, 776
Kaneko, Shinjiro	57, 257, 375, 706, 775	Kim, Jeung Il	537, 550
Kanemura, Tokumi	80	Kim, Jin-Hyok	283, 314
Kang, Daniel	52, 118, 218, 336, 415, 426, 428, 437, 768, 777, 779	Kim, Jin-Soo	6, 283, 314
Kang, Kyu-Bok	716	Kim, Kwan Tae	593, 761, 773, 776
Kang, Kyung-Chung	262, 494	Kim, Kyle	9
Kang, Matthew	533, 767	Kim, Kyoungnam	357, 387, 389, 395
Karakoc, Zehra Cagla	485	Kim, Philsoo	262
Karami, Kristophe	624	Kim, Sang-Bum	281
Karatas, Ali	82	Kim, Seok Won	593, 761, 773, 776
Karlen, Judson	208, 291, 303, 504	Kim, Sung-Kyu	63, 696
Karlin, Lawrence	376	Kim, Sung-Soo	283, 314
Kato, Fumihiko	88, 457	Kim, Thomas	519
Kato, Nakayuki	508	Kim, Whoan Jeang	63, 360, 696
Kaul, Vikas	449	Kim, Yong Min	98
Kawaguchi, Kenichi	300	Kim, Yongjung	357, 387, 389, 395, 691, 716
		Kim, Youngbae	691, 716
		Kimball, Jeff	745

Presentation Number Key

1C, 2E, etc. = Instructional Course Lectures Debate# = Debates
Comp# = Complications Series 1-135 = Paper/Podium Presentations 200+ = E-Posters

AUTHOR INDEX

Kimura, Hiroaki	463	La Rosa, Guido	738, 754
King, Akilah	31, 341, 634	Labelle, Hubert	1A, 2D, 20, 103, 206, 268, 614, 748
King, Andrew	230, 231, 282, 316, 324	Lafage, Virginie	1, 3, 5, 50, 65, 66, 124, 125, 129, 230, 231, 282, 316, 324, 330, 344, 352, 368, 371, 403, 454
Kirby, Cassie	36	Lafleur, Matthew	558
Kishan, Shyam	21, 725	LaGrone, Michael	2
Klein, Guy	756	Lam, Tsz-Ping	233, 414
Kleinstueck, Frank	398, 568, 581	Lammli, John	654
Klezl, Zdenek	790	Lange, Jeffrey	93, 547, 676, 684
Klineberg, Eric	1, 5, 54, 124, 330, 344, 351, 352, 365	Lapinsky, Anthony	93, 547, 676, 684
Knapp, Dennis	285, 585	Larson, Annalise	103, 206, 226, 325, 480, 534, 545, 549, 577
Knott, Patrick	540, 548, 590	Larson-Ode, Katie	531
Kobayashi, Sho	369, 644	Latorre-Reviriego, Rafael	447
Kobayashi, Yoshiomi	473	Laufer-Molnar, Viviane	542
Kochai, Alauddin	69, 210, 221, 315, 327, 390, 485, 633, 723	Lawrence, Brandon	48, 64, 119, 339, 340, 363, 364, 444, 718
Koehler, Steven	422	Layer, Douglas	705
Koester, Linda	51, 122, 131, 245, 335, 361	Le Huec, Jean-Charles	1A, Debate2, 66
Koivusalo, Antti	113	Le Naveaux, Franck	206
Kojima, Atsushi	251, 343, 383, 554	Leasure, Jeremi	354
Koller, Heiko	224, 263, 279, 450, 610, 629	Lebel, David	737
Kondrashov, Dimitriy	354	Lebl, Darren	556
Kono, Hitoshi	57, 375	Lecaros, Miguel	514, 515, 709, 766
Konye, Geoffrey	654	Ledic, Darko	673, 678
Kopjar, Branko	699	Ledonio, Charles Gerald	103, 226, 243, 325, 534, 545, 549, 577
Koptan, Wael	313	Lee, Andrew	461, 506
Korhonen, Katariina	113	Lee, Byoung-Joo	764
Korovessis, Panagiotis	92, 613	Lee, Chong	9
Kosaka, Hirofumi	621	Lee, Chongsuh	262, 494
Kosemehmetoglu, Kemal	565, 584	Lee, Christopher	242, 646
Koski, Tyler	3C, Comp3, 346, 487, 489, 509, 679	Lee, Dong-Ho	331
Kotani, Toshiaki	45, 479, 733, 747	Lee, Ho Jin	516
Kothari, Alpesh	310	Lee, Jung Sub	537, 550
Koyasu, Shigeo	473	Lee, Kwong Man	233, 414
Kryl, Jan	602, 790	Lee, Mark	220, 294
Krzak, Joseph	211	Lee, Sang-Ho	560
Krzysztof, Koltowski	573	Lee, Seung Myung	593, 761, 773, 776
Kudyakov, Rustam	53	Lee, Soo Eun	408, 464, 635
Kuhns, Craig	107	Legakis, Julie	271
Kulkarni, Arvind	707	Leger St-Jean, Benjamin	538
Kulkarni, Preethi	306, 474	Lehman, Ronald	52, 118, 218, 336, 415, 423, 426, 428, 437, 446, 768, 777, 779
Kumar, Anant	370, 499	Lehmen, Jeffrey	84, 86, 617, 682, 683, 749
Kumar, Mayanka	370, 499	Lemma, Mesfin	452
Kuramoto, Tetsuya	473		
Kurd, Mark	483		
Kwan, Mun Keong	12, 434, 468, 721, 786		
Kwon, Brian	4B, Debate4, 41		

Presentation Number Key

1C, 2E, etc. = Instructional Course Lectures Debate# = Debates

Comp# = Complications Series 1-135 = Paper/Podium Presentations 200+ = E-Posters

AUTHOR INDEX

Lenke, Lawrence	2C, 4D, Comp2, 16, 35, 50, 51, 52, 118, 122, 131, 218, 226, 245, 331, 336, 361, 384, 415, 451	Machida, Masafumi	57, 257, 375, 706, 775
Letko, Lynn	235, 272	Machino, Masaaki	88, 457
Leung, Yee	297	Mac-Thiong, Jean-Marc	56, 268, 614, 748, 758, 784
Leveque, Jean-Christophe	9, 625	Maeno, Takafumi	611
Levy, Mark	595	Mahan, Mark	690
Lewis, Stephen	1A, 2A, Debate1, 737	Mahmood, Babur	229
Li, Fangcai	134	Mak, Kin	26
Li, Ming	227, 254, 372	Malcolm, James	440
Li, Qiyi	583	Malcolmson, George	686, 689
Li, Weishi	637	Malik, Farid	478, 727
Li, Zheng	412	Mall, Nathan	765
Lieberman, Isador	85, 462, 553, 596	Maltenfort, Mitchell	483
Lierl, Michelle	36	Manabe, Michihiko	591
Lim, Dong-Ju	283, 314	Mannion, Anne	398
Lim, Jaewoo	6, 281	Mansour, Shaun	564
Lim, Jong Min	537, 550	Mao, Saihu	216, 276
Limoeiro, America	781	Marchi, Luis	70, 402, 404, 409, 410, 502, 513, 555, 557, 559, 603, 604, 712, 752
Lin, Clifford	737	Marcucio, Ralph	417, 586
Lin, Xiaolong	215	Mardjetko, Steven	107, 495, 540, 548, 590
Lincoln, Todd	319, 528	Maredi, Elena	578
Lindley, Emily	74	Margiotta, Michael	512
Line, Breton	1, 125	Markova, Dessislava	421
Liu, Gabriel	264, 295, 379, 477	Marks, David	2D, 5D, 32, 280
Liu, Jiaming	498	Marks, Michelle	205, 244, 466, 505, 579
Liu, John	487, 679	Marre, Bartolome	514, 515, 709, 766
Liu, King Lok	233	Martikos, Konstantinos	578, 666, 760
Liu, Shaohua	111	Martinez, Celmira	766
Liu, Tie	302	Martirosyan, Nikolay	690
Liu, Zhen	215, 216, 276, 736, 739	Marumo, Keishi	301
Livingood, Matthew	665	Masato, Tanaka	47
Lo, Yungtai	34, 292, 306, 481	Mason, Jonathan	353
Loftus, William	43	Masuda, Christine	269
Lolli, Francesco	209, 248, 289, 578, 645, 666, 760	Matava, Matthew	765
Lonner, Baron	102, 105, 226, 244, 256, 284, 287, 313, 469, 484, 505, 634, 636, 641, 671	Matsumoto, Akiyuki	80
Lubicky, John	530	Matsumoto, Hiroko	309, 497, 522
Lucio, John	592	Matsumoto, Morio	25, 47, 57, 222, 375, 473, 521, 747, 775, 785
Luhmann, Scott	117	Matsumoto, Yoshihiro	300
Luk, Keith	26, 72, 97, 297	Matsuyama, Yukihiko	47, 369, 644, 698
Luo, Zhuojing	8	Maubisson, Laurent	755
Lv, Feng	215	Mayer, Michael	224, 263, 279, 450, 610
		Mazda, Keyvan	259
		Mazioti, Christina	588
		Mccalla, Daren	19
		McCarthy, Ian	53, 125, 129, 371
		McCarthy, Kathryn	35, 77, 719

Presentation Number Key

1C, 2E, etc. = Instructional Course Lectures Debate# = Debates
Comp# = Complications Series 1-135 = Paper/Podium Presentations 200+ = E-Posters

AUTHOR INDEX

McCarthy, Michael	432, 439	Moertel, Christopher	534, 545, 549
McCarthy, Richard	1D, 19, 234, 432, 439, 724	Mohamed, Feroze	536
McClellan, Robert	11, 778	Mohamed, Gouda	744
McClendon, Jamal	346, 489, 509, 679	Mohan, Vivek	351, 365
McClung, Anna	33, 269, 322, 567, 598	Mohd Hussein, Abdul Malik	468
McCormack, Bruce	626	Mok, James	774
McDonald, Erik	11	Moldavsky, Mark	425
McElroy, Mark	4, 579	Molitero, Luis	529, 781
McGillion, Stephen	310	Molloy, Sean	1C
McIntosh, Amy	480	Moon, Eun Su	281
McPhail, Gary	527	Moore, Anne	491
McQuinn, William	625	Moore, Jennifer	725
Mehbod, Amir	482, 681	Moraes, Osmar	699
Mehdian, Hossein	3, 112, 323, 350, 374, 386, 397, 734, 740	Moreau, Alain	96
Mehlman, Charles	36, 756	Morgan, Robert	767
Mehta, Jwalant	449	Morioka, Shigeta	251, 343, 383, 554
Meier, Oliver	224, 263, 279, 450, 629	Morita, Daigo	88, 457
Meirelles, Ricardo	456, 781	Morris, Seamus	757
Mekhail, Anis	495	Maskowitz, Alan	654
Meli, Marco	582	Moussallem, Charbel	58
Mendelow, Michael	634	Mouton, Tanguy	30
Menga, Emmanuel	356, 695	Muchow, Ryan	567
Meredith, Dennis	634	Mueller, Benjamin	655, 784
Merenda, Lisa	700	Muftuoglu, Sevda	24
Mesfin, Addisu	16, 51, 100, 131, 335, 451, 609	Mulcahey, Mary Jane	536, 700
Mesiwala, Ali	401	Mummaneni, Praveen	1B, 3B, 5C, 5, 7, 124, 330, 367, 523, 623, 787
Mhaidli, Hani	79, 285, 304, 366, 376, 391, 445, 476	Mundis, Gregory	1, 54, 116, 132, 330, 352, 377, 381, 454, 510, 572, 753
Michael, Weber	132	Munjin, Aleksandar	515
Micke, Theresa	540	Munjin, Milan	514, 515, 709, 766
Mielke, Cary	577	Murakami, Hideki	308
Mihas, Constantinos	588	Muramoto, Akio	525
Milchteim, Charles	665	Murray, Meghan	522
Miller, Freeman	511	Musaoglu, Resul	217, 299
Miller, Larry	659	Musto, Joseph	590
Min, Kan	273, 424, 542	Mutter, Urs	398
Min, Woo-Kie	331, 764, 772	Myers, John	719
Minami, Shohei	25, 45, 479, 733, 747	Myung, Karen	242, 564, 693, 730
Minamide, Akihito	75, 99, 688	Na, Lumine	623
Mindea, Stefan	39	Nagahama, Ken	51
Mishiro, Takuya	621	Nagai, Shigenori	473
Mitsunaga, Kyle	18	Nagata, Keiji	75
Miyajiri, Firoz	244, 270	Nagoshi, Narihito	706, 775
Miyasaka, Kazuyoshi	312		
Moal, Bertrand	66, 124, 330, 403		
Modhia, Urvij	367		
Modi, Hitesh	72		

Presentation Number Key

IC, 2E, etc. = Instructional Course Lectures Debate# = Debates

Comp# = Complications Series 1-135 = Paper/Podium Presentations 200+ = E-Posters

AUTHOR INDEX

Nakagawa, Yukihiro	75, 99, 688	Oguz, Erbil	240, 318
Nakamura, Masaya	57, 375, 521, 785	Oh, Seong-Rok	691, 716
Nakamura, Yutaka	331, 589, 589	Ohara, Tetsuya	312
Namikawa, Takashi	508, 747	Ohner, F. Chumhur	3B, Comp1, 715
Narayanan, Unni	737	Ohnmeiss, Donna	553
Nascimento, Marcel	781	Okada, Eijiro	222, 222
Nassr, Ahmad	58	Okada, Seiji	300
Nault, Marie-Lyne	268	Okada, Yasunori	473
Neal, Chris	769	Okamoto, Koji	591
Neal, Matthew	631	Okonkwo, David	770
Neckrysh, Sergey	393, 460, 495	Okuda, Shinya	611
Neglia, Joseph	531	Olgun, Z Deniz	586
Neiss, Geraldine	121, 266, 705	Olivar, Stephen	9
Nelson, Ian	296	Oliveira, Leonardo	70, 402, 404, 409, 410, 502, 513, 555, 557, 559, 603, 604, 712, 752
Nesnidal, Petr	602, 790	Olsen, Margaret	130
Neubauer, Philip	120, 347, 356, 751	Ono, Takashi	278, 570
Newton, Peter	5D, Comp2, Debate3, 23, 29, 95, 102, 105, 206, 237, 244, 255, 256, 270, 287, 411, 466, 505, 566, 579, 641, 710	Orndorff, Douglas	394, 486, 524, 659, 672
Ng, Bobby	233, 414	Ornek, Ibrahim	69, 390, 723
Nguyen, Tung	429, 440, 599	Oshaughnessy, Brian	346, 489, 509
Njoku, Dolores	42	Oshima, Yasushi	16, 122
Nnadi, Colin	310	Oskouian, Rod	500
Noel, Mariano	106, 267, 704, 726	Otten, Lucia	561
Nohara, Ayato	312	Ouellet, Jean	232, 288, 416, 575
Nohara, Yutaka	47, 508, 589	Owens, Roger	77, 83, 719, 784
Nojiri, Kenya	57	Oxborrow, Neil	630
Nomoto, Edward	116, 510, 753	Ozaki, Toshifumi	320
Noordeen, Hilali	1C, 3C, 4A, 229, 249, 562	Ozeki, Satoru	589
Norton, Robert	236	Ozturk, Cagatay	69, 210, 221, 307, 315, 327, 390, 485, 633, 723
Noshchenko, Andriy	74	Padua, Mary Ruth	6, 281
Novicoff, Wendy	353	Pahys, Joshua	27, 244, 290, 571, 606, 636, 641, 745
Nowlin, Mandy	732, 741	Paietta, Rachel	431
Nuckley, David	243	Paik, Haines	415
Nunez Pereira, Susana	44, 450	Pak, Sally	357, 387, 389, 395
Oberdorfer, Ewa	531	Pakarinen, Mikko	113
O' Brien, Joseph	665	Palmisani, Matteo	582
O' Brien, Michael	53, 54, 125, 129, 344, 352, 368, 371	Paonessa, Kenneth	634
Oda, Jon	266	Papadopoulos, Elias	634
Oda, Takenori	611	Papatheofanis, Frank	653
Odate, Seiichi	463	Paquette, Scott	41
Offoha, Roosevelt	120	Paradise, Scott	322
Oggiano, Leonardo	738, 754	Parashri, Umesh	94
Ogola, Gerald	53	Parent, Stefan	20, 23, 56, 268, 284, 538, 614, 748, 758
		Park, Andrew	762
		Park, Jin Oh	281

Presentation Number Key

1C, 2E, etc. = Instructional Course Lectures Debate# = Debates
Comp# = Complications Series 1-135 = Paper/Podium Presentations 200+ = E-Posters

AUTHOR INDEX

Park, Jong Ho	494	Pourtaheri, Sina	490, 511, 759
Park, June Young	516	Prasher, Anuj	367, 385
Park, Justin	342	Praud, Jean-Paul	23
Park, Kun Young	360	Presciutti, Steven	220
Park, Moon Soo	331, 587	Preziosi, Anna-Maria	538
Park, Sejun	262, 494	Price, Hannah	524
Park, Shi Hwan	537, 550	Protopsaltis, Themistocles	5
Parvizi, Javad	711	Pynsent, Paul	32
Patel, Akash	471	Pyrovolou, Nikolaos	310
Patel, Alpesh	444, 718, 777	Qi, Ding	219
Patel, Vikas	74, 431	Qi, Qiang	637
Patty, Catherine	394, 486, 524, 672	Qian, Bangping	114, 215, 216, 276, 373
Pavlos, Christodoulou	677	Qin, Ling	414
Pawar, Abhijit	675	Qiu, Guixing	239, 302, 438, 583
Pawelek, Jeff	116, 510, 569, 572, 579	Qiu, Yong	3D, 114, 215, 216, 219, 275, 276, 373, 414, 736, 739
Paxson, Robert	671	Quraishi, Nasir	323, 374
Pekmezci, Murat	11, 778	Ra, In	772
Pellise, Ferran	44, 49, 313, 332, 349, 492, 634	Radcliff, Kristen	76, 711
Pelton, Miguel	37, 650, 656, 660, 670, 692	Raghavan, G.	204, 223
Penn, Phedra	284	Rahm, Mark	285, 366, 376, 391, 436, 442, 476
Pennings, Frederik	686, 689	Raj, Saloni	14, 60, 87, 544, 763
Perepechay, Oleg	664	Ramachandran Nair, Krishna Kum	743
Perez-Orribo, Luis	649	Ramadan, Mohamed	313
Pernus, Franjo	715	Ramakrishnaiah, Raghu	439
Petcharaporn, Maty	95, 505	Ramirez, Norman	479
Peter, Noel	310	Ramirez, Sergio	514, 515, 709
Peterson, Brigette	540	Ramos, Paulo Jose	456
Pflugmacher, Robert	539, 561	Rampersaud, Raja	770
Phillips, Frank	1B, 334, 359, 650, 653, 670, 692	Rampy, Patricia	598
Phillips, Jonathan	453, 585	Rao, Milind	558
Pichelmann, Mark	58	Raphael, Ibrahim	711
Piedboeuf, Bruno	23	Rasouli, Mohammad	711
Pierce, Rosemary	91	Rathinavelu, Sreeramalingam	101, 478, 727
Pigrau, Carles	44	Rathjen, Karl	285
Pimenta, Luiz	70, 402, 404, 409, 410, 502, 513, 555, 557, 559, 603, 604, 712, 752	Ravi, Shashank	39
Piotr, Menartowicz	573	Rawlins, Bernard	329, 362, 615, 728
Ploumis, Avraam	338, 677, 681	Raya, Jose	403
Poe-Kochert, Connie	475, 597, 607	Redding, Greg	569
Polgreen, Lynda	531	Reddy, Silpa	241
Polly, David	Comp3, Debate2, 103, 206, 226, 243, 325, 531, 534, 545, 549, 577, 608	Reigrut, Julie	413, 436, 442, 445
Pong, Ryan	9	Rejec Smrke, Barbara	307
Popper, Orna	595		
Porchet, Francois	398		
Potter, Benjamin	779		

Presentation Number Key

IC, 2E, etc. = Instructional Course Lectures Debate# = Debates

Comp# = Complications Series 1-135 = Paper/Podium Presentations 200+ = E-Posters

AUTHOR INDEX

Remondino, Rodrigo	106	Rullkoetter, Paul	558
Repantis, Thomas	92, 613	Russell, Colin	579
Repko, Martin	742		
Resch, Herbert	610	Sabal, Luigi	628
Reynier, Mariano	267, 704, 726	Saigal, Rajiv	53
Reynolds, Richard	271	Saito, Masashi	57, 375
Rhim, Seung-Chul	357, 387, 389, 395	Saito, Toshiki	312
Ricart-Hoffiz, Pedro	71, 469, 484, 697	Sakellaropoulou, Samantha	588
Rice, James	46	Sakizlioglu, Secil	563
Richards, B. Stephens	Debate3, 35, 226	Salem, Jennifer	730
Richter, Kathleen	53	Sales De Gauzy, Jerome	213, 755
Riedel, Matthew	497, 522	Salheen, Hasan	744, 780
Riew, K.	Daniel	Salminen, Paivi	113
1B, 4B, 5B, 16, 587		Sama, Andrew	506, 675
Rihn, Jeffrey	76, 483	Samartzis, Dino	26, 72, 97, 297, 530
Rinella, Anthony	107, 250	Samdani, Amer	27, 105, 205, 244, 255, 270, 286, 290, 536, 571, 606, 619, 636, 641, 700, 745
Rintala, Risto	113	Samson, Nathalie	23
Riordan, Mary	211	Sanchez Perez-Grueso, Francisco	2D, 4D, 5D, 285, 366, 376, 391, 634, 725
Roberto, Rolando	351, 365	Sanders, James	20, 579
Rocha, Vinicius	708, 781, 782	Sanders, Peter	608
Rodgers, Jody	84, 86, 617, 682, 683, 749	Sanli, Tunay	210, 221, 315, 327
Rodgers, William	84, 86, 359, 592, 617, 682, 683, 749	Sano, Atsuki	225, 274
Rodriguez-Pardo, Dolores	44	Santangelo, Anna Marie	700
Roffey, Darren	702	Santos, Edward Rainier	325, 577, 608
Rogers, Jason	234	Sapir, Elad	595
Rogers, Kenneth	82, 705	Saran, Neil	232, 575
Romero, Antonio	730	Sardar, Zeeshan	73
Romero-Ortega, Mario	433	Sarier, Mercan	69, 315, 723
Rose, Peter	58	Sarlak, Ahmet	217, 299
Rosenstein, Benjamin	243	Sarwahi, Vishal	28, 34, 292, 306, 474, 481
Ross, David	89	Sasaki, Aya	473
Ross, Thomas	285, 329, 366, 376, 391, 615	Sasao, Yutaka	251, 343, 383, 554
Rossel, Felipe	232	Sassi, Davide	538
Rothenfluh, Dominique	424	Satake, Kotaro	80
Rothenfluh, Esin	424	Satomi, Kazuhiko	698
Rothkrug, Alexander	745	Saw, Lim Beng	12, 97, 434, 468, 721, 786
Roughley, Peter	288	Sawyer, Aenor	623
Roussouly, Pierre	30, 750	Sawyer, Jeffrey	574
Rovillos, Allison	406, 632	Scerrati, Massimo	699
Roy-Beaudry, Marjolaine	268, 284, 538	Schairer, William	67, 367, 388, 623, 787
Roye, Benjamin	309, 522	Scharf Stern, Carrie	284
Roye, David	309, 497, 522	Scheer, Justin	54, 65, 352
Ruf, Michael	235, 272	Schettino, Luiz Claudio	781, 782
Ruiz, John Nathaniel	133, 295, 477	Schlenzka, Dietrich	756
		Schmidt, John	413, 436, 442, 445

Presentation Number Key

1C, 2E, etc. = Instructional Course Lectures Debate# = Debates
Comp# = Complications Series 1-135 = Paper/Podium Presentations 200+ = E-Posters

AUTHOR INDEX

Schramm, Martin	258	Shimamura, Tadashi	308
Schwab, Frank	1C, 2C, 3C, 1, 3, 5, 50, 54, 65, 66, 124, 125, 129, 330, 344, 352, 368, 371, 403, 454	Shimaya, Takemi	247, 261
Schwab, Joseph	720	Shimer, Adam	353
Schwartz, Daniel	43, 493	Shin, Dong-Eun	6, 418
Schwartz, Jeffrey	406, 632	Shinohara, Akira	301
Schwend, Richard	413	Shinohara, Kei	301
Scott, Morgan	394, 486, 524, 672	Shinomiya, Kinichi	698
Scuderi, Gaetano	18	Shioda, Masanobu	57, 375, 706, 775
Sdzuy, Christoph	273	Shrader, M.	208, 291, 303, 504, 732, 741
Sedra, Fady	229	Shufflebarger, Harry	27, 102, 105, 236, 244, 255, 287, 313
Segal, Lee	208, 291, 303, 504, 732, 741	Sides, Brenda	16, 52, 118, 245, 331, 336, 361, 451
Sehirlioglu, Ali	240, 318	Siemionow, Krzysztof	393, 460, 495
Seifert, Jennifer	433	Silva, Fernando	384
Seki, Shoji	95, 566	Silvestre, Clement	30
Selby, Michael	270	Simmons, James	535
Sembrano, Jonathan	325, 577, 608	Sinclair, Sarina	444
Senkoylu, Alpaslan	532	Singh, Bhishampal	701
Seo, Hyoung-Yeon	63, 696	Singh, Devender	250
Serhan, Hassan	449	Singh, Kern	37, 650, 656, 660, 670, 692
Sestokas, Anthony	43, 493	Sinha, Kumar	490, 759
Sethi, Rajiv	9, 625	Sirikci, Murat	69
Sha, Norihide	591	Skaggs, David	242, 564, 646, 693, 730
Sha, Shifu	736, 739	Skalli, Wafa	259, 277, 293, 403
Shafa, Eiman	759	Skolasky, Richard	345, 452
Shaffrey, Christopher	2B, 3B, 5C, Comp3, 1, 3, 5, 50, 54, 65, 66, 124, 125, 129, 330, 344, 352, 353, 371, 454	Slimack, Nicholas	487, 679
Shah, Dina	512	Slivka, Michael	10, 614
Shah, Sambhav	379, 707	Slosar, Paul	653
Shah, Suken	3D, 4, 82, 102, 105, 121, 226, 244, 256, 266, 284, 287, 505, 511, 569, 705	Smith, Donald	38, 377, 507
Shan, Le-Qun	242	Smith, John	19, 27
Shannon, Chevis	735	Smith, Justin	2B, 4A, 5A, 1, 5, 50, 54, 65, 66, 124, 125, 129, 325, 330, 352, 368, 371, 454
Sharma, Lalit	264	Smith, Micah	18
Sharma, Shalu	115, 783	Smith, Timothy	346, 487, 489, 509, 679
Shaughnessy, William	480	Smith, William	502, 648, 661, 674
Shawky, Ahmed	780	Smith-Wright, Deborah	531
Shen, Alessandria	657	Smrke, Dragica	307
Shen, Francis	353, 530, 609	Smuck, Matthew	18
Shen, Jesse	748	Snyder, Brian	4, 19
Shen, Jianxiong	239, 302, 412, 498, 583	Snyder, Laura	649, 663
Shetye, Alysha	717	Soeda, Tsunemitsu	463
Shi, Lin	298	Sofela, Agbolahan	717
Shigematsu, Hideki	297	Sokunbi, Gbolabo	31, 329, 362, 615
Shih, Patrick	487	Solano, Rafaela	236
Shikata, Jitsuhikko	463		

Presentation Number Key

1C, 2E, etc. = Instructional Course Lectures Debate# = Debates

Comp# = Complications Series 1-135 = Paper/Podium Presentations 200+ = E-Posters

AUTHOR INDEX

Solomito, Matthew	294	Suzuiki, Yoshitaka	747
Song, Bowei	533	Suzuki, Nobumasa	47
Song, Kai	104, 642, 643	Swider, Pascal	213
Son-Hing, Jochen	475, 597, 607		
Soshi, Shigeru	301	Tacal, Temel	501, 563, 791
Sparagana, Steven	598	Taher, Fadi	443, 556, 675
Sparks, Jason	553	Takahashi, Jun	458
Spilsbury, Jonathan	32, 280	Takahashi, Kazuhisa	733
Sponseller, Paul	Comp2, Debate3, 4, 19, 42, 100, 102, 105, 120, 564, 579, 694, 695	Takemitsu, Masakazu	706, 775
Srivastava, Rajeshwar	14, 60, 87, 94, 544, 763	Takemoto, Richelle	469, 484
St. Amour, Edgar	234	Takemoto, Steven	523, 623
St. Hilaire, Tricia	27, 571	Takeshita, Katsushi	25, 278, 570
Stad, Shawn	614	Takeshita, Yujiro	278
Stallbaumer, Jeremy	52, 118, 336	Takeuchi, Daisaku	508
Standefor, Karen	89	Takigawa, Tomoyuki	320, 321
Stans, Anthony	480	Tan, Eric	120
Stanton, Paul	510, 753	Tan, Gamaliel	699
Stasic, Andrew	21	Tanaka, Masato	320, 321
Stein, Benjamin	452	Taneichi, Hiroshi	25, 47, 508, 747
Stein, Shlomit	673	Tang, Jessica	65, 354
Steinman, Meredith	28, 306	Tang, Mingxing	111, 594, 600
Stenning, Matthew	296	Tani, Toshikazu	698
Stevenson, David	534, 545, 549	Tao, Hui ren	8
Stoker, Geoffrey	552, 587	Tasdemiroglu, Erol	68, 253
Strauss, Kevin	427, 725	Tauchi, Ryoji	479, 525
Street, John	41, 93	Tavares, Renato	781, 782
Stulik, Jan	602, 790	Taylor, Lee	91
Sturm, Peter	19, 211, 255, 527, 546, 638, 639, 729	Telias, Alberto	514, 515, 709
Subhash, M.	223	Tello, Carlos	106, 267, 704, 726
Sucato, Daniel	4D, 17, 33, 35, 89, 103, 218, 226, 269, 322, 419, 420, 430, 433, 534, 545, 549, 598	Teraguchi, Masatoshi	99
Sugimoto, Yoshihisa	320, 321	Terran, Jamie	330, 368, 381
Sugrue, Patrick	346, 489, 509, 679	Tetsunaga, Tomoko	320, 321
Suk, Se-Il	283, 314	Thambiah, Joseph	133
Sullivan, Michael	575	Thawrani, Dinesh	546, 638, 639
Sun, Chuiguo	637	Theodore, Nicholas	649, 663, 690
Sun, Dong	109, 432, 439	Theologis, Alexander	778
Sun, Guang-Quan	414	Thirugnanasambandam, Senthilna	729
Sun, Ming	788	Thomas, Ronald	271
Sun, Xu	114, 215, 216, 219, 275, 276, 736	Thomas, Suresh	271
Sungur, Ibrahim	317	Thompson, Alistair	32
Sutter, Martin	568	Thompson, Cynthia	56, 758
Sutterlin, Chester	601	Thompson, George	4, 19, 475, 564, 572, 597, 607
		Thompson, Samantha	590
		Thompson, Sara	346, 489, 509
		Thornhill, Beverly	28, 474, 481
		Tikoo, Agnivesh	101, 478, 727

Presentation Number Key

1C, 2E, etc. = Instructional Course Lectures Debate# = Debates
Comp# = Complications Series 1-135 = Paper/Podium Presentations 200+ = E-Posters

AUTHOR INDEX

Tintle, Scott	779	Vanconia, Brent	592
Tobert, Dan	309	Vardakastanis, Konstantinos	92, 613
Togawa, Daisuke	369, 644	Varner, Robert	628
Tohmeh, Antoine	359, 448, 674	Varvarousis, Dimitrios	677
Tomak, Patrick	43, 493	Vavken, Patrick	72
Tomaszewski, Ryszard	435	Veliev, Elsen	217
Toombs, Courtney	284, 287, 313	Vellinga, Ryan	496
Torii, Yoshiaki	251, 343, 383, 554	Vereecke, Evie	715
Toscano, Angelo	289, 645	Vialle, Raphael	277, 293
Tougas, Caroline	702	Viergever, Max	128, 715
Tow, Benjamin	81, 647	Vila-Casademunt, Alba	49, 332, 492
Toyama, Yoshiaki	57, 222, 375, 473, 521, 785	Vilendecic, Milorad	673, 678
Toyone, Tomoaki	699	Villanueva, Carlos	44, 49, 332
Tracey, Robert	777	Vincken, Koen	128, 715
Trammell, Terry	285, 366, 376, 391, 725	Vitale, Michael	19, 27, 103, 309, 497, 522, 534, 545, 549, 564
Transfeldt, Ensor	482, 681	Vitsas, Vasilis	92, 613
Traynelis, Vincent	7, 2B, 4B, 5B, Comp1	Vommaro, Francesco	289, 578, 645, 666, 760
Trevino, Hope	535	Vragalas, Vasilios	677
Tribus, Clifford	3	Vrtovec, Tomaz	128, 715
Trobisch, Per	290, 641	Vyskocil, Tomas	602, 790
Tropiano, Patrick	50, 66	Wada, Kanichiro	312
Truumees, Eric	250	Wagner, Scott	777
Tsuji, Taichi	25, 312, 479, 570	Wai, Eugene	702
Tsuji, Takashi	57, 375, 521, 785	Wall, Eric	527, 729
Tsutsui, Shunji	75, 99, 688	Walton, Zeke	108
Turgeon, Isabelle	268	Wang, Bin	219
Turner, Alexander	377	Wang, Chuan-Feng	227, 254, 372
Tweedie, Jillian	271	Wang, Defeng	298
Tyo, Risa	624	Wang, Miao	61, 62, 788
Uehara, Masashi	458	Wang, Weijun	275
Ugras, Akin	317	Wang, Wenhai	619
Ulusoy, Levent	69, 221, 315, 327, 390	Wang, Xinqiang	373
Ungar, Benjamin	3	Wang, Yan	358, 405, 612
Uno, Koki	25	Wang, Yang	373
Uribe, Juan	38, 377, 400, 502, 507, 771	Wang, Yi Peng	239, 438, 583
Urzua, Alejandro	514, 515, 709, 766	Wang, Yuxiang	576
Uschold, Timothy	27, 236	Wang, Zhiwei	275
Ushiku, Chikara	301	Wardlaw, Douglas	55
Vaccaro, Alexander	76, 421, 770	Warner, William	574
Vale, Fernando	507	Warren, Daniel	71, 697
Vallejos Arce, Maria	267, 704, 726	Watanabe, Hironobu	57
Valois Gomez, Teresa	232	Watanabe, Kei	225, 274, 747
Van Allen, Elizabeth	598		
Van Bosse, Harold	574		

Presentation Number Key

IC, 2E, etc. = Instructional Course Lectures Debate# = Debates

Comp# = Complications Series 1-135 = Paper/Podium Presentations 200+ = E-Posters

AUTHOR INDEX

Watanabe, Kota	25, 57, 222, 375, 521, 747, 785	Yagi, Mitsuru	257, 285, 341, 366, 375, 376, 391, 706, 775
Watson, Blake	674	Yagoubi, Fatima	258
Weaver, John	686, 689	Yakici, Sule	349
Webb, Barbara	717	Yalcin, Nadir	417, 586
Weidenbaum, Mark	5D, 396	Yamabe, Daisuke	308
Weinstein, Stuart	226	Yamada, Hiroshi	75, 99, 688
Welk, Thomas	272	Yamaguchi, Kent	564, 646, 730
Werner, Brian	609	Yamamoto, Takuya	25
Whang, Peter	659	Yamasaki, Ryoji	611
Whitaker, Camden	654	Yamato, Yu	47, 369, 644
White, Gregory	208, 291, 303, 504, 732, 741	Yamazaki, Ken	25, 47, 247, 261, 308
White, Nicholas	130	Yanagida, Haruhisa	25, 479, 570, 747
Widmann, Roger	728	Yang, Jun Young	516
Wiedenhofer, Bernd	265	Yasin, Mohammed	630
Wijesekera, Shirvinda	43, 491, 493	Yasuda, Tatsuya	369, 644
Wilkes, David	322	Yaszay, Burt	29, 95, 116, 237, 255, 256, 427, 466, 566, 572, 725
Williams, Brendan	19	Yaszemski, Michael	2A, 5A, Comp4, 58
Willits, Mark	230, 231, 282, 316, 324	Yaylali, Ilker	380
Wilson, Adam	353	Yazici, Muharrem	1D, 3D, 19, 24, 427, 564, 565, 579, 584
Wollowick, Adam	28, 34, 292, 306, 474, 481	Yildirim, Can	68, 253, 563, 731
Wong, Albert	487	Yilgor, Caglar	565, 584
Wong, Chung	434	Yilmaz, Guney	24
Wong, Guoruey	96	Yilmaz, Murat	317
Wong, Hee-Kit	133, 264, 295, 379, 477	Yoo, Andrew	512
Wong, Yat Wa	26	Yoo, Jung	380
Wong, Yatwa	297	Yoon, Seo-Yeon	691, 716
Woo, Raymund	285, 366, 376, 391, 725	Yorgova, Petya	121, 266, 705
Wood, Kirkham	125, 338, 518, 681, 720	Yoshida, Munehito	75, 99, 688
Wood, Robert	527	Yoshida, Satoshi	308
Woodworth, Jessica	540	Yosikawa, Masaho	591
Wooley, Paul	654	Young, Ernest	517, 551
Wright, Neill	762	Youssef, Jim	394, 486, 524, 653, 672
Wright, Patrick	453	Yson, Sharon	325, 608
Wright, Timothy	556	Yu, Bin	239, 438
Wu, Tao	114, 736, 739	Yu, Fiona Wp	233
		Yu, Fish Ws	233
Xiao, Songhua	612	Yu, Miao	30
Xu, Jianzhong	109	Yu, Warren	665
Xu, Leilei	216	Yu, Yang	114, 219
Xu, Yang	245	Yu, Zhengrong	441
		Yukawa, Yasutsugu	88, 457, 699
		Yurac Barrientos, Ratko	514, 515, 709, 766
		Zammarchi, Daniela	582
		Zamorano, Juan	514, 515, 709, 766
		Zebala, Lukas	335, 762
		Zeller, Reinhard	737
		Zeng, Lin	30

Presentation Number Key

1C, 2E, etc. = Instructional Course Lectures Debate# = Debates

Comp# = Complications Series 1-135 = Paper/Podium Presentations 200+ = E-Posters


AUTHOR INDEX

Zeng, Yan	637
Zenner, Juliane	224, 263, 279, 450, 610, 629
Zhang, Daniel	569
Zhang, Guo-You	372
Zhang, Hong	17, 89, 419, 420, 430
Zhang, Hongqi	111, 576, 594, 600
Zhang, Jianguo	22, 239, 583
Zhang, Xing	215
Zhang, Xuesong	358, 405
Zhang, Yonggang	104, 358, 405, 612, 642, 643
Zhen, Xin	114, 736
Zhou, Qiang	699
Zhou, Xuhui	17, 89, 419, 420, 430
Zhu, Feng	114, 219, 275, 276
Zhu, Zezhang	114, 215, 216, 219, 275, 276, 373, 736, 739
Zibera, Tracy	540
Zielinski, Xavier	674
Zigler, Jack	553
Zileli, Mehmet	699
Zinnuroglu, Murat	532
Zisis, Nikolaos	588
Zjakic, Amir	307

Presentation Number Key

1C, 2E, etc. = Instructional Course Lectures Debate# = Debates

Comp# = Complications Series 1-135 = Paper/Podium Presentations 200+ = E-Posters



ABOUT SRS

Founded in 1966, the Scoliosis Research Society is an organization of medical professionals and researchers dedicated to improving care for patients with spinal deformities. Over the years, it has grown from a group of 35 orthopaedic surgeons to an international organization of more than 1,000 health care professionals.

Mission Statement

The purpose of Scoliosis Research Society is to foster the optimal care of all patients with spinal deformities.

Membership

SRS is open to orthopaedic surgeons, neurosurgeons, researchers and allied health professionals who have a practice that focuses on spinal deformity.

Active Fellowship (membership) requires the applicant to have fulfilled a five-year Candidate Fellowship and have a practice that is 20% or more in spinal deformity. Only Active Fellows may vote and hold elected offices within the Society.

Candidate Fellowship (membership) is open to all orthopaedic surgeons, neurosurgeons and to researchers in all geographic locations who are willing to commit to a clinical practice which includes at least 20% spinal deformity. Candidate Fellows stay in that category for five years, during which time they must demonstrate their interest in spinal deformity and in the goals of the Scoliosis Research Society. Candidate Fellows may serve on SRS committees. After five years, those who complete all requirements are eligible to apply for Active Fellowship in the Society. Candidate Fellowship does not include the right to vote or hold office.

Associate Fellowship (membership) is for distinguished members of the medical profession including nurses, physician assistants, as well as orthopaedic surgeons, neurosurgeons, scientists, engineers and specialists who have made a significant contribution to scoliosis or related spinal deformities who do not wish to assume the full responsibilities of Active Fellowship. Associate Fellows may not vote or hold office, but may serve on committees.

Programs and Activities of the SRS are focused primarily on education and research and include the Annual Meeting, the International Meeting on Advanced Spine Techniques (IMAST), Worldwide Regional Conferences, a Global Outreach Program, a Research Endowment Fund which provides grants for spine deformity research, and development of patient education materials.

Website Information

For the latest information on SRS meetings, programs, activities and membership please visit www.srs.org. The SRS Website Committee works to ensure that the information is accurate, accessible and tailored for target audiences. Site content is varied and frequently uses graphics to stimulate ideas and interest. Content categories include information for medical professionals, patients/public, and SRS members.

For more information and printable membership applications, please visit the SRS website www.srs.org.

Board of Directors

B. Stephens Richards, MD	President
Kamal N. Ibrahim, MD, FRCS(C), MA	President-Elect
Steven D. Glassman, MD	Vice President
Hubert Labelle, MD	Secretary
Paul D. Sponseller, MD	Treasurer
Lawrence G. Lenke, MD	Past President 2011
Richard E. McCarthy, MD	Past President 2010
J. Abbott Byrd, MD	Director
John R. Dimar, II, MD	Director
Francisco Sanchez Perez-Gueso, MD	Director
David S. Marks, FRCS	Director
Suken Shah, MD	Director
Christopher I. Shaffrey, MD	Director

Council Chairs

Education Council	Daniel J. Sucato, MD, MS
Finance Council	Paul D. Sponseller, MD
Governance Council	Hubert Labelle, MD
Research Council	Kenneth M C Cheung, MD


ABOUT SRS

Committee & Taskforce (TF) Chairs


Adult Deformity	Sigurd H. Berven, MD
Advocacy and Public Policy	Vishwas A. Talwalkar, MD
Awards and Scholarship	Stephen J. Lewis, MD, MSc, FRCSC
Bylaws and Policies	Michael C. Albert, MD
CME	Glenn R. Rechtine, II, MD
Coding	R. Dale Blasier, MD
Compelling Stories TF	John M. (Jack) Flynn, MD
Corporate Relations	Lawrence G. Lenke, MD
Development	Steven M. Mardjetko, MD, FAAP
Directed Research TF	B. Stephens Richards, III, MD
Education	Mark B. Dekutoski, MD and John R. Dimar, II, MD
E-Text	Praveen Mummaneni, MD
Ethics & Professionalism	J. Abbott Byrd, MD
Evidence Based Medicine	James O. Sanders, MD
Fellowship	Carlos A. Tello, MD
Fellowship Criteria TF	Mark Weidenbaum, MD
50th Anniversary TF	David W. Polly, Jr., MD
Finance	Paul D. Sponseller, MD
Global Outreach	Kenneth J. Paonessa, MD
Globalization	Lawrence G. Lenke, MD
Growing Spine	Suken A. Shah, MD
Historical	Behrooz A. Akbarnia, MD
IMAST	Christopher I. Shaffrey, MD
Long Range Planning	Lawrence G. Lenke, MD
Morbidity and Mortality	Paul A. Broadstone, MD
Newsletter	Vicki Kalen, MD
Nominating	Lawrence G. Lenke, MD
Non-Operative Management	Nigel J. Price, MD
Patient Education	Christopher Bergin, MD
Pediatric Device TF	Michael G. Vitale, MD
Program	Daniel J. Sucato, MD, MS
Public Relations	Andrew G. King, MD
Research Grant	John M. (Jack) Flynn, MD
Scoliosis Screening TF	Hubert Labelle, MD
3D Scoliosis	Hubert Labelle, MD
Website	Michael S. Roh, MD
Worldwide Conference	Ahmet Alanay, MD

Society Office Staff

Tressa Goulding, CAE, CMP — Executive Director (tgoulding@srs.org)
 Cydni Chapman — Meetings Coordinator (cchapman@srs.org)
 Megan M. Kelley — Meetings Director (mkelley@srs.org)
 Courtney Kissinger — Executive Assistant (ckissinger@srs.org)
 Katy Kujala-Korpela — Program Coordinator (kkujala-korpela@srs.org)
 Brian Lueth — Program Manager (blueth@srs.org)
 Nilda Toro — Membership Manager (ntoro@srs.org)



Scoliosis Research Society
 555 East Wells Street, Suite 1100
 Milwaukee, WI 53202
 Phone: 414-289-9107
 Fax: 414-276-3349
www.srs.org





SAVE THE DATES

July 10-13, 2013

Vancouver, British Columbia
Canada

IMAST



20th International Meeting on
Advanced Spine Techniques

Abstract Submission Open
November 1, 2012


Abstract Deadline
February 1, 2013

Registration Open
January 2013

WWW.SRS.ORG



48th



Scoliosis Research Society

Annual Meeting & Course

SEPTEMBER 18-21, 2013

Lyon, France

Abstract Submission Open - November 1, 2012

Abstract Deadline - February 1, 2013

Registration Open - May 2013

Scoliosis Research Society presents

IMAST



20th International Meeting on
Advanced Spine Techniques

July 10-13, 2013

Vancouver, British Columbia
Canada

Abstract Submission Open
November 1, 2012

Abstract Deadline
February 1, 2013

Registration Open
January 2013

www.srs.org