

A literature review and update in endoscopic thyroidectomy

WONG Kai-Pun

MBBS, FRCS

LANG Hung-Hin Brian

MBBS, MS, FRACS

Division of Endocrine Surgery, Department of Surgery, The University of Hong Kong, Queen Mary Hospital, Hong Kong

Correspondence

Dr Brian HH Lang

Department of Surgery

The University of Hong Kong

Queen Mary Hospital

Pokfulam Road

Hong Kong

Tel: (852) 2255 4232

Fax: (852) 2817 2291

Email: blang@hkucc.hku.hk

Keywords: thyroidectomy, endoscopic thyroidectomy, minimal invasive thyroidectomy, scarless

ABSTRACT

Since the first report of endoscopic subtotal parathyroidectomy in 1996, a variety of endoscopic surgical approaches has been reported. These endoscopic approaches include the minimally-invasive video-assisted thyroidectomy (MIVAT), the endoscopic lateral approach, the lateral mini-incision approach, the anterior/chest (hybrid) approach, the transaxillary approach, the axillo-breast approach, the post-auricular and axillary approach and other novel experimental approaches. Some of these approaches could be done with the assistance of the da Vinci robot (i.e. robotic-assisted thyroidectomy). For simplification, these approaches could be categorized into the cervical/direct approach and extra-cervical/indirect approach. Each technique or approach has its own benefits and weaknesses. Currently, there is no preferred approach in the literature and the choice seems to be determined by the surgeon's own experience and patient's preference. In our experience, the transaxillary approach was a technically more challenging procedure and was associated with longer hospital stay, longer operating time, more immediate pain, and increased overall RLN injury and morbidity than MIVAT. The 6-month scar appearance and patient satisfaction were similar between the two procedures.

INTRODUCTION

Thyroidectomy remains one of the most commonly performed surgical procedures. With increasing demand for better safety and surgical outcomes of elective surgical procedures from the community, many thyroid surgeons have adopted a number of new technologies such as intra-operative neuro-monitoring of recurrent laryngeal nerve (RLN), post-operative parathyroid hormone assay and alternative energy device such as ultrasonic shears or bipolar coagulation. Other examples of new surgical technology include endoscopic instruments and high-density telescope which have allowed surgeons to make a smaller incision and be minimally invasive. Any procedure which involves using the endoscope is often collectively called “endoscopic thyroidectomy”

The name “endoscopic thyroidectomy” has generated immense interest among thyroid surgeons. Since the first report in endoscopic parathyroidectomy reported by Gagner et al in 1996 [1], various minimal invasive approaches have been described in the literature. They could be generally classified into direct/cervical and indirect/extra-cervical approach depended on location of incision.[2] For direct/cervical approach, small incision(s) are made in the neck area and the thyroid gland is exposed directly similar to the conventional thyroidectomy but with endoscopic instruments. It may be regarded as truly minimal invasive because incisions are generally smaller than the conventional approach and the amount of surgical dissection is generally less. Figure 1 shows the amount of tissue dissection needed with each approach. Two widely reported examples include the minimally invasive video assisted thyroidectomy (MIVAT) and the minimally invasive lateral approach. On the other hand, the indirect/extra-cervical approach involves having incisions outside the neck area or extra-cervical region e.g. axillary, peri-areolar or post auricular region. The main advantage of this approach is that there is no visible scar in the neck or “scarless” in the neck. However, it is often criticized for being maximally invasive because extensive subcutaneous dissection is often required with this approach.[3] Furthermore, it is technically more demanding and might be associated with a higher morbidity rate. Perhaps, because of the technical difficulties, most of the large reported series came from specialized centers with interest in thyroid surgery.

Therefore, its application to the wider surgical community remains questionable. More recently, the use of the da Vinci Robotic system has been reported in order to overcome some of these technical issues. This review served as an update describing various endoscopic thyroidectomy approaches and the evidence for and against each approach based on the current literature.

Cervical / Direct endoscopic approaches

MIVAT

The MIVAT was first described by a group of surgeons from Pisa, Italy in 1998 [4]. It was quickly adopted by surgeons worldwide because it was truly minimally invasive and the use of the endoscope gave the surgeons a magnified view of the operative field. MIVAT is often regarded as a hybrid procedure as opposed to other endoscopic procedures because it requires both open and laparoscopic surgical skills. Similar to the traditional thyroidectomy, patient is often put under a general anaesthesia, although regional anaesthesia by bilateral deep cervical plexus block is possible. A 1.5cm midline incision is then made about 2cm above sternal notch. Midline is incised longitudinally for 3~4cm to separate the strap muscle. Strap muscle is then separated from thyroid with blunt dissection. The operative field is developed and maintained by external retractor held by an assistant. After that, the operation is conducted under endoscopic/ video assisted manner. A 5mm 30 degree telescope is inserted with the external branch of superior laryngeal nerve identified and preserved with the help of optical magnification of telescope. Superior lobe vessel is then either clipped or divided by ultrasonic shears. Superior lobe is gradually pulled and delivered through the wound. Thereafter, the rest of the procedure is performed not dissimilar to the conventional thyroidectomy. Contralateral lobe would be excised and delivered in similar manner. No drain is needed and skin is closed with subcuticular stitches and sealant.

This technique is associated with excellent cosmetic and surgical outcomes. [5, 6] However, only 10~15% of patients with a small goiter would be suitable. Only patients with a solitary thyroid nodule < 35mm, and / or thyroid volume < 25 ml are considered suitable for MIVAT. Beside size, redo surgery, previous neck irradiation and locally invasive carcinoma are also considered absolute contraindications. [7] Presence of hypervascular gland e.g. Graves' disease or thyroiditis were initially thought to be contraindications for MIVAT. However, in the latest review of 1946 patients by same group of surgeons, 17.9% of patients with benign disease on final pathology had thyroiditis while 30.9% of patients with malignancy had unexpected thyroiditis. Therefore, the presence of

thyroiditis is no longer considered a contraindication in MIVAT. [8] With more experience, the application of MIVAT has been extended to pediatric patients as well as patients requiring lateral functional neck dissection for lymph node metastases. [9, 10]

Since the first report on MIVAT, numerous comparative studies have evaluated the outcome of MIVAT with the conventional thyroidectomy. [11] A recent meta-analysis did not find significant differences in post-operative hypocalcemia and RLN palsy rates and the MIVAT generally took longer to complete [OR=1.681, 95%CI=0.600-2.762, $p=0.023$]. [12] However, MIVAT was associated with a lower pain score at 24 hours post-operative [odd ratio (OR)= -4.496, 95%CI= -7.146 to -2.045, $p=0.0004$] and better reported cosmesis score [OR= 3.669, 95%CI= 0.636-60.702, $p=0.178$]. [12]

Common indications for MIVAT include indeterminate and low to intermediate-risk papillary carcinoma. MIVAT appeared to have a comparable oncological outcome as conventional thyroidectomy. [14] The thyroglobulin levels, thyrotrophin stimulating hormone and percentage of radiouptake were not different in early operation and long term follow up. [13, 14] There was no significant difference in cure rate after a median follow up of 5 years in these groups of low risk PTC patient. [14]

Endoscopic lateral approach

Unlike the conventional thyroidectomy and MIVAT, the initial incision is made over sternocleidomastoid muscle (SCM). Thyroid gland is being approached laterally through splitting of strap muscle and SCM. Henry et al first reported their technique on endoscopic lateral approach in 1999. [15] One 10mm and two 3mm ports was inserted along SCM. Operating space is maintained with low pressure CO₂ insufflation. Vital structures, like parathyroid gland, RLN and external branch of superior laryngeal nerve could be readily identified and preserved. With the help of endoscopic instruments and magnification, individual vessel could be controlled and thyroid would be completely dissected free. Specimen is normally retrieved through a 12mm incision.

However, one of the disadvantages with this approach is that only unilateral pathology could be resected (i.e. hemithyroidectomy) because the incision is only placed on one side of the neck. If the contralateral side needs to be explored at the same time, a collar incision (i.e. extension of the incision) would be required. However, only 5% would require a conversion if cases are properly selected. [2] On the other hand, strict criteria limited only 5% of workload was eligible by this approach.[2]

Lateral mini-incision Technique

Similar to endoscopic lateral approach, thyroid gland is approached by entering the plane between the SCM and strap muscles. Instead of using endoscopic instruments, it is done in an open fashion. It was first described by Delbridge et al. [16] A small (2.5cm) lateral incision is made over the nodule and subplatysmal flap is raised to allow skin incision to be moved around the neck and relevant area of dissection. Anterior border of SCM is incised to expose lateral margin of strap muscle. Strap muscle is retracted medially and SCM is retracted laterally to expose the lateral part of thyroid gland. Middle thyroid vein is first divided and then isthmus is mobilized and transected to allow maximal mobilization. Skin incision is then retracted cranially and exposed and divided the upper pole vessels. Lower pole is mobilized with careful capsular dissection with preservation of

inferior parathyroid gland. Thyroid gland is then delivered through the skin incision. Rest of the procedure is similar to conventional thyroidectomy. With careful capsular dissection, the superior parathyroid gland and RLN would be dissected away from thyroid gland and preserved.

Comparing to conventional hemithyroidectomy, Sywak et al. reported a single arm-blinded randomized trial. They found that the mini-incision approach took an extra 10 minutes but it was associated with a lower pain score on the 1st postoperative day (2.67 vs 3.43, $p=0.032$) and 10th day (1.5 vs 1.8, $p=0.36$), greater cosmetic satisfaction score (6.3 vs 5.0, $p=0.002$) and a smaller wound (2.6 cm vs 5.4 cm, $p<0.001$). [17] However, owing to the fact that the incision is placed one side of the neck only, it is limited to hemithyroidectomy. Nevertheless, it is relatively easier to learn than other types of endoscopic operation. [18, 19]

Extra-cervical / Indirect approaches

Anterior chest/ breast approach

In 1998, Shimizu et al. reported their experience of approaching the thyroid gland via the infra-clavicular incisions. It is termed video assisted neck surgery (VANS).[20] The operation was aimed to be “scarless” over the neck. However, due to incomplete covering of infra-clavicular scar by clothing and high chance of scar hypertrophic change, Ohgami et al modified the incision and placed it at upper circum-areolar areas in 2000.[21]

The initial incision is made at infra-clavicular or bilateral upper circum-areolar areas. Skin flap is raised by blunt dissection of subcutaneous tissue and sub-platysmal space. Operating space is maintained by skin lifting device or CO2 insufflation. Additional port is inserted at infra-clavicular region. Strap muscle is divided longitudinally to expose the thyroid gland. Rest of the procedure is similar to open thyroidectomy, dissection initiated from inferior lobe and proceed postero-laterally and then superiorly under the aim of endoscopic instruments. Individual vessel is controlled with ultrasonic shears and whole course of RLN is identified and preserved. Despite good covering of the scars, some patients do not want any dissection around nipple areolar region as the presence of breast implant is a concern. [22]

Trans-axillary approach

Trans-axillary approach offers good cosmesis as the axillary wound could be covered by patient’s own clothes. It also avoids unnecessary dissection around areolar region. It was first described by Ikeda et al in 2000. [23] To our knowledge, over 1500 patients had undergone this approach. [24-34] The patient is put under general anesthesia and lies in supine position. The neck is slightly extended and ipsilateral arm is raised and fixed at shortest distance between axilla and anterior neck. A 4 to 6 cm vertical incision is made along the outer border of pectoris major. The skin flap is raised superficial to pectoralis fascia and toward anterior neck. The avascular plan between sternal

and clavicular head of SCM is developed. Anterior part of thyroid is dissected free from strap and skin flap is raised with a skin lifting device.

A 10 mm and a 5 mm trocar are placed on either ends of the axillary wound. Another 5 mm trocar is placed in the chest. The inferior pole of thyroid is carefully dissected to isolate RLN and parathyroid glands. Vessels are divided between clips or by ultrasonic shears. Thyroid is then retracted medially. Berry's ligament is dissected and divided. For hemithyroidectomy, isthmus is transected using ultrasonic shear, while medial approach for contralateral thyroid would be needed if bilateral resection is indicated. Specimen is retrieved through axillary wound and operating field is irrigated. Drain is placed before wound closure. This approach avoids any scar over the neck. Distance between incision and thyroid is short and therefore less subcutaneous dissection is needed. However contralateral dissection is difficult and collision of instruments is common due to limited working space. Figure 2 shows pictures of a patient who underwent transaxillary thyroidectomy after 3 months.

The largest series was reported by Kang et al. in 2009. Five hundred and eighty one patients including 410 with cancer underwent the gasless endoscopic thyroidectomy.[27] The complication rates were not high with 3.2% of patients having transient hypocalcemia, 1.5% having transient hoarseness and 0.2% having permanent RLN palsy. Compared to conventional approach, this approach took longer time.[28] Patients also had more pain but were more satisfied.[35] Figure 3 shows the endoscopic view of transaxillary thyroidectomy. On the other hand, some studies suggested that trans-axillary approach might be associated with higher rate of transient hypocalcemia and transient RLN palsy.[36, 37] In a patient with a low risk papillary thyroid microcarcinoma, Jeong et al. reported that trans-axillary thyroidectomy with prophylactic central neck dissection was feasible. Oncologically, though less numbers of lymph node were retrieved than that of the conventional approach (5.05 vs 5.96, $p=0.007$), none of 275 patients underwent trans-axillary approach had Tg >1 ng/ml. In the conventional group, 6 of 224 had Tg > 1ng/ml. However, there might have been some selective bias with the results as high risk patients were

likely undergoing conventional approach.[36] With application of the da Vinci robotic system and maturation of skills, discussion on endoscopic approach on central and lateral neck dissection has largely shifted to the robotic approach (see later). [38-40]

Further advances in trans-axillary approach have been proposed to optimize or maximize the cosmetic outcome of the wound. Presence of anterior chest incision was associated with hypertrophic change or even keloid, especially in Asian patients. Surgeons from Korea proposed lowering the incisions and placing them at peri-areolar site to decrease the “visibility” of the scar, namely unilateral axillo-breast approach.[41] The central neck compartment and tumor nodule \geq 4cm could be tackled by this approach. [41, 42] On the other hand, a single-incision in the axilla was shown to be feasible.[43, 44]

Axillo-breast (hybrid) approach

In anterior approach and trans-axillary approach, narrow endoscopic view and limited angulation of instruction are the major technical challenges for surgeons. To overcome these limitations, Shimazu et al in Japan first described using both axillary and breast incisions and the so-called axillo-bilateral-breast approach (ABBA).[45] Patient is under general anesthesia and arms are abducted. Ipsilateral circum-areolar incision is made. Subcutaneous and sub-platysmal working space is developed with blunt dissection similar to the anterior chest/breast approach. Working space is extended to level of thyroid cartilage superiorly and medial edge of SCM bilaterally. Working space is maintained with low pressure CO₂ insufflation. Additional ports are inserted through ipsilateral axilla and contralateral circum-areolar incision. Rest of the procedure is similar to anterior chest/breast approach. Through endoscopic instruments inserted to axillary port, wider triangulation of manipulation facilitates dissection and mobilization of thyroid gland. The resected thyroid gland is retrieved through circum-areolar wound with a plastic bag.

Choe et al. added another incision to contralateral axilla and is now known as bilateral axillo-breast approach (BABA).[46] From a largest series of 512 patients with thyroidectomy via BABA, Choi et

al. reported a low rate of permanent hypocalcemia (4.2%) and RLN palsy (1.7%).[47] However, transient hypocalcemia rate (31.1%) and proportion of transient RLN palsy (20.1%) was relatively high compared to other reported series (~4%).[46] However, because the technique involves extensive subcutaneous flap dissection, it is often criticized for being “maximally” invasive.[48] It results in upper chest discomfort, pain and fibrosis of skin flap and prolongs paraesthesia of up to 12 -18 months.[49] Unlike the trans-axillary approach, the experience of BABA is reported mainly in Asian countries. We think that it might be related to better acceptance of the peri-areolar incision and extensive dissection over subcutaneous tissue over the breast. Furthermore, the larger-sized breasts commonly seen in the Caucasian population makes BABA more difficult.

Post auricular and axillary approach (PAA)

To avoid dissection around peri-areolar region and maintain triangulation of manipulation, Lee et al. reported this approach by making incision at bilateral axillary and post-auricular region.[50] The operation starts with infusion of diluted adrenaline solution to subcutaneous and sub-platysmal space of anterior chest and neck. After making a 12 mm incision at ipsilateral axilla, subcutaneous space is created with blunt dissection. A 12 mm trocar is inserted into axillary wound and operative space is inflated with low pressure CO₂. Another port is inserted into contralateral axilla and two 5 mm is inserted through bilateral post-auricular incision. Midline incision is made and strap muscle is splitted and retracted lateral by endoscopic instrument through post-auricular ports. The thyroid is dissected and excised similar to conventional anterior approach. It is a technically challenging operation. Branches of facial nerve were also susceptible to traction injury. Even though it avoids the peri-areolar dissection, this technique has not been popular.

Other novel approaches

Other novel endoscopic approaches were mostly based on cadavers. These techniques included the retro-auricular video-assisted gasless thyroidectomy [51], totally trans-oral video assisted thyroidectomy (TOVAT) under gas insufflations [52]. In cadaver studies, it is feasible to excise the

thyroid gland through incision of floor of mouth under gas insufflation. Two cases on trans-oral parathyroidectomy in 2 patients with primary hyperparathyroidism have been reported.[53] This approach seems to be technically feasible but is heavily criticized on its safety. Working space is very limited and potential infection through a relatively contaminated incision is a major concern.[54, 55]

Robotic-assisted thyroidectomy

Since first report of robotic trans-axillary thyroidectomy in 2009, robotic thyroidectomy has been widely performed worldwide.[56-59] Theoretically, it overcomes many of the technical challenges associated with transaxillary thyroidectomy because the robot could provide a three dimensional magnified view, seven degree of freedom and 90° articulation and filter any hand tremors.[56]. In a multi-center study with 2014 patients, Lee et al. showed that robotic thyroidectomy had a minimal major complication rate of about 1 % and superior surgical ergonomic benefits for surgeons.[60] On questioning of 7 operating surgeons, performing robotic thyroidectomy had a lowest rate of neck pain and/or back pain compared to performing open or endoscopic thyroidectomy.[60] Like endoscopic thyroidectomy, single-incision transaxillary robotic assisted thyroidectomy or robotic thyroidectomy with using BABA approach had been reported as feasible and safe surgical approach options.[61, 62]

We reported our initial experience of 7 robotic thyroidectomies and compared their outcomes with that of endoscopic thyroidectomy. We found the former had similar complication rate but it took longer to perform. However, identification of contralateral RLN was easier. (100% vs 42.9%, $p=0.070$).[59] In contrast to our result, operation time was generally shorter in other groups of surgeons.[57, 63] It was probably related to early phase of learning curve.[64] Robotic transaxillary thyroidectomy appeared to have a shorter learning curve than endoscopic thyroidectomy (35~40 cases vs 55~60 cases). [65] In terms of post-operative complication, no significant difference had been reported despite one comparative study suggested higher rate of transient hypocalcemia. [63]. The author hypothesized that it could be due to more complete removal of peri-thyroidal fascia and tissue leading to thermal damage or transient ischemia of parathyroid gland.

Oncologically, incorporation of prophylactic central neck dissection into endoscopic or robotic thyroidectomy is advocated. With the help of Robotic system, higher number of central neck lymph node could be retrieved.[57, 63] In a large Korean series of 1150 patients with papillary thyroid microcarcinoma, after one year of follow up, post-operative serum thyroglobulin was comparably

low in both endoscopic and robotic assisted thyroidectomy. No abnormal uptake after radioactive ablation nor recurrence on neck ultrasonography was noted.[63] It signified possible completed, oncologically safe surgical removal of thyroid gland is feasible by both technique.

One of the major and most important limitations with any robotic procedure is the cost. The cost is not just limited to the initial installment of the da Vinci Robotic system, but also includes the expensive consumables, ongoing maintenance and training of staff. The average operation cost is near 8 time more than the conventional approach (US \$ 6655 vs 829, $p < 0.01$).[26, 66] Therefore, routine use of robotic assisted approach might not be justified in the economic sense. Further studies on the cost-effectiveness of robotic thyroidectomy are needed.

Other than trans-axillary and axillo-breast approaches, an innovative remote approach namely the robotic facelift thyroidectomy have been recently reported.[67] Patient lies in a supine position with head slightly rotated away from the side of pathology. The incision is then made along post auricular crease extending into the occipital hairline. The SCM is dissected along its anterior border. The greater auricular nerve and external jugular vein are identified and retracted anteriorly. The avascular space between SCM and strap muscle is developed and working space is maintained by external retractor. Robotic system is docked. The dissection of thyroid gland begins in the superior pole and then proceeds inferiorly. Compared to trans-axillary or BABA approach, both the distance and area of dissection is reduced. The peri-areolar dissection and dissection across clavicle during flap elevation are avoided. However, it is only limited to hemithyroidectomy.[68]

Robotic-assisted neck dissection for thyroid cancer

Approximately 10-20% of patients with papillary thyroid cancer would present with palpable lateral lymph node metastasis. A total thyroidectomy and comprehensive lateral neck dissection is the treatment of choice for this group of patients. The minimally invasive or endoscopic central or lateral neck dissection had been proven to be feasible and safe.[10, 27, 41, 69] However, there is limited operative space and that makes the manipulation with endoscopic instruments difficult. With the help of the robotic system, more precise and angulation of manipulation could be

performed. Kang et al. reported the first comparative study comparing robotic and conventional approach in radical neck dissection for papillary thyroid cancer. [38] In their studies, despite a selection bias towards younger-aged patients, smaller tumors and earlier tumor stages in the robotic group, the complication rates and mean number of lymph node retrieved were similar. Operation took longer (277.4 +/- 43.2 minutes vs 218.2 +/- 43.8 minutes, $p < 0.00001$) but patients were able to be discharged earlier (6.0 +/- 2.5 days vs 8 +/- 5.2 days, $p < 0.008$) in the robotic group. Postoperative suppressed thyroglobulin level and rate of abnormal uptake in RAI scan were also comparable to conventional open approach. Further prospective studies on robotic thyroidectomy with neck dissection are needed to confirm its cosmetic benefit and oncological safety.

Though metastasis to level I, IIb, Va lymph node was not uncommon (<5-8%), access to these levels was restricted by trans-axillary or BABA approach. Kim et al introduced a new technique called the trans-axillary and retro-auricular approach (TARA). The TARA potentially provide a better access and comprehensive neck dissection to these levels. [70] Robotic arms are inserted through retro-auricular and axillary incision. The level IIb & Va lymph nodes are dissected under direct vision through retro-auricular incision. Level I lymph node is dissected with robotic arm at retro-auricular incision. A case series of 7 patients with head and neck squamous cell cancer was recently reported. [70]

Selection of approach and patient satisfaction

Different minimally invasive approaches have been described in the literature. Currently, there is no evidence to suggest that one particular approach is better than the other. It appears it is highly variable and is dependent on the surgeon's own experience and patient's preference. Nevertheless, we tried to answer this question by comparing the short-term surgical outcomes, scar appearance and patient satisfaction between MIVAT and the transaxillary approach. In our recent comparison, we found that the transaxillary approach was a technically more challenging procedure and was associated with longer hospital stay, longer operating time, more immediate pain, and increased overall RLN injury and morbidity than MIVAT. The 6-month scar appearance and patient satisfaction were similar between the two procedures.[71]

By operating with minimal invasive or endoscopic approach, reports suggest a higher patient satisfaction and cosmetic outcome could be achieved.[12, 28] However, we could not negate the potential publication bias. Recent reports in Europe even criticized the size of incision in MIVAT was not associated with better patient satisfaction. [72, 73]

Conclusion

Since the first report of endoscopic subtotal parathyroidectomy in 1996, a variety of endoscopic surgical approaches have been reported. They could be categorized into the cervical/direct approach and extra-cervical/indirect approach. Each technique or approach has its own benefits and weaknesses. Currently, there is no preferred approach and the choice between different approaches seems to be determined by the surgeon's own experience and patient's preference. In our experience, the transaxillary approach was a technically more challenging procedure and was associated with longer hospital stay, longer operating time, more immediate pain, and increased overall RLN injury and morbidity than the MIVAT. The 6-month scar appearance and patient satisfaction were similar between the two procedures.

Bibliography

1. Gagner, M., Endoscopic subtotal parathyroidectomy in patients with primary hyperparathyroidism. *Br J Surg*, 1996. **83**(6): p. 875.
2. Slotema, E.T., F. Sebag, and J.F. Henry, What is the evidence for endoscopic thyroidectomy in the management of benign thyroid disease? *World J Surg*, 2008. **32**(7): p. 1325-32.
3. Tan, C.T., W.K. Cheah, and L. Delbridge, "Scarless" (in the neck) endoscopic thyroidectomy (SET): an evidence-based review of published techniques. *World J Surg*, 2008. **32**(7): p. 1349-57.
4. Miccoli, P., et al., Minimally invasive surgery for thyroid small nodules: preliminary report. *J Endocrinol Invest*, 1999. **22**(11): p. 849-51.

** The first report on MIVAT.
5. Bellantone, R., et al., Video-assisted vs conventional thyroid lobectomy: a randomized trial. *Arch Surg*, 2002. **137**(3): p. 301-4; discussion 305.
6. El-Labban, G.M., Minimally invasive video-assisted thyroidectomy versus conventional thyroidectomy: A single-blinded, randomized controlled clinical trial. *J Minim Access Surg*, 2009. **5**(4): p. 97-102.
7. Miccoli, P., G. Materazzi, and P. Berti, Minimally invasive thyroidectomy in the treatment of well differentiated thyroid cancers: indications and limits. *Curr Opin Otolaryngol Head Neck Surg*, 2010. **18**(2): p. 114-8.
8. Minuto, M.N., et al., Minimally invasive video-assisted thyroidectomy: an analysis of results and a revision of indications. *Surg Endosc*, 2012. **26**(3): p. 818-22.
9. Spinelli, C., et al., Minimally invasive video-assisted thyroidectomy in pediatric patients. *J Pediatr Surg*, 2008. **43**(7): p. 1259-61.
10. Lombardi, C.P., et al., Minimally invasive video-assisted functional lateral neck dissection for metastatic papillary thyroid carcinoma. *Am J Surg*, 2007. **193**(1): p. 114-8.

** The study showed feasibility of functional neck dissection with MIVAT.

11. Miccoli, P., et al., Minimally invasive video-assisted thyroidectomy for benign thyroid disease: an evidence-based review. *World J Surg*, 2008. **32**(7): p. 1333-40.
12. Radford, P.D., et al., Meta-analysis of minimally invasive video-assisted thyroidectomy. *Laryngoscope*, 2011. **121**(8): p. 1675-81.

** This metaanalysis analyzed 5 comparative studies and showed superior result in pain control and cosmetic outcome but comparable surgical complication in MIVAT compared to conventional thyroidectomy
13. Miccoli, P., et al., Minimally invasive video-assisted thyroidectomy for papillary carcinoma: a prospective study of its completeness. *Surgery*, 2002. **132**(6): p. 1070-3; discussion 1073-4.
14. Miccoli, P., et al., Surgical treatment of low- and intermediate-risk papillary thyroid cancer with minimally invasive video-assisted thyroidectomy. *J Clin Endocrinol Metab*, 2009. **94**(5): p. 1618-22.
15. Henry, J.F., et al., Minimally invasive videoscopic parathyroidectomy by lateral approach. *Langenbecks Arch Surg*, 1999. **384**(3): p. 298-301.
16. Gosnell, J.E., et al., Minimal access thyroid surgery: technique and report of the first 25 cases. *ANZ J Surg*, 2004. **74**(5): p. 330-4.
17. Sywak, M.S., et al., A randomized controlled trial of minimally invasive thyroidectomy using the lateral direct approach versus conventional hemithyroidectomy. *Surgery*, 2008. **144**(6): p. 1016-21; discussion 1021-2.
18. Palazzo, F.F., et al., Safety and feasibility of thyroid lobectomy via a lateral 2.5-cm incision with a cohort comparison of the first 50 cases: evolution of a surgical approach. *Langenbecks Arch Surg*, 2005. **390**(3): p. 230-5.
19. Lundgren, C.I., et al., Minimally invasive thyroid surgery for diagnostic excision of solitary thyroid nodules. *Asian J Surg*, 2007. **30**(4): p. 250-4.

20. Shimizu, K., S. Akira, and S. Tanaka, Video-assisted neck surgery: endoscopic resection of benign thyroid tumor aiming at scarless surgery on the neck. *J Surg Oncol*, 1998. **69**(3): p. 178-80.
21. Ohgami, M., et al., Scarless endoscopic thyroidectomy: breast approach for better cosmesis. *Surg Laparosc Endosc Percutan Tech*, 2000. **10**(1): p. 1-4.
22. Lee, Y.S., et al., Endoscopic Thyroidectomy via a Transaxillary Approach Is a Safe Procedure in Patients With Breast Augmentation. *Surg Innov*, 2012.
23. Ikeda, Y., et al., Endoscopic neck surgery by the axillary approach. *J Am Coll Surg*, 2000. **191**(3): p. 336-40.

** The first study reporting thyroidectomy through trans-axillary approach.
24. Chang, E.H., T.E. Lobe, and S.K. Wright, Our initial experience of the transaxillary totally endoscopic approach for hemithyroidectomy. *Otolaryngol Head Neck Surg*, 2009. **141**(3): p. 335-9.
25. Rao, R.S. and T.D. Duncan, *Endoscopic total thyroidectomy*. *JSLs*, 2009. **13**(4): p. 522-7.
26. Yoo, H., et al., Comparison of surgical outcomes between endoscopic and robotic thyroidectomy. *J Surg Oncol*, 2012. **105**(7): p. 705-8.
27. Kang, S.W., et al., Gasless endoscopic thyroidectomy using trans-axillary approach; surgical outcome of 581 patients. *Endocr J*, 2009. **56**(3): p. 361-9.

** The largest single centre series on endoscopic transaxillary thyroidectomy showed lower surgical morbidity including RLN palsy and hypocalcemia.
28. Ikeda, Y., et al., Endoscopic thyroidectomy and parathyroidectomy by the axillary approach. A preliminary report. *Surg Endosc*, 2002. **16**(1): p. 92-5.
29. Udomsawaengsup, S., et al., Endoscopic transaxillary thyroid lobectomy: flexible vs rigid laparoscope. *J Med Assoc Thai*, 2004. **87 Suppl 2**: p. S10-4.

30. Chantawibul, S., S. Lokechareonlarp, and C. Pokawatana, Total video endoscopic thyroidectomy by an axillary approach. *J Laparoendosc Adv Surg Tech A*, 2003. **13**(5): p. 295-9.
31. Yoon, J.H., C.H. Park, and W.Y. Chung, Gasless endoscopic thyroidectomy via an axillary approach: experience of 30 cases. *Surg Laparosc Endosc Percutan Tech*, 2006. **16**(4): p. 226-31.
32. Jung, E.J., et al., Endoscopic thyroidectomy using a gasless axillary approach. *J Laparoendosc Adv Surg Tech A*, 2007. **17**(1): p. 21-5.
33. Witzel, K., The axillary access in unilateral thyroid resection. *Langenbecks Arch Surg*, 2007. **392**(5): p. 617-21.
34. Duncan, T.D., et al., Endoscopic transaxillary approach to the thyroid gland: our early experience. *Surg Endosc*, 2007. **21**(12): p. 2166-71.
35. Ikeda, Y., et al., Are there significant benefits of minimally invasive endoscopic thyroidectomy? *World J Surg*, 2004. **28**(11): p. 1075-8.
36. Jeong, J.J., et al., Comparative study of endoscopic thyroidectomy versus conventional open thyroidectomy in papillary thyroid microcarcinoma (PTMC) patients. *J Surg Oncol*, 2009. **100**(6): p. 477-80.
37. Chung, Y.S., et al., Endoscopic thyroidectomy for thyroid malignancies: comparison with conventional open thyroidectomy. *World J Surg*, 2007. **31**(12): p. 2302-6; discussion 2307-8.
38. Kang, S.W., et al., A comparative study of the surgical outcomes of robotic and conventional open modified radical neck dissection for papillary thyroid carcinoma with lateral neck node metastasis. *Surg Endosc*, 2012.

** the only available comparative study on robotic neck dissection in patient with thyroid carcinoma with lateral neck lymph node metastasis. It showed similar number of lymph node retrieval and duration of post-operative hospital stay in this “scarless” approach.

39. Lee, J. and W.Y. Chung, Current status of robotic thyroidectomy and neck dissection using a gasless transaxillary approach. *Curr Opin Oncol*, 2012. **24**(1): p. 7-15.
40. Agcaoglu, O., et al., Robotic transaxillary central neck dissection: video description of the technique. *Surg Laparosc Endosc Percutan Tech*, 2012. **22**(4): p. e197-8.
41. Koh, Y.W., et al., Endoscopic hemithyroidectomy with prophylactic ipsilateral central neck dissection via an unilateral axillo-breast approach without gas insufflation for unilateral micropapillary thyroid carcinoma: preliminary report. *Surg Endosc*, 2010. **24**(1): p. 188-97.
42. Kim, W.S., et al., Increasing the size limit of benign thyroid lesions resectable by endoscopic thyroidectomy via a unilateral axillo-breast approach without gas insufflation. *World J Surg*, 2011. **35**(10): p. 2203-11.
43. Lee, D., Y. Nam, and K. Sung, Single-incision endoscopic thyroidectomy by the axillary approach. *J Laparoendosc Adv Surg Tech A*, 2010. **20**(10): p. 839-42.
44. Fan, Y., S.D. Wu, and J. Kong, Single-port access transaxillary totally endoscopic thyroidectomy: a new approach for minimally invasive thyroid operation. *J Laparoendosc Adv Surg Tech A*, 2011. **21**(3): p. 243-7.
45. Shimazu, K., et al., Endoscopic thyroid surgery through the axillo-bilateral-breast approach. *Surg Laparosc Endosc Percutan Tech*, 2003. **13**(3): p. 196-201.
46. Choe, J.H., et al., Endoscopic thyroidectomy using a new bilateral axillo-breast approach. *World J Surg*, 2007. **31**(3): p. 601-6.

** This study first described another popular extra-cervical approach, the bilateral axillo-breast approach (BABA).

47. Choi, J.Y., et al., Endoscopic thyroidectomy via bilateral axillo-breast approach (BABA): review of 512 cases in a single institute. *Surg Endosc*, 2012. **26**(4): p. 948-55.

** The largest series reported the single outcome of endoscopic thyroidectomy with BABA approach.

48. Duh, Q.Y., Presidential Address: Minimally invasive endocrine surgery--standard of treatment or hype? *Surgery*, 2003. **134**(6): p. 849-57.
49. Kim, S.J., et al., Recovery of sensation in the anterior chest area after bilateral axillo-breast approach endoscopic/robotic thyroidectomy. *Surg Laparosc Endosc Percutan Tech*, 2011. **21**(5): p. 366-71.
50. Lee, K.E., et al., Postauricular and axillary approach endoscopic neck surgery: a new technique. *World J Surg*, 2009. **33**(4): p. 767-72.
51. Walvekar, R.R., et al., Retro-auricular video-assisted "gasless" thyroidectomy: feasibility study in human cadavers. *Surg Endosc*, 2010. **24**(11): p. 2895-9.
52. Benhidjeb, T., et al., Natural orifice surgery on thyroid gland: totally transoral video-assisted thyroidectomy (TOVAT): report of first experimental results of a new surgical method. *Surg Endosc*, 2009. **23**(5): p. 1119-20.
53. Karakas, E., et al., Transoral thyroid and parathyroid surgery--development of a new transoral technique. *Surgery*, 2011. **150**(1): p. 108-15.
54. Miccoli, P., G. Materazzi, and P. Berti, Natural orifice surgery on the thyroid gland using totally transoral video-assisted thyroidectomy: report of the first experimental results for a new surgical method: are we going in the right direction? *Surg Endosc*, 2010. **24**(4): p. 957-8; author reply 959-60.
55. Dionigi, G., F. Rovera, and L. Boni, Commentary on transoral access for endoscopic thyroid resection : Witzel K, von Rahden BH, Kaminski C, Stein HJ (2008) Transoral access for endoscopic thyroid resection. *Surg Endosc* 22(8):1871-1875. *Surg Endosc*, 2009. **23**(2): p. 454-5; discussion 456.
56. Kang, S.W., et al., Robot-assisted endoscopic thyroidectomy for thyroid malignancies using a gasless transaxillary approach. *J Am Coll Surg*, 2009. **209**(2): p. e1-7.
57. Lee, J., et al., Comparison of endoscopic and robotic thyroidectomy. *Ann Surg Oncol*, 2011. **18**(5): p. 1439-46.

58. Koppersmith, R.B. and F.C. Holsinger, Robotic thyroid surgery: an initial experience with North American patients. *Laryngoscope*, 2011. **121**(3): p. 521-6.
59. Lang, B.H. and M.P. Chow, A comparison of surgical outcomes between endoscopic and robotically assisted thyroidectomy: the authors' initial experience. *Surg Endosc*, 2011. **25**(5): p. 1617-23.
60. Lee, J., et al., Multicenter study of robotic thyroidectomy: short-term postoperative outcomes and surgeon ergonomic considerations. *Ann Surg Oncol*, 2011. **18**(9): p. 2538-47.
61. Ryu, H.R., et al., Feasibility and safety of a new robotic thyroidectomy through a gasless, transaxillary single-incision approach. *J Am Coll Surg*, 2010. **211**(3): p. e13-9.
- ** The study introduced the single-incision transaxillary approach for robotic thyroidectomy. The study proved it is safe and technically feasible with comparable outcome with traditional transaxillary approach
62. Lee, K.E., J. Rao, and Y.K. Youn, Endoscopic thyroidectomy with the da Vinci robot system using the bilateral axillary breast approach (BABA) technique: our initial experience. *Surg Laparosc Endosc Percutan Tech*, 2009. **19**(3): p. e71-5.
63. Lee, S., et al., Excellence in robotic thyroid surgery: a comparative study of robot-assisted versus conventional endoscopic thyroidectomy in papillary thyroid microcarcinoma patients. *Ann Surg*, 2011. **253**(6): p. 1060-6.
- ** This comparative study showed the superiority of robotic thyroidectomy in terms of increased LN retrieval and shorter operating time
64. Lang, B.H., M.P. Chow, and K.P. Wong, Endoscopic vs robotic thyroidectomy: which is better? *Ann Surg Oncol*, 2011. **18 Suppl 3**: p. S251.
65. Lee, J., et al., The learning curve for robotic thyroidectomy: a multicenter study. *Ann Surg Oncol*, 2011. **18**(1): p. 226-32.
- ** This study compared the learning curve of robotic and endoscopic transaxillary thyroidectomy.

66. Broome, J.T., S. Pomeroy, and C.C. Solorzano, Expense of Robotic Thyroidectomy: A Cost Analysis at a Single Institution. *Arch Surg*, 2012: p. 1-5.
67. Terris, D.J. and M.C. Singer, Robotic facelift thyroidectomy: Facilitating remote access surgery. *Head Neck*, 2012. **34**(5): p. 746-7.
68. Terris, D.J. and M.C. Singer, Qualitative and quantitative differences between 2 robotic thyroidectomy techniques. *Otolaryngol Head Neck Surg*, 2012. **147**(1): p. 20-5.
69. Miccoli, P., et al., Video-assisted central compartment lymphadenectomy in a patient with a positive RET oncogene: initial experience. *Surg Endosc*, 2007. **21**(1): p. 120-3.
70. Kim, W.S., et al., Feasibility of robot-assisted neck dissections via a transaxillary and retroauricular ("TARA") approach in head and neck cancer: preliminary results. *Ann Surg Oncol*, 2012. **19**(3): p. 1009-17.
71. Lang, B.H. and K.P. Wong, A Comparison of Surgical Morbidity and Scar Appearance Between Gasless, Transaxillary Endoscopic Thyroidectomy (GTET) and Minimally Invasive Video-Assisted Thyroidectomy (VAT). *Ann Surg Oncol*, 2012.
** A study compared cervical (MIVAT) and extra-cervical (transaxillary thyroidectomy) approaches.
72. Bokor, T., et al., Cosmesis and body image after minimally invasive or open thyroid surgery. *World J Surg*, 2012. **36**(6): p. 1279-85.
73. Linos, D., et al., Scar perceptions after thyroid and parathyroid surgery: Comparison of minimal and conventional approaches. *Surgery*, 2012.

Figure 1. Diagrams illustrate the area of dissection of different endoscopic thyroidectomy. From left to right, minimally invasive video-assisted thyroidectomy, transaxillary thyroidectomy, Endoscopic thyroidectomy by bilateral axillo-breast approach.

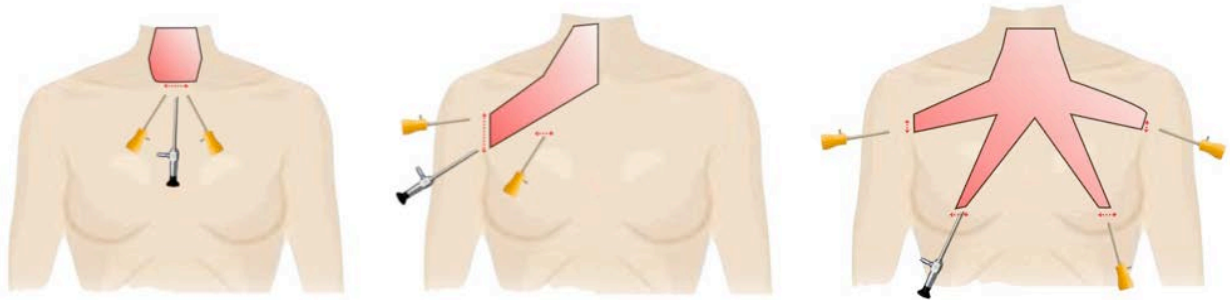


Figure 2. A patient underwent transaxillary thyroidectomy 3 months after the operation.

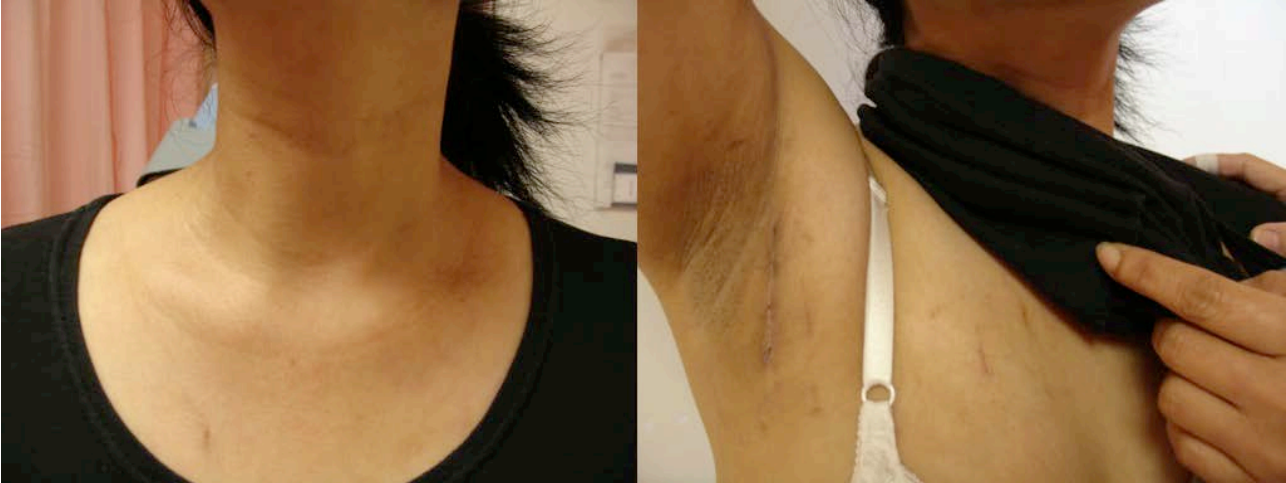

Figure 3. Endoscopic lateral view of thyroid gland during transaxillary thyroidectomy. Thyroid gland was retracted medially. And recurrent laryngeal nerve was dissected clearly.

