

Meta-Analysis of the Effect of Intravitreal Bevacizumab Versus Intravitreal Triamcinolone Acetonide in Central Retinal Vein Occlusion

Zi Ye Jin,^{1,*} Dan Zhu,^{1,*} Yong Tao,² Ian Y. Wong,³ and Jost B. Jonas⁴

Abstract

Purpose: To further evaluate the effect of intravitreal bevacizumab (IVB) for the treatment of central retinal vein occlusion (CRVO) by meta-analysis.

Methods: Pertinent publications were identified through PubMed, EMBASE, and the Cochrane Controlled Trials Register up to 30 January 2013. Changes in central macular thickness (CMT) and best-corrected visual acuity (BCVA) were extracted at 4, 12, and 24 weeks after treatment, and a meta-analysis was carried out to compare results between groups receiving IVB and intravitreal triamcinolone acetonide (IVTA).

Results: One randomized controlled trial and 4 comparative studies were identified and included. All of the funnel plots, the Egger's method and Begg method did not show publication bias. Our meta-analysis revealed that BCVA and CMT at 4, 12, and 24 weeks after treatment did not vary significantly between the IVB groups and IVTA groups (BCVA: at 4 weeks, $P=0.27$; at 12 weeks, $P=0.51$; at 24 weeks, $P=0.64$; CMT at 4 weeks, $P=0.88$; at 12 weeks, $P=0.57$; at 24 weeks, $P=0.64$). However, the rate of intraocular pressure rise after intravitreal injection varied significantly between the IVB groups and IVTA groups ($P<0.001$).

Conclusions: Our results showed a similar improvement in BCVA and CMT among CRVO patients was obtained after intravitreal injections of both IVB, or IVTA, while the rate of IOP rise was significantly higher in the latter.

Introduction

CENTRAL RETINAL VEIN occlusion (CRVO) is a common retinal vascular disorder in patients more than 50 years old, and one of the commonest causes of visual loss in CRVO patients is macular edema.¹ Till now, numerous interventions have been developed to tackle this, namely, systemic anticoagulation, panretinal photocoagulation, macular grid photocoagulation, hemodilution, laser chorioretinal venous anastomosis, and radial optic neurotomy. Nevertheless, there is still inadequate level I evidence to show superiority in any specific regimen to improve vision in CRVO patients.¹⁻³

The panoply of therapeutic possibilities increased dramatically with the development of intravitreal medical therapies, initially with the intravitreal use of triamcinolone (IVTA),⁴⁻⁸ followed by the intravitreal application of bevacizumab (IVB), and subsequently, the other antivascular endothelial growth factors in the recent 8 years.⁹⁻¹⁴ Although reduction of macular thickness and improvement of vision were observed after both treatments, as far as the authors were aware, no systematic reviews comparing the therapeutic effects of IVB and IVTA for CRVO have been published. It is necessary to review in greater depth, the benefits and risks of IVB and IVTA for CRVO. We have performed a meta-analysis to review the literature to compare the effect

¹The Affiliated Hospital of Inner Mongolia Medical University, Hohhot, Inner Mongolia, China.

²Department of Ophthalmology, People's Hospital, Peking University, and Key Laboratory of Vision Loss and Restoration, Ministry of Education, Beijing, China

³Department of Ophthalmology, University of Hong Kong, Hong Kong, China.

⁴Department of Ophthalmology, Medical Faculty Mannheim of the Ruprecht-Karls-University, Heidelberg, Germany.

*These authors contributed equally to this study.

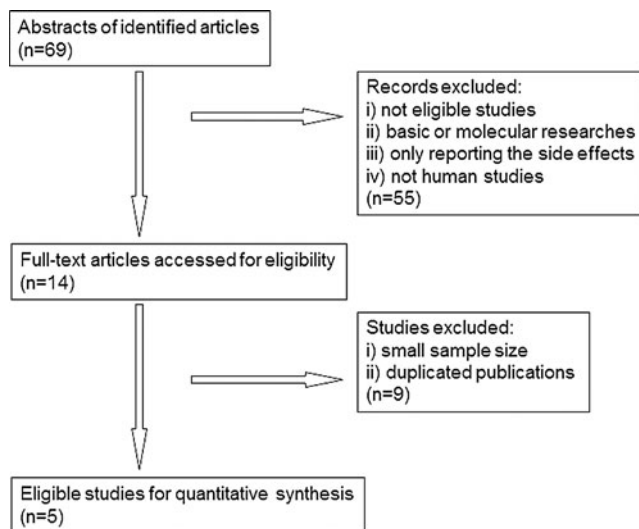


FIG. 1. Flowchart of literature search and study selection.

and safety profiles of both IVB and IVTA, in treating patients with CRVO.

Methods

Two reviewers independently searched the following electronic databases: PubMed, EMBASE, and the Cochrane

Controlled Trials Register up to January 30, 2013. Free text and thesaurus terms, including “bevacizumab,” “triamcinolone acetonide,” “central retinal vein occlusion,” and “macular edema” were used. When titles and/or abstracts met the objectives, the full article would be retrieved. A manual cross-reference search for bibliographies of relevant articles was also conducted. The inclusion criteria for references were (1) all published studies comparing IVB versus IVTA for CRVO, including randomized controlled trials (RCTs) and high-quality comparative studies; and (2) all articles, where pre- and post-treatment visual acuity and the macular thickness were measured and recorded. There was no language restriction. For the publications from the same group of authors, only the article with the largest number of patients was used. The selected articles were then critically appraised by 2 reviewers, who independently assessed their quality using the modified Jadad score table.¹⁵ Parameters judging the methodological quality included allocation concealment, the method of intervention allocation, the degree of masking, and the completeness in subject follow-up. The postoperative outcome parameters included best-corrected visual acuity (BCVA) and central macular thickness (CMT).

The following data from the original articles were being extracted: first author and year of publication; study site; study design; sample size and age of the participants; treatment method and follow-up duration; numbers lost to follow-up; and treatment outcome in terms of BCVA and CMT.

TABLE 1. MAIN CHARACTERISTICS OF STUDIES INCLUDED IN THIS META-ANALYSIS

Authors	Publication time (year)	Study design	Region	Number of cases	Mean age of IVB cases (years)	Mean time of IVB during follow-up	Dosage of IVB (mg)	Dosage of IVTA (mg)	Follow-up duration
Ding et al. ¹²	2011	Controlled, randomized	China	32 (IVB 16)	54.6 ± 14.2	2.38	1.25	4.0	9 months
Guthoff et al. ³⁷	2010	Controlled, nonrandomized	Germany	18 (IVB 9)	65 ± 4	1.3	1.5	8.0	12 months
Lim and Na ¹¹	2011	Controlled, nonrandomized	India	38 (IVB 24)	68.7 ± 14.7	3.6	1.25	4.0	12 months
Tao et al. ⁹	2010	Controlled, nonrandomized	China	72 (IVB 30)	55.15 ± 15.9	2.7	1.25	4.0	12 months
Wu et al. ¹⁴	2009	Controlled, nonrandomized	Taiwan	35 (IVB 13)	59.07 ± 17.49	1.62	1.25	4.0	12 months

IVB, intravitreal bevacizumab; IVTA, intravitreal triamcinolone acetonide.

TABLE 2. COMPARISON OF BEST-CORRECTED VISUAL ACUITY AT 24 WEEKS AFTER INITIAL TREATMENT BETWEEN INTRAVITREAL INJECTION OF BEVACIZUMAB GROUPS AND INTRAVITREAL INJECTION OF TRIAMCINOLONE ACENOTIDE GROUPS

Authors	Subgroup						Weight	Mean difference IV, random, 95% CI
	IVB group			Triamcinolone group				
	Mean	SD	Total	Mean	SD	Total		
Ding et al. ¹²	0.889	0.568	16	0.802	0.45	16	8.4%	0.09 [-0.27, 0.44]
Guthoff et al. ³⁷	0.19	0.2	9	0.11	0.19	9	32.7%	0.08 [-0.10, 0.26]
Lim and Na ¹¹	0.9	0.36	24	0.93	0.41	14	15.9%	-0.03 [-0.29, 0.23]
Tao et al. ⁹	0.12	0.27	30	0.13	0.41	42	43.0%	-0.01 [-0.17, 0.15]
Total (95% CI)			79			81	100.0%	0.02 [-0.08, 0.13]

Heterogeneity: Tau²=0.00; χ²=0.84, df=3 (P=0.84); I²=0%.
 Test for overall effect: Z=0.46 (P=0.64).

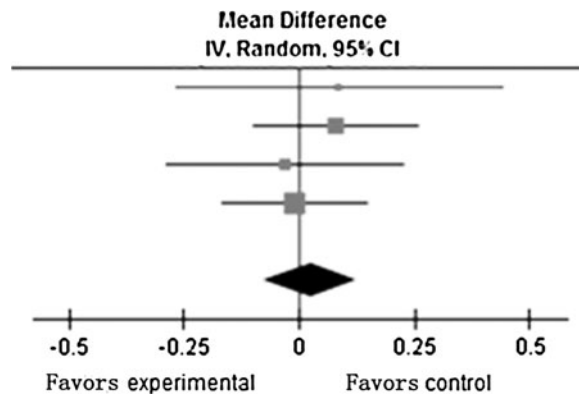


FIG. 2. Comparison of best-corrected visual acuity at 24 weeks after initial treatment between intravitreal injection of bevacizumab (IVB) groups and intravitreal injection of triamcinolone acetonide (IVTA) groups in published studies (from top to bottom): Ding et al.,¹² Guthoff et al.,³⁷ Lim et al.,¹¹ and Tao and Jonas.⁵

Data extraction was conducted by the 2 reviewers independently, and discordance was resolved through discussion until 100% agreement was reached.

A meta-analysis on the effect of IVB or IVTA on macular edema secondary to CRVO was performed using Cochrane Review Manager (RevMan; version 5.0 software). The treatment effect was estimated by means of weighted mean deviation (WMD) in BCVA and CMT. The incidence of adverse events such as ocular hypertension was evaluated by the risk ratio (RR). Random effect models were used for the meta-analysis, and were verified using the Q test ($P < 0.10$ was considered to indicate statistically significant heterogeneity) and the I^2 statistic (values of 25%, 50%, and 75% are considered to represent low, medium, and high heterogeneity, respectively). Publication bias was assessed by visually inspecting a funnel plot.

Results

A total of 69 articles were identified, of which 55 articles were excluded due to the above-mentioned reasons. A full review was performed for the remaining 14 articles. Nine out of 14 were further excluded due to similarities with previous studies from the same group of

authors (Fig. 1). Five articles published between 2005 and 2012 were finally included into the meta-analysis (Table 1).^{9,11–14}

There were one RCT and 4 nonrandomized controlled studies (Table 1). The sample sizes varied from 18 to 75 subjects, and mean follow-up durations varied from 9 to 12 months. The treatment outcome estimates were provided for a total of 92 eyes in the IVB group and 103 eyes in the IVTA group. In all studies, distribution of age, gender, and history of CRVO did not vary significantly between the IVB group and the IVTA group.

Four studies reported data on BCVA at 4 weeks after the initial treatment. The BCVAs were converted to logarithm of the minimum angle of resolution (logMAR) vision and were summarized by means of meta-analysis ($I^2 = 0\%$). The BCVA at 4 weeks after IVB treatment did not vary significantly when compared to those using IVTA (WMD=0.06; 95% CI: -0.04–0.16; $P = 0.27$). All the 5 studies reported data on BCVA at 12 weeks after the initial treatment, and demonstrated low heterogeneity ($I^2 = 0\%$). The improvement in BCVA did not vary significantly between the IVB and IVTA groups (WMD=0.03; 95% CI: -0.06–0.13; $P = 0.51$). Four studies reported data on BCVA at 24 weeks after the initial treatment, and showed low heterogeneity ($I^2 = 0\%$). Again, the improvement in BCVA did not vary significantly between the IVB and IVTA groups (WMD=0.02; 95% CI: -0.08–0.13; $P = 0.64$) (Table 2) (Fig. 2).

Four studies reported data on CMT at 4 weeks after the initial treatment. Low heterogeneity between studies was detected ($I^2 = 0\%$). Changes in CMT at 4 weeks after IVB did not vary significantly as compared to those using IVTA (WMD=-4.97; 95% CI: -71.41–61.47; $P = 0.88$). All 5 studies reported data on CMT at 12 weeks after the initial treatment, and demonstrated low heterogeneity ($I^2 = 32\%$). Changes in CMT also did not vary significantly between the IVB and IVTA groups (WMD=20.29; 95% CI: -50.53–91.12; $P = 0.57$). Four studies reported data on CMT at 24 weeks after the initial treatment, but showed high heterogeneity ($I^2 = 58\%$). Changes in CMT at 24 weeks after IVB treatment did not vary significantly as compared to those that received IVTA (WMD=67.75; 95% CI: -35.30–170.79; $P = 0.20$) (Table 3) (Fig. 3).

All 5 studies reported complications during the follow-up period, such as intraocular pressure (IOP) rise. No

TABLE 3. COMPARISON OF CENTRAL MACULAR THICKNESS AT 24 WEEKS AFTER INITIAL TREATMENT BETWEEN INTRAVITREAL INJECTION OF BEVACIZUMAB GROUPS AND INTRAVITREAL INJECTION OF TRIAMCINOLONE ACENOTIDE GROUPS

Authors	Subgroup						Weight	Mean difference IV, Random, 95% CI
	IVB group			Triamcinolone group				
	Mean	SD	Total	Mean	SD	Total		
Ding et al. ¹²	326.38	163.07	16	333.46	121.41	16	31.6%	-7.08 [-106.70, 92.54]
Guthoff et al. ³⁷	514.0	249.0	9	488.0	251.0	9	13.8%	26.00 [-204.99, 256.99]
Lim and Na ¹¹	302.4	198.3	24	263.5	158.8	14	28.7%	38.90 [-76.05, 153.85]
Tao et al. ⁹	596.5	319.76	30	383.54	212.51	42	25.9%	212.96 [81.72, 344.20]
Total (95% CI)			79			81	100.0%	67.75 [-35.30, 170.79]

Heterogeneity: $\text{Tau}^2 = 6177.35$; $\chi^2 = 7.17$, $df = 3$ ($P = 0.07$); $I^2 = 58\%$.
Test for overall effect: $Z = 1.29$ ($P = 0.20$).

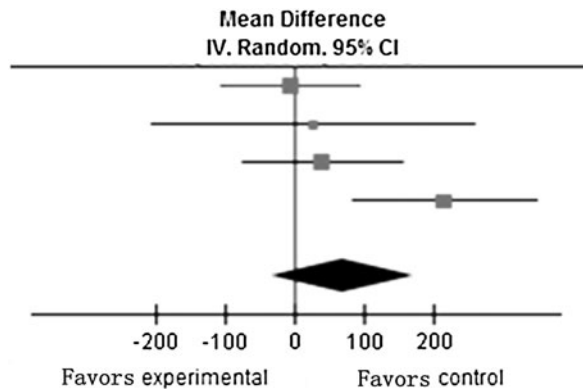


FIG. 3. Comparison of central macular thickness (CMT) at 24 weeks after initial treatment between IVB groups and IVTA groups in published studies (from top to bottom): Ding et al.,¹² Guthoff et al.,³⁷ Lim et al.,¹¹ and Tao and Jonas.⁵

patients had IOP rise after IVB, but IOP rise after IVTA was reported to be as high as 50.5% in one study (52/103). All cases with IOP rise after injection were controllable by medication. Low heterogeneity between studies was detected ($I^2=0\%$). Random-effects model analysis demonstrated a significant difference between IVB and IVTA in this regard (RR, relative risk=0.06; 95% CI: 0.02–0.22; $P<0.001$) (Table 4) (Fig. 4).

Based on funnel plots, no obvious evidence of publication bias was found for the treatment outcome estimates (BCVA and CMT at 12 weeks after initial treatment) (Figs. 5 and 6). Since the number of enrolled studies was low, additional tests (the Egger’s Method, and the Begg’s method) were used to measure publication bias, but none was able to detect any (BCVA at 12 weeks after initial treatment: the Egger’s method: $P=0.14$, the Begg’s method: $P=0.09$; CMT at 12 weeks after initial treatment, the Egger’s method: $P=0.26$, the Begg’s method: $P=0.81$).

Discussion

Our meta-analysis failed to detect any statistical significant difference between the IVB and the IVTA groups, in

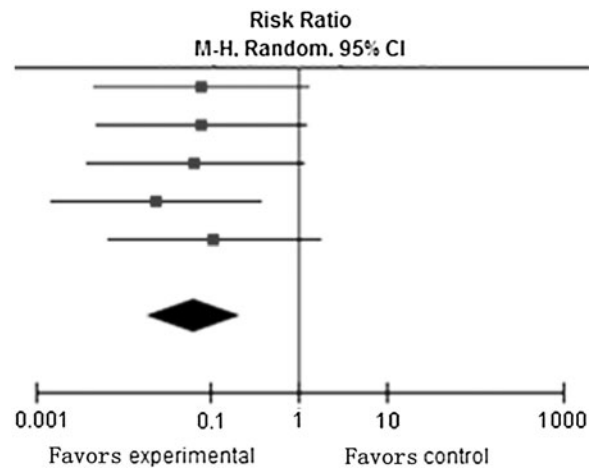


FIG. 4. Comparison of increasing intraocular pressure during follow-ups between IVB groups and IVTA groups in published studies (from top to bottom): Ding et al.,¹² Guthoff et al.,³⁷ Lim et al.,¹¹ Tao and Jonas,⁵ and Wu et al.¹⁴

terms of BCVA measured at 4, 12, and 24 weeks after baseline (at 4 weeks: $P=0.27$; at 12 weeks: $P=0.51$; at 24 weeks: $P=0.64$). Similarly, the difference in reduction in CMT between the 2 groups also did not vary significantly at 4, 12, and 24 weeks (at 4 weeks: $P=0.88$; at 12 weeks: $P=0.57$; at 24 weeks: $P=0.64$). However, the rates of IOP rise were significantly higher in the IVB groups than the IVTA groups ($P<0.001$).

There have been several studies looking into the effect of bevacizumab in macular edema secondary to CRVO. The common results were improvements in BCVA, reduction in CMT on optical coherence tomography (OCT), or improvement in electroretinographic outcomes. At the same time, common shortcomings were the short-term efficacy of IVB, and the high recurrence rates of macular edema after the wearing off of its effect. While the dosage varied from 1.25 to 2.0 mg, there is no difference in terms of the outcomes.^{16–23} On the other hand, similar improvements in BCVA and CMT after IVTA for CRVO were also observed in some other reports.^{4,5,8,24–30} After IVTA, IOP readings higher than 21/30/35/40 mmHg, was reported in as high

TABLE 4. COMPARISON OF INTRAOCULAR PRESSURE AFTER INITIAL TREATMENT BETWEEN INTRAVITREAL INJECTION OF BEVACIZUMAB GROUPS AND INTRAVITREAL INJECTION OF TRIAMCINOLONE ACENOTIDE GROUPS

Authors	Subgroup				Weight	Risk ratio M-H, random, 95% CI
	IVB group		Triamcinolone group			
	Events	Total	Events	Total		
Ding et al. ¹²	0	16	6	16	19.8%	0.08 [0.00, 1.26]
Guthoff et al. ³⁷	0	9	6	9	20.7%	0.08 [0.00, 1.19]
Lim and Na ¹¹	0	24	4	14	19.1%	0.07 [0.00, 1.15]
Tao et al. ⁹	0	30	29	42	20.4%	0.02 [0.00, 0.37]
Wu et al. ¹⁴	0	13	7	22	20.0%	0.11 [0.01, 1.77]
Total (95% CI)		92		103	100.0%	0.06 [0.02, 0.22]
Total events	0		52			

Heterogeneity: $\tau^2=0.00$; $\chi^2=0.77$, $df=4$ ($P=0.94$); $I^2=0\%$.
Test for overall effect: $Z=4.35$ ($P<0.0001$).

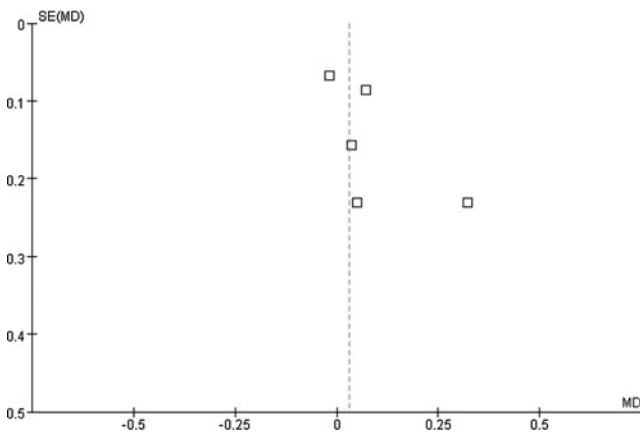


FIG. 5. Funnel plots with respect to best-corrected visual acuity at 12 weeks after initial treatment.

as 36.2/8.5/4.2/1.5% of patients, respectively.⁵ The International Intravitreal Bevacizumab Safety Survey gathered adverse events after IVB from doctors around the world using the internet and found that all ocular and systemic side effects were below 0.21%, including corneal abrasion and lens injury.³¹

These results were in agreement with other comparative studies between IVB and IVTA for the treatment of branch retinal vein occlusion (BRVO).^{32–35} In a study by Kwon et al., both IVTA- and IVB-treated groups showed improvement after injections for BRVO, and there was no significant difference in the visual outcome and macular thickness at 6 months.³² Considering the potential risks with IVTA injections, some authors recommended prescheduled repeated IVB injections for BRVO cases.³³

The findings in our meta-analysis were partly in disagreement with comparative studies between IVB and IVTA for diabetic macular edema (DME). A recent published meta-analysis showed that IVTA was more effective in improving BCVA than IVB in DME, while reduction in CMT was unsustainable.³⁶

The main limitation of this study was that the number of included studies and the total number of subjects were relatively low. This probably reflected the strict inclusion and exclusion criteria. The included studies, however, originated

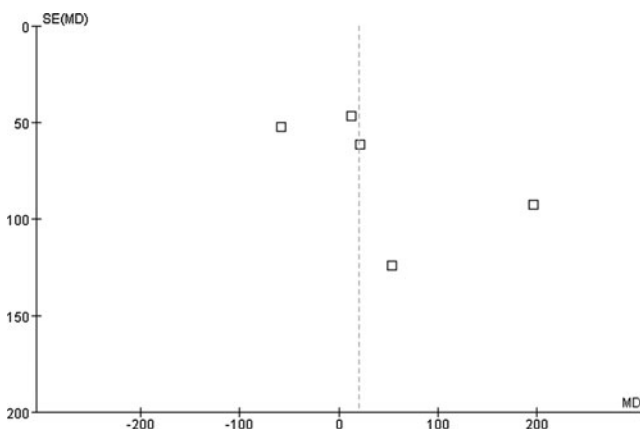


FIG. 6. Funnel plots with respect to CMT at 12 weeks after initial treatment.

from several regions, and all except one⁹ led to similar conclusions in the outcomes measured.

In conclusion, our meta-analysis showed a similar improvement BCVA and CMT in CRVO patients after intravitreal injections of either IVB or IVTA, but IVB appeared to be devoid of unfavorable IOP elevation after injections.

Acknowledgment

This study was supported by the Program for New Century Excellent Talents in University (No. NCET-12-0010).

Author Disclosure Statement

J.B.J.: Consultant for Allergan, Inc., Merck & Co., Inc., Alimera Co., and patent holder with CellMed AG, Alzenau, Germany; all other authors: none.

References

- McAllister, I.L. Central retinal vein occlusion: a review. *Clin. Exp. Ophthalmol.* 40:48–58, 2012.
- Mohamed, Q., McIntosh, R.L., Saw, S.M., et al. Interventions for central retinal vein occlusion: an evidence-based systematic review. *Ophthalmology.* 114:507–519, 524, 2007.
- Ehlers, J.P., and Fekrat, S. Retinal vein occlusion: beyond the acute event. *Surv. Ophthalmol.* 56:281–299, 2011.
- Jonas, J.B., Kreissig, I., and Degenring, R.F. Intravitreal triamcinolone acetonide as treatment of macular edema in central retinal vein occlusion. *Graefes Arch. Clin. Exp. Ophthalmol.* 240:782–783, 2002.
- Tao, Y., and Jonas, J.B. Intravitreal triamcinolone. *Ophthalmologica.* 225:1–20, 2011.
- Ip, M.S., and Kumar, K.S. Intravitreal triamcinolone acetonide as treatment for macular edema from central retinal vein occlusion. *Arch. Ophthalmol.* 120:1217–1219, 2002.
- Park, C.H., Jaffe, G.J., and Fekrat, S. Intravitreal triamcinolone acetonide in eyes with cystoid macular edema associated with central retinal vein occlusion. *Am. J. Ophthalmol.* 136:419–425, 2003.
- Krepler, K., Ergun, E., Sacu, S., et al. Intravitreal triamcinolone acetonide in patients with macular oedema due to central retinal vein occlusion. *Acta Ophthalmol. Scand.* 83:71–75, 2005.
- Tao, Y., Hou, J., Jiang, Y.R., et al. Intravitreal bevacizumab vs triamcinolone acetonide for macular oedema due to central retinal vein occlusion. *Eye.* 24:810–815, 2010.
- Rosenfeld, P.J., Fung, A.E., and Puliafito, C.A. Optical coherence tomography findings after an intravitreal injection of bevacizumab (avastin) for macular edema from central retinal vein occlusion. *Ophthalmic Surg. Laser Imaging.* 36:336–339, 2005.
- Lim, J.W., and Na, K.I. A comparative study between intravitreal triamcinolone and bevacizumab for macular edema due to central retinal vein occlusion with poor vision. *Indian J. Ophthalmol.* 59:93–96, 2011.
- Ding, X., Li, J., Hu, X., et al. Prospective study of intravitreal triamcinolone acetonide versus bevacizumab for macular edema secondary to central retinal vein occlusion. *Retina.* 31:838–845, 2011.
- Wang, H.Y., Li, X., Wang, Y.S., et al. Intravitreal injection of bevacizumab alone or with triamcinolone acetonide for treatment of macular edema caused by central retinal vein occlusion. *Int. J. Ophthalmol.* 4:89–94, 2011.

14. Wu, W.C., Cheng, K.C., and Wu, H.J. Intravitreal triamcinolone acetate vs bevacizumab for treatment of macular edema due to central retinal vein occlusion. *Eye*. 23:2215–2222, 2009.
15. Jadad, A.R., Moore, R.A., Carroll, D., et al. Assessing the quality of reports of randomized clinical trials: is blinding necessary? *Control. Clin. Trials*. 17:1–12, 1996.
16. Iturralde, D., Spaide, R.F., Meyerle, C.B., et al. Intravitreal bevacizumab (Avastin) treatment of macular edema in central retinal vein occlusion: a short-term study. *Retina*. 26:279–284, 2006.
17. Spandau, U.H., Ihloff, A.K., and Jonas, J.B. Intravitreal bevacizumab treatment of macular oedema due to central retinal vein occlusion. *Acta Ophthalmol. Scand.* 84:555–556, 2006.
18. Shetty, R., Pai, S.A., Vincent, A., et al. Electrophysiological and structural assessment of the central retina following intravitreal injection of bevacizumab for treatment of macular edema. *Doc. Ophthalmol. Adv. Ophthalmol.* 116:129–135, 2008.
19. Ferrara, D.C., Koizumi, H., and Spaide, R.F. Early bevacizumab treatment of central retinal vein occlusion. *Am. J. Ophthalmol.* 144:864–871, 2007.
20. Moschos, M.M., and Moschos, M. Intraocular bevacizumab for macular edema due to CRVO. A multifocal-ERG and OCT study. *Doc. Ophthalmol. Adv. Ophthalmol.* 116:147–152, 2008.
21. Hsu, J., Kaiser, R.S., Sivalingam, A., et al. Intravitreal bevacizumab (avastin) in central retinal vein occlusion. *Retina*. 27:1013–1019, 2007.
22. Priglinger, S.G., Wolf, A.H., Kreutzer, T.C., et al. Intravitreal bevacizumab injections for treatment of central retinal vein occlusion: six-month results of a prospective trial. *Retina*. 27:1004–1012, 2007.
23. Rensch, F., Jonas, J.B., and Spandau, U.H. Early intravitreal bevacizumab for non-ischaemic central retinal vein occlusion. *Acta Ophthalmol.* 87:77–81, 2009.
24. Bashshur, Z.F., Ma'luf RN, Allam, S., et al. Intravitreal triamcinolone for the management of macular edema due to nonischemic central retinal vein occlusion. *Arch. Ophthalmol.* 122:1137–1140, 2004.
25. Cekic, O., Chang, S., Tseng, J.J., et al. Intravitreal triamcinolone treatment for macular edema associated with central retinal vein occlusion and hemiretinal vein occlusion. *Retina*. 25:846–850, 2005.
26. Degenring, R.F., Kampeter, B., Kreissig, I., et al. Morphological and functional changes after intravitreal triamcinolone acetate for retinal vein occlusion. *Acta Ophthalmol. Scand.* 81:399–401, 2003.
27. Greenberg, P.B., Martidis, A., Rogers, A.H., et al. Intravitreal triamcinolone acetate for macular oedema due to central retinal vein occlusion. *Br. J. Ophthalmol.* 86:247–248, 2002.
28. Ip, M., Kahana, A., and Altaweel, M. Treatment of central retinal vein occlusion with triamcinolone acetate: an optical coherence tomography study. *Semin. Ophthalmol.* 18:67–73, 2003.
29. Ip, M.S., Gottlieb, J.L., Kahana, A., et al. Intravitreal triamcinolone for the treatment of macular edema associated with central retinal vein occlusion. *Arch. Ophthalmol.* 122:1131–1136, 2004.
30. Jonas, J.B., Akkoyun, I., Kampeter, B., et al. Intravitreal triamcinolone acetate for treatment of central retinal vein occlusion. *Eur. J. Ophthalmol.* 15:751–758, 2005.
31. Fung, A.E., Rosenfeld, P.J., and Reichel, E. The International Intravitreal Bevacizumab Safety Survey: using the internet to assess drug safety worldwide. *Br. J. Ophthalmol.* 90:1344–1349, 2006.
32. Kwon, S.I., Kim, Y.W., Bang, Y.W., et al. Comparison of natural course, intravitreal triamcinolone, and intravitreal bevacizumab for treatment of macular edema secondary to branch retinal vein occlusion. *J. Ocul. Pharmacol. Ther.* 29:5–9, 2013.
33. Ramezani, A., Esfandiari, H., Entezari, M., et al. Three intravitreal bevacizumab versus two intravitreal triamcinolone injections in recent-onset branch retinal vein occlusion. *Graefes Arch. Clin. Exp. Ophthalmol.* 250:1149–1160, 2012.
34. Higashiyama, T., Sawada, O., Kakinoki, M., et al. Prospective comparisons of intravitreal injections of triamcinolone acetate and bevacizumab for macular oedema due to branch retinal vein occlusion. *Acta Ophthalmol.* 91:318–324, 2013.
35. Hou, J., Tao, Y., Jiang, Y.R., et al. Intravitreal bevacizumab versus triamcinolone acetate for macular edema due to branch retinal vein occlusion: a matched study. *Chin. Med. J.* 122:2695–2699, 2009.
36. Zhang, Y., Ma, J., Meng, N., et al. Comparison of intravitreal triamcinolone acetate with intravitreal bevacizumab for treatment of diabetic macular edema: a meta-analysis. *Curr. Eye Res.* 38: 578–587, 2013.
37. Guthoff, R., Meigen, T., Hennemann, K., et al. Comparison of bevacizumab and triamcinolone for treatment of macular edema secondary to central retinal vein occlusion—a matched-pairs analysis. *Ophthalmologica*. 224:126–132, 2010.

Received: June 12, 2013

Accepted: July 9, 2013

Address correspondence to:
 Prof. Yong Tao
 Department of Ophthalmology
 People's Hospital
 Peking University
 11 Xizhimen South Street
 Xicheng District
 Beijing 100044
 China

E-mail: drtaoyong@163.com