

RESEARCH ARTICLE

Evaluation of juxta-apical radiolucency in cone beam CT images

¹R Kapila, ¹N Harada, ¹K Araki, ¹T Sano and ²T K Goto

¹Division of Radiology, Department of Oral Diagnostic Sciences, Showa University School of Dentistry, Tokyo, Japan; ²Oral Radiology, Oral Diagnosis and Polyclinics, Faculty of Dentistry, The University of Hong Kong, Hong Kong

Objectives: The aim of this study was to analyse the position and relationship of juxta-apical radiolucency (JAR) to the mandibular canal and buccal and/or lingual cortical plates using cone beam CT (CBCT).

Methods: A retrospective study was carried out to analyse the JAR on CBCT for 27 patients. These findings were compared with 27 age- and sex-matched patients without the presence of JAR, which acted as the control group. The CBCT images were analysed according to a checklist, to evaluate the position of the JAR and its relationship to the mandibular canal. Then, any thinning or perforation of either the buccal or lingual cortical plate due to JAR was noted, and a classification to quantify the thinning of cortical plates was proposed. The findings in the two groups were analysed using a paired comparison by McNemar test.

Results: A statistical increased thinning of cortical plates was seen in the JAR group compared with the control group, and most of the cases were in the J3 group. None of the patients in either the JAR or the control group showed perforation of the buccal and/or lingual cortical plate on CBCT images.

Conclusions: A classification to quantify the thinning of cortical plates was proposed, which may be used for objective evaluation of the thinning of the cortical plates in future studies. The present study gives an insight into the relationship of the juxta-apical area with the mandibular canal and cortical plates in the mandible using CBCT.

Dentomaxillofacial Radiology (2014) **43**, 20130402. doi: [10.1259/dmfr.20130402](https://doi.org/10.1259/dmfr.20130402)

Cite this article as: Kapila R, Harada N, Araki K, Sano T, Goto TK. Evaluation of juxta-apical radiolucency in cone beam CT images. *Dentomaxillofac Radiol* 2014; **43**: 20130402.

Keywords: third molar; mandible; cone beam computed tomography

Introduction

Surgical extraction of impacted mandibular third molars is a common procedure in dental practice. To minimize the post-operative complications, the surgeon should have relevant information about the impacted third molars, such as the inclination of the tooth root/s to the buccal or lingual cortical plate and the course of the mandibular canal in relation to the roots.¹

Panoramic radiographs are the imaging modality most commonly used by oral and maxillofacial surgeons to view impacted third molars and to estimate the risk of inferior alveolar nerve injury.² In particular, Rood and Shehab³ reported that three of seven classic radiographic

signs indicate a higher risk of inferior alveolar nerve injury, implicating close proximity of the inferior alveolar nerve to the lower third molar. However, some investigators have reported that panoramic radiography does not provide sufficiently reliable images to predict nerve lesions.^{2,4,5} In addition, some reports have indicated that it is only possible to determine the true relationship of the tooth root with the inferior alveolar nerve with CT.^{2,4-6}

In fact, axial, coronal and sagittal CT images, all provide surgeons with useful information, and such images are also beneficial for the pre-operative planning of the surgical procedure because of the high-resolution quality of medical CT.^{1,5} It has been shown that cone beam CT (CBCT) images are best suited for pre-operative

Correspondence to: Dr Rishabh Kapila. E-mail: rishabh.kapila@gmail.com

Received 6 November 2013; revised 21 March 2014; accepted 1 April 2014

assessment of impacted third molars and the relationship of these to surrounding structures.¹

A new radiographic sign, the juxta-apical radiolucency (JAR), has been seen on panoramic radiographs and has been shown to be more predictive of nerve injuries than that of other signs. This new radiographic sign is a well-circumscribed radiolucent area lateral to the root rather than at the apex.⁷ The presence of JAR has been related to a greater incidence of post-operative paraesthesia in some studies.^{8,9}

So far, no studies have been carried out to study the relationship of the juxta-apical area to the mandibular canal and buccal/lingual cortical plates using CBCT. Therefore, the aim of this study was to analyse the position and relationship of JAR with the mandibular canal and the buccal and/or lingual cortical plates using CBCT and to compare the findings with non-juxta-apical cases, as controls.

Methods and materials

A retrospective study was carried out to analyse the JAR on CBCT for 27 patients. The JAR group had 10 males and 17 females with a mean age of 34 years. The findings of this group were compared with 27 age- and sex-matched patients without the presence of JAR, which acted as a control group. The control group had 8 males and 19 females with a mean age of 31 years. All the cases were selected on the basis of the presence or the absence of JAR on panoramic radiographs. The inclusion criteria also warranted the involved third molar to be non-carious and without the presence of any other pathology like a cyst or tumour.

Subsequently, CBCT images were collected for these cases. The CBCT machine used was “3D Accuitomo 80” (J Morita, Kyoto, Japan), operating at 90 kV and 4 mA, with a field of view of a cylinder of 4 cm in height and 4 cm

Table 1 Classification for thinning of cortical plates

J1	When the remaining thickness of the cortical plate was two-thirds of the maximum thickness
J2	When the remaining thickness of the cortical plate was one-half of the maximum thickness
J3	When the remaining thickness of the cortical plate was one-quarter of the maximum thickness

in diameter. All these images were viewed using One Data Viewer software (J Morita) on a liquid-crystal display screen with a resolution of 1366 × 768 pixels, without any magnification. The multiplanar reconstructed images (MPR) images were selected at the mandibular third molar region with a slice thickness of 0.25 mm and an interslice distance of 0.25 mm. The CBCT images were analysed in all dimensions to evaluate the position of the JAR and its relationship with the mandibular canal. A checklist was prepared for the parameters to be evaluated on CBCT data. Before reaching a consensus, two radiologists independently evaluated all of the subjects based on the checklist, and the images were then reviewed together for a final decision.

The position and relationship of JAR to the mandibular canal was recorded as lingual, buccal, inferior and central or others. In the control group, the spatial relationship of the apex of the root to the mandibular canal was evaluated using the same parameters.

The condition of the cortical plates was then analysed to see whether the JAR in the JAR group or the third molar roots/mandibular canal in the control group caused any thinning or perforation of either the buccal or lingual cortical plate. The CBCT images were analysed three dimensionally, and an MPR image was selected, which showed the maximum thinning of the cortical plate. Then, using the measurement tool, the remaining

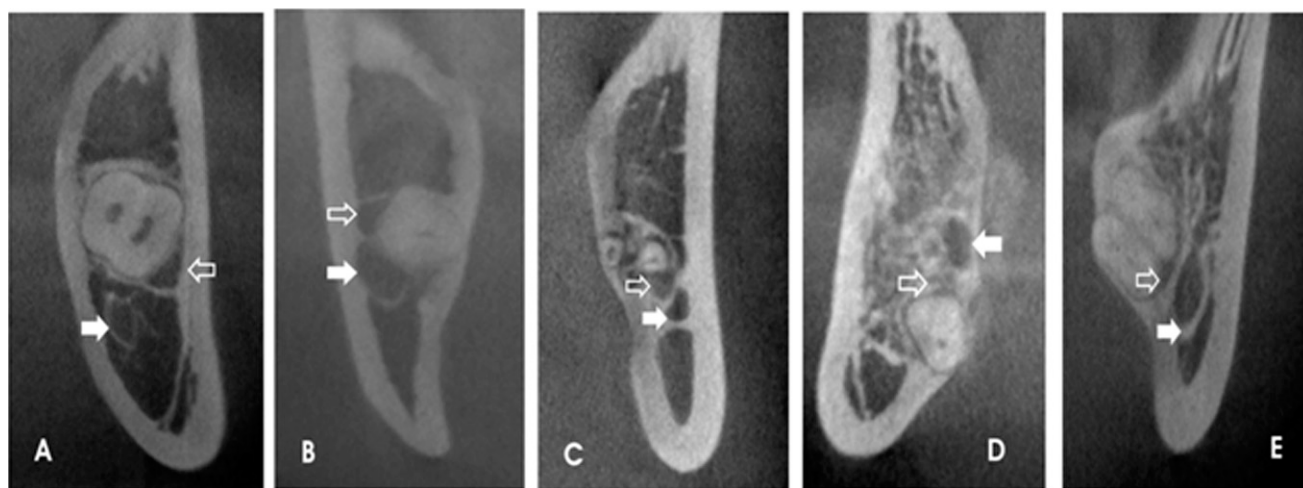


Figure 1 Positional relationship of juxta-apical radiolucency (JAR) (empty arrows) to mandibular canal (filled arrows) in the JAR group: (a) buccal, (b) superior, (c) central, (d) inferior and (e) lingual.

Table 2 Positional relationship of juxta-apical radiolucency (JAR)/apex of root with mandibular canal (% of cases)

Positions	JAR group	Control group
Buccal	30	26
Lingual	15	33
Inferior	15	30
Superior	29	0
Central/inter-radicular	11	11

cortical width in the area of JAR was measured. In the same image, the maximum cortical width was also measured to analyse the difference in the thinning, and the subjects were classified according to a proposed classification for thinning of the cortical plates (Table 1). In the control group, the same procedure was followed to measure the thinning of the cortical plate by either the root or the mandibular canal. Subsequently, the CBCT images in both the groups were evaluated for the presence or the absence of any perforation of the cortical plates.

The approval from the Ethical Committee of Showa University, Tokyo, Japan, was obtained for this study (No 2011-022).

Statistical analysis

The data collected were tabulated and analysed using the Statistical Package for the Social Sciences (SPSS® v. 17; SPSS Inc., Chicago, IL). The results obtained from the JAR group and control group were compared using a paired comparison by McNemar test. The level of significance was set at $p < 0.05$. However, interobserver or intraobserver reliability tests were not carried out, and a consensus was reached between both the examiners by viewing the images together for a final result.

Results

The position and relation of JAR and its relationship with the mandibular canal was visualized on CBCT images. The JAR was seen buccal to the mandibular canal in 30% of cases, superior to the mandibular canal in 29% cases, either lingual or inferior to the mandibular canal in 15% case and in-between the root and mandibular canal in 11% of cases (Figure 1, Table 2). In the control group, the apex

of the root was seen to be lingual to the mandibular canal in 33% cases, inferior in 30%, buccal in 26% and enclosing the mandibular canal in 11% of the cases (Figure 2, Table 2).

Thinning of either the buccal or lingual cortical plate was seen in 19 (70%) cases with JAR, whereas it was seen in only 10 (37%) cases in the control group. When the subjects were grouped according to the classification given in Table 1, it was seen that in the JAR group, 17 (63%) cases were in the J3 group, 9 (33%) in the J2 group and only 1 (4%) case in the J1 group (Figure 3, Table 3). For the control group, 15 (55.5%) cases were seen in the J2 group, 10 (37%) in the J3 group and 2 (7.5%) cases in the J1 group (Figure 4, Table 3). A statistically significant difference ($p < 0.05$) was seen, on comparison of the thinning of the cortical plate of the JAR and the control groups.

None of the patients in either the JAR or the control group showed perforation of the buccal and/or lingual cortical plate on CBCT images.

Discussion

Panoramic radiographic imaging is currently the most frequently employed technique to evaluate the risk of nerve injury following extraction of an impacted mandibular third molar. The risk of nerve injury is evaluated based on radiographic evidence of an intimate anatomic relationship between the third molar and the inferior alveolar nerve canal. Validation studies¹⁰ have shown that the panoramic radiograph as a test for nerve injury has a relatively low sensitivity (24%–38%) and a relatively high specificity (96%–98%). These studies indicate that, while there are discretely defined parameters on panoramic radiographs that are suggestive of nerve injury, only a minority of patients who sustain nerve injuries will have these signs. Conversely, the absence of these radiographic signs is of greater diagnostic utility for assuring a patient that they are at decreased risk for inferior alveolar nerve injury.¹⁰

Radiographic signs indicative of possible inferior alveolar nerve risk, as seen on panoramic radiographs include diversion of the canal, darkening of the root due

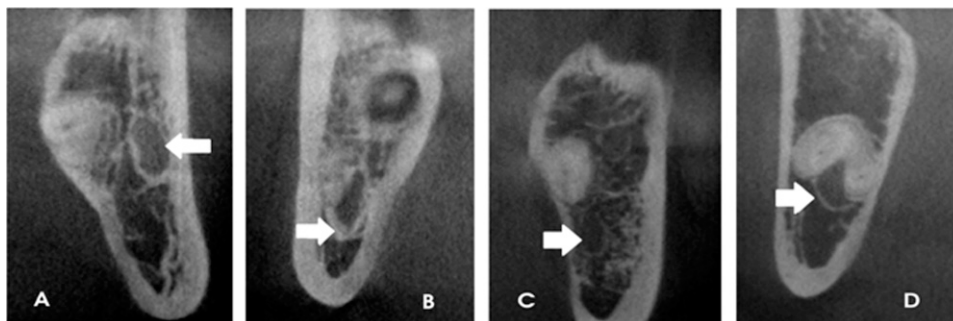


Figure 2 Positional relationship of apex of root with mandibular canal (arrows) in the control group: (a) lingual, (b) inferior, (c) buccal and (d) inter-radicular.

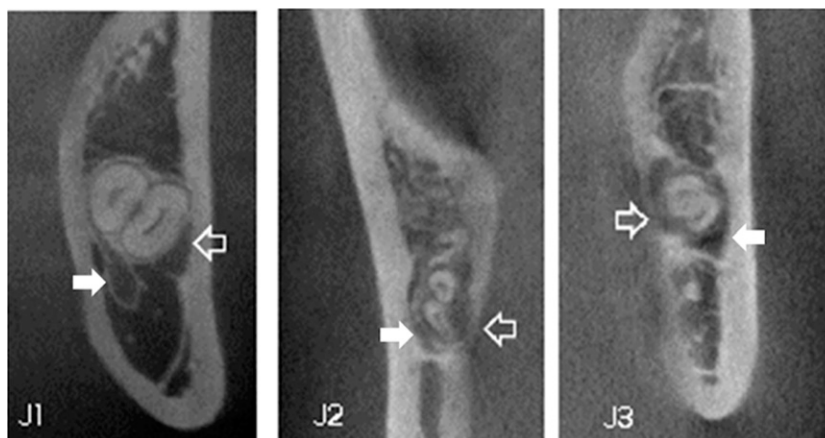

Figure 3 Classification of thinning of the cortical plates due to juxta-apical radiolucency (JAR) (empty arrows) in the JAR group. Solid arrows show the mandibular canal.

to superimposition of mandibular canal, deflection of the root, narrowing of the canal and interruption of the canal lamina dura.¹¹

However, there is no agreement on which of the radiographic signs described in the literature are the most reliable to show an anatomic relationship between the molar roots and the mandibular canal. The detection by CT of an intimate contact between the lower third molar roots and the mandibular canal has been associated with a higher risk of exposure of the neurovascular bundle during surgery and seems to be associated with a higher risk of inferior alveolar nerve injury. There are still no clear guidelines that can be used to indicate a CT/CBCT exploration for third molar extractions, and the debate is still open. Monaco *et al*⁴ recommended such exploration when there are two or more radiographic signs of proximity between the mandibular canal and the roots of the third molar and deep impaction and horizontal position of the third molar. There are more chances of inferior alveolar nerve injury in patients with “higher” mandibular canals (which could be classified as “deeper impaction”). Maegawa *et al*⁵ recommended CT examination when the panoramic radiograph shows the following conditions: (1) a root apex at the lower half or under the inferior wall of the mandibular canal; or (2) the white line, indicating the border of the mandibular canal is not seen clearly. However, Better *et al*¹² pointed out that the data obtained from CT scans have a minimal effect on the final surgical outcome or morbidity, and their routine use cannot be recommended. On the other hand, there is low positive-predictive value of the orthopantomogram in detecting patients at risk of inferior alveolar nerve injuries after the third molar extraction, as most patients classified as high risk based on orthopantomographic findings do not sustain such complications.¹³ It has been seen that direct exposure of the neurovascular bundle and/or a contact relationship between the tooth and the inferior alveolar nerve on CT increases the incidence of injury to the inferior alveolar nerve (IAN) by approximately 20%–30%.¹⁴

Recently, in a randomized controlled clinical trial,⁸ it was found that some radiographic signs may be more predictive of nerve injury than those of others. These include deviation of the canal at the apex of the root and the presence of JAR. In the trial, this new radiographic sign was seen as a well-circumscribed radiolucent area lateral to the root rather than to the apex.⁸ In another study, dysaesthesia was seen in a patient with the presence of pre-operative JAR, when subjected to coronectomy.⁹ Some studies have shown that this JAR is likely to be a continuity of the inferior alveolar nerve lamella with the periodontal lamina dura of the adjacent tooth.⁷ However, in the present study, we were able to clearly locate and differentiate the JAR and the mandibular canal, and there was no superimposition seen between the two.

We compared the relationship of JAR and the mandibular canal and cortical plates with control cases in the present study (Table 2). The JAR was seen most commonly buccally or superiorly in relation to the mandibular canal. A large percentage of cases showed cortical plate thinning in the JAR group as compared with the control group. Moreover, on comparing the cortical plate thinning in the two groups according to the proposed classification given in Table 1, it was seen that an increased number of cases showed cortical plate thinning in the JAR group as compared with the control group (Table 3). This greater amount of cortical

Table 3 Distribution of thinning of cortical plates according to the proposed classification (% of cases)

Classification	Juxta-apical radiolucency group	Control group
J1	4	7.5
J2	33	55.5 ^a
J3	63 ^a	37.0

^aStatistical difference: a higher number of patients in the control group showed cortical plate thinning of the J2 type; whereas a higher number of patients in the juxta-apical radiolucency group showed cortical plate thinning of the J3 type. This difference was statistically significant.

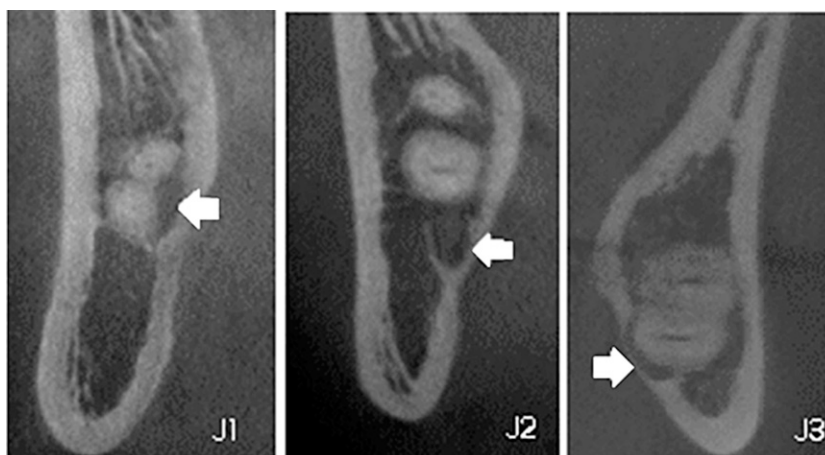


Figure 4 Classification of thinning of cortical plates due to mandibular canal (filled arrows) or roots in control group.

plate thinning in the JAR group might be one of the factors leading to an increased incidence of paraesthesia following extraction of the third molars in cases with JAR. The findings of the present study were contradictory to one study,⁶ where JAR was seen as a large anatomic cancellous bone space superimposed with the mandibular canal; thus, the image of JAR was created by the cancellous bony architecture rather than pathology.

Some future prospective studies using a large sample size should be carried out to evaluate the effect of JAR on the cortical plates and its possible role in post-

operative paraesthesia after the third molar extraction, as mentioned in some studies.⁷⁻⁹

In conclusion, based on the evaluation of the cortical plates, we were able to propose a classification to quantify the thinning of cortical plates, which may be used for objective evaluation of the thinning of the cortical plates in future studies. The present study gives an insight into the relationship of JAR with mandibular canal and cortical plates in the mandible using CBCT. However, future studies are warranted that use a larger sample size to validate the above findings.

References

- Harada N, Vasudeva SB, Joshi R, Seki K, Araki K, Matsuda Y, et al. Correlation between panoramic radiographic signs and high-risk anatomical factors for impacted mandibular third molars. *Oral Surgery* 2013; **6**: 129–36.
- Sedaghatfar M, August MA, Dodson TB. Panoramic radiographic findings as predictors of inferior alveolar nerve exposure following third molar extraction. *J Oral Maxillofac Surg* 2005; **63**: 3–7.
- Rood JP, Shehab BA. The radiological prediction of inferior alveolar nerve injury during third molar surgery. *Br J Oral Maxillofac Surg* 1990; **28**: 20–5.
- Monaco G, Montevocchi M, Bonetti GA, Gatto MR, Checchi L. Reliability of panoramic radiography in evaluating the topographic relationship between the mandibular canal and impacted third molars. *J Am Dent Assoc* 2004; **135**: 312–18.
- Maegawa H, Sano K, Kitagawa Y, Ogasawara T, Miyauchi K, Sekine J, et al. Preoperative assessment of the relationship between the mandibular third molar and the mandibular canal by axial computed tomography with coronal and sagittal reconstruction. *Oral Surg Oral Med Oral Pathol Oral Radiol Endod* 2003; **96**: 639–46.
- Umar G, Bryant C, Obisesan O, Rood JP. Correlation of the radiological predictive factors of inferior alveolar nerve injury with cone beam computed tomography findings. *Oral Surgery* 2010; **3**: 72–82.
- Renton T. Prevention of iatrogenic inferior alveolar nerve injuries in relation to dental procedures. *Dent Update* 2010; **37**: 350–63.
- Renton T, Hankins M, Sproate C, McGurk M. A randomised controlled clinical trial to compare the incidence of injury to the inferior alveolar nerve as a result of coronectomy and removal of mandibular third molars. *Br J Oral Maxillofac Surg* 2005; **43**: 7–12. doi: 10.1016/j.bjoms.2004.09.002
- Hatano Y, Kurita K, Kuroiwa Y, Yuasa H, Ariji E. Clinical evaluations of coronectomy (intentional partial odontectomy) for mandibular third molars using dental computed tomography: a case-control study. *J Oral Maxillofac Surg* 2009; **67**: 1806–14. doi: 10.1016/j.joms.2009.04.018
- Susarla SM, Dodson TB. Preoperative computed tomography imaging in the management of impacted mandibular third molars. *J Oral Maxillofac Surg* 2007; **65**: 83–8. doi: 10.1016/j.joms.2005.10.052
- Frafjord R, Renton T. A review of coronectomy. *Oral Surgery* 2010; **3**: 1–7.
- Better H, Abramovitz I, Shlomi B, Kahn A, Levy Y, Shaham A, et al. The presurgical workup before third molar surgery: how much is enough? *J Oral Maxillofac Surg* 2004; **62**: 689–92.
- Sanmartí-García G, Valmaseda-Castellón E, Gay-Escoda C. Does computed tomography prevent inferior alveolar nerve injuries caused by lower third molar removal? *J Oral Maxillofac Surg* 2012; **70**: 5–11.
- Nakamori K, Fujiwara K, Miyazaki A, Tomihara K, Tsuji M, Nakai M, et al. Clinical assessment of the relationship between the third molar and the inferior alveolar canal using panoramic images and computed tomography. *J Oral Maxillofac Surg* 2008; **66**: 2308–13. doi: 10.1016/j.joms.2008.06.042