

Prevalence of Radiographic Parameters Predisposing to Femoroacetabular Impingement in Young Asymptomatic Chinese and White Subjects

Jan Van Houcke, MD, Wan Pan Yau, MBBS, FRCSE, FHKAM, FHKCOS, Chun Hoi Yan, MBBS, FRCSE, FHKAM, FHKCOS, Wouter Huysse, MD, Hannes Dechamps, Wing Hang Lau, MBBS, FHKAM, Chun Sing Wong, MBChB, FRCR, FHKCR, FHKAM, Christophe Pattyn, MD, PhD, and Emmanuel Albert Audenaert, MD, PhD

Investigation performed at Ghent University Hospital, Ghent, Belgium, and Queen Mary Hospital, Hong Kong

Background: Osteoarthritis of the hip is five to ten times more common in white people than in Chinese people. Little is known about the true prevalence of femoroacetabular impingement or its role in the development of osteoarthritis in the Chinese population. A cross-sectional study of both white and Chinese asymptomatic individuals was conducted to compare the prevalences of radiographic features posing a risk for femoroacetabular impingement in the two groups. It was hypothesized that there would be proportional differences in hip anatomy between the white and Asian populations.

Methods: Pelvic computed tomography scans of 201 subjects (ninety-nine white Belgians and 102 Chinese; 105 men and ninety-six women) without hip pain who were eighteen to forty years of age were assessed. The original axial images were reformatted to three-dimensional pelvic models simulating standardized radiographic views. Ten radiographic parameters predisposing to femoroacetabular impingement were measured: alpha angle, anterior offset ratio, and caput-collum-diaphyseal angle on the femoral side and crossover sign, ischial spine projection, acetabular anteversion angle, center-edge angle, acetabular angle of Sharp, Tönnis angle, and anterior acetabular head index on the acetabular side.

Results: The white subjects had a less spherical femoral head than the Chinese subjects (average alpha angle, 56° compared with 50°; $p < 0.001$). The Chinese subjects had less lateral acetabular coverage than the white subjects, with average center-edge angles of 35° and 39° ($p < 0.001$) and acetabular angles of Sharp of 38° and 36° ($p < 0.001$), respectively. A shallower acetabular configuration was predominantly present in Chinese women.

Conclusions: Significant differences in hip anatomy were demonstrated between young asymptomatic Chinese and white subjects. However, the absolute size of the observed differences appears to contrast with the reported low prevalence of femoroacetabular impingement in Chinese individuals compared with the high prevalence in white populations.

Peer Review: This article was reviewed by the Editor-in-Chief and one Deputy Editor, and it underwent blinded review by two or more outside experts. It was also reviewed by an expert in methodology and statistics. The Deputy Editor reviewed each revision of the article, and it underwent a final review by the Editor-in-Chief prior to publication. Final corrections and clarifications occurred during one or more exchanges between the author(s) and copyeditors.

The concept of femoroacetabular impingement was first suggested by Ganz et al.¹ in 1991. Originally, the condition was identified as a long-term complication following femoral neck fractures, although this cause of impingement is rarer than idiopathic femoroacetabular impingement. Femoroacetabular impingement is defined as premature abut-

ment of the waist of the femoral neck against the anterior acetabular rim during repetitive high flexion movement leading to early labral and cartilage lesions of the hip^{2,3}. The premature impingement can be attributed to a decrease in femoral head sphericity (cam-type impingement) and/or increased overhang by the acetabular rim (pincer-type impingement)⁴⁻⁷. Although

Disclosure: One or more of the authors received payments or services, either directly or indirectly (i.e., via his or her institution), from a third party in support of an aspect of this work. None of the authors, or their institution(s), have had any financial relationship, in the thirty-six months prior to submission of this work, with any entity in the biomedical arena that could be perceived to influence or have the potential to influence what is written in this work. Also, no author has had any other relationships, or has engaged in any other activities, that could be perceived to influence or have the potential to influence what is written in this work. The complete **Disclosures of Potential Conflicts of Interest** submitted by authors are always provided with the online version of the article.

TABLE I Definition of Radiographic Parameters Used to Describe Variation in Hip Joint Morphology

Parameter	Definition	Value		Study
		Normal	Risk of Femoroacetabular Impingement	
Proximal part of femur				
CCD angle	Angle formed by the axis of the femoral neck and the proximal femoral diaphyseal axis (on anteroposterior view)	125°-135°	<125°	Tönnis and Heinecke ³⁰ (1999)
Alpha angle	Angle formed by the femoral neck axis and a line connecting the center of the femoral head with the point of beginning asphericity (on anteroposterior, cross-table lateral, or Dunn view)	<55°	>55°	Nötzli et al. ²⁸ (2002)
Anterior offset ratio	Ratio between the anterior offset and the maximal diameter of the femoral head. The anterior offset is the difference in radius between the anterior aspect of the femoral head and the anterior aspect of the femoral neck (on cross-table lateral view)	0.21 ± 0.03 in normal subjects; 0.13 ± 0.05 in patients with cam-type impingement	<0.13	Eijer et al. ²⁹ (2001)
Acetabulum				
Central acetabular anteversion	Angle between a line drawn between the anterior and posterior acetabular ridges and a reference line drawn perpendicular to a line between the posterior pelvic margins at the level of the sciatic notch—at the midpart of the femoral head (on axial CT slice)	15°-20°	<15°	Stem et al. ³¹ (2006)
Crossover sign	Present if the anterior rim runs more laterally in the most proximal part of the acetabulum and crosses the posterior rim distally (on anteroposterior view)	Anterior rim line projects medially to the posterior wall line	Anterior rim crosses the posterior rim	Reynolds et al. ³² (1999)
Ischial spine projection	Projection of the ischial spine into the pelvic cavity (on anteroposterior view)	No projection	Projection	Kalberer et al. ³³ (2008)
Center-edge angle	Angle formed by a line parallel to the longitudinal pelvic axis and by the line connecting the center of the femoral head with the lateral edge of the acetabulum (on anteroposterior view)	25°-45°	>45°	Wiberg ³⁴ (1939)
Acetabular angle of Sharp	Angle formed between a horizontal line and a line from the teardrop to the lateral acetabulum margin (on anteroposterior view)	33°-38°	<33°	Sharp ³⁵ (1961)
Tönnis angle	Angle formed between a horizontal line and a line extending from the medial to the lateral edge of the sourcil (on anteroposterior view)	5°-15°	<5°	Tönnis and Brunken ³⁶ (1968)

continued

TABLE I (continued)

Parameter	Definition	Value		
		Normal	Risk of Femoroacetabular Impingement	Study
Anterior acetabular head index	Ratio between a horizontal line drawn from the most posterior aspect of the femoral head to the anterior aspect of the acetabulum and a horizontal line drawn from the most posterior aspect of the femoral head to the most anterior aspect of the head (on false-profile view)	0.841 ± 0.062	>0.9	Chosa and Tajima ³⁷ (2003)

osseous abutment at the end of the hip range of motion can be normal and asymptomatic⁸, it may occur earlier and to a greater degree in patients with femoroacetabular impingement morphology, with possible progression to a symptomatic femoroacetabular impingement syndrome. This condition is hypothesized to be a likely cause of hip osteoarthritis in white young adults^{4,9,10}.

Hip osteoarthritis has a heterogeneous geographic distribution, with the prevalence in white populations approximately five to ten times higher than that in Chinese people of the same age and sex^{11,12}. This racial variation in osteoarthritis prevalence is demonstrated by the much higher rate of total hip replacements in white individuals. Studies have revealed that the rate of total hip replacement for primary osteoarthritis in white patients is as much as twenty times the rate for Chinese^{13,14}. Whereas most cases of hip osteoarthritis in white populations are considered primary and possibly related to femoroacetabular impingement^{4,9,10,15-17}, in Chinese patients hip osteoarthritis is nearly always secondary to congenital hip disease, in particular developmental dysplasia of the hip^{18,19}. Little is known about the true prevalence of femoroacetabular impingement in the Chinese population, and even the value of current evidence on the contribution of femoroacetabular impingement to the development of hip osteoarthritis in general has been challenged by some²⁰. For example, compared with a rather moderate prevalence of hip osteoarthritis of 5% to 10% in white people, the reported prevalence of radiographic characteristics posing a risk of femoroacetabular impingement in studies of white subjects seems to be substantially larger, ranging from 17% to 48% in men and 4% to 31% in women²¹⁻²⁶.

We are aware of only one study comparing the prevalences of radiographic features related to femoroacetabular impingement between Chinese and white patients (women)²⁷. Therefore, we conducted a cross-sectional study of asymptomatic individuals of both races with use of multidetector computed tomography (CT). We hypothesized that there would be significant differences in the anatomy of the proximal part of the femur and the acetabulum between the two populations with regard to the well-known radiographic parameters of femoroacetabular impingement. It was further hypothesized that there would be significant differences in the number of radiographic signs

predisposing to femoroacetabular impingement in asymptomatic individuals in the two groups.

Materials and Methods

A cross-sectional study was designed to prospectively collect pelvic multidetector CT scans of subjects at the radiology departments of Ghent University Hospital and the University of Hong Kong from September 1, 2011, to January 31, 2013. The selected CT scans were of subjects with abdominal trauma or abdominal pain requiring further investigation for diagnosis. The subjects were not exposed to additional radiation for the study, which was approved by the local ethics committee of both universities.

First, the minimal sample size was determined on the basis of an estimated difference in alpha angle of 5° between the two racial groups. An average anterolateral alpha angle of 50° (standard deviation [SD] = 8°) had previously been reported in an observational study of 200 asymptomatic white subjects by Hack et al.²⁶. The sample size calculation was performed with the assumption of a type-I error of 0.05, a type-II error of 0.2, an estimated difference of 5°, and an SD of 8°. The minimal number of hips to be included in each racial group was calculated to be forty-one hips.

Subjects undergoing a pelvic CT scan for nonorthopaedic reasons were included in the study if they reported an unremarkable hip history and if they were between eighteen and forty years of age. A total of 202 subjects met these initial criteria. One patient in whom osteonecrosis with collapse of the femoral head was noted on CT was excluded, leaving 201 subjects (402 hips), ninety-nine (fifty-eight men and forty-one women) of whom were white and 102 (forty-seven men and fifty-five women) of whom were Chinese. The average ages of the racial and sex subgroups ranged from thirty to thirty-three years (see Appendix). The absolute exclusion criteria were (1) any history of hip pain mentioned by the patient; (2) evidence of hip surgery on imaging; or (3) a history or radiographic evidence of osteoarthritis of the hip, previous hip fracture, Legg-Calvé-Perthes disease, slipped capital femoral epiphysis, congenital hip dysplasia, or arthropathies capable of causing secondary alterations to the hip joint.

CT scanning was performed in a standardized fashion at 120 kVp with use of dose modulation with a sixty-four-slice multidetector CT scanner. The data sets consisted of slices of ≤1 mm in thickness at ≤0.7-mm increments depicting the pelvis and proximal parts of the femora, including the lesser trochanters.

Ten radiographic parameters predisposing to cam or pincer-type femoroacetabular impingement were measured. These included three parameters of proximal femoral morphology (alpha angle^{28,29}, anterior offset ratio²⁹, and caput-collum-diaphyseal [CCD] angle³⁰), three parameters of acetabular orientation (central acetabular anteversion angle³¹, crossover sign³², and ischial spine projection³³), and four parameters of acetabular coverage (center-edge angle of Wiberg³⁴, acetabular angle of Sharp³⁵, Tönnis angle³⁶, and anterior acetabular head index³⁷). The definition and normal values of these radiographic

TABLE II Differences in Continuous Radiographic Parameters Predisposing Chinese and White Subjects, Classified by Sex, to Femoroacetabular Impingement*

Radiographic Parameter	Chinese Men† (N = 94 Hips)	White Men† (N = 116 Hips)	P Value‡	Chinese Women† (N = 110 Hips)	White Women† (N = 82 Hips)	P Value‡
Femur (deg)						
Alpha angle: 1:30 o'clock	52 (50-54)	56 (54-58)	0.01	49 (48-50)	56 (53-59)	<0.001
Anterior offset ratio	0.19 (0.18-0.20)	0.19 (0.18-0.20)	NS	0.21 (0.20-0.21)	0.19 (0.19-0.20)	0.038
CCD angle	131 (130-132)	127 (126-128)	<0.001	132 (131-133)	132 (131-133)	NS
Acetabulum						
Central acetabular anteversion (deg)	18 (17-19)	19 (18-20)	NS	21 (20-22)	21 (20-22)	NS
Center-edge angle (deg)	37 (36-38)	40 (38-42)	0.006	33 (32-34)	38 (36-40)	<0.001
Acetabular angle of Sharp (deg)	37 (37-38)	35 (34-36)	<0.001	38 (38-39)	36 (35-37)	<0.001
Tönnis angle (deg)	9.6 (9.1-10.0)	10.7 (10.3-11.0)	<0.001	11.7 (9.6-13.8)	10.9 (10.5-11.3)	NS
Acetabular head index	0.90 (0.89-0.91)	0.88 (0.87-0.89)	NS	0.90 (0.89-0.91)	0.89 (0.88-0.90)	NS

*The crossover sign and ischial spine projection are shown in Table III. †The values are given as the mean and 95% confidence interval. ‡NS = not significant.

parameters are summarized in Table I. The techniques for measurement of each parameter are illustrated in figures in the Appendix.

All of these parameters were originally measured on radiographs, except for the acetabular anteversion angle, for which the original axial CT images were reformatted with use of the Mimics 15.01 software package (Materialise, Leuven, Belgium). The following reconstructions were made for each subject (see Appendix): a transparent three-dimensional rotational model simulating the anteroposterior pelvic view with pelvic tilt standardized as described by Siebenrock et al.³⁸—i.e., with a pubic symphysis-to-sacrococcygeal joint distance of approximately 32 mm in men and 47 mm in women; oblique, coronal, and axial views along the axis of the femoral neck for each hip; an orthogonal axial view of the pelvis at the level of the sciatic notch where the acetabulum is the deepest; and a lateral view of each hip joint with the pelvis at an angle of 65°, simulating the false profile.

The data were analyzed with use of the SPSS software package (version 20; IBM, Armonk, New York). The morphometric parameters were analyzed as dependent variables, while the independent variable was the racial group subdivided according to sex. Continuous data (alpha angle, anterior offset ratio, CCD angle, acetabular version, center-edge angle, acetabular angle of Sharp, Tönnis angle, and anterior acetabular head index) of men and women separately were compared between Chinese and white subjects with use of the independent t test. The standard assumptions for normality of distribution were met by means of the Shapiro-Wilk test and evaluation of the quantile-quantile (Q-Q) plot. The homogeneity of variances was assessed with use of the Levene test. The remaining two variables, the crossover sign and ischial spine projection, were categorical and were evaluated by means of the chi-square test.

TABLE III Prevalence of Radiographic Parameters Predisposing Chinese and White Subjects, Classified by Sex, to Femoroacetabular Impingement

Radiographic Parameter*	% of Hips with Parameter*		P Value‡	% of Hips with Parameter*		P Value‡
	Chinese Men† (N = 94 Hips)	White Men† (N = 116 Hips)		Chinese Women† (N = 110 Hips)	White Women† (N = 82 Hips)	
Femur						
Alpha angle: 1:30 o'clock	22 (14-31)	34 (25-42)	NS	15 (8-21)	32 (21-42)	0.004
Anterior offset ratio	1 (0-3)	4 (1-8)	NS	2 (0-4)	2 (0-6)	NS
CCD angle	15 (8-22)	28 (20-37)	0.019	11 (5-17)	4 (0-8)	NS
Acetabulum						
Central acetabular anteversion	32 (22-42)	16 (9-22)	0.005	13 (6-19)	11 (4-18)	NS
Crossover sign	12 (5-19)	41 (32-50)	<0.001	2 (0-5)	16 (8-24)	<0.001
Ischial spine projection	33 (23-43)	29 (21-37)	NS	6 (2-10)	12 (5-19)	NS
Center-edge angle	15 (18-22)	19 (12-26)	NS	3 (0-6)	13 (6-21)	0.005
Acetabular angle of Sharp	4 (0-8)	16 (10-23)	0.005	2 (0-4)	7 (2-13)	NS
Tönnis angle	7 (2-13)	2 (0-4)	NS	1 (0-3)	0	NS
Acetabular head index	52 (42-62)	38 (29-47)	0.039	51 (41-60)	28 (18-36)	0.001

*The eight continuous variables were converted to binary ones, with hips classified as "at risk for femoroacetabular impingement" when the value exceeded the normal range indicated in the literature. The crossover sign and ischial spine projection are binary variables. †The values are given as the prevalence and 95% confidence interval. ‡NS = not significant.

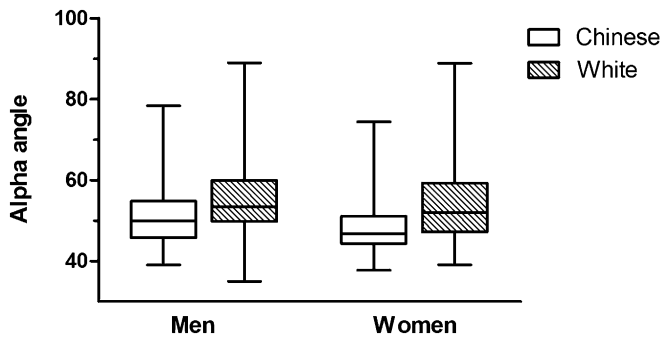


Fig. 1
Box-and-whisker plot of the measured alpha angle in the hips of Chinese and white subjects classified by sex. The top and bottom of the box represent the interquartile range, the horizontal line in each box represents the median, and the whiskers represent the minimum and maximum.

The eight continuous radiographic parameters were also converted to dichotomous variables on the basis of cutoff values that imply the risk of femoroacetabular impingement. The prevalence of these radiographic signs in asymptomatic Chinese and white men and women was evaluated by using the chi-square test.

Two observers (J.V.H. and H.D.) performed all of the radiographic measurements on anonymized imaging files. Both observers each repeated the measurements on forty-eight hips one week later to obtain test-retest data. The interobserver and intraobserver reliability was evaluated by using the intraclass correlation coefficient (ICC).

The level of significance for all tests was set at $\alpha = 0.05$.

Source of Funding

Two authors (E.A.A. and J.V.H.) were supported by the Research Foundation-Flanders (FWO).

Results

The ICC for interobserver and intraobserver reliability showed an agreement of more than 80% for most parameters, indicating strong reliability. The Tönnis angle, anterior offset ratio, anterolateral alpha angle, and acetabular angle of Sharp showed moderate agreement for interobserver reliability (ICC, 72% to 78%) (see Appendix).

Proximal Part of the Femur

The average alpha angle over the anterolateral aspect of the femoral neck (at the 1:30 o'clock position) was significantly larger in white subjects (56° in both white men and white women compared with 52° in Chinese men and 49° in Chinese women; $p = 0.01$ and $p < 0.001$) (Fig. 1 and Table II). The femoral neck had a more pronounced varus configuration in white men, with an average CCD angle of 127° compared with 131° in Chinese men ($p < 0.001$). The anterior offset ratio was significantly higher in Chinese women (0.21 compared with 0.19 in white women; $p = 0.038$).

Twenty-four percent of the hip joints in the Chinese subjects (31% of those in the Chinese men and 17% of those in the Chinese women) compared with 40% of the hip joints in the white subjects (41% of those in the white men and 39% of those in the white women) had an aspherical femoral head at the head-neck junction ($p < 0.001$) (see Appendix). Asphericity

of the femoral head was defined as an anterior, anterolateral, or lateral alpha angle that exceeded 55° in at least one of these three planes. Thirty-four percent of the Chinese subjects and 56% of the white subjects had an aspherical femoral head in one or both hips ($p < 0.001$). Elevated alpha angles were most common at the 1:30 o'clock (anterolateral) position in both racial groups and were present in 33% of the hips in the white subjects (34% of those in the white men and 32% of those in the white women) compared with just 18% of the hips in the Chinese subjects (22% of those in the Chinese men and 15% of those in the Chinese women) ($p = 0.001$) (Table III).

Acetabulum

The acetabula of the Chinese subjects appeared more shallow in the coronal plane, with a mean center-edge angle of 37° in Chinese men compared with 40° in white men ($p = 0.006$) and 33° in Chinese women compared with 38° in white women ($p < 0.00$) (Fig. 2). The acetabular angle of Sharp averaged 37° in Chinese men and 35° in white men ($p < 0.001$) and 38° in Chinese women and 36° in white women ($p < 0.001$). The Tönnis angle was significantly lower in Chinese men than in white men ($p < 0.001$) (Table II).

Increased center-edge angles, indicative of acetabular overcoverage, were significantly more prevalent in white women than in Chinese women (13% of the hips compared with 3%; $p = 0.005$). The prevalence of a decreased acetabular angle of Sharp, also indicative of acetabular overcoverage, was significantly higher in white men than in Chinese men (16% of the hips compared with 4%; $p = 0.005$). The central acetabular version angle indicated a tendency toward retroversion in 32% of the hips of Chinese men compared with 16% of those of the white men ($p = 0.005$). However, the crossover sign was more prevalent in both white men and white women (41% and 16% of the hips, respectively, compared with 12% and 2% in the Chinese group; $p < 0.001$). Overcoverage at the anterior acetabular rim, based on the anterior acetabular head index, was present in 52% of the hips of Chinese men compared with 38% of those of white men ($p = 0.039$) and in 51% of the hips of Chinese women compared with 28% of those of white women ($p = 0.00$) (Table III).

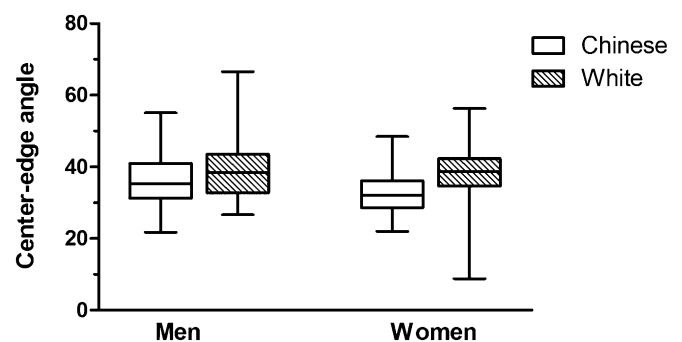


Fig. 2
Box-and-whisker plot of the measured center-edge angle in the hips of Chinese and white subjects classified by sex. The box represents the interquartile range, the horizontal line in each box represents the median, and the whiskers represent the minimum and maximum.

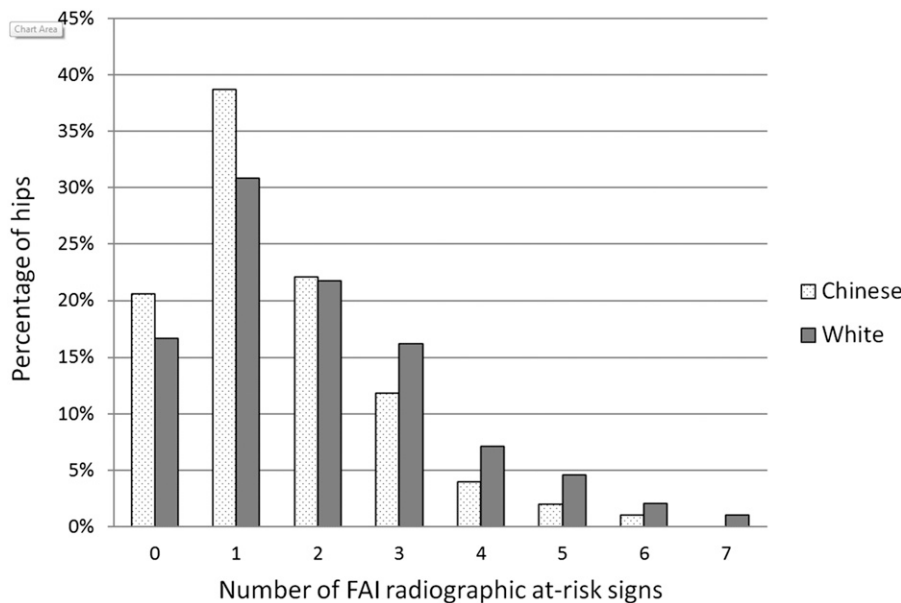


Fig. 3 Percentages of hips in Chinese subjects compared with those in white subjects as a function of the number of femoroacetabular impingement (FAI) at-risk signs. All ten morphometric variables were taken into account: two categorical radiographic parameters (the crossover and ischial spine signs) and eight continuous variables that were converted into dichotomous variables by selecting the subjects who had a value exceeding the normal range.

Signs Predisposing to Femoroacetabular Impingement

There were at least two or more radiographic signs of a risk of femoroacetabular impingement in 41% of the hips of the Chinese subjects compared with 53% of the hips of the white subjects ($p = 0.017$) (Fig. 3).

Discussion

The current study demonstrates that the proximal part of the femur tends toward more varus in white men and generally has a less spherical femoral head in white subjects. On the other hand, Chinese people, and especially Chinese women, clearly possess a shallower acetabulum. The prevalence of radiographic signs indicating a risk of femoroacetabular impingement was significantly higher in white subjects than in Chinese subjects. However, the absolute size of the observed differences appears to contrast with the reported low prevalence of femoroacetabular impingement in Chinese people compared with the high number of impingement cases diagnosed in white populations as well as with the significantly lower prevalence of hip osteoarthritis in Chinese people^{13,14,20}. This finding suggests that some of the current radiographic concepts directly linking femoroacetabular impingement morphology to actual impingement syndrome and the development of hip osteoarthritis may need to be revised.

We believe that this study is the first to comprehensively compare, with use of multidetector CT, the morphology of the proximal part of the femur and the acetabulum between asymptomatic young Chinese and white subjects in a large sample. To our knowledge, the only study comparing hip joint morphology between Chinese and white subjects (women) was performed by Dudda et al.²⁷, who used anteroposterior radiographs. They reported that the white female population had

significant increases in lateral overcoverage (average center-edge angle, 30.4° compared with 25.5°) and femoral head asphericity (average impingement angle, 83.6° compared with 87°), findings that agree with our results.

We included three parameters for the evaluation of the occurrence of acetabular retroversion in the racial groups: a decreased central acetabular anteversion angle ($<15^\circ$), the crossover sign, and ischial spine projection^{31-33,39}. We found that the prevalence of hips with a decreased acetabular anteversion angle was significantly higher in Chinese subjects (22% compared with 13% in white subjects), whereas the crossover sign was more prevalent in white subjects (30% compared with 6%). The ischial spine projection showed no significant difference in racial prevalence. The acetabular anteversion angle in this study was measured according to the method described by Stem et al.³¹, at the midfemoral head level on the axial CT slices, whereas Reynolds et al.³² claimed that measurement of acetabular version at the superior part of the acetabulum was of greater value. With acetabular retroversion, the version angle is decreased at both levels, albeit less so at the midfemoral level³². The measurement of central—instead of superior—acetabular anteversion can be considered a limitation; however, it does not sufficiently explain the observed inverse relationship between the crossover sign and the acetabular anteversion angle. This contradiction might be due to a low reliability of the crossover sign in the diagnosis of acetabular retroversion, as debated in recent studies^{40,41}.

The prevalence of radiographic evidence of hip osteoarthritis is $\geq 5\%$ in white people compared with barely 1% in Chinese people (sixty to seventy-four years of age)^{11,42}. Symptomatic hip osteoarthritis in the Chinese population is as low as

0.3% (in patients fifty-five years of age or older¹²). However, the prevalences of hand¹² and knee⁴³ osteoarthritis are rather similar between the two racial populations. Knee arthrosis is even more prevalent in Chinese women than in white women. These contradictory findings in different joint types make it less probable that genetic mutations of general articular cartilage metabolism are responsible for the observed differences in the prevalence of hip osteoarthritis between races. Nevertheless, genetic factors may help provide an explanation, since hip osteoarthritis has a reported odds ratio of 6.4 in siblings^{44,45}. It is possible that inheritance of anatomic variants that predispose to hip osteoarthritis contributes to such familial clustering¹¹.

Recent studies suggest that acetabular overcoverage and femoral head asphericity contribute to the development of hip osteoarthritis^{4,9,14-16}. Our findings confirmed a higher prevalence of lateral acetabular overcoverage and osseous bumps in white subjects compared with Chinese subjects, a finding that agrees with those of previous studies^{27,46}. However, the absolute difference in these values is not in proportion to the difference in the prevalence of hip osteoarthritis. Thus, our finding provides little additional evidence that femoroacetabular impingement plays a role in the development of hip osteoarthritis in white populations. Clearly, femoroacetabular impingement is a dynamic condition, with the radiographic features merely risk factors predisposing to the actual development of a true impingement syndrome. The present study was not designed to describe the epidemiology of impingement syndrome. We can conclude only that additional work seems to be required to establish the variables that differentiate individuals with radiographic variation from those who will develop clinical symptoms or even articular cartilage defects.

The current study had limitations. First, the selected sample consisted of young individuals requiring pelvic CT scans for nonorthopaedic reasons, which is probably not a true representation of the general population. However, it would be difficult and probably unethical to recruit healthy volunteers to undergo pelvic CT scans for purely research purposes. Furthermore, the bias toward younger subjects is actually a strength rather than a limitation of our study. If femoroacetabular impingement morphology is actually a risk factor for later hip osteoarthritis, the risk factor should be present before the onset of osteoarthritis. In older people (commonly the subjects of studies in the literature), early osteophytes are often misinterpreted as representing proximal femoral asphericity or acetabular overcoverage. A second limitation of this study is that, although the hips were asymptomatic, they did not undergo an actual physical examination. It is not actually known whether the recruited subjects were truly free of impingement signs, despite the fact that none of them reported previous hip symptoms. Third, femoral anteversion was not measured. It has been documented that decreased femoral anteversion adds to the risk of femoroacetabular impingement^{47,48}. However, measuring femoral torsion requires scans made through the femoral condyles, which was impractical for the study protocol. Fourth, some of the cutoff values

for defining the femoroacetabular impingement risk factors adopted in this study (summarized in Table I) might be considered arbitrary. Although the current literature suggests that these risk factors for femoroacetabular impingement might contribute to the pathogenesis of femoroacetabular impingement syndrome, the exact values associated with the development of femoroacetabular impingement have not yet been established. We believe, however, that it is the overall morphology of the hip in terms of specific combinations of anatomical abnormalities, combined with an increased activity level, that gives rise to femoroacetabular impingement.

In conclusion, this study showed that Chinese and white subjects differ significantly with regard to hip anatomy: the proximal part of the femur tends more toward varus in white men and has a less spherical femoral head in white subjects, whereas the acetabulum is more shallow in Chinese subjects. The prevalence of radiographic signs associated with a risk of the development of femoroacetabular impingement was significantly higher in white subjects than in Chinese subjects. The observed absolute differences between the two racial groups, however, appeared too small to explain the reported differences in the prevalence of hip osteoarthritis. This finding seems to suggest that femoroacetabular impingement morphology is probably at most a secondary risk factor for the development of hip osteoarthritis, at least in the Chinese population. Future work should focus on further investigating the cause for this contradictory finding.

Appendix

eA Tables showing the ages of the subgroups as well as the interobserver and intraobserver repeatability of measurements of the radiographic parameters and figures demonstrating techniques for measuring the radiographic parameters are available with the online version of this article as a data supplement at jbjs.org. ■

Jan Van Houcke, MD
Wouter Huyse, MD
Hannes Dechamps
Christophe Pattyn, MD, PhD
Emmanuel Albert Audenaert, MD, PhD
Departments of Orthopaedic Surgery and
Traumatology (J.V.H., H.D., C.P., and E.A.A.) and
Radiology (W.H.), Ghent University Hospital,
De Pintelaan 185, B-9000 Ghent, Belgium.
E-mail address for E.A. Audenaert: emmanuel.audenaert@ugent.be

Wan Pan Yau, MBBS, FRCSE, FHKAM, FHKCOS
Chun Hoi Yan, MBBS, FRCSE, FHKAM, FHKCOS
Wing Hang Lau, MBBS, FHKAM
Chun Sing Wong, MBChB, FRCS, FHKCR, FHKAM
Departments of Orthopaedic Surgery and
Traumatology (W.P.Y. and C.H.Y.) and
Radiology (W.H.L. and C.S.W.),
Queen Mary Hospital,
University of Hong Kong,
102 Pokfulam Road,
Hong Kong, China

References

1. Ganz R, Bamert P, Hausner P, Isler B, Vreva F. [Cervico-acetabular impingement after femoral neck fracture]. *Unfallchirurg*. 1991 Apr;94(4):172-5.
2. Ito K, Minka MA 2nd, Leunig M, Werlen S, Ganz R. Femoroacetabular impingement and the cam-effect. A MRI-based quantitative anatomical study of the femoral head-neck offset. *J Bone Joint Surg Br*. 2001 Mar;83(2):171-6.
3. Laude F, Boyer T, Nogier A. Anterior femoroacetabular impingement. *Joint Bone Spine*. 2007 Mar;74(2):127-32. Epub 2007 Feb 5.
4. Ganz R, Parvizi J, Beck M, Leunig M, Nötzli H, Siebenrock KA. Femoroacetabular impingement: a cause for osteoarthritis of the hip. *Clin Orthop Relat Res*. 2003 Dec; (417):112-20.
5. Kassarian A, Brisson M, Palmer WE. Femoroacetabular impingement. *Eur J Radiol*. 2007 Jul;63(1):29-35. Epub 2007 May 7.
6. Lavigne M, Parvizi J, Beck M, Siebenrock KA, Ganz R, Leunig M. Anterior femoroacetabular impingement: part I. Techniques of joint preserving surgery. *Clin Orthop Relat Res*. 2004 Jan;(418):61-6.
7. Tannast M, Siebenrock KA, Anderson SE. Femoroacetabular impingement: radiographic diagnosis—what the radiologist should know. *AJR Am J Roentgenol*. 2007 Jun;188(6):1540-52.
8. Yamamura M, Miki H, Nakamura N, Murai M, Yoshikawa H, Sugano N. Open-configuration MRI study of femoro-acetabular impingement. *J Orthop Res*. 2007 Dec;25(12):1582-8.
9. Ganz R, Leunig M, Leunig-Ganz K, Harris WH. The etiology of osteoarthritis of the hip: an integrated mechanical concept. *Clin Orthop Relat Res*. 2008 Feb;466 (2):264-72. Epub 2008 Jan 10.
10. Reid GD, Reid CG, Widmer N, Munk PL. Femoroacetabular impingement syndrome: an underrecognized cause of hip pain and premature osteoarthritis? *J Rheumatol*. 2010 Jul;37(7):1395-404. Epub 2010 Jun 1.
11. Nevitt MC, Xu L, Zhang Y, Lui LY, Yu W, Lane NE, Qin M, Hochberg MC, Cummings SR, Felson DT. Very low prevalence of hip osteoarthritis among Chinese elderly in Beijing, China, compared with whites in the United States: the Beijing osteoarthritis study. *Arthritis Rheum*. 2002 Jul;46(7):1773-9.
12. Hoaglund FT, Yau AC, Wong WL. Osteoarthritis of the hip and other joints in southern Chinese in Hong Kong. *J Bone Joint Surg Am*. 1973 Apr;55(3):545-57.
13. Hoaglund FT, Oishi CS, Gialamas GG. Extreme variations in racial rates of total hip arthroplasty for primary coxarthrosis: a population-based study in San Francisco. *Ann Rheum Dis*. 1995 Feb;54(2):107-10.
14. Oishi CS, Hoaglund FT, Gordon L, Ross PD. Total hip replacement rates are higher among Caucasians than Asians in Hawaii. *Clin Orthop Relat Res*. 1998 Aug; (353):166-74.
15. Bardakos NV, Villar RN. Predictors of progression of osteoarthritis in femoroacetabular impingement: a radiological study with a minimum of ten years follow-up. *J Bone Joint Surg Br*. 2009 Feb;91(2):162-9.
16. Beck M, Kalhor M, Leunig M, Ganz R. Hip morphology influences the pattern of damage to the acetabular cartilage: femoroacetabular impingement as a cause of early osteoarthritis of the hip. *J Bone Joint Surg Br*. 2005 Jul;87(7):1012-8.
17. Doherty M, Courtney P, Doherty S, Jenkins W, Maciewicz RA, Muir K, Zhang W. Nonspherical femoral head shape (pistol grip deformity), neck shaft angle, and risk of hip osteoarthritis: a case-control study. *Arthritis Rheum*. 2008 Oct;58(10):3172-82.
18. Hoaglund FT, Shiba R, Newberg AH, Leung KYK. Diseases of the hip. A comparative study of Japanese Oriental and American white patients. *J Bone Joint Surg Am*. 1985 Dec;67(9):1376-83.
19. Takeyama A, Naito M, Shiramizu K, Kiyama T. Prevalence of femoroacetabular impingement in Asian patients with osteoarthritis of the hip. *Int Orthop*. 2009 Oct;33 (5):1229-32. Epub 2009 Mar 11.
20. Rubin DA. Femoroacetabular impingement: fact, fiction, or fantasy? *AJR Am J Roentgenol*. 2013 Sep;201(3):526-34.
21. Gosvig KK, Jacobsen S, Sonne-Holm S, Gebuhr P. The prevalence of cam-type deformity of the hip joint: a survey of 4151 subjects of the Copenhagen Osteoarthritis Study. *Acta Radiol*. 2008 May;49(4):436-41.
22. Kang ACL, Gooding AJ, Coates MH, Goh TD, Armour P, Rietveld J. Computed tomography assessment of hip joints in asymptomatic individuals in relation to femoroacetabular impingement. *Am J Sports Med*. 2010 Jun;38(6):1160-5. Epub 2010 Mar 12.
23. Laborie LB, Lehmann TG, Engesaeter IØ, Eastwood DM, Engesaeter LB, Rosendahl K. Prevalence of radiographic findings thought to be associated with femoroacetabular impingement in a population-based cohort of 2081 healthy young adults. *Radiology*. 2011 Aug;260(2):494-502. Epub 2011 May 25.
24. Jung KA, Restrepo C, Hellman M, AbdelSalam H, Morrison W, Parvizi J. The prevalence of cam-type femoroacetabular deformity in asymptomatic adults. *J Bone Joint Surg Br*. 2011 Oct;93(10):1303-7.
25. Reichenbach S, Jüni P, Werlen S, Nüesch E, Pfirrmann CW, Trelle S, Odermatt A, Hofstetter W, Ganz R, Leunig M. Prevalence of cam-type deformity on hip magnetic resonance imaging in young males: a cross-sectional study. *Arthritis Care Res (Hoboken)*. 2010 Sep;62(9):1319-27.
26. Hack K, Di Primio G, Rakhra K, Beaulé PE. Prevalence of cam-type femoroacetabular impingement morphology in asymptomatic volunteers. *J Bone Joint Surg Am*. 2010 Oct 20;92(14):2436-44.
27. Dudda M, Kim YJ, Zhang Y, Nevitt MC, Xu L, Niu J, Goggins J, Doherty M, Felson DT. Morphologic differences between the hips of Chinese women and white women: could they account for the ethnic difference in the prevalence of hip osteoarthritis? *Arthritis Rheum*. 2011 Oct;63(10):2992-9.
28. Nötzli HP, Wyss TF, Stoecklin CH, Schmid MR, Treiber K, Hodler J. The contour of the femoral head-neck junction as a predictor for the risk of anterior impingement. *J Bone Joint Surg Br*. 2002 May;84(4):556-60.
29. Eijer H, Leunig M, Mahomed M, Ganz R. Crosstable lateral radiograph for screening of anterior femoral head-neck offset in patients with femoro-acetabular impingement. *Hip Int*. 2001;11:37-41.
30. Tönnis D, Heinecke A. Acetabular and femoral anteversion: relationship with osteoarthritis of the hip. *J Bone Joint Surg Am*. 1999 Dec;81(12): 1747-70.
31. Stem ES, O'Connor MI, Kransdorf MJ, Crook J. Computed tomography analysis of acetabular anteversion and abduction. *Skeletal Radiol*. 2006 Jun;35(6):385-9. Epub 2006 Mar 29.
32. Reynolds D, Lucas J, Klaue K. Retroversion of the acetabulum. A cause of hip pain. *J Bone Joint Surg Br*. 1999 Mar;81(2):281-8.
33. Kalberer F, Sierra RJ, Madan SS, Ganz R, Leunig M. Ischial spine projection into the pelvis: a new sign for acetabular retroversion. *Clin Orthop Relat Res*. 2008 Mar;466(3):677-83. Epub 2008 Feb 10.
34. Wiberg G. The anatomy and roentgenographic appearance of a normal hip joint. *Acta Chir Scand Suppl*. 1939;83:7-38.
35. Sharp IK. Acetabular dysplasia: the acetabular angle. *J Bone Joint Surg Br*. 1961;43(2):268-72.
36. Tönnis D, Brunken D. [Differentiation of normal and pathological acetabular roof angle in the diagnosis of hip dysplasia. Evaluation of 2294 acetabular roof angles of hip joints in children]. *Arch Orthop Unfallchir*. 1968;64(3): 197-228.
37. Chosa E, Tajima N. Anterior acetabular head index of the hip on false-profile views. New index of anterior acetabular cover. *J Bone Joint Surg Br*. 2003 Aug; 85(6):826-9.
38. Siebenrock KA, Kalbermatten DF, Ganz R. Effect of pelvic tilt on acetabular retroversion: a study of pelves from cadavers. *Clin Orthop Relat Res*. 2003 Feb; (407):241-8.
39. Murray DW. The definition and measurement of acetabular orientation. *J Bone Joint Surg Br*. 1993 Mar;75(2):228-32.
40. Zaltz I, Kelly BT, Hetsroni I, Bedi A. The crossover sign overestimates acetabular retroversion. *Clin Orthop Relat Res*. 2013 Aug;471(8):2463-70.
41. Werner CML, Copeland CE, Stromberg J, Ruckstuhl T. Correlation of the cross-over ratio of the cross-over sign on conventional pelvic radiographs with computed tomography retroversion measurements. *Skeletal Radiol*. 2010 Jul;39(7):655-60. Epub 2010 Jan 8.
42. Dagenais S, Garbedian S, Wai EK. Systematic review of the prevalence of radiographic primary hip osteoarthritis. *Clin Orthop Relat Res*. 2009 Mar;467(3):623-37. Epub 2008 Nov 27.
43. Zhang Y, Xu L, Nevitt MC, Aliabadi P, Yu W, Qin M, Lui LY, Felson DT. Comparison of the prevalence of knee osteoarthritis between the elderly Chinese population in Beijing and whites in the United States: The Beijing Osteoarthritis Study. *Arthritis Rheum*. 2001 Sep;44(9):2065-71.
44. Lanyon P, Muir K, Doherty S, Doherty M. Assessment of a genetic contribution to osteoarthritis of the hip: sibling study. *BMJ*. 2000 Nov 11;321(7270): 1179-83.
45. Spector TD, Cicuttini F, Baker J, Loughlin J, Hart D. Genetic influences on osteoarthritis in women: a twin study. *BMJ*. 1996 Apr 13;312(7036):940-3.
46. Joo JH, Lee SC, Ahn HS, Park JS, Lee WJ, Jung KA. Evaluation of the alpha angle in asymptomatic adult hip joints: analysis of 994 hips. *Hip Int*. 2013 Jul-Aug; 23(4):395-9. Epub 2013 Aug 25.
47. Audenaert EA, Peeters I, Vigneron L, Baelde N, Pattyn C. Hip morphological characteristics and range of internal rotation in femoroacetabular impingement. *Am J Sports Med*. 2012 Jun;40(6):1329-36. Epub 2012 Apr 2.
48. Bedi A, Dolan M, Leunig M, Kelly BT. Static and dynamic mechanical causes of hip pain. *Arthroscopy*. 2011 Feb;27(2):235-51. Epub 2010 Oct 29.