

U.S.-Citizen International Medical Graduates

TO THE EDITOR: The Perspective article on U.S.-citizen international medical graduates (IMGs) by Eckhert and van Zanten (April 30 issue)¹ used data from the National Resident Matching Program (NRMP)² to assert that “the forecasts that there would soon be no room in U.S. residency programs for IMGs were not accurate: since the number of positions for postgraduate-year-1 [PGY-1] residents increased by 26% between 2004 and 2014.” Before the 2013 “all-in” policy of the NRMP, data for the Residency Match did not accurately reflect the number of PGY-1 residents who actually entered training, because programs could fill positions (e.g., with IMGs) outside the Match. The Accreditation Council for Graduate Medical Education (ACGME) collects actual counts of residents occupying positions in accredited programs.³

Before “all-in,” the 2011 Match placed 23,420 PGY-1 residents, and the ACGME counted 26,737 entry-level residents in 2011–2012 (in “pipeline” programs leading to initial board certification). After “all-in,” the 2014 Match placed 26,678 PGY-1 residents, and the ACGME counted 27,534 first-year pipeline residents in 2014–2015, which is consistent with closer compliance with the “all-in” policy. According to the ACGME counts, the number of positions actually occupied by entry-level pipeline residents increased from 24,069 in 2004–2005 to 27,534 in 2014–2015, a 14.4% increase.

Paul H. Rockey, M.D., M.P.H.
Rebecca S. Miller, M.S.
Thomas J. Nasca, M.D.

Accreditation Council for Graduate Medical Education
Chicago, IL
prockey@acgme.org

No potential conflict of interest relevant to this letter was reported.

1. Eckhert NL, van Zanten M. U.S.-citizen international medical graduates — a boon for the workforce? *N Engl J Med* 2015; 372:1686-7.
2. National Resident Matching Program (NRMP). Results and data: 2014 main residency match. Washington, DC: NRMP, April 2014 (<http://www.nrmp.org/wp-content/uploads/2014/04/Main-Match-Results-and-Data-2014.pdf>).
3. Accreditation Council for Graduate Medical Education (ACGME). Data resource book, academic year 2013-2014 (<https://www.acgme.org/acgmeweb/tabid/259/Publications/GraduateMedicalEducationDataResourceBook.aspx>).

DOI: 10.1056/NEJMc1507438

THE AUTHORS REPLY: We appreciate the clarification by Rockey et al. with regard to data from the ACGME. Although the magnitude of the increase in graduate medical education positions during the past decade is smaller than we indicated, our statement concerning the continued supply of residency positions for IMGs remains valid. Data from the 2015 Match indicate that there were 1.51 positions per senior at U.S. allopathic medical schools, with IMGs (both U.S.-citizen and non-U.S.-citizen) filling 6301 of these excess positions,¹ despite the increasing pool of seniors at U.S. allopathic medical schools and students and graduates of U.S. osteopathic medical schools.

N. Lynn Eckhert, M.D., Dr.P.H.

Partners HealthCare International
Boston, MA

Marta van Zanten, Ph.D.

Foundation for Advancement of International Medical
Education and Research
Philadelphia, PA

Since publication of their article, the authors report no further potential conflict of interest.

1. National Resident Matching Program (NRMP). Advance data tables: 2015 main residency match. Washington, DC: NRMP, March 2015 (http://www.nrmp.org/wp-content/uploads/2015/03/ADT2015_final.pdf).

DOI: 10.1056/NEJMc1507438

Human Infection with a Novel Avian Influenza A(H5N6) Virus

TO THE EDITOR: Multiple reassortant strains of novel, highly pathogenic avian influenza A(H5) viruses in clade 2.3.4.4 have recently emerged and spread in Asia, Europe, and North America,

giving rise to multiple subtypes (H5N2, H5N5, H5N6, and H5N8).¹⁻³ We report on a 59-year-old man in Guangzhou, China, with influenza A(H5N6) infection and associated illness. He had

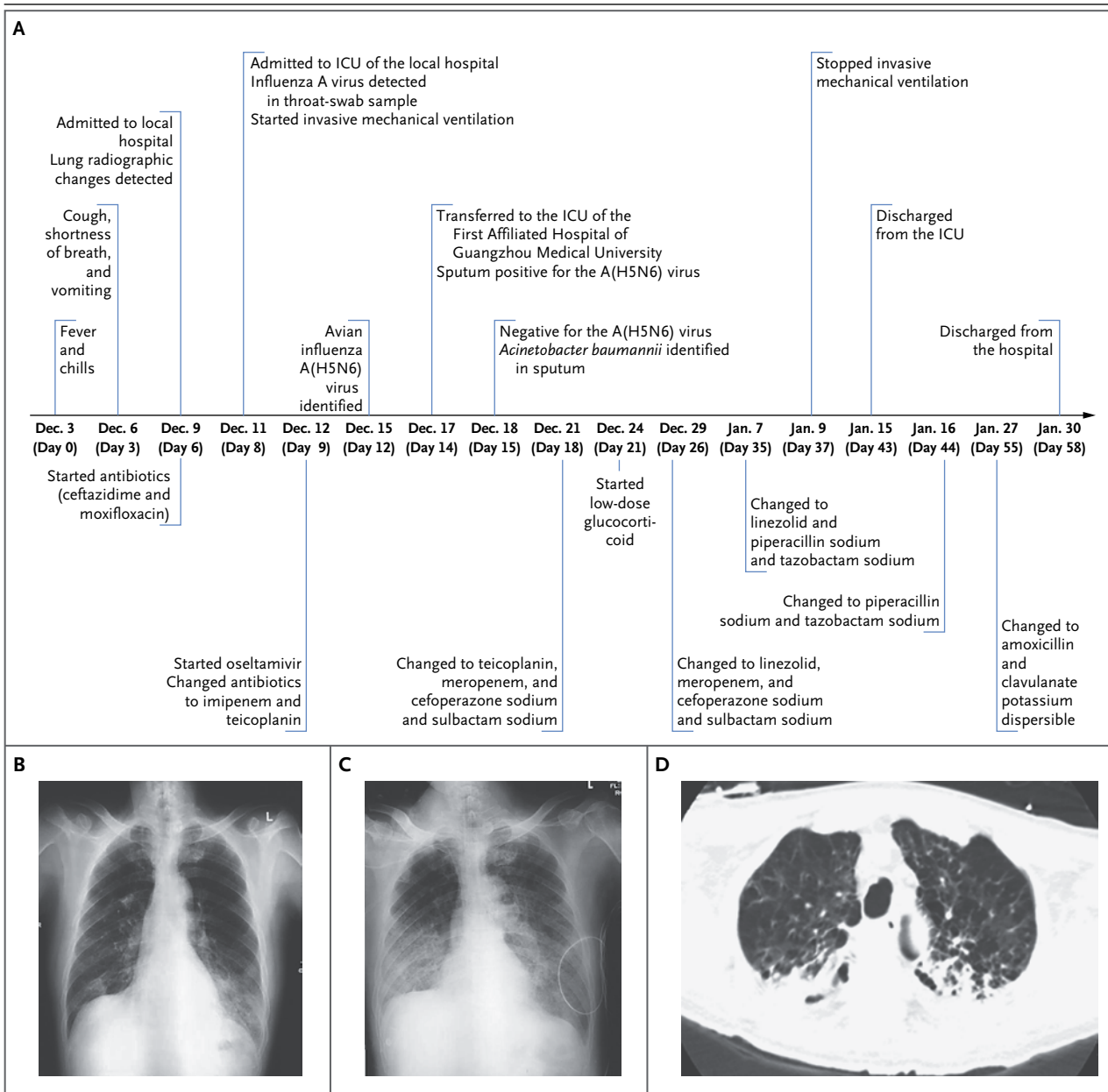


Figure 1. Timeline and Imaging.

Panel A is a timeline of the patient's clinical course. Panels B and C show plain chest radiographs. Bilateral mild partial ground-glass opacities were observed in the lower lung, especially in the left lower lung field, on day 6 (Panel B) and extended to midlung fields by day 13 (Panel C). Panel D is a computed tomographic scan of the chest (lung window), showing bilateral ground-glass opacity and consolidation on day 14. ICU denotes intensive care unit.

a 30-year history of smoking and had stopped smoking in January 2014. He had undergone surgery and chemotherapy for colon cancer, the last chemotherapy dose having been administered in April 2014. During the weeks before illness on-

set, he regularly purchased and handled live poultry in live poultry markets.

Fever and chills developed on December 3, 2014. In the next 3 days, his body temperature rose to 40°C, and the fever was not relieved by

acetaminophen; vomiting, cough, and shortness of breath also developed. He was hospitalized on day 6 of his illness and began receiving antibiotic treatment (Fig. 1A). Chest radiography revealed mild bilateral ground-glass opacities in his lower lung (Fig. 1B). Two days later, pulse oximetry showed that the arterial blood oxygen saturation levels had declined (to approximately 50 to 70%) in spite of the administration of high-flow oxygen (5 to 6 liters per minute), and invasive mechanical ventilation was commenced. A throat-swab sample was positive for influenza A virus, as assessed by means of real-time reverse-transcriptase–polymerase chain reaction (PCR), and treatment with oseltamivir (150 mg twice a day for 13 days, administered through a nasogastric tube) was initiated on day 9. On day 12 of his illness, an influenza A virus isolate, designated A/Guangzhou/39715/2014 (H5N6), was obtained from a throat-swab specimen (see the Supplementary Appendix, available with the full text of this letter at NEJM.org, for details). Influenza A(H5N6) was identified by means of subtype-specific PCR and sequencing of the virus isolate (GenBank accession numbers, KP765785 through KP765792).

On day 14, the patient was transferred to the isolation ward of the intensive care unit in the First Affiliated Hospital of Guangzhou Medical University. A chest radiograph and a computed tomographic scan showed progression of lung consolidation (Fig. 1C and 1D). Influenza A RNA was detectable by means of real-time PCR in sputum samples but not from throat-swab, blood, urine, or stool samples. The next day, virus was undetectable in throat-swab, sputum, and bronchoalveolar-fluid specimens. Multidrug-resistant *Acinetobacter baumannii* was detected in sputum but not in blood cultures. There was evidence of neutrophilia and lymphocytopenia (Table S1 in the Supplementary Appendix). Serum levels of aspartate aminotransferase, creatinine, lactate dehydrogenase, creatine kinase, and myoglobin were within the normal range throughout his illness. Antibiotic therapy was changed to teicoplanin, meropenem, and cefoperazone–sulbactam on day 18. Low-dose methylprednisolone treatment was started on day 21 and was administered until day 42. Imaging showed resolution of the bilateral lung infiltrations. Fever recurred on day 25 in association with eosinophilia. Invasive mechanical ventilation was stopped on day 37,

and the patient was later discharged (day 58). This case shows that a novel H5 clade 2.3.4.4 influenza virus can cause human infection, similar to other influenza A(H5N1) viruses.⁴

Zi-Feng Yang, M.D., Ph.D.

State Key Laboratory of Respiratory Disease
Guangzhou, China

Chris K.P. Mok, Ph.D.

Joseph S.M. Peiris, Ph.D.

University of Hong Kong
Hong Kong, China

Nan-Shan Zhong, M.D.

State Key Laboratory of Respiratory Disease
Guangzhou, China
nanshan@vip.163.com

Drs. Yang and Mok contributed equally to this letter.

Supported by Municipal Science and Technology Bureau Foundation of Guangzhou (2014Y2-00031), National Science and Technology Major Project of the Ministry of Science and Technology of China (2014ZX10004006), and the Area of Excellence Scheme of the University Grants Committee (AoE/M-12/06), Hong Kong SAR Government.

Disclosure forms provided by the authors are available with the full text of this letter at NEJM.org.

1. World Health Organization. Antigenic and genetic characteristics of zoonotic influenza viruses and development of candidate vaccine viruses for pandemic preparedness. February 2015 (http://www.who.int/influenza/vaccines/virus/201502_zoonotic_vaccinevirusupdate.pdf?ua=1).
2. European Food Safety Authority. Highly pathogenic avian influenza A subtype H5N8. Parma, Italy: EFSA, 2014 (<http://www.efsa.europa.eu/en/efsajournal/doc/3941.pdf>).
3. Outbreaks of avian influenza A (H5N2), (H5N8), and (H5N1) among birds — United States, December 2014–January 2015. *MMWR Morb Mortal Wkly Rep* 2015;64:111.
4. Writing Committee of the Second World Health Organization Consultation on Clinical Aspects of Human Infection with Avian Influenza A (H5N1) Virus. Update on avian influenza A (H5N1) virus infection in humans. *N Engl J Med* 2008;358:261-73.

DOI: 10.1056/NEJMc1502983

Correspondence Copyright © 2015 Massachusetts Medical Society.

INSTRUCTIONS FOR LETTERS TO THE EDITOR

Letters to the Editor are considered for publication, subject to editing and abridgment, provided they do not contain material that has been submitted or published elsewhere. Please note the following:

- Letters in reference to a *Journal* article must not exceed 175 words (excluding references) and must be received within 3 weeks after publication of the article.
- Letters not related to a *Journal* article must not exceed 400 words.
- A letter can have no more than five references and one figure or table.
- A letter can be signed by no more than three authors.
- Financial associations or other possible conflicts of interest must be disclosed. Disclosures will be published with the letters. (For authors of *Journal* articles who are responding