

Intraoperative Contrast-Enhanced Sonography of Bowel Blood Flow

Preliminary Experience

Andrew J. Swift, BMedSci, MRCP, FRCR, Pamela Parker, BSc, Kieth Chiu, MBChB, Ian A. Hunter, PhD, FRCS, John E. Hartley, BSc(Hons), MD, MRCS, Oliver R. Byass, FRCR

Objectives—The potential to predict, and therefore avoid, anastomotic failure has eluded generations of colon and rectal surgeons to date. A reliable, reproducible method of assessing bowel blood flow therefore would be of enormous potential clinical relevance. To our knowledge, intraoperative contrast-enhanced sonography of the bowel has not been performed previously. We present our study assessing the feasibility of using contrast-enhanced sonography to study bowel perfusion intraoperatively.

Methods—We studied 8 patients (4 male and 4 female) with an age range of 52 to 81 years who underwent colorectal surgery (right hemicolectomies, $n = 3$; Hartmann procedure, $n = 1$; anterior resections, $n = 2$; and bowel resections with ileocolic anastomoses, $n = 2$). A 5-mL bolus of a sulfur hexafluoride contrast agent solution was injected before and after vascular ligation with simultaneous noncompression ultrasound scanning directly over the large bowel. The patients were followed clinically to assess for leaks. Contrast-enhanced sonographic time-intensity curves were generated for the time to peak and maximum amplitude.

Results—Moderate interobserver agreement was shown for the time to peak ($\kappa = 0.50$) and maximum amplitude ($\kappa = 0.42$), and moderate intraobserver agreement was shown for the time to peak ($\kappa = 0.53$) and maximum amplitude ($\kappa = 0.53$). No significant differences were shown between the time to peak ($P = .28$) and maximum amplitude ($P = .49$) for the preligation and postligation scans.

Conclusions—To our knowledge, intraoperative contrast-enhanced sonography of the bowel has not been performed previously. We have shown the technique to be feasible with good intraobserver and interobserver agreement. Further work is ongoing to optimize the technique and assess its use in predicting anastomotic breakdown.

Key Words—blood flow; bowel; contrast-enhanced sonography

Received May 25, 2011, from the Departments of Radiology (A.J.S., P.P., K.C., O.R.B.) and Academic Surgery (I.A.H., J.E.H.), Hull and East Yorkshire Hospitals National Health Service Trust, Hull, East Yorkshire, England. Revision requested June 13, 2011. Revised manuscript accepted for publication August 2, 2011.

Address correspondence to Andrew J. Swift, BMedSci, MRCP, FRCR, Department of Radiology, Castle Hill Hospital, Hull and East Yorkshire Hospitals National Health Service Trust, Castle Road, Cottingham, East Yorkshire HU16 5JQ, England.

E-mail: andrewjamesswift@gmail.com

Anastomotic breakdown in colorectal surgery is a common and feared complication. Several factors may contribute to tissue breakdown; however, adequate bowel perfusion seems to be the key factor.¹ The problem is particularly apparent with low rectal anastomoses, which have a higher risk of leaks: approximately 10%.² Predicting patients who will have an anastomotic leak is of value because fecal diversion can be performed, reducing the severity of secondary complications.^{3,4}

Studies using intraoperative laser Doppler flowmetry have been performed to measure microperfusion/blood flow in the bowel.⁵ A recent study assessed the use of contrast-enhanced sonography for the assessment of the normal jejunum in dogs and showed it to be a viable method for assessing the bowel intraoperatively.⁶ Studies

have quantified bowel wall vascularity in patients with Crohn disease using transabdominal contrast-enhanced sonography.⁷⁻⁹ Furthermore, the use of contrast-enhanced sonography in the assessment of bowel ischemia has been studied.¹⁰ The method has a good safety profile for abdominal applications.¹¹

The potential to predict, and therefore avoid, anastomotic failure has eluded generations of colon and rectal surgeons to date. A reliable, reproducible method of assessing bowel blood flow therefore would be of enormous potential clinical relevance. The aim of our study was to assess the feasibility of using contrast-enhanced sonography to study bowel blood flow intraoperatively.

Materials and Methods

Patients

We prospectively studied 8 patients who underwent colorectal surgery in the Department of Academic Surgery of Castle Hill Hospital between September 2009 and February 2010 (right hemicolectomies, n = 3; Hartmann procedure, n = 1; anterior resections, n = 2; and bowel resections with ileocolic anastomoses, n = 2). Approval was given by our Institutional Review Board. Mentally incapacitated patients, patients unable to consent to the study, and those with major cardiac disease (a contraindication for the sonographic contrast agent) were excluded from the study. Informed consent was attained for all patients enrolled in the study.

Procedure

The contrast-enhanced sonographic procedure required a 2-stage process, detailed below.

Preligation Scans

After mobilization of the bowel but before vascular ligation, we performed our initial ultrasound scan. A 5-mL bolus of SonoVue solution (sulfur hexafluoride; Bracco International BV, Amsterdam, the Netherlands) was injected by an anesthetist into a peripheral vein using a 20-gauge venous catheter. SonoVue injection was followed immediately by a 5-mL saline bolus to flush the injection line. Scanning was performed longitudinal to the bowel using a Technos MPX ultrasound machine (Esaote Biomedica, Genoa, Italy). Cine image recording was initiated 10 seconds before the injection and continued for 3 minutes after the injection. The bowel was scanned proximal to the operation site; for example, in patients undergoing anterior resection, the distal sigmoid colon was imaged. In the cases

in which a right hemicolectomy was performed, the small bowel was imaged.

Four patients were scanned using a 5–2-MHz curvilinear probe; 2 were scanned using a 9–3-MHz linear probe and a sterile gel standoff pad; and 2 were scanned with the bowel submerged in sterile water using a 5–2-MHz curvilinear probe (Figure 1). The sonographic examinations were performed under sterile conditions using a probe cover and a sterile contact medium.

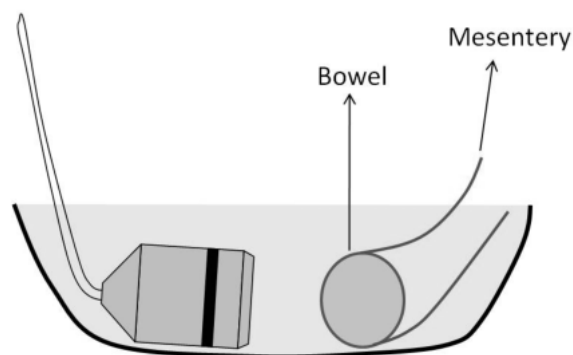
Postligation Scans

A second 5-mL injection of SonoVue was administered after formation of the anastomosis using the same described technique. The bowel was imaged at the site of the anastomosis longitudinal to the bowel with the distal limb on the left of the image and the proximal on the right. The patient who underwent the Hartmann procedure underwent scanning only before vascular ligation because no anastomosis was formed. In 1 of the 2 anterior resection cases, the anastomosis was low in the pelvis; hence, the bowel was imaged proximal to the anastomosis for the second scan. The patients were followed clinically to assess for anastomotic leaks.

Image Analysis

Contrast-enhanced sonographic time-intensity curves were postprocessed using the time-intensity software on our Esaote MPX machine. The time to peak and maximum amplitude were assessed using sectorial region-of-interest boxes positioned on the imaged bowel. The images were analyzed by 2 observers both experienced in performing contrast-enhanced sonographic studies. The observers were blinded to the clinical information; the first observer repeated the measurements twice. Intraobserver and interobserver variability was analyzed using the κ sta-

Figure 1. Water submersion technique using a surgical kidney dish filled with sterile water as the contrast medium.



tistic. Preligation and postligation group comparisons were made using the Mann-Whitney test, with significance at $P < .05$.

Results

We studied 8 patients in total (4 male and 4 female) with an age range of 52 to 81 years. Time-intensity curves were produced for all patients (Figure 2). No significant differences were shown between the time to peak ($P = .28$) and maximum amplitude ($P = 0.49$) for the preligation and postligation scans. The contrast-enhanced sonographic technique was shown to be feasible and practical in the intraoperative setting. The image quality was considered inferior when the bowel was imaged in direct contact with the probe using the 5–2-MHz probe; substantial near-field artifacts hindered interpretation (Figure 3). The image quality was not greatly improved when the higher-frequency linear probe (9–3 MHz) was used. However, the image quality was markedly improved for the 2 patients in whom the bowel was submerged in sterile water.

Figure 4 shows contrast-enhanced sonograms before and after anastomosis formation in a patient who underwent a right hemicolectomy using the water submersion method. The image quality improved markedly when this technique was used. An interference pattern is shown on the image, and the artifact lines of fire correlate with the individual transducer elements. We presume the artifact to have been caused by nonlinear harmonic echoes in the surrounding fluid, which are displayed as a received signal on the low-mechanical index image.

Table 1 shows the mean, standard deviation, and range values for the time to peak and maximum amplitude.

Figure 2. Time-intensity curve generated from an intraoperative contrast-enhanced ultrasound scan. The cine recording is commenced at time 0, and the contrast agent is injected at 10 seconds. The intensity rise represents contrast entering the bowel tissue.

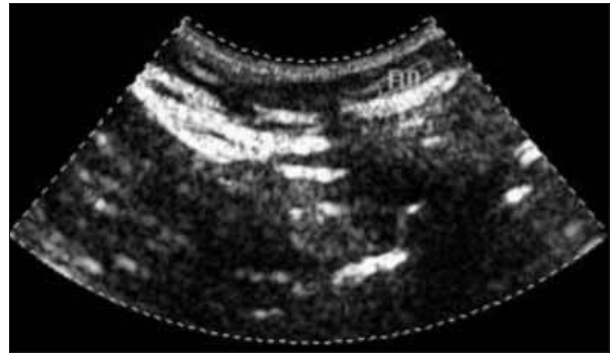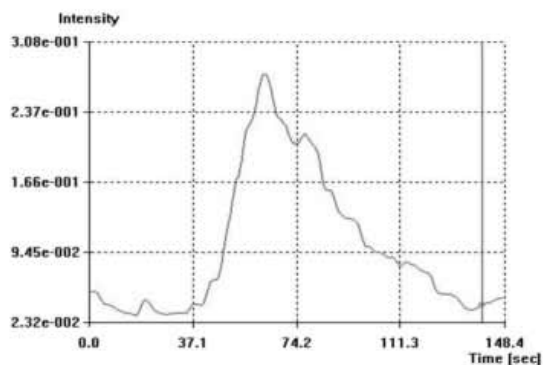


Figure 3. Contrast-enhanced sonogram illustrating the method with the probe in direct contact with the bowel. The image shows substantial near-field artifacts, which hindered interpretation. The artifacts are shown as echogenic linear bands caused by interference on the low-mechanical index image.

Moderate interobserver agreement was shown for the time to peak ($\kappa = 0.50$) and maximum amplitude ($\kappa = 0.42$), and moderate intraobserver agreement was shown for the time to peak ($\kappa = 0.53$) and maximum amplitude ($\kappa = 0.53$; Table 2). The average time taken to perform contrast-enhanced sonography intraoperatively was approximately 5 to 10 minutes per scan. None of the 7 patients in whom an anastomosis was formed had anastomotic complications, and all 8 patients had an uneventful postoperative recovery.

Figure 4. Contrast-enhanced sonograms before and after formation of an anastomosis in a patient who underwent a right hemicolectomy using the water submersion imaging method. The image quality improved markedly when this technique was used. **A**, Segment of the small bowel proximal to where the anastomosis was formed. **B**, Appearance after anastomosis formation, with the proximal small-bowel limb on the right and distal limb of the anastomosis on the left. The linear artifacts related to individual transducer elements are likely caused by nonlinear harmonic echoes in the surrounding fluid, which are displayed as a received signal on the low-mechanical index image.

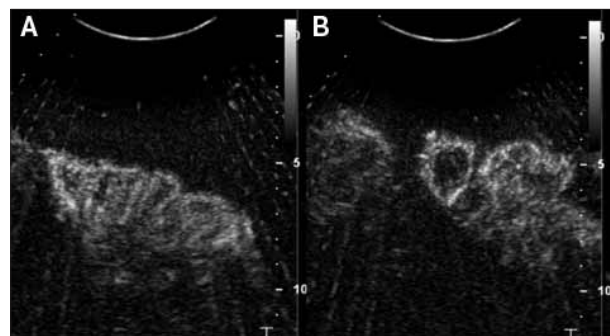


Table 1. Quantitative Time-Intensity Curve Data

Parameter	Preligation (n = 8)	Postligation (n = 7)
Time to peak, s	Mean, 26.4 SD, 11.4 Range, 13.6–47.7	Mean, 19.9 SD, 10.9 Range, 10.0–40.7
Maximum amplitude, units of echogenicity	Mean, 3.7 SD, 0.7 Range, 3.2–4.9	Mean, 3.4 SD, 1.7 Range, 1.5–6.2

Discussion

There is currently no reliable method of assessing bowel blood flow that is used in the routine clinical setting. This work has shown that intraoperative contrast-enhanced sonography is a feasible method for assessing bowel blood flow. We found water-submerged contrast-enhanced sonography the most successful method in terms of image quality and visualization of contrast enhancement, and we would recommend this method for further studies. Our study has shown that time-intensity curves can be generated from bowel scanned intraoperatively, and the results are reproducible. No significant differences between pre-anastomosis and postanastomosis time-intensity curves were shown; however, given the small numbers, no definitive conclusions can be drawn, and further studies will be required to validate this technique. We used a semiquantitative method of analysis in this study; however, a qualitative assessment may be sufficient in the clinical setting. This question could be answered in further work comparing qualitative and quantitative methods of analyzing bowel enhancement.

The cause of anastomotic breakdown is multifactorial, with a good blood supply, absence of tension, and the general circulatory condition of the patient being key factors.¹ Vignali et al² assessed 1014 patients with stapled colorectal anastomoses, and the overall leak rate was 2.9%. Low anastomoses (<7 cm from the anal verge) have a higher risk of leaks: approximately 10%.² Predicting patients who

will have an anastomotic leak is of value because fecal diversion using an ileostomy can be performed. Fecal diversion does not reduce the incidence of leaks; however, it does reduce the severity of secondary complications.^{3,4} Our small study showed no significant difference between the preligation and postligation scans. However, a larger patient group would be required to determine whether the technique is feasible for predicting anastomotic breakdown.

The limitations of the study included the small patient number and the lack of a positive control group. No patients had anastomotic leak-related complications; hence, the value of this technique in predicting anastomotic breakdown has not been proven. Limitations of the technique itself include motion of the probe in relation to the bowel. The operator should be experienced in performing sonography to minimize potential motion artifacts. Our technique required the surgery to be open, or such an operation in which the bowel could be in direct contact with the probe. Hence, with the trend toward laparoscopic surgery, a rectal probe is likely to be the best device for direct rectal imaging.

The utility of Doppler sonography for assessing bowel blood flow intraoperatively has been studied; however, the method has limited predictive value, and a comparative study showed laser Doppler to be a superior method for assessing bowel perfusion.¹² Studies using intraoperative laser Doppler flowmetry have been performed to measure microperfusion/blood flow in the proximal and rectal stump and anastomoses in patients undergoing anterior resections. Vignali et al⁵ showed a good correlation with anastomotic breakdown. Blood flow and tissue perfusion measurements with laser Doppler flowmetry allow noninvasive examination of the microcirculation. The tissue perfusion measurements obtained by laser Doppler flowmetry are relative measurements instead of accurate and absolute measurements because of the complexity of the system.¹³ Hence, the method is not widely used in clinical practice. However, further studies assessing the applicability of contrast-enhanced sonography should use a laser Doppler blood flow imager for correlation with contrast-enhanced sonographic findings. Studies measuring anastomotic intramucosal pH in the early postoperative period have been performed; this technique can further help predict the risk of anastomotic leakage.¹⁴ However, the current means of assessing the anastomosis is to check that the resection rings from the cartridge shaft are complete and then perform the “bubble test” or “water test.” This basic test involves filling the pelvis with sterile water and manually occluding the proximal limb of the anastomosis. The rec-

Table 2. Interobserver and Intraobserver Variability

Parameter	Intraobserver Variability	Interobserver Variability
Time to peak	$\kappa = 0.53$ SE, 0.10 95% CI, 0.33–0.73	$\kappa = 0.50$ SE, 0.12 95% CI, 0.28–0.73
Maximum echogenicity	$\kappa = 0.53$ SE, 0.15 95% CI, 0.24–0.82	$\kappa = 0.42$ SE, 0.15 95% CI, 0.12–0.71

CI indicates confidence interval.

tum is insufflated with air, and a positive result is indicated by the presence of gas bubbles rising to the surface.¹⁵ Our technique was simple to perform and did not substantially prolong the operation time, with the imaging time taking approximately 5 to 10 minutes per scan.

In conclusion, to our knowledge, intraoperative contrast-enhanced sonography of the bowel has not been performed previously. It is a widely available, safe technique that provides a quantitative measure of bowel blood flow. We have shown the reproducibility of contrast-enhanced sonographic time-intensity curves for bowels scanned intraoperatively. Further work is required to optimize the technique and assess its use in predicting anastomotic breakdown.

References

- Schrock TR, Deveney CW, Dunphy JE. Factor contributing to leakage of colonic anastomoses. *Ann Surg* 1973; 177:513–518.
- Vignali A, Fazio VW, Lavery IC, et al. Factors associated with the occurrence of leaks in stapled rectal anastomoses: a review of 1,014 patients. *J Am Coll Surg* 1997; 185:105–113.
- Marusch F, Koch A, Schmidt U, et al. Value of a protective stoma in low anterior resections for rectal cancer. *Dis Colon Rectum* 2002; 45:1164–1171.
- Hüser N, Michalski CW, Erkan M, et al. Systematic review and meta-analysis of the role of defunctioning stoma in low rectal cancer surgery. *Ann Surg* 2008; 248:52–60.
- Vignali A, Gianotti L, Braga M, Radaelli G, Malvezzi L, Di Carlo V. Altered microperfusion at the rectal stump is predictive for rectal anastomotic leak. *Dis Colon Rectum* 2000; 43:76–82.
- Jiménez DA, O'Brien RT, Wallace JD, Klocke E. Intraoperative contrast-enhanced ultrasonography of normal canine jejunum. *Vet Radiol Ultrasound* 2011; 52:196–200.
- Kratzer W, Schmidt SA, Mittrach C, et al. Contrast-enhanced wideband harmonic imaging ultrasound (SonoVue): a new technique for quantifying bowel wall vascularity in Crohn's disease. *Scand J Gastroenterol* 2005; 40:985–991.
- Pauls S, Gabelmann A, Schmidt SA, et al. Evaluating bowel wall vascularity in Crohn's disease: a comparison of dynamic MRI and wideband harmonic imaging contrast-enhanced low MI ultrasound. *Eur Radiol* 2006; 16:2410–2417.
- Girlich C, Jung EM, Iesalnieks I, et al. Quantitative assessment of bowel wall vascularisation in Crohn's disease with contrast-enhanced ultrasound and perfusion analysis. *Clin Hemorheol Microcirc* 2009; 43:141–148.
- Hata J, Kamada T, Haruma K, Kusunoki H. Evaluation of bowel ischemia with contrast-enhanced US: initial experience. *Radiology* 2005; 236:712–715.
- Piscaglia F, Bolondi L; Italian Society for Ultrasound in Medicine and Biology (SIUMB) Study Group on Ultrasound Contrast Agents. The safety of SonoVue in abdominal applications: retrospective analysis of 23,188 investigations. *Ultrasound Med Biol* 2006; 32:1369–1375.
- Roterer RH Jr, Dixon JA, Holloway GA, McCloskey DW. A comparison of the He Ne laser and ultrasound Doppler systems in the determination of viability of ischemic canine intestine. *Ann Surg* 1982; 196:705–708.
- Leahy MJ, de Mul FFM, Nilsson GE, Maniewski R. Principles and practice of the laser-Doppler perfusion technique. *Technol Health Care* 1999; 7:143–162.
- Millan M, García-Granero E, Flor B, García-Botello S, Lledo S. Early prediction of anastomotic leak in colorectal cancer surgery by intramucosal pH. *Dis Colon Rectum* 2006; 49:595–560.
- Catalano O, Nunziata A, Siani A. *Fundamentals in Oncologic Ultrasound: Sonographic Imaging and Intervention in the Cancer Patient*. Berlin, Germany: Springer; 2009.