

Use of robotic-assisted laparoscopic Mitrofanoff appendicovesicostomy in a paediatric patient: problem encountered

Ivy HY Chan *, Florence HQ Li, Lawrence CL Lan, Kenneth KY Wong, Peter KF Yip, Paul KH Tam

ABSTRACT

This report is of robotic-assisted laparoscopic Mitrofanoff appendicovesicostomy in a 12-year-old patient with detrusor underactivity and hereditary sensory neuropathy. The whole operation was performed in 555 minutes with no open conversion. The patient experienced one episode of stomal stenosis, which required dilatation. At 3-year follow-up, the patient had both stomal and urinary continence. This is a safe and effective procedure to create a means of urinary catheterisation with avoidance of a large unsightly scar and comparable clinical outcome to an open procedure.

Hong Kong Med J 2015;21:468–70

DOI: 10.12809/hkmj144340

IHY Chan *, FRCSEd(Paed), FHKAM (Surgery)

FHQ Li, MB, ChB

LCL Lan, FRCSEd, FHKAM (Surgery)

KKY Wong, FRCSEd, FHKAM (Surgery)

PKF Yip, FRCSEd, FHKAM (Surgery)

PKH Tam, FRCS (Edin, Glasg, Irel), FHKAM (Surgery)

Division of Paediatric Surgery, Department of Surgery, The University of Hong Kong, Queen Mary Hospital, Pokfulam, Hong Kong

* Corresponding author: ivyhychan@gmail.com

► A video clip showing robotic-assisted laparoscopic Mitrofanoff appendicovesicostomy is available at www.hkmj.org.

Introduction

The da Vinci Surgical System for robotic-assisted laparoscopic surgery was approved by the US Food and Drug Administration in 2000.¹ Since its introduction, various types of operations have been successfully performed by robotic-assisted laparoscopic surgery. This technique, however, is limited by its lack of flexibility in the operative field and the size of paediatric patients. Therefore, its use is mainly confined in adult patients. Here, we describe the use of robotic-assisted laparoscopic Mitrofanoff appendicovesicostomy in a paediatric patient with detrusor underactivity and sensory neuropathy.

Case report

In September 2009, a 12-year-old girl with hereditary sensory neuropathy presented to Queen Mary Hospital with overflow incontinence. She had a rare hereditary sensory neuropathy, which resulted in no pain sensation and no sensation of bladder fullness. As well as sensory neuropathy, she had mild mental retardation, and studied in a special school.

She presented with overflow incontinence, difficulty in initiating voiding, long voiding time, and large volume of post-void residual urine. The results of investigations—including renal function test, ultrasound of the urinary system, and magnetic resonance imaging of the lumbosacral spine—were normal. Video urodynamics revealed poor bladder sensation despite high detrusor pressure, low voiding

detrusor pressure, and incomplete emptying. The overall impression was detrusor underactivity.

The initial treatment plan was for transurethral clean intermittent urinary catheterisation (CIC) to be performed regularly by the patient's caregiver. Because of the patient's mental status and uncooperability, however, she could not tolerate CIC. After thorough discussion, the patient's parents agreed to the patient undergoing Mitrofanoff appendicovesicostomy.

The operation was performed in a Trendelenburg position. A 12-mm camera port was placed at the circumumbilical position. Two 8-mm working ports were placed one each at the left lower quadrant and right upper quadrant. A 5-mm assistant port was placed at the epigastric area, mainly for bowel retraction and passing sutures (Fig).

Preoperative intravenous antibiotics of amoxicillin-clavulanic acid 30 mg/kg were administered. A urinary catheter was inserted under aseptic conditions. The appendix was mobilised with its mesentery. However, the appendix and its mesentery appeared to be relatively short (appendix was approximately 6 cm and mesentery was approximately 4 cm) in this patient so the right colon was mobilised en bloc up to the hepatic flexure to create mobility of the appendix and its mesentery.

Initial mobilisation of the right colon and bladder was performed with conventional laparoscopy. The robotic system was docked in to

perform the anastomosis between the bladder and appendix.

The urinary bladder was partially infused with normal saline via the urinary catheter. The tip of the appendix was opened and an 8-French infant feeding tube was inserted to ease manipulation of the appendix. The detrusor muscle was incised and opened by electrocautery at the supero-anterior aspect of the urinary bladder. Appendicovesicostomy was performed with 5/0 vicryl in an interrupted manner. The other end of the appendix was retrieved at the right lower quadrant of the abdominal wall. A V flap was created and the stoma was fashioned with 5/0 vicryl. The infant feeding tube was kept in situ as a stent. The whole operation took 555 minutes (9.25 hours).

The patient's recovery was complicated by urinary tract infection with extended-spectrum beta-lactamase-producing *Escherichia coli*. Intravenous meropenem 20 mg/kg every 8 hours was initiated for 14 days. The infant feeding catheter was removed and the technique of CIC was taught to the patient's caregiver.

The continence outcome was good as reported by the patient's caregiver. There was no urine leak from the stoma or urethra. The technique of CIC with an 8-French catheter 4 times a day was performed uneventfully by the patient's caregiver until around 6 months after the operation, when examination under anaesthesia and cystogram found mild stenosis of the stoma. Serial dilatation of the stoma site was suggested. There is no urine leak until the bladder reaches 400 mL in capacity. At 3-year follow-up, the patient's caregiver can catheterise the bladder with ease and the patient has both stomal and urinary continence.

Discussion

The Mitrofanoff procedure was described in 1980.² It uses the appendix to create a channel from the urinary bladder to the skin surface. This procedure has helped many patients who cannot tolerate urethral catheterisation over the past three decades. The procedure, however, was done via a conventional open surgery approach until 1993, when Jordan and Winslow³ described the technique of laparoscopic-assisted appendicovesicostomy. Despite the benefit of minimally invasive surgery, this technique has not become popular. In 2004, Pedraza et al⁴ and Hsu and Shortliffe⁵ described the use of the robotic-assisted technique in creating an appendicovesicostomy. Since then, a few case reports or case series⁶⁻⁸ have described this technique. This is largely attributed to the delicacy of the appendiceal blood supply and challenging intracorporeal anastomosis. The surgical robot offers three-dimensional visualisation, downscaling of surgeons' tremor and hand movements, range of motion resembling that of the

於小兒患者身上使用機器人輔助腹腔鏡 Mitrofanoff 闌尾膀胱造口術：遇見的問題

陳巧兒、李賀翹、藍傳亮、黃格元、葉錦輝、譚廣亨

本文報告一名逼尿肌無力和遺傳性感覺神經病變的12歲患者接受機器人輔助腹腔鏡Mitrofanoff闌尾膀胱造口術的病例。整個手術過程歷時555分鐘，並毋須轉至開腔術。術後患者曾出現一次吻合口狹窄，遂施以擴張術。患者術後三年復查一直均能達到尿控和控制造口開合。機器人輔助腹腔鏡Mitrofanoff闌尾膀胱造口術是一種安全的方法，不但能導尿，更不會留下明顯疤痕，臨床結果亦可媲美開腔術。

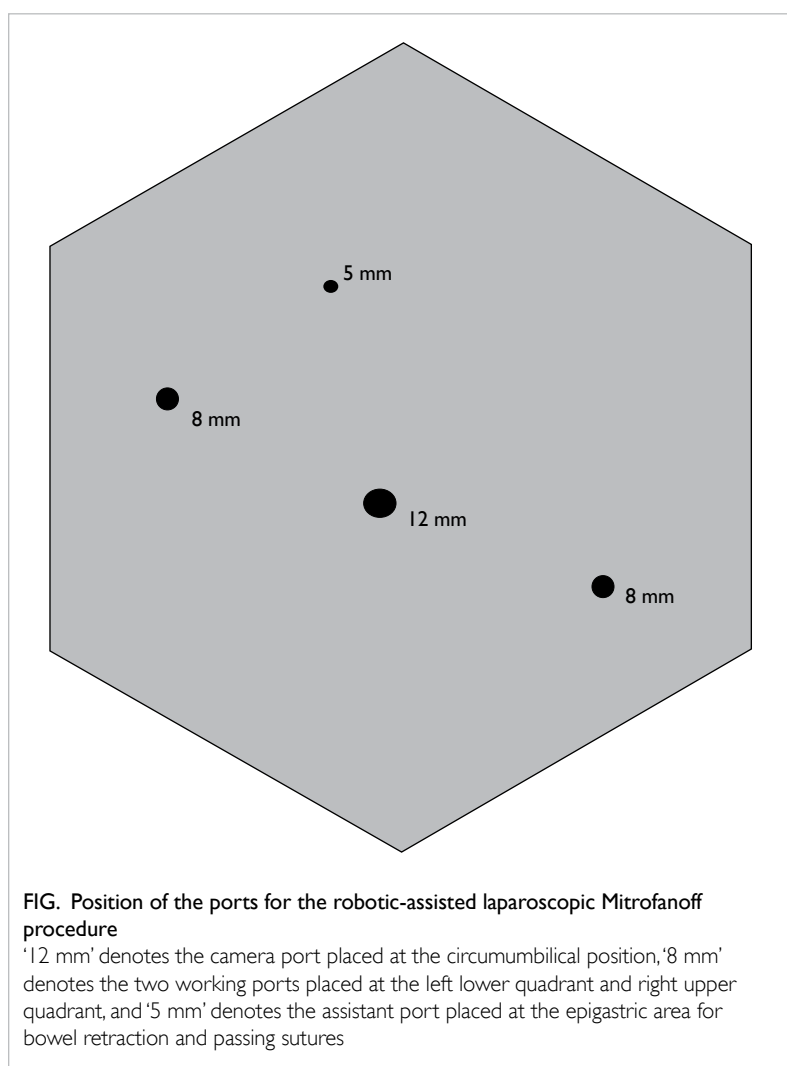


FIG. Position of the ports for the robotic-assisted laparoscopic Mitrofanoff procedure
'12 mm' denotes the camera port placed at the circumumbilical position, '8 mm' denotes the two working ports placed at the left lower quadrant and right upper quadrant, and '5 mm' denotes the assistant port placed at the epigastric area for bowel retraction and passing sutures

human wrist, and increased degrees of freedom.

The benefits of applying robotic technology for this procedure are greatest at two stages: first when dissecting the appendiceal blood supply and second when recreating a circumferential sealed

anastomosis joining the appendix and bladder. Maintaining the blood supply to the appendix is one of the most important steps for avoiding cutaneous stomal stenosis and scarring. The challenge of making an intracorporeal watertight anastomosis may also be an important reason for the scarce reports of the pure laparoscopic approach for this technique. In view of this, there is no doubt that the surgical robot has a fine ability to mimic the open procedure without introducing a large unsightly abdominal incision.

On the other hand, the operative field is limited with the robotic system. This created a problem for this patient, as the appendix and its mesentery was short. The robotic machine was docked towards the feet of the patient and the targeted area of interest was at the pelvis and right lower quadrant. During mobilisation of the upper part of the right colon, crowding of instruments was encountered. As the port was placed as shown in the Figure, the operative field was fixed in the right lower quadrant. For mobilisation of the right colon, the operative field moved from the right lower quadrant to the right upper quadrant. The robotic instruments were not sufficiently flexible for the different surgical fields required for this patient, so we reverted to conventional laparoscopic mobilisation of the right colon. This necessitated more time to redock the whole system back to perform the appendicovesicostomy anastomosis. This is one of the drawbacks of the robotic-assisted Mitrofanoff procedure.

The short-term and mid-term outcomes of this patient are good. She recovered well and became fully mobilised on day 3 after operation. The continence outcome of this patient is good, and the caregiver also found this helpful for doing CIC for this patient.

Conclusion

The robotic-assisted laparoscopic Mitrofanoff procedure is a feasible and safe operation. The technique has the advantage of performing the delicate anastomosis between the appendix and the bladder intracorporeally. Lack of flexibility when changing the surgical field is the major drawback. The robotic-assisted laparoscopic Mitrofanoff procedure can produce a smaller scar and better cosmetic outcome.

References

1. Meadows M. Computer-assisted surgery: an update. Available from: http://web.archive.org/web/20090301135726/http://www.fda.gov/fdac/features/2005/405_computer.html. Accessed 9 Jul 2015.
2. Mitrofanoff P. Trans-appendicular continent cystostomy in the management of the neurogenic bladder [in French]. *Chir Pediatr* 1980;21:297-305.
3. Jordan GH, Winslow BH. Laparoscopically assisted continent catheterizable cutaneous appendicovesicostomy. *J Endourol* 1993;7:517-20.
4. Pedraza R, Weiser A, Franco I. Laparoscopic appendicovesicostomy (Mitrofanoff procedure) in a child using the da Vinci robotic system. *J Urol* 2004;171:1652-3.
5. Hsu TH, Shortliffe LD. Laparoscopic Mitrofanoff appendicovesicostomy. *Urology* 2004;64:802-4.
6. Storm DW, Fulmer BR, Sumfest JM. Laparoscopic robot-assisted appendicovesicostomy: an initial experience. *J Endourol* 2007;21:1015-8.
7. Thakre AA, Yeung CK, Peters C. Robot-assisted Mitrofanoff and Malone antegrade continence enema reconstruction using divided appendix. *J Endourol* 2008;22:2393-6.
8. Willie MA, Zagaja GP, Shalhav AL, Gundeti MS. Continence outcomes in patients undergoing robotic assisted laparoscopic mitrofanoff appendicovesicostomy. *J Urol* 2011;185:1438-43.