

Research Article**Minimally Invasive Treatment of Oligometastasis in the Liver in Recurrent Nasopharyngeal Carcinoma**

Jimmy Yu Wai Chan, Stanley Thian Sze Wong, William Ignace Wei.

Division of Head & Neck Surgery, Department of Surgery, University of Hong Kong Medical Centre, Queen Mary Hospital. 102 Pokfulam Road, Hong Kong SAR, China

Corresponding author: Jimmy Yu Wai Chan. Division of Head & Neck Surgery, Department of Surgery, University of Hong Kong Medical Centre, Queen Mary Hospital. 102 Pokfulam Road, Hong Kong SAR, China. Telephone: +852 22554394. Fax: +852 28193780.

E-mail:chanjyw@gmail.com

Citation: Chan JYW, Wong STS, Wei WI. Minimally Invasive Treatment of Oligometastasis in the Liver in Recurrent Nasopharyngeal Carcinoma[J]. J Nasopharyng Carcinoma, 2016, 3(2): e30. doi:10.15383/jnpc.30.

Competing interests: The authors have declared that no competing interests exist.

Conflict of interest: None

Copyright: ©2016 By the Editorial Department of Journal of Nasopharyngeal Carcinoma. This is an open-access article distributed under the terms of the Creative Commons Attribution License, which permits unrestricted use, distribution, and reproduction in any medium, provided the original author and source are credited.

Abstract: Objective: The principle of management of patients with oligometastasis is evolving. The current study aims to investigate the efficacy of percutaneous radiofrequency ablation (RFA) of the solitary liver metastasis after previous radiotherapy for nasopharyngeal carcinoma (NPC). **Methods:** A pilot study involving 4 patients with biopsy proven solitary liver metastasis from NPC. After creation of artificial ascites, cooltip RFA needle was inserted into the intra-hepatic tumor under ultrasound guidance. Procedure related complications were noted and patients were followed up regularly and indefinitely for oncological outcome. **Results:** All patients had locoregionally advanced NPC at initial diagnosis and were treated with concurrent chemoradiation. Complete response was achieved in all patients. The mean time to tumor recurrence was 21.3 months. The mean size of the liver tumor was 3.5cm. Two patients had synchronous local tumor recurrence, and they underwent nasopharyngectomy and neck dissection before receiving treatment to the liver. Percutaneous RFA was performed in all patients. The mean hospital stay was 2.2 days and no procedure related complications were detected. No systemic treatment was given afterwards. The mean follow-up interval was 40.5 months. One of the patients developed progression of disease and died at 13 months after RFA, while the rest of the patients were alive and

remained disease free at the last follow-up. **Conclusion:** Percutaneous RFA is potentially useful as a minimally invasive procedure for patients with solitary liver metastasis after radiotherapy for NPC. Further study is required to confirm its efficacy and to define the protocol of adjuvant systemic chemotherapy to improve the treatment outcome.

Keywords: Nasopharyngeal carcinoma; Recurrent; Distant metastasis; Oligometastasis; Survival

Introduction

Southern China and Hong Kong is one of the endemic areas where the incidence of nasopharyngeal carcinoma (NPC) is among the highest in the world^[1]. Unfortunately, more than 50% of the patients present with stage III-IVB disease, according to the American Joint Committee on Cancer (AJCC, 6th edition)^[2]. In the presence of locoregionally advanced tumor, the use of concurrent chemoradiation was shown to be superior compared to radiotherapy alone, either in terms of improvement in local and regional control^[3-5], or reduced risk of distant failure^[3, 6-7]. In a study involving 256 patients with NPC, the incidence of systemic metastasis was up to 36%^[8], the most common sites of which being the bones, lungs and the liver. Data on the treatment of distant failures after radiotherapy for NPC is limited. At the moment, treatment in such circumstances is mainly palliative in nature, which usually consists of the use of combination chemotherapy.

Trans-arterial chemo-embolization (TACE) has been used in the treatment of liver metastasis^[9], although its efficacy has not been properly studied in NPC. In a recent study of 15 patients with TACE performed for liver metastasis from NPC^[10], the 1-, 3- and 5-year progression free survival rates were 27%, 7% and 0%, respectively, and the median survival was 4.2 months. Hepatectomy results in a significantly better survival rates and median survival. However, the corresponding post-operatively morbidities are not insignificant,

including pain, fever, and hepatic insufficiency, leading to a longer hospital stay. The aim of the current report is to investigate the role of percutaneous radiofrequency ablation (RFA) as a minimally invasive procedure for patients with oligometastasis in the liver after previous chemoradiotherapy for NPC.

Patients and Methods

The present study was approved by the Institutional Review Board of the University of Hong Kong/Hospital Authority Hong Kong West Cluster. Between 2006 and 2010, four patients were referred to the Division of Head and Neck Surgery, Department of Surgery, Queen Mary Hospital, the University of Hong Kong, for the treatment of recurrent NPC with oligometastasis involving the liver. Clinical data that were retrieved from the Head and Neck Cancer Database included the demographic information, initial and recurrent tumor stage (AJCC 6th Edition), plasma Epstein-Barr virus Deoxyribonucleic acid (EBV DNA) level before and after treatment, complication and disease status.

Pre-treatment Assessment

Flexible nasoendoscopy was routinely performed under topical anaesthesia and any suspicious area would be biopsied for histological confirmation. In patients whose tumor was entirely located in the submucosal plane, examination under anaesthesia and deep biopsy after incising the overlying nasopharyngeal mucosa

would be performed. Plasma Epstein-Barr virus (EBV)-DNA level was measured with real-time quantitative PCR, which identified the *Bam* HI-W fragment region of the EBV genome^[11]. Contrast magnetic resonance imaging (MRI) from the skull base to the neck was crucial to assess the locoregional extent of the tumor, if present. Computer tomography (CT) of the hepatobiliary system with contrast was performed to assess the number and location of the intra-hepatic metastatic tumors, as well as the relationship of the tumor to vital structures, including the diaphragm, bile ducts and the major vasculatures. CT guided fine needle aspiration of the intra-hepatic tumors were performed. PET scan was required to rule out the presence of metastatic tumors in other organs apart from the liver.

Exclusion criteria included the presence of simultaneous and unresectable loco-regional tumors, more than one intra-hepatic metastatic lesion, tumor in close proximity to the major bile ducts, hepatic and portal veins, biochemical or radiological liver cirrhosis, and the presence of metastatic tumors in other organs apart from the liver. A multidisciplinary meeting would be held with the participation of surgeons, clinical oncologists, radiologists as well as the patients and their relatives.

Treatment of Loco-Regional Recurrent NPC

If pre-treatment investigation confirmed the presence of locoregional recurrence, surgical salvage will be performed before the treatment of the liver metastasis. The local tumor in the nasopharynx was resected via the maxillary swing approach^[12]. The Weber Ferguson Longmire incision ipsilateral to the nasopharyngeal tumor was used. After osteotomy, the maxilla was swung out, providing spacious

access to allow resection of the tumor with wide margins. Frozen section examination was employed to make sure the resection margins were histologically clear of tumor. Afterwards, the maxilla was returned and fixed with titanium mini-plates and screws. In patients with nodal metastasis, radical neck dissection was performed.

Radiofrequency Ablation of Liver Metastases

The procedure was performed under sedation using intravenous injection of pethidine (50mg) and midazolam (10-15mg). Artificial ascites was induced by intra-peritoneal injection of normal saline solution. Afterwards, cooltip RFA needle was inserted into the intra-hepatic tumor under ultrasound guidance (Figure 1). Real time ultrasound monitoring was performed during the delivery of energy. After ablation, intensive monitoring of the haemodynamic status was provided in the ward. Blood test for liver function and haemoglobin was checked 6 hours and 12 hours after the procedure.

Post-operative Follow-up

In view of the small volume of recurrent disease and in order to examine the efficacy of percutaneous RFA in disease control, no adjuvant systemic chemotherapy was given in our patients. After discharge from the hospital, endoscopic examination was performed monthly at the out-patient clinic for the first post-operative year, which was spaced out gradually afterwards. Therapeutic response of metastatic liver tumor to RFA was assessed by plasma EBV DNA 1 month after the procedure. It was then serially measured 6 monthly afterwards to monitor the disease status. MRI examination of the nasopharynx and CT scan of the liver was performed every 6 months

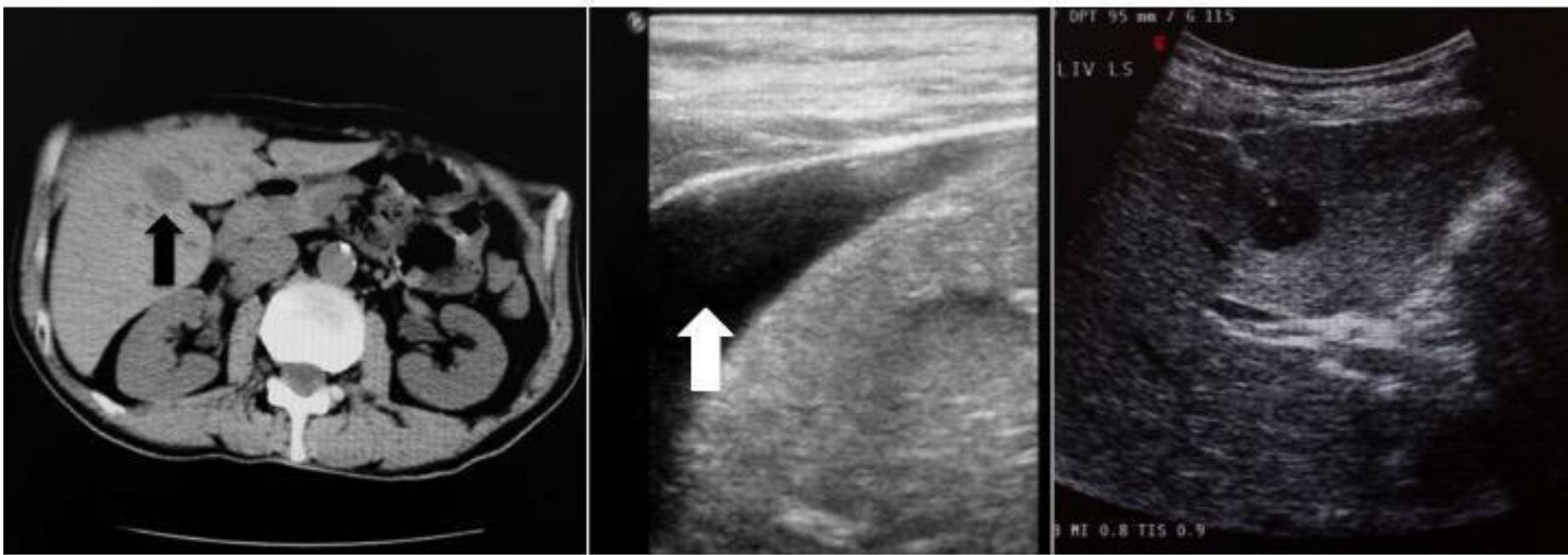


Figure 1. (Left) CT scan showed the presence of solitary liver metastasis (black arrow) measuring 3.2cm in size, located at segment 5 of the liver. (Middle) Before the start of RFA, artificial ascites (white arrow) was created by intra-peritoneal injection of normal saline solution. This was especially important for tumors located in the dome of the liver to prevent collateral damage to the ipsilateral diaphragm. (Right) Afterwards, cooltip RFA needle was inserted under ultrasound guidance. During the delivery of energy, real time ultrasound monitoring was performed.

for the first 2 years to detect tumor recurrence, and then yearly afterwards.

Results

Patient Characteristics : During the study period, 12 patients were found to have liver metastasis after previous radiotherapy for NPC. Eight patients were excluded from the study (multiple organs with distant metastasis, n = 6; multiple metastatic tumors involving both lobes of the liver, n = 2), while the remaining 4 patients with oligometastasis of the liver were recruited into the study. The patient and tumor characteristics were shown in Table 1. All of them were male. Their age ranged from 34 to 55 years. There were 2 patients with initially Stage II and 2 patients with Stage III according to American Joint Committee on Cancer (AJCC, 6th edition). One patient received induction chemotherapy followed by concurrent chemoradiation, while the rest received concurrent chemoradiotherapy alone. None of the patients received adjuvant chemotherapy after the radical treatment. The mean time of diagnosis of tumor recurrence from the completion of radiotherapy was 21.3 months. All tumors were non-keratinizing,

undifferentiated type. The mean plasma EBV DNA level was 442.5 copies / mL (range, 214 to 845 copies / mL).

Two patients had simultaneous tumor recurrence in the nasopharynx and one of them had ipsilateral nodal metastasis as well. These two patients underwent surgical salvage for the locoregional tumors before treatment of the liver metastases. Both patients had complete resection of tumors with microscopically clear resection margins. Mean hospital stay was 9.5 days (7 to 12 days, respectively) and there was no hospital mortality. The mean interval from surgery to RFA for the metastatic liver tumors was 6 weeks.

All the patients had USG guided tru-cut biopsy of the liver tumors and they were confirmed to be metastatic undifferentiated carcinoma. The characteristics of the liver tumors were shown in Table II. The mean size of the tumors was 3.5 ± 0.9 cm (range, 2.8 to 4.4 cm). All the patients received RFA of the liver tumors under sedation. The mean duration of the procedure was 14 ± 2.4 minutes (range, 12 – 16 minutes). The mean hospital stay after the procedure was 2.2 days. None of the patients had derangement of liver function or developed complications related to the procedure performed to the liver tumors.

Table 1 Patients' clinical characteristics.

	Patient 1	Patient 2	Patient 3	Patient 4
Age	34	38	45	55
Sex	M	M	M	M
Initial NPC stage *	T3N3M0	T2N1M0	T2N1M0	T3N2M0
Initial treatment protocol	Induction CT + CTRT	CTRTR	CTRTR	CTRTR
Time to recurrence (months)	14	32	23	16
Recurrent NPC stage *	T2N1M1	T0N0M1	T0N0M1	T1N0M1
Pre-treatment pEBV DNA level (copies / mL)	845	344	214	367

* American Joint Committee on Cancer ([AJCC], 6th edition .

Abbreviations: CT, chemotherapy; CTRTR, chemoradiotherapy; pEBV DNA: plasma Epstein-Barr virus deoxyribonucleic acid

The mean follow-up of the patients was 40.5 months. One patient was diagnosed of multiple bone and bilateral pulmonary metastases at 11 months after RFA and died subsequently from complications of palliative chemotherapy at 13 months after RFA. The rest of the patients were alive and remained disease free at last follow-up. Their pEBV DNA remained undetectable.

Discussion

High incidence of distant metastasis in patients with NPC has long been recognized. It remained the major cause of death, despite the improving locoregional control. Two decades ago, a retrospective review and an autopsy study of patients with NPC has found that the overall incidence of distant metastasis was 36%^[13]. In the report, liver was the most common site of involvement. The authors found a strong correlation with the presence of advanced locoregional disease on presentation. In another study involving 629 patients with NPC, the chance of distant metastasis was 19.8%^[14], among whom, 75% had bone metastasis, 46% had lung metastasis, 38% had liver metastasis, 10% had retroperitoneal nodal metastasis, and 57% of these patients had multiple organs involvement. Majority (95%) of the patients had the distant metastases diagnosed within 3 years after the completion of

radiotherapy [first year (52%), the second year (23%) and the third year (20%)]. The median survival from the diagnosis of distant metastasis was poor, ranging from 3.2 months for hepatic metastasis, 11.2 months for bone metastasis, to 16.3 months for pulmonary metastasis.

With improving techniques of radiotherapy and the availability of new chemotherapeutic agents, treatment of distant metastasis from NPC has been revisited. Prolonged survival of over 82 months was reported in a patient with lung metastasis after radiotherapy for NPC^[15]. In this patient, an intensive chemotherapy regimen was given, including a continuous four-day infusion of cisplatin (20 mg/m²/day), 5-fluorouracil (2200 mg/m²/day) and leucovorin (120 mg/m²/day) every 4 weeks, leading to almost complete disappearance of the lung lesions. In another report, a patient with solitary liver metastasis was treated with neoadjuvant chemotherapy and subsequent concurrent chemoradiotherapy, followed by surgical resection of the liver tumor with segmentectomy. Early assessment at 6-months after surgery showed no signs of local recurrence in the liver or progression of distant metastasis^[16]. In a subsequent study, 15 patients with liver metastasis from NPC were treated by partial hepatectomy, and the

Table 2. Clinical data and outcome of percutaneous radiofrequency frequency ablation of liver metastasis after radiotherapy for NPC

	Patient 1	Patient 2	Patient 3	Patient 4
Size of live tumor	3.2	2.8	4.4	3.6
Location of liver tumor (segment)	5	8	6	6
Mean duration of treatment (minutes)	12	14	14	16
pEBV DNA (1 month after treatment) (copies / ml)	0	0	0	0
Duration of follow-up (months)	13	62	41	46
Liver status at last follow-up	No recurrence	No recurrence	No recurrence	No recurrence
Overall status at last follow-up	Died from multiple bone / lung metastasis	Alive, disease free	Alive, disease free	Alive, disease free

* American Joint Committee on Cancer ([AJCC], 6th edition

Abbreviations: pEBV DNA: plasma Epstein-Barr virus deoxyribonucleic acid

outcomes were compared with another cohort of patients treated by transcatheter hepatic artery chemoembolization (TACE)^[10]. The number of intrahepatic tumors were more than 3 in 20% of the patients, and 46.7% of them had the largest tumor measuring more than 5cm in size. The authors have shown that surgery was associated with a superior 1-, 3- and 5-year overall survival rates. The median survival after hepatectomy was 45.2 months. Five out of 15 patients have survived more than 5 years and the longest survival was 168.1 months. Apparently, with aggressive local and systemic treatment, the outcome of patients with distant metastasis after treatment for NPC, especially for oligometastasis, is not as dismal as previously believed. The concept of oligometastasis was first proposed by Hellman et al. as an intermediate state (≤ 5 metastases) between limited primary and polymetastatic cancers in which local therapy could achieve long-term survival or cure, with no restrictions on primary lesions^[17,18]. Oligo-recurrence was defined as the state that cancer patients have ≤ 5 metastatic or recurrent lesions with controlled primary lesions^[19], while sync-oligometastasis was proposed as the state that cancer patients have ≤ 5 metastatic or recurrent lesions with active primary

lesions^[20]. In recent years, several modifications were made to the TNM staging system for NPC, but these were focused mainly on the T and N components of the system. Based on the evidence that local treatment offers the chance of cure in liver metastases in colorectal cancer, a new M1 staging system that subdivided the M1 classification into 3 subcategories was proposed by the European Colorectal Metastases Treatment Group, and it was accepted and incorporated into the 7th edition of the American Joint Committee on Cancer (AJCC) staging manual^[21]. There were several recent reports investigating the need for modifying the M1 stage of the TNM staging system for NPC. In a retrospective study involving 1016 patients from the Sun Yat-Sen University Cancer Center, 33.96% of patients had solitary organ metastasis and 16.15% had solitary metastatic lesion in the whole body^[22]. The commonest organs of involvement were bone (53.35%), lung (41.34%) and liver (29.72%). It was shown that the state of solitary metastases was one of the independent prognostic predictors for better survival compared with those with multi-organs involvement (HR 0.37, $P = 0.003$). Further study on patients with liver metastasis alone from the same institute showed that the survival rates

were 62% at 1 year, 31% at 2 years and 21% at 3 years^[23].

Multivariate analysis identified less than 3 metastatic lesions in the liver (HR 0.52, $P = 0.004$) and unilobular metastasis (HR 0.35, $P < 0.001$) as the independent predictor for better survival after treatment.

The current investigation is a pilot study of the potential role of percutaneous radiofrequency ablation as a minimally invasive local treatment for oligometastasis to the liver after previous treatment for NPC. All our patient had locoregionally advanced NPC at initial diagnosis but none of them had distant metastasis detected. All of them demonstrated initial complete response, but were found to have either oligometastasis ($n = 2$) or sync-oligometastasis ($n = 2$) after a mean of 21.3 months from previous radiotherapy. All of them had a solitary metastatic lesion in the liver, and the mean size of the intrahepatic lesion was much smaller compared to that of the previous report treated by partial hepatectomy^[10]. In our highly selected group of patients with small and solitary liver metastasis from NPC, RFA appears to be an effective local treatment with minimal morbidities and short hospital stay. The efficacy of the procedure is reflected by the prompt return of the plasma EBV DNA level to normal within 1 month after treatment and the apparent good local control after a follow-up duration of 40.5 months. Apart from 1 patient who died from pneumonia during systemic chemotherapy for multiple bone and lung metastasis, the rest of the patients remained alive and disease free at last follow-up. Systemic treatment after RFA/surgery for the liver tumor is probably necessary for better tumor control, and further study is required to determine the protocol and regimen of chemotherapy in such context.

Conclusion

Percutaneous RFA is potentially useful as a minimally invasive procedure for patients with solitary liver metastasis after radiotherapy for NPC. Further study is required to confirm its efficacy and to define the protocol of adjuvant systemic chemotherapy to improve the treatment outcome.

Funding and Source

This work is supported by the Hong Kong UGC Area of Excellence (AoE) scheme.

Conflict of Interest Disclosures

The authors made no disclosures.

References

1. Luo J, Chia KS, Chia SE, et al. Secular trends of nasopharyngeal carcinoma incidence in Singapore, Hong Kong and Los Angeles Chinese population, 1973 – 1997. *Eur J Epidemiol.* 2007; 22:513-21.
2. Lee AW, Sze WM, Au JS, et al. Treatment results for nasopharyngeal carcinoma in the modern era: the Hong Kong experience. *Int J Radiat Oncol Biol Phys.* 2005; 61: 1107 – 16.
3. Al-Sarraf M, LeBlanc M, Giri PG, et al. Chemoradiotherapy versus radiotherapy in patients with advanced nasopharyngeal cancer: phase III randomized Intergroup study 0099. *J Clin Oncol.* 1998; 16: 1310–1317.
4. Lee AW, Tung SY, Chan AT, et al. Preliminary results of a randomized study (NPC-9902 Trial) on therapeutic gain by concurrent chemotherapy and/or accelerated fractionation for locally advanced nasopharyngeal carcinoma. *Int J Radiat Oncol Biol Phys.* 2006; 66: 142–151.

5. Chan AT, Teo PM, Ngan RK, et al. Concurrent chemotherapy-radiotherapy compared with radiotherapy alone in locoregionally advanced nasopharyngeal carcinoma: progression-free survival analysis of a phase III randomized trial. *J Clin Oncol.* 2002; 20: 2038–2044.
6. Kwong DL, Sham J, Au GK, et al. Concurrent and adjuvant chemotherapy for nasopharyngeal carcinoma: a factorial study. *J Clin Oncol.* 2004; 22: 2643–2653.
7. Wee J, Tan EH, Tai BC, et al. Randomized trial of radiotherapy versus concurrent chemoradiotherapy followed by adjuvant chemotherapy in patients with American Joint Committee on Cancer/International Union against cancer stage III and IV nasopharyngeal cancer of the endemic variety. *J Clin Oncol.* 2005; 23: 6730–6738.
8. Ahmad A, Stefani S. Distant metastases of nasopharyngeal carcinoma: A study of 256 male patients. *J Surg Oncol.* 1986; 33: 194 – 7.
9. Vogl TJ, Zangos S, Balzer JO, et al. Transarterial chemoembolization of liver metastases: Indication, techniques, results. *RoFo: Tortschritte auf Gebiete der Rontgenstrahlen und der Nuklearmedizin.* 2002; 174(6): 675 – 83.
10. Huang J, Li Q, Zheng Y, et al. Partial hepatectomy for liver metastases from nasopharyngeal carcinoma: a comparative study and review of the literature. *BMC Cancer.* 2014; 14: 818 – 27.
11. Lo DYM, Chan LYS, Lo KW, et al. Quantitative analysis of cell-free Epstein-Barr virus DNA in plasma of patients with nasopharyngeal carcinoma. *Cancer Res.* 1999; 59:1188-1191.
12. Wei WI, Lam KH, Shan JS. New approach to the nasopharynx: the maxillary swing approach. *Head Neck.* 1991; 13:200-7.
13. Ahmad A, Stefani S. Distant metastases of nasopharyngeal carcinoma: a stud of 256 male patients. *J Surg Oncol.* 1986; 33(3): 194 – 7.
14. Huang CJ, Leung SW, Lian SL, et al. Patterns of distant metastases in nasopharyngeal carcinoma. *Kaohsiung J Med Sci.* 1996; 12(4): 229 – 34.
15. Chou CW, Liu JM, Wu MF, et al. Prolonged survival in a nasopharyngeal carcinoma patient with multiple metastases: A case report and review of the literature. *Jpn J Clin Oncol.* 1997; 27(5): 336 – 9.
16. Spiros D, Ioannis B, Antonia B, et al. Surgical resection of a solitary liver metastasis from nasopharyngeal carcinoma: a case report. *Hepatobiliary Pancreat Dis Int.* 2006; 5(4): 610 – 2.
17. Hellman S, Weichselbaum RR. Oligometastases. *J Clin Oncol.* 1995; 13: 8 – 10.
18. Weichselbaum RR, Hellman S. Oligometastases revisited. *Nat Rev Clin Oncol.* 2011; 8: 378 – 82.
19. Niibe Y, Hayakawa K. Oligometastases and oligo-recurrence: the new era of cancer therapy. *Jpn J Clin Oncol.* 2010; 40: 107 – 11.
20. Niibe Y, Chang JY. Novel insights of oligometastases and oligo-recurrence and review of the literature. *Pulm Med.* 2012; 261096.
21. Nordlinger B, Van Cutsem E, Rougier P, et al. Does chemotherapy prior to liver resection increase the potential for cure in patients with metastatic colorectal cancer? A report from the European Colorectal Metastases Treatment Group. *Eur J Cancer.* 2007; 43: 2037 – 45.
22. Pan CC, Lu J, Yu JR, et al. Challenges in the modification of the M1 stage of the TNM staging system for nasopharyngeal

carcroma: A study of 1027 cases and review of the literature.

Exp Ther Med. 2012; 4(2): 334-8.

metastasis for nasopharyngeal carcroma to better predict

metastatic survival. Med Oncol. 2011; 28: 1349-55.

23. Pan CC, He N, Zhao M, et al. Subdividing the M1 stage of liver