

How to obtain and identify the acetabular anterior column axial view projection in patients?

Journal of Orthopaedic Surgery

Volume: 25(1) 1–6

© Journal of Orthopaedic Surgery 2017

Reprints and permissions:

sagepub.co.uk/journalsPermissions.nav

DOI: 10.1177/2309499016685012

journals.sagepub.com/home/osj

**Xiaoreng Feng¹, Huijie Fan², Frankie Leung¹, and Bin Chen³**

Abstract

Purpose: This study aims at sharing our experience as how to obtain and identify axial view image of the acetabular anterior column in patients. **Methods:** Pelvic computed tomography data of six normal adults were used to reconstruct three-dimensional (3D) models. The transparency of each 3D model was downgraded at the view perpendicular to the cross section of the anterior column axis to simulate the anterior column axial view image. Fluoroscopy was performed in all patients to obtain the anterior column axial view image in the operating room. Each fluoroscopic image was compared with the corresponding simulation image to analyze potential anatomic landmarks that were helpful to identify the translucent area (projection of the screw path) in the patients. **Results and Conclusions:** To obtain ideal anterior column axial fluoroscopic image, the patient should be positioned supine with the leg of “abnormal side” straight and contralateral side flexion, abduction, and external rotation; the C-arm machine should be placed at the caudal end of the operation table with the C-arm fluoroscopic intensifier first positioned at the pelvic lateral view and then tilted approximately 30° toward the “abnormal side” and rotated approximately 45° toward the caudal end of the operation table. To identify the translucent area on the anterior column axial view fluoroscopic image obtained from the patient, the greater sciatic notch, the true pelvis edge, and the acetabulum should be identified first and the translucent area is located in the area surrounded by these three anatomic landmarks.

Keywords

acetabular fractures, anterior column axial view projection, patient and C-arm position, 3D technology

Introduction

Closed reduction and percutaneous long-screw fixation along the long axis of the anterior column has been recommended for the treatment of nondisplaced or minimally displaced transverse and T-type acetabular fractures,¹ because it is less invasive and avoids high risks of post-operative infection, neurovascular injury, heterotopic ossification, and thromboembolism due to conventional open reduction and internal fixation (ORIF).^{2–4} However, this procedure is technically demanding because of the unique and complex three-dimensional (3D) anatomy of the anterior column. A misdirected or misplaced screw during internal fixation of an acetabular fracture may penetrate the hip joint or damage the neurovascular structures around the narrow column.^{5–7}

To ensure safe insertion of a long screw into the anterior column, the screwing procedure has to be monitored radiographically to avoid iatrogenic neurovascular injury.

Although new 3D computer-assisted guidance has been developed with more advantages,^{8,9} conventional two-dimensional fluoroscopy remains a routine means for many

¹ Department of Orthopedics and Traumatology, Queen Mary Hospital, University of Hong Kong, Pok Fu Lam, Hong Kong

² School of Traditional Chinese Medicine, Southern Medical University, Guangzhou, China

³ Department of Orthopedics and Traumatology, Nanfang Hospital, Southern Medical University, Guangzhou, China

Corresponding authors:

Bin Chen, Department of Orthopedic and Traumatology, Nanfang Hospital, Southern Medical University, No. 1838 North Guangzhou Avenue, Guangzhou 510515, China.

Email: chb@smu.edu.cn

Frankie Leung, Department of Orthopedics and Traumatology, Queen Mary Hospital, University of Hong Kong, 5/f, Professorial Block, Queen Mary Hospital, Pok Fu Lam road, Hong Kong SAR, China.

Email: klleunga@hku.hk

surgeons to monitor the placement of implants in various trajectories for pelvic and acetabular fixation.^{10–12} In the percutaneous screw fixation of the anterior column fractures, traditional radiographic images are obtained at outlet view, inlet view, and obturator-outlet view.^{12–14} Each image plays a very important role in the percutaneous screwing procedure that surgeons have to adjust the positions of a C-arm machine repeatedly to obtain those images intraoperatively. Therefore, more operation time, more blood loss, and more radiation exposure are required.

To overcome the shortcomings of the traditional radiographic images, our previous study¹⁵ and Zheng's research¹⁶ had found and verified it in cadaveric specimens of the pelvis that image projection at the anterior column axial view can show the anterior column screw path as a translucent area and that with the translucent area determined, percutaneously inserting a long screw can be accomplished only with the anterior column axial view projection without adjusting the positions of the C-arm machine repeatedly as surgeons do in conventional procedures.

However, the anterior column axial view images reported in the previous two studies were the images obtained from cadaveric specimens of the pelvis,^{15,16} which might have the following problems in guiding clinical application. First, the specimens were cadaveric pelvis without intact lower limbs that the position of the C-arm in these studies didn't have to consider the interference of the thighs in imaging. Therefore, it is still unknown what position of a patient can facilitate the C-arm imaging in the clinic. Second, the cadaveric pelvis specimens were pelvis treated with formaldehyde for a long time that components of bone and soft tissue were degenerated, which would make their fluoroscopic images quite different from those obtained in a living patient. To correctly identify the translucent area intraoperatively is crucial for the success of the percutaneous screwing operation. On axial fluoroscopic image of a cadaveric pelvis, the anatomic structures and translucent area are clear and very easy to identify. However, images difference could make the translucent area hard to identify on the images obtained in the patient. How to obtain and identify the anterior column axial view image in patient intraoperative is a key step for the anterior column axial view projection come into clinical use. The purpose of this study is to delineate the safety corridor during intraoperative fluoroscopy with 3D technique.

Materials and methods

Data collection

The study protocol was approved by the ethics review board. All the procedures were done in accordance with the Declaration of Helsinki and relevant policies in China. Six patients (3 men, 3 women with mean age of 50.28 years and range of 48–52 years, without pelvic deformity, injury, or lesions) admitted to our institution were recruited in this

study. All patients underwent a 16-line pelvic helical computed tomography scan (GE, Fairfield, CT, USA) with 1.0 mm slices at 0.1 s intervals for pelvic imaging. The raw data obtained were stored in Dicom format in a computer.

Model reconstruction

The raw data sets of each patient were reconstructed into 3D model using the software MIMICS 14.11 (Materialise, Leuven, Belgium). The 3D pelvic model was exported as a STereoLithography (STL) model and then imported into the image-processing software Geomagic Studio 12.0 (Geomagic, US). Then, the inner triangular patches, representing the contents of the marrow cavity, were deleted to make the marrow cavity hollow in the 3D models. Following processing in Geomagic Studio 12.0, the images were exported to an STL model and imported again into MIMICS where all simulations were carried out.

Anterior column axial view projection simulation

To determine the screw path in the 3D models from one single perspective, the transparency of the 3D pelvic model was downgraded and the 3D model was turned at a view perpendicular to the cross section of the anterior column axis. Thus, a translucent area with a darker outline was seen clearly. The translucent area represented the screw path of the anterior column (the projection of the anterior column screw path).

And then, as in our previous study,¹⁵ the position of the 3D model was adjusted carefully to find the largest screw path (translucent area that could accommodate a screw with largest diameter). The image with the largest translucent area showing in the computer was the simulation of the anterior column axial view projection (Figure 1), which would be helpful in identifying and confirming the anterior column axial view image obtained intraoperatively.

Virtual screw position

After the largest translucent area was determined, a virtual computer-aided design screw (6.5 mm in diameter) was placed perpendicular to the screen at the center of the translucent area to make sure the screw was placed in the largest screw path of the anterior column (Figure 1). 3D images reconstructed the skin model of each patient and turned the pelvic model opaque; we could get the relative position of the virtual screw and the body (Figure 2), which would be helpful to guide the initial C-arm position intraoperatively.

Patient and C-arm position

To obtain the anterior column axial view fluoroscopic image, each patient lied supine in a fully radiolucent operation table with the leg of "abnormal side" straight and the leg of the contralateral side flexion, abduction, and external rotation. The C-arm machine was placed at the caudal end

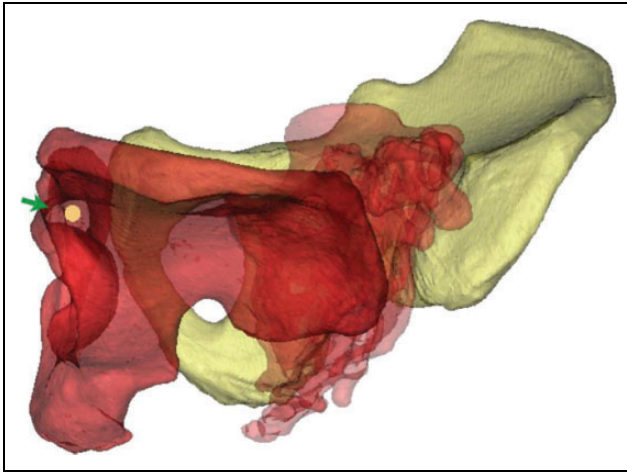


Figure 1. Simulation of the anterior column axial view projection. The transparency of the 3D pelvic model was downgraded at the view perpendicular to the cross section of the anterior column axis (the green arrow points to the translucent area). A 6.5 mm virtual screw was placed in the screw path of the anterior column (the yellow circle represents the screw). 3D: three-dimensional.

of the operation table with the C-arm fluoroscopic intensifier position at the pelvic lateral view. Guided by the relative position between the virtual screw and the body, the C-arm intensifier was first tilted approximately 30° toward the “abnormal side” of the patient and then rotated approximately 45° toward the caudal side of the operation table (Figure 3).

Anterior column axial view projection in patient

With the patient and C-arm position described above, we obtained a fluoroscopic image that was similar to the corresponding simulation image in each patient. We adjusted the position of the C-arm fluoroscopic intensifier carefully until the largest translucent area that represents the screw path show up. The fluoroscopic image with the largest translucent area was defined as the ideal anterior column axial view projection (Figure 4b). Each anterior column axial fluoroscopic image was compared with the images obtained in cadaveric pelvis specimens to analyze the difference between them. Each anterior column axial fluoroscopic image was compared with the corresponding simulation image to find and analyze potential anatomic landmarks that were helpful to identify the translucent area in each patient (Figure 5).

Results

The anterior column axial view images were successfully obtained in all six patients. To obtain the ideal anterior column axial view image, the position of the patient should lie supine with the leg of the abnormal side straight and the leg of the contralateral side flexion, abduction, and external rotation; the C-arm machine should be placed at the caudal

end of the operation table with the C-arm fluoroscopic intensifier first positioned at the pelvic lateral view and then tilted approximately 30° toward the “abnormal side” of the patient and rotated approximately 45° toward the caudal side of the operation table (Figure 3).

Unlike the anterior column axial view images obtained from cadaveric pelvic specimens that the translucent area and anatomy structures were so clear to identify, the fluoroscopic images obtained from the patients were quite ambiguous that it's too hard to identify the corresponding anatomical structure to finally determine the translucent area that represents the screw path (Figure 4). With the help of the simulation image, we found that the translucent area (the projection of the screw path) could be quickly identified through three anatomic landmarks, including the greater sciatic notch, the true pelvis edge, and the acetabulum. The translucent area is just located in the area surrounded by the three anatomic landmarks (Figure 5). The boundary lines of translucent area were the projection of the anterior column superior cortex, the anterior column medial cortex, and the acetabulum.

Discussion

In early 2015, ours and Zheng's study almost simultaneously reported a new fluoroscopic view, anterior column axial view, which can show the anterior column screw path as a translucent area and help to accomplish the percutaneous long screw insertion alone without repeatedly adjusting the C-arm machine position.^{15,16} With the anterior column axial view obtained, the entry point can be determined by locating the guide pin at the center of the translucent area and the inserting direction can be determined when the projection of the guide pin became a point inside the translucent area. After the entry point and direction of the guide pin were determined, the guide pin can be inserted using battery-powered equipment.

However, previous studies gave little information on how to position the patient and C-arm machine to obtain the ideal axial fluoroscopic image. This study found that to obtain the ideal image, the patient should be positioned supine with the leg of “abnormal side” straight and the leg of the contralateral side flexion, abduction, and external rotation; the C-arm machine should be positioned at the caudal end of the operation table and the C-arm fluoroscopic intensifier should be approximately 30° with the coronal plane and approximately 45° with the cross section (Figure 3). The C-arm position described above can be easily obtained through the following steps. First, the C-arm machine was placed at the caudal end of the operation table with the C-arm fluoroscopic intensifier position at the pelvic lateral view, and then the C-arm intensifier was tilted approximately 30° toward the “abnormal side” of the patient and finally rotated approximately 45° toward the caudal side of the operation table. With the C-arm machine positioned at the caudal end of the operation table,

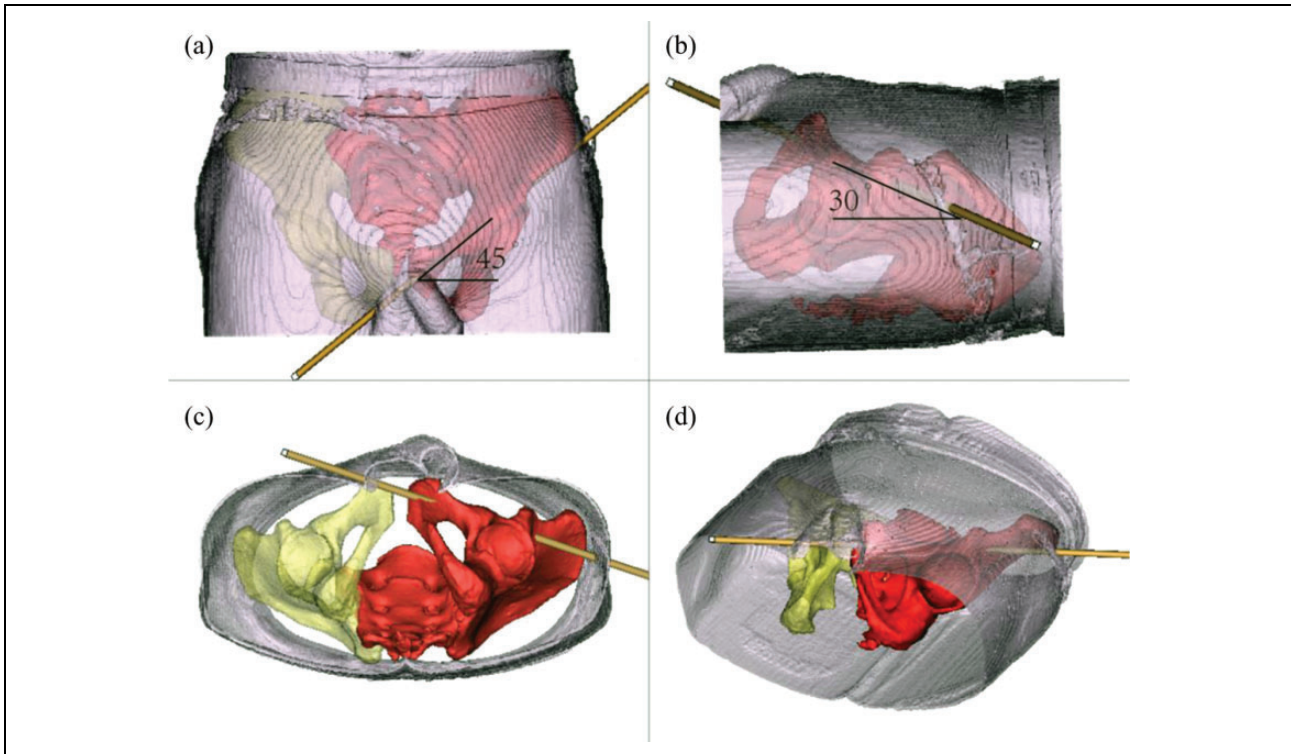


Figure 2. The relative position of the virtual screw and the body.

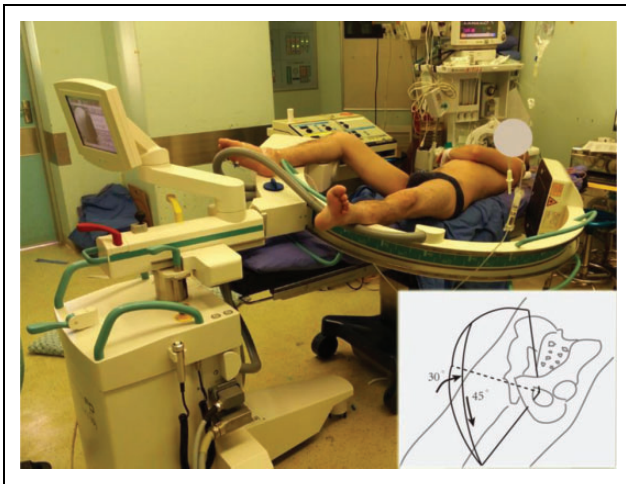


Figure 3. The position of the patient and C-arm to obtain the anterior column axial view image. The patient was positioned supine with the leg of abnormal side straight and the leg of the contralateral side flexion, abduction, and external rotation. The C-arm machine was positioned at the caudal end of the operation table; the C-arm fluoroscopic intensifier was about 30° with the coronal plane and 45° with the cross section of the patient.

its interference to the surgery operation can be avoided. Even though exact C-arm angles of each patient can be calculated through the 3D software in this study, it is very hard to adjust the C-arm to the specified angle intraoperatively. The C-arm position recommended in this study successfully generates a translucent area in all six patients,

respectively. On this basis, the C-arm fluoroscopic intensifier is carefully adjusted to obtain the largest translucent area that represents the largest screw path.

Percutaneously inserting a long screw safely and accurately requires surgeons to be familiar with the fluoroscopic image view. This study found that the fluoroscopic images obtained in all six patients were quite different with that obtained in the cadaveric specimens. Unlike the clear anatomic structure and translucent area that were very easy to identify in the cadaveric pelvic specimen fluoroscopic images, the fluoroscopic images obtained from real patients were quite ambiguous that it was hard to identify the corresponding anatomical structure (Figure 4) to finally determine the translucent area that represents the screw path, making it hard to come into clinical use. To identify the unclear and ambiguous anatomic structure and translucent area from the anterior column axial fluoroscopic images of the patient, this study used 3D technology. By comparing the patient's anterior column axial fluoroscopic images with the 3D simulation image, we found three recognizable corresponding anatomic landmarks, the greater sciatic notch, the true pelvis edge, and the acetabulum. The translucent area is just located in the area surrounded by the projection of the greater sciatic notch, the true pelvis edge, and the acetabulum (Figure 5). With these anatomic landmarks determined, the translucent area that presents the screw path could be identified easily, intraoperatively. The translucent area was surrounded by the projection of the anterior

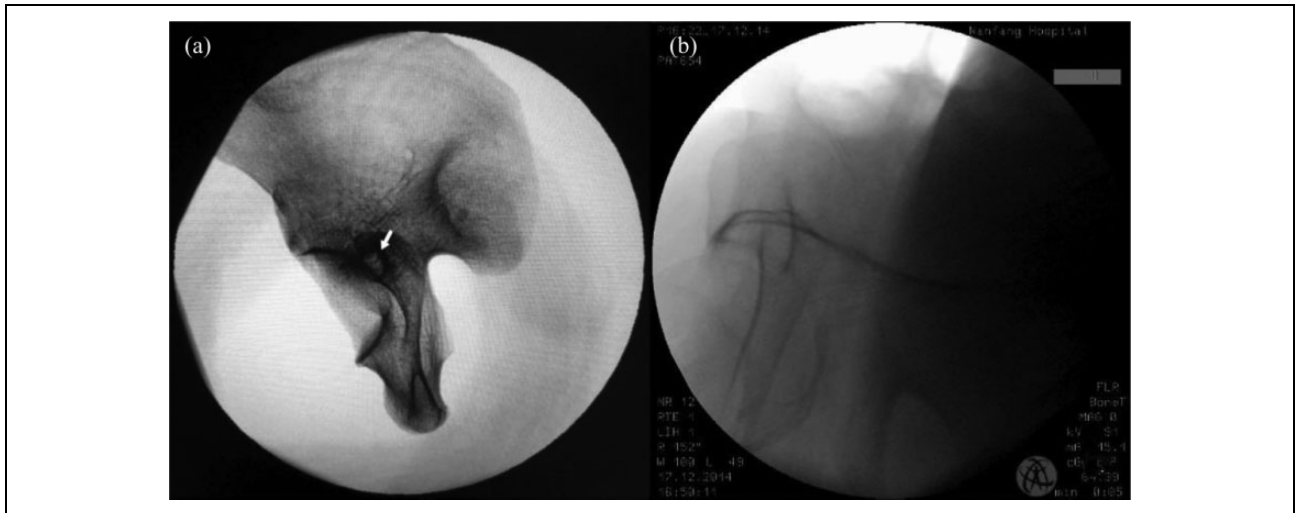


Figure 4. Difference between the anterior column axial view images obtained from cadaveric specimen and patient.

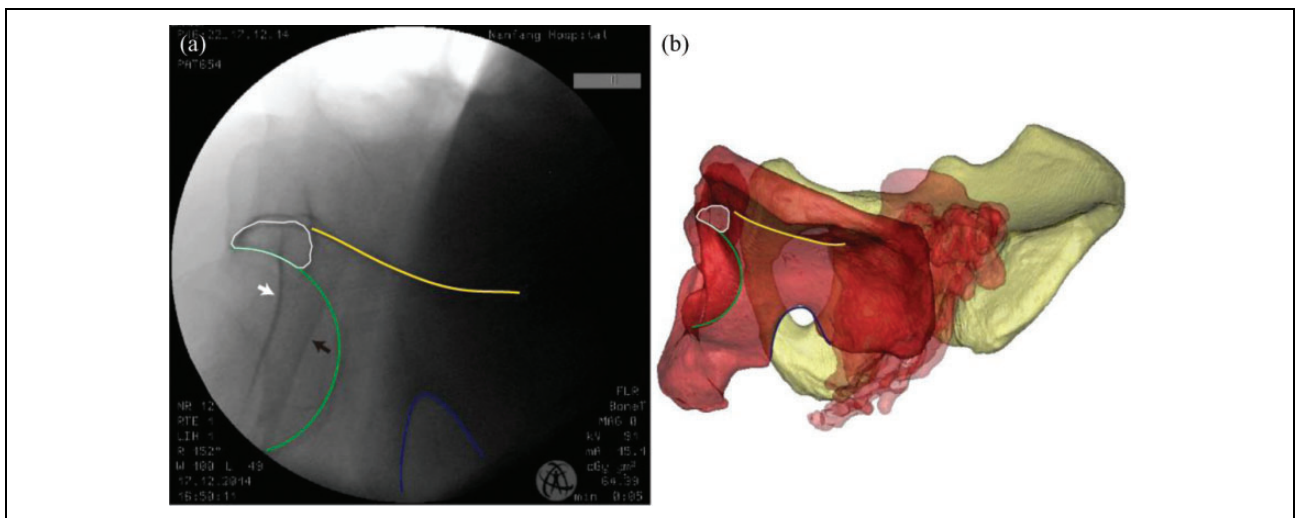


Figure 5. Simulation image (b) helping to illustrate the anterior column axial view image obtained in patient (a). The green lines represent the acetabulum, the yellow lines represent the true pelvis edge, the blue lines represent the greater sciatic notch, the white lines represent the screw path, and the white arrow and black arrow represent the lateral and medial cortex of the inferior ramus, respectively. The lines with the same color represent the same anatomic structure.

column superior cortex, the anterior column medial cortex, and the acetabulum.

Considering that the previous studies had described in detail the percutaneous screwing procedure using the anterior column axial projection alone and reported with a 100% success rate, this study did not choose an anterior column fracture patient as the research object using the anterior column axial view image obtained intraoperatively. However, this study gave detailed information on how to obtain and identify the anterior column axial view image in patients and would lay the foundation for our next clinical application.

Author's Note

Xiaoreng Feng and Huijie Fan contributed equally to this work.

Declaration of conflicting interests

The author(s) declared no potential conflicts of interest with respect to the research, authorship, and/or publication of this article.

Funding

The author(s) disclosed receipt of the following financial support for the research, authorship, and/or publication of this article: This project was supported by the Cultivation Fund of Guangdong College Students' Scientific and Technological Innovation (Climbing Program Special Funds pdjh2016b0101).

References

1. Rommens PM. Is there a role for percutaneous pelvic and acetabular reconstruction? *Injury* 2007; 38(4): 463–477.

2. Matta JM, Anderson LM, Epstein HC, et al. Fractures of the acetabulum: a retrospective analysis. *Clin Orthop Relat Res* 1986; 205: 230–240.
3. Matta JM, Mehne DK and Roffi R. Fractures of the acetabulum. Early results of a prospective study. *Clin Orthop Relat Res* 1986; (205): 241–250.
4. Giannoudis PV, Grotz MR, Papakostidis C, et al. Operative treatment of displaced fractures of the acetabulum. A meta-analysis. *J Bone Joint Surg Br* 2005; 87(1): 2–9.
5. Heeg M, Klasen HJ and Visser JD. Operative treatment for acetabular fractures. *J Bone Joint Surg Br* 1990; 72(3): 383–386.
6. Oransky M and Sanguinetti C. Surgical treatment of displaced acetabular fractures: results of 50 consecutive cases. *J Orthop Trauma* 1993; 7(1): 28–32.
7. Mayo KA. Open reduction and internal fixation of fractures of the acetabulum. Results in 163 fractures. *Clin Orthop Relat Res* 1994; (305): 31–37.
8. Ochs BG, Gonser C, Shiozawa T, et al. Computer-assisted periacetabular screw placement: comparison of different fluoroscopy-based navigation procedures with conventional technique. *Injury* 2010; 41(12): 1297–1305.
9. Behrendt D, Mutze M, Steinke H, et al. Evaluation of 2D and 3D navigation for iliosacral screw fixation. *Int J Comput Assist Radiol Surg* 2012; 7(2): 249–255.
10. Routt ML Jr, Simonian PT and Grujic L. The retrograde medullary superior pubic ramus screw for the treatment of anterior pelvic ring disruptions: a new technique. *J Orthop Trauma* 1995; 9(1): 35–44.
11. Parker PJ and Copeland C. Percutaneous fluoroscopic screw fixation of acetabular fractures. *Injury* 1997; 28(9–10): 597–600.
12. Mouhsine E, Garofalo R, Borens O, et al. Percutaneous retrograde screwing for stabilisation of acetabular fractures. *Injury* 2005; 36(11): 1330–1336.
13. Yi C, Burns S and Hak DJ. Intraoperative fluoroscopic evaluation of screw placement during pelvic and acetabular surgery. *J Orthop Trauma* 2014; 28(1): 48–56.
14. Routt ML Jr, Nork SE and Mills WJ. Percutaneous fixation of pelvic ring disruptions. *Clin Orthop Relat Res* 2000; (375): 15–29.
15. Feng X, Fang J, Lin C, et al. Axial perspective to find the largest intraosseous space available for percutaneous screw fixation of fractures of the acetabular anterior column. *Int J Comput Assist Radiol Surg* 2015; 10(8): 1347–1353.
16. Zheng Z, Wu W, Yu X, et al. Axial view of acetabular anterior column: a new X-ray projection of percutaneous screw placement. *Arch Orthop Trauma Surg* 2015; 135(2): 187–192.