

# We are IntechOpen, the world's leading publisher of Open Access books Built by scientists, for scientists

3,900

Open access books available

116,000

International authors and editors

120M

Downloads

Our authors are among the

154

Countries delivered to

TOP 1%

most cited scientists

12.2%

Contributors from top 500 universities



WEB OF SCIENCE™

Selection of our books indexed in the Book Citation Index  
in Web of Science™ Core Collection (BKCI)

Interested in publishing with us?  
Contact [book.department@intechopen.com](mailto:book.department@intechopen.com)

Numbers displayed above are based on latest data collected.  
For more information visit [www.intechopen.com](http://www.intechopen.com)



---

# Temporomandibular Joint Pathology and Its Indication in Clinical Orthodontics

---

Bakr M. Rabie, Jeremy Ho and Qianfeng Li

Additional information is available at the end of the chapter

<http://dx.doi.org/10.5772/intechopen.72651>

---

## Abstract

Temporomandibular joint (TMJ) pathology has been an area of study in dentistry specifically a research interest in clinical orthodontics in which treatment option has been a dilemma for practitioners. Discussion between 'dos' and 'don'ts' in growth modification has drawn spread however opposite opinions from different schools of thoughts in whether growth modification itself is working. To provide a better illustration of biological process within TMJ, this chapter discussed aspects including overall condylar growth; the histological structure of endochondral bone of condyle; extracellular factors that regulate proliferation, differentiation, hypertrophy, terminal maturation and apoptosis of chondrocytes; and molecular regulation of the entire process. An understanding of the pathology, histology, cellular and molecular events related to the morphology and growth of TMJ forms through reading over this chapter; the emphasis of the mechanotransduction mediators and the influence of mechanical strain on the level of expression of genes were presented in details. Novel studies using virus vector stimulating condylar growth through enhancing angiogenesis within a time limit were discussed; also clinical implications in treatment options in relation to mandibular advancement were briefly compared.

**Keywords:** temporomandibular joint pathology, condylar growth, orthodontics, gene therapy, growth modification

---

## 1. Introduction

More than 700 of 6000 known hereditary syndromes involve dental or craniofacial disorders; temporomandibular disorders (TMDs) are one subgroup [1]. TMDs are a class of musculoskeletal disorders related to mouth opening and closing, chewing and other mandibular processes necessitating the involvement of the temporomandibular joint (TMJ) and any of its associated structures [2]. Currently, one of the most widely used diagnostic criteria remains

to be the RDC/TMJ criteria, axis 1 diagnoses by Manfredini et al. which classifies TMJ cases into one of three categories: musculoskeletal issues [3], TMJ disc displacements and joint pain (arthralgia). There are also other classifications of TMDs which focus on inflammation, injury and systemic conditions (**Table 1**) [3–5].

As TMDs have implications on the quality of life and well-being of affected individuals and their families, it is of major interest to clarify the etiology of TMDs. Several issues have arisen with the understanding of the etiology, treatment options and preventative measures of TMDs. There is a great variability in symptoms of TMDs (ranging from pain and inflammation to limitations of jaw movements) which can even vary in prevalence between genders—as

---

### I. Musculoskeletal issues

**A. Myofascial pain:** pain or ache in the jaw, temples, face, preauricular area or inside the ear at rest or during function and pain in response to palpation of three muscle sites of the mandible with at least one of the painful sites on the same side as the complaint of pain [3, 4]

**B. Myofascial pain with limited opening:** myofascial pain with pain-free unassisted mandibular opening 40 mm and maximum assisted opening (passive stretch) 5 mm greater than pain-free unassisted opening [3, 4]

**C. Ankylosis:** joint stiffness potentially from disease and injury or a consequence of surgery [4, 5] and can be divided into fibrous, fibro-osseous and osseous conditions [4, 5]

### II. TMJ disc displacements

**A. Disc displacement with reduction:** reciprocal clicking in TMJ or clicking in TMJ on both vertical ranges of motion in two of three consecutive trials [3, 4]

**B. Disc displacement without reduction with limited opening:** history of significant limitation in opening, maximum unassisted opening 35 mm, passive stretch increases opening by 4 mm over maximum unassisted opening, contralateral excursion 7 mm or uncorrected deviation to ipsilateral side on opening and the absence of joint sound or joint sounds not meeting criteria for disc displacement with reduction [3, 4]

**C. Disc displacement without reduction, without limited opening:** history of limitation of mandibular opening, maximum unassisted opening 35 mm, passive stretch increases opening by 5 mm over maximum unassisted opening, contralateral excursion 7 mm, the presence of joint sounds not meeting criteria for disc displacement with reduction, imaging conducted by either arthrography or magnetic resonance reveals disc displacement without reduction [3, 4]

### III. Arthralgia, osteoarthritis and osteoarthrosis

**A. Arthralgia:** pain in one or both joint sites during palpation; one or more self-reports of pain; for simple cases, coarse crepitus must be absent [3, 4]

**B. Osteoarthritis of the TMJ:** arthralgia, coarse crepitus in the joint or radiologic signs of arthrosis, classified as a degenerative joint disorder [3–5]

**C. Osteoarthrosis of the TMJ:** the absence of all signs of arthralgia; coarse crepitus in the joint or radiologic signs of arthrosis; classified as a degenerative joint disorder [3–5]

### III. External causes

**A. Inflammation:** can be acute, chronic or, a third option, infectious, which can be nonspecific or specific to a type of disease [3, 4]

**B. Tumors:** can be benign or malignant [4, 5]

**C. Systemic conditions:** include rheumatoid, juvenile and psoriatic arthritis, scleroderma and mixed connective tissue disease [4, 5]

---

**Table 1.** General classification of temporomandibular disorders (TMDs).

### Etiological factors of TMDs

**A. Predisposing factors:** factors of structure (decrease in calibration, disc erosion or improper alignment, patterns of occlusion and bruxism); tissue quality; systemic diseases such as rheumatoid arthritis (RA), gout and fibromyalgia; facial typology; as well as age [5, 7]

**B. Triggering factors:** trauma at the macro and micro levels (e.g. injury to the jaw joint, osteoarthritis), bruxism as well as excess ability of articular tolerance [5, 7]

**C. Perpetuating factors:** underlying behavioral, social and emotional stresses [7]

Table 2. Classification of etiological factors of TMJ [5, 7].

females have been found to be more susceptible to TMDs compared to males [6]. This has resulted in treatment options being too broad or general, such as cognitive behavior therapy, nonsteroidal anti-inflammatory drugs (NSAIDs) and physiotherapy [6]. While there have been efforts for classification of the etiological factors including a widely known classification by de Boever et al. (Table 2) [7], current literature has shifted its focus to anatomical and histological examination of the structures within the TMJ, to identify contributing factors for TMDs, which will be the focus of this chapter.

## 2. Anatomy of the TMJ

The temporomandibular joint (TMJ) is an articular disc between the cranium and mandible and, more specifically, centered within the orofacial system, a functional group of structures which includes the masticatory and stomatognathic systems as well as the maxilla-mandibular apparatus (Figure 1) [5, 8]. The TMJ contains the glenoid fossa, TMJ disc (center, anterior and

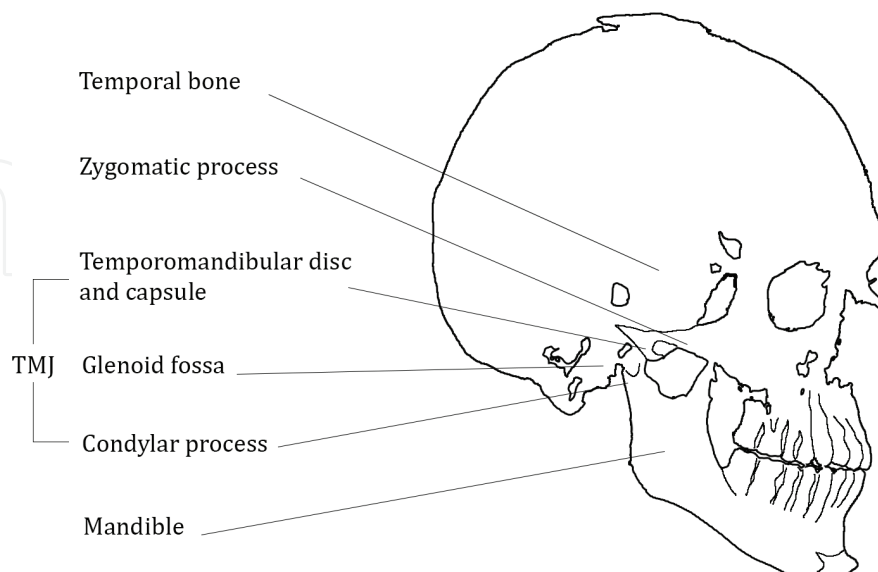


Figure 1. Schematic representation of the TMJ and associated structures in the human skull. The temporomandibular disc and capsule, glenoid fossa, neck of the condylar process and articular eminence (not labeled) are adjacent to each other and comprise the TMJ.

posterior), porous bone and mandibular condyle. It is a synovial joint and is unique in that it is one bone that is composed of two bilateral joints which cannot move independently of each other [6, 9]. Between the two joints is synovial fluid which promotes the hinge and sliding movements of the mandibular condyles required for mouth opening and closing and occlusion of the teeth [6].

The major function of the TMJ includes the coordination of individual tooth positions and other features of the orofacial system [8]. This is accomplished by lateral ligaments which are attached inside of joint capsules, being the structures which stabilize the intra-articular discs [10, 11]. The capsule is surrounded by fibrocartilage (rather than hyaline cartilage) and contrasts in thickness—the anteromedial and medial aspects are thin (0.7 mm), while the lateral and posterior aspects are thick (1.8 mm) [5, 9]. The capsule extends from the glenoid fossa to the neck of the mandible, preventing excessive displacement of the TMJ [5]. The majority of blood supply originates from the trail of superficial temporal, superior articular, anterior tympanic, and pterygoid arteries [5].

### **2.1. Glenoid fossa**

The glenoid fossa is a concave portion of the temporal bone [8]. It borders the articular eminence anteriorly and the tympanic plate posteriorly [5, 9]. The glenoid fossa, similar to the disc and condyle, is a site of angiogenesis when subjected to mechanical stimuli [5, 9]. However, its histological composition has striking differences. Histological examination of the glenoid fossa has recorded fewer posterior layers of chondrocytes than the condyle. As chondrocytes are involved in chondrogenesis in the formation of cartilage to support the growth of the bone by means of endochondral ossification, the glenoid fossa may undergo a reduced level of endochondral ossification and a greater level of intramembranous ossification [5].

### **2.2. TMJ disc**

The disc is fibrocartilaginous and biconcave and takes on a bow-tie morphology [5]. The two ridges of the disc are referred to as bands which attach to different structures. The smaller and shorter anterior band connects with the joint capsule, condylar head and articular eminence [5]. On the other hand, the larger and longer posterior band attaches to the condyle and the temporal bone [9]. The disc attaches to the capsule and neck of the condyle medially. The disc facilitates jaw opening in which the disc moves between the head of the mandible and the articular eminence [5].

### **2.3. Mandibular condyles**

The articular surface of the mandible borders the anterior surface of the mandibular condyles [12]. The mandibular condyles are structures of the human mandible, covered with fibrous tissue composed of predominantly type I collagen, which present a surface for interaction with the articular disc of the temporomandibular joint, composed of avascular fibrous tissue including collagen and fibroblasts [12]. Below this resting, the fibrous layer of the condyles is four layers of cartilage: the proliferative, chondroblast, hypertrophic and erosive layers [12].

Extending further posteriorly than anteriorly, the condyles are convex laterally with a long axis situated medially and partially backwards [13]. The convex lateral extremities of the condyles are connected to small tubercles for attachment to the ligament of the TMJ [13].

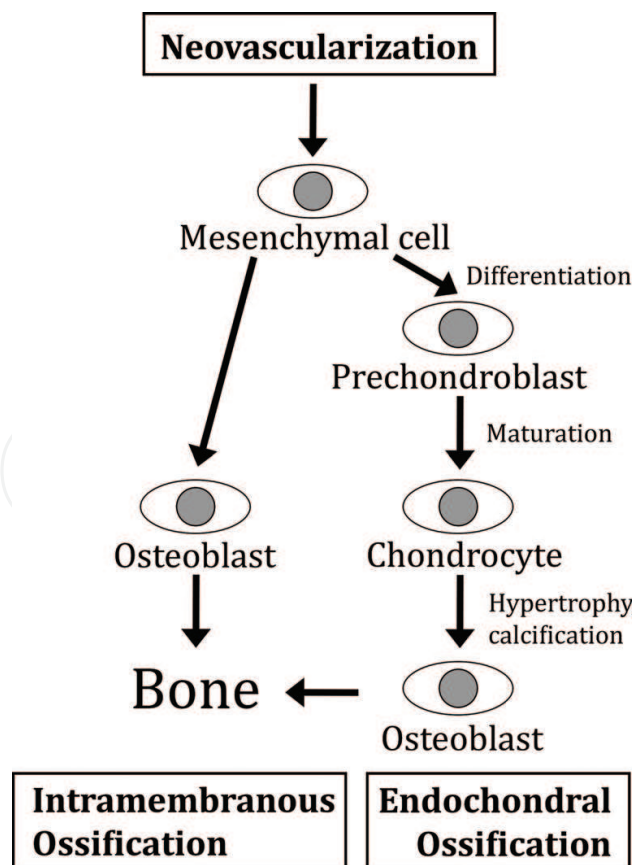
Human condyles grow to 15–20 mm laterally and 8–10 mm anteroposteriorly in adulthood [5]. The growth of condyles is attributed to the condylar cartilage which acts as a template for bone growth [12]. The mandibular condyles are unique in that the cartilage (predominantly type II collagen) is known as secondary, compared to main and primary cartilage [12]. Another categorization of the condylar cartilage is articular [14]. However, unlike other types of the articular cartilage such as the synovial or epiphyseal cartilage, it has a striking difference of undergoing adaptive changes in response to external stimuli including mechanical or positional changes (e.g. repositioning of the condyles and/or the mandible, the functioning of the articular discs and the mechanical loading of the condyles) [15–17]. Some of the adaptive changes are related to growth and remodeling such as endochondral ossification and altering or regenerating chondrogenesis [14]. While these changes can occur during or after the natural growth period, there has been study that in adult rats, the remnant condylar cartilage serves more ‘articular’ function than ‘growth’ function as the adult rat condyle stops growth or becomes inactive of endochondral ossification [14]. Additionally, Luder studied adult human condyle structures and found that the cellular layers of organization did not resemble that of growing condyles and attributed the discrepancy to articular remodeling from mechanical loading [18]. As it was determined that articular tissue differed considerably between areas of loading and non-loading, Luder proposed that adult condyles should be divided differently and into three zones of organization—superficial, intermediate and deep [18]. Luder completed a follow-up study and found that features of the articular tissue in the condyles were subject to changes based on age [19]. Most tissue features were altered between 15 and 30 years of age and generally remained stable beyond this age range [19]. During this time, there was a progressive cartilaginitis of the newly formed superficial zone, disappearance of the hypertrophic growth plate, appearance of the grid-fibrous fibrocartilage accompanied by a decline in endochondral ossification as well as formation of the subchondral bone plate [19]. From middle age to older age, there was a decrease in cellularity and some senescence and a progressive fibrosis of the intermediate zone. It was determined that the extent of maturation and remodeling and changes experienced in later age were related to articular load bearing [19].

Recently, there has been a spotlight on the mandibular condyles as major contributing factors to TMDs. As active growth sites of the mandible, impaired growth of the condyles has been associated with the development of TMDs [14]. Impairment of condylar development can result in mandibular asymmetry (e.g. hemifacial macrosomia and retrognathia) and problems in mastication, breathing and facial harmony which can lead to the onset of TMDs [14]. As it is evident that the etiological causes of TMDs are multifactorial, an evaluation of the influences and treatment options in the context of condylar growth is of great importance for affected individuals and their respective practitioners. Of major interest in condylar growth is the condylar cartilage for its influence in the growth of the mandible and its adaptive remodeling of the condyles in orthodontic intervention [14]. An understanding of the process of condylar growth and the involvement of cartilage in growth is therefore essential.

### 3. Steps in mandibular condylar growth

Given the fact that the anatomy of the condyles is clinically relevant in addressing TMDs, it is of importance to distil the major steps and cell types involved in the condylar growth process. There are two major processes involved in the growth of the mandibular condyles: chondrogenesis (cartilage formation) and osteogenesis (bone formation).

Mesenchymal cells eventually undergo one of two processes of osteogenesis by means of endochondral or intramembranous ossification, the latter of which is completed in the absence of the cartilage (**Figure 2**). In the former process, the mesenchymal cells will first differentiate into prechondrocytes which will mature into terminally hypertrophic chondroblasts [20–22]. This sequence of steps is collectively known as chondrogenesis. The chondroblasts eventually calcify and die, resulting in the bone replacing the cartilage by the bone through the invasion of osteoprogenitors which differentiate into osteoblasts [20]. This final step is known as endochondral ossification [23, 24]. Conversely, in intramembranous ossification, mesenchymal cells recruited from neovascularization migrate to the subperiosteal connective tissue and directly differentiate into osteoblasts to give rise to new bone (**Table 3**) [25].



**Figure 2.** Schematic of the effects of VEGF during chondrogenesis, neovascularization and osteogenesis.

---

### I. Chondrogenesis: mesenchymal cells

**A. Fibrous layer** [20]: differentiation into prechondroblasts [20]; can replicate up to  $38 \pm 4$  times, and its quantity (dictated by various cellular and molecular factors) influences the growth potential [21, 26]; affected by mechanical forces [27]

**B: Proliferative layer** [21]: differentiates into chondroblasts and chondrocytes to maintain cartilage [21, 22]; affected by mechanical forces [27]

**C: Erosive layer** [21]: recruited with neovascularization and migrates to the subperiosteal connective tissue to directly give rise to osteoblasts through intramembranous ossification for the remodeling and repair of the bone [12, 21, 25, 28]

### II. Chondrogenesis: prechondroblasts

**Proliferative layer** [12]: expresses type II collagen [12]; multipotential—can switch to differentiation of osteoblasts if articulate functioning is limited which can increase growth as articulate functioning retards growth versus condylar unloading which stimulates growth [23]

### III. Chondrogenesis: hypertrophic chondrocytes

**Hypertrophic layer, erosive layer** [29–32]: maturation facilitates the transition from chondrogenesis to osteogenesis to serve as a regulatory point for growth [33], impacts cartilage formation and influences the growth of the condyle [34]; intercellular matrix calcification inhibits diffusion of nutrients, ultimately causing the death of the hypertrophic chondrocytes [20]

### IV. Neovascularization

Refer to 3.1.

#### Va. Osteogenesis: endochondral ossification

**Beneath erosive layer** [20]: facilitates postnatal condylar growth and replaces degrading cartilage with the bone [20]

#### Vb. Osteogenesis: intramembranous ossification

**Subperiosteal connective tissue** [25]: unlike endochondral ossification, the cartilage is not present with this process of ossification which also serves the purpose for forming new bone [25]

---

**Table 3.** Analysis of the major processes involved in condylar growth and the corresponding stages within each process.

### 3.1. Neovascularization

Neovascularization is an essential step in endochondral or intramembranous ossification which occurs in the hypertrophic and erosive layers of the condylar cartilage as well as the glenoid fossa and the TMJ disc [28]. It is quantitatively correlated with endochondral ossification and is an indicator of osteogenesis in the replacement of dying cartilage with new bone [20]. Neovascularization functions by replenishing the population of mesenchymal cells for osteogenesis as blood vessels are the regions where progenitor cells are able to diffuse out and into the surrounding tissues [28].

While neovascularization has been determined to play a major role in condylar bone formation, it is of future interest to investigate the glenoid fossa and the TMJ disc, regions also characterized by mesenchymal cells and chondrocytes [5], as additional potential regions of neovascularization and subsequent bone growth. However, irrespective of anatomical location, an understanding of the factors influencing each of the steps in bone growth in the condyles and its associated regions is of major relevance for improving the management of TMDs.



## 4. Factors influencing condylar growth

Factors influencing the growth of condylar cartilage can be categorized into cellular (**Table 4**) and molecular factors (**Table 5**).

### 4.1. Factors at the cellular level

Cellular factors can be defined as factors that exert their activity at the extracellular level, including growth factors, cytokines, extracellular matrix (ECM) and other types of proteins. Growth factors and cytokines serve as local mediators in response to mechanical and inflammatory stimuli, while ECM serve as intercellular structural support [14].

---

#### I. Growth factors

**A. Insulin-like growth factor (IGF):** found in chondrocytes [35, 36], mediates growth and development of the cartilage and bone [14, 37]

**B. Fibroblast growth factor (FGF):** found in proliferating and chondroblast layers [14, 36]; regulates skeletal development and postnatal osteogenesis (e.g. FGF-2 promotes angiogenesis, inhibits the terminal differentiation of chondrocytes and reduces the formation of the bone) [14]

**C. Vascular endothelial growth factor (VEGF):** refers to 4.1.1

**D. Connective tissue growth factor (CTGF):** found in hypertrophic layer [38], regulates cartilage ECM and VEGF-A expression [38]; CTGF null or deficiency impairs endochondral ossification [39]

#### II. Cytokines

**A. TGF- $\beta$ :** found in site of endochondral ossification, articular cartilage and growth plate [40, 41]; stimulatory and inhibitory roles dependent on concentration, culture period and state of cellular differentiation [42–44]; generally inhibits chondrocyte maturation and hypertrophy and alkaline phosphatase activity [45–47]

**B. Bone morphogenetic protein (BMP):** BMP-2 and BMP-4 are involved with cellular proliferation by regulating endochondral ossification [48]; activity of BMP-2 can be inhibited by Wnt signaling [14]

#### III. Extracellular matrix

**A. Type II collagen:** supports cartilage formation [12]

**B. Type III collagen:** regulates bone repair and development [49]; cross links are weaker than type I collagen and therefore can support replacement by type I collagen in remodeling [28]

**C. Type X collagen:** short-chain collagen [20]; correlated to the hypertrophic phenotype and marks the transition to osteogenesis [20]

#### IV. Other proteins

**A. Parathyroid hormone-related protein (PTHrP):** refers to 4.1.2

**B. Indian hedgehog (Ihh):** refers to 4.1.3

**C. Matrix metalloproteinases (MMP-1, MMP-9):** found in hypertrophic layer [50]; mediates the transition to osteogenesis, angiogenesis and further proliferation of the hypertrophic chondrocytes [20, 50]; facilitates remodeling of the bone by degrading matrix [51]

---

**Table 4.** Analysis of the cellular factors involved in condylar growth and, if applicable, the localizations of its respective activities.

---

### I. Transcription factors

**A. Core binding factor A1 (CBFA1):** found in erosive layer [21]; essential for chondrocyte differentiation as the earliest regulator of transcription [21, 68, 69] can induce premature hypertrophy of chondrocytes [68]; mediates VEGF-A in endochondral ossification as its overexpression increases VEGF expression [38, 70]

**B: SOX-9:** refers to 4.2.1

### II. Novel genes specific for condylar growth

**A. Mustang, alpha B-crystallin (CryAB):** associated with increased mesenchymal cell and osteoblast differentiation in response to mechanical strain [64]

**B: Noggin:** prevents apoptosis of chondrocytes [71]

**C: Chondroadherin (CHAD):** increases type II collagen expression in response to mechanical strain [64]

**D: Nephroblastoma overexpressed (NOV):** improves cartilage formation and integrity by positive modulation of type X collagen [64]

### III. Other proteins

**A: Wnt family:** found in proliferative and hypertrophic layers [72]; controls mesenchymal cell differentiation into chondrocytes (e.g. Wnt1 and Wnt7a block chondrocyte differentiation, while Wnt4 blocks chondrogenesis but accelerates chondrocyte differentiation) [72–74]

**B: Proliferating cell nuclear antigen (PCNA):** found in hypertrophic layer [14]; increases the DNA replication of mesenchymal cells and is the marker for cell proliferation [14]

**C: D-type cyclins:** ‘gatekeeper’ of the G1 phase of the cell cycle which regulates the DNA replication of mesenchymal cells [72]

---

**Table 5.** Analysis of the molecular factors involved in condylar growth and, if applicable, the locations of its respective activities.

#### 4.1.1. Vascular endothelial growth factor (VEGF)

VEGF is one of the most prominent regulators of mandibular condylar growth. It is found mainly in the hypertrophic layer of the condylar cartilage [24, 28, 52, 53], but traces have been discovered in the proliferative layer [54]. VEGF serves multiple functions in supporting the growth of the condyles including the coordination of the death of chondrocytes, function of chondroblasts, remodeling of ECM, secretion of growth factors and cytokines, angiogenesis as well as formation of the bone [12, 25, 26, 55].

Observing each of the functions of VEGF in greater detail, the coordination of chondrocyte death is accomplished by guiding of mesenchymal cell differentiation towards osteogenesis by bringing the cells to the mineralization front for calcification [24, 56, 57]. Additionally, VEGF-A has been the main isoform which facilitates the progression of angiogenesis [12]. VEGF in general supports rapid vascularization essential to healing and induction of bone associated with bone matrix that has been demineralized [58]. With respect to supporting bone formation, VEGF has been noted to increase mandibular length, and its expression has been correlated with the quantity of newly formed bone in the posterior of the condyle [12]. It is therefore evident that VEGF is a major therapeutic target of interest in research towards regulation of condylar growth.

#### 4.1.2. Parathyroid hormone-related protein (PTHrP)

Another major regulator of condylar growth, PTHrP, is found in the transition zone between the proliferative and hypertrophic layers [59, 60]. It controls the condylar bone formation by facilitating and mediating the biomolecular pathway through which chondrogenic phenotype is shifted to osteogenesis [20]. This is accomplished by slowing down the hypertrophy of mature chondrocytes to promote further maturation and to provide more time to develop the cartilage in preparation for osteogenesis [33, 61]. By promoting further maturation and delaying the transition from chondrogenesis to osteogenesis, the population of chondrocytes continues to rise, leading to an increase in cartilage volume and subsequently bone formation.

Additionally, PTHrP induces the differentiation of mesenchymal cells through SOX-9, a transcription factor which serves to positively regulate the growth of the condyles [33].

#### 4.1.3. Indian hedgehog (Ihh)

Compared to other factors at the cellular level, Ihh functions as a highly dynamic mechano-transduction factor which increases in expression in response to mechanical stimuli [12]. It is expressed by prechondroblasts and early hypertrophic chondrocytes in the proliferative layer [12, 62]. Ihh has a variety of effects on the TMJ and condyles including supporting early development [63] by regulating mesenchymal cell and chondrocyte proliferation and cartilage development (most notably type II collagen) in chondrogenesis as well as the transition to osteogenesis under mechanical strain [34, 64–66]. Interestingly, Ihh can also function as a molecular factor by shortening the turnover and enhancing the renewal of condylar cells [34] by upregulating cyclin D1, the ‘gatekeeper’ of the transition from the G1 to the S phases of the cell cycle [65, 67].

#### 4.1.4. PTHrP/Ihh negative feedback loop

Rabie et al. postulated that PTHrP and Ihh activities are linked through a negative feedback loop which regulates the development of the growth plate [5]. In the feedback loop, when PTHrP production is fleeting and not sufficiently stimulating chondrocytes, chondrocytes stop proliferating and maturing [66]. The chondrocytes begin to synthesize Ihh in the hypertrophic layer which acts on the chondrocytes by means of receptor-mediated signaling [66]. Ihh increases the proliferative rate of the chondrocytes and stimulates the production of PTHrP at the terminus of the bone. PTHrP then maintains the chondrocytes in a proliferative state and delays further maturation and differentiation which delays Ihh production [34]. As a result, the PTHrP/Ihh negative feedback loop modulates the pace of proliferation and differentiation of the chondrocytes to regulate cartilage and eventual bone formation [12].

### 4.2. Factors at the molecular level

Molecular factors can be defined as factors that operate within the cell by means of genetic and other intracellular factors. Such factors can be categorized into transcription factors, novel genes specific for condylar growth and other intracellular proteins. Transcription factors control genetic expression, while intracellular proteins control signal transduction and cell cycling pathways.

#### 4.2.1. SOX-9

Targeted in PTHrP signaling, SOX-9 is a transcription factor that regulates the differentiation process from mesenchymal cells to hypertrophic chondrocytes [12]. Additionally, SOX-9 prevents premature differentiation and regulates type II collagen synthesis and cartilage formation through activation of the enhancer region of Col1a2 and Col2a1 [20, 75–77]. It is able to accomplish its activities by recognizing the DNA sequence of CCTTGAG and other members of the high mobility group (HMG) box class of DNA-binding proteins [71].

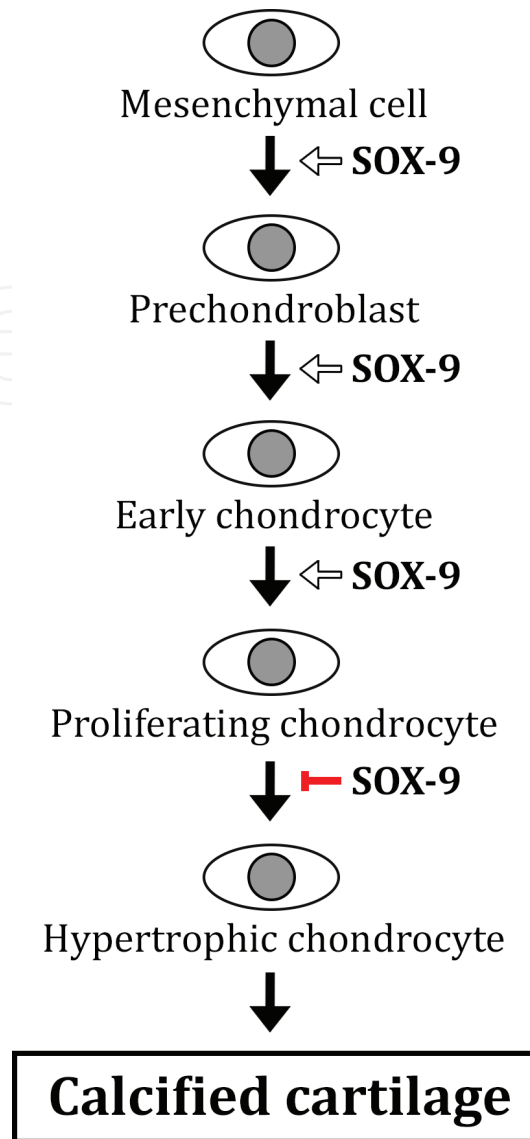
To understand how SOX-9 facilitates differentiation, it is vital to recognize that SOX-9 is expressed in mesenchymal cells, prechondroblasts and early differentiated chondrocytes but not in hypertrophic chondrocytes [78]. In mesenchymal cells, SOX-9 is required for differentiation into prechondroblasts. Later in the prechondroblast stage, SOX-9 supports the proliferation and further differentiation into early and proliferating chondrocytes. At the same time, SOX-9 regulates the expression of Noggin, an anti-apoptotic gene to support the proliferation of the chondrocytes [71]. After this stage, SOX-9 inhibits the transition from proliferative to hypertrophic chondrocytes to control subsequent endochondral ossification. Overall, SOX-9 is involved in cell proliferation of successive cell types in the earlier stages of chondrogenesis, but it also serves to prevent the hypertrophy of chondrocytes (**Figure 3**).

## 5. Interventions to address condylar growth

Given the working understanding of the stages and factors involved in condylar growth, researchers have found the condyles to be clinically relevant to the development and morphology of the orofacial complex [14, 20]. The condyles have been studied as a therapeutic target in addressing TMD and craniofacial issues in general. Two leading interventions to reactivate and control condylar growth have been the use of the recombinant adeno-associated virus (rAAV) vector and the application of mandibular advancement orthodontic appliances.

### 5.1. Intervention by the rAAV vector

The rAAV vector has become of interest in *in vivo* TMD therapy as it has been shown to overcome many limitations involved in the gene therapy of the cartilage and bone [79, 80]. Some advantages of the vector include reduced pathogenicity and immunogenicity, which supports long-term expression of transgenes which can be restricted to defined anatomical locations including specific oral tissues and success in transfecting many types of dividing and nondividing cells due to its size of 22–25 nm [55, 79, 81]. At this small size, rAAV-VEGF has been demonstrated as a suitable *in vivo* vector to significantly induce condylar growth by diffusing through the layers of the cell surface and infect with regular and hypertrophic chondrocytes to promote VEGF-mediated growth [79]. The systemic safety of the rAAV-VEGF vector has also been studied as exogenous VEGF was not identified in reverse-transcribed RNA samples of remote organs (e.g. heart, spleen and kidney) of transfected subjects [79].



**Figure 3.** The roles of SOX-9 in each successive step of chondrogenesis towards endochondral ossification in the condyles. SOX-9 functions to commit mesenchymal cells to differentiate into prechondroblasts and supports the transition of prechondroblasts to early and proliferating chondrocytes but inhibits hypertrophy of the chondrocytes prior to the calcification of the cartilage.

Rabie et al. investigated the effect of *in vivo* rAAV-mediated VEGF administration on female Sprague–Dawley rats and found increases of the length of the condylar process axis (B-F) and the mandibular length from day 30 post-surgery and beyond [55]. The condylar width and length also increased during the same time period [55]. The growth of the condyle was upwards and backwards such that the greatest cellular response was found in the posterior condyle compared to the anterior surface [55]. This supported the adaptability of the condyle in directional changes in the growth of the mandible [24]. In addition, other studies have found a gain of function of VEGF, or VEGF gene has been associated with increases in neovascularization and regeneration of the bone in defective condyles [82, 83]. This has also reinforced the significance of rAAV-mediated VEGF as an appropriate option in contributing to neovascularization and endochondral ossification [28].

Most notably, it was determined that there was a delay in morphological effects of rAAV vector such that VEGF levels were increased on day 14 while chondrogenesis and osteogenesis occurred on days 21 and 30, respectively [55]. This finding had clinical implications in terms of understanding that gene therapy required a careful balance of inhibition or reinjection of the viral vector to address the potential consequences of overgrowth or relapse [55].

## 5.2. Intervention by mandibular advancement orthodontic devices

Recently, it has been proposed that condylar growth can be induced by forward mandibular advancement which has been noted to mirror natural growth [21]. Animal studies of mandibular advancement treatment on rats have reported the enhancement of chondrocyte maturation and endochondral ossification which give rise to new bone and condylar growth [84].

Three major factors of consideration include the age of the patient, the length of the treatment and stepwise versus single-step mandibular advancement. First, there have been recommendations of using functional appliances during or after the peak pubertal period to observe the greatest stability of treatment results [85–87]. Second, recommendations have been made to extend the commonly studied period of mandibular advancement of 6 months to 1 year in order to support the maturity of type I collagen [88–90]. Two other separate studies also noted that the treatment length was correlated to the maintenance of the effects of the orthodontic intervention [91, 92]. However, there have been mixed conclusions on the effect of lengthening the treatment period. Hagg et al. and Phan et al. found opposing trends of the length of treatment on the maxilla and the mandible, increasing the effect for the former and decreasing the effect for the latter [93, 94].

### 5.2.1. Stepwise versus single-step mandibular advancement

There has been extensive literature for the comparison of two approaches of mandibular advancement: stepwise versus single-step advancement. Currently, stepwise advancement has been determined as being the preferable therapy.

One of the reasons supporting stepwise advancement is the improvement in skeletal effect, most notably the sagittal jaw relationship with the maxilla, assuming a more forward positioned mandible due to more growth than single-step advancement [21, 95]. This improvement may be attributed to work completed by Petrovic et al. who found that the forward repositioning of the mandible periodically increases the rate and amount of growth in the condylar cartilage [96]. Van Lam and Rabie also found that stepwise treatment was correlated with significantly greater new bone formation [21].

From a cellular and molecular perspective, stepwise advancement that exceeded a minimum threshold of mechanical strain resulted in increases in *Ihh*, type II collagen, PTHrP and VEGF [34, 57, 97–100]. Thus, stepwise treatment involves repeated cycles of mechanical strain and increases neovascularization which results in increases in eventual new condylar bone formation [57]. Studies have shown that manipulating the amplitude of mechanical strain by stepwise advancement can significantly impact VEGF production by chondrocytes [55]. Moreover, the later stages of stepwise treatment are responsible for more VEGF production

and subsequent condylar bone formation [57]. The extent of condylar growth modification from mandibular advancement has been determined through changes in measurements of the condyle and documented effects at the cellular and molecular levels (**Table 6**).

One modality of stepwise advancement in orthodontic treatment is the Herbst appliance; due to the advantages of stepwise treatment, it has been recommended to be included in an

---

### I. Chondrogenesis

**A. Mesenchymal cells:** increase in quantity and rate of replication which is correlated to increased bone formation [12, 101]; cells deformed and oriented in the direction of the strain in the proliferative layers [84]

**B: Prechondroblasts:** reactivation of cells and chondrogenesis to promote growth of the condyle [12], which leads to an increase of osteogenesis [102, 103]

**C: Hypertrophic chondrocytes:** enhances but does not accelerate (a point that has not been clarified) [104] the hypertrophy of the cells towards osteogenesis [23]

**D: Neovascularization:** increased by means of VEGF expression which preceded the peaks of chondrogenesis and osteogenesis [55]; angiogenesis in the erosive layer during the enhanced, not accelerated (a point that has not been clarified) [104], transition towards osteogenesis [23]

### II. Osteogenesis

**Endochondral ossification:** reactivation in the posterior aspect of the condyle leading to formation of new bone [12]

### III. Cellular factors

**A. IGF:** increases expression of IGF-I and IGF-II [105]

**B. VEGF:** refers to 'neovascularization' in I (chondrogenesis)

**C. Type II collagen:** increases in expression [104]

**D. Type X collagen:** 540% increase in the posterior condyle which is correlated with 319% increase in bone formation [102, 106] by means of a similar temporal pattern when compared to natural growth [23]; maximal expression coinciding with that of Cbfa [88]

**E. PTHrP:** increases in expression which is associated with an increase in new chondrocyte population level [33]

**F. Indian hedgehog (Ihh):** immediate increase in expression due to deformation of the ECM and subsequent cellular cytoskeleton [62, 84, 107]; mechanical strain can reactivate dormant condylar growth [12], but the extent of reactivation of the condyle and glenoid fossa reduced with increasing age [108–110]; promotes chondrocyte proliferation, increased expression of cyclin D [72]

### IV. Molecular factors

**A. Cbfa1:** upregulation of expression despite similar pattern of expression, coinciding with the maximal expression of type X collagen [21]

**B. SOX-9:** increases in expression which increased mesenchymal cell commitment to endochondral ossification [12, 33]

**C. Novel condylar genes:** increase in expression of Mustang, CryAB, NOV, Noggin and CHAD [64]

### V. Morphology

**Mandibular condyles:** bending of the bone elongates [111, 112] the length and width of the condylar process and length of the mandible [55] with most change in direction posteriorly [24, 55]; there is potential to target the superior condylar layer to regulate upward condylar growth [55]

---

**Table 6.** Analysis of the factors affected by means of orthodontic mandibular advancement.

orthodontist's armamentarium [72]. The Herbst appliance has been evaluated with young adult patients and has yielded promising results in the treatment of Class II malocclusion [12]. It has been identified to operate by reactivating prechondroblast activity [12]. However, Pancherz has found several limitations of the Herbst appliance. The appliance has been met with concerns of relapse in cephalometric angle measurements after treatment [88, 90]. Additionally, it is most effective with Class II cases and thus cannot be used by individuals who have fully completed growth [90]. Thus, Pancherz has recommended the use of removable functional appliances post-treatment to maintain the effects from the Herbst appliance [90].

## 6. Conclusion

There have been considerable efforts to elucidate the etiological factors of TMDs and understand the factors regulating the growth of the TMJ and mandibular condyles at both the cellular and molecular levels. Current approaches to stimulating and controlling the growth of the condyles to address craniofacial abnormalities and/or TMDs have proven to be promising. Further research will be required to develop orthodontic treatment modalities that can be applied in a clinical setting on a case-to-case basis.

## Author details

Bakr M. Rabie<sup>1</sup>, Jeremy Ho<sup>2</sup> and Qianfeng Li<sup>2\*</sup>

\*Address all correspondence to: qianfengjennifer@gmail.com

1 Faculty of Dentistry, The University of Hong Kong, Hong Kong

2 The University of Hong Kong, Hong Kong

## References

- [1] Thyagarajan T, Totey S, Danton MJ, Kulkarni AB. Genetically altered mouse models: The good, the bad, and the ugly. *Critical Reviews in Oral Biology and Medicine*. 2003;**14**:154-174. DOI: 10.1177/154411130301400302
- [2] Tanaka E, Detamore MS, Mercuri LG. Degenerative disorders of the temporomandibular joint: Etiology, diagnosis, and treatment. *Journal of Dental Research*. 2008;**87**:296-307. DOI: 10.1177/154405910808700406
- [3] Manfredini D, Guarda-Nardini L, Winocur E, Piccotti F, Ahlberg J, Lobbezoo F. Research diagnostic criteria for temporomandibular disorders: A systematic review of axis I epidemiologic findings. *Oral Surgery, Oral Medicine, Oral Pathology, Oral Radiology, and Endodontics*. 2011;**112**:453-462. DOI: 10.1016/j.tripleo.2011.04.021



- [4] Edvitar L, Oksana J, Ülle V-O. Temporomandibular joint arthroscopy versus arthrotomy. In: Bagaria V, editor. Regional Arthroscopy. Estonia: Tartu University, Tartu University Hospital; 2013. pp. 61-95. DOI: 10.5772/55011
- [5] Schiffman E, Ohrbach R, Truelove E, et al. Diagnostic criteria for temporomandibular disorders (DC/TMD) for clinical and research applications: Recommendations of the International RDC/TMD Consortium Network and Orofacial Pain Special Interest Group. *Journal of Oral & Facial Pain and Headache*. 2014;**28**:6-27. DOI: 10.11607/jop.1151
- [6] Sangani D, Suzuki A, VonVille H, Hixson JE, Iwata J. Gene mutations associated with temporomandibular joint disorders: A systematic review. *OALib*. 2015;**2**:e1583. DOI: 10.4236/oalib.1101583
- [7] de Boever JA, Carlsson GE, Klineberg IJ. Need for occlusal therapy and prosthodontic treatment in the management of temporomandibular disorders. Part I. Occlusal interferences and occlusal adjustment. *Journal of Oral Rehabilitation*. 2000;**27**:367-379. DOI: 10.1046/j.1365-2842.2000.00574.x
- [8] Patil AS, Bindra GK. Morphology of the temporomandibular joint (TMJ) of sheep (*Ovis aries*). *Open Journal of Veterinary Medicine*. 2012;**2**:242-244. DOI: 10.4236/ojvm.2012.24039
- [9] Alomar X, Medrano J, Cabratosa J, Clavero JA, Lorente M, Serra I, Monill JM, Salvador A. Anatomy of the temporomandibular joint. *Seminars in Ultrasound, CT, and MR*. 2007;**28**:170-183. DOI: 10.1053/j.sult.2007.02.002
- [10] Maynard SJ, Savage RJG. The mechanics of mammalian jaws. *The School Science Review*. 1959;**40**:289-301
- [11] Fanghänel J, Gedrange T. On the development, morphology and function of the temporomandibular joint in the light of the orofacial system. *Annals of Anatomy – Anatomischer Anzeiger*. 2007;**189**:314-319
- [12] Xiong H, Rabie ABM, Hagg U. Mechanical strain leads to condylar growth in adult rats. *Frontiers in Bioscience*. 2005;**10**:65-73
- [13] Gray H. *Anatomy of the Human Body*. 20th ed. Philadelphia: Lea & Febiger; 1918. 1396 p
- [14] Leander D. Role of growth factors in the development of mandible. *The Journal of Indian Orthodontic Society*. 2011;**45**:51-60. DOI: 10.5005/jp-journals-10021-1010
- [15] Kantomaa T, Ronning O. Growth mechanisms of the mandible. Dixon AD, Hoyte DA, Ronning O, editors. In: *Fundamentals of Craniofacial Growth*. New York: CRC Press; 1997. pp. 189-204
- [16] Nakano H, Watahiki J, Kubota M, Maki K, Shibasaki Y, Hatcher D, Miller AJ. Micro X-ray computed tomography analysis for the evaluation of asymmetrical condylar growth in the rat. *Orthodontics & Craniofacial Research*. 2003;**6**:Suppl 1:168-172; discussion: 179-182
- [17] Shen G, Rabie B, Hägg U. Neovascularization in the TMJ in response to mandibular protrusion. *Chinese Journal of Dental Research*. 2003;**6**:28-38

- [18] Luder H. Frequency and distribution of articular tissue features in adult human mandibular condyles: A semiquantitative light microscopic study. *The Anatomical Record*. 1997;**248**:18-28. DOI: 10.1002/(SICI)1097-0185(199705)248:1<18::AID-AR3>3.0.CO;2-B
- [19] Luder H. Age changes in the articular tissue of human mandibular condyles from adolescence to old age: A semiquantitative light microscopic study. *The Anatomical Record*. 1998;**251**:439-447. DOI: 10.1002/(SICI)1097-0185(199808)251:4<439::AID-AR3>3.0.CO;2-N
- [20] Shen G, Hägg U, Rabie AB, Kaluarachchi K. Identification of temporal pattern of mandibular condylar growth: A molecular and biochemical experiment. *Orthodontics & Craniofacial Research*. 2005;**8**:114-122. DOI: 10.1111/j.1601-6343.2005.00316.x
- [21] Van Lam S, Rabie AB. Mechanical strain induces Cbfa1 and type X collagen expression in mandibular condyle. *Frontiers in Bioscience*. 2005;**10**:2966-2971
- [22] She TT, Rabie ABM. Expression of SOX9 in the mandibular condyle. Lecture presented at: 77th European orthodontic society congress; Ghent, Belgium: June 19-23. 2001
- [23] Shen G, Zhao Z, Kaluarachchi K, Rabie AB. Expression of type X collagen and capillary endothelium in condylar cartilage during osteogenic transition — A comparison between adaptive remodelling and natural growth. *European Journal of Orthodontics*. 2006;**28**:210-216. DOI: 10.1093/ejo/cji123
- [24] Rabie AB, Hägg U. Factors regulating mandibular condylar growth. *American Journal of Orthodontics and Dentofacial Orthopedics*. 2002;**122**:401-409. DOI: 10.1067/mod.2002.125713
- [25] Yang YQ, Tan YY, Wong R, Wenden A, Zhang LK, Rabie AB. The role of vascular endothelial growth factor in ossification. *International Journal of Oral Science*. 2012;**4**:64-68. DOI: 10.1038/ijos.2012.33
- [26] Bruder SP, Jaiswal N, Haynesworth SE. Growth kinetics, self-renewal, and the osteogenic potential of purified human mesenchymal stem cells during extensive subcultivation and following cryopreservation. *Journal of Cellular Biochemistry*. 1997;**64**:278-294. DOI: 10.1002/(SICI)1097-4644(199702)64:2<278::AID-JCB11>3.0.CO;2-F
- [27] Rabie AB, Wong L, Tsai M. Replicating mesenchymal cells in the condyle and the glenoid fossa during mandibular forward positioning. *American Journal of Orthodontics and Dentofacial Orthopedics*. 2003;**123**:49-57. DOI: 10.1067/mod.2003.46
- [28] Rabie AB, Leung FY, Chayanupatkul A, Hägg U. The correlation between neovascularization and bone formation in the condyle during forward mandibular positioning. *The Angle Orthodontist*. 2002;**72**:431-438. DOI: 10.1043/0003-3219(2002)072<0431:TCBNAB>2.0.CO;2
- [29] Gerstenfeld LC, Shapiro FD. Expression of bone-specific genes by hypertrophic chondrocytes: Implication of the complex functions of the hypertrophic chondrocyte during endochondral bone development. *Journal of Cellular Biochemistry* 1996;**62**:1-9. DOI: 10.1002/(SICI)1097-4644(199607)62:1<1::AID-JCB1>3.0.CO;2-X

- [30] Hashimoto S, Setareh M, Ochs RL, Lotz M. Fas/Fas ligand expression and induction of apoptosis in chondrocytes. *Arthritis and rheumatism*. 1997;**40**:1749-1755. DOI: 10.1002/1529-0131(199710)40:10<1749::AID-ART4>3.0.CO;2-D
- [31] Garant PR. *Oral Cells and Tissues*. Quintessence: Illinois; 2003. 400 p. DOI: 10.1016/j.oraloncology.2004.06.001
- [32] Chung U-I, Schipani E, McMahon AP, Kronenberg HM. Indian hedgehog couples chondrogenesis to osteogenesis in endochondral bone development. *Journal of Clinical Investigation*. 2001;**107**:295-304. DOI: 10.1172/JCI11706
- [33] Rabie AB, Tang GH, Xiong H, Hägg U. PTHrP regulates chondrocyte maturation in condylar cartilage. *Journal of Dental Research*. 2003;**82**:627-631. DOI: 10.1177/154405910308200811
- [34] Ng TC, Chiu KW, Rabie AB, Hägg U. Repeated mechanical loading enhances the expression of Indian hedgehog in condylar cartilage. *Frontiers in Bioscience*. 2006;**11**:943-948. DOI: 10.2741/1851
- [35] Maor G, Hochberg Z, Silbermann M. Insulin-like growth factor I accelerates proliferation and differentiation of cartilage progenitor cells in cultures of neonatal mandibular condyles. *Acta Endocrinologica*. 1993;**128**:56-64. DOI: 10.1530/acta.0.1280056
- [36] Fuentes MA, Opperman LA, Bellinger LL, Carlson DS, Hinton RJ. Regulation of cell proliferation in rat mandibular condylar cartilage in explant culture by insulin-like growth factor-I and fibroblast growth factor-2. *Archives of Oral Biology*. 2002;**47**:643-654. DOI: 10.1016/S0003-9969(02)00052-3
- [37] Itoh K, Suzuki S, Kuroda T. Effects of local administration of insulin-like growth factor-I on mandibular condylar growth in rats. *Journal of Medical and Dental Sciences*. 2003;**50**:79-85. DOI: 10.11480/jmds.500111
- [38] Dai J, Rabie AB. VEGF: An essential mediator of both angiogenesis and endochondral ossification. *Journal of Dental Research*. 2007;**86**:937-950. DOI: 10.1177/154405910708601006
- [39] Ivkovic S, Yoon BS, Popoff SN, Safadi FF, Libuda DE, Stephenson RC, Daluiski A, Lyons KM. Connective tissue growth factor coordinates chondrogenesis and angiogenesis during skeletal development. *Development*. 2003;**130**:2779-2791. DOI: 10.1242/dev.00505
- [40] Horner A, Kemp P, Summers C, Bord S, Bishop NJ, Kelsall AW, Coleman N, Compston JE. Expression and distribution of transforming growth factor- $\beta$  isoforms and their signaling receptors in growing human bone. *Bone*. 1998;**23**:95-102. DOI: 10.1016/S8756-3282(98)00080-5
- [41] Fukumura K, Matsunaga S, Yamamoto T, Nagamine T, Ishidou Y, Sakou T. Immunolocalization of transforming growth factor-betas and type I and type II receptors in rat articular cartilage. *Anticancer Research*. 1998;**18**:4189-4193
- [42] Crabb ID, O'Keefe RJ, Puzas JE, Rosier RN. Synergistic effect of transforming growth factor  $\beta$  and fibroblast growth factor on DNA synthesis in chick growth plate chondrocytes. *Journal of Bone and Mineral Research*. 1990;**11**:1105-1112. DOI: 10.1002/jbmr.5650051103
- [43] O'Keefe RJ, Crabb ID, Puzas JE, Rosier RN. Effects of transforming growth factor- $\beta$ 1 and fibroblast growth factor on DNA synthesis in growth plate chondrocytes are enhanced

- by insulin-like growth factor-1. *Journal of Orthopaedic Research*. 1994;**12**:299-310. DOI: 10.1002/jor.1100120302
- [44] Grimaud E, Heymann D, Redini F. Recent advances in TGF- $\beta$  effects on chondrocyte metabolism. Potential therapeutic roles of TGF- $\beta$  in cartilage disorders. *Cytokine & Growth Factor Reviews*. 2002;**13**:241-257. DOI: 10.1016/S1359-6101(02)00004-7
- [45] Ballock RT, Heydemann A, Wakefield LM, Flanders KC, Roberts AB, Sporn MB. TGF-beta-1 prevents hypertrophy of epiphyseal chondrocytes: Regulation of gene expression for cartilage matrix proteins and metalloproteases. *Developmental Biology*. 1993;**158**:414-429. DOI: 10.1006/dbio.1993.1200
- [46] Bohme K, Winterhalter KH, Bruckner P. Terminal differentiation of chondrocytes in culture is a spontaneous process and is arrested by transforming growth factor- $\beta$ 2 and basic fibroblast growth factor in synergy. *Experimental Cell Research*. 1995;**216**:191-198
- [47] Ferguson CM, Schwarz EM, Reynolds PR, Puzas JE, Rosier RN, O'Keefe RJ. Smad2 and 3 mediate transforming growth factor- $\beta$ 1-induced inhibition of chondrocyte maturation. *Endocrinology*. 2000;**141**:4728-4735. DOI: 10.1210/endo.141.12.7848
- [48] Ueno T, Kagawa T, Kanou M, Fujii T, Kukunaga J, Mizukawa N, Sugahara T, Yamamoto T. Immunohistochemical observations of cellular differentiation and proliferation in endochondral bone formation from grafted periosteum: Expression and localization of BMP-2 and -4 in the grafted periosteum. *Journal of Craniomaxillofacial Surgery*. 2003;**31**:356-361. DOI: 10.1016/j.jcms.2003.07.006
- [49] Salo LA, Raustia AM. Type II and type III collagen in mandibular condylar cartilage of patients with temporomandibular joint pathology. *Journal of Oral and Maxillofacial Surgery*. 1995;**53**:39-45. DOI: 10.1016/0278-2391(95)90498-0
- [50] Vu TH, Shipley JM, Bergers G, Berger JE, Helms JA, Hanahan D, Shapiro SD, Senior RM, Werb Z. MMP-9/gelatinase B is a key regulator of growth plate angiogenesis and apoptosis of hypertrophic chondrocytes. *Cell*. 1998;**93**:411-422. DOI: 10.1016/S0092-8674(00)81169-1
- [51] Zheng LW, Ma L, Rabie AB, Cheung LK. Effect of recombinant human tissue inhibitor of matrix metalloproteinase-1 in rabbit mandibular distraction osteogenesis: A histological and immunohistochemical study. *Journal of Cranio-Maxillo-Facial Surgery*. 2006;**34**:277-282. DOI: 10.1016/j.jcms.2006.02.005
- [52] Rabie AB, Shum L, Chayanupatkul A. VEGF and bone formation in the glenoid fossa during forward mandibular positioning. *American Journal of Orthodontics and Dentofacial Orthopedics*. 2002;**122**:202-209. DOI: 10.1067/mod.2002.125991
- [53] Xiong H, Rabie AB, Hagg U. Neovascularization and mandibular condylar bone remodeling in adult rats under mechanical strain. *Frontiers in Bioscience*. 2005;**10**:74-82
- [54] Gracia-Ramirez M, Toran N, Andaluz P, Carrascosa A, Audi L. Vascular endothelial growth factor is expressed in human fetal growth cartilage. *Journal of Bone and Mineral Research*. 2000;**15**:534-540. DOI: 10.1359/jbmr.2000.15.3.534
- [55] Dai J, Bakr A, Rabie M. Gene therapy to enhance condylar growth using rAAV-VEGF. *The Angle Orthodontist*. 2008;**78**:89-94. DOI: 10.2319/102606-441.1

- [56] Triffitt JT, Joyner CJ, Oreffo RO, Viridi AS. Osteogenesis: Bone development from primitive progenitors. *Biochemical Society Transactions*. 1998;**26**:21-27. DOI: 10.1042/bst0260021
- [57] Leung FY, Rabie AB, Hagg U. Neovascularization and bone formation in the condyle during stepwise mandibular advancement. *European Journal of Orthodontics*. 2004;**26**:137-141. DOI: 10.1093/ejo/26.2.137
- [58] Rabie AB. Vascular endothelial growth pattern during demineralized bone matrix induced osteogenesis. *Connective Tissue Research*. 1997;**36**:337-345. DOI: 10.3109/03008209709160232
- [59] Lee K, Lanske B, Karaplis AC, Deeds JD, Kohno H, Nissenson RA, Kronenberg HM, Segre GV. Parathyroid hormone-related peptide delays terminal differentiation of chondrocytes during endochondral bone development. *Endocrinology*. 1996;**137**:5109-5118. DOI: 10.1210/endo.137.11.8895385
- [60] Stevens DA, Williams GR. Hormone regulation of chondrocyte differentiation and endochondral bone formation. *Molecular and Cellular Endocrinology*. 1999;**151**:195-204. DOI: 10.1016/S0303-7207(99)00037-4
- [61] de Crombrughe B, Lefebvre V, Nakashima K. Regulatory mechanisms in the pathways of cartilage and bone formation. *Current Opinion in Cell Biology*. 2001;**13**:721-727. DOI: 10.1016/S0955-0674(00)00276-3
- [62] Wu Q, Zhang Y, Chen Q. Indian hedgehog is an essential component of mechanotransduction complex to stimulate chondrocyte proliferation. *The Journal of Biological Chemistry*. 2001;**276**:35290-35296. DOI: 10.1074/jbc.M101055200
- [63] Shibukawa Y, Young B, Wu C, Yamada S, Long F, Pacifi M, Koyama E. Temporomandibular joint formation and condyle growth require Indian hedgehog signaling. *Developmental Dynamics*. 2007;**236**:426-434. DOI: 10.1002/dvdy.21036
- [64] Song Y, Wu C, Wing R, Wong K, Rabie ABM. Identification of the chondrogenic pathway in the mandibular condylar cartilage. *Frontiers in Bioscience*. 2009;**14**:1932-1938
- [65] Long F, Zhang XM, Karp S, Yang Y, McMahon AP. Genetic manipulation of hedgehog signaling in the endochondral skeleton reveals a direct role in the regulation of chondrocyte proliferation. *Development*. 2001;**128**:5099-5108
- [66] Kronenberg HM. Developmental regulation of the growth plate. *Nature*. 2003;**423**:332-336. DOI: 10.1038/nature01657
- [67] Twyman R. *Advanced Molecular Biology*. Singapore: Springer; 1998. 510 p
- [68] Rabie AB, Tang GH, Hagg U. Cbfa1 couples chondrocytes maturation and endochondral ossification in rat mandibular condylar cartilage. *Archives of Oral Biology*. 2004;**49**:109-118. DOI: 10.1016/j.archoralbio.2003.09.006
- [69] Tang GH, Rabie AB. Runx2 regulates endochondral ossification in condyle during mandibular advancement. *Journal of Dental Research*. 2005;**84**:166-171. DOI: 10.1177/154405910508400211

- [70] Zelzer E, Glotzer DJ, Hartmann C, Thomas D, Fukai N, Soker S, Olsen BR. Tissue specific regulation of VEGF expression during bone development requires Cbfa1/Runx2. *Mechanisms of Development*. 2001;**106**:97-106. DOI: 10.1016/S0925-4773(01)00428-2
- [71] Akiyama H, Chaboissier M-C, Martin JF, Schedl A, de Crombrughe B. The transcription factor Sox9 has essential roles in successive steps of the chondrocyte differentiation pathway and is required for expression of Sox5 and Sox6. *Genes & Development*. 2002;**16**:2813-2828. DOI: 10.1101/gad.1017802
- [72] Al-kalaly A, Wu C, Wong R, Rabie AB. The assessment of cell cycle genes in the rat mandibular condyle. *Archives of Oral Biology*. 2009;**54**:470-478. DOI: 10.1016/j.archoralbio.2009.01.020
- [73] Rudnicki JA, Brown AM. Inhibition of chondrogenesis by Wnt gene expression in vivo and in vitro. *Developmental Biology*. 1997;**185**:104-118. DOI: 10.1006/dbio.1997.8536
- [74] Church V, Nohno T, Linker C, Marcelle C, Francis-West P. Wnt regulation of chondrocyte differentiation. *Journal of Cell Science*. 2002;**115**:4809-4818. DOI: 10.1242/jcs.00152
- [75] Nowak-Soliska E, Bakr A, Rabie M, Wong RWK, Lei SWY. The effect of naringin on early growth and development of the spheno-occipital synchondrosis as measured by the expression of PTHrP and Sox9—An in vitro model. *European Journal of Orthodontics*. 2013;**35**:826-831. DOI: 10.1093/ejo/cjs089
- [76] Rabie AB, She TT, Harley VR. Forward mandibular positioning up-regulates SOX9 and type II collagen expression in the glenoid fossa. *Journal of Dental Research*. 2003;**82**:725-730. DOI: 10.1177/154405910308200913
- [77] Cendekiawan T, Wong RW, Rabie AB. Temporal expression of SOX9 and type II collagen in spheno-occipital synchondrosis of mice after mechanical tension stimuli. *The Angle Orthodontist*. 2008;**78**:83-88. DOI: 10.2319/012507-36.1
- [78] Zhao Q, Eberspaecher H, Lefebvre V, de Crombrughe B. Parallel expression of Sox9 and Col2a1 in cells undergoing chondrogenesis. *Developmental Dynamics*. 1997;**209**:377-386. DOI: 10.1002/(SICI)1097-0177(199708)209:4<377::AID-AJA5>3.0.CO;2-F
- [79] Rabie A, Dai J, Xu R. Recombinant AAV-mediated VEGF gene therapy induces mandibular condylar growth. *Gene Therapy*. 2007;**14**:972-980. DOI: 10.1038/sj.gt.3302943
- [80] Dai J, Rabie AB. The use of recombinant adeno-associated virus for skeletal gene therapy. *Orthodontics Craniofacial Research*. 2007;**10**:1-14. DOI: 10.1111/j.1601-6343.2007.00381.x
- [81] Dai J, Rabie AB. Recombinant adeno-associated virus vector hybrids efficiently target different skeletal cells. *Frontiers in Bioscience*. 2007;**12**:4280-4287. DOI: 10.2741/2387
- [82] Street J, Bao M, deGuzman L, Bunting S, Peale Jr FV, Ferrara N, Steinmetz H, Hoeffel J, Cleland JL, Daugherty A, van Bruggen N, Redmond HP, Carano RA, Filvaroff EH. Vascular endothelial growth factor stimulates bone repair by promoting angiogenesis and bone turnover. *Proceedings of the National Academy of Sciences of the United States of America*. 2002;**99**:9656-9661. DOI: 10.1073/pnas.152324099

- [83] Tarkka T, Sipola A, Jamsa T, Soini Y, Yla-Herttuala S, Tuukkanen J, Hautala T. Adenoviral VEGF-A gene transfer induces angiogenesis and promotes bone formation in healing osseous tissues. *The Journal of Gene Medicine*. 2003;**5**:560-566. DOI: 10.1002/jgm.392
- [84] Rabie AB, Zhao Z, Shen G, Hägg EU, Robinson W. Osteogenesis in the glenoid fossa in response to mandibular advancement. *American Journal of Orthodontics and Dentofacial Orthopedics*. 2001;**119**:390-400. DOI: 10.1067/mod.2001.112875
- [85] Ruf S, Pancherz H. Temporomandibular joint remodeling in adolescent and young adult during Herbst treatment: A prospective longitudinal magnetic resonance imaging and cephalometric radiographic investigation. *American Journal of Orthodontics and Dentofacial Orthopedics*. 1999;**115**:607-618. DOI: 10.1016/S0889-5406(99)70285-4
- [86] Hansen K, Pancherz H, Hagg U. Long-term effects of the Herbst appliance in relation to the treatment growth period: A cephalometric study. *European Journal of Orthodontics*. 1991;**13**:471-481. DOI: 10.1093/ejo/14.4.285
- [87] Von Bremen J, Pancherz H. Efficiency of class II, division 1 therapy in relation to treatment timing and modality. *American Journal of Orthodontics and Dentofacial Orthopedics*. 2002;**121**:31-37
- [88] Pancherz H. Treatment of class II malocclusions by jumping the bite with the Herbst appliance: A cephalometric investigation. *American Journal of Orthodontics and Dentofacial Orthopedics*. 1979;**76**:423-442. DOI: 10.1016/0002-9416(79)90227-6
- [89] Weislander L. Intensive treatment of severe class II malocclusion with a headgear-Herbst appliance in the early mixed dentition. *American Journal of Orthodontics and Dentofacial Orthopedics*. 1984;**86**:1-13. DOI: 10.1016/0002-9416(84)90271-9
- [90] Pancherz H. The Herbst appliance—its biological effects and clinical use. *American Journal of Orthodontics and Dentofacial Orthopedics*. 1985;**87**:1-20. DOI: 10.1016/0002-9416(85)90169-1
- [91] Hagg U, Du X, Rabie ABM. Growth modification of severe skeletal class II malocclusions by dentofacial orthopedics. Lecture presented at: 77th European Orthodontic Society Congress; Ghent, Belgium: June 19-23. 2001
- [92] Wey MC, Bendeus M, Peng L, Hägg U, Rabie AB, Robinson W. Stepwise advancement versus maximum jumping with headgear activator. *European Journal of Orthodontics*. 2007;**29**:283-293. DOI: 10.1093/ejo/cjm018
- [93] Hägg U, Du X, Rabie AB. Initial and late treatment effects of headgear-Herbst appliance with mandibular step- by-step advancement. *American Journal of Orthodontics and Dentofacial Orthopedics*. 2002;**122**:477-485. DOI: 10.1067/mod.2002.128218
- [94] Phan KL, Bendeus M, Hägg U, Hansen K, Rabie AB. Comparison of the headgear activator and Herbst appliance—effects and post-treatment changes. *European Journal of Orthodontics*. 2006;**28**:594-604. DOI: 10.1093/ejo/cjl052
- [95] Du X, Hägg U, Rabie AB. Effects of headgear Herbst and mandibular step-by-step advancement versus conventional Herbst appliance and maximal jumping of the mandible. *European Journal of Orthodontics*. 2002;**24**:167-174. DOI: 10.1067/mod.2002.127476

- [96] Petrovic A, Stutzmann J, Gasson N. The final length of the mandible: Is it genetically predetermined? In: Craniofacial Biology. Craniofacial Growth Series. 2nd ed. The University of Michigan, Ann Arbor: 1981. p.105-126
- [97] Rabie ABM, Al-Kalaly A. Does the degree of advancement during functional appliance therapy matter? *European Journal of Orthodontics*. 2008;**30**:274-282. DOI: 10.1093/ejo/cjm129
- [98] Rabie AB, Wong L, Hägg U. 2003c correlation of replicating cells and osteogenesis in the glenoid fossa during stepwise advancement. *American Journal of Orthodontics and Dentofacial Orthopedics*. 2003;**123**:521-526. DOI: 10.1016/S0889-5406(02)57033-5
- [99] Ng AF, Yang YO, Wong RW, Hägg EU, Rabie AB. Factors regulating condylar cartilage growth under repeated load application. *Frontiers in Bioscience*. 2006;**11**:949-954
- [100] Shum L, Rabie AB, Hägg U. Vascular endothelial growth factor expression and bone formation in posterior glenoid fossa during stepwise mandibular advancement. *American Journal of Orthodontics and Dentofacial Orthopedics*. 2004;**125**:185-190. DOI: 10.1016/S0889540603007194
- [101] Rabie AB, Tsai MJ, Hägg U, Du X, Chou BW. The correlation of replicating cells and osteogenesis in the condyle during stepwise advancement. *The Angle Orthodontist*. 2003;**73**:457-465. DOI: 10.1043/0003-3219(2003)073<0457:TCORCA>2.0.CO;2
- [102] Rabie AB, Xiong H, Hägg U. Forward mandibular positioning enhances condylar adaptation in adult rats. *European Journal of Orthodontics*. 2004;**26**:353-358. DOI: 10.1093/ejo/26.4.353
- [103] Chayanupatkul A, Rabie AB, Hägg U. Temporomandibular response to early and late removal of bite-jumping devices. *European Journal of Orthodontics*. 2003;**25**:465-470. DOI: 10.1093/ejo/25.5.465
- [104] Rabie AB, She TT, Hägg U. Functional appliance therapy accelerates and enhances condylar growth. *American Journal of Orthodontics and Dentofacial Orthopedics*. 2003;**123**:40-48. DOI: 10.1067/mod.2003.45
- [105] Haijar D, Santos MF, Kimura ET. Propulsive appliance stimulates the synthesis of insulin-like growth factors I and II in the mandibular condylar cartilage of young rats. *Archives of Oral Biology*. 2003;**48**:635-642. DOI: 10.1016/S0003-9969(03)00128-6
- [106] Rabie ABM, Shen G, Hägg U, Kalurachchi T. Type X collagen—A marker for endochondral ossification of the mandibular condyles. *Quintessence orthodontics year book*. Tokyo. 2000;**2000**:50-58
- [107] Tang GH, Rabie ABM, Hagg U. Indian hedgehog: A mechanotransduction mediator in condylar cartilage. *Journal of Dental Research*. 2004;**83**:434-438. DOI: 10.1177/154405910408300516
- [108] McNamara JA Jr, Hinton RJ, Hoffman DL. Histologic analysis of temporomandibular joint adaptation to protrusive function in young adult rhesus monkeys (*Macaca mulatta*). *American Journal of Orthodontics and Dentofacial Orthopedics*. 1982;**82**:288-298. DOI: 10.1016/0002-9416(82)90463-8



- [109] Hinton RJ, McNamara JA Jr. Temporal bone adaptations in response to protrusive function in juvenile and young adult rhesus monkeys (*Macaca mulatta*). *European Journal of Orthodontics*. 1984;**6**:155-174. DOI: 10.1016/0002-9416(85)90183-6
- [110] Woodside DG, Metaxas A, Altuna G. The influence of functional appliance therapy on glenoid fossa remodeling. *American Journal of Orthodontics and Dentofacial Orthopedics*. 1987;**92**:181-198. DOI: 10.1016/0889-5406(87)90411-2
- [111] Raab-Cullen DM, Akhter MP, Kimmel DB, Recker RR. Periosteal bone formation stimulated by externally induced bending strains. *Journal of Bone and Mineral Research*. 1994;**9**:1143-1152. DOI: 10.1002/jbmr.5650090803
- [112] Xiong H, Hägg U, Tang GH, Rabie ABM. The effect of continuous bite-jumping in adult rats: A morphological study. *The Angle Orthodontist*. 2004;**74**:86-92. DOI: 10.1043/0003-3219(2004)074<0086:TEOCBI>2.0.CO;2