

Scimitar Syndrome with Dilated Azygos Vein and Interrupted Inferior Vena Cava

Theresa NH Leung¹ and Na Xie²

¹Department of Pediatrics and Adolescent Medicine, Faculty of Medicine, The University of Hong Kong, Hong Kong SAR, People's Republic of China

²Department of Medical Imaging, The University of Hong Kong-Shenzhen Hospital, Shenzhen, People's Republic of China

Correspondence author: Theresa NH Leung, Department of Paediatrics and Adolescent Medicine, Faculty of Medicine, The University of Hong Kong, Hong Kong SAR, People's Republic of China, E-mail: leungnht@hku.hk

Received: 02 June 2016; **Accepted:** 03 June 2016; **Published:** 05 June 2016

Citation: Leung TN, Xie N. Scimitar Syndrome with Dilated Azygos Vein and Interrupted Inferior Vena Cava. *Ann Clin Lab Res.* 2016, 4: 2.

Keywords: Diagnostic imaging, Scimitar syndrome, Azygos vein, Pediatrics

Image Case

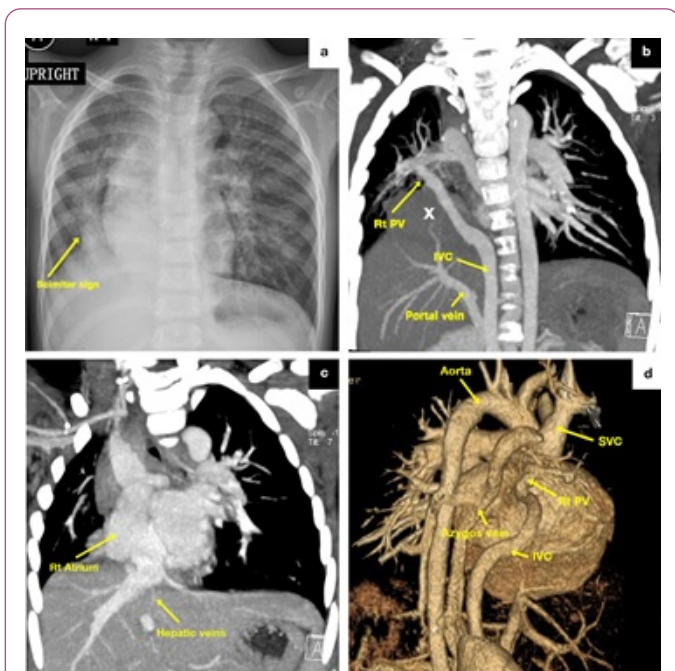


Figure 1 a Chest radiograph with Scimitar or "Turkish sword" sign, b-d. CT thorax images showing diaphragmatic hernia (marked as X in b) and the anomalous vascular connections (Rt PV= right pulmonary veins, IVC = inferior vena cava, SVC = superior vena cava).

A 3 year-old girl with recurrent chest infections had chest radiograph (**Figure 1a**) showing the typical "Turkish sword" sign which could be found in 70% in the childhood-adult group of Scimitar syndrome, a rare form of partial anomalous pulmonary venous drainage (PAPVD) associated with hypoplastic lung [1]. The anomalous pulmonary veins drain into the systemic venous system such as inferior vena cava, right atrium, hepatic or portal vein [1].

The reconstructed Computerized Tomography (CT) images of thorax in this patient demonstrated a few unusual features of the rare condition:

- 1) Anomalous right pulmonary veins joined the inferior vena cava (IVC) was interrupted after coursing through the liver (**Figure 1b**).
- 2) Azygos and hemiazygos veins were dilated (**Figure 1d**).
- 3) The hepatic vein drained directly to right atrium (**Figure 1c**).

Similar to two reported cases [2,3], the IVC was interrupted and the dilated azygos and hemiazygos veins received venous blood from the anomalous scimitar vein and all infra-diaphragmatic systemic return except the hepatic vein which was draining to the right atrium separately. Scimitar syndrome is also classified as "combined pulmonary and vascular lesions" in the group of congenital pulmonary malformations [4]. This patient had hypoplasia of the right lung, right middle lobe and lower lobe bronchi, and a small diaphragmatic hernia involving part of the liver (marked with X in **Figure 1b**). Scimitar syndrome with various complex vascular connections and pulmonary malformations are described in literature, however, the embryological development of the congenital abnormalities is still not well defined.

Ethical Approval

Formal consent is not required for retrospective review and no identifiable detail of the individual is included in the manuscript and figures.

References

1. Cicek S, Arslan AH, Ugurlucan M, Yildiz Y, Ay S (2014) Scimitar syndrome: the Turkey Sword sabre. *Semin Thorac Cardiovasc Surg Pediatr Card Surg Ann* 17: 56-61.
2. Greenberg SB (2008) Combined Scimitar Syndrome and Interruption of the Inferior Vena Cava Causing Mega-azygos and Hemiazygos Veins. *Pediatr Cardiol* 29: 243-244.

3. Celik M, Celik T, Iyisoy A, Ayten O (2012) Scimitar Syndrome and Azygos Continuation of the Inferior Vena Cava Diagnosed in an Adult-An Unusual Association. *Congenit Heart Dis* 7: 85-88.
4. Lee E, Dorkin H, Vargas SO (2011) Congenital Pulmonary Malformations in Pediatric Patients: Review and Update on Etiology, Classification, and Imaging Findings. *Radiol Clin N Am* 49 :921–948.