

Management of Acquired Uterine Arteriovenous Malformations Following Early Pregnancy Complications

1 POINT

Jennifer K.Y. Ko, MBBS, MRCOG, FHKCOG, Cert RCOG (Reprod Med), FHKAM; Vincent Y.T. Cheung, MBBS, FRCOG, FRCSC

INTRODUCTION

Uterine arteriovenous malformation (AVM) is an abnormal connection between arteries and veins within the uterus. Although AVM can be congenital or acquired, this article focuses on the diagnosis and management of acquired AVMs identified following early pregnancy complications. AVMs may develop as a result of damage to the uterine tissue following spontaneous miscarriage, pregnancy termination, dilatation and curettage, caesarean scar pregnancy, or gestational trophoblastic disease.¹ The incorporation of necrotic villi in the venous sinuses of scar tissue is thought to cause acquired AVM.²

DIAGNOSIS

The most common presenting symptom of uterine AVM is abnormal uterine bleeding. The bleeding pattern is typically intermittent and/or torrential, and unresponsive to medical management,³ with approximately 30% of cases requiring blood transfusion.⁴

Angiography is still the gold standard for diagnosing AVM,⁴ but its invasive nature limits its use hence, it is now often reserved for patients who require intervention at the same setting

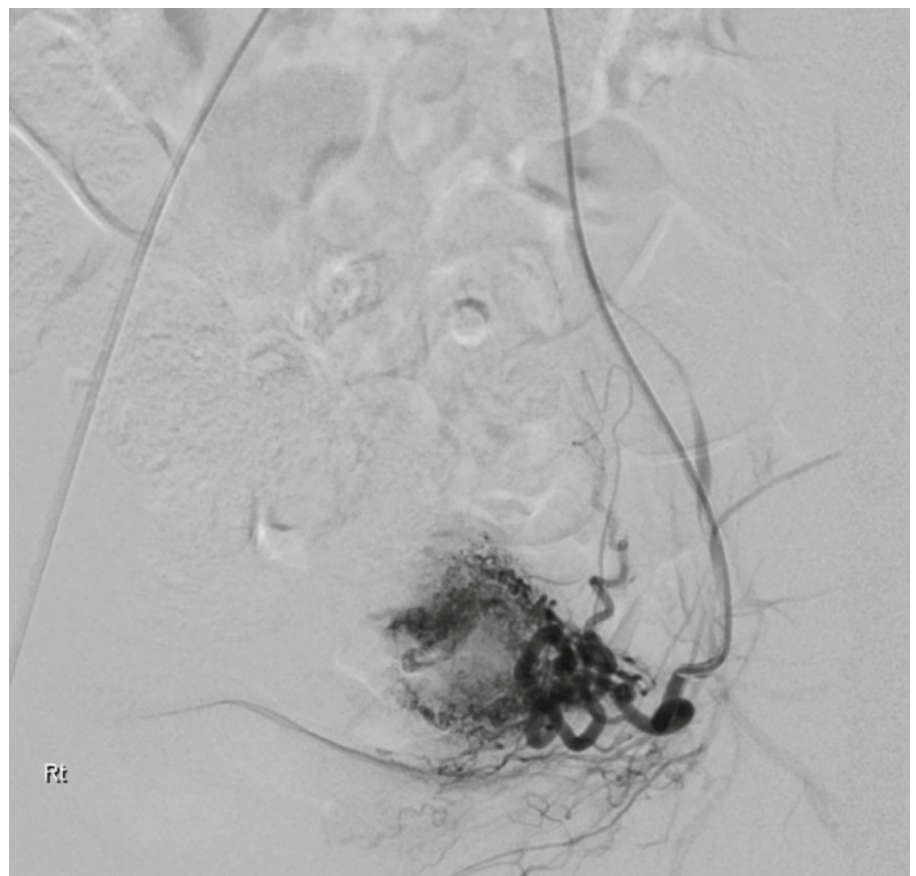
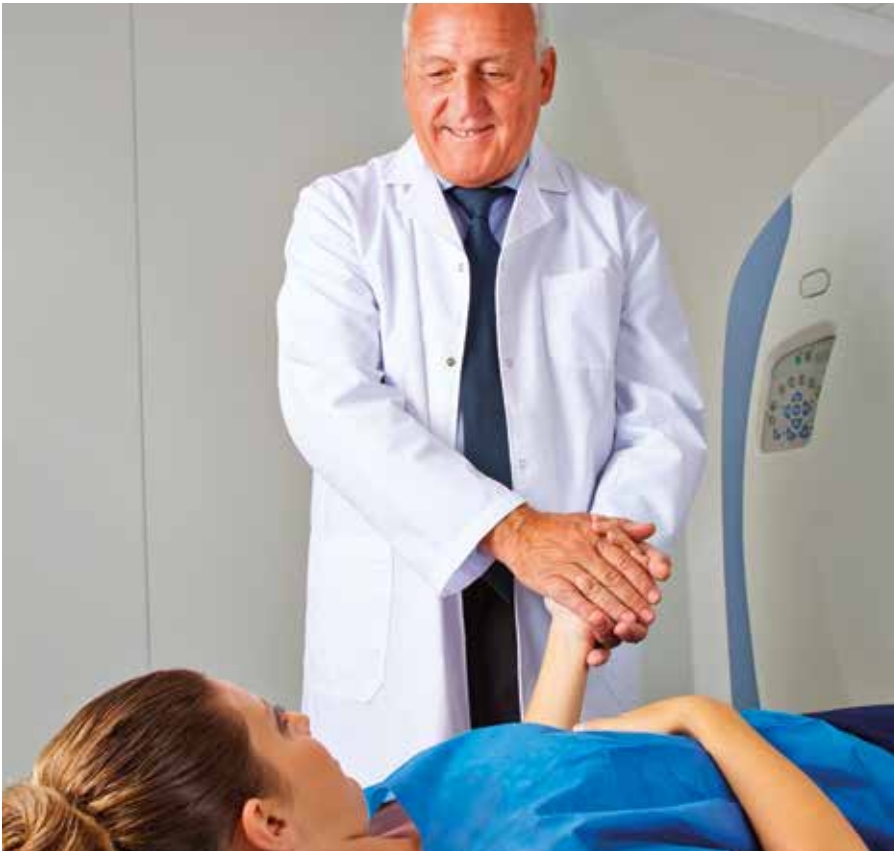

Figure 1. Abnormal vessels with hypertrophied complex feeding artery and early venous drainage on angiography suggestive of uterine AVM

(Figure 1). Currently, ultrasonography is the primary tool for the diagnosis of uterine AVM.⁵ In recent years, the widespread use of ultrasonography during

follow-up after early pregnancy complications has led to an increasing incidence of vascular lesions resembling AVM in asymptomatic women. Some



CT and MRI evaluate the involvement of surrounding visceral structures and are useful when the body habitus limits ultrasonographic images.

authors refer these lesions, which can be indistinguishable from retained products of gestation, as enhanced myometrial vascularity/arteriovenous malformation (EMV/AVM).¹

The ultrasonographic characteristics of EMV/AVM on two-dimensional grayscale ultrasonography are non-specific, which appears as irregular, hypoechoic tubular structures within the myometrium, and the diagnosis can be missed if not clinically aware (Figure 2).¹ The complex network of EMV/AVM may be enhanced by using colour Doppler ultrasonography which shows a mosaic pattern of multidirectional vessels with high-velocity and low-impedance flow (Figure 3).^{1,2} The use of three-dimensional colour Doppler ultrasonography can clearly

demonstrate the configuration as well as feeding and draining vessel of the EMV/AVM.¹

Saline infusion ultrasonography, magnetic resonance imaging (MRI), contrast-enhanced computed tomography (CT), and hysteroscopy have also been used for the diagnosis of EMV/AVM and to further characterise the lesion.⁶⁻⁹ On CT and MRI, characteristic appearances of EMV/AVM are serpiginous flow-related signal voids within the lesion.⁷ Both CT and MRI evaluate the involvement of surrounding visceral structures and are useful when the body habitus limits ultrasonographic images. However, MRI provides better tissue contrast compared with CT and does not involve radiation exposure.¹⁰

It is important to accurately diagnose gestational trophoblastic disease or retained products of gestation in abnormal vaginal bleeding post pregnancy, as uterine curettage in a woman with undiagnosed uterine EMV/AVM can provoke life-threatening bleeding. Unlike gestational trophoblastic disease or retained products of gestation, beta-human chorionic gonadotropin (β -hCG) is usually negative in AVM, and this might be beneficial in diagnosis.

MANAGEMENT

Timmerman, et al, suggested that women with uterine AVMs should be classified into three groups: (1) those with true AVMs with heavy, life-threatening uterine bleeding in nearly all cases, and colour Doppler evidence showing typical signs of vascular malformation including areas of strong hypervascularity and turbulence confirmed by angiography; (2) those with profound uterine bleeding and characteristic appearance on Doppler ultrasound but not angiographically confirmed; and (3) those with minimal symptoms and ultrasound features of vascular malformation.¹¹

The most important determinant in EMV/AVM management is the woman's clinical status, taking into consideration the woman's age and desire for further fertility. Women with life-threatening and profound uterine bleeding (groups 1 and 2) need a timely and definitive treatment such as hysterectomy, which should be considered for those with haemodynamic instability and life-threatening bleeding. However, this would result in permanent loss of fertility. While awaiting definitive treatment, acute blood loss may be successfully controlled by an intrauterine Foley catheter⁴ and should be accompa-

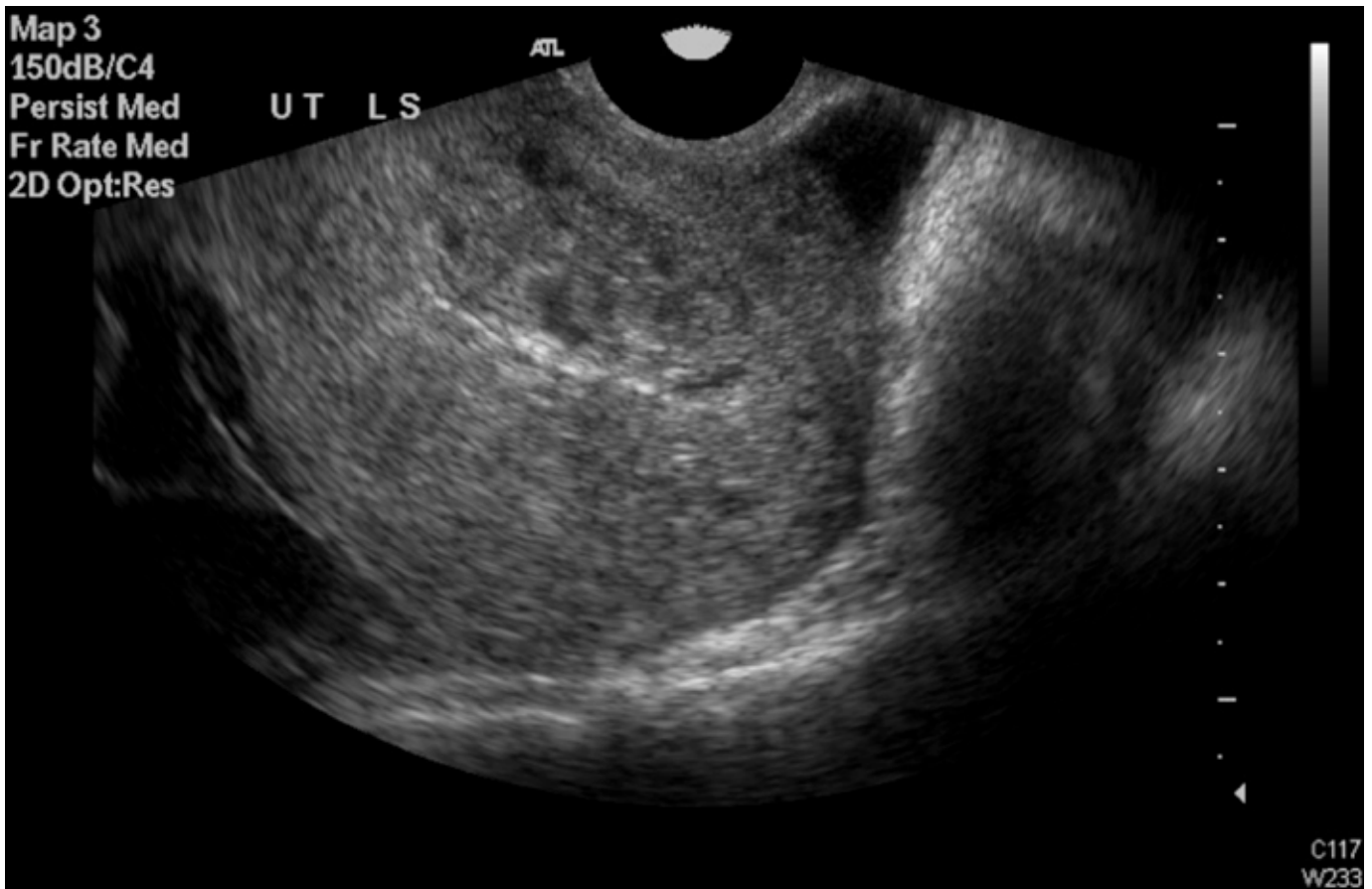


Figure 2. EMV/AVM on two-dimensional grayscale ultrasonography are nonspecific and appears as irregular, hypoechoic tubular structures within the myometrium.

nied by aggressive resuscitation and replacement of blood products as needed.

Most women diagnosed with EMV/AVM are in the reproductive age group who still desire fertility. Therefore, treatment should be aimed at preserving fertility whenever possible. Women with EMV/AVM requiring fertility-sparing management should be referred early to a tertiary centre with the appropriate expertise. High success rates have been reported for uterine artery embolization, which is the most common treatment modality for EMV/AVM.^{7,12-15} Various embolic agents such as gelfoam, polyvinyl alcohol particles, tissue glue, and coils have been used with no statistically significant difference in clinical outcomes reported.¹⁶ The use of unilateral or bilateral emboli-

zation approach should be based on the arterial supply as determined by angiography, clinical scenario, and preference of the radiologist.¹⁰ Although postembolization syndrome with pelvic pain and low-grade fever can occur, this often subsides with conservative management.¹⁵

Laparoscopic treatment using bipolar coagulation of uterine vessels or myometrial resection has been reported in selected cases.¹⁷⁻¹⁸ In a recent retrospective study, 11 women with uterine EMV/AVM were successfully treated using surgical hysteroscopy equipped with an electrosurgical loop, which offers the advantage of a short hospital stay and has no reported complications.¹⁹

A new form of minimally invasive treatment makes use of a human fi-

brin sealant applied selectively to the feeding vessel of the AVM under sonographic guidance. The sealant is a biological substance derived from human donor plasma, producing a highly concentrated solution of fibrinogen and other cryoglobulins, mimicking the final stages of the body's natural clotting cascade. In a previous study, 14 women who had postpartum haemorrhage caused by AVM were successfully treated; however, 3 women required a repeat procedure after 4-7 days.²⁰

Women with minimal or no abnormal bleeding (group 3) constitute the majority of those diagnosed with EMV/AVM on ultrasonography during follow-up of pregnancy complications. However, the natural course, the likeli-

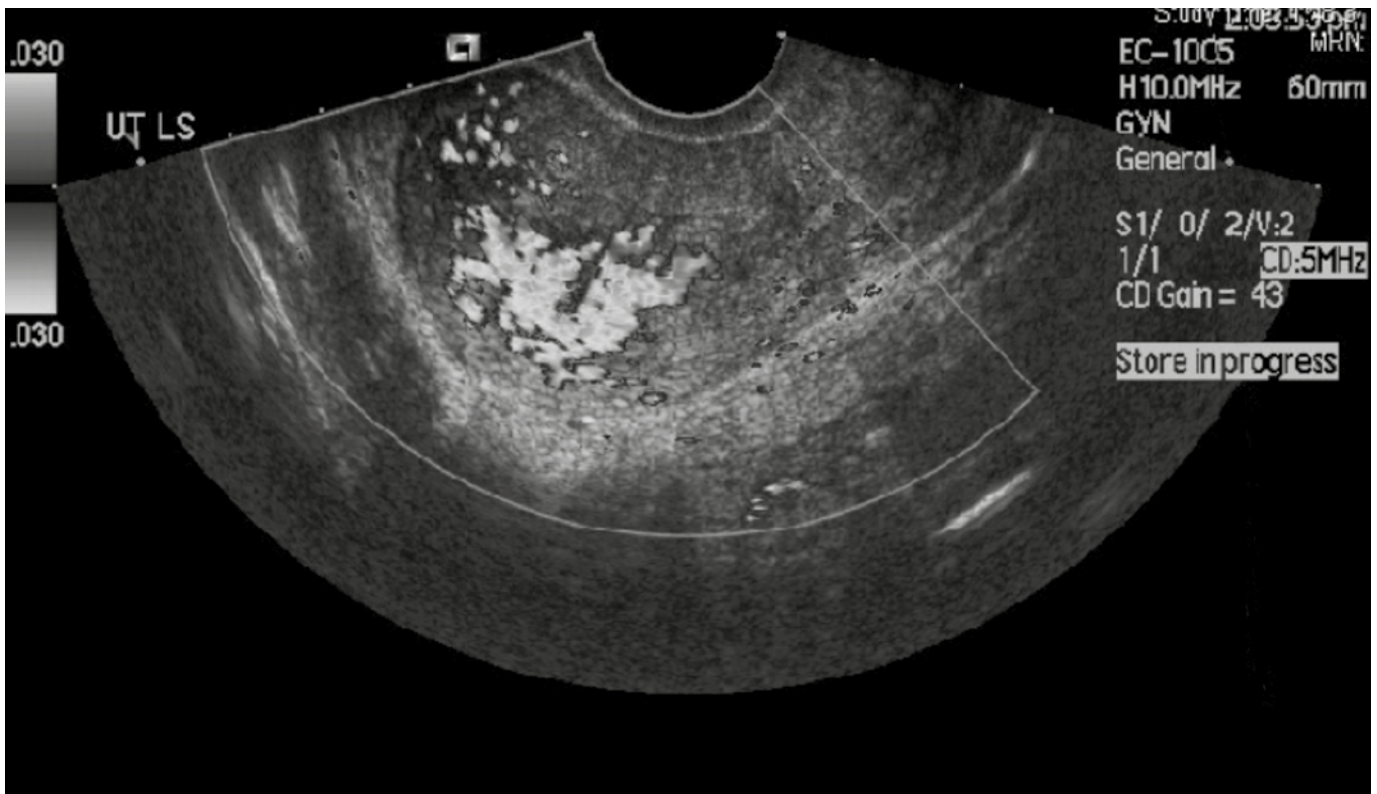


Figure 3. Typical colour Doppler image of EMV/AVM showing increase in vascular flow at the fundus and posterior wall on transvaginal ultrasonography.

hood of bleeding, and the need for intervention in this group of women are not clear. In the study of Timmerman, et al, conservative management was possible in more than two-thirds of patients presenting with uterine AVM diagnosed by colour Doppler ultrasonography.¹¹ In a retrospective review of 22 EMV/AVM cases from our centre, while almost 10% of women with EMV/AVM had unpredictable uterine bleeding requiring angiographic intervention, this only occurred in women with ongoing abnormal bleeding after the pregnancy event. In women who were asymptomatic at the time of diagnosis, the EMV/AVM resolved spontaneously without unpredictable bleeding.²¹

Peak systolic velocity (PSV) has been suggested to be useful in distinguishing between patients with high-

and low-risk bleeding.^{1,11,22} Despite significant overlap of PSV values between the two groups, patients who required uterine artery embolization had a higher mean PSV compared with those who did not require embolization. Timmerman, et al, proposed that a PSV of less than 0.39 m/s should be considered “safe” for conservative management, particularly in asymptomatic patients, while those greater than 0.83 m/s should be re-evaluated at regular intervals.¹¹

In a prospective study of 75 women with vaginal bleeding from pregnancy-related EMV/AVM, the mean haemoglobin of patients who had conservative management was found to be significantly higher than those who had therapeutic management.²² In that study, the diagnostic predictive value of spectral Doppler and haemoglobin level in cor-

rectly classifying patients into conservative and therapeutic management was up to 85.3%.²²

In our experience, ultrasonographic resolution of the EVM/AVM can take up to 12 months.²¹ Even though majority of patients can be reassured, those on conservative management should be advised to seek medical attention if abnormal vaginal bleeding occurs. Patients should be advised against travelling to areas without access to appropriate treatment without ultrasound confirmation that the lesion has resolved.

There have been reports of successful pregnancies after AVM, including those who have undergone uterine artery embolization,^{3,19} which is a selective process that should not affect the menstrual cycle and fertility in the majority of cases. Adequate collateral blood supply can

develop after the procedure to maintain uterine perfusion for pregnancy. In a retrospective case series and literature review conducted at Canberra Hospital, 28 women achieved 36 pregnancies and 32 live births after diagnosis and/or treatment of uterine EMV/AVM.²³ In that study, none of the women had severe intrauterine growth restriction or abnormal invasion of the placental bed.¹⁹ However, the numbers are small and continued monitoring of the pregnancy outcome after management of EMV/AVM should be done.

CONCLUSION

Pregnancy is an important cause of acquired EMV/AVM. Diagnosis is most often by colour Doppler ultrasonography. Patients should be managed based on their clinical status, taking into account objective measurements such as Doppler indices and haemoglobin levels. Most asymptomatic women can be reassured that EMV/AVM will resolve without signifi-



Women with EMV/AVM requiring fertility-sparing management should be referred early to a tertiary centre with the appropriate expertise.

cant sequelae. Uterine artery embolization is the most common fertility-sparing treatment modality for those with significant bleeding, with high success rates.

About the authors

Dr Jennifer K.Y. Ko is an Associate Consultant in the Department of Obstetrics and Gynaecology, Queen Mary Hospital, The University of Hong Kong, Hong Kong.

Dr Vincent Y.T. Cheung is a Consultant Gynaecologist in the Department of Obstetrics and Gynaecology, Queen Mary Hospital, The University of Hong Kong, Hong Kong.

REFERENCES

- Timor-Tritsch, I.E., Haynes, M.C., Monteagudo, A., Khatib, N. & Kovacs, S. (2016) Ultrasound diagnosis and management of acquired uterine enhanced myometrial vascularity/arteriovenous malformations. *Am J Obstet Gynecol* 2016;214:731.e1–731.e10.
- Timmerman, D., Van den Bosch, T., Peer-aer, K., Debrouwere, E., Van Schoubroeck, D., Stockx, L. & Spitz, B. (2000) Vascular malformations in the uterus: ultrasonographic diagnosis and conservative management. *Eur J Obstet Gynecol Reprod Biol* 2000;92:171–178.
- Grivell, R.M., Reid, K.M. & Mellor, A. (2005) Uterine arteriovenous malformations: a review of the current literature. *Obstet Gynecol Surv* 2005;60:761–767.
- Manolitsas, T., Hurley, V. & Gilford, E. (1994) Uterine arteriovenous malformation—a rare cause of uterine haemorrhage. *Aust N Z J Obstet Gynaecol* 1994;34:197–199.
- Cura, M., Martinez, N., Cura, A., Dalsaso, T.J. & Elmerhi, F. (2009) Arteriovenous malformations of the uterus. *Acta Radiol* 2009;50:823–829.
- Fakhri, A., Fishman, E.K., Mitchell, S.E., Siegelman, S.S. & White, R.I. (1987) The role of CT in the management of pelvic arteriovenous malformations. *Cardiovasc Intervent Radiol* 1987;10:96–99.
- Hugues, C., Le Bras, Y., Coateven, F., Brun, J.L., Trillaud, H., Grenier, N. & Cornelis, F. (2015) Vascular uterine abnormalities: Comparison of imaging findings and clinical outcomes. *Eur J Radiol* 2015;84:2485–2491.
- Calzolari, S., Cozzolino, M. & Castellacci, E. (2016) Uterine Arteriovenous Malformation: Hysteroscopic Identification Is Possible. *J Minim Invasive Gynecol* 2016;23:293–294.
- Corticelli, A., Podesta, M., Pedretti, L., Papadia, A., Francescangeli, E. & Valenzano, M. (2005) Uterine arteriovenous malformation: a case report diagnosed by sonohysterography. *Clin Exp Obstet Gynecol* 2005;32:132–134.
- Yoon, D.J., Jones, M., Taani, J.A., Buhimschi, C. & Dowell, J.D. (2016) A Systematic Review of Acquired Uterine Arteriovenous Malformations: Pathophysiology, Diagnosis, and Transcatheter Treatment. *AJP Rep* 2016;6:e6–e14.
- Timmerman, D., Wauters, J., Van Calenberg, S., Van Schoubroeck, D., Maleux, G., Van Den Bosch, T. & Spitz, B. (2003) Color Doppler imaging is a valuable tool for the diagnosis and management of uterine vascular malformations. *Ultrasound Obstet Gynecol* 2003;21:570–577.
- Yang, J.J., Xiang, Y., Wan, X.R. & Yang, X.Y. (2005) Diagnosis and management of uterine arteriovenous fistulas with massive vaginal bleeding. *Int J Gynaecol Obstet* 2005;89:114–119.
- Kim, T.H. & Lee, H.H. (2010) Presenting features of women with uterine arteriovenous malformations. *Fertil Steril* 2010;94:2330.e7–e10.
- Peitsidis, P., Manolagos, E., Tsekoura, V., Kreienberg, R. & Schwentner, L. (2011) Uterine arteriovenous malformations induced after diagnostic curettage: a systematic review. *Arch Gynecol Obstet* 2011;284:1137–1151.
- Wang, Z., Chen, J., Shi, H., Zhou, K., Sun, H., Li, X., Pan, J., Zhang, X., Liu, W., Yang, N. & Jin, Z. (2012) Efficacy and safety of embolization in iatrogenic traumatic uterine vascular malformations. *Clin Radiol* 2012;67:541–545.
- Ghai, S., Rajan, D.K., Asch, M.R., Muradali, D., Simons, M.E. & TerBrugge, K.G. (2003) Efficacy of embolization in traumatic uterine vascular malformations. *J Vasc Interv Radiol* 2003;14:1401–1408.
- Chen, S.Q., Jiang, H.Y., Li, J.B., Fan, L., Liu, M.J. & Yao, S.Z. (2013) Treatment of uterine arteriovenous malformation by myometrial lesion resection combined with artery occlusion under laparoscopy: a case report and literature review. *Eur J Obstet Gynecol Reprod Biol* 2013;169:172–176.
- Wu, Y.C., Liu, W.M., Yuan, C.C. & Ng, H.T. (2001) Successful treatment of symptomatic arteriovenous malformation of the uterus using laparoscopic bipolar coagulation of uterine vessels. *Fertil Steril* 2001;76:1270–1271.
- Calzolari, S., Cozzolino, M., Castellacci, E., Dubini, V., Farruggia, A. & Sisti, G. (2017) Hysteroscopic Management of Uterine Arteriovenous Malformation. *JLS* 2017;21:pii:e2016.00109.
- Bandura, P., Rawnaq, T., Holzknicht, A., Cetin, E., Reemts, P., Zoi, P. & Schwarzler, P. (2015) Management of Intrauterine Arteriovenous Malformation (AVM) in 14 Patients by Sonographically Guided Tisseel Application. *Ultraschall Med* 2015.
- Ko, J.K., Cheung, V.Y. & Khongsni, P. (2016) Management and outcome of sonographically diagnosed uterine enhanced myometrial vascularity / arteriovenous malformations following early pregnancy events: a single center experience. *Med Ultrason* 2016;18:403–404.
- Lee, T.Y., Kim, S.H., Lee, H.J., Kim, M.J., Lee, S.K., Kim, Y.H. & Cho, S.H. (2014) Ultrasonographic indications for conservative treatment in pregnancy-related uterine arteriovenous malformations. *Acta Radiol* 2014;55:1145–1152.
- Eling, R., Kent, A. & Robertson, M. (2012) Pregnancy after uterine arteriovenous malformation-case series and literature review. *Australas J Ultrasound Med* 2012;15:87–96.

This continuing medical education service is brought to you by MIMS. Read the article 'Management of Acquired Uterine Arteriovenous Malformations Following Early Pregnancy Complications' and answer the following questions. This MIMS JPOG article has been accredited for CME by the Hong Kong College of Obstetricians and Gynaecologists.

CME ARTICLE 1 POINT

Management of Acquired Uterine Arteriovenous Malformations Following Early Pregnancy Complications

Answer True or False to the questions below.

- | | True | False |
|---|-----------------------|-----------------------|
| 1. Acquired uterine EMV/AVM can occur following early pregnancy complications. | <input type="radio"/> | <input type="radio"/> |
| 2. The gold standard for diagnosis of uterine EMV/AVM is hysteroscopy. | <input type="radio"/> | <input type="radio"/> |
| 3. Angiography should be performed to confirm the diagnosis in patients with incidental finding of suspected uterine EMV/AVM on ultrasonography after an early pregnancy complication. | <input type="radio"/> | <input type="radio"/> |
| 4. Conservative management should be adopted for a patient with suspected uterine EMV/AVM presenting with heavy vaginal bleeding and anaemia to preserve fertility. | <input type="radio"/> | <input type="radio"/> |
| 5. Doppler indices can be used to triage asymptomatic patients with uterine EMV/AVM for conservative management or treatment with uterine artery embolization. | <input type="radio"/> | <input type="radio"/> |
| 6. Uterine curettage should be performed in patients with suspected uterine EMV/AVM to rule out retained products of gestation. | <input type="radio"/> | <input type="radio"/> |
| 7. Uterine artery embolization is an effective treatment for symptomatic EMV/AVM. | <input type="radio"/> | <input type="radio"/> |
| 8. A Foley catheter can be used to provide intrauterine tamponade effect to arrest bleeding from uterine EMV/AVM while arranging more definitive treatment such as uterine artery embolization or hysterectomy. | <input type="radio"/> | <input type="radio"/> |
| 9. Most patients with asymptomatic EMV/AVM had a resolution of the condition with conservative management. | <input type="radio"/> | <input type="radio"/> |
| 10. Patients should be advised against travelling to remote areas until ultrasonographic resolution of the EMV/AVM. | <input type="radio"/> | <input type="radio"/> |

Name in BLOCK CAPITALS: _____

Signature: _____

Date: _____

Please mail your completed answer sheet back to:
The Secretariat

Hong Kong College of Obstetricians & Gynaecologists
Room 805, Hong Kong Academy of Medicine Jockey Club Building
99 Wong Chuk Hang Road, Aberdeen, Hong Kong

CME Answers for MIMS JPOG May/June 2017

HKCOG CME Article: Acute Pelvic Inflammatory Disease

Answers

1	2	3	4	5	6	7	8	9	10
F	F	T	F	F	F	F	T	F	T