

Prognostic Value of Ultrasonography in Predicting Therapeutic Outcome for Carpal Tunnel Syndrome after Conservative Treatment: A Retrospective Long-term Follow-up Study

Xue Deng¹, Lai-Heung Phoebe Chau², Suk-Yee Chiu², Kwok-Pui Leung³, Yong Hu¹, Wing-Yuk Ip^{1*}

¹Department of Orthopedics and Traumatology, The University of Hong Kong, Pok Fu Lam, Hong Kong, ²Clinical Neurodiagnostic Unit, Tung Wah Hospital, Sheung Wan, Hong Kong, ³Department of Medicine, The University of Hong Kong, Pok Fu Lam, Hong Kong

Abstract

Purpose: This study aimed at investigating prognostic values of different ultrasound variables in predicting therapeutic outcome of the patients with carpal tunnel syndrome (CTS) after conservative treatment in a long-term follow-up data. **Materials and Methods:** One hundred and three participants with 162 affected hands were enrolled in this retrospective study. Records of baseline clinical information, nerve conduction studies (NCSs), and ultrasound assessment were retrieved. A structured telephone interview was conducted for acquiring patients' response to recovery after treatment. Multinomial logistic regression analysis was used to estimate the odds ratio and 95% confidence interval of individual ultrasound variable, adjusted for age, gender, and other confounding factors. **Results:** Perimeter at wrist (W-P), ratio of cross-sectional area of wrist over one-third distal forearm (R-CSA), changes of CSA from wrist to the one-third distal forearm (Δ CSA), and changes of perimeter from wrist to one-third distal forearm (Δ P) were negatively and significantly associated with "improved" and "no change" categories relative to reference category ("deteriorated" category). After adjustment for age, gender, affected hand side, surgical history, and comorbidity, for one unit increase of W-P/ Δ CSA/ Δ P, the odds of "improved" category versus "deteriorated" category decreased by 89.1%/56%/95.2%, whereas the odds of "no change" relative to "deteriorated" category decreased by 77.8%/54.6%/84.9% should one unit increase in the correspondent individual ultrasound variable. **Conclusion:** Ultrasound variables can significantly predict therapeutic outcome in CTS after conservative management in a long-term follow-up. Further studies may be required to assess whether a combination of clinical, NCS, and ultrasound variables can better predict the therapeutic outcome.

Keywords: Carpal tunnel syndrome, conservative treatment, nerve conduction studies, prognosis, ultrasound

INTRODUCTION

Carpal tunnel syndrome (CTS), primarily caused by localized pressure around the median nerve at the wrist carpal tunnel, is a commonly seen peripheral nerve entrapment syndrome, with an overall prevalence of 2%–3%, accumulative incidence rate of 8%, and estimated lifetime risk of 10% in general population.^[1-4] Although nerve conduction studies (NCSs), accompanied with clinical provocative tests (Tinel's sign and Phalen's test),^[5,6] have long been considered as a golden standard assessment protocol, there were technical pitfalls in diagnosing the syndrome.^[7] In recent years, ultrasound has been introduced by providing morphological information to supplement the diagnostic procedures or provide guidance for injection location

in various never entrapment syndrome and musculoskeletal disorders, such as shoulder nerve entrapment syndrome,^[8] dynapenia,^[9] subacromial corticosteroid injection,^[10] as well as CTS itself.^[7,11-13] Its diagnostic utility for CTS has been robustly verified in previous studies with consistent findings.^[14-16]

In clinical practice, there are mainly two types of treatment for managing CTS. Surgical release of the transverse carpal ligament is mostly recommended with strong evidence

Address for correspondence: Dr. Wing-Yuk Ip, Department of Orthopedics and Traumatology, The University of Hong Kong, PB505, Professorial Block, Queen Mary Hospital, Pok Fu Lam 999077, Hong Kong. E-mail: wyip@hku.hk

Received: 13-02-2019 Revised: 06-03-2019 Accepted: 01-04-2019 Available Online: 13-05-2019

Access this article online

Quick Response Code:



Website:
www.jmuonline.org

DOI:
10.4103/JMU.JMU_13_19

This is an open access journal, and articles are distributed under the terms of the Creative Commons Attribution-NonCommercial-ShareAlike 4.0 License, which allows others to remix, tweak, and build upon the work non-commercially, as long as appropriate credit is given and the new creations are licensed under the identical terms.

For reprints contact: reprints@medknow.com

How to cite this article: Deng X, Chau LH, Chiu SY, Leung KP, Hu Y, Ip WY. Prognostic value of ultrasonography in predicting therapeutic outcome for carpal tunnel syndrome after conservative treatment: A retrospective long-term follow-up study. *J Med Ultrasound* 2019;27:192-7.

when denervation occurs while a variety of conservative management included splinting, laser therapy, home program, and medication is recommended with a variant level of evidence supported when current treatment fails or surgical option is rejected.^[17] Nevertheless, tremendous controversies remained regarding the prognostic value of baseline ultrasound for therapeutic outcome in both long-term and short-term follow-up studies. In the surgical studies, Naranjo *et al.*^[18] indicated better improvement after surgical decompression for 112 CTS wrists with larger preoperative cross-sectional area (CSA) of the median nerve measured by ultrasound compared to those with smaller ones. By contrast, Mondelli *et al.*^[19] reported that 67 CTS hands with smaller CSAs were associated with a higher chance of patient satisfaction after surgical decompression. Some studies even reported that baseline CSA was not a significant predictor for clinical outcome after surgical release.^[20,21] On the other hand, the current evidence regarding the prognostic value of ultrasound for conservative management were rare. A recent study even questioned about the predictability of ultrasound in long-term recovery after conservative management.^[22] It seemed the association between baseline ultrasound variables and long-term recovery remained ambiguous.

To clarify this disputation, our study focused on investigating prognostic abilities of various ultrasound parameters at baseline for long-term recovery of CTS patients after conservative management. Our null hypothesis is ultrasound variables cannot predict long-term therapeutic outcome after conservative treatment in CTS. Bearing the nature of economic benefits, simplicity, and noninvasiveness in ultrasound,^[12] this study can be of clinical significance to clarify its prognostic values in CTS management, benefiting clinicians from better treatment regimen planning.

MATERIALS AND METHODS

This retrospective study was approved by the Institutional Review Board (XXX IRB, Ref. Number: UW17-129), registered in clinical trials registry (XXXCTR-2220), and conducted strictly in line with the Declaration of Helsinki.

According to the records of Clinical Management System, participants who received conservative treatment after diagnosis confirmed from January 2016 to January 2017 were enrolled by convenience sampling. The records of electroneurophysiological and ultrasound measurements at baseline were fully retrieved. All the NCS and ultrasound procedures were completed by a specialized physician, who followed the standard procedures described in our previous studies, with clear delineation as follow.^[23]

Procedures of nerve conduction studies and ultrasound

An NCS machine (Nicolet, Middleton, WI, USA) was used to perform NCS procedures. Orthodromic stimulation was applied to assess median sensory nerve function at the wrist by placing recording rings placed at the index finger. Then, the median motor nerve status was assessed by stimulation at

palm (4 cm distal to the wrist), wrist (6.5 cm proximal to the thenar muscle), and elbow (just above the crease of antecubital fossa), respectively. Following NCS, a real-time ultrasound scanner (MyLab™ Twice, Esaote, Maastricht, the Netherlands) with a 4–13 MHz linear array transducer was utilized to perform transverse scan from carpal tunnel inlet to the distal one-third forearm. CSA and perimeter at wrist (W-CSA and W-P) and one-third distal forearm (DF-CSA and DF-P) were tracked continuously by outlining the hyperechoic epineurium [Figures 1 and 2]. Ratios were calculated according to the formula as follows: $R-CSA = |CSA-I|/|DF-CSA|$ and $R-P = |W-P|/|DF-P|$, respectively, whereas changes from wrist to distal one-third forearm (ΔCSA and ΔP) were acquired in line with the following formula: $\Delta CSA = |CSA-I| - |DF-CSA|$ and $\Delta P = |W-P| - |DF-P|$, respectively.

Prescription of conservative treatment

Conservative management was prescribed for patients with mild-to-moderate grade or those who rejected surgery even though they fulfilled the surgical criteria. The conservative management included prescription of resting splint, steroid injection, tendon/nerve gliding exercise, physical agent modalities, educational session at outpatient clinic, and taking nonsteroidal anti-inflammatory drugs.

Inclusion/exclusion criteria

The inclusion criteria were set as follows: (1) age <0 years, (2) diagnosis confirmed when (a) clinical provocative tests (Phalen's test and Tinel's sign) showed positive results, with clinical symptoms such as numbness, tingling, or pain sustained over a period of 3 months; (b) NCS: distal motor latency >4.5 ms, and/or sensory conduction velocity/motor conduction velocity <50 m/s;^[24] and (c) ultrasound: W-CSA >9 mm² and/or R-CSA >1.4,^[12,25] and (3) right handedness; whereas the exclusion criteria were (1) age ≥70 years, (2) abnormal anatomical structure of the median nerve such as bifid structure, and (3) absent records of NCS and/or ultrasound reports.

A structured telephone interview was performed by an occupational therapist since January 2018 (at least 1 year post the treatment period), asking patients' recovery of their specific affected hand(s). Their responses were categorized into (1) improved, when their responses were "fully recovered," "syndrome disappeared," or "symptoms relieved;" (2) no change should their responses be "the symptoms sustained" or "no improvement;" and (3) deteriorated: under the condition that they replied "symptoms (e.g., numbness, tingling, or pain) got worse" or "symptoms aggravated."

Statistical analysis

IBM SPSS Statistics 24 (SPSS Inc., Armonk, New York, USA) was used for analyzing the data. Demographics, NCS, and ultrasound characteristics were generated descriptively. To investigate the prognostic value of baseline ultrasound variables for predicting therapeutic outcome, multinomial logistic regression analysis was used to estimate the odds ratio (OR) of ultrasound variables. Multinomial logistic regression is usually utilized to predict probabilities of

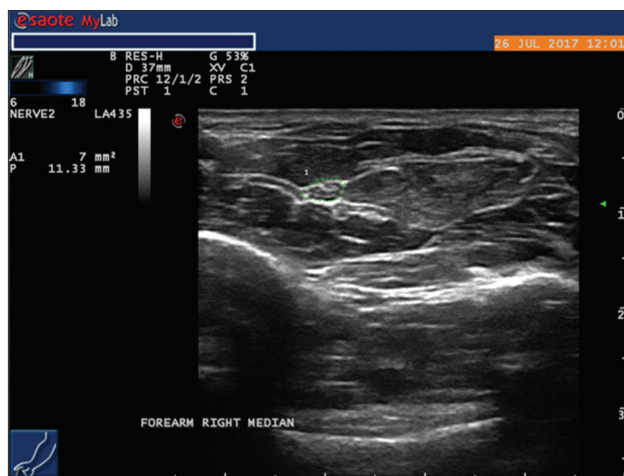


Figure 1: Ultrasound measurement of median nerve at one-third distal forearm (Green dash line circled)

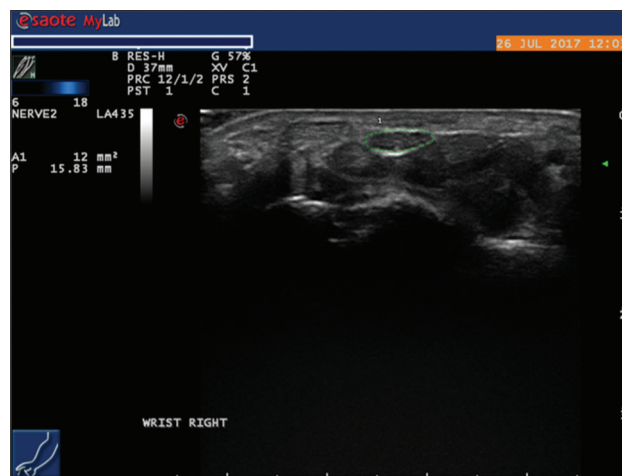


Figure 2: Ultrasound measurement of median nerve at wrist carpal tunnel (Green dash line circled)

different categorical dependent outcomes based on a set of independent variables.^[26] In this model, the outcome variable was the therapeutic outcome, including (1) improved, (2) no change, and (3) deteriorated, with “deteriorated” taken as the reference category after adjustment made for age, gender, affected hand side, surgical history, and comorbidities. Regressors were summarized as follow for establishment of the regression model: (1) age – unit in year; (2) gender – male or female; (3) NCS severity grade: from mild to very severe grade based on the Bland’s classification;^[24] (4) affected hand side: left or right side; (5) comorbidities – (a) CTS-relevant comorbidity: comorbidities that may cause CTS, including diabetes mellitus, thyroid dysfunction, urinary retention, menopause, high blood pressure, obesity, rheumatoid arthritis, hemodialysis, pseudogout, polymyalgia rheumatic, acromegaly (hormonal disorder), stenosis (abnormal narrowing) at carpal tunnel, fractures or trauma to the wrist, and patent median artery; (b) CTS-irrelevant comorbidities: comorbidities which may not cause CTS, such as skin abscess, endometrial polyp, cellulitis (bacterial skin infection), cataract, constipation, gastritis, glaucoma; and (c) no comorbidities; (6) surgical history – surgical record within recent 2 years was reviewed and categorized as follow: (a) CTS-relevant surgical history: surgeries which were associated with CTS-relevant comorbidities mentioned above, including thyroidectomy (surgical removal of thyroid), hysterectomy (surgical removal of the uterus), oophorectomy (surgical removal of ovaries), and open reduction and internal fixation at wrist; (b) CTS-irrelevant surgery: surgeries which were disassociated with CTS-relevant comorbidities, including hysteroscopy (inspection of the uterine cavity by endoscopy), excision of skin lipoma (surgical excision of knob of fatty tissue), laminoplasty (surgical pressure relief for spinal stenosis), prostatectomy (surgical removal of prostate gland), cholecystectomy (surgical removal of gallbladder), laparoscopy (surgical procedure to facilitate fiberoptic instrument to view abdominal organ), sigmoidectomy (surgical removal of sigmoid colon), and angioplasty (surgically

widening narrowed or obstructed arteries or veins); and (c) no surgical history within 2 years; and (7) ultrasound variable: W-CSA, W-P, R-CSA, R-P, Δ CSA, and Δ P.

RESULTS

Subject characteristics

As shown in Table 1, a total of 103 participants with 162 CTS hands were finally enrolled in the study, with 50% (81 out of 162) of the enrolled hands improved, 37.7% (61 out of 162) unchanged, and 12.3% (20 out of 162) deteriorated, respectively. The mean age of the enrolled participants was 61.3 ± 11.62 years old. About 81% (83 out of 103) of the enrolled participants were female and 53.7% of the enrolled hands were diagnosed as severe grade or above. 32% of the participants were associated with CTS-relevant comorbidities while 12.6% had CTS-relevant surgical history. The overall performance of NCS and ultrasound indicated all the enrolled participants fulfilled the criteria of diagnostic confirmation for CTS.

Baseline ultrasound variables for the prediction of long-term therapeutic outcome

As shown in Table 2, after adjustment for age, gender, affected hand side, surgical history, and comorbidity, ultrasound variables, including W-P (OR: 0.109; 95% confidence interval [CI]: [0.039, 0.308]); Δ CSA (OR: 0.44; 95% CI: [0.222, 0.871]); and Δ P (OR: 0.048; 95% CI: [0.014, 0.169]), were negatively and significantly associated with “improved” categories relative to reference category (“deteriorated” category). For one unit increase of W-P/ Δ CSA/ Δ P (each correspondent variable increase value 1), the odds of “improved” category versus “deteriorated” category decreased by 89.1%/56%/95.2%, respectively. On the other hand, in “no change” category, the odds of W-P (OR: 0.222; 95% CI: [0.082, 0.605])/ Δ CSA (OR: 0.454; 95% CI: [0.228, 0.905])/ Δ P (OR: 0.151; 95% CI: [0.046, 0.496]) in “no change” category relative to “deteriorated” category were also negatively and significant associated. For one unit increase in each ultrasound variable,

Table 1: Demographics, nerve conduction studies, and ultrasound characteristics

Baseline variables	Conservative group (n=162 hands)
Therapeutic outcome (%)	
Improved	81 (50)
No change	61 (37.7)
Deteriorated	20 (12.3)
Age (years), mean (SD)	61.3 (11.62)
Gender	
Male	20
Female	83
Affected hand side (%)	
Right hand	84 (51.9)
Left hand	78 (48.1)
Severity grade (%)	
Mild	15 (9.3)
Moderate	16 (9.9)
Moderate to severe	44 (27.2)
Severe	85 (52.5)
Very severe	2 (1.2)
Comorbidity (%)	
CTS relevant	33 (32)
CTS irrelevant	55 (53.4)
No comorbidities	15 (14.6)
Surgical history (%)	
CTS relevant	13 (12.6)
CTS irrelevant	31 (30.1)
No surgeries within 2 years	59 (57.3)
NCS performance, mean (SD)	
DML	6.58 (2.04)
CMAP	6.79 (3.47)
MCV	19.68 (8.39)
DSL	3.45 (0.6)
SNAP	9.38 (5.88)
SCV	35.18 (4.57)
Ultrasound variables, mean (SD)	
W-CSA	14.58 (1.3)
W-P	18.16 (1.49)
R-CSA	2.31 (0.14)
R-P	1.72 (0.12)
Δ CSA	8.25 (1.02)
Δ P	7.61 (1.25)

CTS: Carpal tunnel syndrome, NCSs: Nerve conduction studies, DML (ms): Distal ML, ML (ms): Motor latency, CMAP (mV): Compound motor action potential, MCV (m/s): Motor conduction velocity, DSL (ms): Distal sensory latency, SNAP (μ V): Sensory nerve action potential, SCV (m/s): Sensory conduction velocity, W-CSA (mm^2): Cross-sectional area at wrist, W-P (mm): Perimeter at wrist, R-CSA: Ratio of cross-sectional area of wrist over one-third distal forearm, R-P: Ratio of perimeter of wrist over one-third distal forearm, Δ CSA (mm^2): Changes of cross-sectional area from wrist to one-third distal forearm, Δ P (mm): Changes of perimeter from wrist to one-third distal forearm, SD: Standard deviation

the odds of “no change” versus “deteriorated” category decreased by 77.8%/54.6%/84.9%, respectively. In addition, we also found statistically significant ORs both in R-CSA and R-P, but there was no clinical prognostic significance as the values of OR for each variable were too small [Table 2].

In general, the overall result indicates that there are prognostic values of ultrasound for predicting long-term recovery of CTS after conservative management. A worse baseline condition of median nerve reflected by ultrasound is indicative of less satisfactory recovery after conservative management in a long run.

DISCUSSION

To the best of our knowledge, this is the first retrospective study to investigate prognostic ability of ultrasound variables in predicting recovery after conservative treatment in a long-term follow-up data. Our major findings implied that ultrasound can predict therapeutic outcome in CTS in a long-term recovery after conservative treatment. The reason for lack of evidence regarding prognostic values of ultrasound in conservative studies may be because the conservative management varies in terms of treatment modalities, dosage, package, and duration bringing in difficulties for standardization when figuring out the study design. Each individual hand may have been treated with single or multiple conservative approaches, which can cause difficulty to standardize the diversified treatment protocol. There is a dilemma for researchers when conservative treatment protocol was too clearly specified as it may require a much larger sample size or deviate the primary study goal. Nevertheless, it is not equivalent to say exploration of prognostic abilities of ultrasound for conservative management is unattainable or pragmatically insignificant. It is still of great clinical significance to explore the prognostic values of ultrasound besides its well-studied diagnostic values due to numerable evidence on the effectiveness of conservative management for CTS and increasing use of ultrasound in various aspects of clinical practice. To improve the feasibility for prognostic exploration, we have standardized the time point of follow-up telephone interview, participants' admission date, characteristics, and many other baseline information. We also categorized all the conservative approaches under an umbrella term such that a reasonable sample size can be guaranteed.

Even though the current limited evidences were contradictory to ours, questioning the prognostic value of ultrasound in long-term clinical outcomes after conservative management.^[22] However, the sample size in their studies was small, with no explanation for the lack of association. In spite of this, the long-term clinical efficacy after local steroid injection has been reported in a previous 2-year follow-up study.^[27] In our studies, those who received local steroid injection were also enrolled, which may possibly contribute to the significant result of our studies. Therefore, it can be estimated that significant prognostic ability of ultrasound variables in conservative management is pragmatically obtainable.

Regarding model establishment, we identified and categorized the disorder factor associated with CTS into the category of CTS-relevant comorbidities based on previous large epidemic studies.^[28-37] Meanwhile, we clustered types of surgery which are associated/disassociated with correspondent risk factors

Table 2: Multinomial logistic regression for long-term outcome after conservative treatment in carpal tunnel syndrome

Ultrasound variables	Improved ($n_1=81$) versus deteriorated category		No change ($n_2=61$) versus deteriorated category	
	Unadjusted OR (95% CI)	Adjusted OR [†] (95% CI)	Unadjusted OR (95% CI)	Adjusted OR [†] (95% CI)
W-CSA	0.742 (0.488, 1.128)	0.726 (0.438, 1.203)	0.7 (0.456, 1.076)	0.629 (0.373, 1.06)
W-P	0.168** (0.079, 0.355)	0.109** (0.039, 0.308)	0.372** (0.184, 0.752)	0.222** (0.082, 0.605)
R-CSA	4.978E-5** (3.779E-7, 0.007)	2.868E-5** (1.004E-7, 0.008)	0.001** (5.147E-6, 0.082)	0.000 (1.547E-6, 0.108)
R-P	1.153E-10** (2.955E-14, 4.496E-7)	3.227E-14** (1.676E-19, 6.214E-9)	5.045E-5** (4.991E-8, 0.051)	5.918E-8** (1.917E-12, 0.003)
ΔCSA	0.461* (0.256, 0.829)	0.44* (0.222, 0.871)	0.504* (0.277, 0.915)	0.454* (0.228, 0.905)
ΔP	0.101** (0.043, 0.235)	0.048** (0.014, 0.169)	0.311** (0.146, 0.663)	0.151** (0.046, 0.496)

* <0.05 , ** <0.01 , reference category was “deteriorated” category, [†]Adjusted for age, gender, affected hand side, surgical history, and comorbidity.

OR: Odds ratio, 95 CI: 95% confidence interval, W-CSA (mm²): Cross-sectional area at wrist, W-P (mm): Perimeter at wrist, R-CSA: Ratio of cross-sectional area of wrist over one-third distal forearm, R-P: Ratio of perimeter of wrist over one-third distal forearm, ΔCSA (mm²): Changes of cross-sectional area from wrist to the one-third distal forearm, ΔP (mm): Changes of perimeter from wrist to one-third distal forearm

into CTS-relevant/irrelevant categories. Nevertheless, we did not find significant prognostic values of comorbidities and surgical history for functional recovery. We infer it may be due to small sample size, lack of a control population, which was also identical with points of view from the previous epidemic studies.^[38]

On the whole, this is the first retrospective study to report significant prognostic value of ultrasound variables for long-term recovery after conservative treatment. Even though there are drawbacks of utilizing subjective outcome in prognostic studies,^[20] previous studies indicated neither clinical tests nor NCS parameters could reliably predict recovery after treatment.^[18,39,40] Further studies may be required to assess whether a combination of clinical, NCS, and ultrasound variables can better predict the therapeutic outcome of CTS patients.

Nevertheless, there are several limitations in our study. First, we did not involve clinical outcome measurement tools to reflect the therapeutic outcome. However, previous literature demonstrated binary responses to measure satisfaction and resolution of symptoms.^[41] Statistical significant changes in clinical measurements are not necessarily equivalent to clinical importance.^[42] A large minimal clinically important difference was also found in the Levine Carpal Tunnel Questionnaire, which may constrain its use for detecting clinical significant outcome.^[43] On the other hand, small sample size, lack of symptom duration due to incomplete documentation, and no clear differentiation of conservative therapeutic approaches may also result in biased results. Further randomized clinical trials with a larger sample size are required to examine patients' overall improvement.

CONCLUSION

Ultrasound variables can significantly predict therapeutic outcome after conservative management in CTS in a long-term follow-up. Further studies with a larger sample size can be taken into act to assess whether a combination of clinical, NCS, and ultrasound variables can better predict the therapeutic outcome of CTS patients after conservative management.

Acknowledgment

I attest that written permission has been obtained from all individuals in the authors' list. We would like to express our gratitude to Dr. Lui Yuk-Fai, from the Department of Orthopedics and Traumatology, the University of Hong Kong, who helped in refining the language for publication.

Financial support and sponsorship

Nil.

Conflicts of interest

There are no conflicts of interest.

REFERENCES

- Viera AJ. Management of carpal tunnel syndrome. *Am Fam Physician* 2003;68:265-72.
- Atroshi I, Gummesson C, Johnsson R, Ornstein E, Ranstam J, Rosén I. Prevalence of carpal tunnel syndrome in a general population. *JAMA* 1999;282:153-8.
- Rempel D, Evanoff B, Amadio PC, de Krom M, Franklin G, Franzblau A, *et al.* Consensus criteria for the classification of carpal tunnel syndrome in epidemiologic studies. *Am J Public Health* 1998;88:1447-51.
- Werner RA, Andary M. Carpal tunnel syndrome: Pathophysiology and clinical neurophysiology. *Clin Neurophysiol* 2002;113:1373-81.
- El Miedany YM, Aty SA, Ashour S. Ultrasonography versus nerve conduction study in patients with carpal tunnel syndrome: Substantive or complementary tests? *Rheumatology (Oxford)* 2004;43:887-95.
- Baiee RH, AL-Mukhtar NJ, Al-Rubiae SJ, Hammoodi ZH, Abass FN. Neurophysiological findings in patients with carpal tunnel syndrome by nerve conduction study in comparing with ultrasound study. *J Nat Sci Res* 2015;5:111-28.
- Mallik A, Weir AI. Nerve conduction studies: Essentials and pitfalls in practice. *J Neurol Neurosurg Psychiatry* 2005;76 Suppl 2:ii23-31.
- Wu WT, Chang KV, Mezian K, Naňka O, Lin CP, Özçakar L, *et al.* Basis of shoulder nerve entrapment syndrome: An ultrasonographic study exploring factors influencing cross-sectional area of the suprascapular nerve. *Front Neurol* 2018;9:902.
- Chang KV, Wu WT, Huang KC, Jan WH, Han DS. Limb muscle quality and quantity in elderly adults with dynapenia but not sarcopenia: An ultrasound imaging study. *Exp Gerontol* 2018;108:54-61.
- Chang KV, Wu WT, Han DS, Özçakar L. Static and dynamic shoulder imaging to predict initial effectiveness and recurrence after ultrasound-guided subacromial corticosteroid injections. *Arch Phys Med Rehabil* 2017;98:1984-94.
- Graham B, Dvali L, Regehr G, Wright JG. Variations in diagnostic criteria for carpal tunnel syndrome among Ontario specialists. *Am J Ind Med* 2006;49:8-13.

12. Duncan I, Sullivan P, Lomas F. Sonography in the diagnosis of carpal tunnel syndrome. *Am J Roentgenol* 1999;173:681-4.
13. Klauser AS, Abd Ellah MM, Halpern EJ, Siedentopf C, Auer T, Eberle G, *et al.* Sonographic cross-sectional area measurement in carpal tunnel syndrome patients: Can delta and ratio calculations predict severity compared to nerve conduction studies? *Eur Radiol* 2015;25:2419-27.
14. Mondelli M, Filippou G, Gallo A, Frediani B. Diagnostic utility of ultrasonography versus nerve conduction studies in mild carpal tunnel syndrome. *Arthritis Rheum* 2008;59:357-66.
15. Azami A, Maleki N, Anari H, Iranparvar Alamdari M, Kalantarhormozi M, Tavosi Z. The diagnostic value of ultrasound compared with nerve conduction velocity in carpal tunnel syndrom. *Int J Rheum Dis* 2014;17:612-20.
16. Fernández-de-Las-Peñas C, Cleland JA, Salom-Moreno J, Palacios-Ceña M, Martínez-Perez A, Pareja JA, *et al.* Prediction of outcome in women with carpal tunnel syndrome who receive manual physical therapy interventions: A validation study. *J Orthop Sports Phys Ther* 2016;46:443-51.
17. Graham B, Peljovich AE, Afra R, Cho MS, Gray R, Stephenson J, *et al.* The american academy of orthopaedic surgeons evidence-based clinical practice guideline on: Management of carpal tunnel syndrome. *J Bone Joint Surg Am* 2016;98:1750-4.
18. Naranjo A, Soledad O, Virginia A, Baeta P, Fernández-Palacios J, García-Duque O, *et al.* Usefulness of clinical findings, nerve conduction studies and ultrasonography to predict response to surgical release in idiopathic carpal tunnel syndrome. *Clin Exp Rheumatol* 2009;27:786-93.
19. Mondelli M, Filippou G, Aretini A, Frediani B, Reale F. Ultrasonography before and after surgery in carpal tunnel syndrome and relationship with clinical and electrophysiological findings. A new outcome predictor? *Scand J Rheumatol* 2008;37:219-24.
20. Bland JD, Rudolfer SM. Ultrasound imaging of the median nerve as a prognostic factor for carpal tunnel decompression. *Muscle Nerve* 2014;49:741-4.
21. Ibrahim I, Khan WS, Goddard N, Smitham P. Carpal tunnel syndrome: A review of the recent literature. *Open Orthop J* 2012;6:69-76.
22. Marschall A, Ficjian A, Stradner MH, Husic R, Zauner D, Seel W, *et al.* The value of median nerve sonography as a predictor for short- and long-term clinical outcomes in patients with carpal tunnel syndrome: A prospective long-term follow-up study. *PLoS One* 2016;11:e0162288.
23. Deng X, Chau LP, Chiu SY, Leung KP, Li SW, Ip WY, *et al.* Exploratory use of ultrasound to determine whether demyelination following carpal tunnel syndrome co-exists with axonal degeneration. *Neural Regen Res* 2018;13:317-23.
24. Bland JD. A neurophysiological grading scale for carpal tunnel syndrome. *Muscle Nerve* 2000;23:1280-3.
25. Altinok T, Baysal O, Karakas HM, Sigirci A, Alkan A, Kayhan A, *et al.* Ultrasonographic assessment of mild and moderate idiopathic carpal tunnel syndrome. *Clin Radiol* 2004;59:916-25.
26. Chang KV, Chen WS, Wang TG, Hung CY, Chien KL. Associations of sonographic abnormalities of the shoulder with various grades of biceps peritendinous effusion (BPE). *Ultrasound Med Biol* 2014;40:313-21.
27. Ly-Pen D, Andréu JL, Millán I, de Blas G, Sánchez-Olaso A. Comparison of surgical decompression and local steroid injection in the treatment of carpal tunnel syndrome: 2-year clinical results from a randomized trial. *Rheumatology (Oxford)* 2012;51:1447-54.
28. De Krom MC, Knipschild PG, Kester AD, Thijs CT, Boekkooy PF, Spaans F. Carpal tunnel syndrome: Prevalence in the general population. *J Clin Epidemiol* 1992;45:373-6.
29. Stevens JC, Beard CM, O'Fallon WM, Kurland LT. Conditions associated with carpal tunnel syndrome. *Mayo Clin Proc* 1992;67:541-8.
30. Bicknell JM, Lim AC, Raroque HG Jr., Tzamaloukas AH. Carpal tunnel syndrome, subclinical median mononeuropathy, and peripheral polyneuropathy: Common early complications of chronic peritoneal dialysis and hemodialysis. *Arch Phys Med Rehabil* 1991;72:378-81.
31. Patrick MG, Watt I, Dieppe PA, Doherty M. Peripheral nerve entrapment at the wrist in pyrophosphate arthropathy. *J Rheumatol* 1988;15:1254-7.
32. Ahmed T, Braun AI. Carpal tunnel syndrome with polymyalgia rheumatica. *Arthritis Rheum* 1978;21:221-3.
33. Dekel S, Papaioannou T, Rushworth G, Coates R. Idiopathic carpal tunnel syndrome caused by carpal stenosis. *Br Med J* 1980;280:1297-9.
34. Lavey EB, Pearl RM. Patent median artery as a cause of carpal tunnel syndrome. *Ann Plast Surg* 1981;7:236-8.
35. O'Duffy JD, Randall RV, MacCarty CS. Median neuropathy (carpal-tunnel syndrome) in acromegaly. A sign of endocrine overactivity. *Ann Intern Med* 1973;78:379-83.
36. Dorwart BB, Schumacher HR. Joint effusions, chondrocalcinosis and other rheumatic manifestations in hypothyroidism: A clinicopathologic study. *Am J Med* 1975;59:780-90.
37. Roquer J, Cano JF. Carpal tunnel syndrome and hyperthyroidism. A prospective study. *Acta Neurol Scand* 1993;88:149-52.
38. Solomon DH, Katz JN, Bohn R, Mogun H, Avorn J. Nonoccupational risk factors for carpal tunnel syndrome. *J Gen Intern Med* 1999;14:310-4.
39. Choi SJ, Ahn DS. Correlation of clinical history and electrodiagnostic abnormalities with outcome after surgery for carpal tunnel syndrome. *Plast Reconstr Surg* 1998;102:2374-80.
40. Fernández-de-Las-Peñas C, Ortega-Santiago R, de la Llave-Rincon AI, Martínez-Perez A, Fahandezh-Saddi Diaz H, Martínez-Martín J, *et al.* Manual physical therapy versus surgery for carpal tunnel syndrome: A randomized parallel-group trial. *J Pain* 2015;16:1087-94.
41. Longstaff L, Milner RH, O'Sullivan S, Fawcett P. Carpal tunnel syndrome: The correlation between outcome, symptoms and nerve conduction study findings. *J Hand Surg Br* 2001;26:475-80.
42. Hägg O, Fritzell P, Nordwall A. The clinical importance of changes in outcome scores after treatment for chronic low back pain. *Eur Spine J* 2003;12:12-20.
43. Kim JK, Jeon SH. Minimal clinically important differences in the carpal tunnel questionnaire after carpal tunnel release. *J Hand Surg Eur* 2013;38:75-9.