

# The Natural History of Ossification of Yellow Ligament of the Thoracic Spine on MRI: A Population-Based Cohort Study


Global Spine Journal

1-10

© The Author(s) 2020

Article reuse guidelines:  
[sagepub.com/journals-permissions](http://sagepub.com/journals-permissions)  
 DOI: 10.1177/2192568220903766  
[journals.sagepub.com/home/gsj](http://journals.sagepub.com/home/gsj)



Chris Yuk Kwan Tang, MBBS, FHKCOS, FHKAM, FRCSEd<sup>1,\*</sup> ,  
 Kenneth Man Chee Cheung, MBBS, MD, FRCS, FHKCOS, FHKAM<sup>1</sup>,  
 Dino Samartzis, DSc<sup>1</sup>, and Jason Pui Yin Cheung, MBBS, MMedSc,  
 MS, MD, PDipMDPath, FHKCOS, FHKAM, FRCSEd<sup>1,\*</sup>

## Abstract

**Purpose:** To assess the natural history of ossification of yellow ligament (OYL) in the thoracic spine and determine risk factors for progression based on a longitudinal population-based cohort.

**Methods:** A prospective, longitudinal cohort study was performed on a population-based cohort of Southern Chinese volunteers. T2-weighted magnetic resonance imaging (MRI) was used at baseline to identify any OYL and was verified with computed tomography. Follow-up MRI was performed 5 years later. Parameters under study included the size of OYL, levels of involvement, morphology (round, triangular, beak), whether it crossed the midline and any disc degeneration.

**Results:** A total of 114 (6.1%) individuals were identified to have OYL at baseline out of the 1864 individuals. Size progression occurred predominantly at the lower thoracic region. Majority of the new OYL were also in the lower thoracic spine and was associated with higher body mass index (BMI). Smokers were associated with OYL size progression while patients with higher BMI tended to develop new OYL at follow-up. Progression commonly occurred at the lower thoracic levels and regression occurred mostly at the upper thoracic levels.

**Conclusions:** This is the first population-based series addressing the natural history of OYL. Better understanding of the natural history of OYL may provide incentive to introduce preventive measures such as weight reduction and close monitoring for myelopathy development in those at-risk groups for progression. This is especially important for patients with lower thoracic OYL and who are smokers with higher BMI.

**Level of Evidence:** I (prognostic study).

## Keywords

ossification of yellow ligament (OYL), ligamentum flavum, natural history, thoracic

## Introduction

Ligamentum flavum, also known as the yellow ligament, is in close proximity to the spinal cord. If it undergoes ossification, these ossified yellow ligaments (OYL) may cause spinal cord compression.<sup>1</sup> A previous population study showed that the overall prevalence of OYL within the Southern Chinese population was 3.8%.<sup>2</sup> It also showed that T2-weighted sagittal magnetic resonance imaging (MRI) was able to identify OYL as a hypointense signal intensity at the posterior margin of the

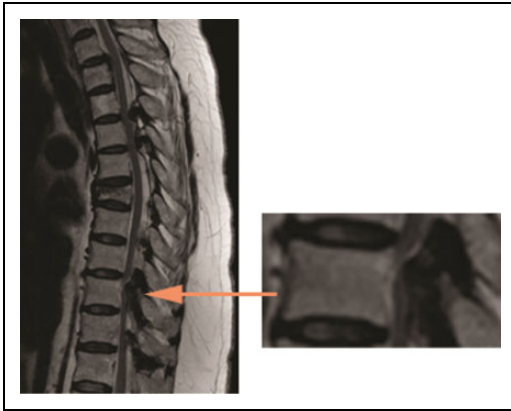
<sup>1</sup> The University of Hong Kong, Pokfulam, Hong Kong, SAR, China

\* Chris Yuk Kwan Tang and Jason Pui Yin Cheung contributed equally to this study.

### Corresponding Author:

Jason Pui Yin Cheung, Professorial Block, 5th Floor, 102 Pokfulam Road, Department of Orthopaedics and Traumatology, The University of Hong Kong, Queen Mary Hospital, Pokfulam Road, Hong Kong SAR, China.  
 Email: [cheungjp@hku.hk](mailto:cheungjp@hku.hk)





**Figure 1.** Ossified yellow ligament (OYL; orange arrow) indicated by a hypodense lesion on sagittal T2-weighted magnetic resonance imaging.

spinal canal (Figure 1).<sup>3,4</sup> The majority of OYL occurs in the thoracic spine<sup>2</sup> and up to 75% of all cases of thoracic myelopathy are caused by OYL.<sup>5</sup> Thoracic myelopathy usually presents with gait disturbance, lower limb numbness and weakness.<sup>6</sup> Delay in treatment may cause individuals to develop spastic gait, urinary and bowel sphincter incontinence, paraplegia, and bedsores.<sup>6,7</sup> Hence, this condition imposes significant detriment to patients' function.

Thoracic stenosis has been shown to be associated with advanced age and obesity.<sup>8</sup> Decompression surgery is important for neurological improvement in thoracic stenosis. However, decompression surgery in the presence of OYL is not without risk. OYL surgery is inherently high risk for intraoperative dural tear due to dural adhesions.<sup>9</sup> The chance of this complication may further increase with the presence of dural ossification.<sup>10,11</sup> In a series of 110 patients undergoing multi-level lumbar laminectomies,<sup>9</sup> dural tears occurred in all 10 patients with OYL. Moreover, three of these patients (30%) had dural ossification.

The development of OYL is likely a result of endochondral ossification.<sup>12</sup> There are 2 layers of ligamentum flavum: the interlaminar portion over the central (or medial) part and the lateral capsular portion.<sup>12</sup> Ossification is usually initiated in the capsular portion but may progress to the interlaminar area.<sup>13</sup> The ossification then proceeds to enlarge ventrally with compression of the spinal cord. If the ossification occurs bilaterally, the bony mass will then fuse in the middle and thicken to form a central tuberous mass.<sup>13</sup> In the sagittal plane, ossification begins at the site of attachment caudally along the superficial layer of the ligamentum flavum and then progresses cephalo-anteriorly.<sup>12</sup> Articular processes and laminae may also thicken with compact lamellar bone but usually do not directly cause cord compression.

Despite understanding of the pathological process of OYL, its natural history and risk factors for OYL progression are unknown. Similar to its anterior counterpart, the ossified posterior longitudinal ligament (OPLL), natural

history is important as it indicates whether the disease process may continue to deteriorate and it determines when surgeons should intervene.<sup>14</sup> The authors believe that, if OYL progresses with time, treatment should not be delayed even in presence of mild symptoms. Without timely intervention, patients may deteriorate, lose the opportunity to regain complete function, and undergo decompression for more severe OYL, which carries higher risk of complications. Knowing the risk factors for progression can help to identify the high-risk subjects for closer monitoring. As such, this current study aims to identify the natural history of thoracic OYL on MRI and to determine risk factors for OYL progression based on a large-scale, population cohort assessed longitudinally.

## Methods

### Study Design

This was a prospective, longitudinal cohort study of 1864 subjects ( $n = 1158$  women,  $n = 706$  men) as part of the Hong Kong Disc Degeneration Population-Based Cohort.<sup>15-21</sup> This study was ethically approved by a local institutional review board and informed consent was obtained by all subjects. Volunteers were between 18 and 55 years old and were recruited from the population by open invitation. All subjects were of Southern Chinese origin and had baseline T2-weighted sagittal MRI of the whole spine. Exclusion criteria included pregnancy, severe osteoporosis, previous spinal surgery, treated or untreated central nervous system impairment, fracture, illiteracy, subjects unable to undergo MRI scanning because of ferromagnetic implants, severe claustrophobia or inability to tolerate positioning for MRI.

### Imaging

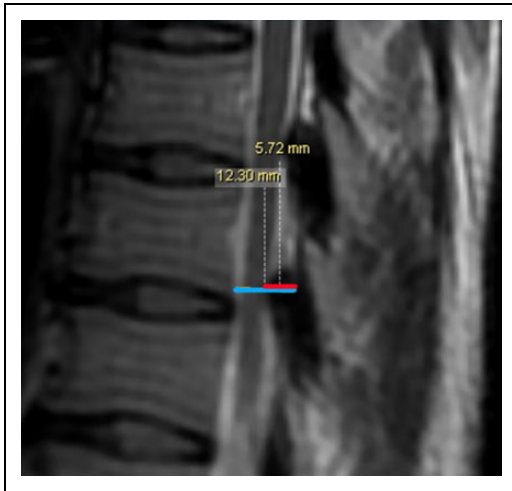
T2-weighted, 5-mm spin-echo sagittal MRI sequences using 1.5-T clinical MRI (General Electric Medical System, Milwaukee, WI, USA) were obtained. The field of view was  $18 \times 18$  cm, slice thickness was 4 mm, and slice spacing was 0 mm. The imaging matrix was  $288 \times 192$ . The repetition time (TR) was 3325 ms and the echo time (TE) was 85 ms. Follow-up MRI used were 3 T.

All included patients had hypointense signal intensities identified on the baseline MRI with subsequent computed tomography (CT) scans to confirm that the lesions were ossifications and not calcifications. Ossification showed bony trabeculae in CT scan whereas calcification did not have trabeculae. Confirmed patients underwent another set of MRI at 5 years of follow-up to assess the natural history of the lesions on imaging.

### Parameters Under Study

Clinical parameters included age, sex, height (meters), weight (kilograms), body mass index (BMI;  $\text{kg}/\text{m}^2$ ), and smoking

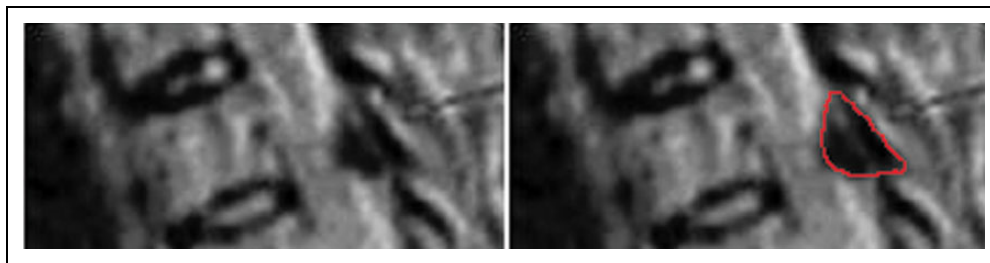
status (smoker or nonsmoker). BMI greater than  $25 \text{ kg/m}^2$  was considered obese, BMI of  $23$  to  $25 \text{ kg/m}^2$  was considered overweight, BMI of  $18.5$  to  $23 \text{ kg/m}^2$  was considered normal, and BMI less than  $18.5 \text{ kg/m}^2$  was considered underweight. Imaging parameters included the size, level of involvement, and morphology of the OYL. As the clinical significance of OYL



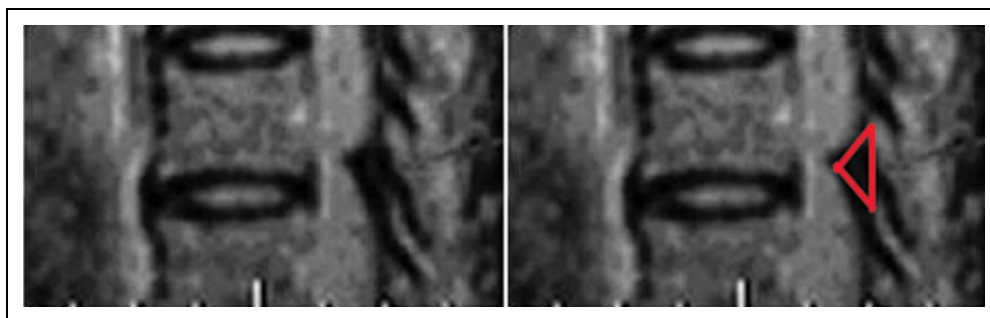
**Figure 2.** Ossified yellow ligament (OYL) size is measured on sagittal T2-weighted magnetic resonance imaging scans. The OYL size is expressed as a percentage of the spinal canal size. The anteroposterior diameter of OYL is first measured (blue line). Then, the spinal canal diameter is measured by the distance from, the posterior longitudinal ligament to the spinolaminar line at the corresponding level (red line). Finally, the first measurement is divided by the second measurement and expressed in terms of a percentage.

progression is represented by an increasing severity of cord compression, the size of the OYL should be expressed as a fill of the spinal canal. Thus, size was expressed as a percentage dividing the anteroposterior diameter of OYL in the sagittal cuts in which the diameter of OYL was largest, by the distance from posterior longitudinal ligament to the spinolaminar line at the corresponding level in the mid-sagittal cut (Figure 2). This provided the narrowest ratio between the 2 distances, which was most clinically relevant. Growth rates were also calculated and defined as the percentage change in OYL size divided by the initial OYL size. The types of OYL morphology had been described<sup>2</sup> as round (Figure 3), triangular (Figure 4), or beak types (Figure 5). The triangular type had a height smaller than or equal to its base while the beak type had a height greater than its base. Other imaging parameters included whether the OYL crossed the midline (bilateral involvement and visible in the mid-sagittal cuts) and the presence of disc degeneration defined as Pfirrmann grade 4 (hypointense disc signal) or 5 (hypointense disc signal with disc space narrowing)<sup>22</sup> and disc protrusion (bulging of the disc beyond the posterior longitudinal ligament).

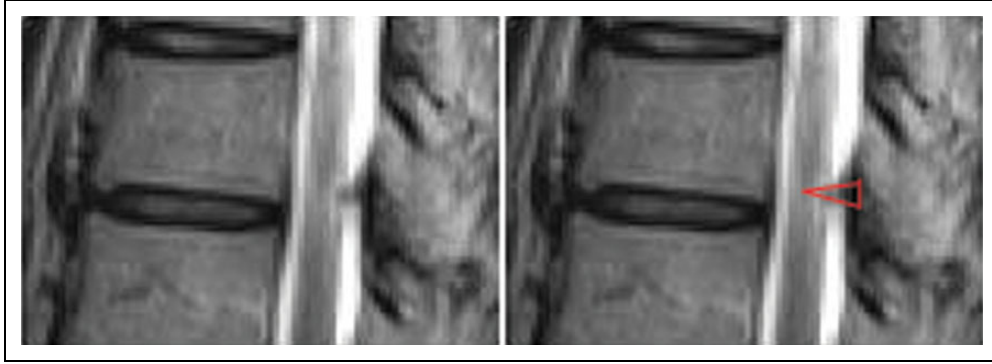
Both original baseline images and 5-year follow-up images were read by 2 experienced orthopedic surgeons independently. Measurement differences of  $>10\%$  for numerical measurements and differences in categorical measurements, if any, were settled by consensus. The average scores were used for analysis. All patient details were blinded to the readers during measurements. They were also blinded to the results of the initial MRI when interpreting the 5-year images. Four major features were studied over the 5-year period including the change in size and morphology, and any disappearance or de



**Figure 3.** Round-type ossified yellow ligament (OYL; red line marked its margin).



**Figure 4.** Triangular-type ossified yellow ligament (OYL) is indicated when the height of the ossification is smaller than or equal to the base (red line marked its margin).



**Figure 5.** Beak-type ossified yellow ligament (OYL) is indicated when the height of the ossification is greater than the base (red line marked its margin).

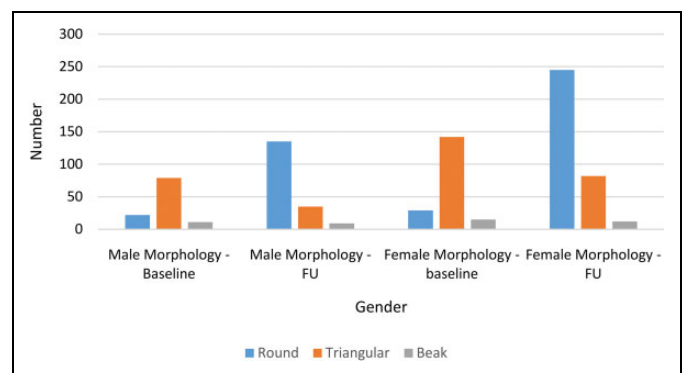
novo appearance. Size progression was defined as a larger sized OYL (in terms of the size of OYL in relation to the size of spinal canal) in the follow-up MRI than that of baseline. Growth rates were expressed as a percentage calculated by dividing the follow-up size by the initial size. Spinal levels were compared from baseline to follow-up to determine any disappearance (absence of OYL at the follow-up but present at baseline) and de novo appearance (presence of OYL at follow-up but not present at baseline).

### Statistical Analysis

Descriptive statistics were expressed in mean  $\pm$  standard deviation (SD). This was used for age, gender, BMI, smoking status, levels of involvement, OYL size, morphology, whether it crossed the midline and disc degeneration. Interobserver reliability was assessed by intraclass correlation (ICC). Cronbach alpha values of .90 to 1.00 were considered to indicate excellent reliability; .70 to .89, good reliability; and  $\leq .69$ , poor reliability.<sup>23,24</sup> Paired *t* tests were used to compare the changes between baseline and follow-up for changes in size and growth rate. Correlations (*r*) between growth rates and levels of involvement were also determined. Chi-square test was used to assess for correlation between smoking status, BMI, and disappearance of de novo appearance of OYL at follow-up.

### Results

At baseline, 114 subjects ( $n = 40$  males and  $n = 74$  females) or 6.1% of the cohort were found to have OYL (Figure 6). There were no dropouts during follow-up. The mean age of subjects was  $47.5 \pm 6.5$  years (range 19.7-60.5 years) (Figure 7) and the mean BMI was  $24.0 \pm 5.6$  kg/m<sup>2</sup> (range 14.2-71.6 kg/m<sup>2</sup>). Up to 7.0% of the study population were smokers. A total of 298 spinal segments were found to have OYL on the baseline MRI and 518 spinal segments had OYL at follow-up indicating an overall progression in OYL observed. The majority (61.7%) of OYL at the baseline MRI were in the lower thoracic region (T8-12: 184 spinal segments). In the follow-up MRI, the majority (54.2%) of OYL were also found in the lower thoracic



**Figure 6.** Ossified yellow ligament (OYL) type according to gender at baseline and follow-up (FU).

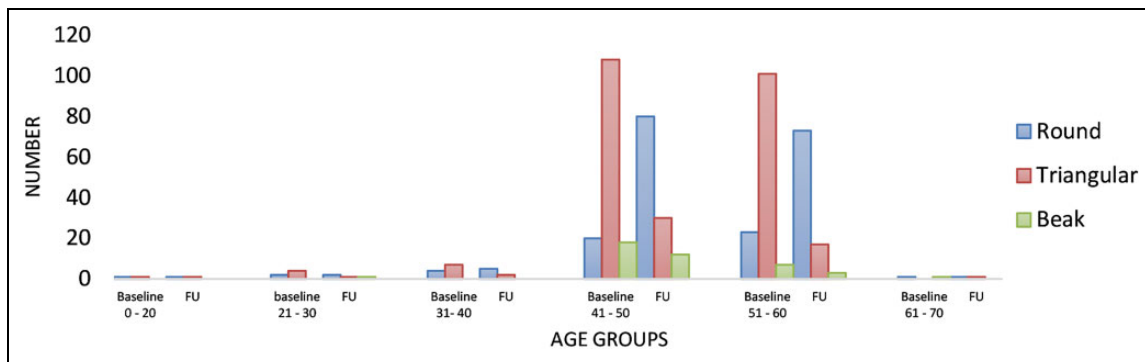
region (T8-12: 281 spinal segments). A total of 31 spinal segments (10.4%;  $n = 14$  subjects) at baseline had OYL that crossed the midline. In addition, 8 (2.7%) spinal segments with OYL had corresponding levels of disc degeneration, all of whom were nonsmokers. Three of these patients had OYL progression. A total of 50 (9.7%) spinal segments in the follow-up MRI had OYL that crossed the midline (20 new spinal segments) and 16 of these (3.1%) had corresponding levels of disc degeneration (9 of these 16 were newly developed).

Of the outcomes described below, no statistically significant associations were found with age, gender, whether the OYL crossed the midline initially and disc degeneration (Table 1).

### Size Progression

The mean initial size of OYL was  $40.8\% \pm 10.9\%$  and the mean size at follow-up was  $41.7\% \pm 11.0\%$ . Majority of OYL in the lower thoracic region, especially T9-T10 level, showed size progression (Figure 8). In the subgroup analysis, 70% of OYL at T9-T10 and 62% of OYL at T10-T11 became larger ( $P < .05$ ). T9-T10 OYL had statistically significant size progression (from 41.8% to 46.3%) while C7-T1 OYL had statistically significant size regression (from 49.4% to 32.9%) ( $P < .05$ ). The chance of size progression was not related to





**Figure 7.** Ossified yellow ligament (OYL) type according to each age group at baseline and follow-up (FU).

**Table 1.** Risk Factors for Changes in Ossified Yellow Ligament (OYL) Size, Morphology, and Disappearance.<sup>a</sup>

	Age	Gender	OYL Crosses Mid-Sagittal Region Initially	Presence of Corresponding Level of Disc Degeneration
Size progression	.24	.95	.67	.55
OYL morphology changes	.05	.12	.61	.15
OYL disappearance	.20	.20	.82	.58

<sup>a</sup> Data are presented as *P* values. *P* < .05 indicates statistical significance.

BMI ( $P = .38$ ) or initial morphology ( $P = .13$ ). Growth rates at T9-T10 and T10-T11 were +13.4% and +3.8%, respectively (Figure 9). Within the level of T9-T10, the growth rate was negatively correlated ( $r = -0.32$ ) with the size of OYL ( $P = .02$ ). This suggested that a smaller sized OYL would grow more, while a larger sized OYL would grow less. A total of 75% of smokers had size progression while only 46% of nonsmokers had size progression ( $P = .04$ ). A total of 53.4% of those with low back pain and 46.7% of those without low back pain had size progression. Presence of low back pain did not predict the size progression of OYL at 5 years ( $P = .39$ ). An example of OYL size progression in 5 years is shown in Figure 10.

### Change in Morphology

Regarding the morphology at baseline, 74.2% were triangular type, 17.1% were round type, and 8.7% were beak type. For the subsequent morphology changes at follow-up, 22.6% remained triangular type, 70.4% were round type, and 7.0% were beak type. Regarding the 74.2% triangular OYL at baseline, 55.7% of them became round type. Up to 123 segments changed from triangular to round type with follow-up (Figure 11).

### OYL Disappearance

OYL disappearance was observed in 22.8% (68 out of 298 segments) of segments. In the subgroup analysis of different

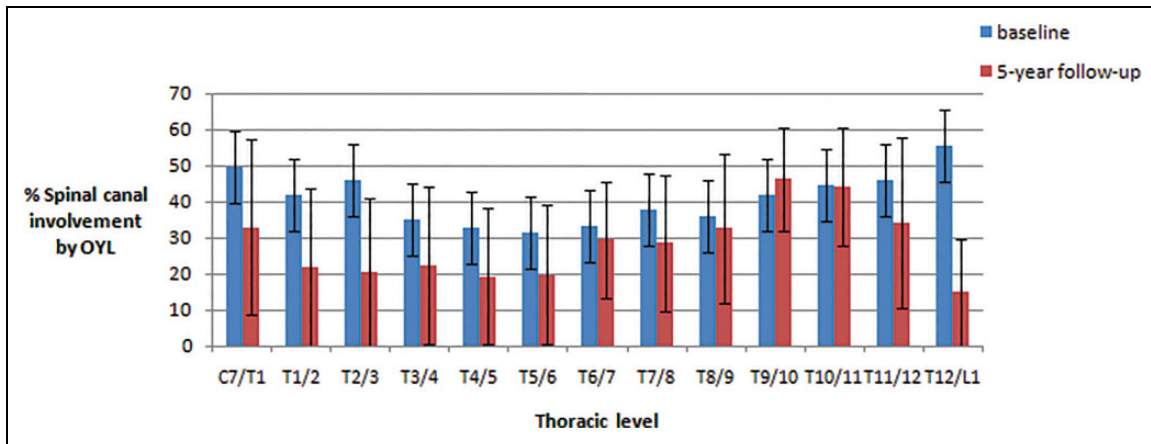
levels, T9-T10 and T10-T11 OYL were least likely to disappear ( $P < .05$ ) (Table 2). Only 3.7% of T9-T10 and 7.6% of T10-T11 OYL disappeared. In patients aged 30 to 40 years, 41.7% of OYL resolved ( $P = .03$ ). Four subjects who had OYL disappearance in 5 years were smokers and they continued to smoke within the study period. Reduced BMI was observed in subjects with OYL disappearance within the 5-year follow-up (initial BMI of 23.7 vs 5-year follow-up BMI of 23.4,  $P < .01$ ). An example of OYL disappearance in 5 years is shown in Figure 12.

### De Novo Appearance

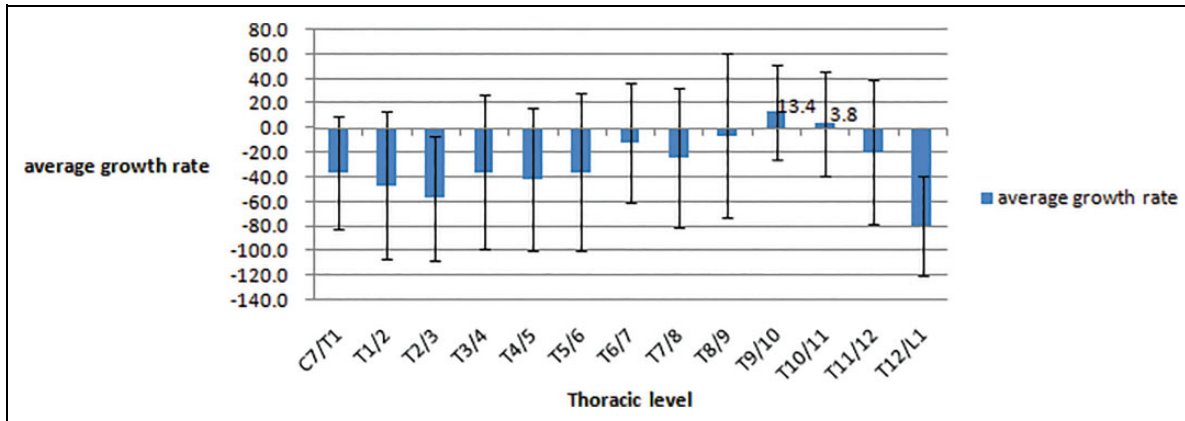
There was de novo OYL formation in 55.6% of spinal segments. The majority occurred in the lower thoracic levels: T8-T9 (11.5%), T9-T10 (11.1%), T10-T11 (10.4%), and T11-T12 (10.1%) (Table 3). De novo formation was associated with higher BMI as 55.8% of the spinal segments with newly formed OYL occurred in obese subjects. By comparison, 52.8% of segments occurred in overweight subjects, 42.7% in subjects with normal BMI and 30.8% in underweight subjects ( $P = .02$ ). A total of 48.1% of those with low back pain and 52.8% of those without low back pain had de novo OYL appearance. Presence of low back pain did not predict the de novo OYL appearance at 5 years ( $P = .37$ ).

### Discussion

This is the first population-based series addressing the natural history of OYL and risk factors for its progression. The strength of the study is in the large number of subjects screened at baseline and with all of them followed up longitudinally for 5 years with repeated scans. Not only does this study identify the prevalence of OYL (6.1%) in a cohort that essentially represents the general southern Chinese population, it also suggests that OYL has variable natural history that may be related to a subject's BMI, smoking status, location, and morphology of OYL. OYL tend to progress in smokers and in the lower thoracic region. Furthermore, morphology changes and new formation occur with time and especially in higher BMI



**Figure 8.** This chart highlights ossified yellow ligament (OYL) size progression in this study comparing percentages of spinal canal involvement according to specific spinal levels between baseline and 5-year follow-up with standard error bars. There is statistically significant OYL size progression at T9/10 and significant OYL size regression at C7/T1.



**Figure 9.** This chart highlights the average growth rate of ossified yellow ligament (OYL) over 5-year follow-up. There were positive growth rates at T9/10 and T10/11. Growth rate was calculated as the percentage change in OYL size divided by the initial OYL size.

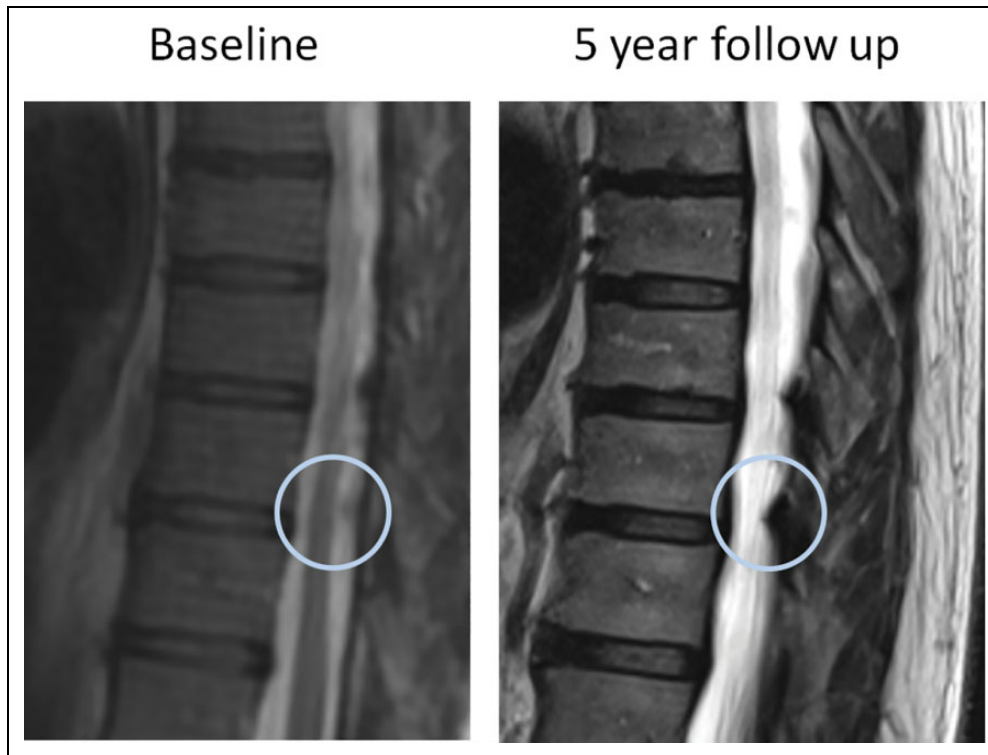
groups. Presence of low back pain has no association with size progression or de novo appearance of OYL.

One of the key messages highlighted by this study is size progression with time. Within 5 years of follow-up, a significant increase in size has been identified, which occurs particularly in the lower thoracic region. This is of concern since it is in the experience of the authors that thoracic myelopathy caused by OYL usually occurs in the same region. This may indicate that clinically relevant OYL disease deteriorates with time with more significant compression.<sup>25</sup> However, this is a theory that is difficult to prove as patients with myelopathy are rarely studied prospectively without intervention. Biomechanics is the likely rationale for predominantly the lower thoracic region to observe size progression. The lower thoracic region is more mobile due to the transition of thoracic to lumbar spine and the less rigid portion of the rib cage with false ribs. Higher tensile forces exist and as a result, the spine is more prone to degeneration. Conversely, the upper thoracic region is relatively stiffer and

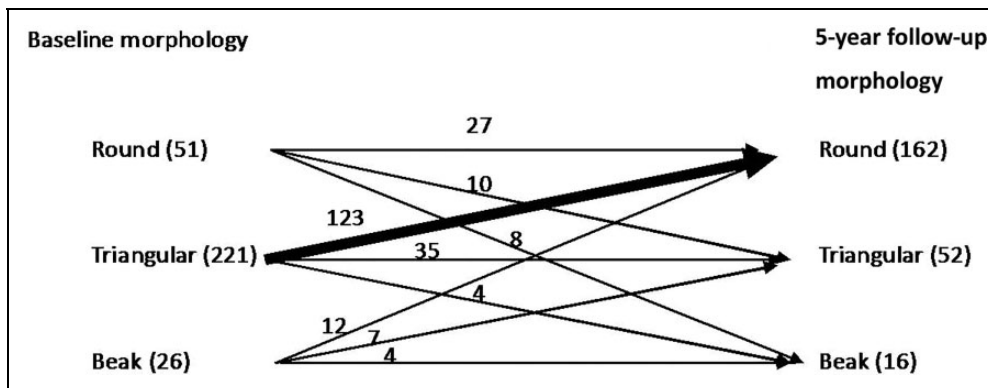
thus regression is more commonly found at this region. OYL forms by this process with deposition of calcium pyrophosphate dehydrate and calcium hydroxyapatite in the ligamentum flavum, which has undergone collagen hyperplasia and hypertrophy.<sup>26</sup> Another risk factor that links OYL with the spine degeneration pathway is smoking.<sup>27</sup> Despite the small number of smokers in our study with OYL, undoubtedly the analysis suggests that smoking may be related to size progression.

Alternatively, most of the OYL with size reduction occurred at the upper thoracic segments. It is interesting to find that some OYL reduces in size at follow-up. This phenomenon may be explained by a similar occurrence reported with OPLL.<sup>28</sup> Non-ossified segments of OPLL may decrease in size after stabilization of the segment. Hence, the size reductions may have occurred due to the comparably stiffer upper thoracic region. This suggests that remodeling occurs with time and may be region specific.

Remodeling may also pertain to morphological changes. A large portion of triangular-type OYL converted into round-type



**Figure 10.** Serial magnetic resonance imaging scans in 5 years showed T9/10 ossified yellow ligament (OYL) size progression.



**Figure 11.** This diagram highlights the ossified yellow ligament (OYL) morphology changes over 5-year follow-up. Majority of OYL were triangular at the baseline, while majority of OYL were round at follow-up. Of note, 123 triangular-type OYL changed to round type at follow-up.

at follow-up. This may have significant clinical implications since it is logical to think that round type may cause a more diffuse compression while triangular or beak type may cause a more focal compression. The “rounding-off” of triangular OYL with time may also have implications on postoperative neurological outcomes. A previous study<sup>29</sup> showed that a beak-type OYL experienced a higher recovery rate and a better satisfaction grade than did those with a round-type OYL after operation. This may be related to the chronicity of compression as a longer period of time has elapsed before beak types become round types. Hence, if subjects present with a round-type OYL, they may have had the compression longer. It is also important

to note that beak-types were quite uncommon in our cohort. We postulate that beak types may be more likely to be symptomatic and thus these subjects are less likely to undergo a 5-year follow-up without requiring intervention.

Another interesting observation was the new formation of OYL with longitudinal follow-up. Ossification of spinal ligaments is a condition characterized by ectopic bone formation in the spinal ligaments such as posterior longitudinal ligament, yellow ligament, and anterolateral spinal ligament. They are caused by complex interaction between genetic and environmental factors as evidenced by the previous studies.<sup>30-33</sup> Results suggest that 55.6% of spinal segments with OYL at

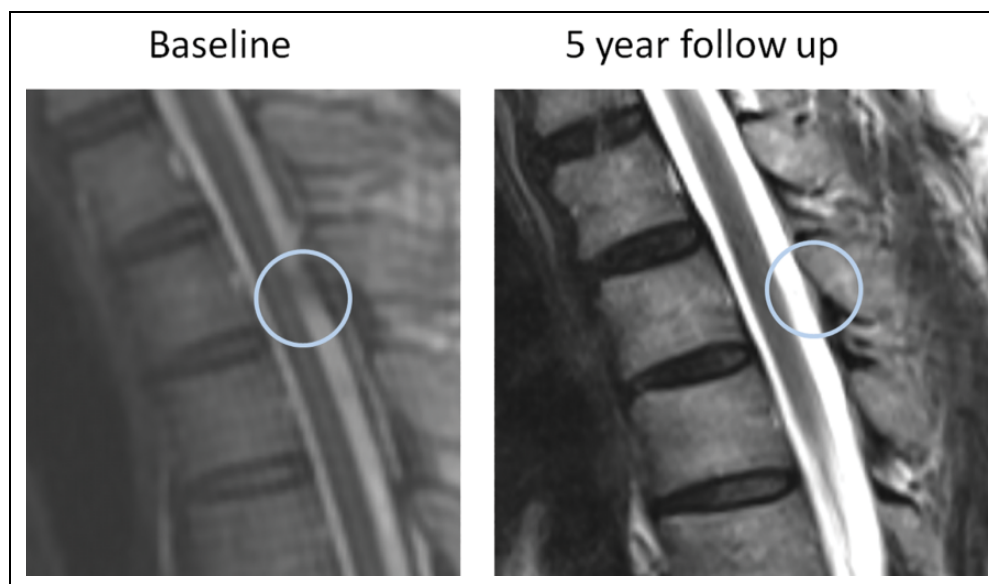
baseline developed new OYL at other levels suggesting that OYL may be more likely to appear once it has developed in a spinal segment. Growth factors including bone morphogenetic proteins (BMPs) and transforming growth factor- $\beta$  (TGF $\beta$ ) may also have important roles in OYL development.<sup>34</sup> BMPs initiate cartilage and bone differentiation and induce new cartilage and bone formation *in vivo*, while TGF $\beta$  stimulates cartilage and bone formation via determined chondrogenitor and osteoprogenitor cells *in vivo*.<sup>35</sup> Diet that involves pickles (salted products) have also been implicated in the development of spinal ligament ossification.<sup>30,36</sup> Thus, OYL may be more prevalent in Chinese and Japanese populations. Patients with OYL also have a higher prevalence of obesity, diabetes mellitus, hyperinsulinism, and impaired glucose tolerance.<sup>32,33</sup> De novo appearance of OYL was found in this study to be more common in patients with higher BMI. This relationship may be related to the higher biomechanical stress

brought on by obesity in addition to the endocrine factors described above. Mechanical stress may increase the tension of ligamentum flavum, such as disc degeneration and vertebral wedging, which contributes to the ossification.<sup>12</sup> Similarly, patients with OYL disappearance appeared to have lost weight with longitudinal follow-up. Nevertheless, this causal relationship, and the effect of diabetes, require further pathomechanistic studies.

One important limitation of this study is the lack of CT scan verification at follow-up. Although these lesions on MRI were verified with CT scan at baseline, we avoided overexposure of radiation with repeated scans at follow-up. However, because of this, we cannot verify whether the new appearances of OYL at follow-up are calcifications or ossifications. Hence, the incidence of new OYL formation may be overestimated.<sup>37</sup> There is also a limitation with the clinical assessment. This longitudinal cohort was based on the Hong Kong Disc Degeneration Population-Based Cohort, which was originally built for lumbar disc degenerative disease. Hence, we only had assessments for presence of back pain rather than focused assessments for myelopathy such as limb spasticity and proprioceptive loss. Some patients may have developed subtle myelopathy but were not systematically identified. Another limitation is the lack of information regarding smoking exposures (pack-years), which made it impossible for dose-response relationship analysis. Nevertheless, it is important to note that this was a prospective longitudinal follow-up study and any findings at follow-up is representative of changes that occurred with time. Another limitation is the lack of size measurements on axial scans which may better represent the severity of canal compromise. Thus, these findings of OYL progression should be validated with other cohorts with axial images available. It is also important to correlate our findings with changes in clinical symptomatology. Finally, the longitudinal follow-up only included subjects

**Table 2.** Level-Specific Rates of Ossified Yellow Ligament (OYL) Disappearance at 5-Year Follow-up.

Spine Level	OYL Disappearance (%)
C7/T1	31
T1/T2	50
T2/T3	55
T3/T4	44
T4/T5	44
T5/T6	45
T6/T7	18
T7/T8	27
T8/T9	24
T9/T10	4
T10/T11	8
T11/T12	30
T12/L1	75



**Figure 12.** Serial magnetic resonance imaging scans in 5 years showed disappearance of T2/3 ossified yellow ligament (OYL).



**Table 3.** Level-Specific Rates of De Novo Ossified Yellow Ligament (OYL) Formation.<sup>a</sup>

Spine Level	De Novo OYL Formation (%)
C7/T1	6.6
T1/2	5.2
T2/3	4.9
T3/4	7.6
T4/5	5.2
T5/6	5.9
T6/7	6.9
T7/8	9.7
T8/9	11.5
T9/10	11.1
T10/11	10.4
T11/12	10.1
T12/L1	4.9

<sup>a</sup>De novo development: number of newly formed OYL at 5-year follow-up magnetic resonance imaging divided by the total number of OYL at the same level.

with OYL at baseline and thus our prevalence may be underestimated. It is possible for previous unaffected individuals develop OYL only at the follow-up.

## Conclusion

This is the first prospective, longitudinal follow-up study of OYL based on a population-based cohort. Study results show that OYL may progress, may regress, and may remodel with variable morphology and appearance. This has significant implications on our understanding of OYL natural history. With predominant progression in the lower thoracic spine, we can deduce that patients with thoracic myelopathy caused by OYL in the lower thoracic levels will likely progress and thus may require more timely surgery. Further study concerning symptomatology and other clinical data is necessary to link these radiological findings with the clinical presentation. In addition, further understanding behind why OYL progresses is necessary, including genetic predisposition and spine biomechanics.


## Declaration of Conflicting Interests

The author(s) declared no potential conflicts of interest with respect to the research, authorship, and/or publication of this article.

## Funding

The author(s) disclosed receipt of the following financial support for the research, authorship, and/or publication of this article: This study was supported by the Hong Kong Theme-Based Research Scheme (T12-708/12N).

## ORCID iD

Chris Yuk Kwan Tang, MBBS, FHKCOS, FHKAM, FRCSEd   
<https://orcid.org/0000-0002-9854-8917>

## References

- Aizawa T, Sato T, Sasaki H, Kusakabe T, Morozumi N, Kokubun S. Thoracic myelopathy caused by ossification of the ligamentum flavum: clinical features and surgical results in the Japanese population. *J Neurosurg Spine*. 2006;5:514-519. doi:10.3171/spi.2006.5.6.514
- Guo JJ, Luk KD, Karppinen J, Yang H, Cheung KM. Prevalence, distribution, and morphology of ossification of the ligamentum flavum: a population study of one thousand seven hundred thirty-six magnetic resonance imaging scans. *Spine (Phila Pa 1976)*. 2010;35:51-56. doi:10.1097/BRS.0b013e3181b3f779
- Sugimura H, Kakitsubata Y, Suzuki Y, et al. MRI of ossification of ligamentum flavum. *J Comput Assist Tomogr*. 1992;16:73-76.
- Xiong L, Zeng QY, Jinkins JR. CT and MRI characteristics of ossification of the ligamenta flava in the thoracic spine. *Eur Radiol*. 2001;11:1798-1802.
- Aizawa T, Sato T, Sasaki H, et al. Results of surgical treatment for thoracic myelopathy: minimum 2-year follow-up study in 132 patients. *J Neurosurg Spine*. 2007;7:13-20. doi:10.3171/spi-07/07/013
- Gao R, Yuan W, Yang L, Shi G, Jia L. Clinical features and surgical outcomes of patients with thoracic myelopathy caused by multilevel ossification of the ligamentum flavum. *Spine J*. 2013;13:1032-1038. doi:10.1016/j.spinee.2013.02.034
- He S, Hussain N, Li S, Hou T. Clinical and prognostic analysis of ossified ligamentum flavum in a Chinese population. *J Neurosurg Spine*. 2005;3:348-354. doi:10.3171/spi.2005.3.5.0348
- Hitchon PW, Abode-Iyamah K, Dahdaleh NS, et al. Risk factors and outcomes in thoracic stenosis with myelopathy: A single center experience. *Clin Neurol Neurosurg*. 2016;147:84-89. doi:10.1016/j.clineuro.2016.05.029
- Epstein NE. The frequency and etiology of intraoperative dural tears in 110 predominantly geriatric patients undergoing multi-level laminectomy with noninstrumented fusions. *J Spinal Disord Tech*. 2007;20:380-386. doi:10.1097/BSD.0b013e31802dabd2
- Muthukumar N. Dural ossification in ossification of the ligamentum flavum: a preliminary report. *Spine (Phila Pa 1976)*. 2009;34:2654-2661.
- Tang CYK, Cheung JPY, Samartzis D, et al. Predictive factors for neurological deterioration after surgical decompression for thoracic ossified yellow ligament. *Eur Spine J*. 2017;26:2598-2605. doi:10.1007/s00586-017-5078-7
- Yoshida M. Pathology of ossification of the ligamentum flavum. In: Yonenobu K, Nakamura K, Toyama Y, eds. *OPLL*. Tokyo, Japan: Springer; 2006:49-57.
- Tanaka Y, Sato T, Aizawa T. Surgery for ossification of the ligamentum flavum. In: Yonenobu K, Nakamura K, Toyama Y, eds. *OPLL*. Tokyo, Japan: Springer; 2006:265-269.
- Matsunaga S, Sakou T. Ossification of the posterior longitudinal ligament of the cervical spine: etiology and natural history. *Spine (Phila Pa 1976)*. 2012;37:E309-E314.
- Cheung KM, Samartzis D, Karppinen J, Luk KD. Are "patterns" of lumbar disc degeneration associated with low back pain? New insights based on skipped level disc pathology. *Spine (Phila Pa 1976)*. 2012;37:E430-E438. doi:10.1097/BRS.0b013e3182304dfc
- Li Y, Samartzis D, Campbell DD, et al. Two subtypes of intervertebral disc degeneration distinguished by large-scale

- population-based study. *Spine J.* 2016;16:1079-1089. doi:10.1016/j.spinee.2016.04.020
17. Maatta JH, Karppinen J, Paananen M, et al. Refined phenotyping of modic changes: imaging biomarkers of prolonged severe low back pain and disability. *Medicine (Baltimore).* 2016;95:e3495. doi:10.1097/md.0000000000003495
  18. Maatta JH, Karppinen JI, Luk KD, Cheung KM, Samartzis D. Phenotype profiling of Modic changes of the lumbar spine and its association with other MRI phenotypes: a large-scale population-based study. *Spine J.* 2015;15:1933-1942. doi:10.1016/j.spinee.2015.06.056
  19. Mok FP, Samartzis D, Karppinen J, Luk KD, Fong DY, Cheung KM. ISSLS prize winner: prevalence, determinants, and association of Schmorl nodes of the lumbar spine with disc degeneration: a population-based study of 2449 individuals. *Spine (Phila Pa 1976).* 2010;35:1944-1952. doi:10.1097/BRS.0b013e3181d534f3
  20. Samartzis D, Karppinen J, Chan D, Luk KD, Cheung KM. The association of lumbar intervertebral disc degeneration on magnetic resonance imaging with body mass index in overweight and obese adults: a population-based study. *Arthritis Rheum.* 2012;64:1488-1496. doi:10.1002/art.33462
  21. Samartzis D, Karppinen J, Mok F, Fong DY, Luk KD, Cheung KM. A population-based study of juvenile disc degeneration and its association with overweight and obesity, low back pain, and diminished functional status. *J Bone Joint Surg Am.* 2011;93:662-670. doi:10.2106/JBJS.I.01568
  22. Pfirrmann CW, Metzendorf A, Zanetti M, Hodler J, Boos N. Magnetic resonance classification of lumbar intervertebral disc degeneration. *Spine (Phila Pa 1976).* 2001;26:1873-1878.
  23. Landis JR, Koch GG. The measurement of observer agreement for categorical data. *Biometrics.* 1997;33:159-174.
  24. Vangeneugden T, Laenen A, Geys H, Renard D, Molenberghs G. Applying concepts of generalizability theory on clinical trial data to investigate sources of variation and their impact on reliability. *Biometrics.* 2005;61:295-304. doi:10.1111/j.0006-341X.2005.031040.x
  25. Nishiura I, Isozumi T, Nishihara K, Handa H, Koyama T. Surgical approach to ossification of the thoracic yellow ligament. *Surg Neurol.* 1999;51:368-372.
  26. Fukuyama S, Nakamura T, Ikeda T, Takagi K. The effect of mechanical stress on hypertrophy of the lumbar ligamentum flavum. *J Spinal Disord.* 1995;8:126-130.
  27. Jackson AR, Dhawale AA, Brown MD. Association between intervertebral disc degeneration and cigarette smoking: clinical and experimental findings. *JBJS Rev.* 2015;3:01874474-201503030-00002. doi:10.2106/JBJS.RVW.N.00057
  28. Koda M, Furuya T, Okawa A, et al. Bone union and remodelling of the non-ossified segment in thoracic ossification of the posterior longitudinal ligament after posterior decompression and fusion surgery. *Eur Spine J.* 2015;24:2555-2559. doi:10.1007/s00586-015-3888-z
  29. Kang KC, Lee CS, Shin SK, Park SJ, Chung CH, Chung SS. Ossification of the ligamentum flavum of the thoracic spine in the Korean population. *J Neurosurg Spine.* 2011;14:513-519. doi:10.3171/2010.11.spine10405
  30. Mobbs RJ, Dvorak M. Ossification of the ligamentum flavum: diet and genetics. *J Clin Neurosci.* 2007;14:703-705. doi:10.1016/j.jocn.2006.01.010
  31. Sakou T, Taketomi E, Matsunaga S, Yamaguchi M, Sonoda S, Yashiki S. Genetic study of ossification of the posterior longitudinal ligament in the cervical spine with human leukocyte antigen haplotype. *Spine (Phila Pa 1976).* 1991;16:1249-1252.
  32. Takeuchi Y, Matsumoto T, Takuwa Y, et al. High incidence of obesity and elevated serum immunoreactive insulin level in patients with paravertebral ligamentous ossification: a relationship to the development of ectopic ossification. *J Bone Miner Metab.* 1989;7:17-21.
  33. Terayama K. Genetic studies on ossification of the posterior longitudinal ligament of the spine. *Spine (Phila Pa 1976).* 1989;14:1184-1191.
  34. Li H, Jiang LS, Dai LY. Hormones and growth factors in the pathogenesis of spinal ligament ossification. *Eur Spine J.* 2007;16:1075-1084. doi:10.1007/s00586-007-0356-4
  35. Hayashi K, Ishidou Y, Yonemori K, et al. Expression and localization of bone morphogenetic proteins (BMPs) and BMP receptors in ossification of the ligamentum flavum. *Bone.* 1997;21:23-30.
  36. Okamoto K, Kobashi G, Washio M, et al. Dietary habits and risk of ossification of the posterior longitudinal ligaments of the spine (OPLL); findings from a case-control study in Japan. *J Bone Miner Metab.* 2004;22:612-617. doi:10.1007/s00774-004-0531-1
  37. Okada G, Hosoi S, Kato K, et al. Case report 779. Carbonate apatite calcification of ligamentum flavum. *Skeletal Radiol.* 1993;22:211-213.