

Anteroposterior length of the maxillary complex and its relationship with the anterior cranial base:

A study on human dry skulls using cone beam computed tomography

Fabio Savoldi^a; Francesca Massetti^a; James K. H. Tsoi^b; Jukka P. Matinlinna^c; Andy W. K. Yeung^d; Ray Tanaka^e; Corrado Paganelli^f; Michael M. Bornstein^g

ABSTRACT

Objectives: To use both absolute anteroposterior maxillary complex length (APMCL) and relative APMCL to investigate the relationship between the maxillary complex, its individual bony segments, and their association to the anterior cranial base. In addition, the relationship between length and position of the maxillary complex was analyzed.

Materials and Methods: Sixty human skulls were analyzed using cone beam computed tomography. The maxillary complex length was measured between anterior and posterior nasal spine (*ans-pns*), and the average was used as the cut-off to identify a high- and a low-length group based on absolute APMCL. The length ratio between the maxillary complex and the anterior cranial base (*ans-pns/SN*) was used to identify the two groups based on relative APMCL. The anterior cranial base length and the lengths of the maxillary complex bones were compared between the high- and low-length groups.

Results: Based on absolute APMCL, individuals with shorter maxillary complex had shorter anterior cranial base ($P = .003$), representing normal proportions. Based on relative APMCL, individuals with shorter maxillary complex had longer anterior cranial base and vice versa ($P = .014$), indicating disproportions. Individuals with shorter maxillary complex exhibited shorter maxilla ($\Delta = -1.5$ mm, $P = .014$).

Conclusions: When skeletal deformity of the midface is suspected, individual disproportions in the anteroposterior length of the maxillary complex in relation to the anterior cranial base (relative measurements) should be assessed through radiological imaging. A shorter maxillary complex may be associated with a shorter maxilla, and not with a shorter premaxilla or palatine bone. (*Angle Orthod.* 2021;91:88–97.)

KEY WORDS: Hypomaxillia; Retromaxillia; Midface hypoplasia; Sutures; Cone beam computed tomography; Cranial base

^a Postgraduate Student, Orthodontics, Dental School, Department of Medical and Surgical Specialties, Radiological Sciences and Public Health, University of Brescia, Brescia, Italy.

^b Assistant Professor, Dental Materials Science, Division of Applied Oral Sciences & Community Dental Care, Faculty of Dentistry, The University of Hong Kong, Prince Philip Dental Hospital, Hong Kong S.A.R.

^c Professor, Dental Materials Science, Division of Applied Oral Sciences & Community Dental Care, Faculty of Dentistry, The University of Hong Kong, Prince Philip Dental Hospital, Hong Kong S.A.R.

^d Tutor, Oral and Maxillofacial Radiology, Division of Applied Oral Sciences & Community Dental Care, Faculty of Dentistry, The University of Hong Kong, Prince Philip Dental Hospital, Hong Kong S.A.R.

^e Clinical Assistant Professor, Oral and Maxillofacial Radiology, Division of Applied Oral Sciences & Community Dental Care, Faculty of Dentistry, The University of Hong Kong, Prince Philip Dental Hospital, Hong Kong S.A.R.

^f Professor and Dean, Orthodontics, Dental School, Department of Medical and Surgical Specialties, Radiological Sciences and Public Health, University of Brescia, Brescia, Italy.

^g Honorary Professor, Oral and Maxillofacial Radiology, Division of Applied Oral Sciences & Community Dental Care, Faculty of Dentistry, The University of Hong Kong, Prince Philip Dental Hospital, Hong Kong S.A.R.; and Department of Oral Health & Medicine, University Center of Dental Medicine Basel UZB, University of Basel, Basel, Switzerland.

Corresponding author: Dr Fabio Savoldi, Orthodontics, Dental School, Department of Medical and Surgical Specialties, Radiological Sciences and Public Health University of Brescia, Piazzale Spedali Civili 1, 25123, Brescia, Italy. (e-mail: fabiosavoldi@live.com)

Accepted: July 2020. Submitted: February 2020.

Published Online: October 12, 2020

© 2021 by The EH Angle Education and Research Foundation, Inc.

INTRODUCTION

The human maxillary complex is composed of two premaxillary bones, two maxillary bones, and two palatine bones.¹⁻³ During intrauterine life, their growth proceeds independently via intramembranous formation,¹ but postnatal growth consists of subperiosteal remodelling and sutural apposition.⁴ In particular, sutural growth has variable timing and the maxillopalatal suture tends to ossify later⁵ compared to the premaxillomaxillary suture,^{1,2,6} which identifies the premaxilla. Nevertheless, the first occurrence of complete obliteration of both structures may not happen earlier than the third decade of life.⁷

The bones composing the maxillary complex may be affected by genetic⁸ or environmental⁹ factors leading to reduced size, ie, maxillary hypoplasia,¹⁰ or retruded position, ie, maxillary retrusion.¹¹ A reduced antero-posterior maxillary complex length (APMCL) may be associated with oral function limitations,¹² and the oral cavity size reduction may lead to relative macroglossia and upper airway obstruction.¹³

The definition of APMCL is debatable and both the maxillary complex length,¹⁴ ie, absolute APMCL, and its length ratio relative to the anterior cranial base,¹⁵ ie, relative APMCL, have been proposed for its radiological assessment. Although length measurements can indicate the net growth amount,^{8,14} relative measurements offer a better understanding of regional growth proportions.^{15,16} In addition, little is known about the relationship between APMCL and dimensional variations of the bones constituting the maxillary complex (premaxilla, maxilla, and palatine bone). Although some authors suggested that the APMCL was associated with the anteroposterior position of the maxillary complex,¹² others reported that maxillary size did not influence its prognathism.¹⁷

The aim of the present study was to use absolute and relative APMCL to compare the size of the maxillary complex, its individual bony segments, and the anterior cranial base in subjects with long vs short maxillary complex. In addition, the position of the maxillary complex was compared between the two groups.

MATERIALS AND METHODS

Sample Selection

A total of 256 human dry skulls of Chinese ethnicity from the Faculty of Dentistry of the University of Hong Kong were analyzed and those with documented sex and age >20 years were included. Skulls with fractures, missing parts, or severe deformities (cleft palate or hemifacial microsomia), were excluded. The protocol was approved by the Institutional Review

Board (UW-18112), and the study was registered in the HKU Clinical Trials Registry (HKUCTR-2383).

Image Analysis

Cone beam computed tomography scans (CBCTs) were acquired (ProMax 3D Mid, Planmeca, Helsinki, Finland) with field of view of 20 × 17 cm, exposure of 36 s, 19 mGy, 90 kV, 14 mA, and voxel size of 200 μm. Images were analyzed using a computer software (Planmeca Romexis 5.0, Planmeca) with slice thickness of 200 μm. Skulls were oriented starting from the axial view and positioning the coronal slice passing through the maxillopalatal suture, and the parasagittal slice aligned to *ans-pns*. In the coronal view, the para-axial slice was aligned with the hard palate. In the sagittal view, the para-axial slice was aligned to *ans-pns* (Figure 1, Appendix Table 1).

Group Allocation

On the parasagittal slice, the anterior cranial base length (*SN*, mm) and the maxillary complex length (*ans-pns*, mm) were measured (Figure 1). The length ratio of the maxillary complex relative to the anterior cranial base was measured (*ans-pns/SN*). Based on absolute APMCL, the mean *ans-pns* value among the whole sample was used as the cut-off for identifying a low- and a high-length group. Based on relative APMCL, the mean *ans-pns/SN* value was used, instead, to identify the two groups.

Sample Size Calculation

The sample size was calculated based on a collective decision between absolute and relative APMCL. Ten skulls not included in the final study were included in a pilot study, showing a standard deviation (SD) of 5.7 mm for *ans-pns* and 6% for *ans-pns/SN*, which were the primary parameters for each criterion, respectively. Setting a clinically significant difference of 5.0 mm^{11,17-20} and 5%^{15,18} between the two groups, respectively, a significance level $\alpha = 0.05$, and a power $\beta = 90\%$, the required sample size was 30 skulls for each group.

Experimental Variables

On the para-axial slice, the length of the premaxilla (*PM*, mm), maxilla (*MA*, mm), and palatine bone (*PA*, mm) were measured to quantify the contribution of each segment to the maxillary complex length (Figure 1, Appendix Table 1). Their length ratios relative to the maxillary complex were calculated and expressed in percentage ($PM\% = PM/ans-pns$, $MA\% = MA/ans-pns$, and $PA\% = PA/ans-pns$).

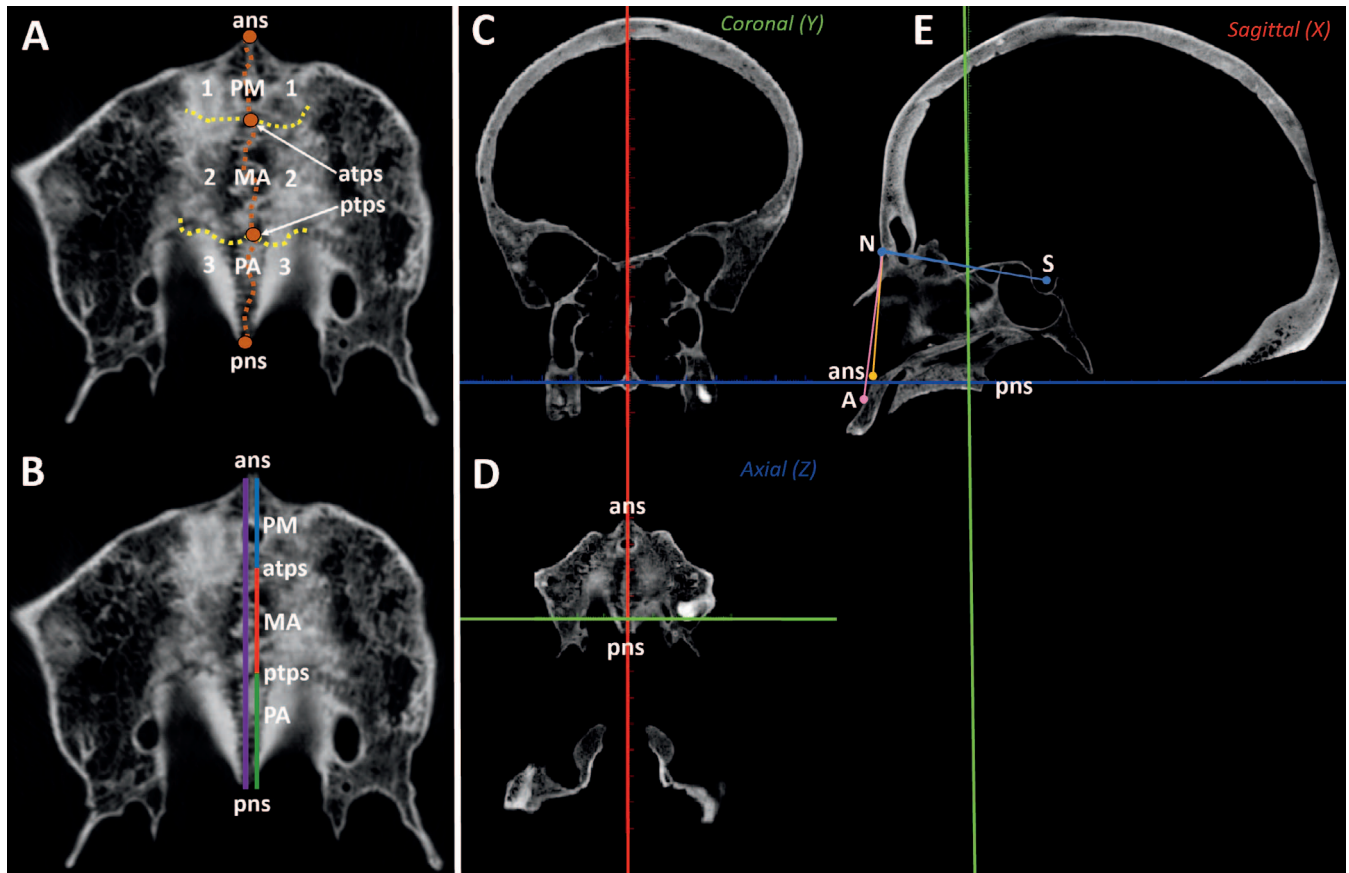


Figure 1. Premaxilla (1), maxilla (2), palatine bones (3), midpalatal suture (brown), anterior and posterior transverse palatal sutures (yellow), intersection of the midpalatal suture with anterior (atps) and posterior (ptps) transverse palatal sutures (A). Premaxillary (PM, blue), maxillary (MA, red), and palatine segment (PA, green), forming the total maxillary complex length (*ans-pns*, violet) (B). Orientation in the coronal view according to the hard palate (C), in the axial view according to *ans-pns* (D), and in the sagittal view according to *ans-pns* (E). Sella (S), nasion (N), anterior nasal spine (*ans*), posterior nasal spine (*pns*), subspinal point (A).

On the parasagittal slice, the maxillary complex alveolar protrusion (*SNA*, °) and the maxillary complex basal protrusion (*SNans*, °) were measured to quantify its anteroposterior position (Figure 1, Appendix Table 1).

Data Analysis

Measurements were taken by a primary (FM) and a secondary assessor (FS), after calibration on five skulls. The primary assessor repeated all measurements after a washout period of one month, and the mean between the repeated measurements was used for data analysis. The secondary assessor repeated 50% of the measurements. The intraclass correlation coefficient (ICC) was used to calculate intra and inter-assessor agreement (“*poor*” if <0.5 , “*fair*” from 0.5 to 0.7, “*good*” from 0.7 to 0.8, “*excellent*” if >0.8).²¹ The method error was estimated with Dahlberg’s formula.²²

Normality of data distribution was assessed with Shapiro-Wilk test. Two independent analyses were carried out based either on maxillary complex length (*ans-pns*, absolute APMCL), or on the length ratio of

the maxillary complex relative to the anterior cranial base (*ans-pns/SN*, relative APMCL). Student’s *t*-tests were used to assess differences between high- and low-length groups. Two linear regression models were developed: one with *ans-pns* and one with *ans-pns/SN* as outcome variables, to assess their correlation with the length of each segment of the maxillary complex, with the length ratio of each segment relative to the maxillary complex, and with the maxillary complex position.

Data analysis was performed using SPSS (V23.0, IBM, Armonk, New York) with a significance level $\alpha = .05$.

RESULTS

Sample

Among 246 skulls available, 90 fulfilled the inclusion criteria, 18 were further excluded because sutures were not clearly visible on CBCT, and 60 were randomly selected. By using either absolute APMCL or relative

Table 1. Descriptive Statistics of the Measurements of the Low-Length Group, of the High-Length Group, of the Difference Between the Two Groups (Δ), and of the Total Sample. Grouping Was Based on Absolute APMCL, ie, the Length of the Maxillary Complex (*ans-pns*)^{a,b}

	SN, mm (%) ^b	ans-pns, mm (%) ^b	ans-pns/SN, %	PM, mm (%) ^b	MA, mm (%) ^b	PA, mm (%) ^b	SNA, °	SNans, °
Low-length								
Mean	62.5 (141)	44.5 (100)	71	14.9 (34)	17.2 (39)	11.1 (25)	82.3	83.6
SD	2.7 (10)	2.3 (0)	5	2.6 (6)	2.3 (5)	2.4 (5)	4.1	4.2
CI (lower)	61.6 (137)	43.7 (100)	70	14.0 (31)	16.4 (37)	10.2 (23)	80.8	82.1
CI (upper)	63.5 (144)	45.3 (100)	73	15.9 (36)	18.0 (41)	11.9 (27)	83.7	85.1
Min	56.7 (123)	35.9 (100)	55	11.2 (25)	10.5 (24)	4.7 (13)	73.7	76.9
Max	70.5 (180)	46.8 (100)	82	19.9 (45)	21.4 (51)	16.2 (35)	89.8	92.6
High-length								
Mean	64.7 (131)	49.5 (100)	77	16.5 (33)	18.0 (36)	12.8 (26)	84.4	86.2
SD	2.6 (8)	2.4 (0)	5	2.7 (6)	2.5 (5)	2.1 (4)	4.4	3.9
CI (lower)	63.8 (128)	48.7 (100)	75	15.5 (31)	17.1 (35)	12.1 (24)	82.8	84.8
CI (upper)	65.6 (134)	50.4 (100)	78	17.5 (35)	18.9 (38)	13.6 (27)	86.0	87.6
Min	60.4 (116)	46.8 (100)	65	12.2 (25)	13.1 (27)	9.2 (19)	78.2	80.4
Max	72.2 (155)	54.7 (100)	86	22.8 (48)	22.8 (46)	16.2 (33)	93.6	96.3
All								
Mean	63.6 (136)	47.0 (100)	74	15.7 (33)	17.6 (38)	12.0 (25)	83.3	84.9
SD	2.9 (10)	3.4 (0)	5	2.8 (6)	2.4 (5)	2.4 (5)	4.3	4.2
CI (lower)	62.9 (133)	46.2 (100)	73	15.0 (32)	17.0 (36)	11.4 (24)	82.2	83.8
CI (upper)	64.3 (139)	47.9 (100)	75	16.4 (35)	18.2 (39)	12.6 (27)	84.4	86.0
Min	56.7 (116)	35.9 (100)	55	11.2 (25)	10.5 (24)	4.7 (13)	73.7	76.9
Max	72.2 (180)	54.7 (100)	86	22.8 (48)	22.8 (51)	16.2 (35)	93.6	96.3
Δ								
Mean	-2.1 (10)	-5.0 (0)	-6	-1.6 (0)	-0.8 (2)	-1.7 (-1)	-2.1	-2.5
SD	4.3 (12)	1.8 (0)	6	4.1 (9)	3.7 (8)	3.1 (7)	6.0	5.7
CI (lower)	-3.7 (6)	-5.6 (0)	-8	-3.0 (-3)	-2.1 (-1)	-2.8 (-3)	-4.3	-4.6
CI (upper)	-0.6 (14)	-4.4 (0)	-4	-0.1 (3)	0.5 (5)	-0.6 (1)	0.0	-0.5
Min	-11.1 (-18)	-10.6 (0)	-20	-9.5 (-17)	-9.3 (-19)	-7.6 (-14)	-13.1	-10.8
Max	7.0 (44)	-2.1 (0)	5	5.7 (16)	4.4 (16)	4.7 (13)	8.1	9.6
P value*	.003 (<.001)	<.001 (1.000)	<.001	.026 (.879)	.197 (.077)	.004 (.318)	.057	.019

* Two-samples *t*-test comparing low- and high-length group; significant *P* values are in bold.

^a SD indicates standard deviation; CI, 95% confidence interval.

^b Calculated using the ratio with *ans-pns*.

APMCL, half were assigned to the low-length group and the other half to the high-length group.

The sample consisted of 49 males and 11 females, ranging from 20 and 86 years (mean 61.0 ± 14.9 years). Most subjects were dentate (73%), few had complete dentition (21%), and medical conditions were unknown.

Method Error and Reliability

The method error was ≤ 0.6 mm for linear measurements and $\leq 1.1^\circ$ for angular measurements. The intra-assessor agreement was excellent for all measurements (0.93 to 0.98). The inter-assessor agreement ranged from good to excellent (0.70 to 0.93) for all variables apart from the premaxillary (0.54) and maxillary (0.53) segment length, for which it was fair.

Grouping Based on Absolute Measurements

By grouping based on absolute APMCL, the length of the anterior cranial base ($\Delta = -2.1 \pm 4.3$ mm, $P = .003$) and of the maxillary complex ($\Delta = -5.0 \pm 1.8$ mm, $P < .001$) were both shorter in the low-length

group. The length of the premaxilla ($\Delta = -1.6 \pm 4.1$ mm, $P = .026$), palatine bone ($\Delta = -1.7 \pm 3.1$ mm, $P = .004$), and maxilla ($\Delta = -0.8 \pm 3.7$ mm, $P = .197$) were also shorter in the low-length group, although the maxilla did not show a significant difference. Nevertheless, no significant differences were present when the length ratio of each segment relative to the maxillary complex was considered, showing that the proportions of the segments were similar between groups (Table 1, Figures 2 and 3). The maxillary complex basal protrusion was smaller in the low-length group ($\Delta = -2.5 \pm 5.7$, $P = .019$), but the alveolar protrusion was similar (Table 1).

The maxillary complex length was correlated to both the length of each segment and to the length ratio of each segment relative to the maxillary complex ($\beta = 0.449$ to 1.125 , $P \leq .003$). No correlation was found between the maxillary complex length and its protrusion (Table 2).

Grouping Based on Relative Measurements

By grouping based on relative APMCL, the low-length group showed a shorter maxillary complex ($\Delta =$

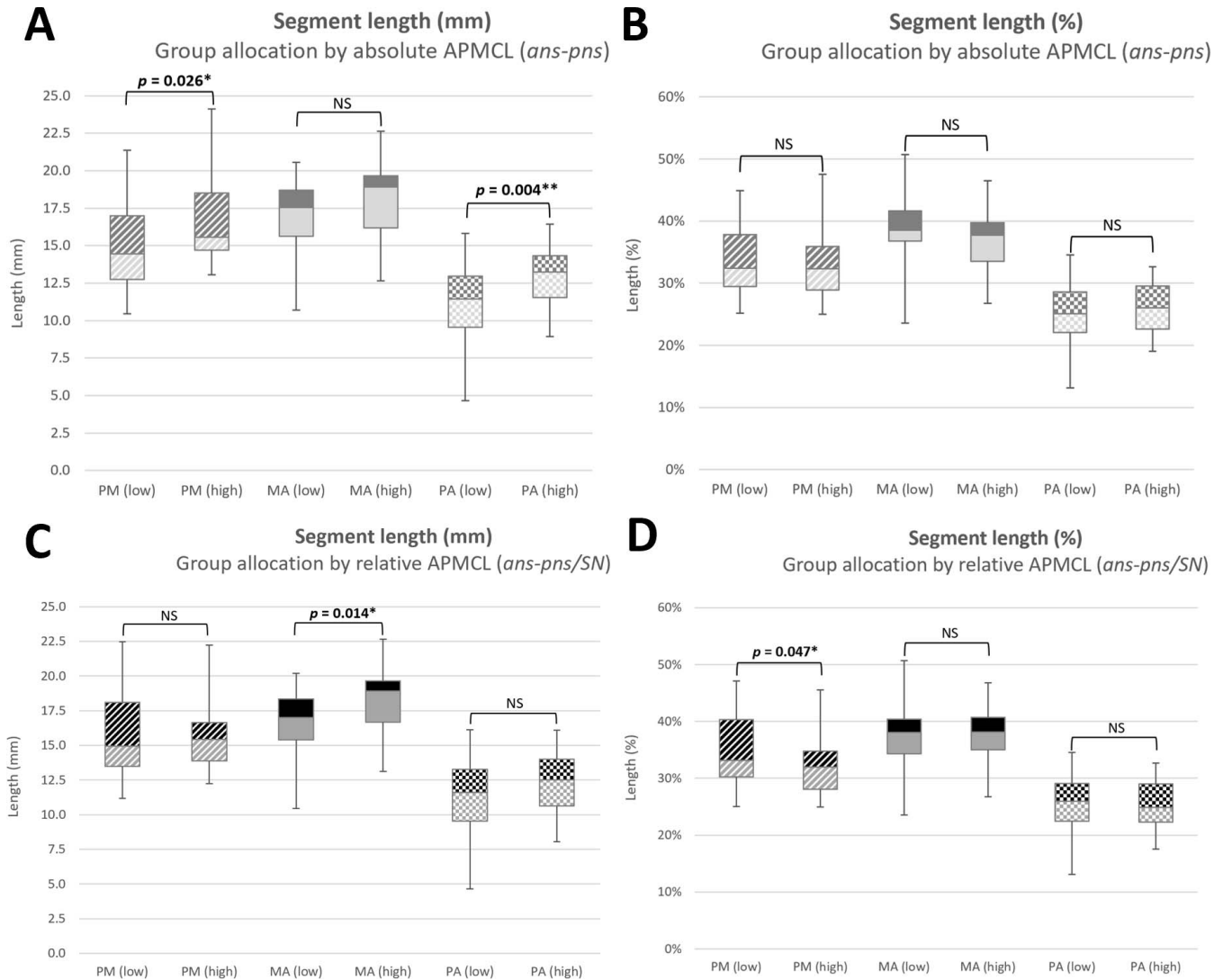


Figure 2. Comparison of the length of premaxilla (PM), maxilla (MA), and palatine bone (PA) between low- and high-length groups. Grouping based on absolute maxillary complex length (*ans-pns*) (A, B) and maxillary complex length ratio relative to the anterior cranial base (*ans-pns/SN*) (C, D). Length values (A, C) and length ratio relative to the maxillary complex (B, D) are indicated. NS: $P > .05$.

-3.8 ± 3.1 mm, $P < .001$) and a longer anterior cranial base ($\Delta = 1.8 \pm 3.3$ mm, $P = .014$). In particular, the maxilla was shorter ($\Delta = -1.5 \pm 3.3$ mm, $P = .014$), but the length of the premaxilla and the palatine bone were similar in both groups. However, when the length ratios of each segment relative to the maxillary complex were measured, the premaxilla was longer in the low-length group ($\Delta = 3 \pm 9\%$, $P = .047$) (Table 3, Figures 2 and 3). The maxillary complex alveolar protrusion ($\Delta = -3.7 \pm 5.5^\circ$, $P = .001$) and basal protrusion ($\Delta = -3.6 \pm 5.5^\circ$, $P = .001$) were smaller in the low-length group (Table 3).

The regression model showed that the length ratio of the maxillary complex relative to the anterior cranial base was positively correlated to the maxillary length ($\beta = 1.968$, $P < .001$) but negatively correlated to the relative length of the premaxilla compared to the

maxillary complex ($\beta = -2.118$, $P < .001$). No correlation was found between the maxillary complex length and its protrusion (Table 2).

DISCUSSION

Maxillary Anteroposterior Length

Anteroposterior maxillary complex hypoplasia is particularly relevant in patients with skeletal Class III,¹² Down syndrome,⁸ and obstructive sleep apnea,²⁰ and cephalometry is used for both skeletal diagnosis and upper airway assessment.²³ However, the criteria to identify this condition are not well defined, and both the maxillary complex length^{8,14,20} and its ratio relative to the anterior cranial base^{15,18} have been used. In fact, absolute measurements showed that subjects with a

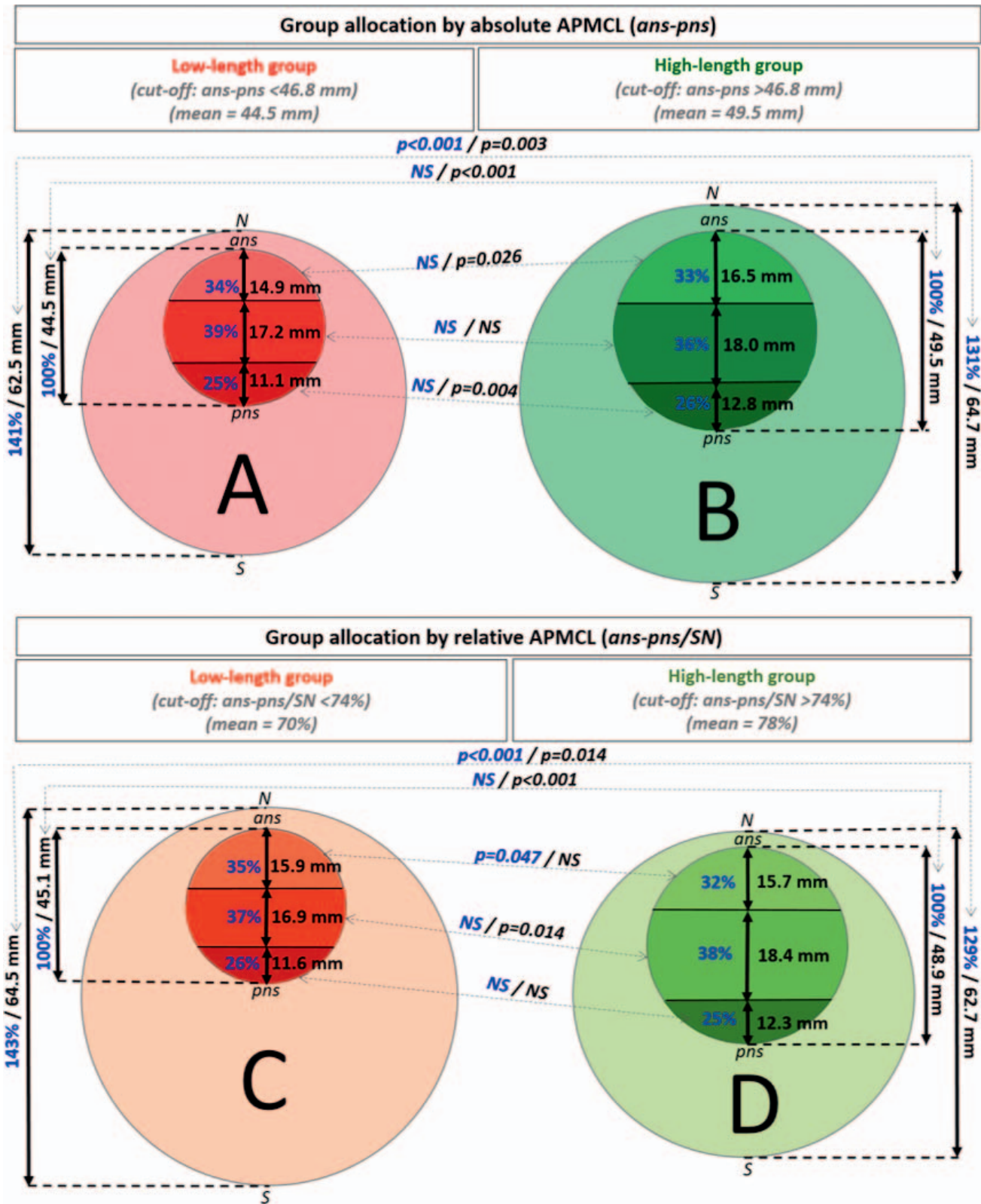


Figure 3. Anterior cranial base length (SN, outer circle) and maxillary complex length (*ans-pns*, inner circle). Premaxilla (PM), maxilla (MA), and palatine bone (PA) are represented as inner circle sub-divisions. Each item size exemplifies the real proportion with the other parts. Grouping based on maxillary complex absolute length (*ans-pns*) (A, B) and maxillary complex length ratio relative to the anterior cranial base (*ans-pns/SN*) (C, D). Low- (A, C) and high-length groups (B, D) are represented. Data related to relative measurements (blue) and absolute measurements (black) are reported. NS: $P > .05$.

Table 2. Linear Regression Models, One With Outcome Variable the Absolute Anteroposterior Length of the Maxillary Complex (*ans-pns*) (Upper), and the Other With the Relative Anteroposterior Length of the Maxillary Complex With Respect to the Anterior Cranial Base (*ans-pns/SN*) (Lower)^{a,b}

Outcome	Model Statistics		Predictors	
	R ²	ANOVA P Value	β	P Value
<i>ans-pns</i> Predictors				
SN	0.992	<.001	-0.007	.671
PM			0.449	.003
MA			0.779	<.001
PA			1.125	<.001
MA%			-0.511	<.001
PM%			-0.844	<.001
PA%			-1.048	<.001
SNA			0.039	.354
SNans			-0.037	.370
<i>ans-pns/SN</i> Predictors				
PM	0.774	<.001	-0.549	.445
MA			1.968	<.001
PA			-0.310	.640
MA%			0.363	.599
PM%			-2.118	<.001
PA%			0.102	.863
SNA			0.366	.083
SNans			-0.210	.318

^a β indicates standardized coefficient beta; R², coefficient of determination.

^b Significant P values are in bold.

shorter anterior cranial base had a shorter maxillary complex (Figure 3), and the length of the maxillary complex was correlated to the length of each bone of which it was constituted, suggesting limitations of absolute parameters for the identification of disproportions (Table 2). In addition, despite that a shorter maxillary complex presented shorter premaxillary bones and palatine bones, no difference was present in the percentages in which each of these contributed to its total length, confirming that the proportions among the parts were maintained (Figure 3).

It is worth noting that the discrimination between “absolute” and “relative” measurements has been applied to other medical conditions such as “*macro-glossia*,” in which diagnosis may be based either on the tongue absolute size, or on its ratio relative to the oral cavity.¹³ In agreement with the present findings, the same study concluded that the relative criterion should be preferred.¹³

When relative APMCL was adopted, the low-length group had a significantly longer cranial base, suggesting that disproportions were identified (Figure 3). Accordingly, relative measurements through counterpart analysis can show treatment-induced remodeling compensations of the craniofacial skeleton that may be missed using conventional cephalometrics.¹⁶

In the present study, the maxillary complex length was measured relative to the anterior cranial base,

since the growth of this structure is related to the growth of the midface,²⁴ and it is also counterpart of the nasomaxillary complex.²⁵ In particular, despite having a longer cranial base, the short maxillary complex group had significantly shorter maxillary bones. Hence, a reduced length of the maxilla, and not the premaxilla or palatine bones, was associated with a relatively shorter maxillary complex. Conversely, the length ratio of the premaxilla relative to the maxillary complex in the short-length group (35%) was higher than in the long-length group (32%). Interestingly, the premaxillary length in the low-length group (15.9 ± 3.1 mm), which was expected to be shorter, resulted to be as long as in the high-length group (15.7 ± 2.5 mm) (Figure 3). Accordingly, the regression model based on relative APMCL showed a positive correlation with the maxillary length ($\beta = 1.968$), confirming the maxilla to be associated with a shortening of the maxillary complex. On the contrary, a negative correlation was present with the length ratio of the premaxilla ($\beta = -2.118$) (Table 2). The premaxilla may have implications in the onset of midfacial deformities,² and such greater premaxillary length ratio could be resulting either from an active compensatory sutural growth stimulated by homeostatic forces acting on the septopremaxillary ligament,³ or from a passive mechanism involving reduction of the subperiosteal resorption on the anterior premaxillary surface,²⁶ both aiming at counterbalancing the deficient maxillary growth to maintain adequate proportions.²⁴

With regard to norms to identify relative maxillary hypoplasia, previous authors reported a normal maxillary complex to anterior cranial base ratio of $65 \pm 3\%$.¹⁸ However, that sample consisted of Caucasian children and may not be comparable to the present results as the anterior cranial base is shorter in Asians compared to Caucasians.²⁷ Furthermore, other authors reported no differences in the maxillary complex to anterior cranial base ratio between Class III subjects ($127.8 \pm 4.1\%$) and controls ($130.5 \pm 4.5\%$).¹⁵ However, the cited study adopted the distance between condylion and anterior nasal spine, which is not the actual length of the maxillary complex. That said, the present study did not aim at providing norms for maxillary hypoplasia, since the sample did not represent a random selection from the general population as it was evident from the higher proportion of males. Furthermore, even if such a norm were identified, its diagnostic value and range of normality would be widely debatable due to age, sex, and race variations.²⁸ Still, given the variety of methods proposed in the literature,^{11,14,15,17–20} a critical analysis of the criteria to assess the maxillary complex anatomy is a requisite for achieving consistent diagnosis of its deformities.

Table 3. Descriptive Statistics of the Measurements of the Low-Length Group, of the High-Length Group, of the Difference Between the Two Groups (Δ), and of the Total Sample. Grouping Was Based on Relative APMCL, ie, the Length Ratio of the Maxillary Complex Relative to the Anterior Cranial Base (*ans-pns/SN*)

	SN, mm (%) ^b	ans-pns, mm (%) ^b	ans-pns/SN, %	PM, mm (%) ^b	MA, mm (%) ^b	PA, mm (%) ^b	SNA, °	SNans, °
Low-length								
Mean	64.5 (143)	45.1 (100)	70	15.9 (35)	16.9 (37)	11.6 (26)	81.5	83.1
SD	3.2 (9)	2.9 (0)	4	3.1 (7)	2.2 (5)	2.6 (5)	3.3	3.3
CI (lower)	63.4 (140)	44.1 (100)	69	14.7 (33)	16.1 (36)	10.7 (24)	80.3	81.9
CI (upper)	65.6 (146)	46.2 (100)	71	17.0 (37)	17.7 (39)	12.5 (27)	82.7	84.3
Min	59.3 (135)	35.9 (100)	55	11.2 (25)	10.5 (24)	4.7 (13)	73.7	76.9
Max	72.2 (180)	50.2 (100)	74	22.8 (47)	20.3 (51)	16.2 (35)	89.8	92.6
High-length								
Mean	62.7 (129)	48.9 (100)	78	15.7 (32)	18.4 (38)	12.3 (25)	85.2	86.7
SD	2.2 (6)	2.8 (0)	4	2.5 (5)	2.4 (5)	2.1 (4)	4.5	4.4
CI (lower)	61.9 (126)	47.9 (100)	77	14.8 (30)	17.5 (36)	11.6 (24)	83.5	85.2
CI (upper)	63.5 (131)	49.9 (100)	79	16.5 (34)	19.2 (39)	13.1 (27)	86.8	88.3
Min	56.7 (116)	44.5 (100)	74	12.2 (25)	13.1 (27)	8.1 (18)	76.5	77.4
Max	66.4 (136)	54.7 (100)	86	22.3 (46)	22.8 (47)	16.2 (33)	93.6	96.3
All								
Mean	63.6 (136)	47.0 (100)	74	15.8 (34)	17.6 (38)	12.0 (25)	83.3	84.9
SD	2.9 (10)	3.4 (0)	5	2.8 (6)	2.4 (5)	2.4 (5)	4.3	4.2
CI (lower)	62.9 (133)	46.2 (100)	73	15.0 (32)	17.0 (36)	11.4 (24)	82.2	83.8
CI (upper)	64.3 (139)	47.9 (100)	75	16.5 (35)	18.2 (39)	12.6 (27)	84.4	86.0
Min	56.7 (116)	35.9 (100)	55	11.2 (25)	10.5 (24)	4.7 (13)	73.7	76.9
Max	72.2 (180)	54.7 (100)	86	22.8 (47)	22.8 (51)	16.2 (35)	93.6	96.3
Δ								
Mean	1.8 (15)	-3.8 (0)	-8	0.2 (3)	-1.5 (0)	-0.7 (0)	-3.7	-3.6
SD	3.3 (6)	3.1 (0)	3	4.4 (9)	3.3 (8)	2.9 (6)	5.5	5.5
CI (lower)	0.6 (13)	-4.9 (0)	-9	-1.4 (0)	-2.7 (-3)	-1.7 (-2)	-5.6	-5.6
CI (upper)	3.0 (17)	-2.6 (0)	-7	1.8 (6)	-0.3 (3)	0.3 (2)	-1.7	-1.6
Min	-4.3 (7)	-10.8 (0)	-18	-8.3 (-15)	-8.8 (-14)	-6.9 (-13)	-15.4	-14.5
Max	8.7 (44)	2.1 (0)	-4	10.6 (21)	6.0 (16)	5.6 (11)	6.2	6.8
P value*	.014 (<.001)	<.001 (1.000)	<.001	.790 (.047)	.014 (.902)	.249 (.825)	.001	.001

* Two-samples *t*-test comparing low- and high-length group; significant *P* values are in bold.

^a SD indicates standard deviation; CI, 95% confidence interval.

^b Calculated using the ratio with *ans-pns*.

Maxillary Anteroposterior Position

The literature refers to “maxillary retrusion” as a condition in which the maxillary complex is normal in size but repositioned with respect to the anterior cranial base.²⁹ This condition has clinical relevance since, for example, it has been associated with obstructive sleep apnea in adults.³⁰ Even though maxillary “retrusion” and “hypoplasia” have been sometimes used interchangeably, the present results showed the presence of an association (Tables 1 and 3) but not a correlation (Table 2) between the anteroposterior maxillary complex length and its protrusion. Furthermore, although the basal protrusion was smaller in the low-length group, both by using absolute APMCL ($\Delta = -2.5 \pm 5.7$) and relative APMCL ($\Delta = -3.6 \pm 5.5^\circ$), the findings related to the alveolar protrusion were less consistent (Table 1). Previous authors reported that the size of the maxilla may not influence its prognathism,¹⁷ and it is suggested to differentiate retrusion from hypoplasia. The present study did not aim at providing norms for maxillary

retrusion, as the prevalence of skeletal Class III in Chinese is about 13%,³¹ and only a subgroup of the present sample may belong to that category. In addition, the diagnosis of midface deformities is based on a comprehensive assessment of the relationship among skeletal components, which include the whole cranial base, maxillary complex, and mandible.^{8,11,15}

Limitations

Although human dry skulls offer the advantage to acquire high resolution CBCTs thanks to the absence of soft tissues and no risk of radiation exposure, the premaxillomaxillary suture was difficult to identify^{6,32} as it undergoes progressive ossification postnatally.³³ The inter-assessor agreement for premaxillary and maxillary length was fair, showing variations in the interpretation between clinicians. For this reason, and because of controversies related to the premaxilla in humans,^{1,2} a further comparison between the high-length and the low-length group based on relative APMCL was performed considering the premaxilla and maxilla as

a single bone, confirming the presence of a shorter premaxillomaxillary segment in the low-length group ($P = .044$) and no differences in the length of the palatine bones.

Despite that size anomalies of the maxillary complex may be three-dimensional,¹² only the anteroposterior dimension was analyzed because of the already complex study design and the lack of reliable references for latero-lateral and supero-inferior measurements of such structures. Overall, the present study did not investigate the characteristics of subjects with maxillary hypoplasia or retrusion, which would require a case control study. Furthermore, demonstrating the etiology of the presented anatomical findings and their underlying growth mechanisms, including allometry and differential growth among the parts,²⁴ would require longitudinal investigations in growing subjects.

CONCLUSIONS

- Evaluating the anteroposterior maxillary complex length by using its ratio with the anterior cranial base may be more clinically relevant than adopting absolute measurements, which may not be optimal for the identification of disproportions.
- For the present sample, the use of relative measurements revealed that a shorter maxilla (and not premaxilla or palatine bone) was associated with a shorter maxillary complex.
- The anteroposterior position of the maxillary complex seemed to be associated but not correlated to its anteroposterior length. Thus, clinicians should perform differential diagnosis between these two conditions when performing radiological skeletal assessments.

ACKNOWLEDGMENTS

The authors declare no conflicts of interest. The authors express their gratitude to Ms. Li SKY (Central Research Laboratory, Faculty of Dentistry, The University of Hong Kong, Hong Kong S.A.R.) for her assistance in the statistical analysis. This work was supported by the scholarship "Preparazione di tesi o relazione finale all'estero" (University of Brescia, Brescia, Italy) received by Massetti F.

REFERENCES

1. Woo JK. Ossification and growth of the human maxilla, premaxilla and palate bone. *Anat Rec.* 1949;105(4):737–761.
2. Barteczko K, Jacob M. A re-evaluation of the premaxillary bone in humans. *Anat Embryol (Berl).* 2004;207(6):417–437.
3. Latham RA. Maxillary development and growth: the septo-premaxillary ligament. *J Anat.* 1970;107(Pt 3):471–478.
4. Enlow DH, Bang S. Growth and Remodeling of the Human Maxilla. *Am J Orthod.* 1965;51:446–464.
5. Melsen B. Palatal growth studied on human autopsy material. A histologic microradiographic study. *Am J Orthod.* 1975;68(1):42–54.
6. Haskell BS, Farman AG. Exploitation of the residual premaxillary-maxillary suture site in maxillary protraction. An hypothesis. *Angle Orthod.* 1985;55(2):108–119.
7. Mann RW, Jantz RL, Bass WM, Willey PS. Maxillary suture obliteration: a visual method for estimating skeletal age. *J Forensic Sci.* 1991;36(3):781–791.
8. Suri S, Tompson BD, Cornfoot L. Cranial base, maxillary and mandibular morphology in Down syndrome. *Angle Orthod.* 2010;80(5):861–869.
9. Harvold EP, Tomer BS, Vargervik K, Chierici G. Primate experiments on oral respiration. *Am J Orthod.* 1981;79(4):359–372.
10. Conway H, McKinney P. Surgical correction of hypoplasia of the maxilla. *Arch Surg.* 1966;92(5):759–764.
11. Guyer EC, Ellis EE III, McNamara JA Jr, Behrents RG. Components of Class III malocclusion in juveniles and adolescents. *Angle Orthod.* 1986;56(1):7–30.
12. Ngan P, Moon W. Evolution of Class III treatment in orthodontics. *Am J Orthod Dentofacial Orthop.* 2015;148(1):22–36.
13. Guimaraes CV, Donnelly LF, Shott SR, Amin RS, Kalra M. Relative rather than absolute macroglossia in patients with Down syndrome: implications for treatment of obstructive sleep apnea. *Pediatr Radiol.* 2008;38(10):1062–1067.
14. Thilander B, Persson M, Adolfsson U. Roentgen-cephalometric standards for a Swedish population. A longitudinal study between the ages of 5 and 31 years. *Eur J Orthod.* 2005;27(4):370–389.
15. Proff P, Will F, Bokan I, Fanghanel J, Gedrange T. Cranial base features in skeletal Class III patients. *Angle Orthod.* 2008;78(3):433–439.
16. Cevidanes LH, Franco AA, Scanavini MA, Vigorito JW, Enlow DH, Proffit WR. Clinical outcomes of Frankel appliance therapy assessed with a counterpart analysis. *Am J Orthod Dentofacial Orthop.* 2003;123(4):379–387.
17. Kerr WJ, Ford I. The variability of some craniofacial dimensions. *Angle Orthod.* 1991;61(3):205–210.
18. Stojanovic Z, Nikolic P, Nikodijevic A, Milic J, Stojanovic B. Cephalometric assessment of maxillary length in Serbian children with skeletal Class III. *Vojnosanit Pregl.* 2013;70(7):645–652.
19. Chang HP, Kinoshita Z, Kawamoto T. Craniofacial pattern of Class III deciduous dentition. *Angle Orthod.* 1992;62(2):139–144.
20. Seto BH, Gotsopoulos H, Sims MR, Cistulli PA. Maxillary morphology in obstructive sleep apnoea syndrome. *Europ J Orthod.* 2001;23(6):703–714.
21. Blacker D. Psychiatric Rating Scales. In: Sadock BJ, Sadock V, eds. *Comprehensive Textbook of Psychiatry.* 8th ed. Philadelphia: Lippincott Williams & Wilkins; 2005: 929–955.
22. Dahlberg G. Statistical methods for medical and biological students. *Br Med J.* 1940;2(4158):358–359.
23. Savoldi F, Xinyue G, McGgrath CP, Yang Y, Chow SC, Tsoi JKH, Gu M. Reliability of lateral cephalometric radiography in the assessment of the upper airway in children: A retrospective study. *Angle Orthod.* 2020;90(1):47–55.
24. Scott JH. The growth of the human face. *Proc R Soc Med.* 1954;52:263–268.

25. Bhat M, Enlow DH. Facial variations related to headform type. *Angle Orthod.* 1985;55(4):269–280.

26. Martinez-Maza C, Rosas A, Nieto-Diaz M. Postnatal changes in the growth dynamics of the human face revealed from bone modelling patterns. *J Anat.* 2013; 223(3):228–241.

27. Chang HP, Liu PH, Tseng YC, Yang YH, Pan CY, Chou ST. Morphometric analysis of the cranial base in Asians. *Odontology.* 2014;102(1):81–88.

28. Hixon EH. The norm concept and cephalometrics. *Am J Orthod.* 1956;42(12):898–906.

29. Jackson IT. Maxillary hypoplasia. *Clin Plast Surg.* 1989; 16(4):757–775.

30. Kubota Y, Nakayama H, Takada T, et al. Facial axis angle as a risk factor for obstructive sleep apnea. *Intern Med.* 2005; 44(8):805–810.

31. Lew KK, Foong WC, Loh E. Malocclusion prevalence in an ethnic Chinese population. *Aust Dent J.* 1993;38(6):442–449.

32. Savoldi F, Tsoi JKH, Paganelli C, Matinlinna JP. Sutural morphology in the craniofacial skeleton: a descriptive micro-computed tomography study in a swine model. *Anat Rec.* 2019;302(12):2156–2163.

33. Behrents RG, Harris EF. The premaxillary-maxillary suture and orthodontic mechanotherapy. *Am J Orthod Dentofacial Orthop.* 1991;99(1):1–6.

Appendix Table 1. Description of the Cephalometric Landmarks and Variables Used in the Study

	Abbreviation	Unit	Description
Landmarks			
Sella	S		The center of the pituitary fossa of the sphenoid bone
Nasion	N		The most anterior point of the frontonasal suture
Anterior nasal spine	ans		The most anterior point of the basal bone of the maxilla
Posterior nasal spine	pns		The most posterior point of the hard palate
Point A (subspinale)	A		The most posterior point of the curvature of the maxilla between the ans and the alveolar crest
Posterior limit of the premaxilla	atps		The intersection of the anterior transverse palatal suture (premaxillomaxillary suture) with the midpalatal suture
Posterior limit of the maxilla	ptps		The intersection of the posterior transverse palatal suture (maxillopalatal suture) with the midpalatal suture
Measured variables			
<i>Cranial base length</i>	SN	mm	The distance from S to N
<i>Maxillary complex length</i>	ans-pns	mm	The distance from ans to pns
<i>Premaxillary length</i>	PM	mm	The distance from ans to atps
<i>Maxillary length</i>	MA	mm	The distance from atps to ptps
<i>Palatine length</i>	PA	mm	The distance from ptps to pns
<i>Maxillary complex alveolar protrusion</i>	SNA	°	The angle formed between S, N, and A
<i>Maxillary complex basal protrusion</i>	SNans	°	The angle formed between S, N, and ans
Calculated variables			
<i>Relative premaxillary length</i>	PM%	%	The relative length of PM with respect to ans-pns ($PM/ans-pns$)
<i>Relative maxillary length</i>	MA%	%	The relative length of MA with respect to ans-pns ($MA/ans-pns$)
<i>Relative palatine length</i>	PA%	%	The relative length of PA with respect to ans-pns ($PA/ans-pns$)
<i>Relative maxillary complex length</i>	ans-pns/SN	%	The relative length of ans-pns with respect to SN ($ans-pns/SN$)

Downloaded from <http://meridian.allenpress.com/angle-orthodontist/article-pdf/91/1/88/2685499/0003-3219-91-1-88.pdf> by Univ of Hong Kong user on 26 May 2021