

Conservative Composite Resin Restoration for Proximal Caries – Two Case Reports

This article was published in the following Dove Press journal:
Clinical, Cosmetic and Investigational Dentistry

Ollie Yiru Yu ¹
Ahmed Mohamed Zaeneldin ¹
Hamdi Hosni Hamda Hamama ²
May Lei Mei ³
Neil Patel⁴
Chun-Hung Chu ¹

¹Faculty of Dentistry, The University of Hong Kong, Hong Kong SAR, People's Republic of China; ²Faculty of Dentistry, Mansoura University, Mansoura, Dakahlia, Egypt; ³Faculty of Dentistry, University of Otago, Dunedin, Otago, New Zealand; ⁴Division of Dentistry, University of Manchester, Manchester, UK

Abstract: The paradigms of contemporary caries management have shifted to minimal intervention dentistry. Conservative restorative procedures are recommended to replace the complete removal of all carious tissues in the management of dental caries. This article reports two clinical cases of conservative restorations of proximal caries. Different conservative cavity designs and restorative techniques were performed in the two cases. Proximal caries in posterior teeth were prepared using the box-only preparation technique or the proximal tunnel preparation technique. The cavities were restored directly with resin composites. The advantages of using the box-only preparation with fissure sealant included the maximum conservation of tooth hard tissues and the prevention of unnecessary tissue removal in the occlusal surface. The tunnel preparation preserved the marginal ridge and protected the restored tooth from fracture. The filling of composites into the tunnel demonstrated a better marginal adaptation than other restorative materials. These two techniques allowed for the preservation of more healthy dental hard tissue compared with traditional techniques. Potential problems in the restoration included the high incidence of the inappropriate removal of dental hard tissue, damage of the vital pulp and the microleakage due to the polymerization shrinkage. The solutions to minimize the risk of these problems in the operative procedures were discussed.

Keywords: case report, caries, restoration, resin composite, minimally invasive dentistry

Introduction

Dental caries is the most prevalent non-communicable oral disease worldwide.¹ The World Health Organization has defined the noncommunicable diseases as “disease tend to be of long duration and are the result of a combination of genetic, physiological, environmental and behavioural factors.” The traditional management of dental caries employed the concept of “extension for prevention” is no longer acceptable in contemporary practice.² However, the implementation of “extension for prevention” required the removal of some sound enamel or dentine to reduce the incidence of secondary caries. It was recommended to completely remove carious tissue and to leave only hard tissue behind. Extensive cavity design was also suggested. The cavity preparation had to be extended following the fissure anatomy. In addition, the cavosurface margins of the cavity had to be located on non-fissured enamel. The proximal cavity preparation had to be extended to break contact with the adjacent teeth to create self-cleansing margins.²

In addition, the use of traditional dental restorative materials made excessive cavity preparation unavoidable due to the physical properties of these materials. Restorative materials, such as dental amalgam and glass ionomer cement, are liable for fracture when an occlusal force causes the flexure of these materials. Therefore,

Correspondence: Chun-Hung Chu
The University of Hong Kong, 3B26,
Prince Philip Dental Hospital, 34 Hospital
Road, Hong Kong SAR, People's Republic
of China
Tel +852 2859 0287
Fax +852 2559 4194
Email chchu@hku.hk

cavity designs ensuring enough material thickness are required when one is placing these restorative materials into the cavity. Usually these materials require a minimum thickness of 1.5 to 2.0 mm to resist occlusal loading.³

However, all current dental restorations have limited lifespans. According to previous studies on the annual failure rate of dental restorations, it was estimated that dental restorations would need to be replaced after three to ten years.⁴ The finite lifespans of restorations indicate that dental restorations will need to be replaced several times in most patients. The replacement of dental restorations leads to cavities of increased sizes.⁵ This is known as the repeat restoration cycle. The repeat restoration cycle requires additional time and expense for the re-restoration therapy, including complex and expensive endodontic or surgical treatments. It eventually leads to the infeasibility of further restoration, as well as the increased possibility of extraction. Therefore, avoiding or slowing down the repeat restoration cycle has great significance in preserving teeth for longer periods, which has a profound impact on the development of minimal intervention dentistry.

Minimal intervention dentistry is a philosophy aimed at attempting to keep teeth healthy and functional for life.⁶ Following the principle of minimal intervention dentistry, conservative interventions are required to restore the morphology and function of teeth when cavitated lesions have developed. The current article reports two clinical cases of the restoration of cavitated caries involving the proximal surface of the teeth, embracing the principle of minimal intervention dentistry. The purpose of this article is to demonstrate two conservative operative techniques for the management of proximal caries in posterior teeth. The advantages and disadvantages of the techniques are discussed.

Case Report

Case I: Box-Only Restoration with Fissure Sealing

A 35-year-old female patient presented in a clinical appointment complaining about intermittent pain during meals in the maxillary posterior area on the left. An initial clinical examination revealed that caries extended along the central fissure on the occlusal surface of tooth 24. A cavitated carious lesion was found on the distal occlusal surfaces. The distal marginal ridge was destructed (Figure 1A). A bite-wing radiograph showed that the carious lesion on the distal side extended to the middle

third of the dentine (Figure 1B). The examinations indicated active deep caries that had developed in the distal occlusal area with proximal surface involvement (International caries detection and assessment system - ICDAS 5). Micro-cavitated enamel caries (ICDAS 3) in the fissure area of the occlusal surface was visualized as well. The patient's informed consent for the dental treatment, the publication of the clinical photos, and the publication of the case report were obtained before the treatment. No institutional approval was required to publish this case report.

A rubber dam (Dental dam, Coltene, Cuyahoga Falls, OH, USA) was placed for the isolation of the working field with a w7 clamp fixed on tooth 26. The excavation of caries-infected dentine was performed using a round carbide bur in a slow-speed handpiece. The carious and unsupported enamel and carious dentine on the distal proximal surface was removed conservatively until the firm dentine was reached. A cavity outline form was therefore established (Figure 1C).

A layer of glass ionomer cement liner (Vitrebond Light Cure Glass Ionomer Liner and Base, 3M ESPE Dental Products, St. Paul, MN, USA) was placed on the pulpal floor of the cavity for pulp protection (Figure 1D). In addition, a sectional matrix and a suitable pre-fabricated band (Palodent Matrix System, Dentsply Sirona, Charlotte, NC, USA) were placed for the separation of the contact area with the adjacent tooth. Selective acid etching on enamel was performed for 15 seconds. Specifically, a two-step self-etch bonding system (Scotchbond™ Etchant, 3M ESPE Dental Products, St. Paul, MN, USA; Clearfil™ SE Bond, Kuraray, Tokyo, Japan) was applied on the enamel and dentine of the cavity. Then, a thin layer of flowable resin composite (Filtek™ Supreme XT Flowable Restorative, 3M ESPE Dental Products, St. Paul, MN, USA) was injected into the floor of the cavity and light-cured (Figure 1E).

Afterwards, the distal proximal wall of the tooth was built up with resin composite (Filtek™ Z250 Resin Composite, 3M ESPE Dental Products, St. Paul, MN, USA), using the sectional matrix as a guide (Figure 1F). The sectional matrix and clamp were then removed to check any voids on the external surface of the proximal composite wall (Figure 1G). The cavity was filled with resin composite using the incremental layering technique. Specifically, the resin composite was stacked on a slope on the buccal side of the cavity to restore the morphology of the buccal cusp (Figure 1H). After light-curing, the lingual

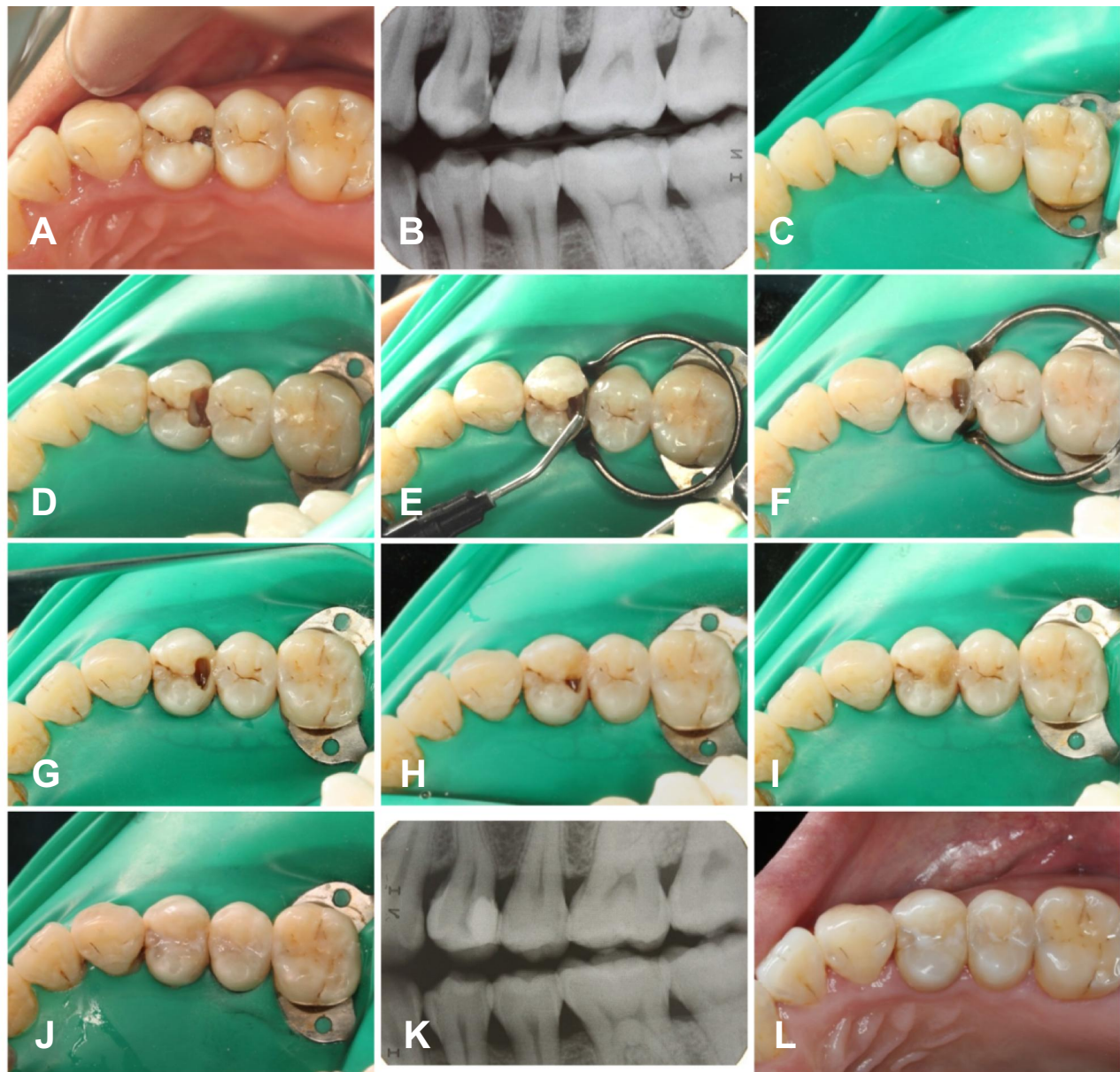


Figure 1 Steps of restoration in Tooth 24. (A) Preoperative image of 24; (B) Preoperative radiographic image of 24; (C) Removal of carious enamel and dentine; (D) Placement of glass ionomer cement liner; (E) Injection of flowable composite into the floor of the cavity; (F) Construction of the distal proximal wall; (G) Removal of the sectional matrix; (H) Filling the cavity using the incremental technique; (I) Reconstruction of the morphology of 24; (J) Sealing the micro-cavitated occlusal fissure caries with a fissure sealant; (K) Postoperative bitewing radiograph; (L) Postoperative image taken three months after the restoration.

cusps was built up in an oblique incremental manner. In addition, the occlusal surface, cusps, and marginal ridge were shaped during the procedure (Figure 1I). In addition, the initial fissure caries on the occlusal surface was cleaned and sealed with a fissure sealant (Clinpro™ Sealant, 3M ESPE Dental Products, St. Paul, MN, USA) (Figure 1J). The restoration and sealants were subsequently checked and adjusted for any occlusal discrepancies with articulating paper. The occlusion was adjusted. Finally, the restorations and sealants were polished with

a finishing and polishing system Sof-lex Finishing and Polishing Kit (3M ESPE Dental Products, St. Paul, MN, USA). Post-operative bitewing radiography was performed to check the restoration (Figure 1K). The caries risk of the patient was high. Therefore, the patient was asked to make a recall visit three months later. Caries activity and risk factors were re-evaluated. Clinical examinations were performed, and the restoration was checked for marginal integrity, marginal adaptation, color, retention, and occlusion (Figure 1L).

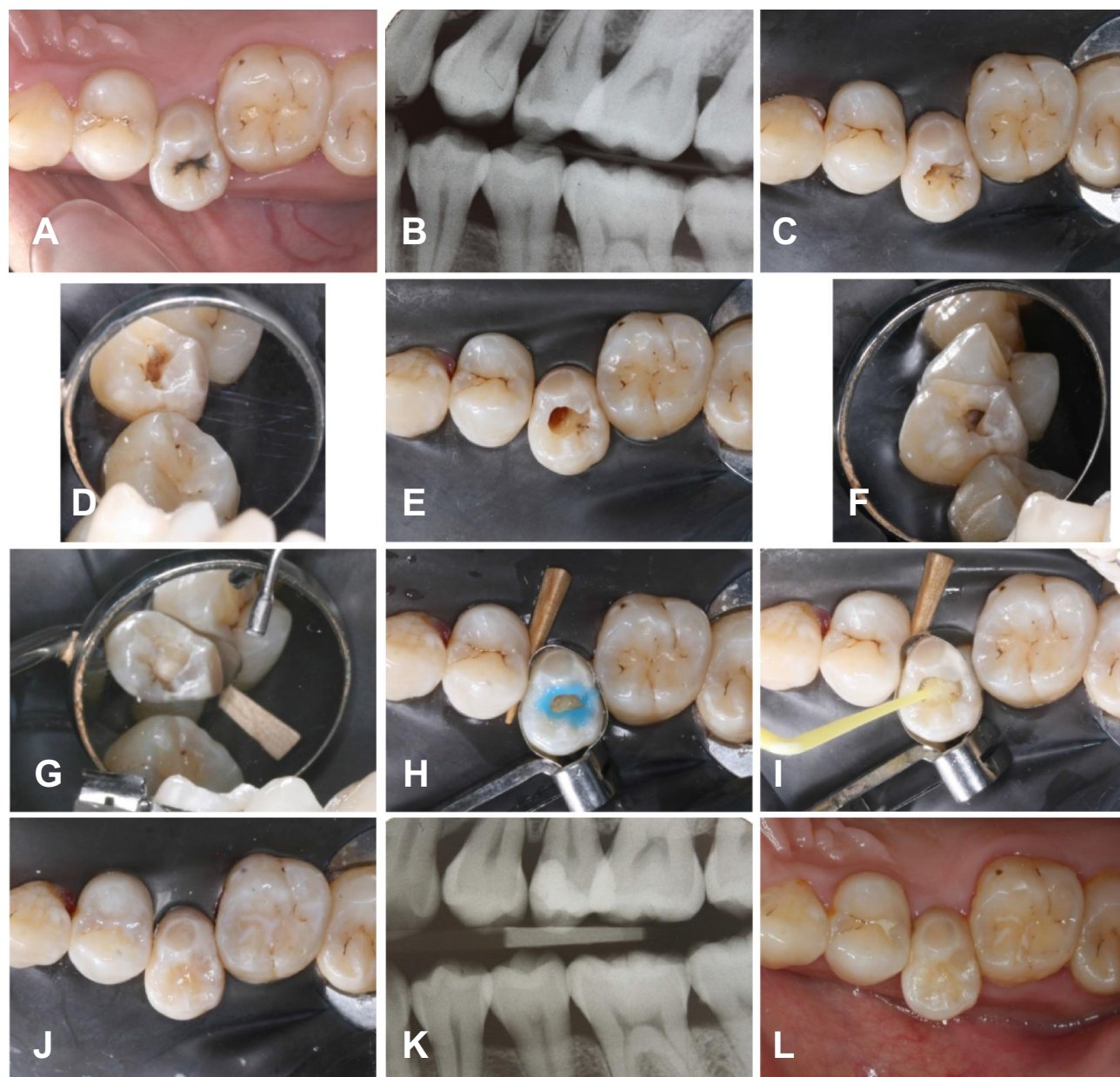


Figure 2 Steps of tunnel restoration in Tooth 15. (A) Occlusal view of 15 before operation; (B) Right bitewing radiography; (C) Occlusal view of the access to the mesial proximal caries; (D) Lateral view of the access to the mesial proximal caries; (E) Occlusal view of the cavity after caries removal; (F) Lateral view of the cavity after caries removal; (G) Restoration of the proximal wall of the cavity; (H) Selective acid-etching on enamel; (I) Bonding agents were applied to the cavity; (J) Restoration of the occlusal cavity; (K) Postoperative bitewing radiograph; (L) Occlusal view after three months.

Case 2: Tunnel Preparation with Resin Composite Restoration

A 36-year-old female patient was complaining about an uncomfortable feeling in the maxillary posterior area on the right. A clinical examination found cavitated enamel caries in the fissure area of the occlusal surface of her upper second premolar. The marginal ridge was not involved (Figure 2A). A bitewing radiograph showed that the carious lesion was undermined from the occlusal surface to the mesial proximal

surface. The middle third of the dentine was involved (Figure 2B). The examinations indicated dentine caries (ICDAS 4) on the occlusal surface and mesial proximal surface. The patient's informed consent for the dental treatment, the publication of the clinical photos, and the publication of the case report were obtained before the treatment. No institutional approval was required to publish this case report.

A rubber dam (Dental dam, Coltene, Cuyahoga Falls, OH, USA) was used to isolate the operating field. Access

to the caries on the mesial proximal surface was achieved through the fissure area of the occlusal surface (Figure 2C and D). The carious tissue was removed from the occlusal assess with the bur oriented mesially. Infected dentine with soft texture was removed and firm affected dentine was remained. Thus, a tunnel under the mesial marginal ridge was built. The mesial marginal ridge remained intact (Figure 2E and F).

A Tofflemire matrix system (Original Tofflemire[®] Matrix Band, Water Pik, Inc, CO, USA; Tofflemire[®] II Retainers, Water Pik, Inc, CO, USA) was placed on the premolar, and a wooden wedge was inserted from the palatal embrasure between teeth 14 and 15. The mesial proximal wall of the cavity was restored using a two-step self-etching bonding system (Scotchbond TM Etchant, 3M ESPE Dental Products, St. Paul, MN, USA; Scotchbond TM Multipurpose Adhesive System, 3M ESPE Dental Products, St. Paul, MN, USA) and resin composite (Figure 2G). Selective acid-etching on the enamel was performed using 37% phosphate acid (Scotchbond TM Etchant, 3M ESPE Dental Products, St. Paul, MN, USA) on the enamel wall of the cavity for 15 seconds, and then, the acid was rinsed thoroughly (Figure 2H). The tooth was partially dried with oil-free air. A universal bonding agent was then applied (Figure 2I) and light cured. The occlusal cavity was restored using composite (Filtek TM Z250 Resin Composite, 3M ESPE Dental Products, St. Paul, MN, USA) and the incremental layering technique (Figure 2J). Bitewing radiography was performed after the restoration process to check the marginal status of the restorative material (Figure 2K). The patient was checked three months later, at which time the caries activity and risk were reassessed. Clinical photos of the restored tooth were taken (Figure 2L).

Discussion

Rational Behind Box-Only Restoration with Fissure Sealing

The advantage of the box-only preparation in Case 1 is that it exhibits the maximum conservation of tooth hard tissues compared with a traditional proximal (Class II) restoration. A classical posterior proximal restoration requires the preparation of an occlusal box with a dovetail outline form and a proximal box with the clearance of contact with the adjacent teeth. The occlusal cavity is extended through the fissures to the central pits to prevent the further development of carious lesions.⁷ The excessive removal of sound tooth

structure weakens the tooth, rendering it more susceptible to failure, fracture, and cracks. The box-only preparation follows the principle of minimally invasive preparation and of avoiding the excessive removal of dental hard tissue.

Occlusal caries was sealed with fissure sealant to prevent unnecessary tissue removal in the occlusal surface of the tooth. Dental fissure sealing can slow down the repeat restoration cycle of a tooth by avoiding having to place a restoration.⁴ It is a non-invasive and non-restorative approach that could preserve dental hard tissue by avoiding the unnecessary removal of caries lesions. It is effective in the prevention and management of non-cavitated caries.⁸ In addition, fissure sealants are proven to be effective in the management of micro-cavitated caries.⁹ A systematic review showed the effectiveness of fissure sealants in the management of dental caries and in the control of a bacterial infection.¹⁰ A clinical study applied fissure sealant on occlusal caries (ICDAS code 0 to 4) on permanent molars of children and found that the sealants were 100% effective at 12 months and 98% effective up to 44 months.⁹

Rational Behind Tunnel Preparation with Resin Composite Restoration

Apart from being conservative, tunnel preparation preserve the marginal ridge, which is important for protecting the restored tooth from fracture.¹¹ The resistance of the restored tooth to fracture would be similar to that of a sound tooth if the tooth were appropriately prepared.¹² Studies showed that the preservation of the marginal ridge played a significant role in maintaining the integrity of the tooth structure. The removal of the marginal ridge leads to liability for fracture under normal masticatory forces.^{13–16}

A tunnel preparation filled with posterior composites demonstrated a better marginal adaptation than glass ionomer cements, metal-reinforced glass-ionomer-cements, or amalgams dud.¹⁷ A study by Kinomoto et al showed that a two-year clinical success rate of composite tunnel restorations was 96%, which was not significantly different when compared with a conventional composite restoration.¹⁸

There have been controversial comments on the tunnel technique due to the different success rate reported in previous studies.^{18,19} This may be explained by the high technique sensitive of tunnel restoration. A previous study found that the dentist's skill played a significant role in the success of tunnel restorations.²⁰ A high success rate was found in tunnel restorations performed by an experienced dentist.^{18,21} In addition, the significant advances in dental

instruments including handpieces emerging with light-emitting diodes and high-magnification dental loupes enhance intraoral visibility.

Potential Problems in the Operative Procedure and Their Solutions

In the removal of a carious lesion, the incidence of the inappropriate removal of dental hard tissue is high. The removal of healthy enamel or dentine was not favorable in both of the current cases. In the preparation of the proximal box in Case 1, the excessive removal of dental hard tissue could have occurred. This might have increased the risk of tooth fracture. In the preparation of the tunnel in Case 2, an enamel fracture would have occurred if the cavity preparation had been too close to the marginal ridge (less than 1.5 mm).¹² On the other hand, the preparation would have removed excessive dentine if 3.5 mm of the marginal ridge had been retained. The resulting tunnel preparation could have been more prone to fatigue crack growth.¹⁶ A study showed that 2.5 mm of the marginal ridge is the critical amount for the success of a tunnel preparation. The strength of the tooth with this amount of a marginal ridge would be comparable to that of a sound tooth.¹² Therefore, the precise removal of carious tissues was difficult but essential in both cases.

To prevent unwanted enamel/dentine removal in the cavity preparation, we suggested that three essential conditions should be achieved in the operation process, including a clear operation field, strict moisture control, and suitable magnification. A clear operation field was created via the removal of supra-/sub-gingival plaque, debris, and calculus before the operative intervention, as well as the application of a rubber dam. The placement of the rubber dam isolated the carious tooth from the other teeth. It helped to keep saliva and blood from contaminating the operating area during treatment. Previous studies showed that a rubber dam might actually increase the lifespans of dental restorations.²² The placement of a rubber dam not only improves visibility during operative procedures but also it helps with moisture control. Poor moisture control increases the risk of secondary caries, the early dislocation of the restoration, and the need for redo a restoration,⁴ which enlarges the cavity and increases hard tissue loss.⁵ Thus, strict moisture control is one of the key factors affecting the longevity of the composite restorations. Suitable magnification could be achieved by using magnifying loupes or microscopes. These devices could

improve the operator's ability to visualize the extent of the lesion.²³ Thus, more precise caries removal and better cavity preparation were possible. In addition, the use of magnifying loupes was helpful in reducing the formation of marginal overhangs in up to 40% restorations of proximal cavities.²⁴ Another approach to reduce the risk of the unwanted enamel/dentine removal is to treat the proximal caries with resin infiltration. The merge of resin infiltration and tunnel preparation is possible to preserve both the marginal ridge and the proximal contact of the tooth.²⁵

Another potential problem is the damage of vital pulp in the preparation and restoration process. The occurrence of pulp irritation or pulp exposure is common when one is restoring deep carious lesions. In both cases, caries extended to the dentine close to the vital pulp. The possibility of pulp damage was high in the process of caries removal and cavity restoration.

We used different strategies to prevent this problem in the two cases based on the extension of the caries. In Case 1, after the removal of all caries-infected dentine, the thickness of the remaining dentine was approximately 0.5 mm to 1.5 mm. Therefore, we used a resin-modified glass ionomer cement liner as indirect pulp capping according to a previous recommendation.²⁶ The layer of the resin-modified glass ionomer cement not only acted as a protective barrier for the pulp but also it released fluoride ion, which enhanced the remineralization of the caries-affected dentine. In Case 2, the risk of pulp damage mainly came from the preparation of the tunnel. As the tunnel was prepared from the occlusal surface and angled to the proximal surface without a direct view, well control of the orientation of the bur according to the radiographic examination is the key to protect the pulp.

Resin composite was used as the restorative material in these two cases to support minimal cavity design. However, the polymerization shrinkage of the resin composite results in the formation of inner stresses, which might cause cuspal deflection, strain at the margins, contraction gaps, and microleakage.²⁷ All of these may lead to marginal staining, post-operative sensitivity in the patient, the occurrence of secondary caries, and restoration failure.²⁸

To reduce the inner stress resulting from the polymerization shrinkage of resin composite, we used the oblique incremental restoration technique to restore the cavity. This is a technique used to place the composite incrementally to ensure maximum polymerization and to reduce the adverse effects of polymerization shrinkage. The resin

composite increment was built obliquely because the oblique incremental technique reduced residual shrinkage stress along the tooth/composite interface compared with the horizontal incremental technique.²⁹ A study showed that composite restored with the incremental technique presented a higher bond strength compared with that restored with the bulk-fill technique.³⁰

In addition, we used a revised sandwich technique in Case 1 to reduce the microleakage stemming from the shrinkage stress of resin composite. A traditional sandwich technique was to place resin composite over a resin-modified glass ionomer cement material. The polymerization shrinkage stresses might be reduced due to the favorable elastic modulus of the resin-modified glass ionomer cement.³¹ The marginal seal of the resin-modified glass ionomer cement was related to the viscosity of the material and to the application technique. A study showed that the traditional sandwich technique using resin-modified glass ionomer cement with resin composite leads to more leakage than that using flowable resin composite does.³² Therefore, we covered the resin-modified glass ionomer cement liner and the floor of the cavity with a layer of flowable resin composite. Flowable composites showed more stress-buffering capacity and an improved marginal seal than hybrid resin composites did. More importantly, it would not reduce the retention of resin composite restorations.³³

Conclusion

This article reports and discusses two clinical cases of restoring proximal caries. Conservative cavity design was executed in the restorative procedures to embrace the principle of minimal intervention dentistry. The advantages and disadvantages of the restorative techniques should be taken into consideration when making treatment plans. Attentions need to be paid to the potential problems which may influence the long-term prognosis of cavity restoration.

Disclosure

The authors declare no conflicts of interest.

References

- Kassebaum N, Bernabé E, Dahiya M, Bhandari B, Murray C, Marcenes WJ. Global burden of untreated caries: a systematic review and metaregression. *J Dent Res.* 2015;94(5):650–658. doi:10.1177/0022034515573272
- Osborne JW, Summitt JB. Extension for prevention: is it relevant today? *Am J Dent.* 1998;11(4):189–196.
- Ritter AV, Boushell LW, Walter R. *Sturdevant's Art and Science of Operative Dentistry.* 7th ed. St. Louis: Elsevier; 2018.
- Schwendicke F, Lamont T, Innes N. Removing or controlling? How caries management impacts on the lifetime of teeth. In: Schwendicke F, Frencken J, Innes N, editors. *Caries Excavation: Evolution of Treating Cavitated Carious Lesions.* Vol. 27. Karger Publishers; 2018:32–41.
- Brantley CF, Bader JD, Shugars DA, Nesbit SP. Does the cycle of reresoration lead to larger restorations. *J Am Dent Assoc.* 1995;126(10):1407–1413. doi:10.14219/jada.archive.1995.0052
- Frencken JE, Peters MC, Manton DJ, Leal SC, Gordan VV, Eden E. Minimal intervention dentistry for managing dental caries - a review: report of a FDI task group. *Int Dent J.* 2012;62(5):223–243.
- Black GV. *The Pathology of the Hard Tissues of the Teeth.* Vol. 1. Medico-Dental Publishing Company; 1914.
- Griffin SO, Oong E, Kohn W, et al. The effectiveness of sealants in managing caries lesions. *J Dent Res.* 2008;87(2):169–174. doi:10.1177/154405910808700211
- Fontana M, Platt JA, Eckert GJ, et al. Monitoring of sound and carious surfaces under sealants over 44 months. *J Dent Res.* 2014;93(11):1070–1075.
- Oong EM, Griffin SO, Kohn WG, Gooch BF, Caufield PW. The effect of dental sealants on bacteria levels in caries lesions: a review of the evidence. *J Am Dent Assoc.* 2008;139(3):271–278. doi:10.14219/jada.archive.2008.0156
- Xie KX, Wang XY, Gao XJ, Yuan CY, Li JX, Chu CH. Fracture resistance of root filled premolar teeth restored with direct composite resin with or without cusp coverage. *Int Endod J.* 2012;45(6):524–529. doi:10.1111/j.1365-2591.2011.02005.x
- Ji W, Chen Z, Frencken JE. Strength of tunnel-restored teeth with different materials and marginal ridge height. *Dent Mater.* 2009;25(11):1363–1370. doi:10.1016/j.dental.2009.06.007
- Palamara JE, Palamara D, Messer HH. Strains in the marginal ridge during occlusal loading. *Aust Dent J.* 2002;47(3):218–222. doi:10.1111/j.1834-7819.2002.tb00332.x
- Covey D, Schulein TM, Kohout FJ. Marginal ridge strength of restored teeth with modified Class II cavity preparations. *J Am Dent Assoc.* 1989;118(2):199–202. doi:10.14219/jada.archive.1989.0226
- Shahrbaf S, Mirzakouchaki B, Oskoui SS, Kahnamousi MA. The effect of marginal ridge thickness on the fracture resistance of endodontically-treated, composite restored maxillary premolars. *Oper Dent.* 2007;32(3):285–290. doi:10.2341/06-83
- Chu CH, Mei ML, Cheung C, Nalliah RP. Restoring proximal caries lesions conservatively with tunnel restorations. *Clin Cosmet Investig Dent.* 2013;5:43–50. doi:10.2147/CCIDE.S48567
- Chalker SA, Lumley PJ. An in vitro assessment of cavity margin finishing and marginal adaptation of tunnel restorations. *Eur J Prosthodont Restor Dent.* 1993;1(4):151–156.
- Kinomoto Y, Inoue Y, Ebisu S. A two-year comparison of resin-based composite tunnel and Class II restorations in a randomized controlled trial. *Am J Dent.* 2004;17(4):253–256.
- Strand GV, Tveit AB, Eide GE. Cavity design and dimensions of tunnel preparations versus composite resin Class-II preparations. *Acta Odontol Scand.* 1995;53(4):217–221. doi:10.3109/00016359509005975
- Pilebro CE, van Dijken JW. Analysis of factors affecting failure of glass cermet tunnel restorations in a multi-center study. *Clin Oral Investig.* 2001;5(2):96–101.
- Wiegand A, Attin T. Treatment of proximal caries lesions by tunnel restorations. *Dent Mater.* 2007;23(12):1461–1467. doi:10.1016/j.dental.2006.12.004
- Keys W, Carson SJ. Rubber dam may increase the survival time of dental restorations. *Evidence-Based Dent.* 2017;18(1):19. doi:10.1038/sj.ebd.6401221
- James T, Gilmour AS. Magnifying loupes in modern dental practice: an update. *Dent Update.* 2010;37(9):633–636. doi:10.12968/denu.2010.37.9.633

24. Frankenberger R, Kramer N, Pelka M, Petschelt A. Internal adaptation and overhang formation of direct Class II resin composite restorations. *Clin Oral Investig*. 1999;3(4):208–215. doi:10.1007/s007840050103
25. Kielbassa AM, Ulrich I, Werth VD, Schuller C, Frank W, Schmidl R. External and internal resin infiltration of natural proximal subsurface caries lesions: A valuable enhancement of the internal tunnel restoration. *Quintessence Int*. 2017;48(5):357–368.
26. Ritter AV, Swift EJ JR. Current restorative concepts of pulp protection. *Endodontic Topics*. 2003;5(1):41–48. doi:10.1111/j.1601-1546.2003.00022.x
27. Alomari QD, Reinhardt JW, Boyer DB. Effect of liners on cuspal deflection and gap formation in composite restorations. *Oper Dent*. 2001;26(4):406–411.
28. Carrera CA, Lan C, Escobar-Sanabria D, et al. The use of micro-CT with image segmentation to quantify leakage in dental restorations. *Dent Mater*. 2015;31(4):382–390. doi:10.1016/j.dental.2015.01.002
29. Soares CJ, Bicalho AA, Tantbirojn D, Versluis A. Polymerization shrinkage stresses in a premolar restored with different composite resins and different incremental techniques. *J Adhes Dent*. 2013;15(4):341–350.
30. Han SH, Park SH. Incremental and bulk-fill techniques with bulk-fill resin composite in different cavity configurations. *Oper Dent*. 2018;43(6):631–641. doi:10.2341/17-279-LR
31. Ritter AV. *Sturdevant's Art & Science of Operative Dentistry-E-Book*. Elsevier Health Sciences; 2017.
32. Moazzami SM, Sarabi N, Hajizadeh H, et al. Efficacy of four lining materials in sandwich technique to reduce microleakage in class II composite resin restorations. *Oper Dent*. 2014;39(3):256–263. doi:10.2341/11-495-L
33. Kwon OH, Kim DH, Park SH. The influence of elastic modulus of base material on the marginal adaptation of direct composite restoration. *Oper Dent*. 2010;35(4):441–447. doi:10.2341/09-372-L

Clinical, Cosmetic and Investigational Dentistry

Dovepress

Publish your work in this journal

Clinical, Cosmetic and Investigational Dentistry is an international, peer-reviewed, open access, online journal focusing on the latest clinical and experimental research in dentistry with specific emphasis on cosmetic interventions. Innovative developments in dental materials, techniques and devices that improve outcomes and patient

satisfaction and preference will be highlighted. The manuscript management system is completely online and includes a very quick and fair peer-review system, which is all easy to use. Visit <http://www.dovepress.com/testimonials.php> to read real quotes from published authors.

Submit your manuscript here: <https://www.dovepress.com/clinical-cosmetic-and-investigational-dentistry-journal>