

# Cardiac magnetic resonance imaging–negative cardiac sarcoidosis



See-Yue Arthur Yung, MBBS,\* James Chung-Man Ho, MD,† Maximus C.F. Yeung, MBBS,‡  
Carmen Chan, MBBS,\* Chung-Wah Siu, MD\*

From the \*Division of Cardiology, Department of Medicine, The University of Hong Kong, Hong Kong SAR, China, †Division of Respiratory Medicine, Department of Medicine, The University of Hong Kong, Hong Kong SAR, China, and ‡Department of Pathology, Queen Mary Hospital, The University of Hong Kong, Hong Kong SAR, China.

## Introduction

Sarcoidosis is a multisystem inflammatory granulomatous disease of unknown etiology. Up to 55% of patients with systemic sarcoidosis have documented cardiac involvement.<sup>1</sup> Albeit less common, cardiac manifestations can be the first clinical presentation of sarcoidosis. These include conduction disturbances, ventricular arrhythmias, heart failure, and sudden cardiac death, accounting for 13%–25% of sarcoidosis-related death.<sup>1</sup> Initial diagnostic workup often requires comprehensive cardiac imaging, including echocardiography, cardiac magnetic resonance imaging (CMR), and <sup>18</sup>F-FDG positron emission tomography (PET); nonetheless, the diagnosis of cardiac sarcoidosis remains challenging. The present case report illustrates the diagnostic challenge of cardiac sarcoidosis and the impacts on clinical management in a patient with cardiac sarcoidosis presenting with high-degree atrioventricular (AV) conduction block.

## Case report

A 49-year-old Indian woman with progressive shortness of breath presented to the emergency department. Two months before the admission, she experienced increasing shortness of breath while walking upslope. She had not had any episode of chest pain or syncope. Her family history was unremarkable. On admission, her blood pressure was 130/75 mm Hg with heart rate of 40 beats per minute. She had no fever and oxygen saturation of 99% on room air. There was no pitting ankle edema or distended jugular vein. Cardiovascular examination revealed normal heart sounds with no murmur. Remaining physical examination was unremarkable.

**KEYWORDS** Atrioventricular block; Cardiac magnetic resonance imaging; <sup>18</sup>F-FDG positron emission tomography; Sarcoidosis; Ventricular tachyarrhythmia

(Heart Rhythm Case Reports 2021;7:139–143)

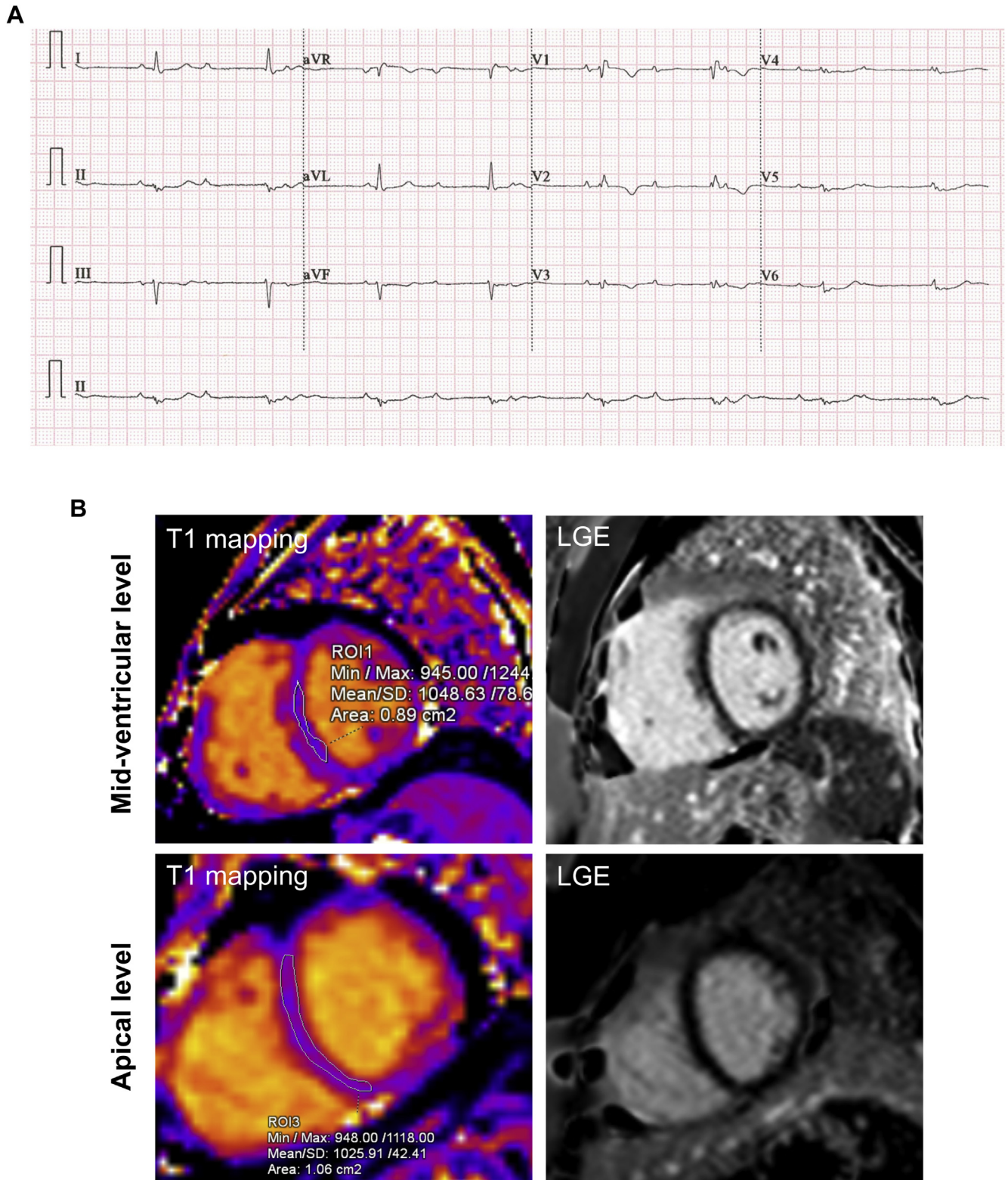
Disclosure: No authors have any real or perceived conflict of interest related to this work. **Address reprint requests and correspondence:** Dr Chung-Wah Siu, Cardiology Division, Department of Medicine, The University of Hong Kong, Queen Mary Hospital, Hong Kong, China. E-mail address: [cwdsiu@hku.hk](mailto:cwdsiu@hku.hk).

## KEY TEACHING POINTS

- Cardiac sarcoidosis commonly manifests as advanced atrioventricular block, necessitating permanent pacing.
- Current guidelines consider implantable cardioverter-defibrillators beneficial for patients with cardiac sarcoidosis who have an indication for permanent pacing because of a higher risk of sudden arrhythmic deaths.
- Cardiac magnetic resonance imaging (CMR) and <sup>18</sup>F-FDG positron emission tomography (PET) are both recommended as the imaging modality of choice for the diagnosis of cardiac sarcoidosis.
- While complementary, the choice between CMR and <sup>18</sup>F-FDG PET should take into account the timing and clinical cardiac manifestations.

A standard 12-lead electrocardiogram revealed sinus rhythm with complete AV block with narrow ventricular escape rhythm at rate of 48 beats per minute and low voltage over the precordial leads (Figure 1). Electrolytes, liver and kidney function tests, thyroid function test, and troponin were all normal. Serology for *Borrelia burgdorferi* and *Toxoplasma* were both negative. Echocardiography showed left ventricular ejection fraction (LVEF) of 55% with no regional wall abnormalities.

On the fifth admission day, CMR for possible infiltrative myocardial disease was performed. The left ventricular end-diastolic volume and end-systolic volume were 92.1 mL and 44.7 mL, respectively, with LVEF of 51.5%. The anteroseptal and posterolateral walls measured 0.7 cm and 0.6 cm, respectively. There was no regional wall motion abnormality or late gadolinium enhancement within the ventricles. T1 mapping showed native T1 value of myocardium of 1011 ms, which was within normal limits (Figure 1). In



**Figure 1** A: Twelve-lead electrocardiogram at presentation. B: Cardiac magnetic resonance imaging 5 days after initial presentation showing normal T1 mapping and normal late gadolinium enhancement of septum at the midventricular level and apical level. C: Stored ventricular electrogram of an episode of ventricular tachycardia. D: Hematoxylin–eosin section of excised lymph node showing multiple noncaseating granulomas; inset: high-power view of asteroid (upper) and Schaumann (lower) bodies in cytoplasm of multinucleated giant cells. E: Coronal <sup>18</sup>F-FDG positron emission tomography images 3 months after initial presentation.



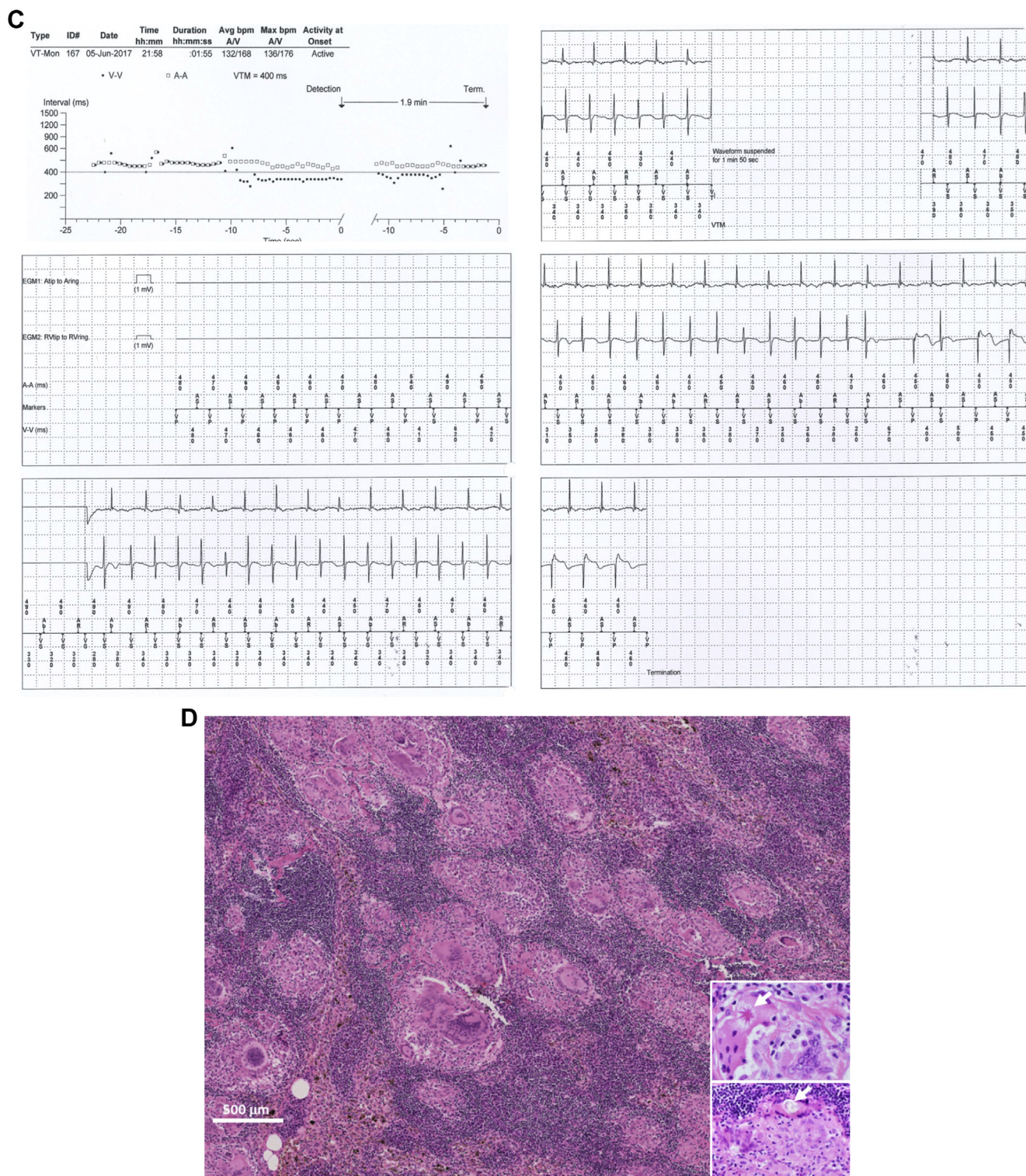
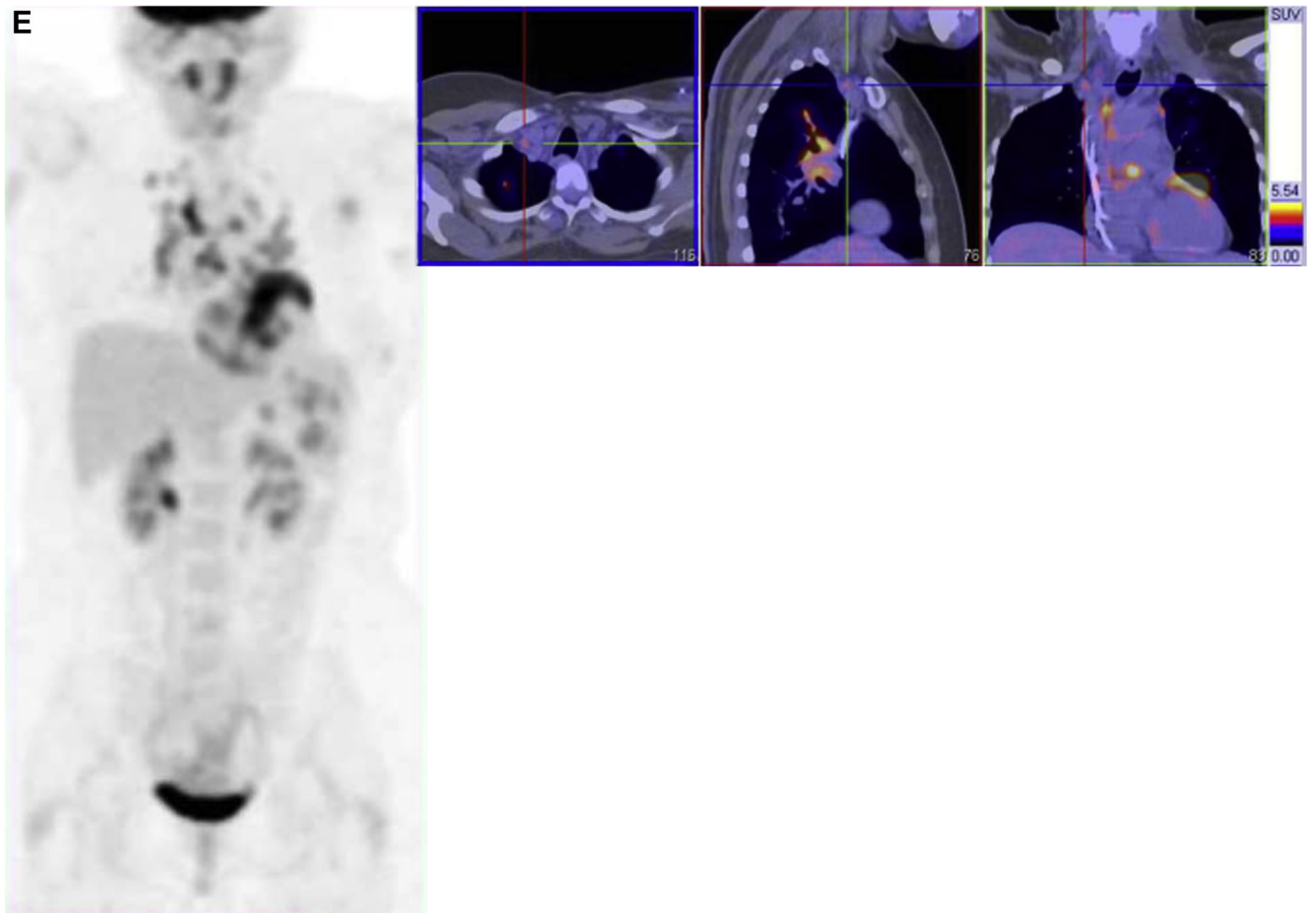


Figure 1 Continued



**Figure 1** *Continued*

view of the young onset of AV conduction block, lamin A/C genotyping was also performed, which turned out to be wild-type.

During her hospital stay, telemetry did not capture any ventricular tachyarrhythmia. A dual-chamber permanent pacemaker was implanted and she was then discharged home uneventfully. Three months after discharge, routine pacemaker interrogation revealed 153 episodes of nonsustained ventricular tachycardia, with the longest episode of 155 seconds, which was associated with presyncope (Figure 1). Echocardiography showed impaired LVEF of 40%.  $^{18}\text{F}$ -FDG PET with limited whole-body computerized tomography was performed, which showed diffusely increased tracer uptake at the right ventricle and interventricular septum. In addition, there were multiple hypermetabolic lymph nodes at the bilateral hilar, interlobar, subcarinal, bilateral paratracheal, and bilateral supraclavicular regions, together with multiple focal hypermetabolic splenic lesions. Excisional biopsy of the right supraclavicular lymph node was performed, with histologic examination showing multiple discrete non-necrotizing granulomas composed of epithelioid cells with scattered multinucleated giant cells, Schaumann bodies, asteroid bodies, and birefringent crystals.

Ziehl–Neelsen stains did not reveal any acid-fast bacilli, and periodic acid–Schiff stain did not reveal any fungal organisms. Subsequent tissue cultures were also negative. The overall features were compatible with sarcoid granulomatous inflammation. The diagnosis of sarcoidosis with cardiac involvement was established. The patient was started on high-dose systemic steroid therapy together with guideline-recommended heart failure treatment, including an angiotensin-converting enzyme inhibitor and a beta-blocker. Given the deterioration of left ventricular function and the documented ventricular tachyarrhythmia, the dual-chamber pacemaker was upgraded to cardiac resynchronization therapy with defibrillator 3 months after the initial presentation. Repeat PET 2 months after the initiation of steroid therapy showed virtually complete resolution of previous hypermetabolic lesions in the heart, spleen, and lymph nodes (Figure 1). Steroid therapy was then gradually tapered with the introduction of methotrexate. Repeated echocardiography during biventricular pacing showed normalized LVEF. Nonetheless, there were altogether 20 episodes of ventricular tachyarrhythmia requiring either antitachycardia pacing or defibrillation in the subsequent 2-year follow-up, despite a reduction of ventricular pacing percentage from 100% to 85%.



## Discussion

Patients with cardiac sarcoidosis often present with advanced AV conduction block necessitating permanent pacing, owing to the involvement of the basal septum by scar tissues, granulomas, or AV nodal artery involvement. Unlike other causes of AV block, patients with cardiac sarcoidosis are at a high risk of sudden arrhythmic death. As a result, implantation of an implantable cardioverter-defibrillator is considered beneficial in patients with cardiac sarcoidosis who have an indication for permanent pacing in the 2017 AHA/ACC/HRS Guideline for Management of Patients With Ventricular Arrhythmias and the Prevention of Sudden Cardiac Death.<sup>2</sup> Thus, it is important to confirm or exclude the diagnosis of cardiac sarcoidosis in patients with advanced AV block prior to cardiovascular implantable electronic device implantation. In fact, it has been recommended for patients younger than 60 years with unexplained Mobitz II or complete AV conduction block to undergo advanced cardiac imaging such as CMR and/or <sup>18</sup>F-FDG PET to ascertain possible cardiac sarcoidosis.<sup>3</sup>

Over the past decades, CMR has been increasingly used as the initial imaging modality of choice for patients with suspected cardiac sarcoidosis because of the reported high sensitivity to detect cardiac involvement in patients with extracardiac sarcoidosis and the ability to provide additional anatomical and functional information with no exposure to radiation. In a study involving 80 patients with chronic sarcoidosis with suspected cardiac involvement,<sup>4</sup> CMR has higher sensitivity (85% vs 28%) and comparable specificity (100% vs 100%) in detecting cardiac sarcoidosis compared with <sup>18</sup>F-FDG PET. Nonetheless, it is important to note that in this study, all patients had chronic extracardiac sarcoidosis, and none of them had advanced AV conduction block at the time of imaging.<sup>4</sup> In stark contrast, in another study involving patients with new-onset second-degree Mobitz type II or third-degree AV block and histologically confirmed sarcoidosis,<sup>5</sup> 92% of patients were positive on <sup>18</sup>F-FDG PET, but only 67% were positive on CMR. More importantly, for patients with onset of symptoms related to AV block less than 30 days, only 43% were positive on CMR, whereas 86% were positive on <sup>18</sup>F-FDG PET. On the other hand, both CMR and <sup>18</sup>F-FDG PET were positive to detect cardiac involvement in those with onset of symptoms more than 30 days.<sup>5</sup> Plausibly, CMR primarily detects fibrotic changes in nonviable myocardium, which may be less sensitive to detect early inflammatory changes at the

early phase of cardiac sarcoidosis, which may more likely be detected with <sup>18</sup>F-FDG PET. As in the present case, CMR performed 5 days after initial presentation failed to detect underlying myocardial pathology and misled the diagnosis. In fact, in a recent study evaluating patients presenting with symptomatic frequent premature ventricular complex using CMR and <sup>18</sup>F-FDG PET, only a minority of patients with <sup>18</sup>F-FDG PET–documented myocardial inflammation had CMR evidence of myocardial disease including regional wall motion abnormality and late gadolinium enhancement.<sup>6</sup> Given the likelihood of patients with cardiac sarcoidosis to develop life-threatening ventricular arrhythmias, particularly those with AV conduction block,<sup>7</sup> a prompt and accurate diagnosis or exclusion of cardiac sarcoidosis is instrumental to the decision of implantable cardioverter-defibrillator implantation.

## Conclusion

We reported a clinical case of cardiac sarcoidosis presenting with advanced AV block, in which CMR failed to detect the underlying myocardial pathology. The choice of initial imaging modality for patients with suspected cardiac sarcoidosis should take into account the timing and clinical cardiac manifestations.

## References

1. Silverman KJ, Hutchins GM, Bulkley BH. Cardiac sarcoid: a clinicopathologic study of 84 unselected patients with systemic sarcoidosis. *Circulation* 1978; 58:1204–1211.
2. Al-Khatib SM, Stevenson WG, Ackerman MJ, et al. 2017 AHA/ACC/HRS Guideline for Management of Patients With Ventricular Arrhythmias and the Prevention of Sudden Cardiac Death: A Report of the American College of Cardiology/American Heart Association Task Force on Clinical Practice Guidelines and the Heart Rhythm Society. *Heart Rhythm* 2018;15:e190–e252.
3. Birnie DH, Sauer WH, Bogun F, et al. HRS expert consensus statement on the diagnosis and management of arrhythmias associated with cardiac sarcoidosis. *Heart Rhythm* 2014;11:1305–1323.
4. Sgard B, Brillet PY, Bouvry D, et al. Evaluation of FDG PET combined with cardiac MRI for the diagnosis and therapeutic monitoring of cardiac sarcoidosis. *Clin Radiol* 2019;74:81.e9–81.e18.
5. Ohira H, Birnie DH, Pena E, et al. Comparison of (18)F-fluorodeoxyglucose positron emission tomography (FDG PET) and cardiac magnetic resonance (CMR) in corticosteroid-naïve patients with conduction system disease due to cardiac sarcoidosis. *Eur J Nucl Med Mol Imaging* 2016;43:259–269.
6. Lakkireddy D, Turagam MK, Yarlagadda B, et al. Myocarditis causing premature ventricular contractions: Insights from the MAVERIC Registry. *Circ Arrhythm Electrophysiol* 2019;12:e007520.
7. Halawa A, Jain R, Turagam MK, Kusumoto FM, Woldu HG, Gautam S. Outcome of implantable cardioverter defibrillator in cardiac sarcoidosis: a systematic review and meta-analysis. *J Interv Card Electrophysiol* 2020; 58:233–242.