

# Insertion of inflatable penile prosthesis in the neophallus of assigned female at birth individuals: a systematic review of surgical techniques, complications and outcomes

Karl H. Pang , Nim Christopher, David J. Ralph and Wai Gin Lee

**Abstract:** Devices such as inflatable penile prostheses (IPP) can be used to achieve erectile rigidity after phalloplasty in assigned female at birth (AFAB) individuals. The approach to inserting an IPP in a neophallus is different and more challenging compared to that of an anatomical penis due to the absence of anatomical structures such as the corpora cavernosa, and the more tenuous blood supply of the neophallus and reconstructed urethra. In addition, the ideal surgical techniques and devices for use in the neophallus have not been defined. This review systematically summarises the literature on the insertion of IPP in the neophallus of individuals AFAB. In particular, the described techniques, types of devices used and peri-operative and patient-reported outcomes are emphasised. An initial search of the PubMed database was performed on 16 September 2022 and an updated search was performed on 26 May 2023. Overall, 185 articles were screened for eligibility and 15 studies fulfilled the inclusion criteria and were included in the analysis. Two studies reported outcomes on the zephyr surgical implant 475 FTM device and the others reported outcomes on the Boston Scientific AMS 600/700™ CX 3-piece inflatable, AMS Ambicor™ 2-piece inflatable, Coloplast Titan® or Dynaflex devices. Overall, 1106 IPPs were analysed. The infection rate was 4.2%–50%, with most studies reporting an infection rate of <30%. Mechanical failure or dysfunction occurred in 1.4%–36.4%, explantation was required in 3.3%–41.6%, and implant revision or replacement was performed in 6%–70%. Overall, 51.4%–90.6% of patients were satisfied and 77%–100% were engaging in sexual intercourse. An IPP in a neophallus is an acceptable option to achieve rigidity for sexual intercourse. However, this challenging procedure has good reports of patient and partner satisfaction despite significant risks of complications.

**Keywords:** gender affirmation surgery, inflatable penile prosthesis, neophallus, phalloplasty

Received: 6 March 2023; revised manuscript accepted: 18 August 2023.

## Introduction

A mismatch between birth-assigned sex and one's gender identity may result in gender incongruence. Gender incongruence is associated with rates of self-harm and suicide attempts at least 10-fold higher than the general population.<sup>1</sup> Some patients choose to physically transition to the gender they identify with using a combination of hormonal therapy with or without reconstructive surgery. Gender affirmation surgery (GAS)

for transgender and non-binary (TGNB) individuals aims to more closely align the physical body with the individual's gender identity. An exponential increase in the demand and provision of GAS has been widely reported but much remains unknown about the optimal techniques.

The aim of masculinising genital GAS is to construct a neophallus (with or without urethra) and scrotum with a male-appearing perineum.<sup>1,2</sup> The

*Ther Adv Urol*

2023, Vol. 15: 1–13

DOI: 10.1177/  
17562872231199584

© The Author(s), 2023.  
Article reuse guidelines:  
sagepub.com/journals-  
permissions

Correspondence to:

**Wai Gin Lee**  
Department of Urology,  
University College London  
Hospitals NHS Foundation  
Trust, 235 Euston Road,  
London NW1 2PG, UK  
[waign.lee@andrology.co.uk](mailto:waign.lee@andrology.co.uk)

**Karl H. Pang**  
Department of Urology,  
University College London  
Hospitals NHS Foundation  
Trust, 235 Euston Road,  
London NW1 2PG, UK

Division of Surgery and  
Interventional Sciences,  
University College London,  
London, UK

Division of Urology,  
Department of Surgery,  
School of Clinical  
Medicine, The University  
of Hong Kong, Hong Kong  
Division of Urology, Queen  
Mary Hospital, Hong Kong

**Nim Christopher**  
**David J. Ralph**  
**Wai Gin Lee**  
Department of Urology,  
University College London  
Hospitals NHS Foundation  
Trust, 235 Euston Road,  
London NW1 2PG, UK  
St. Peter's Andrology  
Centre, London, UK

**Correction (September 2023):** Article has been updated to correct article type.

female reproductive organs can be removed but not every individual will want, require or qualify for every surgical option that may be available. The flaps used in phalloplasty often do not provide full rigidity as they do not contain native erectile tissue. Therefore, rigidity of the neophallus is achieved by inserting an erectile device. Surgical reconstruction is usually staged, with an ideal end result that is aesthetically satisfying, sensate, and allows both micturition whilst standing and penetrative sexual intercourse, if desired.<sup>1</sup>

A study demonstrated that out of 1056 individuals who had a phalloplasty, 792 (75%) received a penile prosthesis.<sup>3</sup> Whilst there are malleable (also known as semi-rigid) and inflatable penile prostheses (IPP), the inflatable devices provide a more natural and concealable appearance.<sup>4</sup> They are the most common type of device chosen for implantation in the neophallus. The approach for inserting an IPP following GAS and phalloplasty is different and invariably more complex than implanting an erectile device in an anatomical penis.<sup>5</sup> The aim of this systematic review is to summarise the current practice for insertion of an IPP into a neophallus following GAS in individuals assigned female at birth (AFAB) with emphasis on the described techniques, types of devices used as well as peri-operative and patient-reported outcomes.

## Methods

### *Search strategy and study eligibility*

The PubMed database was searched on 16 September 2022, using the search terms: (Phalloplasty OR neophallus OR gender reassignment surgery OR gender affirming surgery OR AFAB OR gender dysphoria OR transgender male) AND (penile prosthe\* OR penile implant). All articles published up until 16 September 2022 were screened for eligibility. An updated search was performed on 26 May 2023.

A population (P), intervention (I), comparator (C), outcome (O), study design (S) (PICOS) framework defined the study eligibility. Studies were included if they fulfilled, (P): AFAB, adult ( $\geq 18$  years old) patient with a neophallus who underwent an IPP insertion; (I): any types of IPP; (C) any types of neophallus construction, or any types of IPP; (O) peri- and post-operative outcomes, including revision rates and patient-reported outcomes; (S) any forms of study design

including randomised and non-randomised studies. Only studies or case series involving five or more patients were included.

Case reports, conference abstracts, reviews, letters, commentaries and editorials were excluded as were non-English articles and studies with sample size less than five patients. Individuals for malleable or semi-rigid penile prosthesis insertion or where they were assigned male at birth were also excluded.

The titles and abstracts identified from the search were screened. The full-text articles as well as the reference lists of articles that met the inclusion criteria were reviewed and further screened for eligibility, or other articles that may be suitable for inclusion.

### *Data extraction and analysis*

Data extracted included the number of patients, age, types of grafts and flaps used for phalloplasty, types of IPP and number of cylinders, peri- and post-operative complications, follow-up duration, revision rates, and patient-reported outcomes. As no randomised controlled trial was included in this review, we focused on a narrative synthesis. Continuous variables were described by the number of cases ( $n$ ), mean and range or median and interquartile range (IQR), if available. Heterogeneity of reported data between studies meant that only ranges were able to be presented in the data synthesis.

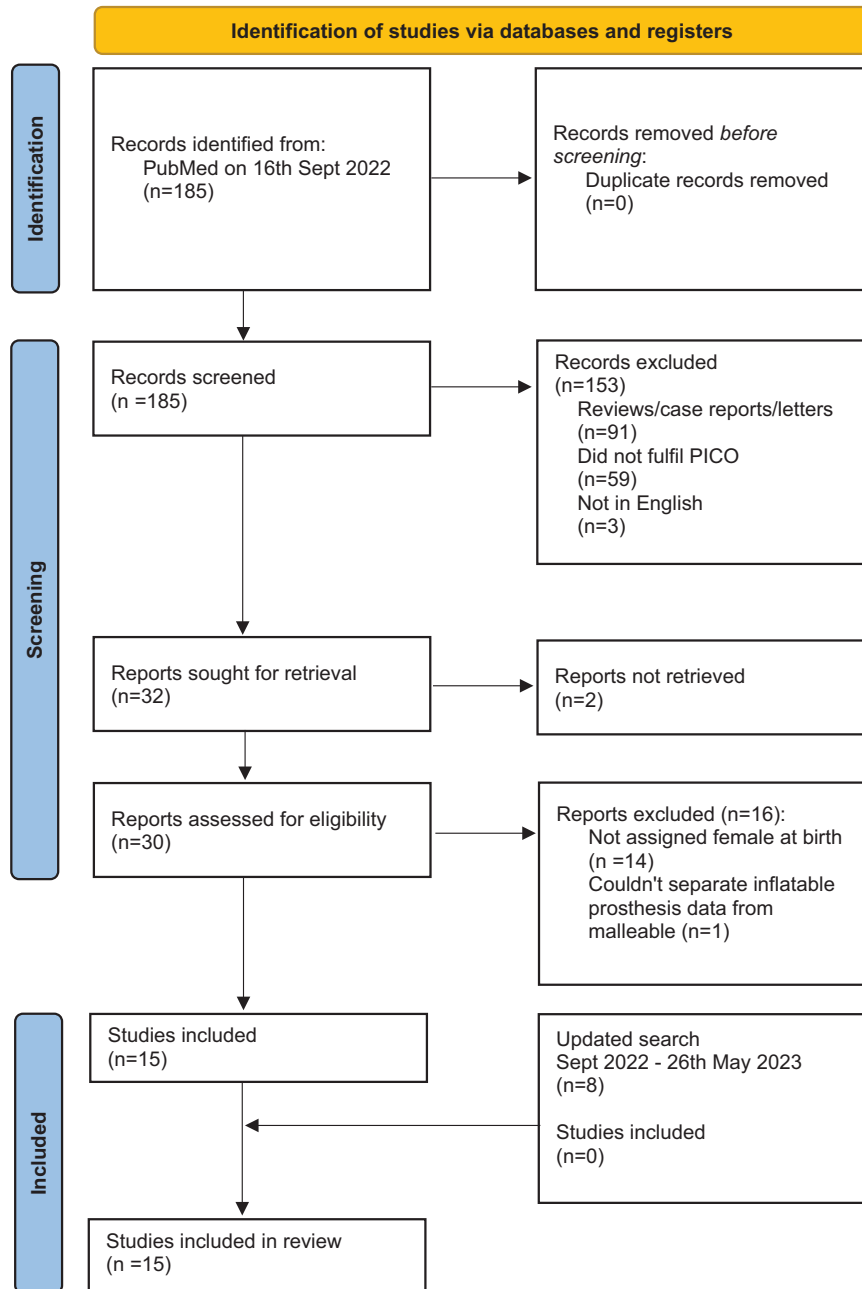
## Results

### *Quantity of evidence identified*

One hundred and eighty-five articles were identified using the search strategy above, and 15 studies<sup>6–20</sup> were included for analysis following abstract and full-text screening (Figure 1). Fourteen studies were retrospective and one study was prospective in nature.<sup>11</sup> A total of 1106 IPPs were included in the analysis.

### *Characteristics of the studies included*

Baseline characteristics of the patients including age, number of AFAB individuals who underwent phalloplasty and penile implant insertion, type of phalloplasty reconstruction, type of IPP used, time to prosthesis insertion and insertion approach are presented in Table 1. The cohort size of



**Figure 1.** PRISMA 2020 flow chart for the current systematic review.

AFAB individuals ranged between 5 and 306, the mean age was 24–41.7 years, and the mean follow-up was 8.9–115 months. The most used flap for phalloplasty was the radial artery forearm free flap (RFFF), with only one study reporting the insertion of IPP following musculocutaneous latissimus dorsi free flap phalloplasty.<sup>13</sup> Five studies<sup>6,7,12,13,17</sup> reported outcomes on both IPP and malleable implants so only data relevant to IPP insertion were extracted and synthesised.

#### *Prosthesis type*

A total of 1106 IPPs (Table 1) were included in the analysis. The models of device spanned the breadth of devices used in cisgender men, but the majority were Boston Scientific AMS 600/700™ or Ambicor™, and Coloplast Titan® in more contemporary studies. In earlier studies, the Dynaflex implants were described, but these implants are no longer in use. Neville *et al.*<sup>14</sup> were the first to publish the outcomes of the ZSI

**Table 1.** Baseline characteristic of the 14 retrospective studies included in the current systematic review.

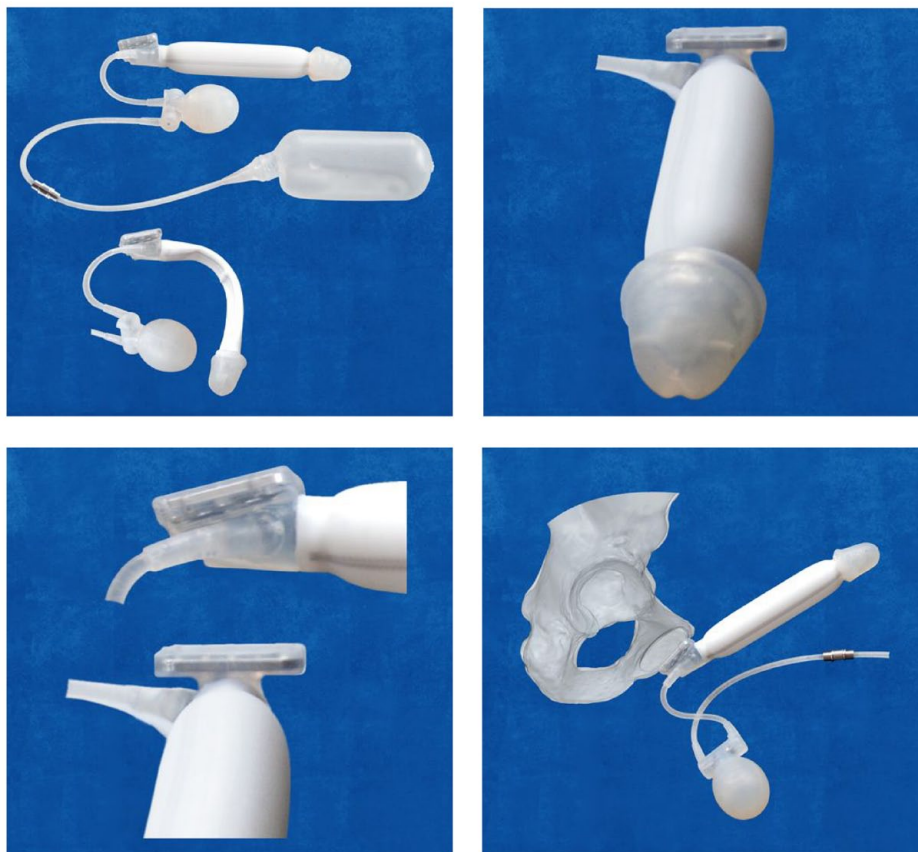Author	Year	Country	Phalloplasty (n)	AFAB (n, %)	PP (n, %)	IPP (n, %)	Age (y), mean (range)	Type of phalloplasty reconstruction	Type IPP	Time to PP (m), mean (range)	Insertion approach	Cylinder (n)	Device anchor	Reservoir	Scrub	Antibiotics	LOS (d)	Postop care	FU (m), mean (range)
Briles BL*	2022	USA	80	80	80	67 (83.7)	34 (16–64)	NR	Coloplast Titan, single cylinder; 67 (83.7)	15 (6–18)	Infrapubic; synthetic vascular grafts for malleable	1	Titanium sutures	Sub-rectus space, 60–80 cc	Povidone and/or iodine	Vancomycin and gentamicin	NR	NR	26.5 (10.3–44.2)
Chen ML*	2021	USA	107	107	107	73 (68.2)	NR	NR	Boston AMS 700/Ambicor; Coloplast Titan; ZSI 475	9–12	Infrapubic; public anchoring; dacron graft for malleable	1	Non-absorbable sutures	Space of Retzius, 75 cc	NR	Cephalosporin and gentamicin	Discharged same day	7 d antibiotics, IPP activation at 6 w	20
Verla W	2021	Belgium	57	50 (87.7)	50	50 (100)	Median, 40 (IQR, 30–48)	RFFF; 38 (76); ALT: 10 (20); other: 2 (4)	ZSI 475 FM	Median, 70 (IQR, 25–142)	Parascrotal incision	1	Non-absorbable sutures	Space of Retzius, 65 mL	10 min with alcohol-based iodine	Cefazolin	Median (IQR), 1 (1–2)	5 d co-amoxiclav or erythromycin/clindamycin, IPP activation at 6 w	Median, 15 (IQR, 10–21)
Djordjevic ML*	2019	Serbia	129	129	61	22 (36.1)	24 (20–53)	Musculocutaneous latissimus dorsi free flap	Boston AMS 700 LGX; Coloplast Titan	NR	Infrapubic and/or penoscrotal; public anchoring	NR	NR	Retro-vesically	NR	NR	NR	NR	43 (13–137)
van der Sluis	2019	Netherlands	32	32	45	22 (48.9)	22 (4.8–9)	RFFF; 22 (68.8); ALT: 5 (15.6); RFFF + ALT: 4 (12.5); fibula: 1 (3.1)	Boston AMS Dymatek; 18 (81.8); AMS Ambicor; 4 (18.2)	Median, 28 (12–228)	Parascrotal incision or dorsal phallus	1–2	Non-absorbable sutures (Prolene)	N/A	Chlorhexidine and povidone-iodine	Cephalosporin	NR	NR	155 (18–287)
Newville P	2019	France	20	20	20	21 (100)	37.9 (26–50)	RFFF; 15 (75); suprapubic; 1 (5); pedicled inguinal flap: 1 (5)	ZSI 475 FM	>6	Neoscrotal; public anchoring	1	Non-absorbable sutures	Pre-peritoneal space	2 × 5-min	NR	Mean (SD), 2.6 (0.5)	5 d co-amoxiclav, IPP activation at 6 w	8.9 (SD, 4.0)
Falcone M	2018	UK	247	247	328	328 (100)	38 (21–69)	RFFF; 157 (63.6); infra-umbilical public flap; 90 (36.4)	Boston AMS 700 CX; 226 (68.9); AMS 700 CXM/R; 31 (9.5); Ambicor; 13 (4.0); Coloplast Titan; 58 (17.7); Single cylinder; 208 (63.4); 2-cylinder; 120 (36.6)	12 (12–37)	Infrapubic via groin incision; public anchoring; Dacron graft	1–2	Non-absorbable sutures (Ethibond)	NR	10 min with povidone-iodine	Co-amoxiclav and gentamicin	1	5 days co-amoxiclav, IPP activation at 3 weeks	20
Cohen AJ	2017	USA	10	8 (80)	10	10 (100)	41.7 (IQR, 39.1–45.4)	RFFF; 10 (100)	Boston LGX; 5 (50); CX; 5 (50)	Median, 7 m (IQR, 5–7)	Infrapubic; public anchoring; GOR-TEX strip	1, n=9; 2, n=1	Non-absorbable sutures (Prolene or Ti-Cron)	Separate right lower quadrant sub-rectus space	NR	NR	Median (IQR), 1.3 (1–4)	NR	49

(Continued)

Table 1. (Continued)

Author	Year	Country	Phalloplasty (n)	AFAB (n, %)	PP (n, %)	IPP (n, %)	Age (y), mean (range)	Type of phalloplasty reconstruction	Type IPP	Time to PP (m), mean (range)	Insertion approach	Cylinder (n)	Device anchor	Reservoir	Scrub	Antibiotics	LOS (d)	Postop care	FU (m), mean (range)
Neville P*	2016	France	69	62 (89.9)	95	94 (98.9)	40 (20–67)	RFFF: 40 (59.7); suprapubic: 23 (34.2); inguinal flap: 3 (4.3); femoral flap: 1 (1.5); missing: 2 (2.9)	AMS Ambicor: 90 (94.7); AMS 700 CX: 1 (1.1); AMS 700 CXR: 3 (3.2)	Median, 19 (8–84)	Neoscrotal; pubic anchoring; vascular graft	1, n=65; 2, n=4	Non-absorbable sutures	NR	2 × 5-min	Cefazolin	Mean (SD), 3.7 (1)	No postop antibiotics, IPP activation at 6 weeks	48 (3–96)
Garcia MM	2014	UK	25	25	11	11	Mean, 34–39.2	RFFF: 15 (60); suprapubic pedicle flap: 10 (40)	NR	NR	NR	NR	NR	NR	NR	NR	NR	NR	Mean, 26–82
Doornaert M	2011	Belgium	316	306 (96.8)	143	143	NR	RFFF: 316 (100)	AMS CX: 71 (49.7); Ambicor: 57 (39.9); AMS Dynaflax: 9 (6.3); Mentor: 6 (4.2)	12	NR	NR	NR	NR	NR	NR	NR	NR	21.1
Hoebeke P	2010	Belgium	129	129	185	185	31.9 (17–53)	RFFF: 129 (100)	AMS CX/CXM: 69 (37.3); Ambicor: 59 (31.9); CX Inhibizone 34 (18.4); Dynaflax: 15 (8.1); Coloplast/ Mentor: 8 (4.3)	23 (9–127)	Parascrotal incision	1, n=127; 2, n=98	Non-absorbable sutures	Paravesical space through paras-crotal incision	5 min with iso-betadine	Cefazolin	NR	Cefazolin 1 day	30.2 (0–132)
Leriche A	2008	France	56	56	38	38	NR	RFFF: 56 (100)	AMS 600/700s; Ambicor	3–9	Basal lateral incision of the phalloplasty	NR	NR	NR	NR	NR	NR	NR	110 (11–204)
Hoebeke P	2003	Belgium	35	35	35	35	NR	RFFF: 35 (100)	Dynaflax: 10 (28.6); AMS CXM: 9 (25.7); AMS CX: 16 (45.7)	>12	Neoscrotal	1–2	Non-absorbable sutures	NR	NR	Cefazolin	4 days bed rest	Ciproxine 5 days, IPP activation at 6 weeks	22
Hage JJ	1997	Nether-lands	5	5	7	7	34 (24–46)	RFFF: 5 (100)	Dynaflax: 5 (100)	22–36	Infrapubic or neoscrotal; dacron graft	1	Non-absorbable sutures (Merstene)	N/A	NR	Cefotaxim and metronidazole	NR	Cefotaxim and metronidazole 5 days	14 (5–21)

\*Studies reporting on both inflatable and malleable penile implants.  
AFAB, assigned female and birth; ALT, anterolateral thigh; FU, follow-up; IPP, inflatable penile prosthesis; LOS, length of stay; PP, penile prosthesis; RFFF, radial forearm free flap; ZS, zephyr surgical implant.



**Figure 2.** ZSI 475 FTM penile prosthesis.

Source: Images obtained from Zephyr Surgical Implants (ZSIs) website: <https://www.zsimplants.ch/en/products-en/phalloplasty/zsi-475-ftm-inflatable-penile-implant/zsi-475-ftm-information>

475 implant (Zephyr Surgical Implants, Geneva, Switzerland) in 20 patients (Figure 2). These are novel inflatable devices that have been specifically designed for the neophallus of individuals AFAB.

Eleven studies reported on the number of cylinders used. Five studies used 1 cylinder only<sup>6,7,10,11,14</sup> and six studies used 1 or 2 cylinders.<sup>9,12,14–16,20</sup>

#### *Surgical technique*

*Preoperative.* The time from neophallus construction to implant insertion is at least 6 months in most studies to allow sensory nerves to regenerate and the urethra to completely heal. Falcone *et al.*<sup>15</sup> recommended that IPP insertion is delayed for at least a year to allow optimal cutaneous sensation of the phallus to develop. All urethral complications were corrected prior to IPP insertion.

With regards to anti-septic scrubbing of the operative field, four studies used povidone-iodine<sup>6,11,15,20</sup> and one study used chlorhexidine and povidone-iodine.<sup>12</sup> In the two studies by Neuville *et al.*,<sup>17</sup> 2 min × 5 min scrubs were performed, but the agent was not mentioned. Nine studies commented on antibiotic prophylaxis where a cephalosporin was the most common antibiotic used on induction.<sup>7,9–12,20</sup> Alternative antibiotics used included gentamicin,<sup>6,7,15</sup> co-amoxiclav,<sup>15</sup> vancomycin<sup>6</sup> and metronidazole<sup>10</sup> (Table 1).

*Intraoperative.* Two studies provided data on neophallus measurements. Djordjevic *et al.*<sup>13</sup> used musculocutaneous latissimus dorsi free flaps and the mean (range) length and girth was 14.6 cm (12–21) and 2.4 cm (12–15). Garcia *et al.*<sup>18</sup> used RFFF and suprapubic pedicle flaps. The RFFF neophallus mean (range) length was 11.95 cm

and girth was 11.7 cm (8.25–14). The suprapubic flap neophallus length was 13.3 cm (11.75–16) and girth was 13.4 cm (13–16).<sup>18</sup>

The IPP insertion approach was commonly infrapubic or parascrotal based on the reporting centre's preference (Table 1). Four studies used the infrapubic approach,<sup>6,7,15,16</sup> five studies used the parascrotal approach<sup>9,11,14,17,20</sup> and two studies used both approaches.<sup>10,13</sup>

Due to the absence of the corpus cavernosa in the neophallus, the rear tips of the IPPs are usually anchored to the pubic bone to prevent migration (Table 1). Some studies use additional grafts such as polyethylene terephthalate (Dacron<sup>TM</sup>)<sup>7,10</sup> or other autologous tissue or acellular matrix<sup>6</sup> to help anchor the implant to the pubis. The material can be fashioned into a sock, cap and sock or a full sheath around each cylinder.

Cohen *et al.*<sup>16</sup> described a novel technique for proximal bone anchoring using a GORE-TEX strip (Gore & Associates Inc, Flagstaff, AZ, USA). They hypothesised that this may strengthen the anchoring. In their cohort of 10 patients at a mean follow-up of 49 months, 7 (70%) patients required a device revision, three of which had inadequate fixation. The authors concluded that their fixation technique was feasible despite a high revision rate but cautioned that the technique was not used in enough patients to draw adequate conclusions on the potential effects on device longevity.

*Reservoir insertion.* Reservoir placement was reported in seven studies (Table 1). All reservoirs were placed extraperitoneal in the retropubic space.<sup>6,7,11,13,14,16,20</sup> Specifically, Briles *et al.*<sup>6</sup> added 60–80 cc saline to the reservoir, Chen *et al.*<sup>7</sup> added 75 cc, and Verla *et al.*<sup>11</sup> added 65 mL. The group from London, United Kingdom referenced a previous publication describing open reservoir placement by counter-incision into the retroperitoneum.<sup>21</sup>

*Post-operative care.* Most studies discharged patients with oral antibiotics for 5–7 days and recommended IPP activation at 6 weeks (Table 1). One study advised IPP activation at 3 weeks.<sup>15</sup>

### Complications

The complications following IPP insertion are summarised in Table 2. Several studies combined both IPP and malleable devices in their analysis.

Where possible, only data relating to IPPs were synthesised. The infection rate was 4.2–50%,<sup>16,17</sup> with most studies (80%) reporting an infection rate of <30%. Mechanical failure occurred in 1.4–36.4% of cases,<sup>7,12</sup> explantation was required in 3.3–41.6%,<sup>13,20</sup> and the device was revised or replaced in 6–70% of cases.<sup>11,16</sup>

Reported data for the ZSI 475 FTM penile implants were more limited. (Tables 1 and 2). Nine out of 20 men (45%) had a primary ZSI 475 FTM device and 11 (55%) had an exchange from a 2-piece IPP (AMS Ambicor; Boston Scientific, Marlborough, MA, USA) due to mechanical failure ( $n=5$ ), malpositioning ( $n=3$ ) and infection ( $n=3$ ). At a follow-up of 8.9 months ( $\pm$ SD 4.0), revision was necessary in 4 (19%) patients due to infection, 2 for mechanical failure (fluid leak and 'activation defect' respectively), and 1 for poor positioning with 16 men still with functioning devices.<sup>14</sup> Subsequently, Verla *et al.*<sup>11</sup> reported a prospective series of 50 ZSI 475 penile implants in AFAB individuals. Explantation occurred in 13 (26%) and revision was required in 3 (6%) cases due to malpositioning.

We previously reported the outcomes of IPP insertion in 247 AFAB patients, and this remains the largest cohort in the literature.<sup>15</sup> IPPs were inserted parascrotal through a groin incision at a mean duration of 12 months following phalloplasty. At a mean follow-up of 20 months, complications included infection (8.5%), mechanical failure (15.4%), explantation for dissatisfaction (19.4%) with an overall revision rate of 43.3%. All patients were able to cycle their device, 77% were engaging in penetrative sexual intercourse and 88% were satisfied with the cosmetic and functional outcomes.<sup>15</sup>

### Patient and partner satisfaction

Details regarding patient satisfaction and functional outcomes (Table 2) were reported in six studies.<sup>8,9,13–15,18</sup> Overall, 51.4–90.6% of patients were satisfied and 77–100% were engaging in penetrative sexual intercourse. Falcone *et al.*<sup>15</sup> reported a partner satisfaction rate of 60%. Neuville *et al.*,<sup>14</sup> used validated questionnaires to assess patient outcomes although the questionnaires had not been validated in TGNB individuals (Table 2). The mean international index of erectile function-5 (IIEF-5) score was 20.2/25 (SD, 7.9); self-esteem and relationship score (SEAR) was 84.5/100 (SD, 9.9); erectile

**Table 2.** Complications and patient-reported outcomes.

Author	Year	Total complication n (%)	Infection (%)	Infection n	Mechanical failure/dysfunction n (%)	Malposition n (%)	Erosion n (%)	Detachment from anchor site n (%)	Explantation n (%)	Revision/replacement n (%)	Other	Patient-reported outcomes n (%)
Briles BL*	2022	IPP: 24 (35.8)	IPP: 15/67 (22.4)	NR	NR	NR	NR	NR	NR	NR	NR	NR
Chen ML*	2021	NR	NR	Leak: 1/73 (1.4)	NR	NR	NR	NR	NR	9/73 (12.3)	NR	NR
Verta W	2021	18 (36)	8 (16)	4 (8)	4 (8)	1 (2) protrusion	1 (2)	1 (2)	13 (26)	3 (6)	Urinary retention: 1 (2)	NR
Djordjevic ML*	2019	NR	NR	2/22 (9.1)	NR	NR	NR	NR	2/61 (3.3)	2 (9.1)	Sex with complete penetration feasible: 22 (100)	Sex with complete penetration feasible: 22 (100)
van der Sluis*	2019	IPP: 13/22 (59.1)	5 (22.7)	8 (36.4)	NR	NR	2 (9.1)	1 (4.5)	7 (31.8)	9 (40.1)		
Neuville P	2019	6/21 (28.6)	3/21 (14.3)	2/21 (9.5)	1/21 (4.8)	NR	NR	NR	4/21 (19.1)	4/21 (19.1)		n = 14. IIEF-5 mean: 20.2 (SD, 7.9); SEAR mean: 84.5 (SD, 9.9); EDITS mean: 82 (SD, 17.5); regular penetrative intercourse: 12 (85.7)
Falcone M	2018	107 (43.3)	21/247 (8.5)	38/247 (15.4)	Dissatisfied: 48/247 (19.4) (reposition or insertion of second cylinder)	NR	NR	NR	21/247 (8.5)	107/247 (43.3)		n = 104. Able to cycle device: all; engaging in penetrative sex: 97 (77); achieved orgasm: 77 (61); satisfied with cosmetic and functional outcome: 97 (88); partner satisfaction: 60%
Cohen AJ	2017	7 (70)	5 (50)	2 (20)	NR	NR	NR	3 (30) inadequate fixation	NR	7 (70)		NR
Neuville P*	2016	30/95 (31.6)	4 (4.2)	10 (10.5)	12 (12.6)	4 (4.2)	NR	NR	5/69 (7.3)	21/69 (30.4)		NR

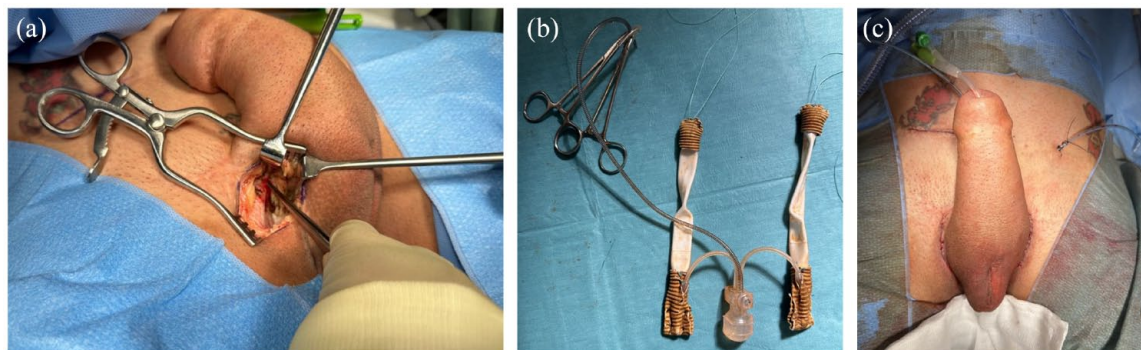
(Continued)



Table 2. (Continued)

Author	Year	Total complication <i>n</i> (%)	Infection (%)	Mechanical failure/ dysfunction <i>n</i> (%)	Malposition <i>n</i> (%)	Erosion <i>n</i> (%)	Detachment from anchor site <i>n</i> (%)	Explantation <i>n</i> (%)	Revision/ replacement <i>n</i> (%)	Other	Patient-reported outcomes <i>n</i> (%)
Garcia MM	2014	NR	NR	1/11 (9.1)	NR	NR	NR	1 (9.1)	NR	NR	No diminished ability to achieve orgasm after PP: 11 (100)
Doornaert M	2011	59/143 (41.3)	19/143 (13.3) infection OR erosion	40/143 (28.0)	NR	19 (13.3) infection OR erosion	NR	59/143 (41.3) revision or explantation	59/143 (41.3) revision or explantation	NR	NR
Hoebeke PB	2010	NR	22/185 (11.9)	41/185 (22.2)	27/185 (14.6)	15/185 (8.1) protrusion	NR	77/185 (41.6)	53/129 (41.1)	3/185 (1.6)	NR
Leriche A	2008	11/38 (28.9)	11/38 (28.9) mechanical or infection	11/38 (28.9) mechanical or infection	NR	NR	NR	3/38 (7.9)	11/38 (28.9)	NR	<i>n</i> = 35. Satisfactory sexual intercourse with penetration: 18 [51.4]
Hoebeke P	2003	7/35 (20)	3 (8.6)	3 (8.6)	NR	1 (2.9)	NR	7 (20)	4/25 (11.4)	<i>n</i> = 2 waiting list for replacement	<i>n</i> = 32. Sexually active and satisfied: 29 [90.6]
Hage JJ	1997	4/5 (80)	2/5 (40)	NR	NR	NR	1/5 (20)	2/5 (40)	2/5 (40) replacement	<i>n</i> = 1 waiting list for replacement	NR

\*Studies reporting on both inflatable and malleable penile implants. EDJTS, erectile dysfunction inventory of treatment satisfaction score; IIEF-5, international index of erectile function-5; IPP, inflatable penile prostheses; NR, not reported; SEAR, self-esteem and relationship score.



**Figure 3.** Intra-operative images of an inflatable penile prosthesis insertion into a neophallus. (a) A groin incision in the skin crease on the side of the eventual pump placement is made and deepened to the pubic bone. (b) A polyethylene terephthalate cap is used to cover the proximal and distal cylinder ends. (c) A contralateral incision in the groin is made for the testis insertion. A separate lower right abdominal is used for the reservoir placement. The urinary catheter is removed on post-operative day 1 and the implant is left semi-inflated for 1–2 weeks.

dysfunction inventory of treatment satisfaction (EDITS) score was 82/100 (SD,17.5). Overall, 92.8% were satisfied or very satisfied with the ZSI 475 FTM device, and 85.7% had regular penetrative sexual intercourse.

## Discussion

### Principal findings

Fifteen studies that fulfilled the inclusion criteria evaluating IPPs in AFAB patients were summarised. Some of these studies evaluated both IPPs and malleable implants. Dynaflex devices were used in earlier studies, but these have been discontinued. Contemporary studies have mostly adapted the 3-piece IPPs from Boston Scientific and Coloplast for use in the TGNB population. Recently, a single-cylinder penile implant (ZSI 475 FTM) specifically designed for the TGNB neophallus has been introduced with good short-term outcomes reported.<sup>11,14</sup> These devices have a large implantation base for pubic bone fixation, a realistically shaped glans, and a pump shaped like a testicle.<sup>14</sup> The infection and mechanical failure rates reported by the included studies were mostly under 30%. Contemporary devices are now coated with antibiotics *via* a hydrophilic coating or the Boston Scientific InhibiZone™ to reduce the risk of infection further.<sup>22</sup> Revision rates varied between 9.1% and 43.3%. These figures depend on the type of implants used, and the follow-up duration. Studies with short follow-up may not have captured long-term complications such as

mechanical failure, so revision/replacement rates may be under-reported in those studies.

### Senior authors' experience

Current practice at our centre is to insert an IPP at least 6 months after phalloplasty with urethral lengthening (if desired). This provides sufficient time for the urethra to completely heal and some cutaneous sensation to develop. The choice of IPP depends on patient preference following appropriate counselling. The Boston Scientific AMS 700™ CX or AMS Ambicor™, Coloplast Titan Touch® and Rigicon Infla10™ are all offered. The anatomy of the patients' neophallus and their preference usually dictate the number of cylinders used.

Peri-operative antibiotics used are intravenous gentamicin and co-amoxiclav. Skin preparation of the surgical field with alcoholic chlorhexidine (ChlorPrep™, Becton Dickinson, Franklin Lakes, NJ) is performed prior to surgery. A 14-Fr urethral catheter is inserted and a groin incision in the skin crease on the side of the eventual pump placement is made and deepened to the pubic bone [Figure 3(a)]. Three J-needle 1 polyester (Ethibond™) sutures are inserted into the pubic bone in two rows (as an inverted L) ~2 cm apart for each cylinder to anchor the prosthesis.<sup>23</sup>

Placing the anchoring sutures can be challenging especially if there is thick subcutaneous fat. Patients are encouraged to have a body mass

index of 30 (or below) to facilitate this. Three patients in the last 23 years in our group of patients (>700 new IPP insertions) suffered bone pain from Dacron sock anchorage without infection. It didn't resolve with pain management, so device was removed eventually and not replaced. One patient in the same time period had osteomyelitis of the pubic bone requiring drilling of the bone to release pus and extended antibiotics for around 5 weeks. He has since had another IPP without any problems.

Following anchorage, sequential dilatation of the neophallus is then performed with Hegar dilators up to size 18 to create space for the cylinder(s) and the polyethylene terephthalate (Silver-coated Dacron™) cap (see below). Care should be taken to avoid injury to the structures within the neophallus including the urethra, vascular pedicle and nerves. Knowledge of the original operation and access to the original operation note are most important. We don't do intra-operative doppler or other scanning as this is not practical. Careful dilation is the key. If using scissors to make the initial space, then one must not open and then close the scissors inside the phallus as that might divide vessels. Gentle dilation is the key and if the phallus is fibrotic, then we do not over dilate. We dilate to 18 mm diameter Hegar if using Dacron cap. However, if there's a fibrotic phallus, we stop at 12/13 mm diameter Hegar and we do not attempt to insert a Dacron cap. This also avoids urethral rupture. There is usually a space between the urethral portion of the flap and the phallus portion of the flap where it is relatively easy to dilate, that is, much less resistance.

Following dilatation, the neophallus length is measured from its tip to the pubis, and the size of cylinder is chosen accordingly. A Dacron-sock is fashioned to cover the proximal cylinder(s) and tubing for additional stability. A similar polyethylene terephthalate cap [Figure 3(b)] is fashioned to incorporate the distal end of the cylinder to prevent hypermobility and erosion. The cylinder(s) is placed as usual using a Furlow introducer and Keith needle. The Dacron sock is then anchored to the pubic bone using the pre-placed one polyester sutures. The pump of the device is placed within the neo-scrotum or the labia majora on the side preferred by the patient. The reservoir is placed in the retroperitoneum *via* a counter-incision similar to an appendicectomy (muscle-splitting) incision. The components are then connected and the wound closed in layers.<sup>15</sup>

The cylinder(s) is left semi-inflated for 1–2 weeks to maintain the position while a capsule forms [Figure 3(c)]. At the same time as the IPP placement, a testicular prosthesis is inserted into the contralateral side through a separate groin incision. The catheter is removed on post-operative day 1 and the patient is discharged on oral co-amoxiclav for 5 days. The patient is taught how to cycle the IPP and encouraged to cycle the device as soon as it is comfortable enough. They can commence sexual intercourse after 6 weeks.

In summary, the challenge of IPP placement in the neophallus for AFAB individuals derives from the lack of native anatomical structures to guide placement of the device. Most devices must be adapted for use in the TGNB population. The ZSI 475 FTM device holds promise but it is not FDA-approved and there is limited experience with the device for now.

#### *Limitations*

The reporting of complications and outcomes was not standardised. All studies did not use validated questionnaires to evaluate patient satisfaction because there are none available for the TGNB population. There was an evolution of techniques and the types of implants used in the included studies that covered a 25-year period between 1997 and 2022. In addition, the follow-up duration was not standardised and often quite short. Therefore, the aggregated rates of specific complications reported here do not correlate with specific techniques or type of implants used, and low rates of complications reported by studies may be associated with the limited follow-up. Going forward, a multi-institutional patient registry may provide standardised reporting of data for surgical outcomes and patient satisfaction in TGNB individuals. The registry should be complemented by patient-reported outcomes questionnaires validated for this cohort of patients.

#### **Conclusions**

IPP implantation in a neophallus constructed for TGNB individuals is commonly sought to achieve rigidity for sexual intercourse. However, this is a challenging procedure due to the lack of anatomical landmarks and tenuous blood supply of the neophallus and urethra. The operation is associated with significant risks of complication. Despite this, good patient and partner satisfaction are reported.

## Declarations

*Ethics approval and consent to participate*  
Not applicable.

*Consent for publication*  
Written consent for the use of images.

## Author contributions

**Karl H. Pang:** Conceptualization; Data curation; Formal analysis; Project administration; Writing – original draft; Writing – review & editing.

**Nim Christopher:** Supervision; Writing – review & editing.

**David J. Ralph:** Supervision; Writing – review & editing.

**Wai Gin Lee:** Conceptualization; Supervision; Writing – original draft; Writing – review & editing.

*Acknowledgements*  
None.

*Funding*  
The authors received no financial support for the research, authorship, and/or publication of this article.

*Competing interests*  
DJR, NC, and WGL are consultants for Coloplast, Boston Scientific. DJR also consultant for Rigicon.

*Availability of data and materials*  
Not applicable.

## ORCID iD

Karl H. Pang  <https://orcid.org/0000-0001-5703-2319>

## References

- Lee WG, Christopher N and Ralph DJ. Penile reconstruction and the role of surgery in gender dysphoria. *Eur Urol Focus* 2019; 5: 337–339.
- Hage JJ, Bout CA, Bloem JJ, *et al.* Phalloplasty in female-to-male transsexuals: what do our patients ask for? *Ann Plast Surg* 1993; 30: 323–326.
- Rooker SA, Vyas KS, DiFilippo EC, *et al.* The rise of the neophallus: a systematic review of penile prosthetic outcomes and complications in gender-affirming surgery. *J Sex Med* 2019; 16: 661–672.
- Mulcahy JJ. The development of modern penile implants. *Sex Med Rev* 2016; 4: 177–189.
- Blecher GA, Christopher N and Ralph DJ. Prosthetic placement after phalloplasty. *Urol Clin North Am* 2019; 46: 591–603.
- Briles BL, Middleton RY, Celtik KE, *et al.* Penile prosthesis placement by a dedicated transgender surgery unit: a retrospective analysis of complications. *J Sex Med* 2022; 19: 641–649.
- Chen ML, Patel DP, Moses RA, *et al.* Infrapubic insertion of penile implants in transmen after phalloplasty. *Urology* 2021; 152: 79–83.
- Lerliche A, Timsit MO, Morel-Journal N, *et al.* Long-term outcome of forearm free-flap phalloplasty in the treatment of transsexualism. *BJU Int* 2008; 101: 1297–1300.
- Hoebeker P, De Cuypere G, Ceulemans P, *et al.* Obtaining rigidity in total phalloplasty: experience with 35 patients. *J Urol* 2003; 169: 221–223.
- Hage JJ. Dynaflex prosthesis in total phalloplasty. *Plast Reconstr Surg* 1997; 99: 479–485.
- Verla W, Goedertier W, Lumen N, *et al.* Implantation of the ZSI 475 FTM erectile device after phalloplasty: a prospective analysis of surgical outcomes. *J Sex Med* 2021; 18: 615–622.
- van der Sluis WB, Pigot GLS, Al-Tamimi M, *et al.* A retrospective cohort study on surgical outcomes of penile prosthesis implantation surgery in transgender men after phalloplasty. *Urology*. 2019; 132: 195–201.
- Djordjevic ML, Bencic M, Kojovic V, *et al.* Musculocutaneous latissimus dorsi flap for phalloplasty in female to male gender affirmation surgery. *World J Urol* 2019; 37: 631–637.
- Neuville P, Morel-Journal N, Cabelguenne D, *et al.* First outcomes of the ZSI 475 FtM, a specific prosthesis designed for phalloplasty. *J Sex Med* 2019; 16: 316–322.
- Falcone M, Garaffa G, Gillo A, *et al.* Outcomes of inflatable penile prosthesis insertion in 247 patients completing female to male gender reassignment surgery. *BJU Int* 2018; 121: 139–144.
- Cohen AJ, Bhanvadia RR, Pariser JJ, *et al.* Novel technique for proximal bone anchoring of penile prosthesis after radial forearm free flap neophallus. *Urology* 2017; 105: 2–5.
- Neuville P, Morel-Journal N, Maucourt-Boulch D, *et al.* Surgical outcomes of erectile implants

- after phalloplasty: retrospective analysis of 95 procedures. *J Sex Med* 2016; 13: 1758–1764.
18. Garcia MM, Christopher NA, De Luca F, *et al.* Overall satisfaction, sexual function, and the durability of neophallus dimensions following staged female to male genital gender confirming surgery: The Institute of Urology, London U.K. Experience. *Transl Androl Urol* 2014; 3: 156–162.
19. Doornaert M, Hoebeke P, Ceulemans P, *et al.* Penile reconstruction with the radial forearm flap: an update. *Handchir Mikrochir Plast Chir* 2011; 43: 208–214.
20. Hoebeke PB, Decaestecker K, Beysens M, *et al.* Erectile implants in female-to-male transsexuals: our experience in 129 patients. *Eur Urol* 2010; 57: 334–341.
21. Garaffa G, Christopher NA and Ralph DJ. Total phallic reconstruction in female-to-male transsexuals. *Eur Urol* 2010; 57: 715–722.
22. Dhabuwala C, Sheth S and Zamzow B. Infection rates of rifampin/gentamicin-coated titan coloplast penile implants. Comparison with inhibizone-impregnated AMS penile implants. *J Sex Med* 2011; 8: 315–320.
23. Lee W, Christopher N and Ralph D. IPP in neophallus. In: Moncada-Iribarren I, Martinez-Salamanca JI, Lledo-Garcia E, *et al.* (eds.) *Textbook of urogenital prosthetic surgery*. Editorial Medica Panamericana S.A.; 2020, p.213–231.

Visit Sage journals online  
[journals.sagepub.com/  
home/tau](http://journals.sagepub.com/home/tau)

 Sage journals