

# Telomerase activity in pancreatic endocrine tumours: a potential marker for malignancy

K Y Lam, C Y Lo, S T Fan, J M Luk

## Abstract

**Aims**—Telomerase activation is known to be a common event in human cancer and may be a useful marker for malignancy. In general, the histological features of pancreatic endocrine tumours cannot be used to determine their malignant potential. The aim of this study was to investigate the role of testing telomerase activity in pancreatic endocrine tumours. **Methods**—Prospectively collected fresh frozen tissue specimens from 10 patients with pancreatic endocrine tumours (nine insulinomas, one adrenocorticotrophin producing pancreatic endocrine tumour) were examined by a highly sensitive polymerase chain reaction (PCR) based telomerase repeat protocol (TRAP).

**Results**—Of the 10 pancreatic endocrine tumours, three had telomerase activity. The positive cases included two frankly malignant tumours with liver metastases and one pancreatic endocrine tumour occurring in the setting of multiple endocrine neoplasia type 1. The latter had an infiltrative border. Vascular and perineural tumour infiltration was noted. In the two malignant pancreatic endocrine tumours with liver metastases, telomerase activity was noted in the tumour and the adjacent morphologically non-neoplastic pancreas.

**Conclusion**—To our knowledge, this is the first report of the role of telomerase activity in pancreatic endocrine tumours. Telomerase activity might be useful for distinguishing between benign and malignant pancreatic endocrine tumours.

(J Clin Pathol: Mol Pathol 2000;53:133–136)

Keywords: telomerase; pancreatic endocrine tumour

Recently, telomere length and telomerase activity have received much attention from the biomedical research community.<sup>1</sup> Human telomeres (terminal chromosome regions) are made up of several thousand copies of repeating nucleotide sequences (TTAGGG)<sub>n</sub>. Their main functions are believed to be the stabilisation and protection of chromosomal ends. These telomeric DNA sequences are not fully replicated at each round of DNA synthesis because of an “end replication problem” at the 5' end of the daughter DNA. Progressive shortening of these sequences is observed in most somatic cells in the body except for the germ line cells.

Telomerase is an important ribonucleoprotein that acts as an enzyme for the maintenance

of telomeres during cell division.<sup>2</sup> It is an RNA dependent DNA polymerase that synthesises the telomeric DNA repeats by using an RNA template (termed “hTR”) subunit of the telomerase holoenzyme. The enzyme is inactive in adult somatic cells, except for germ cells, activated lymphocytes, and stem cells of regenerative tissues. Raised telomerase activity has been selectively demonstrated in a large number of human tumours.<sup>1</sup> It has generated considerable excitement for research workers and has been proposed as a potential marker for malignancy, a prognostic indicator, and a target of future anticancer strategies.

Pancreatic endocrine tumours are an uncommon type of endocrine tumour. These tumours present an important challenge to clinicians because of their hormonal manifestations, associated morbidity, and potential lethality.<sup>3,4</sup> Unlike other tumours in general, it is difficult to assess the biological behaviour of pancreatic endocrine tumours based on histological studies alone. The diagnosis of malignancy usually depends on the presence of metastases. Despite the recent boom in clinical telomerase research, telomerase activity has rarely been studied in pancreatic endocrine tumours.<sup>5</sup> In our study, we analysed the presence of telomerase activity in pancreatic endocrine tumours to evaluate the investigation of telomerase activity as a marker for predicting the biological behaviour of these tumours. Possible correlations with clinicopathological parameters were also studied.

## Patients and methods

### COLLECTION OF TISSUES AND PATHOLOGICAL EXAMINATION

The tissue samples were collected prospectively from patients with pancreatic endocrine tumours in the five year study period (1995 to 1999). The resection specimens were dissected when fresh. Macroscopically, the site and size (maximum dimension) of the pancreatic tumours were recorded by one of us (KYL). In each case, one representative frozen block from the tumour and one from the non-neoplastic pancreas were snap frozen in liquid nitrogen at  $-70^{\circ}\text{C}$  and stored until used. Other standard blocks were then taken, fixed in 10% formalin, and embedded in paraffin wax. Histological sections (6  $\mu\text{m}$  thick) of the paraffin wax and frozen blocks were cut and stained with haematoxylin and eosin for light microscopic analysis. The diagnoses and clinicopathological subtypes of the tumours were confirmed with immunohistochemical stains using antibodies, as in our previous study.<sup>6</sup> The demographic data, clinical characteristics, laboratory

Department of Pathology, University of Hong Kong Medical Center, Queen Mary Hospital, Pokfulam Road 102, Hong Kong, SAR  
K Y Lam

Department of Surgery, University of Hong Kong Medical Center  
C Y Lo  
S T Fan  
J M Luk

Correspondence to:  
Dr Lam  
email: akylam@hkucc.hku.hk

Accepted 21 March 2000

Table 1 Clinicopathological features and telomerase activity in pancreatic endocrine tumours (PETs)

Case/Race	Sex/Age	Site	Tumour type	Size (diameter) of PETs	Telomerase activity	Optical density	Treatment	Follow up (months)	Remarks
1/Chinese	M/46	Head	Insulinoma	1.5 cm	Negative	–	Enucleation	52, alive, NED	
2/Chinese	M/41	Multiple	Insulinoma	Multiple tumors, the largest one: 6.0 cm at tail	Negative	–	Distal subtotal pancreatectomy	46, alive NED	Had MEN 1
3/Chinese	F/43	Body	Malignant ACTH producing PET	1.0 cm	Positive	1.9	Distal pancreatectomy	18, died	Metastases in liver
4/Chinese	M/22	Multiple	Insulinoma	Multiple tumours, the largest one: 1.0 cm at tail	Positive	1.9	Distal subtotal pancreatectomy	36, alive NED	Had MEN 1
5/Indian	F/49	Tail	Insulinoma	1.5 cm	Negative	–	Enucleation	16, alive, NED	
6/Chinese	M/29	Body	Insulinoma	1.5 cm	Negative	–	Distal pancreatectomy	21, alive NED	
7/Chinese	F/64	Tail	Malignant insulinoma	7.0 cm	Positive	1.4	Distal pancreatectomy	15, alive with residual disease	Metastases in liver
8/Chinese	M/35	Tail	Insulinoma	1.5 cm	Negative	–	Distal pancreatectomy	11, alive NED	
9/Chinese	M/68	Head	Insulinoma	1.0 cm	Negative	–	Enucleation	4, alive, NED	
10/Chinese	F/65	Head	Insulinoma	1.5 cm	Negative	–	Enucleation	3, alive, NED	

ACTH, adrenocorticotrophin; MEN 1, multiple endocrine neoplasia type 1; NED, no evidence of disease.

findings, and follow up data were noted from the clinical records. The preoperative localisation studies, biochemical investigations, hormonal studies, and postoperative follow up (radiological, biochemical, and hormonal investigations) were standardised for each patient.

#### TELOMERASE ASSAYS

Frozen tissue specimens were sectioned on a cryostat, and  $10 \times 10 \mu\text{m}$  thick sections from each specimen were resuspended in  $200 \mu\text{l}$  of ice cold lysis buffer. After 30 minutes incubation on ice, the lysate was centrifuged at  $16\,000 \times g$  for 20 minutes at  $4^\circ\text{C}$ . The supernatant was frozen in liquid nitrogen and stored at  $-80^\circ\text{C}$ . The protein concentration of tissue extracts was determined by the BioRad protein assay (Hercules, California, USA).

Telomerase activity was assayed by the telomeric repeat amplification protocol (TRAP) method as described by Kim *et al.*<sup>7</sup> Two protocols were used in our study: Telomerase polymerase chain reaction (PCR) enzyme linked immunosorbent assay (ELISA) (Boehringer Mannheim, Indianapolis, USA) and TRAP gel staining assay (Oncor, Gaithersburg, Maryland, USA).

In PCR ELISA,  $5 \mu\text{l}$  of tissue extracts (corresponding to 3–5  $\mu\text{g}$  total protein) was added to a final volume of  $50 \mu\text{l}$  of reaction mixture (0.1  $\mu\text{g}$  TS primer (5'-AATCCGTCGAGCAGAGTT-3'), 0.1  $\mu\text{g}$  CX primer (5'-CCCTTACCCTTACCCTTACCCTTA-3'), 50  $\mu\text{M}$  dNTPs, and 2 U Taq polymerase in 20 mM Tris/HCl buffer (pH 8.3)). A combined primer elongation/amplification protocol was performed: (1) primer elongation:  $25^\circ\text{C}$  for 30 minutes; (2) telomerase inactivation:  $94^\circ\text{C}$  for five minutes; (3) amplification (for 30 cycles):  $94^\circ\text{C}$  for 30 seconds (denaturation),  $50^\circ\text{C}$  for 30 seconds (annealing), and  $72^\circ\text{C}$  for 90 seconds (polymerisation), followed by a final extension step at  $72^\circ\text{C}$  for 10 minutes. After PCR,  $5 \mu\text{l}$  of the amplification product was treated with  $20 \mu\text{l}$  of denaturation solution for 10 minutes, and then transferred to  $225 \mu\text{l}$  of hybridisation buffer. Duplicate  $100 \mu\text{l}$  aliquots of the mixture were then added to a microplate precoated with streptavidin for capture of the biotinylated amplicons. After hybridisation for two hours at  $37^\circ\text{C}$ , the plate was washed and horseradish

peroxidase conjugated antidigoxigenin Fab antibody was added. TMB substrate solution (containing the peroxidase substrate, 3,3',5,5'-tetramethyl benzidine) was used for colour development, and optical absorbance at 450 and 690 nm was measured using an ELISA reader (Molecular Devices, Sunnyvale, California, USA). Heat inactivated tissue extracts (subjected to 30 minutes treatment at  $85^\circ\text{C}$  before the TRAP assay) were used as telomerase negative controls and extracts prepared from papillary carcinoma of the thyroid (known to be positive for telomerase) were used as telomerase positive controls.<sup>8</sup> Each reading represented the mean value of the  $A_{450-690}$  (sample) minus the  $A_{450-690}$  (control). The criterion for a positive telomerase assay was an  $A_{450-690}$  of 0.2 or greater.

Alternatively, telomerase activity in tissue extracts was determined by the Oncor telomerase detection kit according to the manufacturer's instructions. The TRAP reaction product was analysed by electrophoresis in 0.5 M Tris/borate EDTA buffer on 12% polyacrylamide non-denaturing gels. The gels were soaked in Syber Gold solution for visualisation. A typical hexanucleotide ladder of three or more bands was observed in the telomerase positive lane.

#### Results

Ten patients (six men, four women) with pancreatic endocrine tumours were studied. These comprised nine insulinomas and one tumour with documented ectopic adrenocorticotrophin (ACTH) production and carcinoid syndrome. Table 1 shows the clinicopathological characteristics and the results of the telomerase assay. The median age was 45 years (range, 29 to 64). The median size of the pancreatic endocrine tumours was 1.5 cm (range, 1 to 7). There appeared to be no correlation between tumour size and the results of the telomerase assay. In all the tumours, no significant lymphocytic infiltration was noted. Telomerase activity results were similar for both assays (PCR ELISA and TRAP silver staining assay). Telomerase activity was positive in the control tissue and three of 10 pancreatic endocrine tumours (fig 1).

Two patients presented with multiple liver metastases. One of them (a 43 year old woman) showed ectopic ACTH production and carcinoid syndrome. This patient also developed lung metastases and subsequently died of the

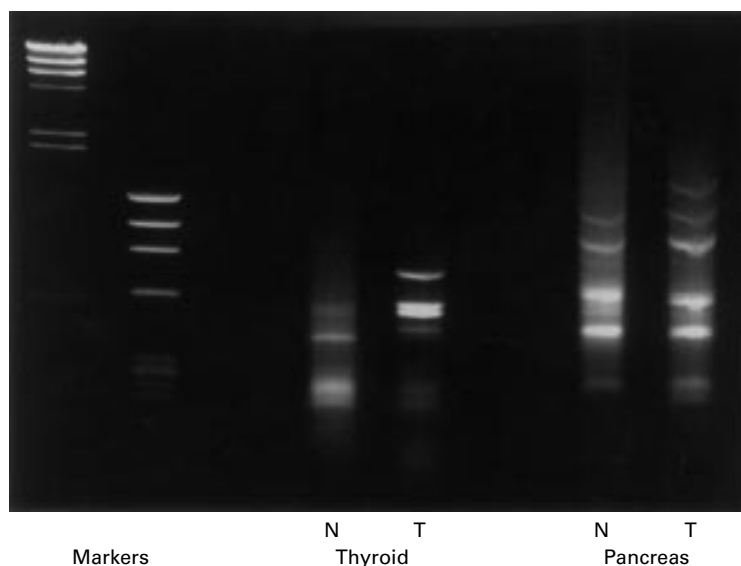


Figure 1 Telomerase activation can be observed in both the positive control (thyroid cancer) and one sample from a malignant endocrine tumour (P). N, normal tissue; T, tumour tissue.

disease 18 months after resection of the pancreatic tumour. In both cases, telomerase activity was documented in the pancreatic tumour and the adjacent non-neoplastic pancreas.

Two of the nine insulinomas were found in patients with multiple endocrine neoplasia type 1 (MEN 1). They showed multiple satellite nodules. In one patient, the tumour showed an infiltrative growth pattern. Vascular and perineural tumour infiltration were present. The resection margin was free of tumour. Biological behaviour was difficult to predict, because gross evidence of distant metastasis was absent. Telomerase activity was positive in this patient. In the other patient with MEN 1, satellite nodules were seen in the peripancreatic soft tissue. No evidence of local infiltration or distant metastasis was present. Telomerase activity was negative in this patient. In the other seven insulinomas, telomerase activity was negative in tissue taken from the tumour and adjacent non-neoplastic pancreas.

### Discussion

Telomerase activity has been proposed to be important in the proliferation of malignant cells and to be correlated closely with the malignant phenotype. More than 20 different tumour types have been tested for telomerase activity, and approximately 85% of all tumours have exhibited such activity.<sup>1</sup> The only study that analysed telomerase activity in human pancreatic endocrine tumours was described recently by Hiyama *et al.*<sup>5</sup> They detected telomerase activity in two of three pancreatic tumours labelled "islet cell carcinomas" in a study of telomerase activity in various types of pancreatic cancer. The study provided no information regarding the clinical presentations, pathological features of the tumours, or follow up data of these patients.

In the present prospective study over a period of three years, we prospectively collected the tissues and analysed the telomerase

activity from our tumour tissue bank. Telomerase activity was detected in three of the 10 pancreatic endocrine tumours. The telomerase positive tumours comprised two malignant pancreatic endocrine tumours with liver metastases and one insulinoma occurring in the setting of MEN 1. The telomerase positive tumour in the patient with MEN 1 was infiltrative and showed vascular and perineural tumour permeation. In addition, two of the three telomerase positive tumours were only 1 cm in diameter. Thus, telomerase was a potential marker for malignancy in pancreatic endocrine tumours and was positive even in malignant pancreatic endocrine tumours of small size.

A different surgical strategy is needed for the management of insulinomas in MEN 1.<sup>9</sup> In our study, both patients with MEN 1 had multiple tumours in the pancreas. Telomerase activity was seen in the insulinoma in one patient but not in the other. Thus, telomerase activity did not distinguish the patients with or without MEN 1.

Telomerase activity has been demonstrated in benign or tumour adjacent somatic tissue samples.<sup>1</sup> In some reports, telomerase activity in tissues resulted from the presence of activated lymphocytes.<sup>10</sup> In our study, telomerase activity was noted in the morphologically non-neoplastic pancreas adjacent to the malignant pancreatic endocrine tumours, whereas no activity was detected in tissue next to benign lesions. No intense lymphocyte infiltration was present to account for the telomerase activity. The reason for this finding is unknown. The adjacent morphologically non-neoplastic tissue in malignant pancreatic endocrine tumours might be genetically unstable, or there might be microinvasion that escapes detection (in routine microscopy) in the adjacent non-neoplastic tissue to give rise to the presence of telomerase activity. Nevertheless, the study of telomerase activity in the non-tumorous tissue adjacent to the tumour might also help predict the malignant potential of pancreatic endocrine tumours.

Human cells in culture undergo a finite number of divisions, during which the length of telomeres declines and then the cells senesce. This stage can be averted by mutations in the tumour suppressor gene p53.<sup>1</sup> Roos *et al* noted that telomerase activity in breast cancer was significantly associated with p53 overexpression.<sup>11</sup> In some other cancers, no such relation was found.<sup>12,13</sup> We have found no evidence of p53 accumulation in a study involving 52 pancreatic endocrine tumours (including the cases noted in our present study).<sup>14</sup> Thus, no correlation was found between p53 overexpression and telomerase activity in pancreatic endocrine tumours. In addition, alternative mechanisms have been suggested for telomeric length stabilisation other than telomerase activation.<sup>15</sup>

In summary, our study suggests that telomerase expression does play a role in distinguishing between benign and malignant pancreatic endocrine tumours. On the basis of this preliminary study, documenting telomerase

assay as a marker for biological aggressiveness in pancreatic endocrine tumours should be investigated.

- 1 Soria JC, Vielh P, El-Naggar AK. Telomerase activity in cancer: a magic bullet or a mirage? *Adv Anat Pathol* 1998;5:86-94.
- 2 Autexier C, Greider CW. Telomerase and cancer: revisiting the telomere hypothesis. *Trends Biochem Sci* 1996;21:387-91.
- 3 Lam KY, Lo CY. Pancreatic endocrine tumors: classical features and current insights. *Cancer J* 1998;11:18-26.
- 4 Lo CY, Lam KY, Kung AWC, et al. Pancreatic insulinomas: a 15-year experience. *Arch Surg* 1997;132:926-30.
- 5 Hiyama E, Kodama T, Shinbara K, et al. Telomerase activity is detected in pancreatic cancer but not in benign tumors. *Cancer Res* 1997;57:326-31.
- 6 Lam KY, Lo CY. Pancreatic endocrine tumor: a 22-year clinicopathologic experience with morphological, immunohistochemical observation and a review of the literature. *Eur J Surg Oncol* 1997;23:36-42.
- 7 Kim NW, Piatyszek MA, Prowse KR, et al. Specific association of human telomerase activity with immortal cells and cancer. *Science* 1994;266:2011-15.
- 8 Lo CY, Lam KY. Telomerase activity in thyroid malignancy. *Thyroid* 1999;112:263-70.
- 9 Lo CY, Lam KY, Fan ST. Surgical strategy for insulinomas in multiple endocrine neoplasia type I. *Am J Surg* 1996;175:305-7.
- 10 Norrback KF, Dahlenborg K, Carlsson R, et al. Telomerase activation in normal B lymphocytes and non-Hodgkin's lymphomas. *Blood* 1996;88:222-9.
- 11 Roos G, Nilsson P, Cajander S, et al. Telomerase activity in relation to p53 status and clinicopathologic parameters in breast cancer. *Int J Cancer* 1998;79:343-8.
- 12 Brown T, Aldous W, Lance R, et al. The association between telomerase, p53 and clinical staging in colorectal cancer. *Am J Surg* 1998;175:364-6.
- 13 Oishi T, Kigawa J, Minagawa Y, et al. Alteration of telomerase activity associated with development and extension of epithelial ovarian cancer. *Obstet Gynecol* 1998;91:568-71.
- 14 Lam KY, Lo CY. Role of p53 tumor suppressor gene in pancreatic endocrine tumors of Chinese patients. *Am J Gastroenterol* 1998;93:1232-5.
- 15 Greider CW. Telomerase activity, cell proliferation, and cancer. *Proc Natl Acad Sci U S A* 1998;95:90-2.