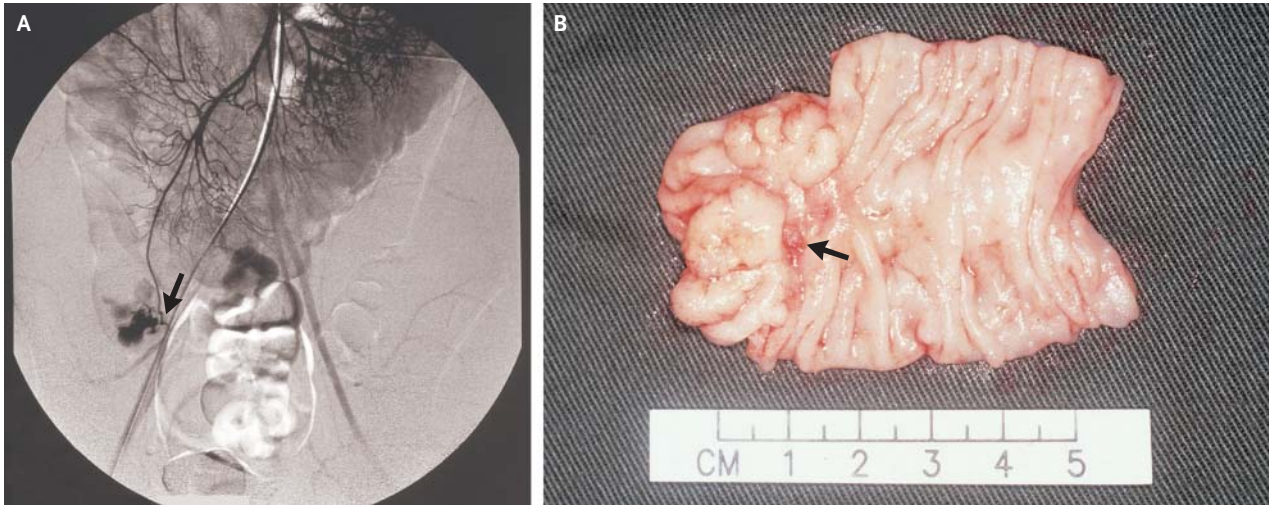


IMAGES IN CLINICAL MEDICINE

## Meckel's Diverticulum in Action



A 26-YEAR-OLD MAN PRESENTED WITH MASSIVE GASTROINTESTINAL hemorrhage and hypovolemic shock. His hemoglobin level dropped by 4 g per deciliter over a six-hour period. Emergency upper endoscopy to the second part of duodenum showed no abnormalities. Digital-subtraction visceral angiography was performed. Superior mesenteric arteriography revealed bleeding from a branch of the ileocolic artery (Panel A, arrow) that supplied the distal ileum. During laparotomy, the bleeding was localized to a 4-cm-long Meckel's diverticulum, located 55 cm proximal to the ileocecal junction. A Meckel's diverticulectomy was performed. A vessel corresponding to the tip of the feeding vessel in Panel A was visible on the mucosal surface of the diverticulum on the cut specimen (Panel B, arrow). The patient's postoperative recovery was unremarkable.

Copyright © 2004 Massachusetts Medical Society.

See-Ching Chan, M.D.  
 Chung-Yau Lo, F.R.C.S., F.A.C.S.  
 University of Hong Kong Medical Center  
 Hong Kong, China