

## Arrhythmia in a 38-year-old man

Tai Pang Ip, Chu Pak Lau, Karen SL Lam

A 38-year-old man presenting with progressive blurring of vision was diagnosed to have a pituitary macroadenoma with suprasellar extension. He underwent left frontal craniotomy with subtotal excision of the tumour without a proper pre-operative endocrine work up. He was put on prophylactic anticonvulsant (sodium valproate) after the operation. Dexamethasone and intravenous desmopressin (DDAVP) were also given, the latter being for the control of cranial diabetes insipidus that developed postoperatively.

On the eleventh postoperative day, a 15 mg tablet of midazolam was given for insomnia. He developed an unexpected episode of generalised tonic-clonic seizure about 12 hours later with an electrocardiogram (ECG) as shown in figure 1. Serum electrolytes showed mild hypokalaemia (3.1 mmol/l) and severe hypercalcaemia (3.37 mmol/l). Hormonal assay revealed a serum prolactin level of 33 507 mIU/l (normal <500).

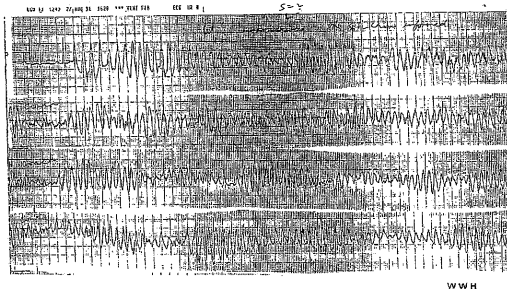


Figure 1 ECG during seizure

### Questions

- 1 What is the abnormal rhythm?
- 2 What is the underlying electrical abnormality?
- 3 What are the possible causes of this arrhythmia?
- 4 What are the treatment options?
- 5 What is the underlying endocrine disorder?

Department of  
Medicine, University  
of Hong Kong,  
Queen Mary  
Hospital,  
Pokfulam Road,  
Hong Kong  
TP Ip  
CP Lau  
KSL Lam

Accepted 7 February 1996

## Answers

### QUESTION 1

Torsade de pointes. The twisting of the QRS complexes about an isoelectric line is typical of torsade de pointes ventricular tachycardia.

### QUESTION 2

Pause-dependent long QT syndrome. The resting ECG showed a QTU duration of 0.4 s. Careful review of the ECG showed dynamic QTU changes with QTU prolongation after a post-ectopic long cycle. Figure 2 (a selected continuous rhythm strip) shows a progressively prolonged QTU interval starting with a QTU of 0.4 s. The QTU increased to 0.5 s after a long cycle due to a post-ectopic pause. This sequence was amplified with repeated long cycles to reach a QTU interval of 0.55 s.

### QUESTION 3

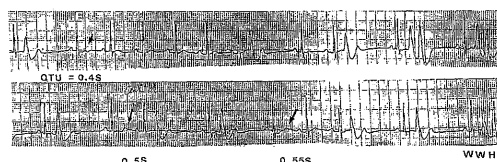
Possible causes of the arrhythmia are shown in the box.

### QUESTION 4

Treatment options include correction of hypokalaemia, intravenous magnesium infusion, isoprenaline infusion, and overdrive pacing. In this patient, the arrhythmia persisted despite correction of hypokalaemia, intravenous magnesium infusion and isoprenaline infusion. It was finally terminated by overdrive pacing at a rate of 110 beats/min through a transvenous pacing wire.

### QUESTION 5

The underlying endocrine disorder is multiple endocrine neoplasia type 1. The exceptionally high serum prolactin level indicated that the pituitary tumour was a prolactinoma which was confirmed by subsequent immunohistochemical staining of the operative specimen. The high serum calcium level suggested the possibility of primary hyperparathyroidism, which was confirmed by a concomitant serum parathyroid hormone level of 487 pg/ml (normal 10–50 pg/ml). He subsequently underwent a subtotal parathyroidectomy with histologically proven parathyroid hyperplasia. The clinical diagnosis of multiple endocrine neoplasia type



**Figure 2** A selected continuous rhythm strip (lead II)

#### Possible causes of the arrhythmia

- post-craniotomy
- hypokalaemia
- desmopressin
- midazolam

**Box 1**

1 was made in the presence of pituitary and parathyroid involvement. Work-up for possible pancreatic involvement was negative.

## Discussion

Torsade de pointes is a form of ventricular tachycardia with QRS complexes that appear to twist about an isoelectric line. It is usually described in patients with a prolonged QT interval secondary to anti-arrhythmic medications, electrolyte disorders or severe bradycardia.<sup>1</sup> However, the precise mechanism giving rise to this arrhythmia is not known. The current report describes a patient who developed torsade de pointes in a complex clinical setting. He had just undergone a major neurosurgical operation. He had mild hypokalaemia with a serum potassium of 3.1 mmol/l and he had been treated with two possible arrhythmogenic drugs, namely, desmopressin and midazolam.

Abnormal ECG patterns and a multitude of arrhythmias have been described in association with acute insults to the central nervous system. Torsade de pointes has been reported in patients with head injury.<sup>2,3</sup> However, it is exclusively mediated by an increase in adrenergic drive<sup>4,5</sup> rather than a pause-dependent mechanism which was the underlying electrical abnormality in our patient.

The hypokalaemia may have set off the ventricular premature beats in this case. However, the persistence of torsade de pointes despite correction of hypokalaemia indicated that other factors were at play. Vasopressin has been reported to induce torsade de pointes.<sup>6,7</sup> This patient was given intravenous and subsequently intranasal desmopressin for the control of cranial diabetes insipidus. There has been no recurrence of arrhythmia despite continuation of the drug in the subsequent three years of follow-up. The benzodiazepine, midazolam, has been known to induce ventricular irritability<sup>8</sup> but its ability to induce torsade de pointes has not been reported. The temporal relationship of ingestion of the drug with the development of torsade de pointes suggested drug-induced arrhythmia. Cardiac investigations have subsequently been performed to exclude intrinsic cardiac abnormality. Echocardiogram showed normal left ventricular function and coronary angiogram revealed normal coronary anatomy. Electrophysiological study showed no inducible ventricular tachyarrhythmia using up to triple ventricular stimulation with isoprenaline and an exercise stress test did not induce any arrhythmia. Therefore, the absence of intrinsic structural and electrical abnormalities of the heart further strengthened the possibility of midazolam-induced arrhythmia. Unfortunately this hypothesis could not be tested electrophysiologically since the patient refused re-challenge of the drug.

In conclusion, the development of torsade de pointes in this patient was probably drug-induced. Midazolam may have induced the arrhythmia in the presence of other predisposing conditions, ie, hypokalaemia. The recognition of this relationship is important as

midazolam is a widely used hypnotic and sedative.

**Keywords:** torsade de pointes, midazolam, multiple endocrine neoplasia

### Final diagnosis

Torsade de pointes, possibly midazolam-induced.

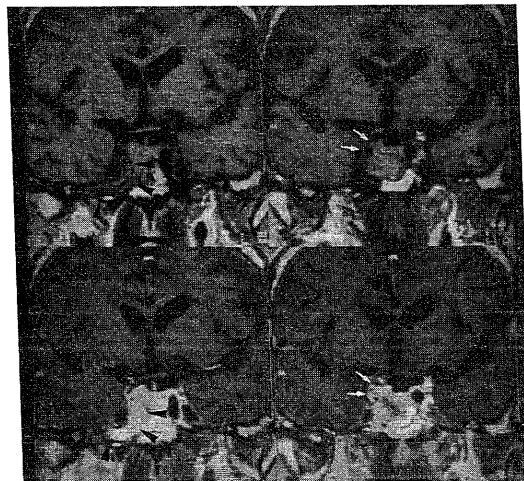
- 1 Smith WM, Gallagher JJ. 'Les torsade de pointes': An unusual ventricular arrhythmia. *Ann Intern Med* 1980; **93**: 578-84.
- 2 Evans DE, Alter WA, Shatsky SA, Gunby EN. Cardiac arrhythmia resulting from experimental head injury. *J Neurosurg* 1976; **45**: 609-16.
- 3 Rotem M, Constantini S, Shir Y, Cotev S. Life threatening torsade de pointes arrhythmia associated with head injury. *Neurosurgery* 1988; **23**: 89-92.
- 4 Jackman WM, Friday JK, Anderson JL, Aliot EM, Lazzara R. The long QT syndromes: a critical review, new clinical observations and a unifying hypothesis. *Prog Cardiovasc Dis* 1988; **31**: 115-72.
- 5 Clifton GL, Ziegler MG, Grossman RG. Circulating catecholamines and sympathetic activity after head injury. *Neurosurgery* 1981; **8**: 10-4.
- 6 Maur VF, Bingle JF, Ginn SM, Jafri FM. Torsade de pointes in a patient receiving intravenous vasopressin. *Crit Care Med* 1988; **16**: 200.
- 7 Stein ZB, Dakezies MA, Siherman M, Brozena SC. Fatal torsade de pointes occurring in a patient receiving intravenous vasopressin and nitroglycerin. *J Clin Gastroenterol* 1992; **15**: 171-4.
- 8 Arcos GJ. Midazolam-induced ventricular irritability. *Anesthesiology* 1987; **67**: 612.

## Cerebrovascular accident in a 77-year-old man

Juan Carlos Garcia-Monco, Ana Capelastegui, Marian Gomez Beldarrain, Elena Guerra

A 77-year-old man was admitted to our hospital because of sudden left hemiparesis. Neurologic examination showed left hemiparesis (upper extremity 3-4/5 and lower extremity 4/5, MRC scale) and left Babinski's sign without a visual or sensory deficit. The patient improved over the ensuing months with rehabilitation therapy, regaining the ability to walk unassisted, and was left with moderate left spastic hemiparesis.

Brain computed tomography (CT) scan disclosed a subcortical ischaemic infarct in the distribution of the right middle cerebral artery. Magnetic resonance imaging (MRI) was performed because CT scan showed a questionable haemorrhagic component. MRI ruled out parenchymal haemorrhage but showed another abnormality (arrowed in figure 1).



### Questions

- 1 What is the most likely pathogenetic mechanism of this patient's stroke?
- 2 What further investigations would be helpful?

Hospital de  
Galdacano, 48960  
Galdacano, Vizcaya,  
Spain  
Department of  
Neurology  
JC Garcia-Monco  
MG Beldarrain  
E Guerra  
Magnetic Resonance  
Unit 'Osatek'  
A Capelastegui

Accepted 28 February 1996

**Figure 1** Brain MRI shortly after the stroke