



The clinicopathological features and importance of p53, Rb, and mdm2 expression in pheochromocytomas and paragangliomas

K Y Lam, C Y Lo, N M S Wat, J M Luk and K S L Lam

J. Clin. Pathol. 2001;54:443-448
doi:10.1136/jcp.54.6.443

Updated information and services can be found at:
<http://jcp.bmj.com/cgi/content/full/54/6/443>

These include:

- | | |
|-------------------------------|---|
| References | This article cites 19 articles, 5 of which can be accessed free at:
http://jcp.bmj.com/cgi/content/full/54/6/443#BIBL |
| | 3 online articles that cite this article can be accessed at:
http://jcp.bmj.com/cgi/content/full/54/6/443#otherarticles |
| Rapid responses | You can respond to this article at:
http://jcp.bmj.com/cgi/eletter-submit/54/6/443 |
| Email alerting service | Receive free email alerts when new articles cite this article - sign up in the box at the top right corner of the article |
-
- | | |
|--------------------------|---|
| Topic collections | Articles on similar topics can be found in the following collections
Other Endocrinology (621 articles)
Molecular Medicine (1111 articles)
Cancer:other (950 articles) |
|--------------------------|---|
-

Notes

To order reprints of this article go to:
<http://www.bmjournals.com/cgi/reprintform>

To subscribe to *Journal of Clinical Pathology* go to:
<http://www.bmjournals.com/subscriptions/>

Papers

The clinicopathological features and importance of p53, Rb, and mdm2 expression in pheochromocytomas and paragangliomas

K Y Lam, C Y Lo, N M S Wat, J M Luk, K S L Lam

Abstract

Aims—Pheochromocytomas and paragangliomas are uncommon. The aims of this study were to analyse the characteristics and the possible roles of p53, Rb, and mdm2 alterations in these tumours.

Methods—The clinicopathological features of 65 patients (31 men, 34 women) with pheochromocytomas or paragangliomas were analysed. The tumours were studied for the expression of p53, Rb, and mdm2 by immunohistochemical methods.

Results—Thirty nine of the patients had pheochromocytomas and 26 had paragangliomas. Bilateral tumours were noted in eight of the patients and malignant tumours were seen in 13. Paragangliomas were often small, non-functional, and presented incidentally, whereas pheochromocytomas were usually large, functional, and symptomatic. p53 overexpression, loss of Rb expression, and mdm2 overexpression were seen in four, 43, and 37 of the patients, respectively. Three of the four patients with p53 overexpression had bilateral tumours. Loss of Rb expression was often found in pheochromocytomas, whereas mdm2 overexpression was more frequently seen in paragangliomas. The 10 year survival rate of patients with malignant tumours was 45%. Two patients died of tumour metastases more than 10 years after resection of the primary tumours.

Conclusions—Pheochromocytomas and paragangliomas had distinctive clinical features and genetic alterations. The prognosis of patients with these tumours was related to the malignant potential. p53 overexpression, more common in bilateral pheochromocytomas and paragangliomas, could be a marker for this tumour subgroup.

(*J Clin Pathol* 2001;54:443–448)

Keywords: pheochromocytoma; paraganglioma; p53

The products of the p53, retinoblastoma (Rb), and mouse double minute 2 (mdm2) genes are important modulators of the cell cycle.^{1–3} The p53 and Rb genes are tumour suppressor

genes, whereas the mdm2 gene is a proto-oncogene, which produces a protein that inhibits the function of the p53 and Rb proteins.^{1–3} Wild-type p53 protein is labile, whereas mutant forms have longer half lives and can be detected by immunohistochemistry. In contrast, the Rb protein can be detected in non-neoplastic tissue, and mutations of the Rb gene could result in the loss of Rb staining. Lastly, amplification of the mdm2 gene may lead to mdm2 protein overexpression.

The role of p53 alterations in pheochromocytomas/paragangliomas has been investigated in several studies.^{4–14} However, to the best of our knowledge, the importance of Rb and mdm2 aberrations in human pheochromocytomas/paragangliomas has never been studied. In our study, we analysed the clinicopathological features of patients with pheochromocytomas and paragangliomas. The possible roles of alterations in the p53, Rb, and mdm2 genes and their interaction in these tumours were also studied by means of immunohistochemistry. Although the immunohistochemical analysis of these cell cycle proteins does not necessarily reflect genetic changes, it allows genetic alterations to be localised and correlated with other clinicopathological parameters.

Materials and methods

DATA COLLECTION

The patients who were chosen for our study had pheochromocytomas or paragangliomas confirmed by histological examination during a 25 year study period (1973–97) at Queen Mary Hospital. The age, sex, clinical presentation, urinary catecholamine values, and survival data of these patients were taken from the clinical records. Macroscopically, the location and size (maximum length) of the tumours were recorded. The tumours were categorised as either benign or malignant. Malignant pheochromocytomas/paragangliomas were defined as tumours with unequivocal evidence of metastatic disease(s).

PATHOLOGICAL REVIEW AND SELECTION OF TISSUES

The histological sections of the tumours were reviewed. The diagnoses were confirmed by positivity to the neuroendocrine markers

Department of Pathology, University of Hong Kong, Hong Kong, China
K Y Lam

Department of Surgery, University of Hong Kong
C Y Lo
J M Luk

Department of Medicine, University of Hong Kong
N M S Wat
K S L Lam

Correspondence to: Dr Lam, Department of Pathology, Queen Mary Hospital, Pokfulam Road, Hong Kong, China
akylam@hotmail.com

Accepted for publication 20 November 2000

(neurone specific enolase, chromogranin, and synaptophysin). Electron microscopic examination was performed to detect the neurosecretory granules if the diagnosis was uncertain. Representative paraffin wax blocks from the tumours were chosen for immunohistochemical studies.

IMMUNOSTAINING

The immunohistochemical study was conducted on 5 µm thick paraffin wax sections using the avidin–biotin–peroxidase complex method. The antibodies against p53 (microwave pretreated; NCL-p53-DO7 at a dilution of 1/50), Rb (microwave pretreated; NCL-RB1 at a dilution of 1/50), and mdm2 (trypsin pretreated; NCL-MDM2 at a dilution of 1/50) were from Novocastra Laboratories Ltd (Newcastle upon Tyne, UK). Paraffin wax blocks of oesophageal squamous cell carcinoma (known to be strongly positive for the p53 and Rb proteins) and breast carcinoma (known to be strongly positive for mdm2) were used as positive controls.^{4–7} Brown nuclear staining was regarded as a positive signal, whereas cytoplasmic staining (non-specific background staining) was considered to be negative. In addition, tumours with less than 5% of tumour cells with a positive signal were defined as negative.

STATISTICAL ANALYSIS

Statistical analysis was performed using the Student's *t* test (continuous variables), with Yates correction and χ^2 /Fisher exact test (categorical variables). The actuarial survival rate of the patients was measured from the date of resection of these tumours to the date of death or of the last follow up. Survival was calculated using the Kaplan–Meier method, whereas the impact of survival by various factors was examined by means of the log rank test.

Results

Sixty five patients (31 men, 34 women) with phaeochromocytomas/paragangliomas were found (62 Chinese, two white, and one Indian). The clinicopathological features of patients are summarised in table 1 and some of the cases had been described previously.^{15–17}

CLINICOPATHOLOGICAL FEATURES

The mean age of the patients was 43 (range, 2–85). Thirty nine had phaeochromocytomas and 26 had paragangliomas. Approximately half (33) of the patients had functional tumours (with raised urinary catecholamine values) and 46 had been diagnosed correctly before pathological examination. Thirty one of the patients with phaeochromocytomas and two of the patients with paragangliomas had functional tumours. Paragangliomas studied comprised: carotid body paragangliomas (12), paragangliomas from the sympathetic trunk (four in the retroperitoneum and two in the bladder), middle ear (five), jaw (two), and base of the skull (one).

Thirty six of the patients had lesions on the right side of body, 21 had left sided tumours, and eight had bilateral tumours. The last group

comprised four patients suffering from bilateral phaeochromocytomas and four with bilateral carotid body tumours. Thus, we analysed a total of 73 phaeochromocytomas and paragangliomas. On gross examination, the tumours usually appeared light brown in colour. The mean diameter of these tumours was 5 cm (range, 0.2–17). Malignancy was noted in 13 of the patients.

Phaeochromocytomas were often functional, usually leading to a correct diagnosis before histological examinations were conducted, whereas paragangliomas were normally non-functional tumours and detected incidentally ($p = 0.0001$ and $p = 0.025$, respectively). The mean diameter of the phaeochromocytomas was significantly larger than paragangliomas (6 *v* 3.5 cm; $p = 0.002$). Phaeochromocytomas were detected more often on the right side (right to left ratio, 1.9 : 1), whereas paragangliomas did not seem to have a predilection for either side (right to left ratio, 1.1 : 1). Nevertheless, the difference between phaeochromocytomas and paragangliomas with respect to side predilection was not significant ($p = 0.32$). Bilateral paragangliomas were limited to the location at carotid bodies. One third (four of 12) of the patients with carotid body tumours suffered from bilateral growth whereas no patients with other paragangliomas had bilateral lesions ($p = 0.033$). There was no significant difference between the phaeochromocytomas and paragangliomas with respect to the age ($p = 0.45$; Student's *t* test) or sex ($p = 1$) of the patients or malignant potential of the tumours ($p = 1$).

p53 EXPRESSION

Four patients had p53 overexpression: three with phaeochromocytomas and one with carotid body tumours. Bilateral phaeochromocytomas were found in two of the three patients with p53 overexpression. Among them, one had multiple endocrine neoplasia type 2 (MEN2) and another died of bilateral phaeochromocytomas with metastases (no necropsy or genetic screening was performed to verify the presence of MEN2). The third patient with a p53 positive phaeochromocytoma was a 2 year old boy (the youngest patient in our series). He was lost to follow up. The patient with p53 positive bilateral carotid body tumours also had familial tumours and her brother also suffered from bilateral carotid body paragangliomas. The difference in p53 overexpression in the patients with and without bilateral tumours was significant ($p = 0.003$). The patients with p53 positive tumours did not differ significantly from those with p53 negative ones with respect to age at presentation ($p = 0.16$), sex ($p = 1$), clinical presentation ($p = 1$), and functional status ($p = 0.61$). Furthermore, there was no difference between p53 positive and p53 negative tumours in relation to their size ($p = 0.36$), location (adrenal medulla *v* extra-adrenal; $p = 0.64$), and malignant potential ($p = 1$).

Rb EXPRESSION

Twenty two of the patients showed Rb staining. Loss of Rb expression was noted in 35 of the 39 patients with pheochromocytomas and eight of the 18 patients with paragangliomas. Therefore, loss of Rb was more frequently detected in pheochromocytomas than in paragangliomas ($p = 0.0001$). In addition, Rb

positive tumours were often non-functional ($p = 0.0001$) and of smaller size ($p = 0.001$). There was no significant difference between patients with Rb positive and Rb negative tumours with respect to age at presentation ($p = 0.58$), sex ($p = 1$), clinical presentation ($p = 0.78$), laterality ($p = 1$), or malignant potential ($p = 0.5$).

Table 1 Clinicopathological features of patients with pheochromocytoma or paraganglioma

Case	Sex/age	Side	Site	Size (cm)	Malignant/ Benign	Expression			Func	Dx	Remarks
						p53	Rb	mdm2			
1	F/21	Right	Adrenal	3.0	Benign	0	+	0	Yes	Yes	-
2	M/57	Left	Adrenal	9.0	Malignant	0	0	0	Yes	Yes	DOD after 8 years
3	M/33	Right	Adrenal	3.5	Benign	0	0	0	Yes	Yes	-
4	F/30	Left	Adrenal	8.0	Benign	0	0	+	Yes	Yes	-
5	M/2	Right	Adrenal	3.0	Benign	+	0	0	Yes	No	-
6	M/52	Right	Adrenal	9.0	Benign	0	0	+	Yes	Yes	-
7	M/22	Left	Adrenal	5.0	Benign	0	0	+	Yes	Yes	-
8	M/36	Right	Adrenal	5.0	Malignant	0	0	0	Yes	Yes	DOD after 16 years
9	M/63	Right	Adrenal	8.0	Benign	0	0	+	Yes	Yes	-
10	F/35	Left	Adrenal	5.0	Malignant	0	0	0	Yes	Yes	AWD after 17 years
11	F/32	Right	Adrenal	8.5	Benign	0	0	+	Yes	Yes	Alive after 1 year
12	F/22	Right	Adrenal	8.0	Benign	0	+	+	Yes	Yes	-
13	F/18	Right	Adrenal	7.5	Benign	0	0	0	Yes	Yes	Alive after 4.3 years
14	M/26	Right	Adrenal	5.0	Benign	0	0	+	No	No	-
15	F/46	Right	Adrenal	8.0	Malignant	0	0	0	No	Yes	AWD after 3.2 years
16	F/40	Right	Adrenal	5.0	Benign	0	0	0	Yes	Yes	Alive after 5 months
17	M/59	Right	Adrenal	5.0	Benign	0	0	+	Yes	Yes	Alive after 11.6 years
18	F/62	Right	Adrenal	9.0	Benign	0	0	0	Yes	Yes	Alive after 1.2 years
19	M/53	Right	Adrenal	12.0	Benign	0	0	0	Yes	Yes	Alive after 1.3 years
20	M/38	Right	Adrenal	3.0	Benign	0	0	0	Yes	Yes	Alive after 12 years;
		Left	Adrenal	1.0							MEN2
21	F/32	Left	Adrenal	3.0	Benign	0	0	0	Yes	Yes	Alive after 10.6 years
22	F/34	Right	Adrenal	5.0	Benign	0	0	0	Yes	Yes	Alive after 9.1 years
23	F/58	Right	Adrenal	5.0	Benign	0	0	0	Yes	Yes	Alive after 7.3 years
24	M/54	Left	Adrenal	4.0	Benign	0	0	0	Yes	Yes	Alive after 6.1 years
25	M/65	Right	Adrenal	9.5	Benign	0	0	0	Yes	Yes	Alive after 4.6 years
26	M/42	Left	Adrenal	6.0	Malignant	0	0	+	Yes	Yes	Alive after 12.4 years
27	M/63	Right	Adrenal	8.0	Malignant	+	+	0	Yes	Yes	DOD after 2 years
		Left	Adrenal	4.5							
28	M/48	Left	Adrenal	6.8	Benign	0	0	+	Yes	Yes	Alive after 2.8 years
29	F/62	Left	Adrenal	11.5	Malignant	0	0	0	No	No	Died shortly after OT
30	F/51	Right	Adrenal	2.5	Benign	0	0	+	No	Yes	Alive after 3.8 years;
		Left	Adrenal	1.7							MEN2
31	F/62	Right	Adrenal	6.0	Benign	0	0	+	Yes	Yes	Alive after 3.8 years
32	F/56	Right	Adrenal	2.0	Benign	0	0	0	Yes	Yes	Alive after 1 year
33	F/73	Right	Adrenal	8.0	Benign	0	0	+	Yes	Yes	Alive after 11 months
34	F/33	Right	Adrenal	2.0	Benign	0	0	+	Yes	Yes	Alive after 8 months
35	F/40	Right	Adrenal	11.0	Benign	+	+	0	Yes	Yes	Alive after 7 months;
		Left	Adrenal	4.5							MEN2
36	M/42	Left	Adrenal	1.0	Benign	0	0	+	No	No	Incidental PM finding
37	M/71	Right	Adrenal	13.0	Malignant	0	0	+	No	No	Incidental PM finding
38	M/50	Right	Adrenal	5.0	Benign	0	0	+	No	No	Incidental PM finding
39	F/47	Left	Adrenal	8.0	Benign	0	0	0	No	No	Incidental PM finding
40	M/50	Right	Carotid body	17.0	Malignant	0	0	0	No	No	Incidental PM finding
41	M/40	Right	Jaw	2.5	Benign	0	+	+	No	No	-
42	F/68	Right	Retropertoneum	3.5	Benign	0	0	+	No	No	Died shortly after OT
43	F/39	Left	Middle ear	0.5	Benign	0	0	0	No	Yes	-
44	F/50	Right	Middle ear	0.5	Benign	0	+	+	No	Yes	-
45	M/63	Left	Jaw	0.5	Benign	0	+	+	No	No	-
46	M/25	Right	Carotid body	3.0	Benign	0	+	+	No	No	-
47	M/22	Left	Carotid body	3.0	Malignant	0	+	0	No	No	DOD after 13 years
48	F/26	Right	Carotid body	4.0	Benign	0	+	+	No	Yes	Alive after 16.4 years
		Left	Carotid body	2.5							
49	F/39	Right	Middle ear	0.7	Benign	0	+	+	No	Yes	Alive after 12.3 years
50	F/60	Right	Middle ear	1.0	Benign	0	+	+	No	Yes	-
51	F/23	Right	Retropertoneum	10.0	Malignant	0	0	+	Yes	Yes	DOD after 6.5 years
52	F/28	Left	Bladder	5.0	Malignant	0	0	+	Yes	No	AWD after 12.4 years
53	M/19	Right	Carotid body	3.5	Benign	0	0	+	No	No	Alive after 11.3 years
54	M/53	Right	Bladder	3.0	Benign	0	0	+	No	No	Alive after 10 years; with rectal carcinoid
55	F/21	Right	Carotid body	5.0	Benign	+	0	+	No	Yes	Brother had carotid body tumour;
		Left	Carotid body	2.0							alive after 8.8 years
56	M/34	Right	Carotid body	4.0	Benign	0	+	+	No	Yes	Sister had carotid body tumour;
		Left	Carotid body	2.0							alive after 8.3 years
57	M/35	Left	Base of skull	1.0	Benign	0	+	+	No	No	Alive after 6 years
58	F/28	Left	Carotid body	3.0	Benign	0	+	+	No	Yes	Alive after 5.2 years
59	M/31	Left	Carotid body	2.5	Benign	0	+	+	No	Yes	Alive after 5 years
60	F/30	Left	Carotid body	4.5	Benign	0	+	+	No	Yes	Alive after 4 years
		Right	Carotid body	4.0							
61	F/85	Left	Retropertoneum	0.6	Benign	0	+	+	No	No	Alive after 1.8 years
62	F/68	Left	Middle ear	0.2	Benign	0	+	+	No	Yes	Alive after 2.1 years
63	M/36	Left	Carotid body	3.5	Malignant	0	+	0	No	Yes	Alive after 1.7 years
64	M/59	Right	Retropertoneum	7.0	Benign	0	+	0	No	No	Alive after 1.3 years
65	F/33	Right	Carotid body	3.0	Benign	0	+	0	No	Yes	Alive after 9 years

Expression: +, positive; 0, negative.

M, male; F, female; Func, functional tumour; Dx, clinical diagnostic; DOD, died of disease; AWD, alive with disease; PM, postmortem; OT, operation.

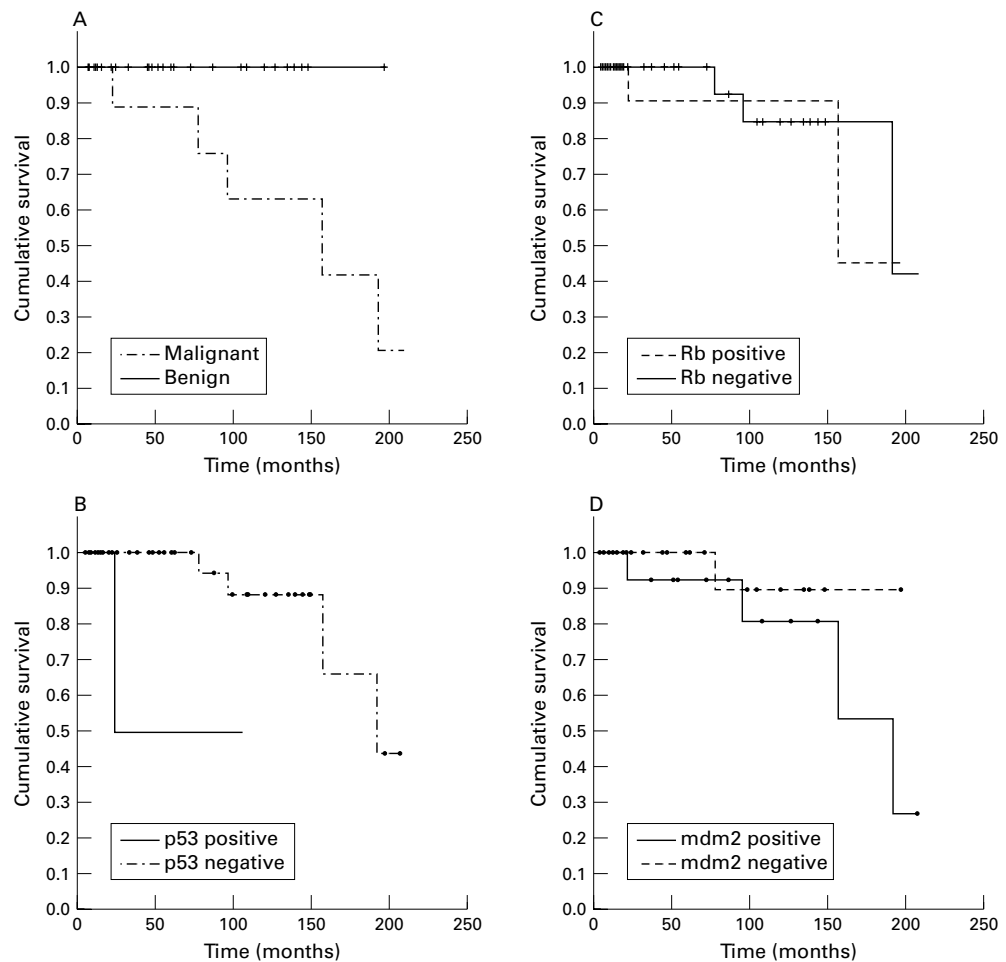


Figure 1 Overall survival curves of patients with pheochromocytomas/paragangliomas. (A) Benign versus malignant tumours, $p = 0.0001$; (B) p53 overexpression (positive versus negative), $p = 0.04$; (C) Rb expression (positive versus negative), $p = 0.80$; mdm2 overexpression (positive versus negative), $p = 0.26$.

mdm2 EXPRESSION

Thirty seven of the patients had mdm2 nuclear staining. Mdm2 staining was found in 20 of the 26 patients with paragangliomas and 17 of the 39 patients with pheochromocytomas. Thus, the incidence of mdm2 staining was significantly higher in paragangliomas than in pheochromocytomas ($p = 0.011$). The staining was also detected frequently in non-functional tumours ($p = 0.024$) and those of a smaller size ($p = 0.038$). However, the patients with mdm2 positive tumours did not differ from those with mdm2 negative tumours with respect to age at presentation ($p = 0.85$), sex ($p = 1$), or clinical presentation ($p = 0.28$). There was no significant difference between the two groups of tumours in terms of the malignant potential ($p = 0.058$) and the occurrence of bilateral tumours ($p = 1$). Overall, there was no significant correlation between p53, Rb, and mdm2 staining in the tumours studied.

SURVIVAL ANALYSIS

Survival data were available for 50 of the 65 patients. Five patients had tumours detected at necropsy and two patients died shortly after surgery. The median follow up of the remaining 43 patients was 5.2 years. The survival rate was not related to the patients' sex ($p = 0.12$),

clinical presentation ($p = 0.86$), functional status ($p = 0.28$), or tumour location ($p = 0.75$). However, survival was related to the malignant potential of the tumour ($p = 0.01$) (fig 1A). Five patients with benign tumours were detected at necropsy, whereas other patients with benign tumours survived and had no recurrence of disease during the follow up period (median follow up, 4.6 years; range, 5 months to over 16 years). In comparison, only 45% of patients with malignant tumours survived for 10 years. Although death in patients with malignant tumours occurred mainly within 10 years after the resection of the primary tumour, two patients lived for more than 10 years before dying of tumour related diseases (one with malignant pheochromocytoma and the other with malignant carotid body tumour died of distant metastases 13 and 16 years, respectively, after surgery). The survival rate of the patients with pheochromocytomas/paragangliomas appeared to be higher in the patients with p53 negative tumours than those with p53 overexpression ($p = 0.04$), even though the number of patients involved was quite small. However, survival was not related to either Rb expression ($p = 0.8$) or mdm2 expression ($p = 0.26$) (fig 1B–D).

Table 2 Summary of studies concerning p53 alterations in pheochromocytomas/paragangliomas

1st author/year/location	Analysis by			Remarks
	Immunohistochemistry	LOH	PCR-SSCP (exons studied)	
Khosia/1991/USA	–	7/29	–	17% are familial cases
Yana/1992/Japan	–	–	–	0/30, exons 4–9 analysed by RNase protection analysis. Includes 10 hereditary cases
Yoshimoto/1993/Japan	–	0/1	0/1 (exons 5–10)	F/18 with MEN2B
Lin/1994/Taiwan	5/6	–	5/6 (exons 2–11)	2 male and 4 female patients
Hagemeyer/1994/Russia	1/1	–	–	Lung paraganglioma after exposure to atomic reactor accident
Dahia/1995/Brazil	1/25	–	0/25 (exons 4–8)	16% were malignant tumours; 4 were paragangliomas; 3 cases were familial; the positive case was a benign, sporadic paraganglioma
Wang/1995/UK	0/36	–	–	Includes 24 pheochromocytomas and 9 paragangliomas
Ballantine/1996/Australia	–	–	0/3 (exons 4–9)	
Reincke/1996/USA	0/6	0/2	0/6 (exon 4)	2 male and 4 female patients
Herfarth/1997/USA	0/19	0/22	0/20 (exons 4–9)	Includes 14 MEN2 and 1 von Hippel-Lindau disease
Yoshimoto/1998/Japan	3/4*	–	6/33 (Exons 4–9)	21 Japanese and 12 Chinese patients (17 male, 16 female); positive cases were either with multiple tumours or malignant tumours
Lam/1999/Hong Kong	4/65	–	–	

*Only cases positive for SSCP were analysed by immunohistochemistry.

LOH, loss of heterozygosity; MEN, multiple endocrine neoplasia; PCR-SSCP, polymerase chain reaction-single strand conformation polymorphism.

Discussion

The reported incidence of malignancy in pheochromocytomas/paragangliomas varies among different series.¹⁸ The variations may be related to differences in the length of the follow up period and the proportions of adrenal and extra-adrenal tumours in the series. The traditional figure of 10% is close to the average of most studies.¹⁵ Paragangliomas have a slightly higher rate of malignancy, from 14% to 50%.¹⁶ In our series, which contained a large number of patients (predominately Chinese), and with longterm follow up in many cases, the rate of malignancy was found to be 20%. This rate was similar both for pheochromocytomas and paragangliomas. The only criterion that determined the prognosis of the patients with pheochromocytomas/paragangliomas was the biological aggressiveness of the disease. Patients with benign tumours had longer term survival, whereas the 10 year survival rate of patients with malignant tumours was only 45%. Some patients with malignant tumours died of metastatic tumours more than 10 years after the resection of their primary tumours.

p53 alterations in pheochromocytomas and paragangliomas have been studied in a few series (table 2).^{4–14} The number of patients investigated in these series was usually small (range, one to 36). In many of these studies, no p53 aberration was found. On the contrary, Lin *et al* in Taiwan and Yoshimoto *et al* in Japan and China detected p53 mutations in pheochromocytomas.^{7–14} However, the mutation patterns identified in these two studies were different. Both geographical and ethnic factors may have affected the mutational spectrum of p53 in different populations. Our investigation, which studied a larger number of patients than the other studies, showed the presence of p53 overexpression in four of the 65 pheochromocytomas and paragangliomas (including three patients with pheochromocytomas and one with paraganglioma). Apart from our case, the other p53 positive paragangliomas reviewed in the English literature include a sporadic paraganglioma reported by Dahia *et al* and a lung paraganglioma, which occurred after radiation exposure, described by Hagemeyer *et al*.^{8,9}

Hereditary factors have been reported in pheochromocytomas and paragangliomas. Pheochromocytoma can occur in the setting of MEN2, an autosomal dominant disease of disordered development and tumour formation that principally affects thyroid C cells, the adrenal medulla, and the parathyroids. Mutations in the RET proto-oncogene, located on chromosome 10, have been related to the MEN2 syndrome. The gene encodes a receptor tyrosine kinase expressed in tissues derived from the neural crest. Familial paragangliomas have been reported and were also noted in our study. Recently, germ line mutations in SDHD, a mitochondrial complex II gene, were found to be responsible for this syndrome.¹⁹ Other genetic alterations may be important in the pathogenesis of pheochromocytomas and paragangliomas.

Bilateral pheochromocytomas were often noted in the patients with MEN2. Lin *et al* found that p53 positive patients had either multiple or malignant pheochromocytomas.⁷ In agreement with this finding, we noted that the p53 positive tumours were found in the patients with bilateral tumours. The p53 positive tumours occurred not only in a patient with bilateral pheochromocytomas (in MEN2) but also in a patient with bilateral carotid body tumours. Thus, p53 overexpression might play a role in the pathogenesis of multiple pheochromocytomas and paragangliomas. It could act as a marker for this subtype of tumour and might be associated with poor prognosis.

Although paragangliomas and pheochromocytomas had identical histological features, we found that they were different in terms of their clinical and genetic attributes. Clinically, paragangliomas were often small, non-functional, presented as incidental findings, and did not show the side predilection seen in pheochromocytomas. In the patients with paragangliomas, the carotid body was the only location with bilateral tumours.

Our study represents the first examination of pheochromocytomas/paragangliomas for alterations in the Rb and mdm2 genes. The high overall rate of loss of Rb staining (43 of 65) and mdm2 expression (37 of 65) emphasised their importance in the development of these tumours. Loss of Rb staining was seen more

often in pheochromocytomas (35 of the 39 patients), whereas the presence of mdm2 expression was seen more frequently in paragangliomas (noted in 20 of the 26 patients). This implies that the tumour suppressor Rb and the oncoprotein mdm2 play different roles in the pathogenesis of pheochromocytomas and paragangliomas. Nevertheless, the alterations in expression of these proteins did not seem to affect the biological aggressiveness and survival of the patients with these tumours.

Mdm2 has recently been shown to interact with tumour suppressor gene products (p53 and Rb) and inhibit their function.³ In our study, no significant relation was found between the alterations of mdm2, p53, and Rb. Recently, it has been noted that mdm2 might function differently in p53 dependent and p53 independent pathways to regulate cellular proliferation.⁴ In the former pathway, loss of p53 leads to a lack of mdm2 and thus to p53 protein accumulation, and vice versa. In our patients, mdm2 staining occurred in tumours with and without p53 overexpression. Many patients with paragangliomas had mdm2 expression but no p53 protein overexpression. In addition, the propensity of Rb and p53 alterations to occur together in samples from the same patient was noted previously in some tumours.²⁰ In our study, Rb and p53 alterations in pheochromocytomas and paragangliomas usually occurred in the absence of each other.

Pheochromocytomas and paragangliomas have distinctive clinical features and genetic alterations. They should not be treated as a single entity although they have identical histological features. The expression profile of Rb and mdm2 might help distinguish the two lesions in some cases. In addition, the expression of p53 could be used as a marker for familial pheochromocytomas and paragangliomas, and might be useful in assessing the prognosis of these patients.

1 Kaye FJ. Can p53 status resolve paradoxes between human and non-human retinoblastoma models? *J Natl Cancer Inst* 1997;89:1476–77.

- 2 Xu HJ. Altered retinoblastoma (Rb) protein expression in human malignancies. *Adv Anat Pathol* 1995;2:213–26.
- 3 Haines DS. The mdm2 proto-oncogene. *Leuk Lymphoma* 1997;26:227–38.
- 4 Khosla S, Patel VM, Hay ID, et al. Loss of heterozygosity suggests multiple genetic alterations in pheochromocytomas and medullary thyroid carcinomas. *J Clin Invest* 1991;87:1691–9.
- 5 Yana I, Nakamura T, Shin E, et al. Inactivation of the p53 gene is not required for tumorigenesis of medullary thyroid carcinoma or pheochromocytoma. *Jpn J Cancer Res* 1992;83:1113–16.
- 6 Yoshimoto K, Iwahana H, Itakura M. Relatively good prognosis of multiple endocrine neoplasia type 2B in Japanese: review of cases in Japan and analysis of genetic changes in tumors. *Endocr J* 1993;40:649–57.
- 7 Lin SR, Lee YJ, Tsai JH. Mutations of the p53 gene in human functional adrenal neoplasms. *J Clin Endocrinol Metab* 1994;78:483–91.
- 8 Hagemeyer O, Gabius HJ, Kayser. Paraganglioma of the lung developed after exposure to nuclear radiation by the Chernobyl atomic reactor accident? *Respiration* 1994;61:236–9.
- 9 Dahia PL, Aguiar RC, Tsanaclis AM, et al. Molecular and immunohistochemical analysis of P53 in pheochromocytoma. *Br J Cancer* 1995;72:1211–13.
- 10 Wang DG, Johnston CF, Anderson N, et al. Overexpression of the tumour suppressor gene p53 is not implicated in neuroendocrine tumour carcinogenesis. *J Pathol* 1995;175:397–401.
- 11 Reincke M, Wachenfeld C, Mora P, et al. p53 mutations in adrenal tumors: Caucasian patients do not show the exon 4 “hot spot” found in Taiwan. *J Clin Endocrinol Metab* 1996;81:3636–8.
- 12 Ballantine DM, Klemm SA, Tunny TJ, et al. PCR-SSCP analysis of the p53 gene in tumours of the adrenal gland. *Clin Exp Pharmacol Physiol* 1996;23:582–3.
- 13 Herfarth KK, Wick MR, Marshall HN, et al. Absence of TP53 alterations in pheochromocytomas and medullary thyroid carcinomas. *Genes Chromosomes Cancer* 1997;20:24–9.
- 14 Yoshimoto T, Naruse M, Zeng Z, et al. The relatively high frequency of p53 gene mutations in multiple and malignant pheochromocytomas. *J Endocrinol* 1998;159:247–55.
- 15 Lam KY, Chan ACL, Wong WM, et al. A review of clinicopathologic features of pheochromocytomas in Hong Kong Chinese. *Eur J Surg Oncol* 1993;19:421–7.
- 16 Lam KY, Chan ACL. Paragangliomas: a comparative clinical, histologic and immunohistochemical study. *Int J Surg Pathol* 1993;1:111–16.
- 17 Lam KY, Chan ACL. Paraganglioma of urinary bladder: an immunohistochemical study and report of an unusual association with intestinal carcinoid. *Aust N Z J Surg* 1993;63:740–5.
- 18 Wenig BM, Heffess CS, Adair CF. Neoplasms of the adrenal gland. In: Wenig BM, Heffess CS, Adair CF, eds. *Atlas of endocrine pathology*. Philadelphia: WB Saunders, 1997:303–6.
- 19 Baysal BE, Ferrell RE, Willett-Brozick JE, et al. Mutations in SDHD, a mitochondrial complex II gene, in hereditary paraganglioma. *Science* 2000;287:848–51.
- 20 Miller CW, Aslo A, Won A, et al. Alterations of the p53, Rb and MDM2 genes in osteosarcoma. *J Cancer Res Clin Oncol* 1996;122:559–65.

Narrative Based Medicine, An Interdisciplinary Conference

Research, Narrative, and Practice

A two day conference—Monday 3rd and Tuesday 4th September 2001

Homerton College, Cambridge, UK

BMJ Publishing Group

For full details contact: BMA/BMJ Conference Unit, Tavistock Square, London, WC1H 9JP
Tel: +44 (0)20 7383 6819; fax: +44 (0)20 7383 6663; email: clyders@bma.org.uk.

www.quality.bmjpg.com