

# Glomerulonephropathy of Laurence-Moon-Biedl syndrome

I.K.P. Cheng, K.W. Chan, M.K. Chan, A. Kung, J. Ma and C. Wang

Departments of Medicine and Pathology, University of Hong Kong, Hong Kong.

**Summary:** A patient with Laurence-Moon-Biedl syndrome and nephrotic range proteinuria is presented. Radiological investigation of the urinary tract revealed clubbed calyces but no evidence of obstruction or vesicoureteric reflux. Renal biopsy revealed occasional sclerotic glomeruli, extensive foot-process fusion and segmental glomerular basement membrane abnormalities with negative immunofluorescence for immunoglobulins and complement. Nephrotic proteinuria responded to steroid therapy but mild proteinuria persisted. The findings were consistent with minimal change nephropathy superimposed on the glomerular lesions of Lawrence-Moon-Biedl syndrome.

## Introduction

Renal involvement is increasingly being recognized as a major manifestation of Laurence-Moon-Biedl syndrome (LMBS).<sup>1-11</sup> Early autopsy series revealed that 90% of patients with LMBS have some form of renal abnormality including cystic changes, hydronephrosis, hydronephrosis, pyelonephritis, nephrosclerosis and glomerulonephritis.<sup>1,3</sup> In addition, renal failure was considered the cause of death in up to 30% of these patients.<sup>2,5</sup>

A limited number of reports on the renal biopsy findings from patients suffering from LMBS have demonstrated characteristic glomerular and tubulointerstitial changes.<sup>5,7-9</sup> We wish to report a case of LMBS presenting with nephrotic change proteinuria which responded to steroid therapy. In this patient, renal biopsy showed an increase in mesangial matrix, segmental thickening of the glomerular basement membrane with intramembranous inclusions and extensive foot-process fusion. The clinicopathological features of the renal lesion in this patient are compared with those reported in the literature and the possible pathogenesis is discussed.

## Case report

The patient is a Chinese male born to a consanguineous marriage. He was a full term infant with a birth weight of 3200 g. Delayed developmental milestones and mental retardation were noticed

at an early age. At the age of 5, he developed an episode of ankle oedema and facial puffiness and was admitted into a private hospital where the diagnosis of 'nephritis' was made. He was treated with herbal medicine and the symptoms subsided. Progressive deterioration of vision began at about the same time and obesity was noticed at the age of 8.

He first presented at our hospital at the age of 13 because of delayed pubertal development. Physical examination revealed polydactyly in both hands and feet, obesity, retinitis pigmentosa, and infantile external genitalia. He was mentally retarded with a verbal IQ of 57 (Wechsler Intelligence Scale for Children). An oral glucose tolerance test was normal. Anterior pituitary function tests showed normal cortisol and growth hormone response to insulin hypoglycaemia, normal thyrotrophin response to thyroid stimulating hormone and normal gonadotrophin response to luteinizing hormone releasing hormone. Clomiphene stimulation up to 10 days failed to increase the serum luteinizing hormone and follicular stimulating hormone level and the human chorionic gonadotrophin stimulation test revealed a subnormal testosterone response. Chromosomal analysis showed a karyotype of 46XY. The results of the endocrine investigations were consistent with normal function of the hypothalamic-pituitary-gonadal axis in a prepubertal male. Urinalysis, serum electrolytes, urea, creatinine, uric acid, cholesterol and triglyceride were normal. A water deprivation test showed that he was able to concentrate his urine normally. An intravenous pyelogram revealed normal size kidneys with good excretion of contrast and bilateral blunt-

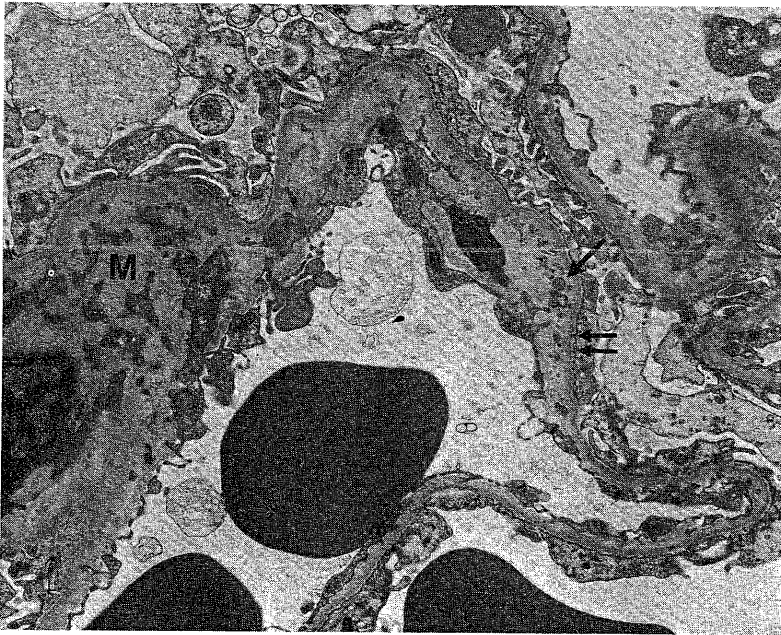
Correspondence: I.K.P. Cheng, Department of Medicine, Queen Mary Hospital, Hong Kong  
Accepted: 16 March 1988

ing of all calyces. He was followed up in the endocrine outpatient department and full pubertal development was observed at the age of 19.

At the age of 23, routine urinalysis first documented glycosuria and albuminuria and the patient was admitted for further investigations. Physical examination confirmed that, except for normal sexual development, the patient had all the clinical features of LMBS. His height was 168.7 cm and his weight was 94.5 kg. Peripheral oedema was absent. Blood pressure was within normal limits. Laboratory investigations showed normal routine haematology, serum electrolytes, proteins, cholesterol and mildly abnormal liver function tests. The serum urea was 7.9 mmol/l, creatinine 0.19 mmol/l, urine microscopy was normal, fasting blood sugar 8.1 mmol/l and Hb<sub>A1</sub> 11.1%. Hepatitis B surface antigen was positive. The urine protein excretion was 9.2 g/day and the creatinine clearance was 54 ml/min. Antinuclear factor was negative and serum complement (C3 and C4) and immunoglobulin levels were all within normal limits. An intravenous urogram (IVU) revealed normal size kidneys with smooth outlines. Although the pelvicalyceal systems were not dilated, there was bilateral blunting of all calyces. A micturating cystogram revealed no vesico-ureteric reflux.

To investigate further the cause of the nephrotic range proteinuria, a renal biopsy was done under X-ray screening. The biopsy consisted of subcapsular cortex with 11 glomeruli. One glomerulus showed global sclerosis. The other glomeruli had no significant light microscopic changes. In particular, there was no mesangial proliferation or increase in mesangial matrix. The interlobular arteries appeared unremarkable. A few tubules were atrophic but there was no significant interstitial cellular infiltrate or fibrosis. Immunofluorescence staining for IgG, IgA, C<sub>3</sub>, Clq was negative. Staining for IgM was equivocal. Electron microscopy confirmed the absence of mesangial proliferation but showed an increase of mesangial matrix (Figure 1). Foot-process fusion was extensive (Figure 1). Diffuse thickening of the lamina densa of the glomerular basement membrane (GBM), as in diabetic glomerulosclerosis, was absent. However, segmental GBM thickening was present along with segments of widened lamina rara interna. Occasional granular inclusion bodies were found in the widened lamina rara interna (Figure 1).

Steroid treatment was started at a dose of 60 mg daily after further documentation of nephrotic proteinuria. This dose was maintained for 5 weeks after which steroid was gradually tailed off over the



**Figure 1** The glomerular basement membrane shows well formed lamina densa. The lamina rara interna has irregular thickening and contains lumpy and granular electron dense inclusions (single arrow). The epithelial foot processes are extensively effaced (double arrows). The mesangium (M) shows an increase of mesangial matrix.

Table I Renal biopsy glomerular pathology in patients with LMBS

No.	Age in years* (sex)	Presenting symptoms referable to urinary system†	24-hour urine protein (g)	Glomerular pathology‡		References (see text)
				Light microscopy	Electron microscopy	
1	16 (F)	Recurrent urinary tract infection	0.912	↑Mes cell + matrix	Irregular GBM thickness, effacement of trilaminar structure, intramembranous inclusions	9
2	38 (F)	Asymptomatic proteinuria	0.128	↑Mes cell + matrix		
3	9 (F)	Renal impairment	0.160	↑Mes matrix + sclerosis		
4	35 (M)	Asymptomatic proteinuria	2.3	↑Mes matrix + sclerosis		
5	1 (-)	Not stated	-	↑Mes tissue		
6	14 (-)	Hypertension	-	↑Mes cell + sclerosis		
7	11 (-)	Renal failure	-	↑Mes cell + sclerosis		
8	8 (-)	Hypertension	-	↑Mes cell + sclerosis		
9	1/12 (F)	Nephrogenic diabetes insipidus	-	Normal		
10	4 (F)	Nephrogenic diabetes insipidus	-	Normal		10
11	1/12 (M)	Nephrogenic diabetes insipidus	-	Normal	10	
12	1/2 (M)	Recurrent urinary tract infection	-	Diffuse hypercellularity	Endothelial cell swelling, subendothelial scalloping of GBM	7
PC	23 (M)	Asymptomatic proteinuria	9.2	↑Mes matrix + sclerosis	Irregular GBM thickness, intramembranous inclusions	

\*Age at diagnosis of renal involvement; †All patients had IVU done which revealed bilateral blunting of all calyces. Patient 12 also had vesicoureteric reflux on micturating cystogram; ‡Immunofluorescence microscopy was negative in all cases; Mes = Mesangial; PC = present case

next 6 weeks. Proteinuria decreased from the pre-treatment level of 9 g/day to 0.74 g/day by 2 months after steroid therapy. Serum creatinine increased slightly to 0.290 mmol/l at 1 month after steroid treatment but stabilized at 0.220 mmol/l. Serum albumin and cholesterol remained within the normal limits while the blood sugar level was maintained in the upper limit of normal with metformin 250 mg twice a day. At the last follow-up 16 months after steroid therapy, the serum creatinine was 0.200 mmol/l, 24 hour urine protein was 0.4 g/day and his blood sugar level remained within the normal range after cessation of metformin.

### Discussion

The clinicopathological features of the renal lesion in the present case and in other published cases, in which detailed information of the renal biopsy findings are available, are shown in Table I. Glomerular lesions which have been described include mesangial proliferation and sclerosis, increase in mesangial matrix and ultrastructural GBM abnormalities. The basis of these glomerular abnormalities in LMBS is unclear at present. The hereditary nature of LMBS and the GBM changes would suggest a metabolic defect affecting the GBM. On the other hand, the glomerular abnormalities may be secondary to pelvicalyceal abnormalities which are frequently demonstrated in patients with LMBS.

Nephrotic range proteinuria is unique to our present case. Whether the nephrotic proteinuria is part of LMBS or is coincidental is debatable. Although ultrastructural GBM abnormalities were found in our patient, they are unlikely to be the cause of nephrotic proteinuria as similar abnormalities were found in non-nephrotic patients with LMBS (Table I). However, they may explain the residual proteinuria which was still present in our patient after steroid-induced remission. As the patient was also found to have diabetes mellitus at the time proteinuria was discovered, the suggestion may be

made that the nephrotic proteinuria is secondary to diabetes mellitus. However, the very mild nature of his diabetes together with the lack of histological evidence of diabetic nephropathy strongly argues against the latter being the cause of proteinuria in this patient. The presence of abnormal serum liver enzymes and hepatitis B antigenaemia may also suggest that the proteinuria is related to hepatitis B infection but the histological pattern of glomerular involvement in this patient is not typical of that in hepatitis B-associated glomerulonephropathy which are usually membranous or mesangiocapillary in type.<sup>12</sup> The nephrotic range proteinuria may be secondary to minimal change nephropathy, or, in view of the finding that 1 of 11 glomeruli is sclerotic, to focal global sclerosis. The presence of a childhood history of nephritis, the demonstration of extensive epithelial foot-process fusion in the renal biopsy and steroid responsiveness are consistent with both diagnoses. However, the histological findings in this patient do not satisfy Habib's criteria for the diagnosis of focal global sclerosis in idiopathic nephrotic syndrome.<sup>13</sup> The latter require the presence of >15–20% of glomeruli to be affected by global sclerosis together with tubulointerstitial scarring in a renal biopsy obtained from a patient in whom the diagnosis of minimal change nephropathy would otherwise be made. Furthermore, occasional sclerotic glomeruli have been found in the renal biopsies from some non-nephrotic patients with LMBS (Table I) and these changes may be secondary to accelerated glomerular drop out consequent upon GBM or pelvicalyceal abnormalities.

Having considered the various possibilities, we concluded that this patient most likely has minimal change nephropathy superimposed on the renal lesion of LMBS. Whether patients with LMBS are more prone to develop minimal change nephropathy or that the two conditions are merely found coincidentally cannot be determined in the present report. However, the occurrence of minimal change nephropathy in a patient with LMBS highlights the importance of careful clinical, laboratory and renal biopsy assessment of patients with LMBS presenting with nephrotic range proteinuria.

### References

1. McLoughlin, T.G. & Shanklin, D.R. Pathology of Laurence–Moon–Bardet–Biedl syndrome. *J Pathol Bact* 1967, **93**: 65–79.
2. Nadjmi, B., Flanagan, M.J. & Christian, J.R. Laurence–Moon–Biedl syndrome associated with multiple genitourinary tract anomalies. *Am J Dis Child* 1969, **117**, 352–356.
3. Bauman, M.L. & Hogan, G.R. Laurence–Moon–Biedl syndrome: report of two unrelated children less than 3 years of age. *Am J Dis Child* 1973, **126**: 119–126.
4. Alton, D.J. & McDonald, P. Urographic findings in the Bardet–Biedl syndrome. *Radiology* 1973, **109**: 659–663.

5. Henley, R.M., Dery, P., Nogrady, M.B. & Drummond, K.N. The renal lesion of the Laurence-Moon-Biedl syndrome. *J Pediatr* 1975 **87**: 206-209.
6. Bluett, N.H., Chantler, C., Singer, J.D. & Saxton, H.M. Congenital renal abnormalities in the Laurence-Moon-Biedl syndrome. *Arch Dis Child* 1977, **52**: 968-979.
7. Falkner, B., Langman, C. & Katz, S. Renal histopathological changes in a child with Laurence-Moon-Biedl syndrome. *J Clin Pathol* 1977, **30**: 1077-1081.
8. Churchill, D.N., McManamon, P. & Henley, R.M. Renal disease - a sixth cardinal feature of the Laurence-Moon-Biedl syndrome. *Clin Nephrol* 1981, **16**: 151-154.
9. Price, D., Gartner, J.G. & Kaplan, B.S. Ultrastructural changes in the glomerular basement of patients with Laurence-Moon-Biedl-Bardet syndrome. *Clin Nephrol* 1981, **16**: 283-288.
10. Tiedler, M., Levy, M., Gubler, M.C., Gagnadoux, M.F. & Broyer, M. Renal abnormalities in the Bardet-Biedl syndrome. *Int J Pediatr Nephrol* 1982, **3**: 199-203.
11. Srinvas, V., Windsor, G.M. & Dow, D. Urological manifestation of Laurence-Moon-Biedl syndrome. *Urology* 1983, **21**: 581-583.
12. Levy, M., Kleinknecht, C., Droz, D. & Druke, T. Glomerular nephropathies and hepatitis-B virus infection. *Adv Nephrol* 1982, **11**: 341-370.
13. Habib, R. Focal glomerular sclerosis. *Kidney Int* 1973, **4**: 355-361.