

Cerebral radionecrosis: is surgery necessary?

E WOO, K LAM, Y L YU, P W H LEE,* C Y HUANG

From the Departments of Medicine and Psychiatry, University of Hong Kong, Queen Mary Hospital, Hong Kong*

SUMMARY Seven patients with cerebral necrosis after radiotherapy for carcinoma of the nasopharynx are presented. The clinical features included seizures and a varying degree of intellectual impairment. In spite of significant mass effect on CT scan, the patients remained alert, ambulatory and independent. We believe that some cases of cerebral necrosis following radiotherapy for extracranial neoplasms present in a more benign fashion than has been portrayed in the literature, and in the absence of clinical evidence of raised intracranial pressure, surgical intervention is unnecessary. The importance of careful fractionation of an optimum radiation dose as a preventive measure is emphasised.

Cerebral necrosis is an infrequent but a significant complication of radiation therapy of extracranial tumours. The exact frequency is unknown although one review¹ suggested an incidence varying from 0.5% to 25%. It has become increasingly apparent that patients treated with radiation therapy for extracranial neoplasms who present with neurological dysfunction are more likely to have radionecrosis of the brain than metastatic tumour. Although the definitive diagnosis can only be established by surgical exploration or biopsy of the lesion, it can be strongly suspected from computed tomographic (CT) findings.^{2,3}

Review of the literature indicates that delayed cerebral radionecrosis constitutes in the majority of instances a life-threatening and often fatal expanding intracranial mass, necessitating surgical treatment such as wide excision or lobectomy. Spontaneous remission is exceedingly rare, having been reported in one case so far,⁴ but even in this case, it appears that the changes are more of an early-delayed encephalopathy rather than the late-delayed radiation necrosis.⁵ It has also been repeatedly stated^{3,6} that surgical excision is the treatment of choice in this clinical entity.

Over the past 4 years, we have encountered seven patients who, after radiotherapy for carcinoma of the nasopharynx, developed cerebral radionecrosis docu-

mented on serial CT studies and who survived without surgery. They are all alive and ambulatory after an interval varying from 2 to 8 years from the diagnosis of cerebral radionecrosis. Our experience suggests that there is a more benign variant in the clinical spectrum of this pathological entity and that surgical excision is not necessarily the optimal form of therapy.

Patients and methods

From 1982 to 1986, seven patients were seen in our unit because of neurological dysfunctions secondary to radiotherapy for nasopharyngeal carcinoma. All were in clinical remission 4 to 13 years after external radiotherapy. With the exception of one patient (Patient 6) who was treated in China and whose radiation dosimetry was unknown, radiotherapy to the nasopharynx in the other six was delivered by linear accelerators producing photons or betatrons through a pair of parallel opposed lateral facial fields (fig 1A) supplemented by an anterior facial field with the eyes shielded. Two of these six patients (Patients 2 and 7) received a second course of radiotherapy to the nasopharyngeal region for local recurrence. Five patients received additional radiotherapy to cervical lymph nodes via an anterior cervical field at the time of initial diagnosis.

From 1976 to 1980 (years in which our patients received radiotherapy), the Radiotherapy Department treated 80-100 new patients per year. During this period, the routine dosimetry to the nasopharynx was 420 rad twice weekly to a total of 5040 rad. With this dosimetry, the estimated dose for the temporal lobe was 4100 to 5950 rad (fig 1B), based on an equivalent of 200 rad per fraction, five fractions per week.

CT scans of the brain were performed in all patients at the time of initial neurological consultation and at varying intervals upon follow-up.

Address for reprint requests: Dr E Woo, University Department of Medicine, Queen Mary Hospital, Hong Kong.

Received 18 November 1986 and in revised form 12 May 1987.
Accepted 22 May 1987

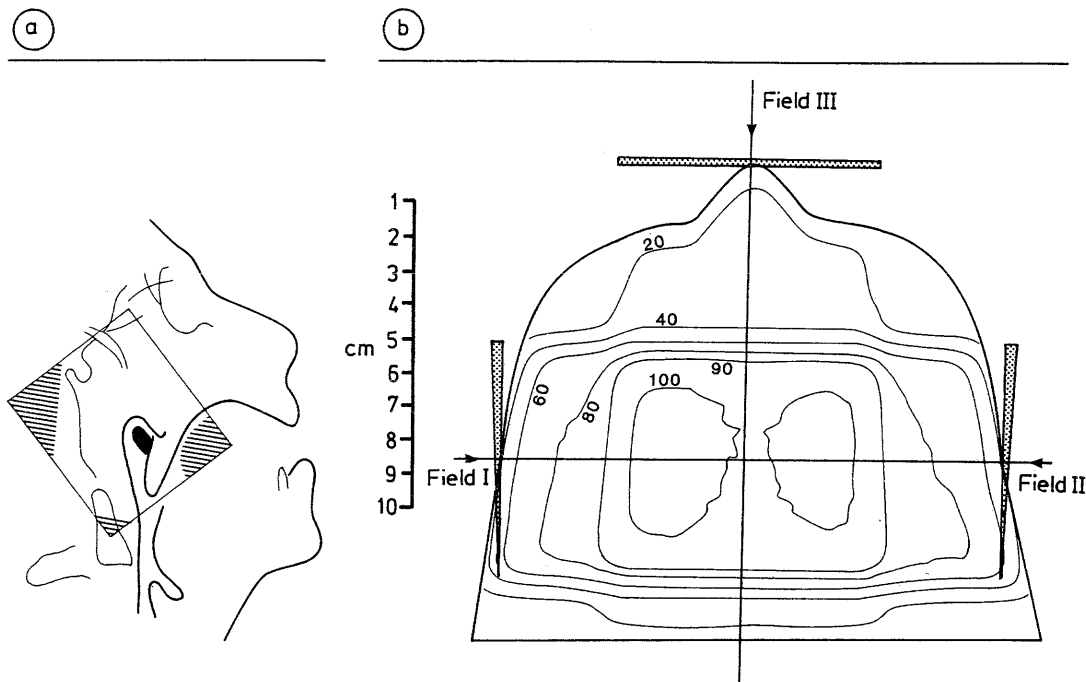


Fig 1 (A) Lateral facial field for radiotherapy of NPC. The shaded areas are shielded. (B) Isodose curve at a plane parallel to the level of the floor of the middle cranial fossa. 100% = 5950 rad.

Results

The clinical and CT data are summarised in Tables 1 and 2 respectively. There were five men and two women with a median age of 43 years (range 32–63). The total dose delivered to the nasopharynx ranged from 5040 to 10320 rad (table 1). Neurological dys-

function started 44 to 105 months (median 60 months) after the initial radiotherapy, with six of the patients presenting within 72 months.

Clinical features (table 1)

Six patients had seizures of which five were complex partial with or without generalisation, and one was a

Table 1 Clinical data of the 7 patients

Patient	Sex/ Age (yr)	RT dose to nasopharynx (rad/fraction/days) (yr)	Interval between 1st RT and symptoms (months)	Neurological findings						MMSE score	Working capacity	EEG	Survival from neurological dysfunction (months)
				Seizure	Cognitive deficit	Memory loss	Personality change	Emotional lability					
Group 1:													
1	M/56	5040/12/38 (1980)	46	+	-	-	-	-	30	Retained	L temporal spike	24 ⁺	
2	F/43	5040/12/38 (1980) 4000/8/28 (1982)	44	+	-	+	-	-	28	Retained	Normal	30 ⁺	
3	F/40	5040/12/38 (1980)	47	+	-	+	+	+	28	Retained	Not done	28 ⁺	
4	M/48	5040/12/38 (1976)	63	+	-	-	+	+	30	Retained	Bitemporal spike	53 ⁺	
Group 2:													
5	M/34	5320/26/38 (1976)	72	+	+	+	+	-	19	Lost	L temporal delta	42 ⁺	
6	M/32	unknown (1973)	60	-	+	+	+	-	20	Lost	R temporal delta	96 ⁺	
7	M/63	5320/27/43 (1973) 5000/20/37 (1981)	105	+	+	+	+	+	11	Lost	Bitemporal delta	54 ⁺	

+ = present, - = absent, L = left, R = right, MMSE = Mini-Mental State Examination.⁷

Table 2 Serial CT findings in the 7 patients

Patient	Initial CT			Follow-up CT			Interval between 2 CTs (months)	Change
	Hypodensity in temporal lobe	Mass effect	Contrast enhancement	Hypodensity in temporal lobe	Mass effect	Contrast enhancement		
1	L moderate; R small	±	++	L minimal; R minimal	-	-	17	almost complete resolution of hypodense areas, resolution of mass effect, loss of contrast enhancement
2	R severe, with extension into frontal and parietal lobes; L small	++	+	R moderate; L small	±	+	27	decrease in size of hypodense area, decreased mass effect
3	L moderate; R small	+	-	L moderate; R small	+	-	21	none
4	R moderate	-	+	R moderate	-	-	12	decreased contrast enhancement
5	L severe; R moderate	-	-	L severe; R moderate	-	-	29	none
6	R severe; L small	-	-	R severe; L small	-	-	20	none
7	L severe	+	+	L severe	+	+	52	none

L = Left; R = Right; ++ = Severe; + = Moderate; ± = Minimal; - = Absent.

nonfocal tonic-clonic convulsion. These were well controlled with monotherapy of anticonvulsants.

Five patients had amnesia for recent events which progressed over the one to two years of follow-up. The amnesia was associated with significant cognitive and intellectual impairment in three patients. Abstract thinking, problem solving and verbal reasoning were impaired. They all scored 20 or below in the Mini-Mental State Examination⁷ and all had lost their capacity for work. A change in personality was observed in five patients and emotional lability in three.

Overall, our patients fall into two main groups: group 1 (Patients 1, 2, 3 and 4) with minimal cognitive abnormality and often with seizures only, and group 2 (Patients 5, 6 and 7) with marked intellectual, memory and behavioural disturbances with resultant limitation of working capacity in addition to seizures. Between the two groups, there was no significant difference with respect to the age of the patient, the dose of radiotherapy, the laterality or severity of the

patients. The pattern was usually mild, patchy and irregular; there was suggestion of ring enhancement in one patient only (fig 2A).

CT was repeated after an interval of 12 to 52 months. There were no changes in four patients (fig 4B). Improvement was seen in three (Patients 1, 2 and 4). In Patient 1, the hypodense area in the left temporal lobe had shrunk considerably; there was also loss of mass effect and contrast enhancement (fig 2C and D). In Patient 2, although the hypodense area persisted in the temporal lobe, the mass effect had decreased (fig 3C and D). Patient 4 showed decreased contrast enhancement although the size of the hypodense area was unchanged. None of these three patients had received steroids.

Therapy and follow-up

As our patients did not present with raised intracranial pressure, surgery was not considered to be indicated. Instead, they were closely followed-up with symptomatic treatment.

Corticosteroid therapy was attempted in three patients (Patients 3, 6 and 7) for periods up to 3 months but alteration in the clinical course was not observed. Unfortunately CT were not repeated immediately after treatment so that it was not possible to assess any radiological change. However, of the three patients who showed radiological improvement, none had received steroids. One of these three (Patient 1) improved clinically and he was seizure-free without any medication. In the other two (Patients 2 and 4),

CT changes (table 2)

In all patients, CT scan at the time of presentation showed hypodensity in the temporal lobes (figs 2A and B, 3A and B, 4A), being bilateral in five and unilateral in two. In one patient (fig 3B), the hypodense area extended into the adjacent portions of the frontal and parietal lobes. Mass effect was observed in four patients, severe in one and mild to moderate in three others. Contrast enhancement was seen in four

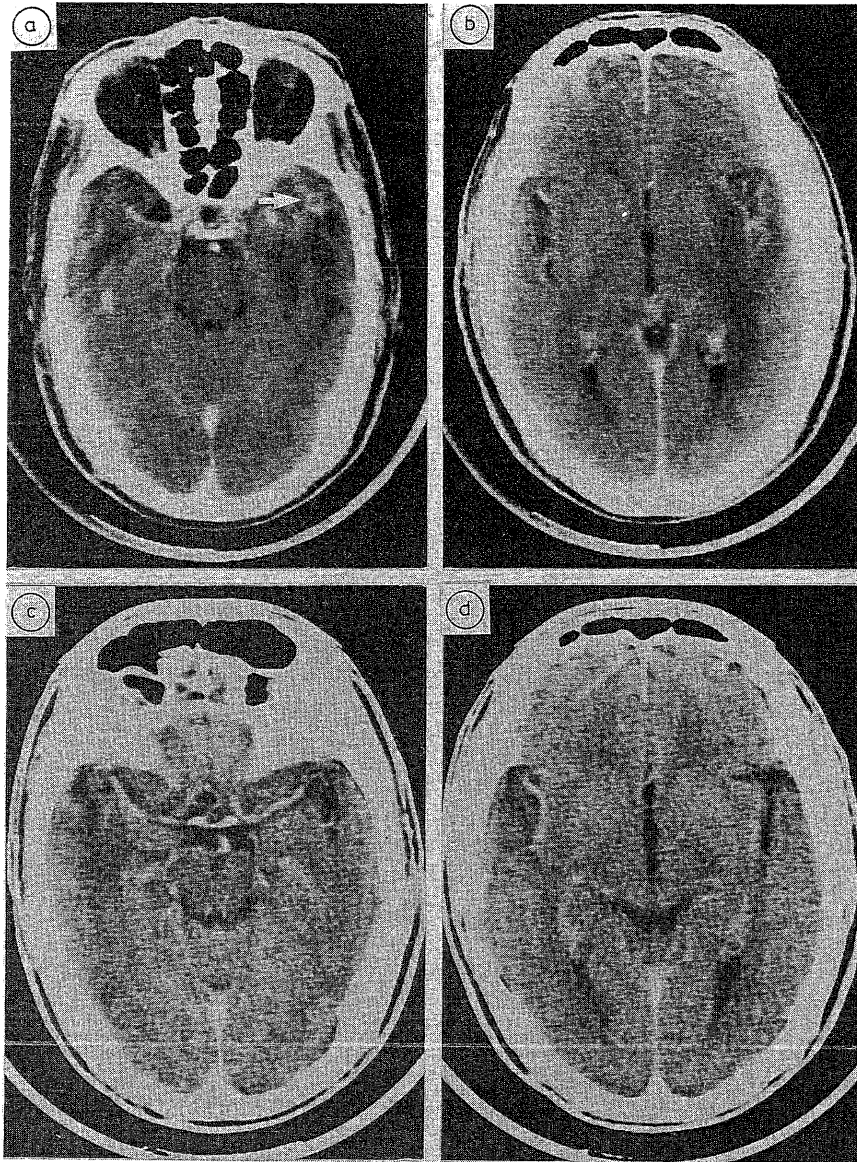


Fig 2 Patient 1. (A, B) Initial CT scan showing a left temporal hypodense area with minimal mass effect. Patchy contrast enhancement with suggestion of a ring pattern (arrow) was present. A small area of decreased attenuation was also present in the right temporal tip without any mass effect or enhancement. (C, D) Follow-up CT scan 17 months later showing almost complete resolution of the left temporal hypodensity with loss of mass effect and contrast enhancement. The right temporal hypodensity had remained relatively unchanged.

despite radiological improvement, cognitive and memory deficits progressed.

Survival from first neurological symptoms ranged from 24 to 96 months (median 42). All are alive and ambulatory at the time of writing. Four remain active

and functional despite a mild degree of cognitive or motor deficit present in three of them. Three patients, however, are unable to continue their previous occupation although still capable of managing their own activities of daily living.

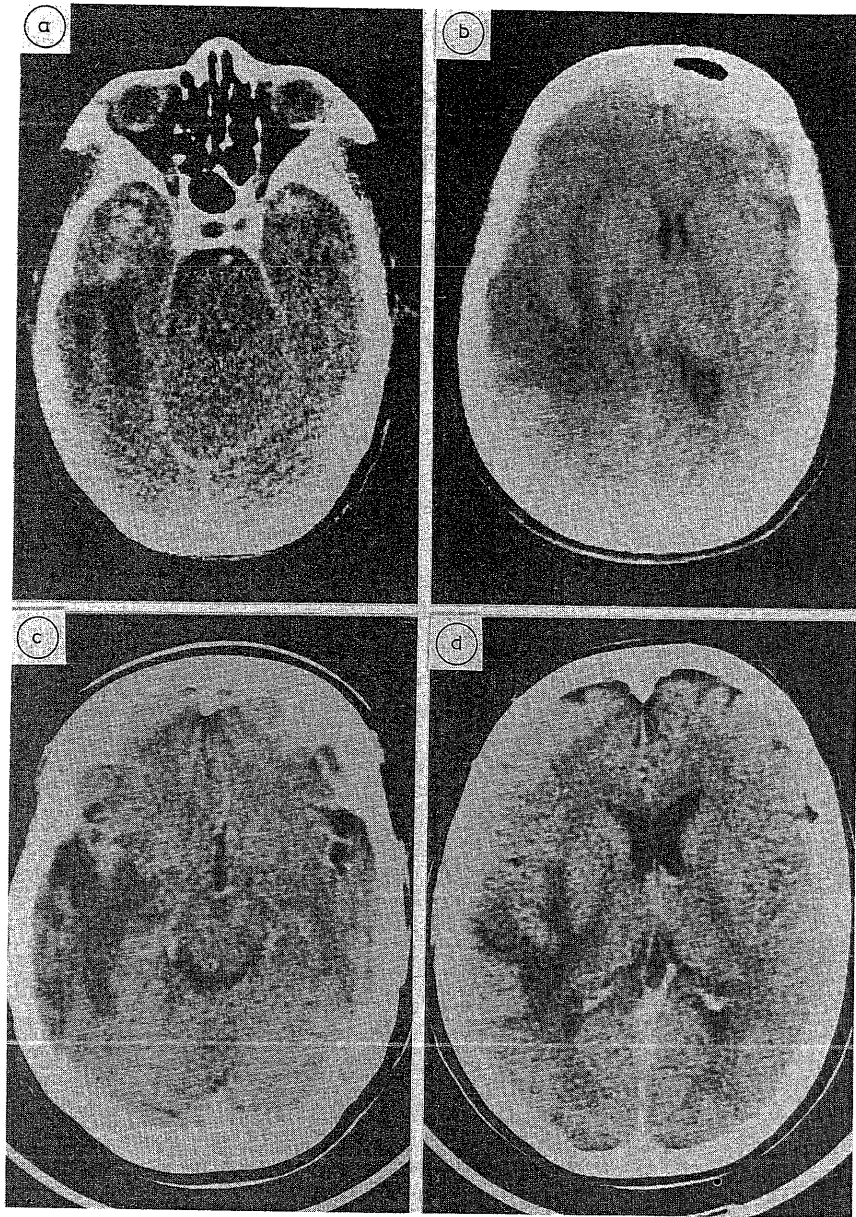


Fig 3 Patient 2. (A, B) Initial CT scan showing a large right temporal hypodense area extending into adjacent portions of the frontal and parietal lobes. There was significant mass effect with midline shift and brain swelling; irregular contrast enhancement was present at the anterior temporal region. (C, D) Follow-up CT scan 27 months later showing a mild decrease in the size of the right temporal hypodense area. Mass effect was much reduced. Contrast enhancement was unchanged.

Illustrative case histories

Case 2 This 43 year old hair-stylist received in January 1980 for her nasopharyngeal carcinoma 5040 rad to the

nasopharynx. Local recurrence 2 years later in 1982 was treated with an additional 4000 rad. In January 1984, 44 months after completion of her first course of radiotherapy

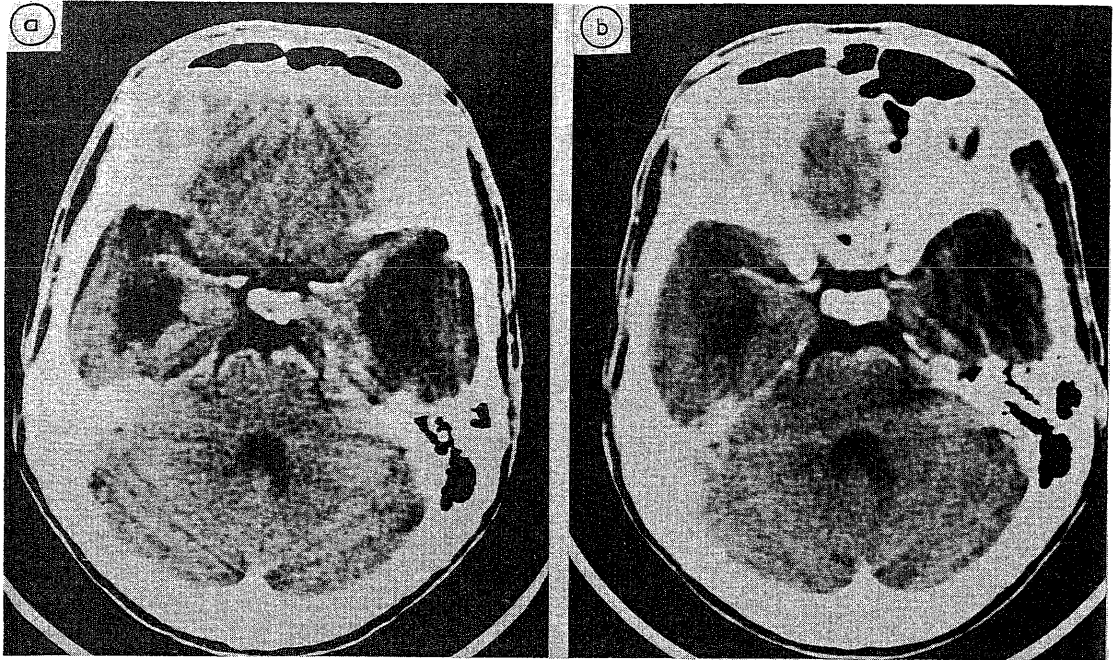

Fig 4 Patient 5. (A) Initial CT scan showing bilateral temporal hypodense areas, more severe on the left than right. There was no mass effect or contrast enhancement. (B) Follow-up CT scan 29 months later showed no significant change.

and 15 months after the second course, she experienced repeated episodes of complex partial seizures in the form of visual and olfactory hallucinations. EEG was normal. CT scan (fig 3A and B) showed a large area of hypodensity involving the right temporal lobe with extension into the frontal and parietal lobes, as well as significant mass effect and patchy contrast enhancement. A small area of decreased attenuation was also present in the left temporal lobe without mass effect. Over the next 2 years, although her seizures were well controlled with carbamazepine only, she noticed gradual amnesia. Repeat CT 27 months later (fig 3C and D) showed that the area of decreased attenuation in the right temporal lobe was mildly reduced in size but the mass effect was much decreased. In spite of these alarming CT appearances, she remained in gainful employment and was fully functional in her daily activities.

Case 5 This 34 year old man had nasopharyngeal carcinoma diagnosed in 1976 and he received 5320 rad to the nasopharynx. Regular follow-up showed no recurrence. Six years later, he began to experience recurrent nonfocal tonic-clonic seizures partially controlled with phenytoin. When first seen in 1984, he was noted to have significant memory loss with a change in personality. He became withdrawn, passive and dependent. CT (fig 4A) showed bitemporal hypodensities, more severe on the left, without any mass effect or contrast enhancement. EEG showed delta slowing in the left temporal region. Over the next 2 years, he became progressively demented to the point that he was unable to carry on with his occupation, although he could look after himself in his activities of daily living. Repeat CT 29 months later (fig 4B) showed no interval change.

Discussion

Although there was no definitive histological proof, there is little doubt that the radiological changes seen on CT in our patients represent radiation necrosis. These changes are compatible with descriptions in previous reports.²⁻⁸ Moreover, there is no evidence of tumour recurrence in our patients and the course of events in a long follow-up period supports the diagnosis.

Reported cases in the literature^{1,3,6,9-13} have documented cerebral radionecrosis as a progressive space-occupying lesion presenting with evolving neurological deficits over weeks or months. Patients eventually become obtunded as a result of the raised intracranial pressure. Surgical excision has been recommended as the treatment of choice of this clinicopathological entity. Takeuchi *et al*¹¹ reviewed eight cases in the literature up to 1975 among which surgical resection cured or improved five patients. Three other patients who did not have surgery deteriorated and died. The authors went further to suggest that as allergic involvement may play a role, surgical excision eliminates the antigen and diminishes the speed of the necrotising process in the brain. Di Lorenzo *et al*¹ showed that of 24 cases subjected to surgical treatment, 19 benefited, two remained unchanged and three deteriorated or died, whereas of 10

treated nonsurgically, only one improved, one remained unchanged and eight deteriorated or died. Glass *et al*³ presented nine patients with cerebral necrosis following radiation therapy for extracranial neoplasms. Three of these had completely normal neurological examination. Although the outcome of surgery in six of their patients was only vaguely documented, these authors recommended surgical removal of the necrotic lesion.

Our experience, however, indicates that cerebral radionecrosis may present differently. Seizures in our patients were not difficult to control. Cognitive dysfunction was often mild with no limitation of working ability. Serial CT also confirmed the favourable prognosis, showing spontaneous radiological improvement in three and no significant interval changes in four. Moreover, in spite of these alarming CT appearances with extensive hypodense areas and mass effect, features of raised intracranial pressure are conspicuously absent in our patients. Surgical removal of the necrotic mass is most unlikely to improve on the cognitive and intellectual abnormalities¹⁴; in addition, unless the seizures from a unilateral temporal lesion are poorly controlled with medical therapy, temporal lobectomy is not indicated.

Why did our patients behave differently? The anatomical site appears not to affect outcome, as the review by Di Lorenzo *et al*¹ indicated that survival was not influenced by whether the lesion was temporal or frontal. Neither was the radiation dose in our patients unusual; Glass *et al*³ in reviewing 68 cases showed that the incidence was much increased once the lesion dose exceeded 4500 rad. However, the latency from the radiotherapy to the onset of neurological symptoms appeared to be of significance. Kramer *et al*¹⁵ showed that cerebral radionecrosis developed within 3 years of radiation in 74% of patients. Marks *et al*¹⁶ reported a median interval of 14 months between completion of irradiation and development of cerebral radionecrosis. Glass *et al*³ showed that 80% of the cases of radionecrosis occurred within 36 months of radiotherapy. The latency in our patients ranged from 44 to 105 months with a median of 60 months. Such a long interval may indicate that the changes of radionecrosis are evolving in a more indolent fashion so that the brain is capable of tolerating such chronic alterations without potentially fatal acute elevation of intracranial pressure. While the above factor(s) may explain the difference in behaviour in our patients, it must be pointed out that the paucity of "mild" cases in the literature may be more apparent than real as a result of under-reporting. Most reported cases^{1 3 6 9-11} were diagnosed at operation or autopsy and not by CT, and these are of necessity severe and progressive cases.

With the increasing use of CT in the investigation of neurological problems following radiotherapy, more mild cases are likely to be encountered.

Perhaps more important is the prevention of radionecrosis. Proper shielding is one obvious measure, but in the case of nasopharyngeal carcinoma, it is practically impossible to completely shield the temporal lobes which lie directly within the radiation ports. An essential factor is the total dose of radiation and its fractionation.¹⁷ Two of our patients were irradiated twice up to 9000 to 10000 rad and it is not surprising that they developed this complication. Of the remaining four patients with known dosimetry, the total tumour dose was between 5000 and 5500 rad. However, three of these four patients received a fractionated dose of 420 rad. It has been pointed out that the fraction size should not exceed 200 rad per day, and the risk-to-benefit ratio of radiotherapy becomes increasingly unfavourable when the standard brain tumour dose of 5000 to 7000 rad is fractionated at greater than 200 rad per day.^{17 18} It is therefore essential that a proper fractionation of the radiation dose be given to minimise the incidence of radiation necrosis, a potentially fatal and disabling, yet largely preventable, complication.

We thank the Institute of Radiotherapy and Oncology, Medical and Health Department, Hong Kong for referring their patients, and Mrs Shirla Tam for secretarial assistance.

References

- 1 Di Lorenzo N, Nolletti A, Palma L. Late cerebral radionecrosis. *Surg Neurol* 1978;**10**:281-90.
- 2 Mikhael MA. Radiation necrosis of the brain: correlation between computed tomography, pathology, and dose distribution. *J Comput Assist Tomogr* 1978;**2**:71-80.
- 3 Glass JP, Hwang T-L, Leavens ME, Libshitz HI. Cerebral radiation necrosis following treatment of extracranial malignancies. *Cancer* 1984;**54**:1966-72.
- 4 Yamashita J, Handa H, Yumitori K, Abe M. Reversible delayed radiation effect on the brain after radiotherapy of malignant astrocytoma. *Surg Neurol* 1980;**13**:413-7.
- 5 Lampert PW, Davis RL. Delayed effects of radiation on the human central nervous system. "Early" and "late" delayed reactions. *Neurology* 1964;**14**:912-7.
- 6 Rottenberg DA, Chernik NL, Deck MDF, Ellis F, Posner JB. Cerebral necrosis following radiotherapy of extracranial neoplasms. *Ann Neurol* 1977;**1**:339-57.
- 7 Folstein MF, Folstein SE, McHugh PR. "Mini-mental state". A practical method for grading the cognitive state of patients for the clinician. *J Psychiatr Res* 1975;**12**:189-98.
- 8 Kingsley DPE, Kendall BE. CT of the adverse effects of therapeutic radiation of the central nervous system. *AJNR* 1981;**2**:453-60.

- 9 Eyster EF, Nielson SL, Sheline GE, Wilson CB. Cerebral radiation necrosis simulating a brain tumor. *J Neurosurg* 1974;**39**:267-71.
- 10 Kusske JA, Williams JP, Garcia JH, Pribram HW. Radiation necrosis of the brain following radiotherapy of extracerebral neoplasms. *Surg Neurol* 1976;**6**:15-20.
- 11 Takeuchi J, Hanakita J, Abe M, Handa H. Brain necrosis after repeated radiotherapy. *Surg Neurol* 1976;**5**:89-93.
- 12 Littman P, James H, Zimmerman R, Slater R. Radionecrosis of the brain presenting as a mass lesion: a case report. *J Neurol Neurosurg Psychiatry* 1977;**40**:827-9.
- 13 Matsumura H, Ross ER. Delayed cerebral radionecrosis following treatment of carcinoma of the scalp: clinicopathologic and ultrastructural study. *Surg Neurol* 1979;**12**:193-204.
- 14 Fontana M, Mastrostefano R, Bernabei A, *et al.* Bilateral temporal lobectomy for late radionecrosis after radiotherapy for acromegaly. *J Neurosurg Sci* 1984;**28**:107-12.
- 15 Kramer S, Southard ME, Mansfield CM. Radiation effect and tolerance of the central nervous system. *Front Rad Ther Oncol* 1972;**6**:332-45.
- 16 Marks JE, Baglan RJ, Prasad SC, Blank WF. Cerebral radionecrosis: incidence and risk in relation to dose, time, fractionation and volume. *Int J Radiat Oncol Biol Phys* 1981;**7**:243-52.
- 17 Kramer S. The hazards of therapeutic irradiation of the central nervous system. *Clin Neurosurg* 1968;**15**:301-18.
- 18 Martins AN, Johnston JS, Henry JM, Stoffel TJ, di Chiro G. Delayed radiation necrosis of the brain. *J Neurosurg* 1977;**47**:336-45.