

# The role of transesophageal echocardiography in the diagnosis and management of children and young adults with valvar diseases of the left heart

Maurice P. Leung, Tak-Cheung Yung, Bobby Chan, Clement Chiu, Jan Lee and Che-Kueng Mok

*From the Department of Paediatrics and Surgery, The Grantham Hospital, University of Hong Kong, Hong Kong*

**Summary** The role of transesophageal echocardiography in the diagnosis and management of left-sided cardiac valvar disease in children and young adults was assessed in terms of whether additional information (over transthoracic echocardiography) could be obtained, and whether the added information contributed to the better management of the patients. Between January 1991 to August 1992, 27 consecutive patients were studied. Their age ranged from 2.5 to 20 years (mean 12.7), with body weights ranging between 12 and 60 kg (mean 35.6). Twelve of the children suffered from atrioventricular valvar disease, 13 had predominant aortic valvar lesions and two had mixed valvar pathologies. Additional information was obtained by transesophageal over that of transthoracic echocardiography in 18 children (67%). Transesophageal echocardiography clarified the etiologies or mechanism of valvar regurgitation in eight and seven children with atrioventricular and aortic pathologies, respectively. The technique correctly diagnosed severe mitral regurgitation underestimated by conventional technique, detected a missed eccentric aortic regurgitant jet and convincingly excluded bacterial vegetations in one case each. The investigation contributed to the better management of three children (11%) by providing information that allowed the appropriate choice of therapy. Transesophageal echocardiography, therefore, is a useful technique for the diagnosis and management of valvar disease of the left heart in children and young adults.

Key words: Transesophageal echocardiography; mitral valve; aortic valve

**T**HE DIAGNOSIS AND EVALUATION OF VALVAR DISEASES have, in the past, largely depended on cardiac catheterization and angiography.<sup>1,2</sup> Recently, transthoracic echocardiography has provided a non-invasive and definitive assessment for these valvar abnormalities.<sup>3,4</sup> The introduction of transesophageal echocardiography now produces an acoustic window in close proximity to the heart which results in better definition of the pathology. The technique is now widely applied to study the mitral and aortic valves in adults.<sup>5-8</sup> The examination is also used to study various

congenital heart diseases in children.<sup>9-11</sup> In this study, we evaluate the role of transesophageal echocardiography in the diagnosis and management of children and young adults suffering from valvar diseases of the left heart.

## Materials and methods

Between January 1991 to August 1992, 27 consecutive patients who had clinical evidence for valvar diseases of the left heart were assessed and judged to require further evaluation of their valvar pathology and disturbed hemodynamics. They formed the study group. Their ages ranged from 2.5-20 years (mean 12.7) with body weights ranging between 12 and 60 kg (mean 35.6). Twelve children suffered from predominantly functional left-sided atrioventricular valvar diseases, 13 had predominant aortic valvar lesions and two had mixed aortic and mitral valvar pathologies (Table 1).

This project is supported by the University and Polytechnic Grants Committee, Hong Kong Heart Foundation and the Paediatric Cardiac Fund of the Grantham Hospital.

Correspondence to Dr. Maurice P. Leung, Paediatric Cardiological Division, University of Hong Kong, Grantham Hospital, 125 Wong Chuk Hang Road, Aberdeen, Hong Kong. Tel. (852) 554-6471 Ext. 249; Fax. (852) 554-2011.

Accepted for publication 21 December 1993

Table. Etiology of the valvar diseases of the children studied.

Pathology	n
Atrioventricular valve (n = 12)	
Regurgitation	
Prolapse	4
Cleft	2
Congenitally corrected transposition	1
Rheumatic	1
Regurgitation (postoperative)	
Mitral valve replacement	1
Mitral valve replacement (Fontan)	1
Plasty + ring	1
Primum atrioventricular septal defect + "cleft"	1
Aortic valve (n = 13)	
Stenosis	
Isolated valvar	3
With supra-valvar ridge	1
Regurgitation	
With ventricular septal defect	6
Prolapse	1
Perforated leaflet	1
Post-resection of subaortic membrane	1
Mixed mitral and aortic valves (n = 2)	
Regurgitation	
Rheumatic	2

Except for the initial four patients in whom we utilized the Siemens Sonoline 2000 for the transesophageal study, both precordial and transesophageal echocardiograms were performed with the Hewlett-Packard Sonos 1000 Instrument. Precordial echocardiograms were studied (by YTC & CB) either immediately or 24 hours prior to the transesophageal examination. A combination of standard views with multiple planes were utilized for the transthoracic approach. Settings of the instrument, such as color gain, depth transmit power and color flow map were individualized to yield optimal images. The studies were recorded on videotapes and the findings were analyzed. Consensus on the information from the transthoracic echocardiography were documented prior to the transesophageal echocardiographic study.

Informed consent on the transesophageal echocardiography was obtained for each patient. All children were fasted for a minimum of six hours. A total of 27 procedures were performed, of which two were conducted under general anesthesia during diagnostic catheterization. The other 25 studies were performed after the patient had received local anesthetic spray and an intravenous sedation (midazolam 1-2 mg/kg. A few needed additional ketamine 0.5-1 mg/kg). An adult sized biplane 5 MHz transesophageal transducer was utilized for the study. The transducer of the Siemens

Sonoline 2000 was limited to single plane (horizontal).

The mitral valve and its tension apparatus were imaged by the four-chamber view, transgastric short-axis cut (horizontal plane) and the two-chamber view of the left ventricle (vertical plane).<sup>12</sup> The aortic valve was assessed by the five-chamber and short-axis views of the aortic root (horizontal plane), and the ventricular outflow tract cuts (vertical plane).<sup>12</sup> Other views were obtained, as warranted by clinical circumstances, by advancement and rotation but without any angulation of the transducer. The transmit power and color flow map were carefully maintained throughout all the studies. Color flow gain was set to immediately below the level where artifacts appeared. All transesophageal studies were performed with a prior knowledge of the information obtained by precordial echocardiography. The investigatory results were recorded on video-tapes for both on- and off-line analysis.

### Analysis

The role of transesophageal echocardiography in the diagnosis and management of left-sided cardiac valvar diseases in children was assessed in terms of whether additional information (over transthoracic echocardiography) could be obtained, and whether the added information contributed to the better management of the patients studied. Cineangiograms for the confirmation of the echocardiographic findings were performed in 20 patients. Of these, 15 angiograms were performed within seven days of the ultrasonic investigations. Further verification of the valvar morphology during surgery was possible in six patients.

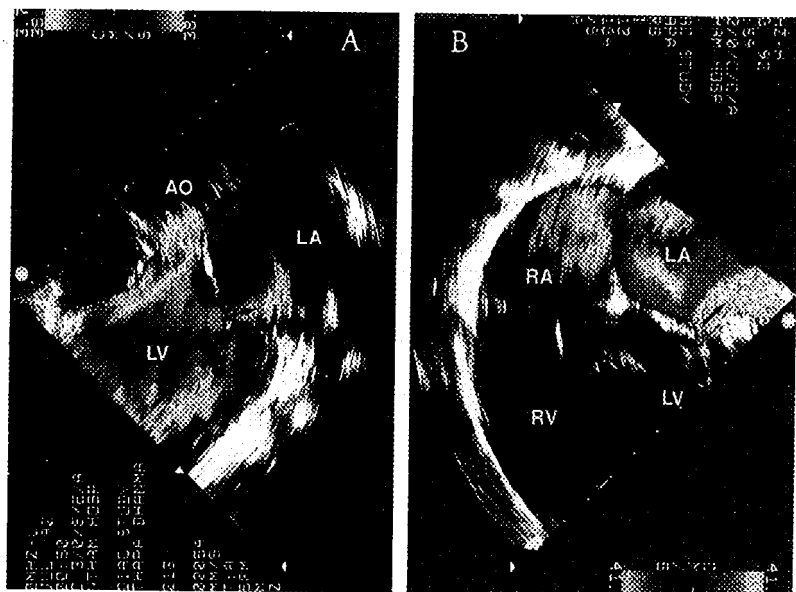
### Results

The 27 transesophageal procedures were successfully performed without any complications. Nine children, each with left-sided atrioventricular and aortic valvar diseases, had additional information obtained over that of transthoracic echocardiography (18 of 30, 60%). The other relevant or added information acquired by transesophageal echocardiography contributed to the better management of 10 patients (33%).

#### *Additional information obtained by transesophageal echocardiography over transthoracic echocardiography*

##### ATRIOVENTRICULAR VALVAR DISEASE

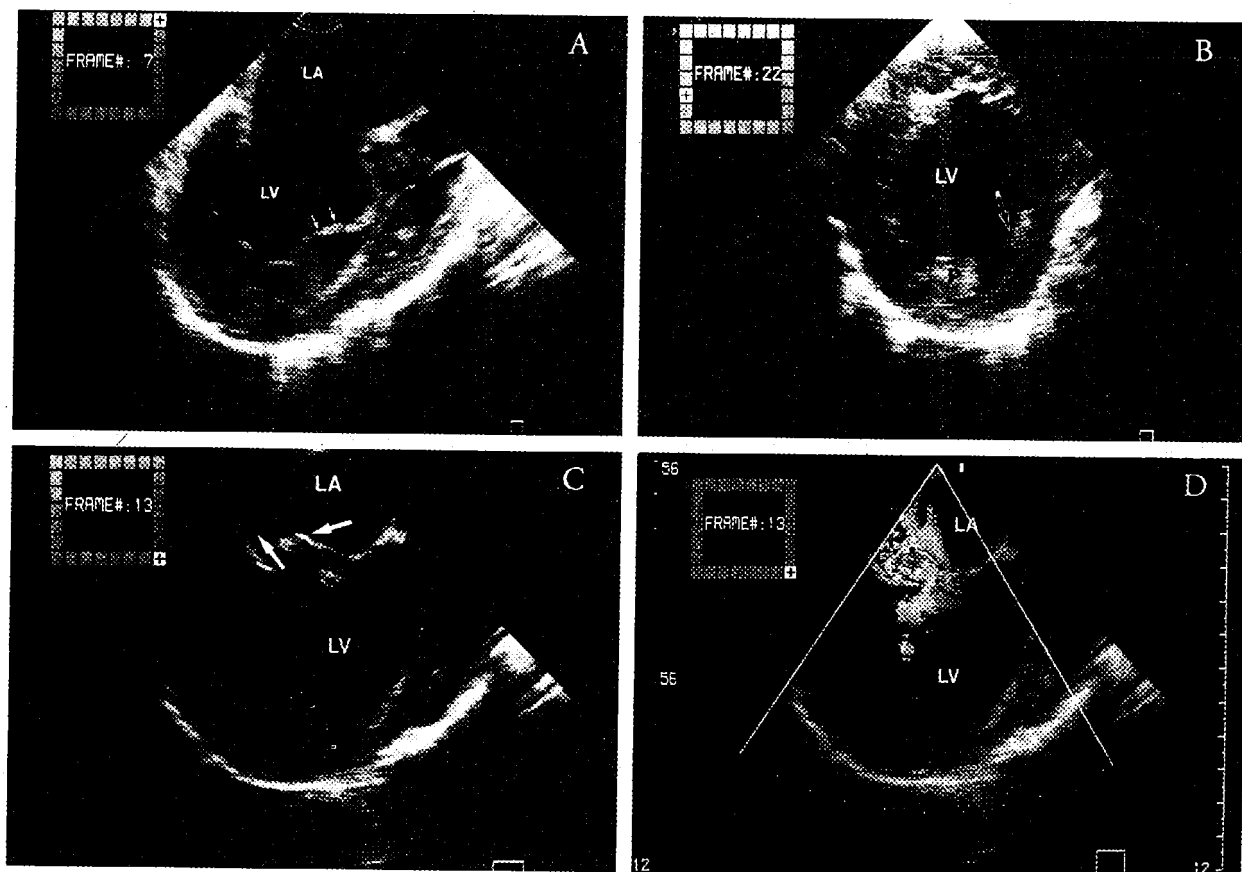
Severe mitral regurgitation was correctly diagnosed by transesophageal echocardiography but underestimated by conventional technique in a patient with rheumatic heart disease (Figure 1). In the other eight patients, their etiologies or mechanisms of valvar regurgitation were clarified. An elongated cord with a hypoplastic papillary



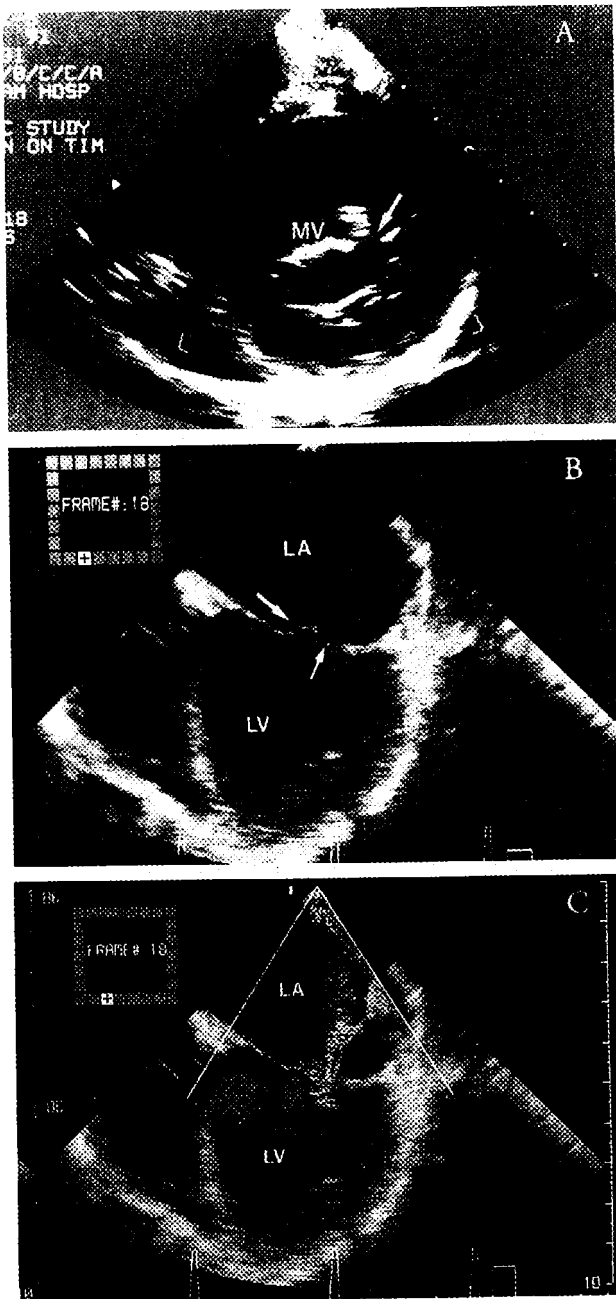
**Figure 1.** Underestimation of mitral regurgitation by conventional echocardiography and color flow mapping in a patient with rheumatic valvar disease. (A) Using precordial long-axis cut of the left ventricle, only mild regurgitation is detected (black arrow). (B) Four-chamber view from transesophageal echocardiography demonstrates severe valvar regurgitation (black arrow). The grossly deformed valve with severe leakage was replaced at surgery. Ao: aorta; LA: left atrium; LV: left ventricle; RA: right atrium; RV: right ventricle.

muscle (transgastric short axis cut of left ventricle) which resulted in a redundant prolapsing aortic leaflet was clearly visualized in one patient (four-chamber

view) (Figure 2). In another, an isolated eccentric cleft as initially diagnosed was excluded and the mitral regurgitation was clarified as relating to a prolapsed

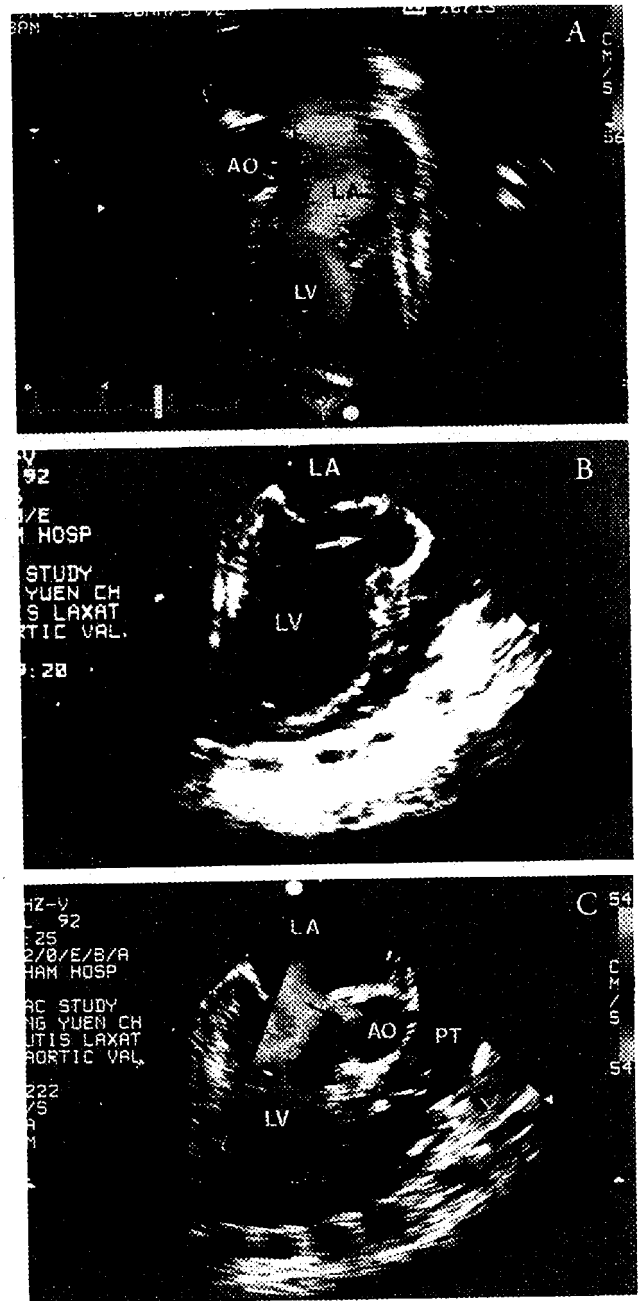


**Figure 2.** Transesophageal echocardiography clearly visualizes (A) the elongated chordae (white arrows, four-chamber view) with (B) hypoplastic papillary muscle (black arrow, transgastric short-axis cut) as the cause of (C) a redundant mitral valve leaflet resulting in (D) significant regurgitation (black arrow). P: papillary muscle; others as in Figure 1.



**Figure 3.** The cause of mitral regurgitation is clarified by transesophageal echocardiography. (A) Precordial short-axis cut of the left ventricle suggests the diagnosis of an isolated eccentric cleft (white arrow) of the mitral valve (MV). (B) Four-chamber view of transesophageal echocardiography shows buckling of the aortic leaflet of the mitral valve (large white arrow) as the cause of (C) moderate mitral regurgitation (black arrow). Abbreviations as in Figure 1.

aortic leaflet (Figure 3). In three patients who had either mitral valvar replacement or valvar ring annuloplasty, the high ultrasonic reflection from the metallic prosthesis could be avoided and perivalvar leak at multiple sites (n=2)



**Figure 4.** The missed aortic regurgitation jet is only diagnosed by transesophageal echocardiography. (A) Precordial apical long-axis cut of the left ventricle shows the prolapsing aortic leaflets (white arrows) without any obvious regurgitation jet. (B) Long-axis cut of the left ventricle with the prolapsed aortic valve (white arrow) as imaged by the vertical plane of transesophageal echocardiography clearly demonstrates (C) the eccentric regurgitation jet (black arrow). Abbreviations as in Figure 1.

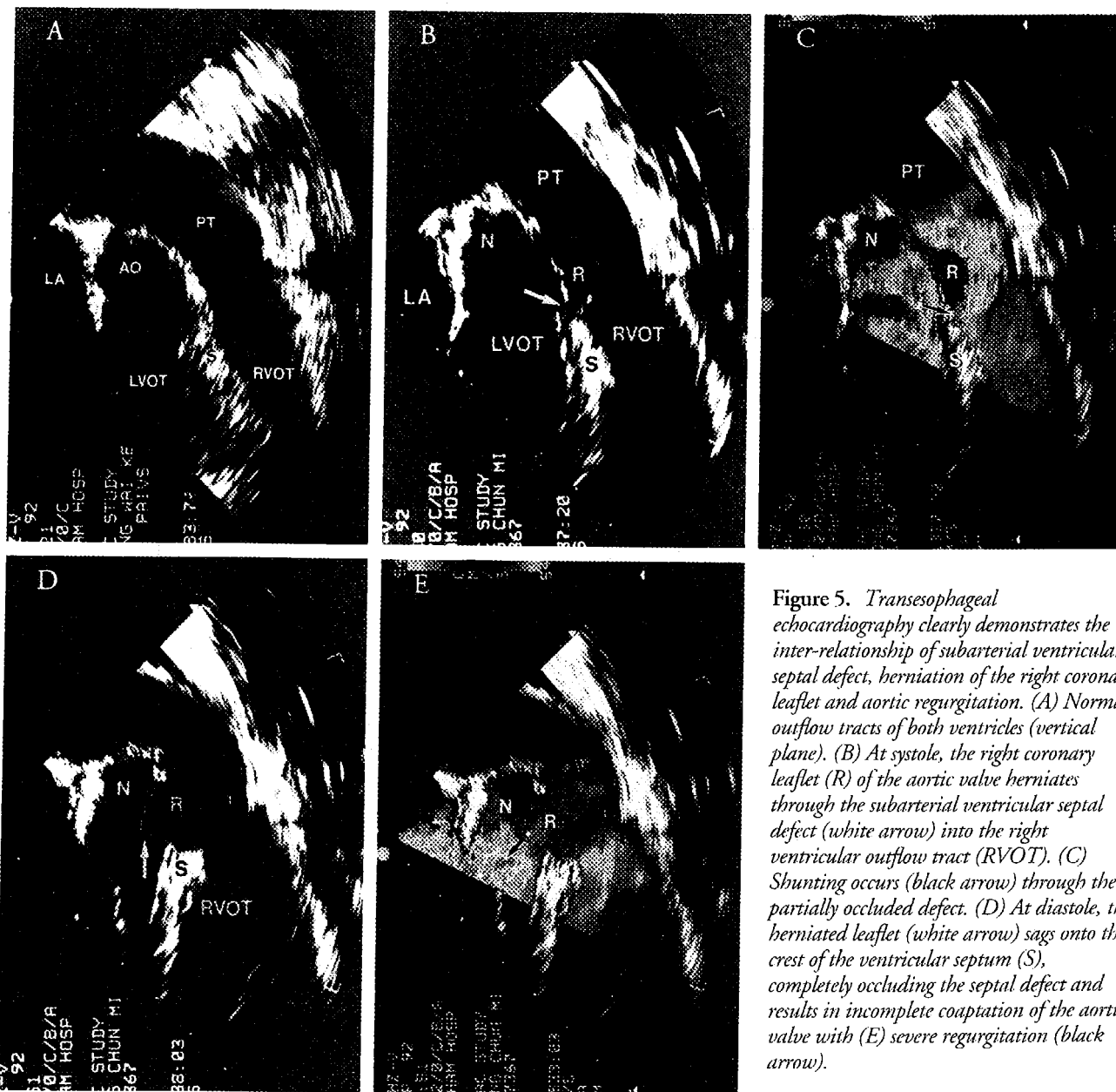
or leakage due to residual valvar prolapse (n=1) was clearly appreciated. In all three patients, the valvar or perivalvar leakages were assessed to be mild. One last patient had undergone repair of a primum atrioventricular septal

defect. There was moderate degree of residual leakage at two commissures (instead of one) of the tri-leaflet left atrioventricular valve (vertical plane of left ventricle). He required modest dosage of diuretics on follow-up.

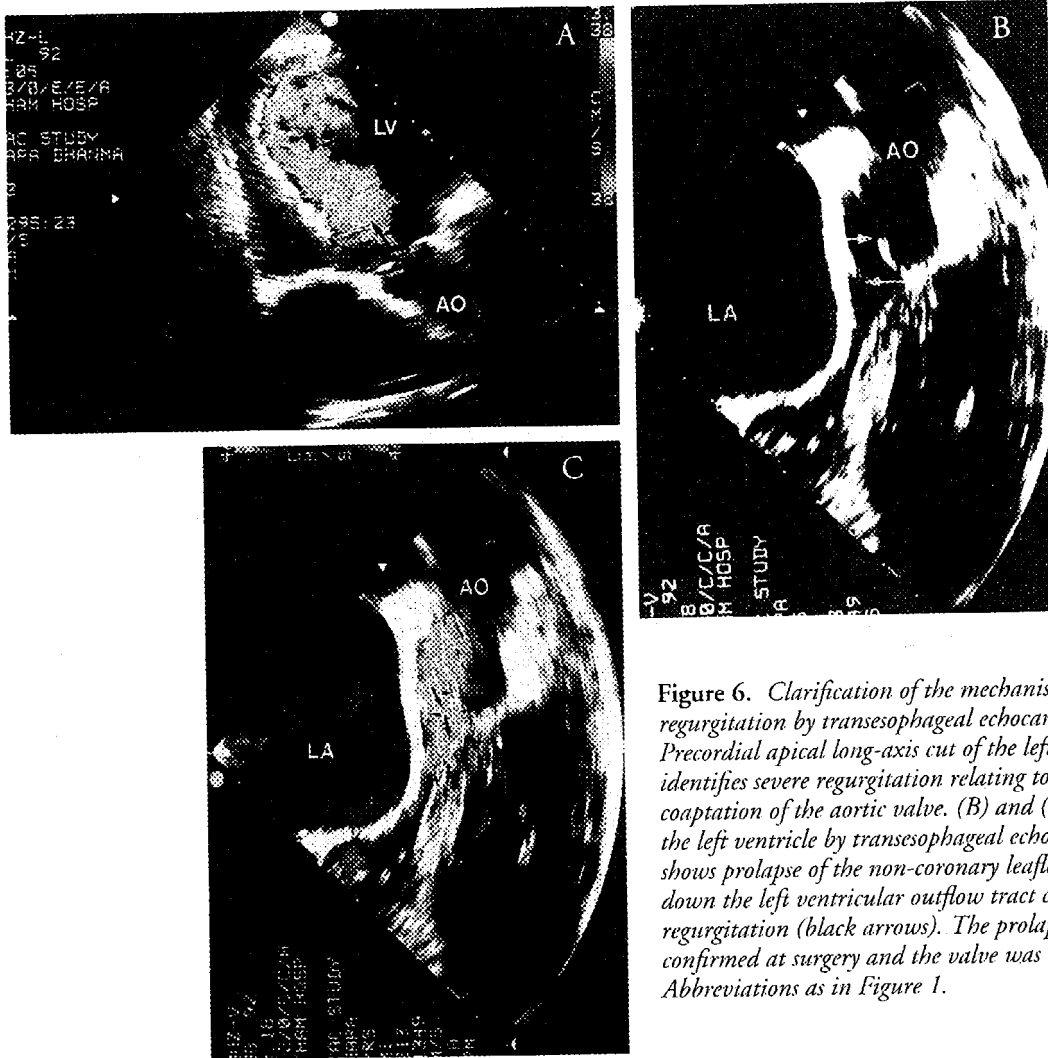
#### AORTIC VALVE

Aortic regurgitation relating to an extremely eccentric jet was missed in a patient with a stenotic and prolapsing valve and only diagnosed by transesophageal study (Figure 4). Vegetations were safely excluded by clear imaging of the thickened leaflets (and other atrioventricular valves) in another patient who had prolonged fever and chronic aortic regurgitation from previous rheumatic carditis. In seven other children with aortic

regurgitation, the mechanism of valvar leakage was clarified. Of these, six children had an associated ventricular septal defect. The herniation of the right coronary leaflet through the defect at systole was clearly visualized. During diastole, the protruded leaflet sagged onto the crest of the ventricular septum, producing incomplete coaptation of the valve and severe regurgitation (Figure 5). Although transthoracic echocardiography could also visualize the herniation of the right coronary leaflet in two of these six patients, the inter-relationship of the herniated leaflet to that of the septal defect, incomplete coaptation of the leaflet and the resultant aortic regurgitation could only be delineated by transesophageal echocardiography. One last patient



**Figure 5.** *Transesophageal echocardiography clearly demonstrates the inter-relationship of subarterial ventricular septal defect, herniation of the right coronary leaflet and aortic regurgitation. (A) Normal outflow tracts of both ventricles (vertical plane). (B) At systole, the right coronary leaflet (R) of the aortic valve herniates through the subarterial ventricular septal defect (white arrow) into the right ventricular outflow tract (RVOT). (C) Shunting occurs (black arrow) through the partially occluded defect. (D) At diastole, the herniated leaflet (white arrow) sags onto the crest of the ventricular septum (S), completely occluding the septal defect and results in incomplete coaptation of the aortic valve with (E) severe regurgitation (black arrow).*



**Figure 6.** Clarification of the mechanism of aortic regurgitation by transesophageal echocardiography. (A) Precordial apical long-axis cut of the left ventricle identifies severe regurgitation relating to failure of coaptation of the aortic valve. (B) and (C) Long-axis cut of the left ventricle by transesophageal echocardiography shows prolapse of the non-coronary leaflet (lower arrow) down the left ventricular outflow tract causing severe regurgitation (black arrows). The prolapsed leaflet was confirmed at surgery and the valve was replaced. Abbreviations as in Figure 1.

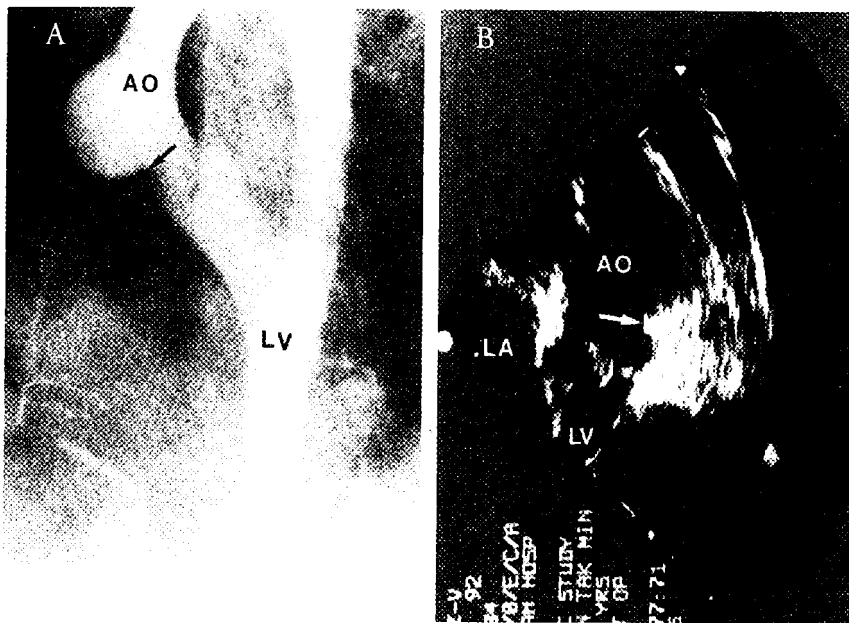
had rheumatic heart disease. The thickened and deformed non-coronary leaflet which prolapsed down the left ventricular outflow tract causing severe valvar incompetence (Figure 6) was appreciated by transesophageal echocardiography.

#### *Contribution by transesophageal echocardiography to the better management of patients*

The management of three patients (11%) was drastically altered after transesophageal echocardiography. The scheduled valvoplasty in one patient was cancelled after the initial diagnosis of a cleft mitral valve was excluded. In another, when severe instead of mild mitral regurgitation was detected, valvar replacement was undertaken. As bacterial endocarditis was safely excluded in the last patient with prolonged fever and achieved rheumatic carditis, response to treatment was achieved when anti-inflammatory in place of antibiotic therapy was instituted.

#### *Confirmation of the transesophageal echocardiographic findings*

The echocardiographic findings were confirmed by reviewing the 20 angiograms available. The only missed diagnosis by both echocardiographic techniques was the supra-valvar ridge in a patient with concomitant aortic valvar stenosis (1/30=3%) (Figure 7). The pathology of a cleft mitral valve (n=2), the protrusion of the right coronary aortic leaflet through a doubly committed and subarterial ventricular septal defect (n=2), severe prolapse of the non-coronary aortic leaflet down the left ventricular outflow tract, and the grossly deformed mitral valve resulting in severe valvar regurgitation in two patients with rheumatic heart diseases were further verified by surgery. A decision on valvar replacement in the latter two patients was based on transesophageal echocardiographic findings without cardiac catheterization.



**Figure 7.** In a patient who had valvar aortic stenosis, the concomitant supervalvar ridge was missed by both echocardiographic technique. (A) The ridge (black arrow) is well demonstrated by ventriculogram. (B) Retrospective review of the left ventricular outflow tract cut by transesophageal echocardiography (vertical plane) shows that the ridge (white arrow) was being overlooked.

## Discussion

Structural valvar abnormalities of the left heart can result in major hemodynamic disturbances. Accurate assessment of the morphology and severity of the valvar lesions can allow optimal timing and appropriate choice of therapy for these patients. The growing interest of valvoplasty by reconstructive surgery<sup>13-15</sup> or balloon dilation<sup>16,17</sup> further stimulates the pursuit for precise anatomical delineation prior to intervention. In many instances, conventional echocardiography with color flow mapping can define the abnormal valvar anatomy and quantify the severity of lesions.<sup>18,19</sup> In this study, we explored and demonstrated that the superior images acquired by the high frequency transducer placed in close proximity of the heart via the esophagus could frequently (67%) provide additional information over and above that gained through precordial studies. We have insisted that transesophageal investigation in children and young adults should only be performed after thorough physical and conventional ultrasonic examinations. Prior knowledge on the transthoracic echocardiographic findings allowed acquisition of maximal information in the shortest time possible. In addition, because we were applying an adult size transducer to children, we avoided totally any angulation of the transducer tip but limited our manipulation to rotation and advancement of the transducer only. In this way we minimized discomfort or complications from the investigation. The youngest patients in whom we could perform the examination under general and local anesthesia were 2.5 and six years old, weighing 12 and 13.5

kg, respectively.

On many occasions, transesophageal echocardiography consistently clarified the exact pathophysiology of valvar regurgitation. The simultaneous visualization of the outflow tract of both ventricles (vertical plane) is of particular interest to the group of patients with doubly committed and subarterial ventricular defect who developed aortic regurgitation. Although precordial examination could demonstrate the septal defect with or without herniation of the right coronary aortic leaflet and aortic regurgitation,<sup>20,21</sup> the relative thick chest wall in these older children and young adults precluded clear imaging of the right ventricular outflow tract or the achievement of precise anatomical details of the aortic valve, especially when color Doppler mapping was superimposed. The interrelation between the defect, and through it the herniation of the aortic leaflet into the right ventricular outflow which resulted in incomplete coaptation of the aortic valve during diastole, could be appreciated only by transesophageal studies. Similarly, biplane studies with superior imaging of the mitral valvar tension apparatus helped to exclude confidently an isolated cleft and diagnosed cordal elongation with hypoplastic papillary muscle as the causes for mitral regurgitation, as well as detecting regurgitation through the two commissures of a left-sided trileaflet atrioventricular valve in the setting of primum atrioventricular septal defect. In addition, as reported in adult patients with valvar replacement,<sup>22</sup> interference from the metallic mitral valve ring was avoided and detection of residual valvar prolapse or paravalvar leakage was then possible.

We have further demonstrated that transesophageal echocardiography contributed significantly to the better management of children suffering from valvar diseases of the left heart (11%). The technique is most useful for valvoplasty at surgery. Preoperative studies provided clear definition of the morphology, surgical anatomy and severity of the malformed valve which helped to formulate a better choice of surgery. The scheduled valvar repair was implemented in four (cleft mitral valve, n=2, prolapsed aortic leaflet through the subarterial ventricular septal defect, n=2), cancelled in one (when cleft mitral valve was excluded) and the valve was replaced in another (instead of the proposed annuloplasty) as severe mitral regurgitation was detected. Moreover, in two of our patients, decisions on valvar replacement were based on the transesophageal echocardiographic findings without catheterization. Furthermore, confirmation or exclusion of bacterial endocarditis was able to alter the policy for medical treatment. We conclude that transesophageal echocardiography is a useful examination for the diagnosis and management of valvar disease of the left heart in children.

#### Acknowledgment

We gratefully acknowledge the secretarial support of Anna Choy and Priscilla Yan.

#### References

- Honey M, Gough SH, Katsaros S, Miller GAH, Thruaisingham V. Left ventricular cine-angiography in the assessment of mitral regurgitation. *Br Heart J* 1969; 31: 596-602.
- Baron MG. Angiocardiographic evaluation of valvar insufficiency. *Circulation* 1971; 43: 599-605.
- Ciobanu M, Abbasi AS, Allen M, Hermer A, Spellberg R. Pulsed-Doppler echocardiography in the diagnosis and estimation of severity of aortic insufficiency. *Am J Cardiol* 1982; 49: 339-343.
- Miyatake K, Nimura Y, Sakakibara H. Localization and direction of mitral regurgitant flow in mitral orifices studied with combined use of ultrasonic pulsed Doppler technique and two dimensional echocardiography. *Br Heart J* 1982; 48: 449-458.
- Hozumi T, Yoshikawa J, Yoshida K, Yamaura Y, Akasaka T, Shakudo M. Direct visualization of ruptured chordae tendineae by transesophageal two-dimensional echocardiography. *J Am Coll Cardiol* 1990; 16: 1315-1319.
- Zamorano J, Erbel R, Mackowski T, Alfonso F, Meyer J. Usefulness of transesophageal echocardiography for diagnosis of mitral valve prolapse. *Am J Cardiol* 1992; 69: 419-422.
- Ballal RS, Mahan EF III, Nanda NC, Sanyal R. Aortic and mitral valve perforation: diagnosis by transesophageal echocardiography and Doppler color flow imaging. *Am Heart J* 1991; 121: 214-217.
- Castello R, Fagan L, Lenzen P, Pearson AC, Labovitz AJ. Comparison of transthoracic and transesophageal echocardiography for assessment of left-sided valvular regurgitation. *Am J Cardiol* 1991; 68: 1677-1680.
- Ritter SB. Transesophageal real-time echocardiography in infants and children with congenital heart disease. *J Am Coll Cardiol* 1991; 18: 569-580.
- Sreeram N, Stümper OFW, Kaulitz R, Hess J, Roelandt JRTC, Sutherland GR. Comparative value of transthoracic and transesophageal echocardiography in assessment of congenital abnormalities of the atrioventricular junction. *J Am Coll Cardiol* 1990; 16: 1205-1214.
- Roberson DA, Muhiudeen IA, Silverman NH, Turley K, Haas GS, Cahalan MK. Intraoperative transesophageal echocardiography of atrioventricular septal defect. *J Am Coll Cardiol* 1991; 18: 537-545.
- Seward JB, Khandheria BK, Edwards WD, Oh JK, Freeman WK, Tajik AJ. Biplanar transesophageal echocardiography: Anatomic correlations, image orientation, and clinical applications. *Mayo Clin Proc* 1990; 65: 1193-1213.
- Carpentier A. Cardiac valve surgery: the "French correction". *J Thorac Cardiovasc Surg* 1980; 86: 323-337.
- Nunley DL, Starr A. The evolution of reparative techniques for the mitral valve. *Ann Thorac Surg* 1983; 37: 393-397.
- Carpentier A, Chauvaud S, Fabiani JN. Reconstructive surgery of mitral valve incompetence: ten year appraisal. *J Thorac Cardiovasc Surg* 1980; 79: 338-348.
- Herrmann HC, Wilkins GT, Abascal VM, Weyman AE, Block PC, Palacios IF. Percutaneous balloon valvotomy for patients with mitral stenosis: analysis of factors influencing results. *J Thorac Cardiovasc Surg* 1988; 96: 33-38.
- Palacios IF, Block PC, Wilkins GT, Weyman AE. Follow-up of patients undergoing mitral balloon valvotomy. *Circulation* 1989; 79: 573-579.
- Helmeke F, Nanda NC, Siung MC, Sota B, Adey CK, Goyal RG, Gatewood RP. Color Doppler assessment of mitral regurgitation with orthogonal planes. *Circulation* 1987; 75: 175-183.
- Perry GI, Hencke F, Nanda NC, Byard C, Soto B. Evaluation of aortic insufficiency by Doppler color flow mapping. *J Am Coll Cardiol* 1987; 9: 952-959.
- Griffin ML, Sullivan ID, Anderson RH, Macartney FJ. Doubly committed subarterial ventricular septal defect: new morphological criteria with echocardiographic and angiographic correlation. *Br Heart J* 1988; 59: 474-479.
- Schmidt KG, Cassidy SC, Silverman NH, Stanger P. Doubly committed subarterial ventricular septal defects: echocardiographic features and surgical implications. *J Am Coll Cardiol* 1988; 12: 1538-1546.
- Nellessen U, Schnittger I, Appleton CP. Transesophageal two-dimensional echocardiography and color Doppler flow velocity mapping in the evaluation of cardiac valve prostheses. *Circulation* 1988; 78: 848-855.