

Mosaic partial trisomy 17q2

P A King, A Ghosh, M Tang

Abstract

Examination of an infant born after prenatal diagnosis of mosaic partial trisomy 17q2 showed the unique phenotypic features of this chromosomal abnormality, that is, frontal bossing, large mouth, brachyrhizomelia, and hexadactyly. Amniocentesis was performed because of polyhydramnios and ultrasound diagnosis of fetal craniofacial dysmorphism and rhizomelic shortening of the limbs. Chromosomal mosaicism was restricted to fetal tissue and amniotic fluid cells. The placental chromosomal complement was normal, suggesting that the abnormality developed after differentiation of embryonic and trophoblastic cells. This emphasises the usefulness of cytogenetic evaluation of placental, fetal, and amniotic fluid cells in delineating the pathogenesis of congenital abnormalities.

Partial trisomy 17q2 is rare. The reported cases have involved a variable length of 17q from band q21,^{1,2} q22,³ q23,^{4,8} and q25.1.⁹ Despite the difference in the size of the chromosome segment involved, there is strong phenotypic resemblance in the reported cases. The diagnosis has previously been made in infancy or early adulthood. One case⁹ was diagnosed by amniocentesis in the second trimester of pregnancy after diagnosis of the disorder in an affected sib and the discovery of a maternal balanced translocation. All previously reported cases, apart from the one described by Fryns *et al*,³ have been the result of a familial translocation.

Case report

The parents were non-consanguineous. Neither parent had any phenotypic abnormalities and they had one normal 3 year old daughter. The mother was 28

and the father was 46 years old when the infant was born.

The pregnancy was uncomplicated until 30 weeks' gestation when clinical polyhydramnios was noted. Ultrasonography showed the liquor volume was markedly increased with several pockets measuring 12 cm. Rhizomelic shortening of all limbs was noted. The other fetal parameters were appropriate for gestation. Frontal bossing and a depressed nasal bridge were noted. In view of the dysmorphic features in association with polyhydramnios, amniocentesis was performed.

The chromosome complement of the cultured amniotic fluid cells was 46,XX/46,XX,-21,+der(21),t(17;21)(q21.1;q22.3) in a ratio of 1:15. The couple were informed of the result and counselled about the prognosis for the infant. The parental chromosomes were normal.

Polyhydramnios persisted and at 38 weeks' gestation spontaneous labour occurred. At artificial rupture of the membranes 4 l of liquor were released. A live female infant was born with Apgar scores of 6 and 9 at one and five minutes respectively.

The birth weight was 2920 g (40th centile). The head circumference was 35 cm (50th centile) and the crown-heel length was 47 cm (10th centile). There were multiple phenotypic abnormalities. Craniofacial anomalies included wide fontanelles and sagittal suture, frontal bossing, temporal retraction, depressed nasal bridge, upturned nose, micrognathia, low set ears, and a low hair line. The thorax was broad with pectus excavatum and widely spaced nipples. Rhizomelic shortening of all limbs was present with the right side being more severely affected. Postaxial polydactyly of both feet was present. The back and limbs were noted to be very hairy. The external genitalia were normal (figs 1 and 2).

Ultrasound scan showed that the left kidney was enlarged with a prominent renal pelvis and the heart was normal. X ray showed two hemivertebrae in the thoracic spine.

Chromosomal study of the baby's blood showed 46,XX/46,XX,-21,+der(21),t(17;21)(q21.1;q22.3) in a ratio of 72:28. The chromosomal constitution of placental tissue was completely normal in all 60 metaphases analysed from two separate cultures.

The baby developed respiratory difficulties and sepsis requiring admission to the neonatal intensive care unit where she died on day 5. Necropsy did not reveal any additional information. Unfortunately, a

Department of Obstetrics and Gynaecology,
University of Hong Kong, Hong Kong.
P A King, A Ghosh, M Tang

Correspondence to Dr King, Department of Obstetrics and Gynaecology, Queen Mary Hospital, Pokfulam Road, Pokfulam, Hong Kong.

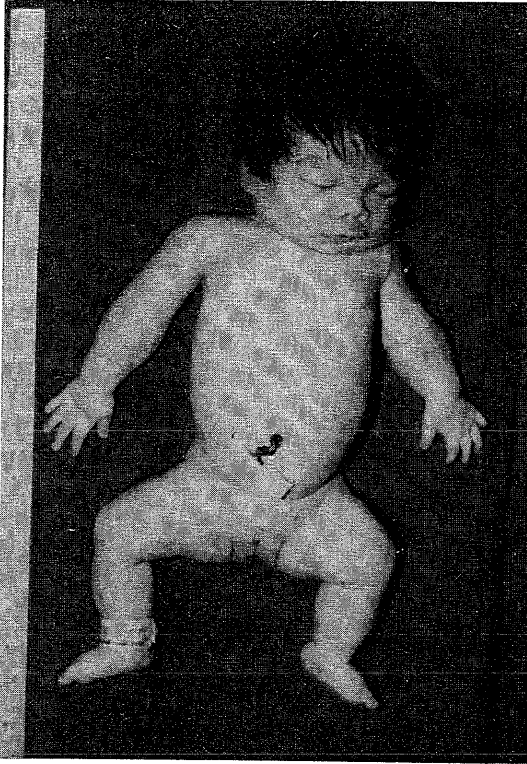


Figure 1 Infant with partial trisomy 17q2. Note frontal bossing, temporal recession, large mouth, and brachyrhizomelia.

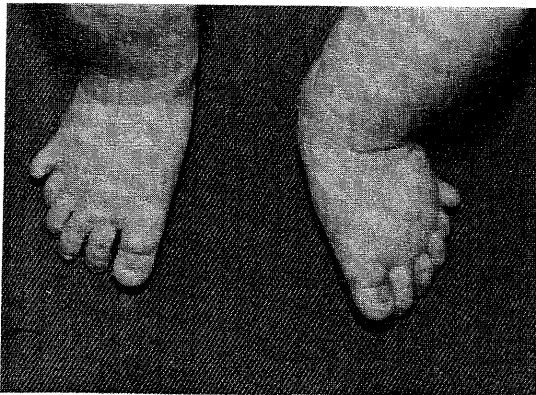


Figure 2 Infant with partial trisomy 17q2. Note hexadactyly of both feet.

cell line is not available from this baby. Since this was a de novo abnormality arising as a postmeiotic event, the couple were counselled that the recurrence risk is low.

Discussion

Partial trisomy 17q2 is a rare but well recognised clinical entity. Despite the presence of a normal cell line in our case, the unique phenotypic features associated with this chromosomal abnormality, frontal bossing, large mouth, brachyrhizomelia, and hexadactyly,¹⁰ are evident. The severity and nature of the dysmorphic features will depend not only on the extent of the chromosome segment involved in the partial trisomy, but also on the associated monosomy of the translocated chromosome. The variation in clinical presentation is evident in the reported cases of trisomy 17q2.²⁻⁹ However, when this case is compared with the three reported cases with trisomy 17q23→qter and monosomy 21q22→qter the phenotypic features are remarkably similar.⁵

The association of polyhydramnios with this abnormality has not previously been reported and, to the best of our knowledge, this is the first report of mosaic partial trisomy 17q2 which was diagnosed prenatally. The presence of a completely normal chromosome constitution in placental tissue despite the analysis of an adequate number of metaphases suggests that this chromosomal abnormality probably developed after the differentiation of embryonic and trophoblastic cells. This phenomenon is likely to be rare but a normal cytogenetic finding in placental tissue of a structurally abnormal fetus should be viewed with caution, since there is a possibility of a false negative cytogenetic diagnosis. Cytogenetic study of fetal blood or amniotic fluid cells should be considered, since an adequate cytogenetic evaluation is a prerequisite for proper counselling of the couple, not only during the antenatal period but also after delivery. If the risk of invasive procedures is unacceptable to the couple antenatally, then the clinician should ensure that both placental tissue and cord blood samples are available after delivery for further cytogenetic study.

At present, owing to lack of adequate information concerning the prognosis of fetuses with mosaic chromosomal abnormality, counselling of the couple is a difficult task. A complete cytogenetic and clinical evaluation of all fetuses diagnosed as having mosaic chromosomal abnormality and adequate follow up of these infants after birth should increase our knowledge in this area and consequently enable us to provide better counselling.

1 Yamamoto Y, Endo Y, Kuroki Y. A case of partial trisomy 17 resulting from X;autosomal translocation. *J Med Genet* 1979;16:395-9.

- 2 Gallien JU, Neu RL, Wynn RJ, Steinberg-Warren N, Bannerman RM. Brief clinical report. An infant with duplication of 17q21-17qter. *Am J Med Genet* 1981;8:111-15.
- 3 Fryns JP, Parloir C, Van den Berghe H. Partial trisomy 17q. *Hum Genet* 1979;49:361-4.
- 4 Shawe DJ, Fear C, Appleyard WJ. A child with partial trisomy of chromosome 17 and partial monosomy of chromosome 3: 46,XY,der(3),t(3;17)(p25;q23). *J Med Genet* 1983;20:383-5.
- 5 Berberich MS, Carey JC, Lawce HJ, Hall BD. Duplication (partial trisomy) of the distal long arm of chromosome 17: a new clinically recognizable chromosome disorder. *Birth Defects* 1978;XIV(6C):287-95.
- 6 Turleau C, de Grouchy J, Bouveret JP. Distal trisomy 17q. *Clin Genet* 1979;16:54-7.
- 7 Naccache NF, Vianna-Morgante AM, Richieri-Costa A. Brief clinical report. Duplication of distal 17q: report of an observation. *Am J Med Genet* 1984;17:633-9.
- 8 Caine A, Knapton DM, Mueller RF, Congdon PJ, Haigh D. Duplication of distal 17q from a maternal translocation: an additional case with some unique features. *J Med Genet* 1989;26:577-9.
- 9 Bridge J, Sanger W, Mosher G, et al. Partial duplication of distal 17q. *Am J Med Genet* 1985;22:229-35.
- 10 De Grouchy J, Turleau C. *Clinical atlas of human chromosomes*. 2nd ed. New York: John Wiley, 1984;286-9.