

# Adult orthodontics and its interface with other disciplines

U Hägg, EF Corbet, AM Rabie

**Orthodontic treatment for adults has been the fastest growing area in orthodontic practice in recent years. The desire to improve facial aesthetics is considered the main reason why individuals seek treatment later in life. Another reason for the increased demand for adult orthodontics is the need for tooth repositioning to make restoration and/or the replacement of teeth easier and more effective and to correct some of the side-effects of periodontal disease. Unlike the young patient—previously the main consumer of orthodontic services—the adult patient may require a team approach involving the orthodontist, the oral and maxillofacial surgeon, the periodontist, and the restorative or general dentist. This paper describes the underlying reasons for adopting a multidisciplinary approach, which may be required to meet the needs of many adult patients. The interfaces between the various specialties are illustrated by means of selected cases and the benefits of the team approach and principles of management are highlighted.**

*HKMJ 1996;2: 186-190*

*Key words: Orthodontics; Periodontics; Prosthodontics; Surgery; oral*

## Introduction

Crowded, irregular, and protruding teeth—collectively termed malocclusion—and jaw discrepancies have been a problem since antiquity, and attempts to correct these disorders go back to at least 1000 BC.<sup>1</sup> More than 100 years ago, Kingsley<sup>2</sup> stated that “It may be regarded as settled fact that there are hardly any limits to the age when movement of teeth might not succeed”. However, for a long time, orthodontic treatment was provided mainly for children and adolescents. Only during the past two decades has orthodontic treatment been available to adult patients in general, and currently it is estimated that the proportion of adult patients in an orthodontic office in Hong Kong, and elsewhere, may amount to 30% to 40% of patients.

## The need for orthodontic treatment in adults

The need for orthodontic treatment in the adult population is high; it has been reported that 50% to 60% of young adults in Hong Kong have a definite need for orthodontic treatment.<sup>3</sup> However, the proportion of adults who have received orthodontic treatment is low. A recent study into the need and demand for orthodontic treatment among students at the University of Hong Kong reports that less than four per cent had received orthodontic treatment; in the adult population, only approximately one-third of those with a definite need of orthodontic treatment demand treatment.<sup>3</sup>

Why are adults undergoing orthodontic treatment? There is no local data for Hong Kong, but a report from Scandinavia shows that aesthetics are definitely the main reason why adults seek and undergo orthodontic treatment. In a large group of patients referred for or seeking orthodontic treatment, Perregaard and Blixencrone-Möller<sup>4</sup> found that the reasons included: (1) untreated malocclusion (50%), (2) unsatisfactory result of previous orthodontic treatment (15%), (3) temporomandibular disorders/functional problems (14%), (4) periodontal disease (12%), and (5) the need for pre-prosthetic orthodontics (9%). Of this group,

---

Faculty of Dentistry, The University of Hong Kong, Prince Philip Dental Hospital, 34 Hospital Road, Hong Kong:

Department of Children's Dentistry and Orthodontics

U Hägg, DDS, Odont Dr

AM Rabie, MSD, PhD

Department of Periodontology and Public Health

EF Corbet, FDSRCS(Eng), FFDRCSI

Correspondence to: Prof U Hägg

approximately half underwent orthodontic treatment. The remainder were not treated mainly because they found treatment to be too expensive, too complex/time-consuming, or because they, or the orthodontist, felt that orthodontic treatment would not have been beneficial.

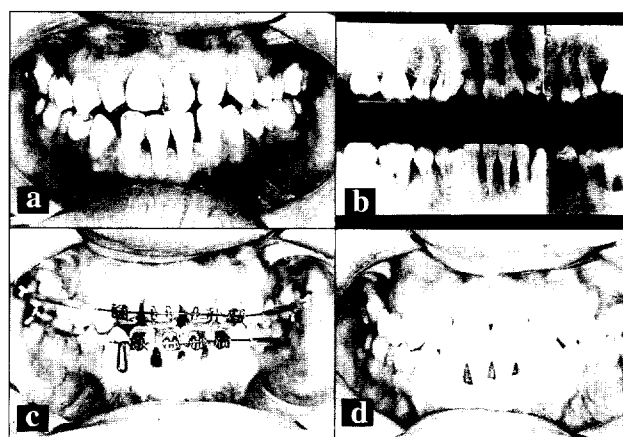
### Differences in approach to orthodontic treatment for children and adults

The orthodontic treatment of adult patients differs from that of children in that there is no further appreciable skeletal growth in adult patients and the treatment is often multidisciplinary. There are, however, slow skeletal changes taking place in the facial bones during adulthood and the dentoalveolar compensation mechanism still occurs.<sup>5</sup> The initially slower tissue response in adults compared with that in children does not significantly affect the total treatment time, since adult patients are generally more co-operative than children, which seems to compensate for the slower tissue response.<sup>6</sup>

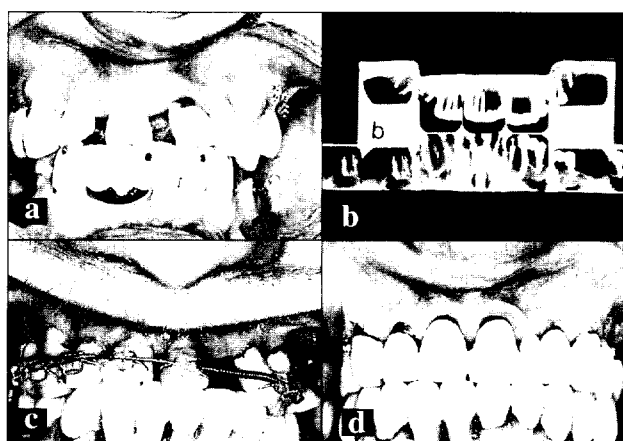
Moyers<sup>7</sup> divided adult orthodontic patients into three categories—those with good oral health, those with a history of periodontal disease and/or loss of permanent teeth, and those with pronounced jaw discrepancies. In general, the patients from the first category can be treated by orthodontics only, but for the other two categories a multidisciplinary approach is necessary. Musich<sup>8-10</sup> found that 30% of adult patients are treated by the orthodontist only, 45% are treated by dual providers, and 25% are treated by multiple providers. In a review of the kind of treatment that the patients needed apart from orthodontics, it was found that nearly half needed periodontal treatment (43%) and/or restorative treatment (47%), and one quarter of patients needed surgical treatment. For those adult orthodontic patients who are to undergo treatment by dual or multiple providers, it is most important that the treatment is planned by all who are involved in any part of the treatment, and that evaluation of treatment progress is shared within the group.

### Increased aesthetic awareness

In general, many adult patients have not been treated orthodontically in childhood because of a lack of either awareness, funds, or access to orthodontic treatment providers. Increased aesthetic awareness among adults is increasing the demand for the correction of malaligned teeth. Most adults seeking orthodontic treatment have been aware of their problem for years, even decades.<sup>11</sup> A common reason for not seeking or-



**Fig 1.** Case 1, a 38-year-old woman. Chief complaint: recent change in dental appearance. 1a. Clinical frontal view on presentation. 1b. Radiographic views showing bone loss. 1c. Fixed orthodontic appliance during treatment. 1d. Post-treatment view, showing veneers on upper incisors.

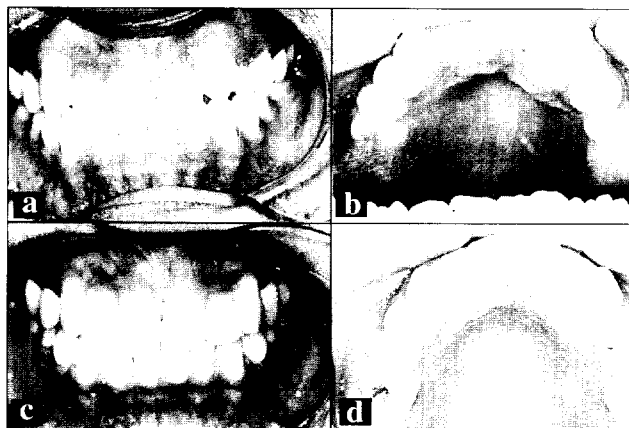


**Fig 2.** Case 2, a 64-year-old woman. Chief complaint: dental appearance. 2a, b. Clinical and radiographic views after periodontal treatment but before orthodontic treatment. 2c. Frontal view after orthodontic treatment. 2d. Frontal view after prosthetic treatment.

thodontic treatment sooner, is that the patient's dentist has not addressed the problem, and as a result, it was thought that orthodontic treatment was not the way to solve the problem. Orthodontic treatment as part of a multidisciplinary approach can certainly contribute to the quality of the restorative procedures given (Figs 1 and 2) and the quality of life of a patient.

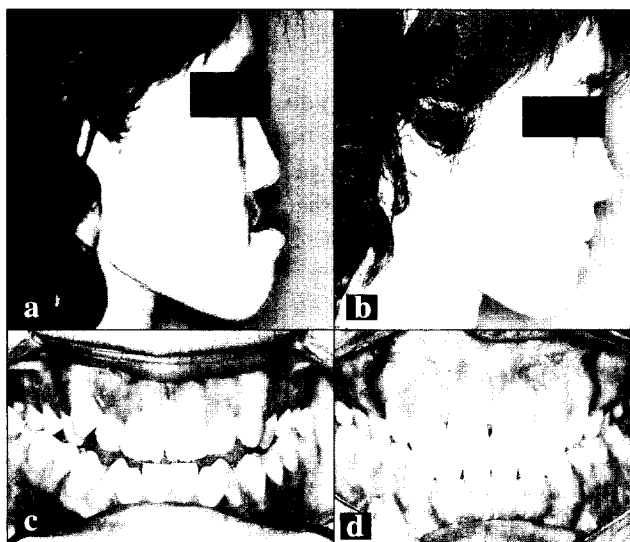### Malocclusions in adults

Malocclusions are very common in adults in Hong Kong.<sup>3</sup> In adults, orthodontic treatment can correct the position of the teeth, change the shape of the dental



**Fig 3.** Case 3, a 21-year-old woman. Chief complaint: dental appearance and functional disorder. 3a, c. Frontal view before and after orthodontic treatment. 3b, d. Occlusal view of the maxillary arch before and after orthodontic treatment.

arches, and within certain limits, change the inter-relationship between the maxillary and mandibular dental arches (Fig 3), and mask mild discrepancies in the jaw relationship. More severe discrepancies of the jaw relationship require a combined orthodontic-surgical approach (Fig 4). In such cases, the objectives of the pre-surgical orthodontic treatment are to align the dental arches and move the teeth into proper inclination and position, so that full surgical correction of the jaw discrepancies can be achieved. Post-surgical orthodontics is indicated for minor adjustment of the occlusion



**Fig 4.** Case 4, a 24-year-old woman. Chief complaint: facial and dental appearance. 4a, b. Lateral facial profile before and after combined orthodontic-surgical treatment. 4c, d. Frontal view before and after combined orthodontic-surgical treatment.

following surgery. Hence, in principle, any malocclusion can be treated in adulthood.

**Previous orthodontic care**

Some adult patients requesting orthodontic treatment have had previous orthodontic work during their childhood or adolescence. These patients usually express dissatisfaction with their dental appearance either because of unfavourable post-treatment changes, or because of an initially compromised treatment outcome. Occasionally, patients have unrealistic expectations for the outcome of treatment.

**Mandibular dysfunction in adults**

Functional temporomandibular disorders are common in childhood<sup>12</sup> and adulthood but severe symptoms appear in only approximately two per cent.<sup>13</sup> No investigation has shown any clinically significant association between malocclusion and mandibular dysfunction and it is generally believed that mandibular dysfunction cannot be prevented by early orthodontic treatment. However, for some adult patients with established mandibular dysfunction and malocclusion, orthodontic treatment is performed in the hope that it may relieve the functional disturbance (Fig 3).

**The replacement of missing teeth in adults**

Missing teeth and prosthetic treatment needs have been extensively studied in Hong Kong adults.<sup>14</sup> In general, missing teeth and unmet prosthetic needs are common findings in Hong Kong adults because of the irregular use of dental services.<sup>15</sup> Tooth extraction rather than preventive and restorative measures is used.

Adults are now more frequently referred for orthodontic treatment to improve the positioning and alignment of teeth prior to the replacement of missing teeth. Such tooth movements may be undertaken to achieved parallel abutments of the teeth used to hold the prosthesis, to create space for a pontic (the false tooth in a bridge) [Fig 2] or to make space for a dental implant (usually a titanium device that integrates with the jaw bone and can be used to support a crown or dental bridge). It is often possible by orthodontic treatment to close spaces or re-position the remaining teeth following tooth loss. A good example of the usefulness of orthodontic treatment is when canines and premolars are moved posteriorly, eliminating either the need for a removable partial prosthesis to replace missing molars, or to allow insertion of a short-span fixed bridge, rather than the use of a removable, partial prosthesis.

## Orthodontics for adults affected by periodontal disease

As previously mentioned, 30% to 40% of patients undergoing orthodontic treatment are adults, and at least 43% of adult patients in one study<sup>9,10</sup> were found to need periodontal treatment. Surveys of Hong Kong adults in the age range 35 to 44 years show that poor oral hygiene is widespread, with approximately 50% of the adult population showing signs of moderate periodontal disease and 16% to 17% showing signs of advanced periodontal destruction with deep periodontal pockets around some teeth, reflecting both loss of supporting alveolar bone and periodontal attachment.<sup>16,17</sup>

One study in Hong Kong shows that dentists give periodontal disease as the reason for extraction of more than one-third of teeth removed by them in patients aged 16 years and older.<sup>18</sup> Teeth affected by advanced periodontal destruction may become so loose that the normal forces generated by the occlusion and movement of the teeth are tantamount to extraction forces and the affected teeth may spontaneously drop out.

Tooth loss often needs orthodontic treatment as part of its management. Health care professionals need to be aware that adults who are losing teeth probably have active periodontal disease and should be treated appropriately prior to the replacement of missing teeth—with or without adjunctive orthodontic treatment.

The drifting of anterior teeth, giving rise to increasingly obvious spaces between the front teeth, may occur as a result of severe periodontal disease. Examples of such compromised aesthetics with drifting, elongation, and the spacing of incisors are shown (Figs 1 and 2). The exact reasons for this drifting are not clearly understood. The inflammatory component of periodontal disease certainly contributes to this phenomenon, as the spontaneous repositioning of drifted teeth has been reported following control of the inflammatory component without specifically treating the periodontal attachment loss.<sup>19</sup>

The loss of periodontal attachment and bony support for teeth affects the balance between the forces acting on teeth from behind (the tongue and opposing teeth) and from in front (the lips and cheeks). These forces act during mastication, clenching, and grinding. This may lead to tooth hypermobility and must be appropriately managed. Some tooth hypermobility, however, may persist after periodontal treatment because this does not usually restore lost periodontal attachment. Careful treatment planning for such pa-

tients with severe periodontal disease, drifting, and hypermobile teeth and those who need dental prostheses should involve the periodontist, the orthodontist, and the restorative or general dentist.

## Principles for the orthodontic care of patients with periodontal disease

There are animal studies that show the deleterious effect of undertaking orthodontic tooth movement while periodontal tissues are actively inflamed.<sup>20,21</sup> The same deleterious effects have been noted in human clinical trials.<sup>22-25</sup> The principles of the orthodontic management of periodontally-involved teeth are based on animal experiments. If teeth with induced periodontal disease (that is subsequently successfully treated and supportive periodontal care is given during the orthodontic tooth movement) are moved orthodontically, no further loss of periodontal attachment or supporting bone is encountered. But if the induced periodontal disease is not treated and plaque control measures are not instituted, then the orthodontic tooth movement (particularly if teeth are moved in the direction of inflamed periodontal pockets that extend beyond the alveolar crest) causes further periodontal destruction.<sup>26</sup> Hence, orthodontic treatment should not be commenced in adult patients with periodontal disease before the disease has been brought under control.

During the orthodontic treatment, every effort should be made to quickly maximize the treatment benefit. The use of heavy orthodontically-generated forces, which teeth with a reduced height of periodontium may not be able to withstand, should be avoided. Optimal plaque control and freedom from active periodontal disease should be ensured through regular periodontal supportive care. Any new or recurrent periodontal disease encountered during the course of orthodontic treatment in such patients must be treated immediately. Following tooth movement in periodontally-compromised patients, post-orthodontic retention, in the form of techniques commonly used for splinting teeth, is often required.

The need for adult orthodontics in Hong Kong could be considered to be high, whereas awareness of the benefits to be gained from such treatment could be considered to be low. The authors encourage Hong Kong's health providers in general, and dentists in particular, to give patients oral health care information and to help increase general awareness of the benefits to be gained from the judicious use of available services.

A multi-disciplinary approach meets the oral health care needs of many adult patients and this should be recognised by all health care providers. For example, dramatic progress in recent years, has made it possible for combined orthodontics and orthognathic surgery to re-align jaws and re-position dentoalveolar segments in adult patients. Surgery is not a substitute for orthodontics in these patients—it must be properly coordinated with orthodontics and other dental treatments to achieve good overall results.

Patients who have had periodontal disease may request, or be assigned, orthodontic treatment to deal with the side-effects of periodontal disease—further support for a multi-disciplinary approach to the management of oral disease and malocclusion in adults.

### Acknowledgements

The authors wish to acknowledge the assistance given in the management of these patients by the various dental hygienists and general dentists involved in their care, and in particular the following colleagues: Dr K Yuen, the University of Hong Kong (Case 1); Dr S Akerman, the University of Lund (Case 2); and Prof H Tideman, the University of Hong Kong (Case 4).

### References

- Proffit WR, Fields HW, Ackerman JL, Sinclair PM, Thomas PM, Tulloch CJF. Contemporary orthodontics. 2nd ed. St Louis: Mosby Year Book, 1993.
- Kingsley NW. Treatise on oral deformities as a branch of mechanical surgery. New York: Appleton, 1880.
- Yip CK. The need and demand of orthodontics among young Chinese adults in Hong Kong [dissertation]. Hong Kong: Univ of Hong Kong, 1992.
- Perregaard J, Blixenchrone-Möller T. Why do adults seek orthodontic treatment? In: Proceedings of the 64th Congress of the European Orthodontic Society; 1988 July; London. London: European Orthodontic Society, 1988:61A.
- Behrents G. Growth in the ageing craniofacial skeleton, monograph 17. Craniofacial Growth Series. Ann Arbor, Michigan: Center for Human Growth and Development, University of Michigan; 1985.
- Reitan K. The initial tissue reaction incident to orthodontic tooth movement as related to the influence of function. *Acta Odont Scand* 1951; (6 Suppl): 240S.
- Moyers RE, Dryland-Vig KW, Fonseca RJ. Adult treatment. In Moyers RE, editor. Handbook of orthodontics. 4th ed. Chicago: Year Book Medical Publishers Inc., 1988:472-510.
- Musich DR. Assessment and description of the treatment needs of adult patients evaluated for orthodontic therapy: characteristics of the solo provider group (I). *Int J Adult Orthognath Surg* 1986;1:55-67.
- Musich DR. Assessment and description of the treatment needs of adult patients evaluated for orthodontic therapy II: characteristics of the dual provider group. *Int J Adult Orthognath Surg* 1986;1:101-17.
- Musich DR. Assessment and description of the treatment needs of adult patients evaluated for orthodontic therapy III: characteristics of the multiple provider group (I). *Int J Adult Orthognath Surg* 1986;1:251-74.
- Tayer BH, Burek MJ. A survey of adults' attitudes toward orthodontic therapy. *Am J Orthod* 1981;79:305-15.
- Deng YM, Fu MK, Hägg U. Prevalence of TMJ - dysfunction in Chinese 3-19 years old children. *Eur J Orthod* 1994; 16:487-95.
- Mohlin B. Need and demand for orthodontic treatment in a group of women in Sweden. *Eur J Orthod* 1982;4:231-42.
- Corbet EF, Lo EC. Tooth spaces in and prosthetic treatment received by Hong Kong adults and elderly. *Community Dent Oral Epidemiol* 1994;21:386-91.
- Schwarz E, Lo EC. Use of dental services by the middle-aged and the elderly in Hong Kong. *Community Dent Oral Epidemiol* 1994;22:374-80.
- Lind OP, Holmgren CJ, Evans RW, Corbet EF, Lim LP, Davies WT. Hong Kong survey of adult oral health, Part I: Clinical findings. *Community Dent Health* 1987;4:351-66.
- Holmgren CJ, Corbet EF, Lim LP. Periodontal conditions in Hong Kong adults and elderly. *Community Dent Oral Epidemiol* 1994;21:396-402.
- Corbet EF, Davies WI. Reasons given for tooth extraction in Hong Kong. *Community Dent Health* 1991;8:121-30.
- Mattout P, Moskow BS, Fourel J. Repair potential in juvenile periodontitis: a case in point. *J Periodontol* 1990;61:653-60.
- Ericsson I, Thilander B, Lindhe J, Okamoto H. The effect of orthodontic tilting movements on the periodontal tissues of infected and non-infected dentitions in dogs. *J Clin Periodontol* 1977;4:278-93.
- Melsen B. Tissue reaction following application of extrusive and intrusive forces to teeth in adult monkeys. *Am J Orthod* 1986;89:469-75.
- Zachrisson BU, Alnaes L. Periodontal condition in orthodontically treated and untreated individuals. I. Loss of attachment, gingival pocket depth and clinical crown height. *Angle Orthod* 1973;43:402-11.
- Artun J, Urbye KS. The effect of orthodontic treatment on periodontal bone support in patients with advanced loss of marginal periodontium. *Am J Orthod Dentofac Orthop* 1988;93:143-8.
- Boyd RL, Leggott PJ, Quinn RS, Eakle WS, Chambers D. Periodontal implications of orthodontic treatment in adults with reduced or normal periodontal tissues versus those of adolescents. *Am J Orthod Dentofac Orthop* 1989;96: 191-9.
- Polson A, Caton J, Polson AP, Nyman S, Novak J, Reed B. Periodontal response after tooth movement into infrabony defects. *J Periodontol* 1984;55:197-202.
- Wennström JL, Stokland BL, Nyman S, Thilander B. Periodontal tissue response to orthodontic movement of teeth with infrabony pockets. *Am J Orthod Dentofac Orthop* 1993;103:313-9.