

Distribution of carbon monoxide producing neurons in human colon and in Hirschsprung's disease patients

Yan Chen, Vincent C.H. Lui, Mai H. Sham* and Paul K.H. Tam

Division of Paediatric Surgery, Department of Surgery, University of Hong Kong Medical Centre, Queen Mary Hospital; and *Department of Biochemistry, University of Hong Kong, Hong Kong SAR, China.

Short title: CO deficiency in aganglionic colon

Correspondence:

Paul K.H. Tam

Division of Paediatric Surgery

Department of Surgery

University of Hong Kong Medical Centre

Queen Mary Hospital, Pokfulam

Hong Kong SAR, China

paultam@hkucc.hku.hk

Tel: (852)28554850

Fax: (852)28173155

Abbreviations: HSCR, Hirschsprung's disease; CO, carbon monoxide; NO, nitric oxide; HO-2, heme oxygenase-2; nNOS, neuronal nitric oxide synthase; ENS, enteric nervous system; NANC, nonadrenergic noncholinergic; NPY, neuropeptide Y; VIP, vasoactive intestinal peptide; ATP, adenosine tri-phosphate; ENK, enkephaline; LCM, laser capture microdissection; RT-PCR, reverse transcription-polymerase chain reaction.

Abstract

Hirschsprung's disease (HSCR) is characterized by the absence of ganglion cells and impaired relaxation of the gut. Nitric oxide (NO), and more recently, carbon monoxide (CO) have been identified as inhibitory neurotransmitters causing relaxation. A deficiency in NO has been reported in aganglionic gut; we hypothesized that CO could also be involved in impaired gut motility in HSCR. The aim of the study was to determine the distribution of CO- and NO-producing enzymes in the normal and aganglionic gut. We performed laser capture micro-dissection, reverse transcription-polymerase chain reaction, and immunohistochemistry on colon biopsies of normal controls (n=9) and patients with HSCR (n=10). The mRNA expression of heme oxygenase-2 (HO-2), immunoreactivities of HO-2 and NO synthase, was determined and compared. Results show a high level of expression of HO-2 mRNA was localized in the myenteric plexus. Expression of HO-2 mRNA was also detected in the mucosa, submucosa and the muscular layer. Down-regulation of the expression of HO-2 mRNA was detected in the aganglionic colon. Immunoreactivities of HO-2 and NO synthase were mainly localized to the ganglion plexus, and nerve fibers within the muscle in the control colons and normoganglionic colons of the patients. HO-2-containing neurons were more abundant than NO synthase-containing neurons in the myenteric plexus. Nearly all the NO synthase-containing neurons also had HO-2. HO-2 and NO synthase were selectively absent in the myenteric and submucosal regions, and in the muscle of the aganglionic colon. Our findings suggest the involvement of both CO and NO in the pathophysiology of HSCR.

Introduction

Hirschsprung's disease (HSCR) is a developmental disorder that is characterized by the deficiency of ganglion cells in the myenteric plexus and submucosal plexus of the distal colon. The distal aganglionic colon in patients with HSCR appears spastic. It is believed that the colon spasm, which causes bowel obstruction, is the result of the circular and longitudinal smooth muscle of the colon not relaxing. Gut peristalsis is mediated by a reflex pathway within the enteric nervous system (ENS) that can function autonomously, without any input from the central nervous system. The neurons of the ENS reside in two types of plexuses, namely the myenteric and submucosal plexuses. The former is between the outer longitudinal and inner circular muscle layer, and the latter is in the submucosal region of the gut. The myenteric and submucosal plexuses are interconnected with intrinsic nerve fibers and form the entire neural network encompassing the full length of the digestive tract. Peristalsis, a rhythmic contraction and relaxation of the two muscle layers of the gut wall, propels the gut content in the lumen uni-directionally. The contraction and relaxation of the two muscle layers are mediated respectively by the activities of the excitatory and inhibitory nerves of the ENS.

In normal bowel, relaxation is mediated, at least in part, by nonadrenergic noncholinergic (NANC) nerve. Gaseous molecules of nitric oxide (NO) and carbon monoxide (CO) are neurotransmitters of NANC neurons. NO and CO are produced by neuronal nitric oxide synthase (nNOS) and heme oxygenase-2 (HO-2), respectively in NANC neurons. The physiological functions of CO and NO in smooth muscle relaxation of the gastrointestinal tract have been demonstrated in genetically engineered mice that do not possess HO-2 and/or nNOS activity^{12,39}. NANC mediated relaxation stimulated by 1'1-dimethyl-4 phenylpiperazinium (DMPP) or electrical field stimulation (EFS) in the gut and isolated smooth muscle cells were substantially suppressed in the HO-2 and nNOS deficient mice^{35,39}.

The effect of the absence of CO in the intestinal relaxation was dramatic and the overall transit through the gastrointestinal tract was significantly slower in the HO-2 deficient mice. The absence of NO had a milder and more localized effect and the nNOS deficient mice exhibited delayed gastric emptying with nearly normal transit through the intestine and colon.

Immunohistochemical and histochemical studies of the aganglionic colon of patients with HSCR have indicated the absence of nitric oxide producing nerves in the plexus area and in the musculature of the aganglionic colon^{23,30}. Functional studies have shown that the internal anal sphincter of patients with HSCR is not responsive to the exogenous NO, suggesting that NO alone is not sufficient to restore the neural deficit^{2,3}. This could be explained by a recent finding, that the nNOS-NO system cannot function unless CO is a coneurotransmitter, and that the effects of CO and NO on muscle relaxation are shown to be additive³⁵. In line with the proposed coneurotransmitter function of CO and NO, HO-2 and nNOS have been colocalized in the ganglionic plexuses of the anorectum in opossum¹, and the stomach and jejunum in humans²¹. In order to investigate the role of CO and NO in the pathophysiology of HSCR, we determined the distribution of HO-2, and nNOS in the colon of patients with and without HSCR using laser capture micro-dissection, reverse transcription-polymerase chain reaction (RT-PCR), and immunohistochemistry.

Materials and methods

Samples collection

Fresh resected specimens of colon were collected from 10 patients with HSCR. Analysis of the rectal biopsy samples of these patients revealed an absence of ganglion cells. Hematoxylin and eosin staining, and acetylcholinesterase histochemical staining on rectal biopsies of patients with HSCR performed by pathologists, confirmed the diagnosis of HSCR in all 10 cases (Table 1). Site-matched specimens of the colon from seven age-matched infants with conditions unrelated to HSCR were included as controls (imperforate anus, n=6; necrotizing enterocolitis, n=1); two adults patients with rectal cancer were separately studied as alternate controls. These control colon specimens were obtained from normal colons proximal to and well away from the diseased bowel; histological analysis of control specimens confirmed no dysganglionosis. Tissue samples were divided for mRNA experiments studies and immunohistochemistry.

Tissue preparation for RNA extraction

Full-thickness specimens from the normoganglionic, hypoganglionic, and aganglionic zones of the bowel of each patient with HSCR and the colons of normal controls were used for RNA extraction using Trizol (Life Technologies, Rockville, MD). The study was approved by the Ethics Committee of the University of Hong Kong, Faculty of Medicine, and tissues were obtained with patients' informed consent.

Semi-quantitative reverse transcription-polymerase chain reaction (RT-PCR)

First strand cDNA was synthesized from 1 μ g of total RNA using oligo d(T)₁₂₋₁₈ as a reverse primer (SuperScript[®] Preamplification System, Life Technologies). Expression of *HO-2* and

β-actin were analyzed using PCR. PCR was performed in 25 μl of standard buffer containing primers (1 μM each), 3 μl of cDNA, 0.5 units of AmpliTaq polymerase (Life Technologies), MgCl₂ (1.5 mM), and dNTP (0.2 mM). After the initial denaturation at 94°C for three minutes, PCR was performed for 30 cycles for *HO-2* and *β-actin* as follows: 30 seconds denaturation at 94°C; one minute annealing at 60°C; 1 minute extension at 72°C for each cycle. A final extension for 10 minutes at 72°C was added. Details of PCR primers and sizes of the RT-PCR products were depicted as shown in Table 2. PCR primers for *HO-2* and *β-actin* genes were specially designed to span at least two exons. With exon-spanning PCR primers, PCR products using the genomic DNA as template would be bigger than those from cDNA and therefore could be readily resolved by gel electrophoresis. The PCR products were analyzed by electrophoresis in a 1% agarose gel. Intensities of PCR bands were quantified and relative expression levels of *HO-2* to *β-actin* were determined using Scion Image software and the comparative method as described by Nicoletti and Sassy-Prigeut²².

Laser Capture Microdissection (LCM) and RT-PCR

In order to determine and compare the expression of *HO-2* in different regions of human colon, we performed LCM and semi-quantitative RT-PCR analysis. Mucosa, submucosa, muscle, and myenteric plexus of the colon were excised from the cryosections of normal colon of three controls for total RNA extraction and semi-quantitative RT-PCR analysis. Relative expression of *HO-2* to the house-keeping gene, *β-actin*, in various excised regions was determined and compared. Colon specimens were embedded in OCT (Sakura Finetek USA Inc. Torrance, USA) and snap frozen in liquid nitrogen before storage at -80°C. Cryosections (12 μm) were prepared on cryotome and mounted on the polyethylene membrane of a histology slide. The sections were stained briefly with hematoxylin and dried completely. Defined regions of the gut were dissected with the PALM LCM (P.A.L.M. Mikrolaser

Technologie, Germany). The mucosa (epithelium layer and lamina propria), submucosa, muscles (circular and longitudinal layers), and myenteric plexus were dissected. Total RNA was isolated from the dissected regions using a Stratagene[®] micro RNA isolation kit following the manufacturer's protocol (Stratagene Cloning Systems, La Jolla, USA). Semi-quantitative RT-PCR analysis of the expression of *HO-2* in different regions of the colon was performed as described above.

Statistic analysis

Means and standard error of the mean (SEM) of the relative expression of *HO-2* to β -actin were determined for each group. Wilcoxon signed rank test was performed using GraphPAD PRISM software (GraphPAD Software, San Diego, CA) to evaluate the significance of the differences between the relative expression of *HO-2* in various segments of patients with HSCR. Unpaired Student t test was performed to evaluate the significance of the differences between the relative expression of *HO-2* in normoganglionic segments of patients with HSCR and normal control bowels.

Immunohistochemistry

Tissues were fixed in 4% formaldehyde/PBS (phosphate buffered saline, pH 7.2) for 16 hours before embedding in paraffin, and sections (4 μ m) were prepared. Antigen unmasking was performed by heating the slides for five minutes at 95°C in 10mM citrate buffer (pH 6). The sections were incubated in 3% hydrogen peroxide in methanol (v/v) to quench the endogenous peroxidase activity. Blocking of sections, incubation of antibodies, and color development were performed using the DAKO EnVision^{TM+} System, HRP (Dako A/S, Glostrup, Denmark). Anti *HO-2* polyclonal antibody (Stressgen[®]; 1:12,000)(StressGen, Victoria BC, Canada) and anti nNOS antibody (Santa Cruz; 1: 4000)(Santa Cruz

Biotechnology, CA, USA) were incubated with the slides at ambient temperature for two hours. Sections were counterstained with haematoxylin, dehydrated, cleared in xylene and mounted in DPX mountant (BDH Laboratory Supplies, Poole, Dorset, UK). Semiquantitation of HO-2 and nNOS immunopositive neurons within the myenteric plexus of normal human colon were made by counting cell in 6 randomly selected sections. Two observers counted separately and the results were compared.

Results

Differential distribution of *HO-2* transcript in normal human colon

Laser capture microdissection allowed different regions of colon to be accurately separated for mRNA experiment analysis. To quantify the expression level of *HO-2* in different regions of the gut, we determined the relative expression levels of *HO-2* using *β-actin* as an internal control. The *β-actin* gene encodes a nonmuscle cytoskeletal actin that is expressed constitutively in all cell types, and *β-actin* gene has been widely used as an internal control for semi-quantitative RT-PCR analysis. No amplified product was obtained in negative controls in which the reverse transcriptase was omitted (data not shown). This indicates that the amplicons observed in our samples were not PCR products of the contaminating genomic DNA. *HO-2* transcripts were detected in the mucosa, submucosa, muscle, and myenteric plexus. The highest level of expression of *HO-2* was detected in the myenteric plexus (Figure 1). The findings in the infant and adult controls were similar.

Down-regulation of *HO-2* in aganglionic colon of patients with HSCR

To determine if CO is involved in the pathophysiology of HSCR, we used a semi-quantitative RT-PCR method to determine and compare the expression of *HO-2* in full-thickness specimens from the normoganglionic and aganglionic colon of patients with HSCR (n=10), and the colon of controls (n=9) (Figure 2). The ratio of *HO-2/β-actin* was 0.27 ± 0.06 (means \pm SEM), 0.50 ± 0.18 (means \pm SEM), and 0.59 ± 0.21 (means \pm SEM) in the aganglionic, normoganglionic colon of patients with HSCR, and colon of controls, respectively. The relative expression of *HO-2* in the aganglionic colon was significantly lower than that in the normoganglionic colon of patients with HSCR (p=0.03). The relative expression of *HO-2* was however not significantly different between the normoganglionic colon of patients with HSCR and the control colons (p=0.77).

Distribution of HO-2 and nNOS immunoreactivity in the colon of patients with HSCR and in controls

HO-2 and nNOS immunoreactivity were mainly localized in the neuronal cell bodies of the myenteric plexus and submucosal plexus of the colon, and the nerve fibers within the longitudinal and circular muscles (Figure 3). HO-2 and nNOS immunoreactivity was also present in the cell bodies and the processes of enteric neurons, in the nerve fascicles of the plexus.

The ganglion plexuses in the gut are composed of two morphologically distinct cell types: glial cells and neurons. The nuclei of glial cells are smaller and slightly elongated while the nuclei of neurons are bigger and round. Within the myenteric plexus, HO-2 immunoreactive enteric neurons were more abundant than the nNOS immunoreactive enteric neurons (means, 82.5% versus 57%). On the contrary, HO-2 immunoreactive nerve fibers were much less abundant than nNOS immunoreactive nerve fibers in the muscle. In addition to the enteric ganglion plexus, HO-2 immunoreactivity was also present in the mucosal epithelium, lamina propria, and the endothelial cells of submucosal blood vessels (Figure 3). Immunoreactivity of nNOS was localized to a few mucosal epithelial cells, and endothelial cells of submucosal blood vessels (Figure 3).

Immunohistochemistry was performed on adjacent sections to investigate the colocalization of HO-2 and nNOS in the colon. Within the myenteric plexus, nearly all the nNOS immunoreactive neurons also contained HO-2 (Figure 4). In contrast, neurons that only showed immunoreactivity for HO-2 and not for nNOS were found in the myenteric plexus. Numerous neurons were immunoreactive for both HO-2 and nNOS in the submucosal plexus (data not shown).

The distribution of HO-2 and nNOS immunoreactivity in normoganglionic colons of patients with HSCR was identical to that of controls (data not shown). In contrast, HO-2 and nNOS immunoreactivity was completely absent from the submucosal and myenteric regions of the aganglionic colon (Figure 5C, F). No HO-2 and nNOS immunoreactive nerve fibers could be localized within the longitudinal and circular muscles in the aganglionic colon (Figure 5C, F). Instead, weak HO-2 and nNOS immunoreactivity was detected in the hypertrophic nerve trunks, in the myenteric and submucosal regions of the aganglionic colon (Figure 5C, F). A gradual reduction of HO-2 and nNOS immunoreactivity in the myenteric region, and in the nerve fibers within the muscle, occurred from the hypoganglionic to the aganglionic colon (Figure 5). HO-2 and nNOS immunoreactivity at the mucosal epithelium and the submucosal blood vessels was unaffected in the aganglionic colon, indicating that the lack of HO-2 and nNOS immunoreactivity in the myenteric and submucosal regions, and in the muscle nerve fibers were not experimental artefacts (data not shown). No signal was observed on the negative control sections if the primary antibody was omitted (data not shown).

Discussion

Nitric oxide (NO) and carbon monoxide (CO) are considered as neurotransmitters in the central, peripheral, and enteric nervous systems^{5,8,25,33,39}. In the gastrointestinal tract, CO and NO that are released from the inhibitory nonadrenergic noncholinergic (NANC) neurons of the ENS diffuse into adjacent smooth muscle cells. CO or NO binds and activates an enzyme guanylate cyclase, in the cytoplasm of the muscle cells. Activated guanylate cyclase catalyses the formation of guanosine 3', 5'-cyclic monophosphate (cGMP) from guanosine monophosphate (GMP). High intracellular cGMP causes relaxation of the muscle cells. The effects of CO and NO in the relaxation of the smooth muscles of the gastrointestinal tract have been demonstrated in mice^{25,35,39}, in the internal anal sphincters in opossums⁴, and in colon of human^{2,3}. A deficiency of NO-producing neurons has been reported in aganglionic colons of patients with Hirschsprung's disease (HSCR)^{23,30}. However, the distribution of CO-producing neurons in the ENS of the normal and aganglionic colon has not been described. Our present study provides data on the detailed localization of both CO- and NO-producing neurons in the ENS of the normal human colon, and in the normoganglionic and aganglionic colon of patients with HSCR.

The immunoreactivity of HO-2 and nNOS was mainly localized in neuronal cell bodies of the myenteric plexus and submucosal plexus of the colon, and in the nerve fibers within the longitudinal and circular muscles. Semi-quantitative RT-PCR analysis of the micro-dissected regions of normal colon using a laser capture micro-dissection (LCM) technique also showed a high level of mRNA expression of *HO-2* in the myenteric plexus and muscle.

Our immunohistochemical study indicated that approximately 82.5% and 57% of enteric neurons showed HO-2 and nNOS immunoreactivity respectively in the myenteric plexus of the human colon. Numerous neurons were found to be immunoreactive for both

HO-2 and nNOS in the submucosal plexus. Our finding of an abundance of HO-2 immunoreactive neurons in myenteric plexus of colon is comparable to previous findings in the human antrum and jejunum. The percentages of HO-2 containing neurons in the myenteric plexuses of the antrum and jejunum were 77% and 92% respectively²⁰. Our data showed that nearly all the nNOS immunoreactive neurons also contained HO-2. A high degree of colocalization of HO-2 and nNOS immunoreactivity in neurons has also been observed in the human antrum and jejunum²⁰, in the human urethral sphincter¹¹, and in the anorectum of opossums¹. Data from this and other studies suggest a high percentage of enteric neurons produce both CO and NO. Colocalization of CO- and NO- producing systems in the enteric neurons has important functional implications. This is in line with recently evidence that suggest the nNOS-NO system cannot function without CO as a coneurotransmitter³⁵.

Semi-quantitative RT-PCR analysis showed that the expression level of *HO-2* mRNA in the normoganglionic colon of patients with HSCR was comparable to that in the colon of normal controls. However, *HO-2* was significantly down-regulated in the aganglionic colon of all 10 patients with HSCR. Furthermore, the distribution of HO-2 and nNOS immunoreactivity in the normoganglionic colon of patients with HSCR was identical to that of the controls. In contrast, HO-2 and nNOS immunoreactivity was completely absent from the myenteric and submucosal regions of the aganglionic colon. No HO-2 and nNOS immunoreactive nerve fibers could be localized within the muscles in the aganglionic colon. Our data showed that CO- and NO- producing neurons were selectively absent in the enteric nervous system of the aganglionic colon of patients with HSCR. In aganglionic colon, the intramural regions are replaced with hypertrophic nerve trunks. The hypertrophied nerve trunks consist of cholinergic nerve fibres that have been shown to be extrinsic parasympathetic nerve fibres of sacral origin^{15,29}. The hypertrophic nerve trunks in the

aganglionic bowel were weakly immunopositive for HO-2 and nNOS indicating that the extrinsic neural components also synthesize and secrete CO and NO as neurotransmitters.

In addition to CO and NO, neurotransmitters such as neuropeptide Y (NPY); vasoactive intestinal peptide (VIP); adenosine tri-phosphate (ATP) and enkephaline (ENK) have also been identified in the inhibitory NANC neurons⁷. Bowel innervation consists of intrinsic and extrinsic neural components that include ganglion cells, nerve fibres and supporting cells. In the aganglionic bowel of Hirschsprung's disease, there is a deficiency of intrinsic nerve cells and nerve processes arising from these cells but not necessary a deficiency of other components. While there is reduction of VIP^{6,17,27}, substance P (SP)^{17,27,28}, and gastrin-releasing peptide (GRP)¹⁷ in aganglionic bowel, calcitonin gene-related peptide (CGRP) and galanin¹⁸ levels are unchanged, and NPY^{9,16}, somatostatin¹⁹ and chromogranin²⁶ levels are increased. This indicates that a deficiency of intrinsic neural components does not necessary result in a pan-reduction of all neurotransmitters in the aganglionic bowel. The individual roles of various neural components in the pathogenesis of Hirschsprung's disease remain to be dissected.

CO and NO have been shown to account for most of the NANC neurotransmission in the gut, suggesting CO and NO are the major neurotransmitters of NANC neurons of the ENS³⁹. Recently, interstitial cells of Cajal (ICC) were shown to contain HO-2 and nNOS in the gastrointestinal tract in mice, canine, humans, and opossum^{1,20,24,34}. CO and NO may serve as an intercellular transmitter between myenteric neurons and ICC, and between ICC and smooth muscle cells. ICC are found throughout the whole gastrointestinal tract and is required for normal gut motility. A deficiency in ICC has been reported in human gut motility disorders including HSCR^{32,36,37}, pseudo-obstruction^{13,14,38}, infantile pyloric stenosis³¹, and slow transit constipation¹⁰. Therefore, it is likely that a deficiency in CO and NO could cause functional deficiency of inhibitory NANC neurons and ICC in the

aganglionic colon. This, in turn, manifests as gut dysmotility and functional obstruction in patients with HSCR.

Our data suggest that CO, in addition to NO, may play a role in the pathophysiology of Hirschsprung's disease. The role of CO and NO in the pathology of other human gut motility disorders such as slow transit constipation, pseudo-obstruction requires additional study.

Legends

Figure 1. Differential expression of *HO-2* in the myenteric plexus of the human colon. The hematoxylin and eosin stained cryosection (4 μ m) of the colon of a normal control. The mucosa, submucosa, muscle, and myenteric plexuses (arrowhead) of the colon (marked with lines) were excised with LCM (left panel). RNA was prepared from the excised gut regions for RT-PCR analysis for *HO-2* and β -actin. Amplicons of *HO-2* and β -actin were resolved by agarose gel electrophoresis. A typical gel picture of the RT-PCR analysis is shown (top right panel). The RT-PCR bands were quantified, and the relative expressions of *HO-2* to β -actin in each region were calculated and are shown as a bar graph (bottom right panel). Scale bar represents 50 μ m.

Figure 2. Down-regulation of *HO-2* in the aganglionic colon of patient with Hirschsprung's disease. A typical gel picture of the RT-PCR results of *HO-2* and β -actin of RNA isolated from the colon of a normal control (C); normoganglionic (N); hypoganglionic (H), and aganglionic (A) colon of a patient with Hirschsprung's disease (top panel). The RT-PCR bands were quantified, and the relative expressions of *HO-2* to β -actin in various segments were calculated and shown as a bar graph (bottom panel). A total of 10 patients with Hirschsprung's disease and seven age-matched controls were recruited in the present analysis. The relative expression of *HO-2* in aganglionic colon was significantly lower than that in the normoganglionic colon of patients with Hirschsprung's disease ($p < 0.05$).

Figure 3. Immunohistochemical analysis of HO-2 and nNOS in normal colon. The immunoreactivity of HO-2 and nNOS (arrowheads) was detected in the mucosa, submucosal plexuses, nerves fibers in the muscle layer, and myenteric plexus. Scale bars represent 50 μ m.

Figure 4. Colocalization of HO-2 and nNOS in the ganglion plexuses. The nNOS immunoreactive neurons were usually immunoreactive for HO-2 (arrowheads). Neurons that

only showed immunoreactivity for HO-2 and not for nNOS were found in the myenteric plexus (unfilled arrowheads). Scale bars represent 50 μm .

Figure 5. Gradual reduction of HO-2 and nNOS immunoreactivity from the hypoganglionic to the aganglionic colon. Immunostaining of HO-2 (A, B, C) and nNOS (D, E, F) in the hypoganglionic gut (A, D), aganglionic gut (C, F), and the transitional zone between the hypoganglionic and aganglionic colon (B, E). HO-2 and nNOS immunoreactive nerve fibres and plexuses (arrowheads) were found in the hypoganglionic colon (A, D). HO-2 and nNOS immunoreactive nerve fibers were scarce in the transitional zone (B, E). The hypertrophic nerve trunk (unfilled arrowhead) was weakly immunoreactive for HO-2 and nNOS in the aganglionic colon (C, F). Scale bars represent 50 μm .

Table 1. Clinical data of the patients with HSCR

Case No.	Age (months)	Sex	Familial (F) Sporadic (S)	Diagnosis
4668	10.5	M	S	Short HSCR
4765	11	F	S	Long HSCR
5055	10	M	S	Short HSCR
5585	50.5	M	S	Short HSCR
6297	39.5	M	S	Short HSCR
7853	5	M	S	Long HSCR
8444	9.5	M	S	Short HSCR
B100	3.5	F	S	Short HSCR
B131	17.5	M	S	Short HSCR
B241	3.5	F	S	Short HSCR

Detail including age, sex, familial or sporadic and diagnosis of HSCR are shown.

Table 2. PCR primers for human *HO-2* and *β -actin*

Gene	Primer	Position	Product
<i>HO-2</i>	F: 5'-AGGAAATGGAGCGCAACA-3' (exon 3)	332-349	554 bp
	R: 5'-GAAAGGGCATTACGCATGTC-3' (exon 4)	885-865	
<i>β-actin</i>	F: 5'-GTGGGGCGCCCCAGGCACCA-3' (exon 2)	176-195	450 bp
	R: 5'-CTCCTTAATGTCACGCACGATTTC-3' (exon 4)	715-692	

Nucleotide positions of primers for *HO-2* and *β -actin* were numbered from the published mRNA sequences NM_002134 and NM_001101 in NCBI, respectively. Amplicon sizes were indicated in base pairs (bp).

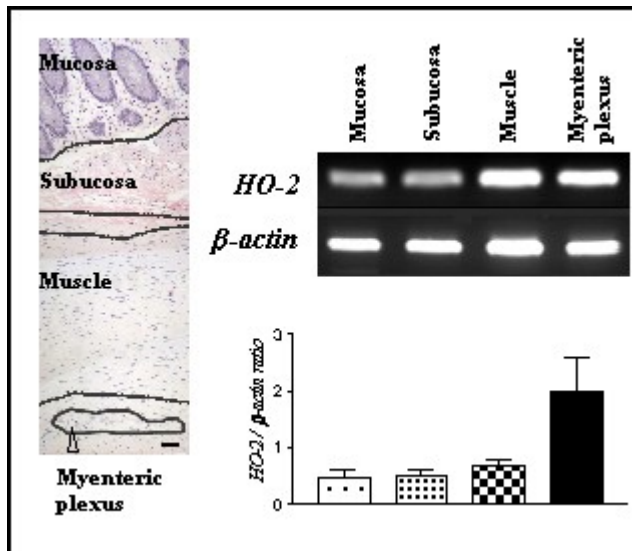


Figure 1

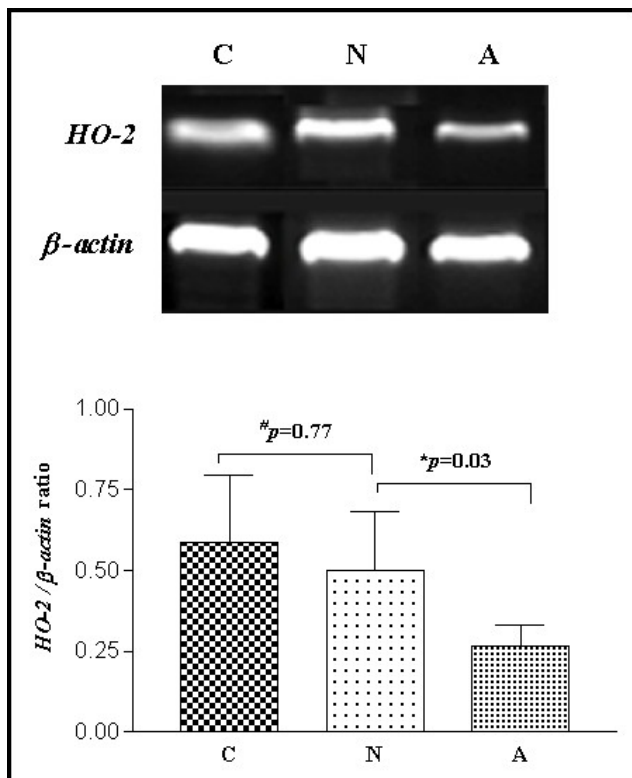


Figure 2

$^{\#}p$: Unpaired Student *t* test
 *p : Wilcoxon signed rank test

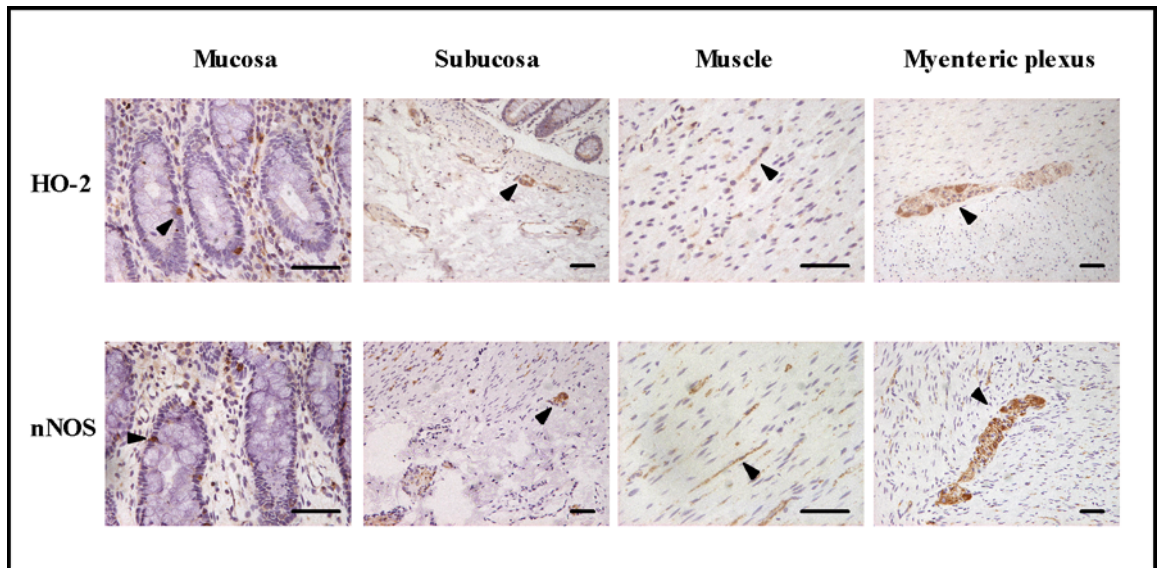


Figure 3

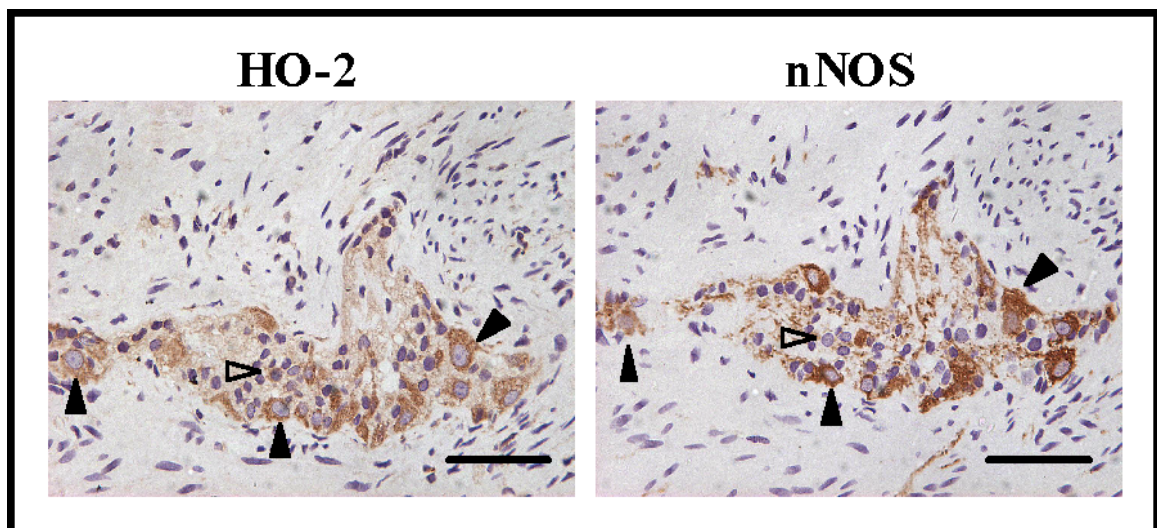


Figure 4

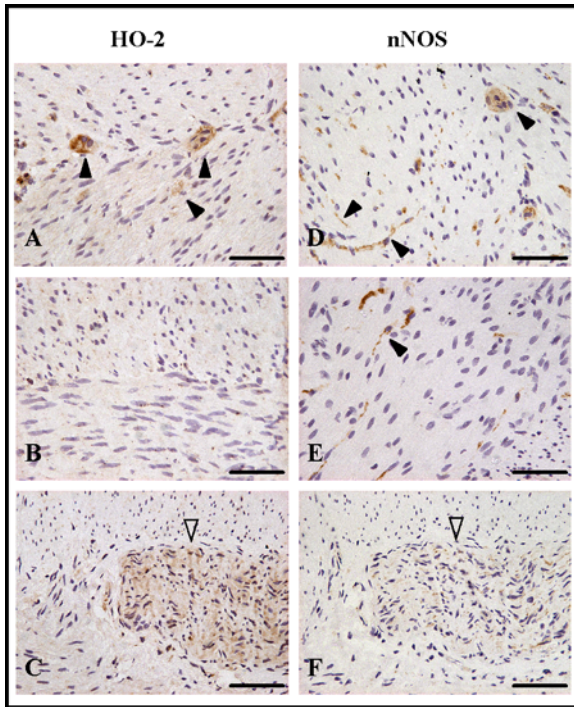


Figure 5

References

1. Battish R, Cao GY, Lynn RB, et al.: Heme oxygenase-2 distribution in anorectum: colocalization with neuronal nitric oxide synthase. *Am J Physiol Gastrointest Liver Physiol* 278:G148-55, 2000
2. Bealer JF, Natuzzi ES, Buscher C, et al.: Nitric oxide synthase is deficient in the aganglionic colon of patients with Hirschsprung's disease. *Pediatrics* 93:647-51, 1994
3. Bealer JF, Natuzzi ES, Flake AW, et al.: Effect of nitric oxide on the colonic smooth muscle of patients with Hirschsprung's disease. *J Pediatr Surg* 29:1025-9, 1994
4. Chakder S, Cao GY, Lynn RB, et al.: Heme oxygenase activity in the internal anal sphincter: effects of nonadrenergic, noncholinergic nerve stimulation. *Gastroenterology* 118:477-86, 2000
5. Dawson TM, Snyder SH: Gases as biological messengers: nitric oxide and carbon monoxide in the brain. *J Neurosci* 14:5147-59, 1994
6. Freund HR, Humphrey CS, Fischer JE: Reduced tissue content of vasoactive intestinal peptide in aganglionic colon of Hirschsprung's disease. *Am J Surg* 141:243-4, 1981
7. Furness JB: Types of neurons in the enteric nervous system. *J Auton Nerv Syst* 81:87-96, 2000
8. Goyal RK, Hirano I: The enteric nervous system. *N Engl J Med* 334:1106-15, 1996
9. Hamada Y, Bishop AE, Federici G, et al.: Increased neuropeptide Y-immunoreactive innervation of aganglionic bowel in Hirschsprung's disease. *Virchows Arch A Pathol Anat Histopathol* 411:369-77, 1987

10. He CL, Burgart L, Wang L, et al.: Decreased interstitial cell of cajal volume in patients with slow- transit constipation. *Gastroenterology* 118:14-21, 2000
11. Ho KM, Ny L, McMurray G, et al.: Co-localization of carbon monoxide and nitric oxide synthesizing enzymes in the human urethral sphincter. *J Urol* 161:1968-72, 1999
12. Huang PL, Dawson TM, Brecht DS, et al.: Targeted disruption of the neuronal nitric oxide synthase gene. *Cell* 75:1273-86, 1993
13. Isozaki K, Hirota S, Miyagawa J, et al.: Deficiency of c-kit+ cells in patients with a myopathic form of chronic idiopathic intestinal pseudo-obstruction. *Am J Gastroenterol* 92:332-4, 1997
14. Kenny SE, Vanderwinden JM, Rintala RJ, et al.: Delayed maturation of the interstitial cells of Cajal: a new diagnosis for transient neonatal pseudoobstruction. Report of two cases. *J Pediatr Surg* 33:94-8, 1998
15. Kobayashi H, Hirakawa H, Puri P: NADPH-diaphorase histochemistry: a reliable test for the intraoperative diagnosis of Hirschsprung's disease. *J Pediatr Surg* 31:1552-3, 1996
16. Larsson LT, Malmfors G, Ekblad E, et al.: NPY hyperinnervation in Hirschsprung's disease: both adrenergic and nonadrenergic fibers contribute. *J Pediatr Surg* 26:1207-14, 1991
17. Larsson LT, Malmfors G, Sundler F: Peptidergic innervation in Hirschsprung's disease. *Z Kinderchir* 38:301-4, 1983
18. Larsson LT, Malmfors G, Sundler F: Neuropeptide Y, calcitonin gene-related peptide, and galanin in Hirschsprung's disease: an immunocytochemical study. *J Pediatr Surg* 23:342-5, 1988

19. Lolova I, Davidoff M, Itzev D, et al.: Distribution of substance P-, methionine-enkephalin-, somatostatin- and serotonin-immunoreactive nerve elements of the large bowel in Hirschsprung's disease. *Zentralbl Allg Pathol* 132:25-32, 1986
20. Miller SM, Farrugia G, Schmalz PF, et al.: Heme oxygenase 2 is present in interstitial cell networks of the mouse small intestine. *Gastroenterology* 114:239-44, 1998
21. Miller SM, Reed D, Sarr MG, et al.: Haem oxygenase in enteric nervous system of human stomach and jejunum and co-localization with nitric oxide synthase. *Neurogastroenterol Motil* 13:121-31, 2001
22. Nicoletti A, Sassy-Prigent C: An alternative quantitative polymerase chain reaction method. *Anal Biochem* 236:229-41, 1996
23. O'Kelly TJ, Davies JR, Tam PK, et al.: Abnormalities of nitric-oxide-producing neurons in Hirschsprung's disease: morphology and implications. *J Pediatr Surg* 29:294-9; discussion 299-300, 1994
24. Porcher C, Orsoni P, Berdah S, et al.: Distribution of heme oxygenase 2 in nerves and c-kit(+) interstitial cells in human stomach. *Histochem Cell Biol* 112:317-22, 1999
25. Rattan S, Chakder S: Inhibitory effect of CO on internal anal sphincter: heme oxygenase inhibitor inhibits NANC relaxation. *Am J Physiol* 265:G799-804, 1993
26. Shen Z, Larsson LT, Malmfors G, et al.: Chromogranin A and B in neuronal elements in Hirschsprung's disease: an immunocytochemical and radioimmunoassay study. *J Pediatr Surg* 29:1293-301, 1994

27. Taguchi T, Tanaka K, Ikeda K, et al.: Peptidergic innervation irregularities in Hirschsprung's disease. Immunohistochemistry--radioimmunoassay. *Virchows Arch A Pathol Anat Histopathol* 401:223-35, 1983
28. Tam PK: An immunochemical study with neuron-specific-enolase and substance P of human enteric innervation--the normal developmental pattern and abnormal deviations in Hirschsprung's disease and pyloric stenosis. *J Pediatr Surg* 21:227-32, 1986
29. Tam PK, Boyd GP: Origin, course, and endings of abnormal enteric nerve fibres in Hirschsprung's disease defined by whole-mount immunohistochemistry. *J Pediatr Surg* 25:457-61, 1990
30. Vanderwinden JM, De Laet MH, Schiffmann SN, et al.: Nitric oxide synthase distribution in the enteric nervous system of Hirschsprung's disease. *Gastroenterology* 105:969-73, 1993
31. Vanderwinden JM, Liu H, De Laet MH, et al.: Study of the interstitial cells of Cajal in infantile hypertrophic pyloric stenosis. *Gastroenterology* 111:279-88, 1996
32. Vanderwinden JM, Rumessen JJ, Liu H, et al.: Interstitial cells of Cajal in human colon and in Hirschsprung's disease. *Gastroenterology* 111:901-10, 1996
33. Verma A, Hirsch DJ, Glatt CE, et al.: Carbon monoxide: a putative neural messenger. *Science* 259:381-4, 1993
34. Xue C, Pollock J, Schmidt HH, et al.: Expression of nitric oxide synthase immunoreactivity by interstitial cells of the canine proximal colon. *J Auton Nerv Syst* 49:1-14, 1994
35. Xue L, Farrugia G, Miller SM, et al.: Carbon monoxide and nitric oxide as neurotransmitters in the enteric nervous system: evidence from genomic deletion of biosynthetic enzymes. *Proc Natl Acad Sci U S A* 97:1851-5, 2000

36. Yamataka A, Kato Y, Tibboel D, et al.: A lack of intestinal pacemaker (c-kit) in aganglionic bowel of patients with Hirschsprung's disease. *J Pediatr Surg* 30:441-4, 1995
37. Yamataka A, Ohshiro K, Kobayashi H, et al.: Intestinal pacemaker C-KIT+ cells and synapses in allied Hirschsprung's disorders. *J Pediatr Surg* 32:1069-74, 1997
38. Yamataka A, Ohshiro K, Kobayashi H, et al.: Abnormal distribution of intestinal pacemaker (C-KIT-positive) cells in an infant with chronic idiopathic intestinal pseudoobstruction. *J Pediatr Surg* 33:859-62, 1998
39. Zakhary R, Poss KD, Jaffrey SR, et al.: Targeted gene deletion of heme oxygenase 2 reveals neural role for carbon monoxide. *Proc Natl Acad Sci U S A* 94:14848-53, 1997