

Reversible acute renal failure in a patient with IgA nephropathy

SL Lui, KW Chan, TM Chan, IKP Cheng

Reversible acute renal failure is a rare complication of IgA nephropathy. We report a patient with IgA nephropathy who developed acute renal failure after an episode of gross haematuria. Renal biopsy revealed extensive acute tubular damage and red blood cell casts. His renal failure recovered spontaneously without specific treatment. The clinical and pathological features of this IgA nephropathy complication are discussed.

HKMJ 1995; 1:351-353

Key words: Glomerulonephritis, IgA; Hematuria; Kidney failure, acute

Introduction

IgA nephropathy is the most common type of primary glomerulonephritis found.¹ Patients with IgA nephropathy usually present with either asymptomatic microscopic haematuria and proteinuria or acute reversible episodes of gross haematuria, often associated with respiratory or gastrointestinal infections. Acute renal failure (ARF) is an uncommon presentation. We present a patient with IgA nephropathy who developed acute reversible renal failure after an episode of gross haematuria, which was associated with tubular red cell casts in his renal biopsy.

Case report

A 22-year-old Chinese man presented to a regional hospital in May 1994 with gross haematuria and proteinuria. His blood pressure was normal and his serum creatinine level was 80 $\mu\text{mol/L}$. Renal biopsy revealed a mesangial proliferative glomerulonephritis. Immunofluorescence staining showed diffuse strong IgA and C3 staining in the mesangium; a diagnosis of IgA nephropathy was made. He defaulted follow up. In January 1995, he presented to our unit with gross

haematuria after an episode of upper respiratory tract infection. The physical examination was unremarkable. His blood pressure was 140/80 mmHg. Urinalysis revealed numerous red blood cells (RBC). His renal function was impaired with a serum creatinine level of 212 $\mu\text{mol/L}$; serum urea of 13.5 mmol/L, and 24-hour urine protein excretion of 1.68 g. The drug history was unremarkable and the antinuclear factor titre was not elevated. The C3 and C4 levels were both normal at 184 mg/dL (normal range, 60-130) and 79 mg/dL (normal range, 13-60), respectively.

An ultrasonogram of the kidneys showed normal findings except for a slight increase in parenchymal echogenicity. There was no evidence of renal vein thrombosis. His renal function deteriorated rapidly following admission, with his serum creatinine rising to 517 $\mu\text{mol/L}$ within three days. He remained non-oliguric and his haemodynamic parameters were stable. Renal biopsy at this time showed similar glomerular changes, namely diffuse mesangial proliferation, as in the first biopsy (Fig 1a) with numerous RBC casts in the cortical and medullary tubules (Fig 1b). Immunofluorescence staining showed diffuse IgA deposits in the mesangium (Fig 1c). Acute tubular injury was suggested by the loss of normal tubular epithelium and the presence of cytoplasmic vacuolation. Glomerular crescents were not observed. His renal function improved spontaneously and his serum creatinine decreased to 193 $\mu\text{mol/L}$ four days later. At follow up four weeks later, his serum creatinine was 77 $\mu\text{mol/L}$. Urinalysis revealed trace proteinuria and microscopic haematuria.

The University of Hong Kong, Queen Mary Hospital, Pokfulam, Hong Kong:

Division of Nephrology, Department of Medicine

SL Lui, MB, BS, MRCP

TM Chan, MD, MRCP

IKP Cheng, PhD, FRACP

Department of Pathology

KW Chan, MB, BS, MRCPPath

Correspondence to: Dr SL Lui

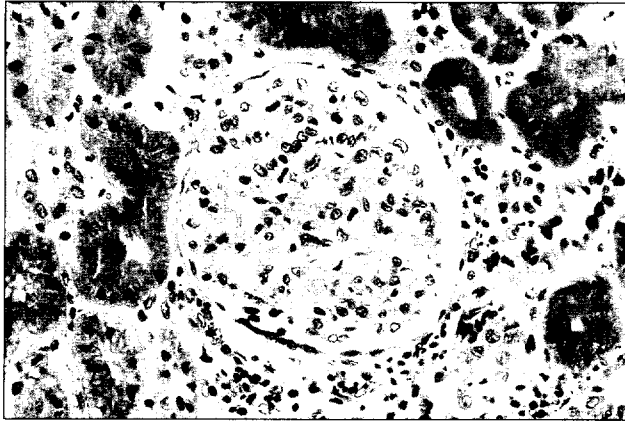


Fig 1a. A representative glomerulus from the renal biopsy of the patient. This shows a slight increase in mesangial matrix substance and cellularity (H&E, x 250)

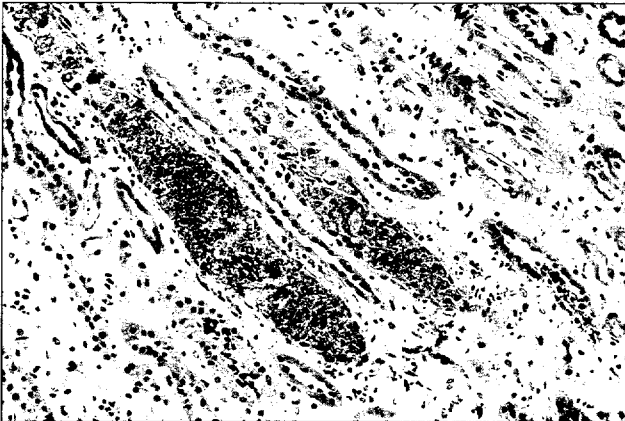


Fig 1b. Prominent granular red cell casts in the medullary tubules. Note the loss of normal tubular epithelium associated with the casts (H&E, x 250)

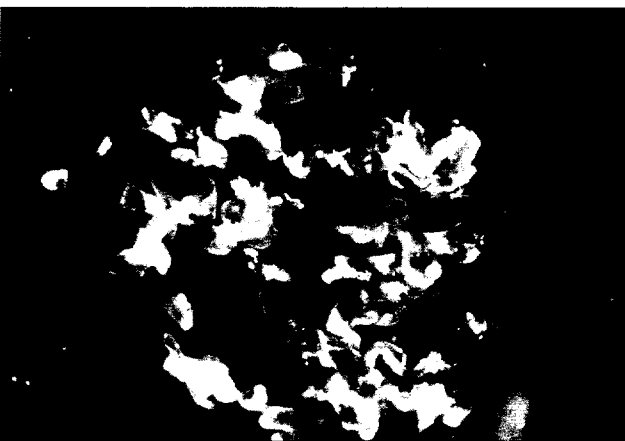

Fig 1c. Immunofluorescence staining showing IgA deposits in the mesangium of the glomerulus (x 250)

Discussion

Reversible ARF associated with gross haematuria in patients with IgA nephropathy is rare. Renal biopsy in these patients usually reveals extensive acute tubular necrosis and RBC casts.²⁻⁸ Our patient also showed similar findings of acute tubular injury and RBC casts. The glomerular lesions could not account for the ARF. These observations suggest that the ARF in this patient was probably due to the acute tubular damage, as evidenced by the loss of normal tubular epithelial cells.

The exact mechanisms of the acute tubular injury remain obscure. It has been suggested that obstruction of the renal tubules by RBC casts as a result of the profuse glomerular bleeding could lead to tubular damage.³ In addition, the haemoglobin and haemosiderin released from these RBC casts could exert a direct nephrotoxic effect on the renal tubules.⁵ The development of proteinuria during the ARF and its disappearance with the recovery of renal function imply that a disorder in glomerular haemodynamics and microcirculation may also play a role in the pathogenesis of ARF.⁶

As patients with IgA nephropathy can develop ARF due to crescentic IgA nephropathy or superimposed acute glomerulonephritis or tubulointerstitial nephritis, renal biopsy is mandatory for accurate diagnosis and optimal treatment. Most of these patients were non-oliguric and approximately 30% of them required temporary dialysis.⁸

Treatment of this complication of IgA nephropathy is mainly supportive as a majority of patients recover completely from their renal failure.²⁻⁸ No treatment is of proven value in hastening the recovery of the renal function.

Whereas the short term prognosis of this condition is good, the long term prognosis is less certain, particularly in those patients with recurrent attacks.⁵ Whether these repeated episodes of ARF will lead to progressive deterioration in renal function remains unknown.

This case highlights the fact that reversible ARF can occur in IgA nephropathy following an episode of macro-haematuria. It is important to perform renal biopsy in these patients to define the underlying renal pathology. The renal biopsy findings will have important implications in terms of prognosis and treatment. Patients with evidence of acute tubular injury and RBC

casts in their renal biopsies have a good prognosis. Their renal function can usually be recovered with supportive treatment.

References

1. D'Amico G. The commonest glomerulonephritis in the world: IgA nephropathy. *Q J Med* 1987;64:709-27.
2. Talwalker YB, Price WH, Musgrave JE. Recurrent resolving renal failure in IgA nephropathy. *J Pediatr* 1978;92:596-7.
3. Kincaid-Smith P, Bennett WM, Dowling JP, Ryan GB. Acute renal failure and tubular necrosis associated with haematuria due to glomerulonephritis. *Clin Nephrol* 1983;40:206-10.
4. Kincaid-Smith P, Ryan GB, Dowling JP, Nicholls K. Acute renal failure in mesangial IgA nephropathy. *Contrib Nephrol* 1984;40:182-6.
5. Praga M, Gutierrez-Millet V, Navas JJ, et al. Acute worsening of renal function during episodes of macroscopic haematuria in IgA nephropathy. *Kidney Int* 1985;28:69-74.
6. Lupo A, Rugiu C, Cagnoli L, Zucchelli P, Maschio G. Acute changes in renal function in IgA nephropathy. *Semin Nephrol* 1987;7:356-62.
7. Lee HS, Pyo HJ, Koh HI. Acute renal failure associated with haematuria in IgA nephropathy. *Am J Kidney Dis* 1988;3:236-9.
8. Delclaux C, Jacquot C, Callard P, Kleinknecht D. Acute reversible renal failure with macroscopic haematuria in IgA nephropathy. *Nephrol Dial Transplant* 1993;8:195-9.

America's #1

USMLE Course:

- * Prepares you for USMLE exam.
- * Helps you to up-grade your qualification.
- * Guides you to a position in a U.S. hospital.
- Computer diagnostic exams
- Home study books
- Practice exercises & tests
- Audio / Video tapes

Free Seminar

Last Wed. **6:30-8pm**
of every month

Call for Reservations

KAPLAN

World Leader in Test Preparation

2359-9033