

Update On Management Of Rhinitis

W K Ho,* FRCSEd, DLO, FHKAM(ORL)

W I Wei, MS, FRCSEd, DLO, FHKAM(ORL)

P K Y Lam, MBBS

Division of Otorhinolaryngology

Department of Surgery

The University of Hong Kong

Summary

Rhinitis is common in Hong Kong. The aim of treatment is to control the symptoms and to allow an undisturbed lifestyle without the side-effects of therapy. A secondary goal is to prevent the complication of sinusitis and its sequelae. Most of these goals can be achieved by the combination of anti-allergy management, oral or topical medication and the occasional surgical intervention. (HK Pract 1998;20:319-326)

摘要

鼻炎是本港常見之病症。治療目標首先是在無藥物副作用及不影響生活方式的情況下，有效地控制症狀；其次是預防鼻竇炎併發症和其後遺症。現在通過口服、局部預防藥物及對敏感原的控制以及偶然施行的外科手術，上述目標絕大多數都能成功達到。

Introduction

Rhinitis is a common problem in Hong Kong. The local prevalence of hay fever, the classical allergic rhinitis, is reported to be 15.7% in a study of 1062 secondary school students.¹ In the United States, it is estimated that one in five persons suffers from allergic rhinitis^{2,3} and 3 percent of all medical consultations are for management of patients with nasal symptoms. Currently 30 to 40 million Americans suffer from nasal congestion, sneezing and runny nose and this prevalence is escalating

both in the USA⁴ and European countries.^{5,6}

Rhinitis, rhinosinusitis and classification

The mucosa of the nose is in continuity with that of the paranasal sinuses. In all forms of rhinitis, some degree of inflammation is also present in the paranasal sinuses. It is often difficult to differentiate rhinitis from sinusitis clinically. As a result, some physicians prefer to use the term rhinosinusitis instead of rhinitis

or sinusitis.⁷ However, isolated rhinitis and sinusitis, for example sinusitis due to odontogenic infection, do exist.

Simple rhinitis may be acute or chronic. Chronic disease is arbitrarily defined as a persistence of symptoms for more than 12 weeks.⁷ By aetiology, rhinitis can be of infective or non-infective in origin. The commonest acute infective rhinitis is common cold virus infection. Patients with non-infective rhinitis belong to one of the two groups. Those related to atopy may

* Address for correspondence: Dr Ho Wai-kuen, Department of Surgery, the University of Hong Kong Medical Centre, Queen Mary Hospital, Hong Kong.

UPDATE ARTICLE

be sensitive to allergens such as pollens, house dust mite (*Dermatophagoides species*) (Figure 1), animal dander, or food. The second group includes the non-allergic related disease entities such as vasomotor rhinitis.

Clinical features and differential diagnosis

Rhinorrhoea, nasal blockage, itchiness and sneezing are cardinal symptoms of rhinitis. Other common complaints include hyposmia, post-nasal dripping, headache and facial pain. Frequently patients have ophthalmic symptoms such as eye itchiness and epiphora as well.

The clue to the diagnosis of allergic rhinitis includes the identification of a specific trigger such as a contact with cats, or onset of symptoms after a trip to the countryside. A consistent pattern of seasonal attack of symptoms is suggestive of hay fever, while a strong personal or family history of asthma or eczema contributes to the diagnosis. With the warm and humid climate in Hong Kong, house dust mites, mould and air pollutants are the likely causes of nasal allergy. Patients with definite disease entities such as the aspirin hypersensitivity-asthma-nasal polyposis (ASA) triad; primary ciliary dyskinesia and Kartagener syndrome, two diseases due to congenital nasal ciliary abnormality, also present initially as persistent rhinitis. The ASA triad can be diagnosed from the history and physical examination but nasal mucosa ciliary problems have to be diagnosed by electron microscopy.

In patients with non-allergic rhinitis, non-specific stimuli such as inhalation of cold, dry air or ingestion of spicy food will trigger an attack. Female patients often experience an increase in severity of symptoms during pregnancy as a result of hormonal changes.

Clinical assessment starts with anterior and posterior rhinoscopy,

otological evaluation and a complete head and neck examination. The presence of anatomical abnormalities such as enlarged turbinates, septal deformities and nasal polyps (Figure 2) should be recorded. The presence of thick mucus or frank pus signifies sinusitis.

Many diseases have symptoms and signs similar to rhinosinusitis

Figure 1: House dust mite

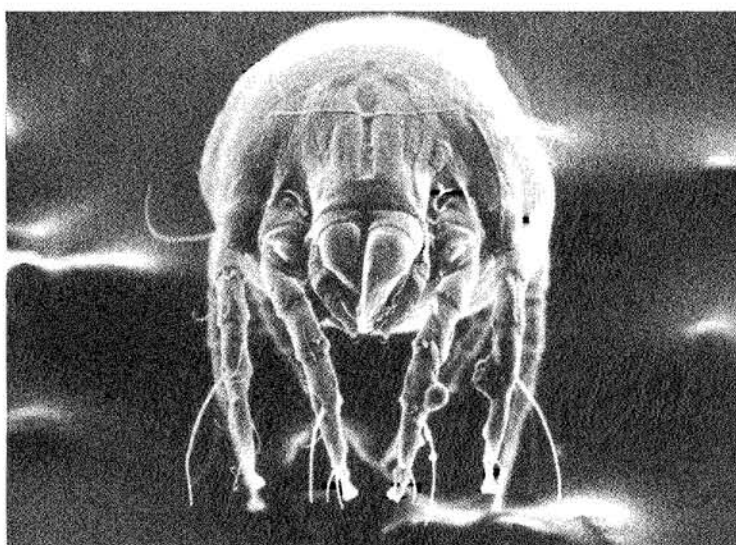
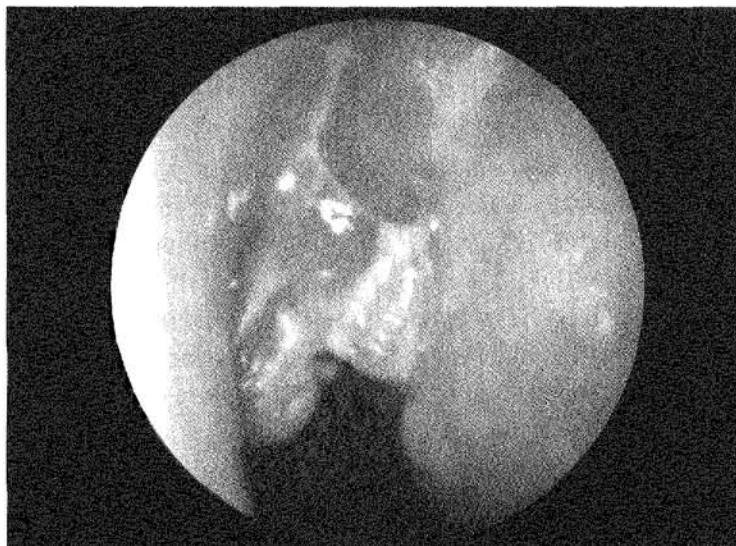

Figure 2: Endoscopic view of right nasal polyp



(Continued on page 322)

UPDATE ARTICLE

(Table 1). These include Wegener's granulomatosis, fungal infection (Figure 3), inverted papilloma of the nose (Figure 4) and notably nasopharyngeal carcinoma (Figure

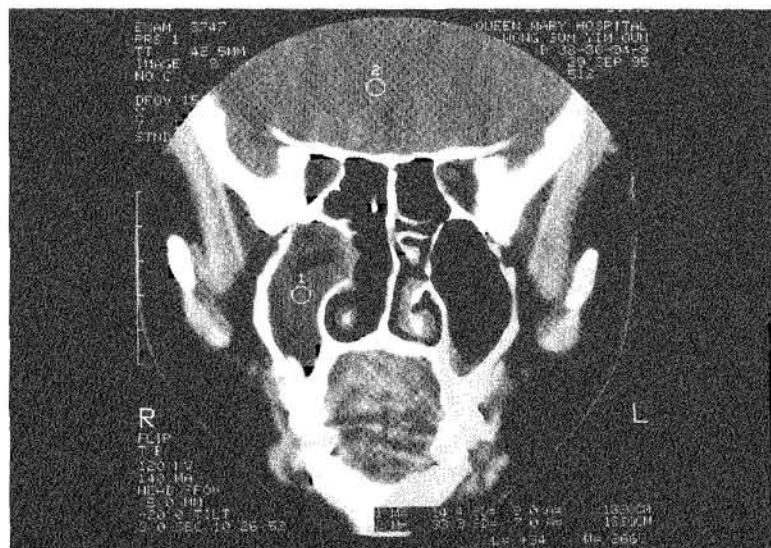
5) in southern Chinese. Most nasal diseases can now be diagnosed with rigid (Figure 6) or flexible nasoendoscopy. X-ray of the paranasal sinus is used for screening,

but a detailed examination of the nose and sinuses would need a computerised tomography (CT) scanning. An abnormal renal function test with shadows of granuloma on chest x-ray may suggest the possibility of Wegener's granulomatosis in a patient with chronic rhinosinusitis. Special request for culture of nasal discharge for mycobacterium and fungi, e.g. aspergillus, is required for immunocompromised patients who have atypical nasal symptoms. Serological test for antibody against Epstein-Barr virus is widely used for the screening of nasopharyngeal cancer. However, a nasal biopsy is required for the definitive diagnosis of neoplastic diseases.

Table 1: Differential diagnosis of rhinitis

Mechanical factors	Hypertrophic turbinates Deviated nasal septum Adenoid hypertrophy, choanal atresia Foreign bodies, rhinoliths
Nasal polyps	
Neoplasms	Benign - inverted papilloma Malignant - sinus cancer - lymphoma - ectopic salivary gland tumour - nasopharyngeal carcinoma
Granuloma	Wegener's granulomatosis Tuberculosis Fungal infection Sarcoidosis
Cerebrospinal fluid rhinorrhoea	Primary Secondary to intracranial lesion, trauma

Figure 3: Coronal CT scan of a patient with leukaemia and fungal sinusitis. (Note the loss of the right inferior turbinate bone as a result of necrosis)



Complications

In children, uncontrolled rhinitis is associated with snoring and sleep disturbances which may lead to deterioration of school performance and impairment of learning ability.⁸

The medical complications of rhinitis are acute and chronic sinusitis. Acute sinusitis typically occurs after a severe upper respiratory tract infection which leaves the patient with a persistent yellowish nasal discharge. There may be pain in the nose, tenderness over sinus area and persistent systemic symptoms such as fever and malaise. Examination of the nose may reveal inflamed nasal mucosa with yellowish purulent discharge. Acute maxillary sinusitis is relatively common in young adults, whereas acute frontal sinusitis occurs more frequently in older children and

UPDATE ARTICLE

Figure 4: Inverted papilloma of the nose

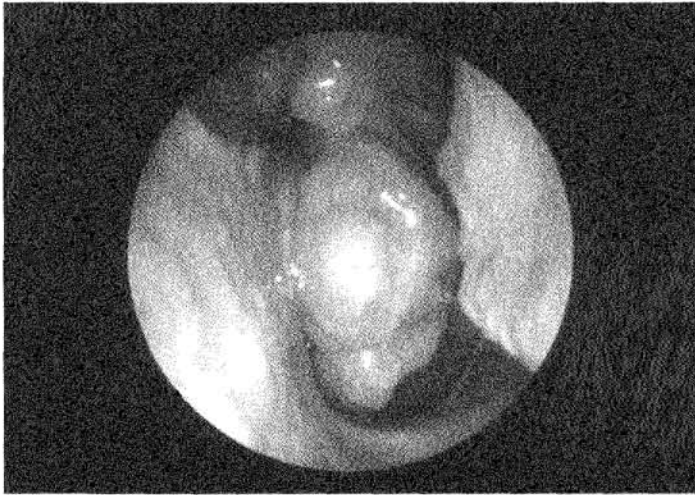

Figure 5: Nasopharyngeal carcinoma in the right fossa of Rosenmuller

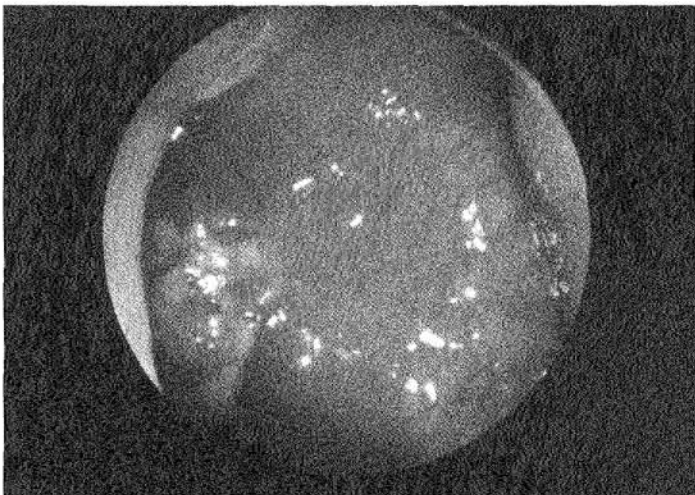



Figure 6: Rigid nasoendoscopes with light cable



teenagers. Acute ethmoidal sinusitis remains the commonest sinusitis associated with orbital complications in children. Early diagnosis and treatment of acute sinusitis is essential to prevent further complications of orbital cellulitis or subperiosteal abscess (**Figure 7**).

The symptoms and signs of chronic sinusitis are less dramatic. There is usually a history of chronic rhinitis with or without allergy. There may be long-standing purulent nasal discharge, nasal obstruction, hyposmia, recurrent facial pain and headache. The patient often has had repeated episodes of increasing nasal discharge which only respond partially to antibiotics, and he is not completely well in between attacks. Examination of the nose shows congested mucosa with thick nasal discharge. Particular attention should be paid to the middle meatus where changes may indicate diseases in the sinuses. Pus may be found flowing into the nasopharynx. In children, the presence of chronic infection in the tonsils and adenoids should be noted. Unilateral maxillary sinusitis (**Figure 8**) occurring for the first time in adult life may suggest that the infection is of dental origin. Besides causing chronic ill-health and persistent discomfort, chronic sinusitis carries definite risks of orbital and intracranial complications.

Plain paranasal sinus x-rays help to confirm the clinical suspicion of acute or chronic maxillary or frontal sinusitis (**Figures 8 and 9**). However, to define the extent of involvement, CT of the sinuses in the coronal plane is necessary. It can also identify the presence of any

anatomical abnormalities which may affect the plan of surgical intervention. A simple nasal swab for culture may reveal the causative organism and guide the choice of antibiotics, but a more definitive identification may need a swab taken from the middle meatus or through a maxillary antral puncture.

Management of rhinitis

In patients with symptoms and signs of hypersensitivity, an allergic work-up should be performed. This includes blood eosinophil count, total serum IgE, skin prick test (Figure 10) or specific serum IgE assay. Nasal provocation test can be performed in a specialist's clinic when a definitive diagnosis is required before immunotherapy. In the simplest form of investigation, avoidance of a specific food for a period of time may give a clue to food allergy.

Figure 7: Patient with left orbital cellulitis

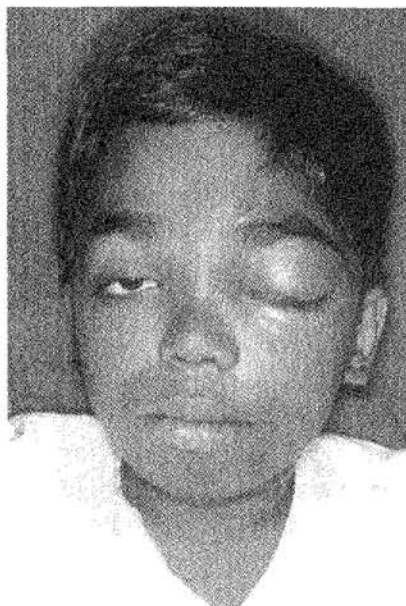

Figure 8: X-ray occipito-mental view: right maxillary sinusitis with opaque right maxillary antrum

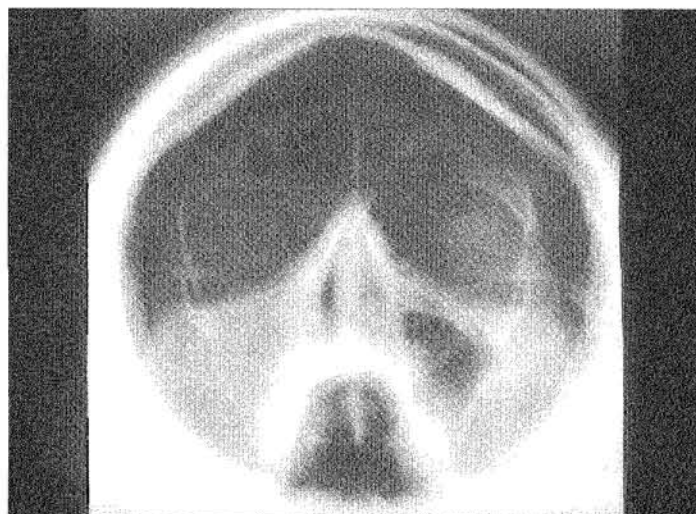

Figure 9: X-ray showing air-fluid level in the right frontal sinus

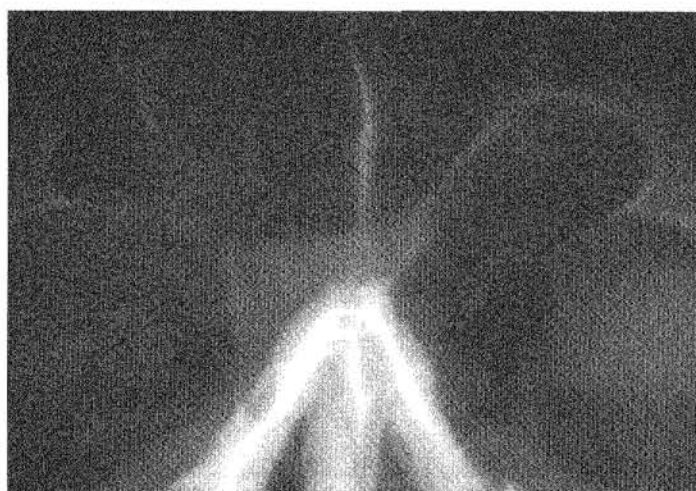
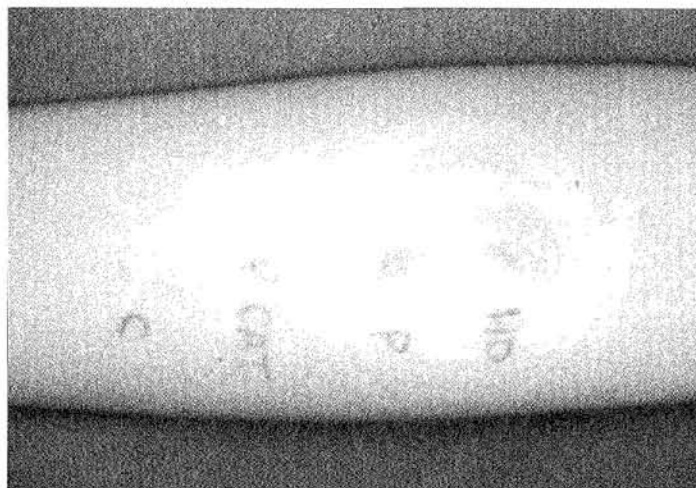


Figure 10: Skin prick test



UPDATE ARTICLE

For patients with confirmed allergy, it is logical and important to avoid the allergen. Pillows and beds should be covered by plastic bags and changed at least weekly. Hot water should be used for washing. Stuffed toys should be removed or machine-washed frequently. Indoor carpeting is not advisable and pets should not be kept. Indoor humidity should be kept below 40%. Cigarette fumes should be avoided.

In general, oral antihistamine is effective for the symptoms of sneezing and itchiness in allergic rhinitis. Unfortunately the classical antihistamines, such as chlorpheniramine, triprolidine, carry the side-effects of drowsiness and dry mouth. The newer antihistamines, loratadine, astemizole, cetirizine, fexofenadine, do not cross the blood-brain barrier and have much lower incidence of central nervous system side-effects and their therapeutic actions last longer. In general, they can be taken regularly during seasons of attack or on demand basis in patients with infrequent symptoms. The experience with the new topical nasal antihistamines is limited. Theoretically, these topical agents should have minimal systemic absorption and infrequent side-effects. The effect of their long-term use, however, needs further evaluation.

For patients with non-allergic vasomotor rhinitis, the rhinorrhoea may only respond to antihistamines with prominent anti-cholinergic action. Patients with significant nasal blockage usually do not have a good response to antihistamines. Systemic decongestant may be

added. Local decongestant nose drops should not be used for patients with chronic nasal disease to avoid the risk of developing rhinitis medicamentosa (rebound congestion). For systemic decongestants, precaution must be taken in paediatric patients and in those with heart diseases and hypertension.

For patients with frequent attacks, topical nasal steroids are very effective in controlling symptoms.⁹ Local steroids have minimal systemic absorption and no effect of adrenal suppression or growth retardation when used in recommended dosages.^{10,11} In a recent Canadian study of elderly patients, there is an increased risk of ocular hypertension in those taking high dose inhaled steroids for asthma.¹² Although this risk is not associated with nasal steroid spray, the dosage should be kept at the recommended level to avoid possible complication.

Topical disodium cromoglycate acts by inhibition of mast cell histamine release. However, its administration has to precede the allergen challenge, and a 4 or 6 times daily administration is required. It is also not very effective in alleviating nasal blockage. All these factors limit its use in patients with allergic rhinitis.

Nasal discharge is the result of stimulation by acetylcholine released by the parasympathetic nervous system. Antihistamines with anti-cholinergic action, however, have side-effects such as dry mouth, constipation and difficulty in urination, especially in elderly male

patients. They may be used only in selected individuals. Topical anticholinergic drug such as ipratropium bromide can reduce the secretion from nasal mucosal glands and would benefit patients with significant rhinorrhoea.

With the finding of inflammation being important in the pathogenesis of rhinosinusitis, recent research has been directed towards the modification of cytokine activities in the inflammatory pathway. The use of leukotriene modifying agents is now under clinical trial.

In patients with severe symptoms, desensitisation programme or immunotherapy can be offered for those with a specific allergen. This involves weekly injections of the allergen to the patient for a long period which may last for years. Good result has been reported particularly in patients with hay fever. This is popular in the United States while most patients in Hong Kong prefer oral or topical medications.

For most patients, symptoms related to rhinitis can be controlled with medical therapy alone. When the symptoms are contributed by structural abnormalities, e.g. hypertrophic turbinates and deviated nasal septum, surgical operations such as turbinectomies and septoplasty may relieve the problem of nasal blockage. For patients complicated with chronic sinusitis, a combination of drug treatment and minimally invasive functional endoscopic sinus surgery is required.¹³ ■

UPDATE ARTICLE

Key messages

Rhinitis is becoming more common in Hong Kong. Proper management requires:

1. accurate diagnosis of different types of rhinitis, and differentiation it from other diseases of the nose;
2. alert on the possible complications of sinusitis and orbital or intracranial infections;
3. appropriate drug treatment;
4. environmental control; and
5. occasional surgical intervention.

References

1. Leung R, Ho P. Asthma, allergy and atopy in three South-east Asian populations. *Thorax*. 1994;49(12):1205-1210.
2. Smith HM. Epidemiology and natural history of asthma, allergic rhinitis, and atopic dermatitis (eczema). *Allergy: Principles and Practice*. 3rd ed. St Louis, Mo: CV Mosby Co; 1988:891-929.
3. Naclerio RM. Allergic rhinitis. *N Engl J H Med*. 1991;325:860-869.
4. Hagy GW, Settiple GA. Risk factors for the development of asthma and allergies rhinitis: a 7-year follow-up of college students. *J Allergy Clin Immunol* 1976;58:330.
5. Aberg N. Asthma and allergic rhinitis in Swedish conscripts. *Clin Exp Allergy* 1989;19: 59-63.
6. Ninan TK, Russell G. Respiratory symptoms and atopy in Aberdeen schoolchildren: evidence from two surveys 25 years apart. *BMJ* 1992; 304:873-875.
7. Clement PAR, Bluestone CD, F Gordts. Management of rhinosinusitis in children. *Arch Otolaryngol Head Neck Surg*, 1998;124:31-34.
8. Simons FER. Learning impairment and allergic rhinitis. *Allergy and Asthma Proc*, 1996;17: 185-189.
9. Svensson C, Klementsson H, Andersson M, *et al*. Glucocorticoid-induced attenuation of mucosal exudation of fibrinogen and bradykinins in seasonal allergic rhinitis. *Allergy* 1994;49:177-183.
10. Pipkorn U, Pukander J, Suonpaa J, *et al*. Long-term safety of budesonide nasal aerosol: a 5.5 year follow-up study. *Clin Allergy* 1988; 18:253-259.
11. Moller C, Ek L, Svensson IL. Nasal budesonide to children for 5 years. *Allergy Clin Immunol News* 1994;6(Suppl 2): 427.
12. Garbe E, LeLorier J, Boivin JF, *et al*. Inhaled and nasal glucocorticoids and the risks of ocular hypertension or open-angle glaucoma. *JAMA* 1997;277:722-727.
13. Kennedy DW. Prognostic factors, outcomes and staging in ethmoid sinus surgery. *Laryngoscope* 1992;102(12 Pt 2 Suppl 57):1-18.