

Recent Advances In The Management Of Nasopharyngeal Carcinoma

W I Wei,* MS, FRCSE, DLO, FACS
Department of Surgery
The University of Hong Kong

Summary

Developments in serology tests, imaging studies and endoscopic examinations contribute to early diagnosis of nasopharyngeal carcinoma. The primary treatment modality is radiotherapy. When tumour recurs after radiation, then surgical salvage contributes to a better prognosis. (HK Pract 1998;20:270-281)

摘要

由於血清學檢查，影像及內窺鏡檢查的發展，對鼻咽癌可以做早期診斷。放射治療是主要的治療方法。當癌症復發時，手術治療預後相對較好。

Introduction

Nasopharyngeal carcinoma (NPC), the most frequent neoplasm in the nasopharynx, is common among the Chinese in Southeast Asia and Hong Kong. The incidence ranges from 18 to 30 per 100,000 population and this has remained static in recent decades.¹ NPC affects all age groups with a peak incidence in the fifth decade of life. When a patient presents with early stage disease then outcome is more favourable. Over the years, advances have been achieved in early diagnosis and in the accurate evaluation of the extent of the tumour

enabling the administration of effective treatment with fewer complications. Significant progress has also been made in therapy, particularly in the treatment of recurrent disease in the nasopharynx, and in the neck after external radiotherapy.

Diagnosis

The early warning signs of NPC are notoriously scanty. Patients may have a "stuffy nose" with occasional epistaxis. Or they may present with serous otitis media as the tumour in the nasopharynx affects Eustachian tube

function. A painless enlarged upper cervical lymph node remains the commonest presenting symptom. In an endemic area, a high index of awareness of the disease is important to make the diagnosis at an early stage.

Serology

Epstein Barr virus (EBV) belongs to the herpes virus family and in different individuals it brings about different pathology. It has been found to be associated with infectious mononucleosis, Burkitt's lymphoma and nasopharyngeal carcinoma. The EBV

* Address for correspondence: Professor William I Wei, W Mong Professor in Otorhinolaryngology, Department of Surgery, The University of Hong Kong Medical Centre, Queen Mary Hospital, Pokfulam, Hong Kong.

UPDATE ARTICLE

specific antigens can be grouped as late antigens, early replicative antigens and latent phase antigens. The antigens associated with NPC are viral capsid antigen (VCA) which belongs to the late antigen group and early intracellular antigen (EA) of the early replicative antigen group. In patients suffering from NPC, high levels of IgA against EA and VCA have been detected² and these can be used as indicators for diagnosis.³ IgA anti EA is a more specific test for NPC than IgA anti VCA which is however, more sensitive and these serological tests have been used to screen high risk groups to obtain an early diagnosis.

In a prospective study carried out in a high risk region attempting to diagnose subclinical NPC, both IgA anti VCA and IgA anti EA were employed as initial screening tests. For patients with elevated levels of both IgAs, flexible endoscopic examination of the nasopharynx and biopsy was performed. Among the 130 seropositive but asymptomatic patients, seven were diagnosed to be suffering from NPC.⁴ The level of the antibodies to IgA anti EBV has also been shown to be related to the stage of disease which indirectly reflects tumour burden.⁵ The level of IgA anti VCA has been reported to decrease after tumour eradication following radiotherapy, its value in monitoring for recurrent disease has not yet been established.⁶

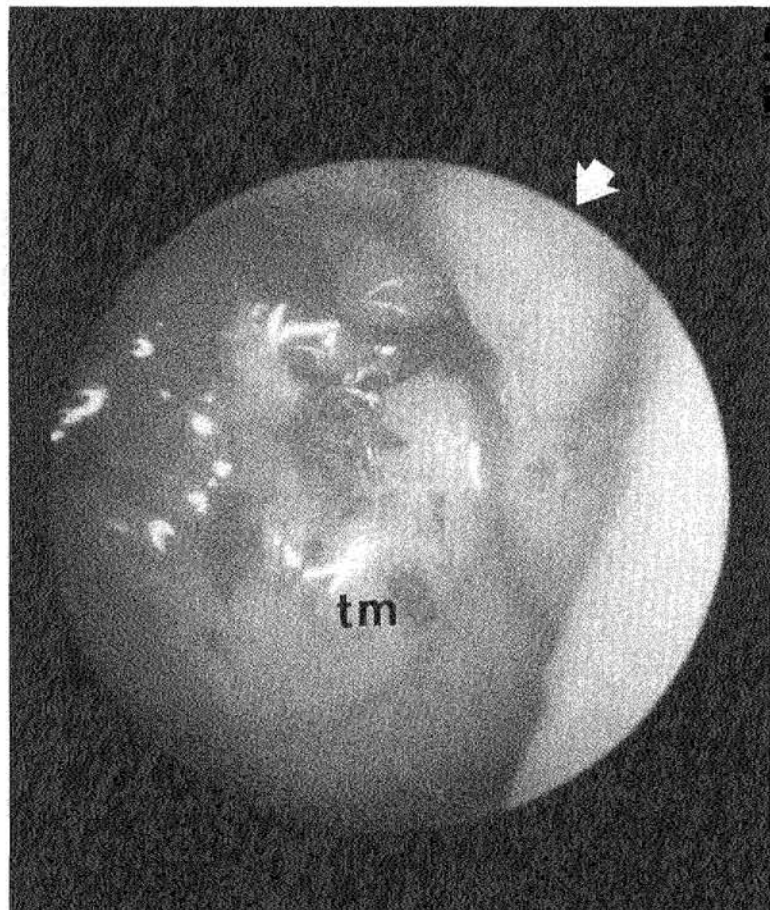
Endoscopic examination

Early NPC is usually located in the fossa of Rosenmuller which is medial to the medial crura of the Eustachian tube. These early lesions

can only be detected with a thorough examination of the nasopharynx and this is difficult with a conventional posterior rhinological mirror. The nasopharynx may now be adequately examined under anaesthesia with either a rigid or flexible endoscope and when a suspicious lesion is seen, biopsy under direct vision is possible. The rigid Hopkin rod endoscope gives an excellent view of the nasopharynx on the side of insertion. (Figure 1) It does not have a suction channel and biopsy forceps can only be inserted alongside the endoscope.

The flexible endoscope with suction and biopsy channels is useful for a detailed examination of the nasopharynx. The scope may be inserted through one nasal cavity and turned to examine the opposite nasopharynx behind the nasal septum. (Figure 2) When a large tumour blocks both nasal cavities or when there are anatomical variations such as a grossly deviated nasal septum, then the flexible endoscope may be inserted transorally and manipulated upwards behind the soft palate to reach the tumour in the nasopharynx (Figure 3).

Figure 1: Rigid endoscopic view of the nasopharynx, showing a tumour (tm) and medial crura of Eustachian tube (arrow)



(Continued on page 274)

UPDATE ARTICLE

Figure 2: Right : The mobile tip of the flexible endoscope
 Left : Flexible endoscope inserted through the right nostril showing the right Eustachian tube opening (arrow) and tumour (tm) of the contralateral nasopharynx behind the posterior edge of the nasal septum. (arrow heads)

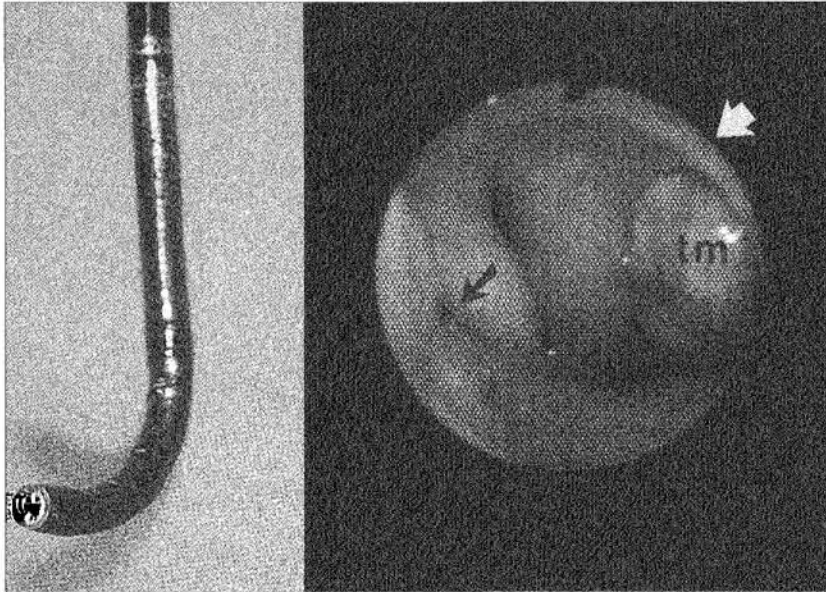
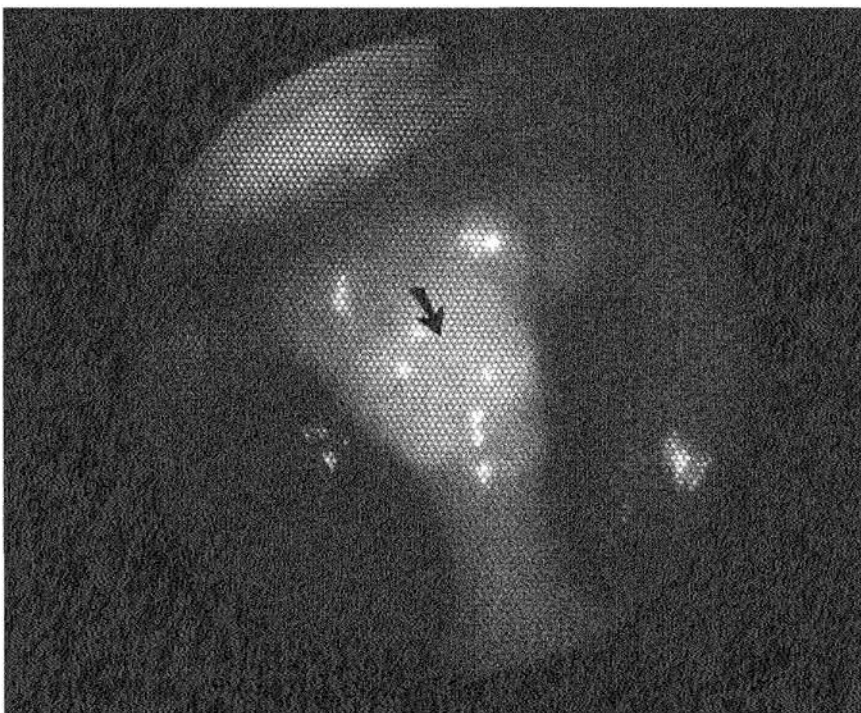


Figure 3: Flexible endoscope inserted transorally and manipulated behind the soft palate to see the tumour (arrow) at the roof of the nasopharynx



As the size of the biopsy forceps is limited by the diameter of the biopsy channel of the scope, it is not easy to obtain large tissue biopsies for histological examination. When taking a biopsy through the flexible endoscope, the mucosa should first be broken with the forceps and then one jaw of the forceps may be inserted into the submucosa to obtain more tissue.⁷

Imaging techniques

Computed tomography (CT) is now routinely employed for the imaging of lesions in the nasopharynx. It is useful to delineate soft tissue swelling in the nasopharynx and thus the extent of tumour. (Figure 4) CT is also superior to conventional radiography in the detection of bony erosion around the tumour, especially of the skull base. CT of the neck performed at the same time helps document involvement of cervical lymph nodes.⁸ It also provides information as to whether retropharyngeal lymph nodes are affected,⁹ this has been shown to be of prognostic value in determining local tumour control and distant metastasis.¹⁰ Magnetic resonance imaging (MRI) besides defining the extent of tumour involvement, has superior multiplanar capability and better delineation of tissue plane. (Figure 5) It can differentiate tumour from inflammation and provides better recognition of the exact extent of the disease but is limited by its ability to provide information on bone erosion. Both CT and MRI can each give precise information on the extent of tumour and are now both routinely used in the planning of radiotherapy.

(Continued on page 276)

UPDATE ARTICLE

Figure 4: Computed tomography showing the tumour in the nasopharynx (T)

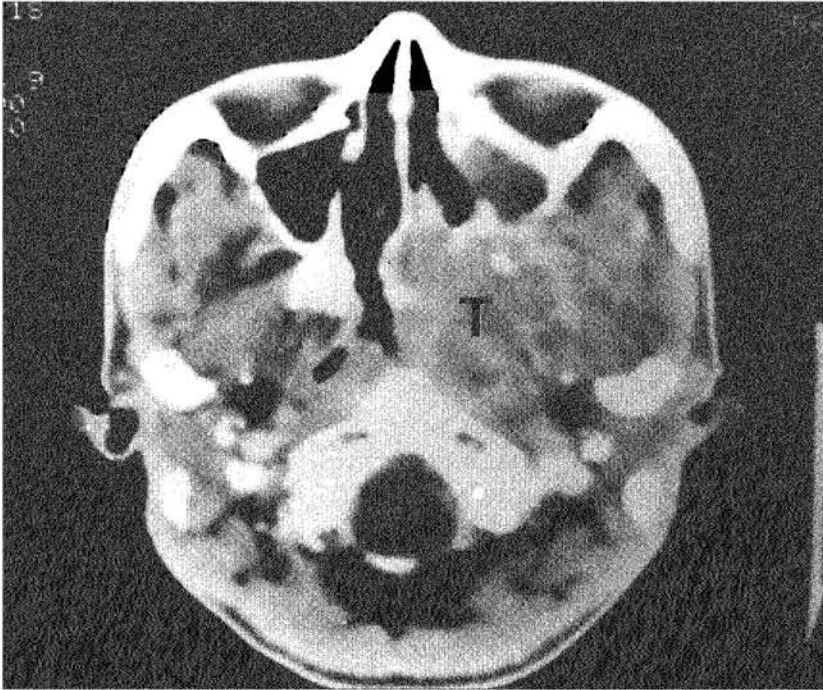
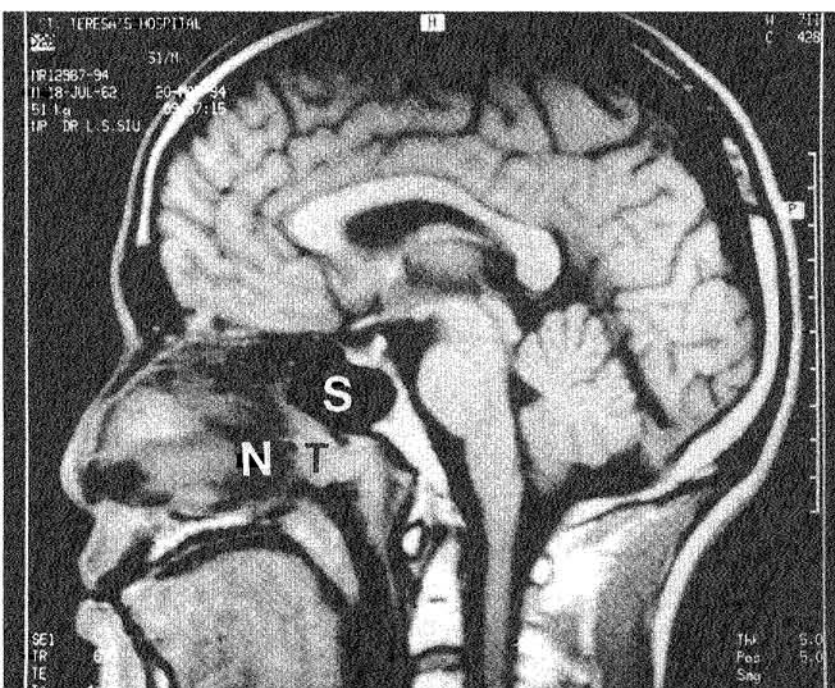


Figure 5: Magnetic resonance image in sagittal plane showing the tumour in the nasopharynx (T) below the sphenoid sinus (S) and involves upper part of nasal septum (N)



Treatment

Radiotherapy

As NPC is a radiosensitive tumour, external radiotherapy is the primary modality of treatment. The results of therapy with radiation have improved over the years because of more precise staging of disease and more refined techniques of delivering the radiation. Overall 5 year survival rates ranged from 70 to 85% for stage I and 20 to 40% for stage IV.¹¹⁻¹³

In view of the location of the nasopharynx, the radiation beam employed for the treatment of the nasopharyngeal carcinoma has to pass through nearby structures and this contributes to the side effects of radiotherapy. A frequent complaint is dryness of mouth, which in its severe form may affect the taste of food and lead to dental caries. As the salivary glands are also in the field of radiation, xerostomia once developed will progress and remain permanent. Frequent fluid ingestion and the use of artificial saliva may help to alleviate symptoms.

With modification of techniques of delivery of radiation energy some complications may be avoided without jeopardizing the efficacy of the radiation. The pituitary gland and the skull base can be shielded and the devastating complication of temporal lobe necrosis avoided. With this modification, frequently quoted neuroendocrine complications following radiotherapy may also be reduced.¹⁴

Patients suffering from NPC are particularly prone to develop serous

(Continued on page 278)

UPDATE ARTICLE

otitis media, as the primary tumour in the nasopharynx may have a mechanical effect on the function of the Eustachian tube. Serous otitis media may also develop after radiotherapy and the radiation energy may cause further Eustachian tube dysfunction.¹⁵⁻¹⁶ Myringotomy and insertion of a ventilation tube is effective in releasing the collection of fluid in the middle ear when serous otitis media is detected prior to radiotherapy. When the ventilation tubes are inserted only after completion of radiotherapy then the incidence of complications such as otorrhoea and gradual decrease in hearing are higher.¹⁷ As the inner ear with the auditory cranial nerve are within the irradiation field for treatment of primary NPC, changes in the nerve and the nearby brainstem have been reported.¹⁸ A prospective study of the effect of radiation on the inner ear has also shown that 24% of individuals developed sensorineural hearing loss when examined at 30 months following radiotherapy. High frequencies are affected more often than the low frequency range and the addition of chemotherapy does not seem to affect the aural function.¹⁹

When the extent of tumour is defined more precisely with better imaging techniques and when more efficient delivery of radiation energy such as hyperfractionation is available, then the results of radiotherapy for NPC will improve further with fewer undesired side effects.

Chemotherapy

Traditionally, patients with advanced locoregional diseases are also treated with radiotherapy. Outcome in these patients both for control of disease locoregionally and systemically are not satisfactory. Chemotherapy has been introduced in an attempt to control distant metastasis and to reduce tumour burden in the nasopharynx before radiotherapy. Prospective randomized trials employing induction chemotherapy showed no overall survival benefit²⁰ but better disease free survival.²¹ Concomitant chemotherapy to eradicate distant metastasis also tends to increase the cytotoxicity of radiation towards the primary tumour. One prospective study comparing radiotherapy alone versus radiotherapy with

concomitant cisplatin followed by three cycles of adjuvant cisplatin and flurouracil showed a survival benefit in favour of the chemotherapy group.²² More prospective studies are necessary to establish the role of chemotherapy in the management of NPC.

Surgery

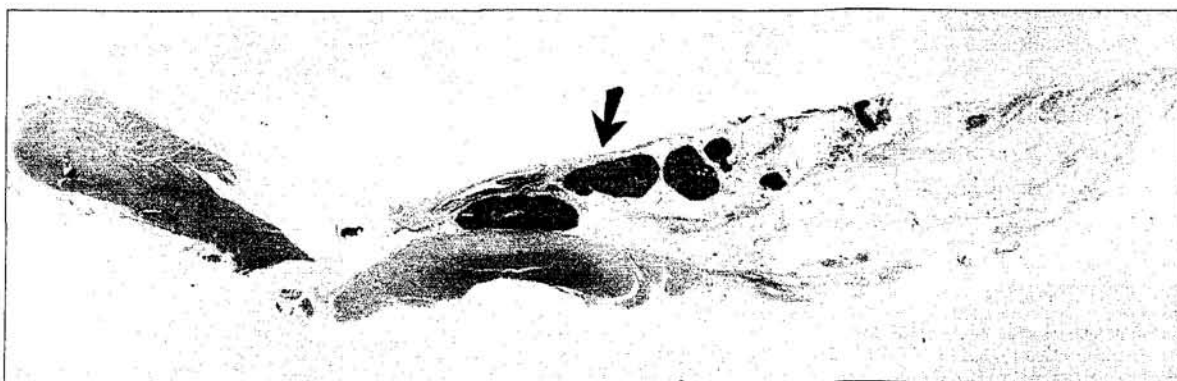
Despite improvements in the treatment results of NPC with radiotherapy in recent years, some patients will develop local or regional recurrence after completion of radiotherapy. Additional courses of external radiotherapy may be useful but a limiting factor is tolerance of surrounding tissues to further doses of radiation.

Surgical resection of either local or regional recurrence has been shown to yield satisfactory results.

Neck recurrence

Nasopharyngeal carcinoma has a high propensity for metastasis to cervical lymph nodes and thus the neck

Figure 6: Histological slide showing multiple tumour bearing lymph nodes (arrow) (haematoxylin and eosin X 40)



UPDATE ARTICLE

is routinely included in the irradiation field. Despite such elective radiotherapy, about 8% of patients suffer from recurrent disease in the cervical lymph nodes. Further irradiation of these nodes controlled tumour in the neck in 19% of patients²³ while surgery in the form of radical neck dissection could achieve local tumour control in 66% of patients.²⁴

Step serial whole organ sectioning of the radical neck dissection specimens showed that the tumour in the cervical lymph nodes showed extensive pathological features. There was a six fold increase in lymph node involvement in the specimens when compared to clinical examination. (Figure 6) Seventy per cent of tumour in the nodes exhibited extracapsular spread and in 30% of the specimens tumour was found to be lying close to the spinal accessory nerve or involving neck muscle. In view of the aggressive behaviour of tumour in the lymph nodes, optimal treatment of cervical nodal metastasis in NPC after radiotherapy involves radical neck dissection.²⁵

Recurrence at the primary site

1. Brachytherapy

Although NPC is radiosensitive, in some patients the primary tumour still persists or recurs after radical doses of external radiotherapy. For further radiotherapy to be effective, the dose has to be greater than 60 Gy. The resulting radiation effect on normal surrounding tissue may

produce serious long term sequelae such as neuro-endocrine disturbances, poor non-verbal memory recall and even the induction of sarcoma in the paranasal sinus.²⁶

Brachytherapy with radioactive gold grains has been employed. When recurrent or persistent tumour in the nasopharynx is 1 to 1.5 cm in diameter. The gold grains can be inserted into the tumour under direct vision via the split palate approach with a special applicator.²⁷ Morbidity associated with the operation is low and the probability of tumour control in the nasopharynx was 80% at 5 years.²⁸

2. Surgical resection

Between February 1989 and July 1997, in the Otorhinolaryngology Department, Head & Neck Division of the Department of Surgery, The University of Hong Kong Medical Centre, Queen Mary Hospital, we have employed an anterolateral (maxillary swing) approach for the resection of recurrent nasopharyngeal carcinoma in 48 patients. At operation, resection margins were subjected to frozen section examination. When all the margins were negative, the resection was considered to be curative. This was achieved in 45 patients and these form the basis of the present study.

All patients received radical external radiotherapy before operation, the dosage ranged from

59.9 to 120 Gy (median 63.5 Gy). The median disease-free interval between the radiation treatment and surgery group was 12 months.

All the 45 patients underwent nasopharyngectomy via the anterolateral (maxillary swing) approach. The maxilla was swung laterally but remained attached to the anterior cheek flap to gain access to the nasopharynx.²⁹ (Figure 7) Macroscopic tumour was removed with at least a 1 cm margin. The extent of resection thus comprised the roof, posterior and the lateral walls of the nasopharynx, including the Eustachian tube on the side of the tumour. After completion of the resection, the whole osteocutaneous complex was returned and fixed to the rest of the facial skeleton with miniplates and screws.³⁰

All 45 patients survived the operation and were discharged from hospital. The follow-up period of the group ranged from 6 to 76 months (median, 24 months). Facial wounds healed primarily and they were able to tolerate an oral diet on the third postoperative day. All developed some degree of trismus during the first few months after operation. Conservative treatment was employed and trismus usually improved with minimal functional disability. A palatal fistula was detected in ten patients (22%). In one patient, the fistula was closed surgically with a palatal flap while in the other patients, the fistulae were managed conservatively with dental plates.

UPDATE ARTICLE

Figure 7: Schematic computed tomography:
 Upper: Osteotomies over the maxilla is marked with dotted line
 Lower: The maxilla attached to the anterior cheek flap is swung laterally to expose tumour in the nasopharynx (arrow)

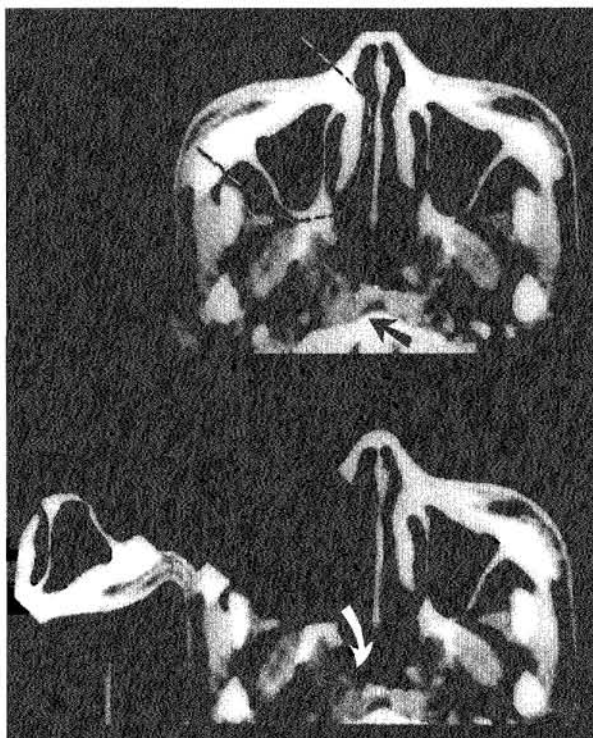
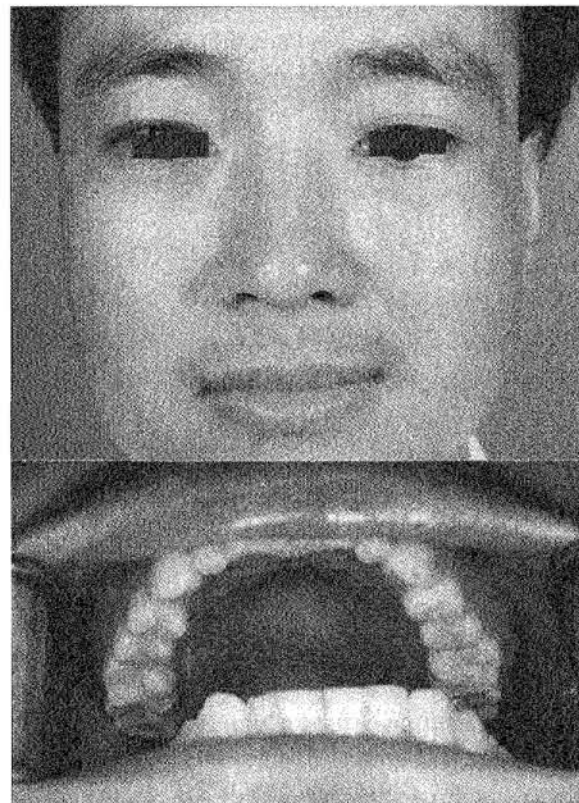


Figure 8: Post operative follow up pictures:
 Upper: Left Weber Ferguson facial scar is invisible at 18 months after operation
 Lower: Lip and palatal wound has healed completely



At the time of assessment, ten patients had developed local recurrent tumour, three patients died of regional disease and two from distant metastasis. Three patients died of causes unrelated to the tumour. The remaining 27 patients were alive and free of disease. The 5-year actuarial control of tumour in the nasopharynx was 52% and the 5-year actuarial survival of this group of patients was 43%, with a median survival of 53 months.

The anterolateral route to the nasopharynx with the maxillary swing approach provides wide exposure of

the whole nasopharynx and the paranasopharyngeal space. The operation is not difficult and associated morbidity is acceptable. (Figure 8) This approach for nasopharyngectomy should be employed whenever it is considered appropriate. ■

References

1. Muir C, Waterhouse J, Mack T, *et al.* Cancer incidence in five continents. *IARC and IACR.* 1987;5:840-841.
2. Henle G, Henle W. Epstein-Barr virus-specific IgA serum antibodies as an outstanding feature of nasopharyngeal carcinoma. *Int J Cancer* 1976;17:1-17.
3. Ho JHC, Ng MH, Kwan HC, *et al.* Epstein-Barr-virus-specific IgA and IgG serum antibodies in nasopharyngeal carcinoma. *Br J Cancer* 1976;34:655-660.
4. Sham JST, Wei WI, Zong YS, *et al.* Detection of subclinical nasopharyngeal carcinoma by fiberoptic endoscopy and multiple biopsy. *Lancet* 1990;335:371-374.
5. Henle W, Ho JHC, Henle G, *et al.* Antibodies to Epstein-Barr virus related antigens in nasopharyngeal carcinoma. Comparison of active cases and long-term survivors. *J Natl Cancer Inst* 1973;51:361-369.
6. Lynn TC, Tu SM, Kawamura A. Long-term follow-up of IgG and IgA antibodies against viral capsid antigens of Epstein-Barr virus in nasopharyngeal carcinoma. *J Laryngol Otol* 1985;99:567-572.
7. Wei WI, Sham JST, Zong YS, *et al.* The efficacy of fiberoptic endoscopic examination and biopsy in the detection of early nasopharyngeal carcinoma. *Cancer* 1991;67:3127-3130.

UPDATE ARTICLE

Key messages

1. Early nasopharyngeal carcinoma has few symptoms.
2. Serology test, computed tomography and magnetic resonance imaging together with endoscopic examination of the nasopharynx and biopsy contribute to early diagnosis.
3. Radiotherapy remains as the primary treatment modality for nasopharyngeal carcinoma and results have improved in recent years.
4. Neck recurrence should be managed with radical neck dissection.
5. Small recurrence at the primary site can be managed by gold grain implantation as brachytherapy while adequate surgical resection for large recurrence is now possible with the maxillary swing approach.

8. Sham JST, Cheung YK, Choy D, *et al.* Nasopharyngeal carcinoma: CT Evaluation of patterns of tumour spread. *AJNR* 1991;12:265-270.
9. Chua DTT, Sham JST, Kwong DLW, *et al.* Retropharyngeal lymphadenopathy in patients with nasopharyngeal carcinoma. *Cancer* 1997; 79:869-877.
10. Chua DTT, Sham JST, Kwong DLW, *et al.* Prognostic value of paranasopharyngeal extension of nasopharyngeal carcinoma. *Cancer* 1996;78:202-210.
11. Sham JST, Choy D. Prognostic factors of nasopharyngeal carcinoma: a review of 759 patients. *Brit J Radiol* 1990;63:51-58.16.
12. Lee AWM, Poon YF, Foo W, *et al.* Retrospective analysis of 5037 patients with nasopharyngeal carcinoma treated during 1976 - 1985: overall survival and patterns of failure. *Int J Radiat Oncol Biol Phys* 1992;23:261-270.
13. Perez CA, Devineni VR, Marciai-Vega V, *et al.* Carcinoma of the nasopharynx: factors affecting prognosis. *Int J Radiat Oncol Biol Phys* 1992;23:271-280.
14. Sham JST, Choy D, Kwong PWK, *et al.* Radiotherapy for nasopharyngeal carcinoma: shielding the pituitary may improve therapeutic ratio. *Int J Radiat Oncol Biol Phys* 1994;29: 699-704.
15. Wei WI, Lund VJ, Howard DJ. Serous otitis media in malignancies of the nasopharynx and maxilla. *J Laryngol Otol* 1988;102:129-132.
16. Brill AH, Martin MM, Fitz-Hugh GS, *et al.* Postoperative and postradiotherapeutic serous otitis media. *Arch Otolaryngol* 1974;99:406-408.
17. Wei WI, Engzell UCG, Lam KH, *et al.* The efficacy of myringotomy and ventilation tube insertion in middle-ear effusions in patients with nasopharyngeal carcinoma. *Laryngoscope* 1987;97:1295-1298.
18. Lau SK, Wei WI, Sham JST, *et al.* Early changes of auditory brain stem evoked response after radiotherapy for nasopharyngeal carcinoma - A prospective study. *J Laryngol Otol* 1992; 106:887-892.
19. Kwong DLW, Wei WI, Sham JST, *et al.* Sensorineural hearing loss in patients treated for nasopharyngeal carcinoma: A prospective study of the effect of radiation and cisplatin treatment. *Int J Radiat Oncol Biol Phys* 1996;36:281-289.
20. Chan ATC, Teo PML, Leung TWT, *et al.* A prospective randomized study of chemotherapy adjunctive to definitive radiotherapy in advanced nasopharyngeal carcinoma. *Int J Radiat Oncol Biol Phys* 1995;33:569-577.
21. International Nasopharynx Cancer Study Group VUMCA I Trial: Preliminary results of a randomized trial comparing neoadjuvant chemotherapy (cisplatin, epirubicin, bleomycin) plus radiotherapy vs Radiotherapy alone in stage IV (>N2, M0) undifferentiated nasopharyngeal carcinoma: a positive effect on progression-free survival. *Int J Radiat Oncol Biol Phys* 1996; 35:463-469.
22. Al-Sarraf M, LeBlanc M, Fu K, *et al.* Superiority of chem-radiotherapy (CT-RT) vs radiotherapy in patients with locally advanced nasopharyngeal carcinoma. *Am Soc Clin Oncol* 1966;15:313.
23. Sham JST, Choy D. Nasopharyngeal carcinoma: treatment of neck node recurrence by radiotherapy. *Australasian Radiol* 1991;35: 370-373.
24. Wei WI, Lam KH, Ho CM, *et al.* Efficacy of radical neck dissection for the control of cervical metastasis after radiotherapy for nasopharyngeal carcinoma. *Am J Surg* 1990; 160:439-442.
25. Wei WI, Ho CM, Wong MP, *et al.* Pathological basis of surgery in the management of postradiotherapy cervical metastasis in nasopharyngeal carcinoma. *Arch Otolaryngol Head Neck Surg* 1992; 118:923-929.
26. Dickens P, Wei WI, Sham JST. Osteosarcoma of the maxilla in Hong Kong Chinese postirradiation for nasopharyngeal carcinoma. *Cancer* 1990;66:1924-1928.
27. Wei WI, Sham JST, Choy D, *et al.* Split-palate approach for gold grain implantation in nasopharyngeal carcinoma. *Arch Otolaryngol Head Neck Surg* 1990;116:578-582.
28. Choy D, Sham JST, Wei WI, *et al.* Transpalatal insertion of radioactive gold grain for the treatment of persistent and recurrent nasopharyngeal carcinoma. *Int J Radiat Oncol Biol Phys* 1993;25:505-512.
29. Wei WI, Lam KH, Sham JST. New approach to the nasopharynx: the maxillary swing approach. *Head Neck* 1991;13:200-207.
30. Wei WI, Ho CM, Yuen PW, *et al.* Maxillary swing approach for resection of tumours in and around the nasopharynx. *Arch Otolaryngol Head Neck Surg.* 1995;121:638-642.