

# **The rationale for the treatment of traumatized primary teeth**

**A dissertation submitted as partial fulfillment for the**

**Post-graduate Diploma in Dental Surgery**

**by**

**Dr. Rungsima Siraklao**

**Paediatric Dentistry and Orthodontics**


**Faculty of Dentistry**

**2001**



**Supervisor : Professor Nigel M King, B.D.S.,  
M.Sc., Ph.D., F.H.K.A.M., F.C.D.S.H.K., L.D.S.R.C.S.**

THE UNIVERSITY OF HONG KONG  
LIBRARIES



*This book was a gift  
from*

Dr. Rungsima Siraklao

---

---

## Abstract

---

---

Injuries to a young child's teeth and face are not only traumatic in a physical sense, but also in an emotional and psychological sense. Before the damaged tissues can be treated the distress suffered by the child and parents must be managed; also, other injuries of greater significance need to be ruled out. A good history of the accident, as well as a medical history, must be taken in concert with a clinical evaluation of the child's neurological and physical status; and level of cooperation.

The treatment that offers the best prognosis should be performed, because risky procedures can increase the chance of failure, also the willingness of parents to comply with follow-up regimens must be considered before planning the definitive treatment. Ideal treatment modalities may have to be modified, or even compromised for the child who is difficult to manage.

This review of the published literature, which contains numerous epidemiological studies, several review articles on the prevalence and incidence of trauma to the primary teeth and many case reports, was conducted to determine if there were adequate rationale for the treatment of traumatized primary teeth. Sadly, the treatment recommendations for most types of injuries are not based on reliable research data, or consecutive treated cases; rather they have been taken from individual case reports.

For concussion and subluxation injuries, that do not render the tooth excessively mobile, no active treatment should be provided. It is generally agreed that regular monitoring of an intruded tooth should take place because spontaneous eruption can be expected within 4 weeks after the trauma. For extrusion, repositioning of the tooth can be made when it is slightly displaced from the socket. However, extraction needs to be performed for extremely mobile and displaced teeth. Most authors have expressed the strong opinion not to reimplant avulsed primary teeth because of the possibility of chronic infection and dystrophic changes to the developing tooth.

From the literature it appears that enamel infraction does not require any specific treatment other than regular reviews. While smoothing of the sharp margins of the fractured area is the best management for an enamel fracture, it also seems that, the treatment of crown and crown-root fracture is determined by whether or not the pulp is exposed and the child's level of cooperation. Direct pulp capping, pulpotomy, and pulpectomy can be done and are largely dependent on the size of the exposure and possibility of pulp contamination. In addition, for teeth with root fractures, but which are not excessively mobile, conservative treatment is provided, while extraction should be the treatment of choice if the tooth has excessive mobility to avoid the development of pulpal necrosis.

Although the majority of the recommended treatment is based on case reports and is therefore open to criticism and discussion, it is universally agreed that long-term follow-up is essential because of the sequelae to the injured tooth and the developing permanent tooth.



---

---

# Table of Contents

---

---

<b>Abstract</b>	i
<b>Acknowledgements</b>	iii
<b>Table of Contents</b>	iv
<b>List of Tables</b>	vii
<b>List of Figures</b>	viii
<b>1.0 Introduction</b>	1
1.1 Etiology	1
1.2 Prevalence and incidence of dental injuries	2
1.3 Distribution according to age and gender	3
1.4 Location of dental injuries	4
1.5 Seasonal variation	4
1.6 Types of injuries	4
<b>2.0 Objectives</b>	7
<b>3.0 Treatment of Dental Injuries</b>	8
3.1 Treatment of injuries to supporting structures	10
3.1.1 Concussion	10
3.1.2 Subluxation	11
3.1.3 Intrusion	12
3.1.4 Lateral luxation	13
3.1.5 Extrusion	16
3.1.6 Avulsion	16
3.2 Treatment of injuries to the teeth	20

3.2.1	Enamel infraction	20
3.2.2	Enamel fracture	20
3.2.3	Enamel-dentin fracture	21
3.2.4	Complicated crown fracture	22
3.2.5	Crown-root fracture	24
3.2.6	Root fracture	25
<b>4.0</b>	<b>Sequelae of Injuries</b>	<b>43</b>
4.1	Sequelae of injuries on primary dentition	43
4.2	Sequelae of injuries on permanent dentition	45
4.2.1	Discoloration	47
4.2.2	White or yellow-brown discoloration of enamel and horizontal enamel hypoplasia	47
4.2.3	Crown dilaceration	47
4.2.4	Odontome-like malformation	48
4.2.5	Root duplication	48
4.2.6	Vestibular root angulation	48
4.2.7	Lateral root angulation or dilaceration	48
4.2.8	Partial or complete arrest of root formation	49
4.2.9	Sequestration of permanent tooth germ	49
4.2.10	Ectopic, premature or delayed eruption or impaction	49
<b>5.0</b>	<b>Conclusions</b>	<b>51</b>
<b>6.0</b>	<b>References</b>	<b>55</b>
<b>Appendix 1</b>	Statistics on the frequency of injuries to the primary dentition of children from different countries in the world	71
<b>Appendix 2</b>	The classification of the injuries	77
<b>Appendix 3</b>	Statistics on the frequency of the various types of injuries	83

to the primary teeth

**Appendix 4** Examination and diagnosis of dental injuries

85



---

---

## List of Tables

---

---

	<b>Page</b>
Table 1 The percentage of traumatic dental injuries in the primary dentition of children from different countries	72
Table 2 Prevalence of traumatic dental injuries to the primary teeth of 5-year-old children in different countries	73
Table 3 Distribution of injuries to the primary dentition according to gender	74
Table 4 The peak age for traumatic injuries to the primary dentition	75
Table 5 The most commonly affected teeth for traumatic injuries to the primary dentition	76
Table 6 Percentage of injuries to the primary teeth in different countries	84

---

---

## List of Figures

---

---

	<b>Page</b>
Figure 1 Treatment of concussion	28
Figure 2 Treatment of subluxation	30
Figure 3 Treatment of intrusion	31
Figure 4 Treatment of intrusion	32
Figure 5 Treatment of lateral luxation	33
Figure 6 Treatment of extrusion	34
Figure 7 Treatment of avulsion	35
Figure 8 Treatment of crown fracture	37
Figure 9 Treatment of crown-root fracture	38
Figure 10 Treatment of crown-root fracture	39
Figure 11 Treatment of root fracture	41
Figure 12 Treatment of root fracture	42

---

---

## **1.0 Introduction**

---

---

Most traumatic injuries to the teeth and their supporting structures constitute a true dental emergency and are amongst the most serious of dental conditions. In comparison to other types of traumatic bodily injuries, dental trauma may not seem that serious. Nevertheless, oro-facial injuries are particularly important because of the critical sensory, communicative, gustatory, and psychosocial functions of the teeth and mouth. Furthermore, because teeth have the lowest potential, of any bodily tissue, to return to a normal state after injury, appropriate rational therapy, based upon accurate diagnosis, must be instituted (Josell and Abrams 1982).

### **1.1 Etiology**

Injuries can be considered as being intentional or unintentional (Graitcer 1994). Falling against an object is the most common cause of unintentional injury and most of these injuries occur inside the home (Andreasen 1981, Garcia-Godoy et al. 1987, Oikarinen and Kassila 1987, Von Arx 1990, Perez et al. 1991, Schatz and Joho 1994, Wilson 1995).

When children reach school age, accidents in the school playground are extremely common (Ravn 1974). Most of these injuries are due to falls or children running into each other. Moreover, Johnson (1975) mentioned that dental injuries have also been found among mentally and physically compromised patients; the causative factors being a lack of motor coordination, crowded conditions in institutions and

concomitant epilepsy. Many of these injuries can be directly related to falls during epileptic seizures (Johnson 1975).

Domestic violence (child abuse) is an example of an intentional injury (Tate 1971, Laskin 1978). The tragic cause of injuries in small children has been called the "battered child syndrome", or non-accidental injuries (NAI) Most studies indicate that about 50% of fatal cases involve oro-facial trauma (Davis et al. 1979).

The types of dento-alveolar traumatic injuries differ according to the source of the material being investigated, also there seems to be a relationship to the place of treatment; such as hospitals, where the material includes the more severe injuries (Andreasen 1970, Ravn 1974).

## **1.2 Prevalence and incidence of dental injuries**

The data in Table 1 (Appendix 1) on the frequencies of dental injuries in the primary dentition which has been assembled from studies from various countries indicate that the prevalence varies from 10.9% to 35.0%. These figures are probably underestimates because a number of children may have sustained minor injuries, which were either neither diagnosed nor treated by a dentist (Andreasen 1981).

Variations in the different reports can be attributed to actual differences in the prevalence in the populations examined, or to a bias in the selection of patients seeking treatment in different types of clinics. Therefore, it is important to assess the prevalence of traumatized teeth by the use of a survey (Andreasen and Ravn

1972). This approach means that even those children who do not seek any treatment following the trauma would be included (Zadik 1976).

### **1.3 Distribution by age and gender**

Table 2 (Appendix 1) shows the prevalence of traumatic dental injuries to the primary dentition of boys and girls. These age-corrected statistics indicate that in the primary dentition, the prevalence of injuries ranges from 28% to 40% in boys and from 16% to 30% in girls.

The distribution of injuries in the primary dentition according to gender is shown in Table 3 (Appendix 1). Most of the studies have shown that more boys injure their teeth than girls indicating a greater proneness of boys to injury. The explanation may be that boys are more physically active and so at greater risk than girls. However, this influence would be expected to be relatively minor in children under 5 years of age. Nevertheless, it appears that gender is of decisive importance for both risk and the severity of injuries. However, this may be of less significance in the primary than the permanent dentition.

More traumatic dental injuries occurred to younger children probably because the children are learning to walk, gaining mobility and independence, yet they lack full, or even adequate coordination and judgement to avoid falling and/or to minimize consequential injuries (Andreasen and Ravn 1972, Ferguson and Ripa 1979, Sanchez et al. 1981, Garcia-Godoy et al. 1983, Schatz and Joho 1994), see Table 4.

## **1.4 Location of dental injuries**

The majority of dental injuries involve the anterior teeth, most especially the maxillary central incisors (Table 5). Generally, only a single tooth is affected (Zadik 1976, Forsberg and Tedestam 1990, Glendor et al. 1996, Hargreaves et al. 1999). However, Schatz and Joho (1994) found that 53% of the children had two teeth injured compared with 38% who had single tooth injuries.

## **1.5 Seasonal variation**

There appears, to be some seasonal variation in the occurrence of dental injuries. However, these variations could be dependent on the reporter. For example, Emergency Room reports indicate a greater frequency of dental trauma in the summer months (Garcia-Godoy et al. 1987, Von Arx 1990, Bhat 1990, Schatz and Joho 1994), whereas reports from the Scandinavian school dental services indicate a drop during the same period (Ravn 1974, Oikarinen and Kasilla 1987, Hayrinen-Immonen et al. 1990). This disagreement could reflect differences in the clinical activities in this period, or the nature of the catchment area such as it being a city, or a holiday resort.

## **1.6 Types of injuries**

They have been classified according to a variety of factors, such as etiology, anatomy, pathology, or therapeutic considerations (Johnson 1981, Garcia-Godoy

1981). Trauma to the primary dentition is common in a paediatric dental setting; hence, the injuries have been classified in various ways (Johnson 1981). A simple and widely accepted classification, which will be used in this dissertation, subclassifies the condition into trauma affecting the tooth, the periodontium, and oral mucosa based on anatomical, therapeutic and prognosis considerations (Andreasen and Andreasen 1994). For reference purposes a comprehensive description of each injury is given in Appendix 2.

Each injury may result in one or more diagnoses for a primary tooth. Table 6 (Appendix 3) shows the percentage of injuries to the primary teeth according to the involvement of the supporting structure and hard tissues.

Studies of trauma in the primary dentition are relatively few and the data that are available are often grouped into broad age categories. Furthermore, the quality of the data varies because of the different conditions in different studies. Some have been collected from hospitals, other from dental schools and some from private clinics.

However, a comprehensive review of the epidemiology of injured primary teeth shown in Table 6 indicates that the prevalences of injuries to the supporting structures were from 10% to 90% of all studied cases from different countries, while those of hard dental tissue injuries were from 8% to 83.7%.

In comparing data concerning the type of trauma, most of the studies report that the supporting structures are injured more often than the hard tissues. This is due to the fact that the supporting tissue around the primary dentition is thin, elastic, and has a

low level of mineralisation; consequently, it has a greater resilience to the force of trauma to the bone which preferentially absorbs the energy of the force, so displacement of the tooth occurs rather than fracture of the crown or root.

However, the percentage of hard dental tissue injuries is higher in the studies by Schutzmansky (1963), Zadik (1976), and Hargreaves and his co-workers (1999). The fact that the cited works were carried out in hospital, or clinic populations explains the differences. On the other hand, discolorations and periodontal tissue injuries are definitely under-reported because of possible spontaneous healing with time.

The difference in prevalence rates for supporting structure injuries and hard tissue injuries could also be influenced by the different times the studies were conducted, the places producing the data, differences in socio-economic backgrounds, a small sample size with a broad age range, and simply the validity of the data from different investigators. However, as these are the only data available, it is recommended that all of these data be used to develop the appropriate preventive and treatment regimens for injuries to the primary dentition, but the limited robustness of the data must be remembered and so the data should be used with caution.



---

## **2.0 Objectives**

---

The treatment plan for traumatized primary teeth is often different from that for permanent teeth because of the difference of the healing mechanisms of the pulp and periodontal tissues. Protection of the pulp and the periodontal ligament from bacterial infection along with efforts to avoid any residual damage to the underlying permanent successor are the desired treatment objectives. However, for young children treatment may be compromised due to their uncooperative behavior.

The objectives of this dissertation are to review the treatment options that have been recommended, in the literature, for injuries to the primary teeth and their supporting structures and the sequelae of these injuries; in an attempt to determine if the literature contains sound rationales for the treatment of the various traumatic injuries to the primary teeth.

---

---

### **3.0 Treatment of Dental Injuries**

---

---

Before describing the treatment options for injuries to the supporting structures and the hard tissues of the primary teeth it proposed to consider the general principles underlying all forms of treatment for traumatized children.

DeVore (1995) stated that when treating traumatized children, the dentist has no less professional and legal responsibilities than when treating a non-emergency patient. After obtaining proper consent, the examination, diagnosis, subsequent treatment, and follow-up of the patient must not be made negligently. The treating dentist must not practice below the standard of care of a similar practitioner acting in the same or similar circumstances. In addition, it should be remembered that the dentist may be called on to further assist the parent, or patient, in an attempt to obtain compensation for the loss brought about by the trauma.

Several factors need to be considered prior to considering the definitive treatment options that have been recommended. First is cooperation. Ideal treatment modalities may have to be compromised, or even modified for the unmanageable child. Treatment offering the best prognoses should be performed, because risky and/or complex procedures can increase the chance of failure or damage to the permanent successor. When determining the treatment of choice for traumatically injured primary teeth, underlying factors should be considered that may affect the outcome of such treatments; for example, the presence of deep caries that may already have affected the pulp, previous traumatic injuries that could diminish the

recuperative capabilities of the tooth, or a habit that may interfere with healing of the periodontal tissues. If any of these conditions exists, then extraction may be a least risky treatment option. Treatment considerations should also include the willingness of the parents to comply with follow-up regimens, space maintenance, time until exfoliation of the injured tooth, coronal development of succedaneous teeth, dental occlusion, and medical status. Each of these variables can affect the treatment modalities selected (Wilson 1995).

The treatment plan for traumatised primary teeth is often different from that for permanent teeth. The healing mechanisms of the pulp and periodontal tissues in primary teeth are different from those of permanent teeth, for primary teeth sometimes extraction has a high priority in order to limit damage to the permanent successors. However, it is prudent to heed the warning that a lack of understanding of the healing mechanisms unique to primary teeth may result in unnecessary treatment or inappropriate extraction (Tsukiboshi 2000).

Traumatic injuries to the teeth and oral tissues constitute true dental emergencies requiring experienced diagnostic and treatment skills plus an empathetic operator. When such injury affects the young child, the level of judgement and experience necessary for treatment may be unequalled by any other situation the dentist may face in practice (Wilson 1995).

It is now proposed to describe the treatment of each type of injury to the primary tooth and the rationale for that treatment modality. The treatment of the dental injuries related to the supporting structures will be discussed first, followed by the

treatment of injuries to the hard tissues.

### **3.1 Treatment of injuries to supporting structures**

#### **3.1.1 Concussion**

This is the simplest type of injury to treat (Mackie and Blinkhorn 1996). Usually, no active treatment is required, however, the patient should be kept on a soft diet for a few days (Mackie and Warren 1988, Andreasen and Andreasen 1994, Mackie and Blinkhorn 1996, Tsukiboshi 2000).

Greyish brown discoloration of the crown, pulp obliteration, or abscess formation due to trauma-induced pulpal death may be seen after the injury (Andreasen and Andreasen 1994, Josell 1995, Mackie and Blinkhorn 1996, Tsukiboshi 2000). Therefore, the parents should be informed of these possibilities, even if no abnormality is apparent, and the importance of observation and the need for periodic examinations should be emphasised.

As concussion represents a crushing of the nervous innervation and the blood supply to the tooth, these changes may only be transient. They manifest sometimes as a reddish discoloration followed by a change to a brownish grey colour, which can then change to an almost normal tooth colour. Thus endodontic therapy should be resisted until multiple clinical and radiographic signs and symptoms are present (Figure 1).

### 3.1.2 Subluxation

It is important to note the child's age because exfoliation and not trauma may be a major contributory factor to the mobility of the tooth. Treatment for subluxation is the same as for concussion, and it is usually found that after one or two weeks the teeth become firm and the tenderness spontaneously resolves (Mackie and Warren 1988, Andreasen and Andreasen 1994, Mackie and Blinkhorn 1996).

However, Fried and co-workers (1996) found that the treatment of subluxed teeth varies. From their study, 80.2% of teeth required no dental treatment (Figure 2). This finding supports the monitoring of afflicted teeth, on a regular basis, for the first year as opposed to immediately instituting invasive treatment. When excessive mobility is present short-term splinting for seven to ten days using an acid-etched resin attachment such as a light orthodontic wire or fishing line should be considered if the child's behavior is considered to be adequate. If behavior is a major deterrent to accomplishing splinting techniques, and the clinician judges the tooth's mobility excessive enough to place it at risk of being lost, with the theoretical potential of inhalation or aspiration, the tooth should be extracted. Occlusal equilibration of opposing teeth to reduce repeated trauma due to hyperocclusion of the afflicted teeth can also enhance stabilization. The existence of a non-nutritive sucking habit needs to be determined because, unless stopped, this will compromise the healing process.

Periodic re-evaluation is advisable according to the findings from Ravn's 1968 study of subluxated primary teeth, in which he found that 10% of teeth subsequently required extraction because of suspected pulp necrosis, while 48% showed pulp

canal obliteration.

### **3.1.3 Intrusion**

When intrusive displacement occurs, the primary tooth usually remains labial to the developing permanent tooth which is the normal developmental relationship of these teeth. Furthermore, because of the labial inclination of the root of the primary incisor, intruded primary incisors are mostly forced towards the labial, often penetrating the thin vestibular bone, as a result of an axial impact. In such cases, a “wait and see” policy should be implemented, for it can reasonably be anticipated that re-eruption will normally occur within a maximum of 6 months after the injury (Andreasen and Ravn 1972, Andreasen and Andreasen 1994, Wilson 1995, Dummett 2000; as shown in Figure 3). According to the findings of Soporowski and co-workers (1994), intruded primary teeth have the highest correlation with hypoplastic defects in the underlying permanent tooth successors when compared with lateral luxation and avulsion. Therefore, intruded primary teeth that re-erupt should subsequently be monitored closely for signs of pulp degeneration, a complication found in approximately one third of re-erupted primary teeth (Ravn 1968), that may necessitate either a pulpectomy procedure or extraction.

If some movement of an intruded tooth is not evident within 4 weeks, or if the intruded primary tooth is displaced in a palatal direction towards the underlying permanent tooth, it should be extracted to relieve the pressure upon the odontogenic tissue within the follicle (Wilson 1995). The extraction procedure should aim to minimise any further injury to the developing permanent successor. Therefore,

Andreasen and Andreasen (1994) recommended that elevators should not be used to luxate the primary incisor. Forceps should be the only instrument employed for this purpose. Moreover, the primary incisor should be grasped by the proximal surfaces, as there is a risk that if the tooth is grasped bucco-palatally that the forceps could glide along the crown apically into the follicle zone. Once grasped mesiodistally, the displaced incisor should be lifted out of its socket in a labial and axial direction. Finally, once extracted, digital pressure should be applied to the buccal and lingual aspects of the socket to reposition the displaced bone plates (Figure 4).

Moreover, according to Fried and co-workers (1996), antibiotics should be prescribed in cases where a potential for systemic infection is considered possible, and they found this to so be in 41.8% of children. The risk is less for avulsion or luxation injuries, where there is a higher likelihood that the gingival structures have been lacerated, hence there is an increased risk of systemic infection. There are no written guidelines, or sound clinical data, to determine whether antibiotics should, or should not, be prescribed. Most authors state that the decision is left solely to the practitioner who needs to make a clinical evaluation of each individual patient.

#### **3.1.4 Lateral luxation**

The best treatment regimen for laterally luxated primary teeth is still a cause for debate (Andreasen and Andreasen 1994). The main objective is the prevention of further damage to the developing permanent tooth, or teeth.

Laterally luxated primary teeth are usually repositioned spontaneously by the tongue

and lip pressure within a period of 1-6 months (Ravn 1968, Andreasen and Andreasen 1992). Therefore, they can be left untreated. However, before a decision is made to wait for spontaneous repositioning, the direction of the displacement should be considered (Andreasen and Andreasen 1994). The crown is often displaced lingually and the apex of the root labially, so taking it away from the developing tooth germ. In this case, the prognosis is better because the eruption of the permanent tooth is to the lingual aspect of the primary tooth. So there is less chance of damage to the erupting teeth as a consequence of this type of injury (Moss and Maccaro 1985). Unless there is an occlusal interference, or the tooth is excessively mobile, a laterally luxated incisor can often be left untreated. However, if an interference does exist, the tooth may be gently repositioned with finger pressure to afford the child greater comfort (Wilson 1995; as shown in Figure 5). However, this must be done gently and with great care because repositioning might disrupt the development of the permanent successor and lead to malformations (Mackie and Blinkhorn 1996). It has even been recommended that the tooth be repositioned followed by suturing of the gingiva and splinting of the teeth as with permanent teeth (Tsukiboshi 2000), that is in the same way as Dummett advised for minimal horizontal displacements (Dummett 2000).

Splinting of luxation injuries in the primary dentition is usually not performed for several reasons (Wilson 1995). Firstly, most injuries occur in children aged 3 years, or younger, so that cooperation is often a problem. Most children this young cannot remain still enough for the time it takes to apply a splint. Secondly, the clinical crowns of the primary teeth are short and bonding to them can be difficult especially when there is gingival bleeding. And, lastly, because the bone in young children is



so spongy and malleable, once the teeth have been repositioned the bone can be remodelled around the teeth with gentle finger pressure, and this is sufficient to hold the teeth in a fairly stable position.

In rare instances, the laterally luxated tooth will be displaced with the apex being forced into the follicle. This may be difficult to assess both clinically and radiographically but if this is the case, extraction is the treatment of choice to prevent further damage to the permanent tooth germ (Mackie and Warren 1988, Andreasen and Andreasen 1992, Mackie and Blinkhorn 1996). Extraction is also advisable if the displaced tooth is so mobile that there is a danger the child might inhale it, (Mackie and Warren 1988, Mackie and Blinkhorn 1996) or if there is excessive tooth displacement accompanied by alveolar fracture, gingival laceration, and uncooperative behavior (Dummett 2000). It is interesting that Soporowski and co-workers (1994) reported that repositioning of laterally luxated primary teeth was associated with an increased prevalence of pulp necrosis; which would support the option of extraction if subsequent endodontic therapy will, in the clinician's opinion, be contra-indicated.

Mackie and Warren (1988) also commented that in all laterally luxated cases advise must be given to the parents on the importance of maintaining the fluid intake. A soft diet should be recommended, and the parent must take responsibility for gently brushing the teeth, initially the damaged region of the mouth can have 1% chlorhexidine gel applied with a cotton tipped applicator or with a toothbrush up to three times per day (King personal communication) and the parent should be informed about pulp obliteration, or rapid root resorption that might occur

subsequently after lateral luxation injury, whether or not there has been any active treatment. However, treatment is usually unnecessary when there is pulpal obliteration or resorption (Tsukiboshi 2000).

### **3.1.5 Extrusion**

Extruded primary teeth should be evaluated clinically and radiographically to detect any evidence of fracture of either the root or alveolar bone, or of damage to the underlying developing permanent tooth. Few data are available on either the definitive treatment or prognosis of these injuries. Extrusion injuries can cause occlusal interferences. If the tooth is only slightly displaced from its socket and not excessively mobile, it can usually be repositioned using gentle finger pressure (Wilson 1995, Josell 1995, Dummett 2000). However, if the tooth is extremely mobile with incisal displacement of more than 2mm, it is best to be extracted so as to avoid the potential of chronic periradicular infection and hence, adverse effects on the underlying permanent tooth (Dummett 2000; as shown in Figure 6). Some authorities are much more radical and advocate that, generally, extruded teeth should be extracted (Andreasen and Andreasen 1992), so as to promote optimal healing. However, there does not seem to be any data to support this option.

### **3.1.6 Avulsion (Exarticulation)**

Assuming, that an avulsed tooth has been found, and brought to the dental office, then treatment can be considered. If however, the location of the avulsed tooth is unknown, then it is prudent to take a radiograph of the chest and stomach if there is,

even the slightest, possibility that the tooth may have been inhaled. This avoids any respiratory complications that may subsequently arise ( Holan and Ram 2000).

Opinion is somewhat divided with respect to the treatment recommendation for avulsed or exarticulated primary teeth. The predominant opinion is that primary teeth should not be reimplanted because of the increased risk of interference with the developing succedaneous permanent teeth because of the development of subsequently dystrophic changes and the associated inflammation that may damage the underlying tooth bud (Andreasen and Andreasen 1994, Josell 1995, Wilson 1995, Mackie and Blinkhorn 1996). Moreover, Andreasen and Andreasen (1992) also mentioned that there is a risk of further injury to the permanent tooth germ by the reimplantation procedure whereby the coagulum can be forced into the area of the follicle. This approach overcomes any doubts about the child being able to tolerate the treatment procedures of splinting and pulp therapy of the subsequently non-vital tooth.

However, in young patients, the absence of anterior teeth until the eruption of the permanent teeth may cause esthetic and functional complications, and anxiety for the child and the parents. Therefore, attempting reimplantation can sometimes be a worthwhile option (Tsukiboshi 2000; as shown in Figure 7). Furthermore, reimplantation may be indicated, in children aged from 2 to 4 years so as not to interfere with their speech development (Mueller and Whitsett 1978, Andreasen and Andreasen 1992, Kawashima and Pineda 1992, Andreasen and Andreasen 1994).

Reimplantation of avulsed primary teeth has been the subject of several case reports.

Eisenberg (1965) successfully reimplanted an avulsed primary incisor immediately after extra-oral root canal therapy had been performed. Although the tooth was not splinted, it remained functional for 3 years when it underwent physiologic exfoliation. Ravn (1968) reported four cases of avulsed primary teeth, which were reimplanted and immobilized for 4 to 6 weeks; root canal therapy was not performed on these teeth. Two of the teeth showed increased mobility and advanced root resorption within the first year after replantation. A third tooth was shed prematurely while the fourth functioned normally for 27 months. An avulsed primary tooth that had been reimplanted by the father “one minute” after the trauma was subsequently splinted for 2 weeks, but not treated endodontically, and was preserved until its natural exfoliation (Mueller and Whitsett 1978).

Filippi and co-workers (1997) recommended resecting the root of avulsed primary incisors followed by retrograde instrumentation of the root canal system prior to reimplantation. Although no clinical cases with significant observation times were presented, the authors stated that resection of the root apex prevents damage to the underlying tooth germ during the reimplantation process. The proposed procedures, however, increase the extra-alveolar time. In addition, complete extirpation of the pulpal tissue and adequate preparation of the root canal are critical factors.

Recently, Weiger and Heuchert (1999) described the management of an avulsed primary maxillary central incisor in a 3 years 6 months old girl. The tooth was out of its socket, but still in contact with the vestibular mucosa, for 30 minutes. After reimplantation it was splinted for 17 days. On day eleven the root canal was instrumented and obturated with a calcium hydroxide paste; the access cavity was

then restored with a glass ionomer cement. In this case, the root was fully formed thus increasing the likelihood that the endodontic instruments and medicaments were limited to the confines of the root canal system, thereby reducing the risk of unintentionally damaging the permanent tooth germ. The one-year follow-up documented no clinical or radiographic pathology. One and a half years after reimplantation the tooth was extracted because a fistula had developed and there was extensive external inflammatory resorption. The periapical lesion probably occurred as a result of a re-infection of the root canal system (Tronstad 1988), because the glass ionomer cement restoration in the access cavity had failed and allowed marginal leakage to occur. The permanent successor erupted 6 months later along with its neighboring central incisor without any evidence of complications.

A number of case reports have indicated success in reimplanting avulsed primary teeth in selected cases with an extra-oral time, without wet storage, of less than 30 minutes. However, until data from large controlled studies become available to confirm the success of reimplantation of avulsed primary teeth, this technique can not be recommended (Dummett 2000).

While the success of the various treatment options that have been described in the literatures cannot be disputed it is sad that many are anecdotal in nature and are based on case reports, often of only one case.

## **3.2 Treatment of injuries to the teeth**

### **3.2.1 Enamel infraction (crazing)**

Detection of this type of injury can be facilitated by direct illumination of the tooth; the infraction appears as a vertical or horizontal crazing. At times this crazing may be the only evidence that there was trauma to the tooth. Though the injury does not require initial therapy, the tooth should be periodically evaluated for possible adverse sequelae (Josell 1995); such as pulpal complications (Jacobsen 1981). A possible explanation for this is that the energy of the impact is transmitted to the pulp, and/or the surrounding tissues.

### **3.2.2 Enamel fracture**

Enamel fractures in primary teeth are best managed by smoothing of the sharp margins of the fractured areas to prevent irritation to the lips, tongue and other soft tissues (Dummett 2000). In most instances slight contouring of the tooth will provide an aesthetically acceptable result (Jacobsen 1981). After 2 to 3 months, these teeth should be regularly monitored for clinical and radiographic signs of pathology.

Discoloration is a significant clinical entity associated with traumatized primary teeth. Borum and Andreasen (1998) noted that 51.4% of his studied cases exhibited discoloration after being traumatized. Yellow discoloration was most frequently

seen and was commonly associated with pulp canal calcification. Traumatized primary teeth with discoloration should therefore be closely monitored for increased potential of developing pulpal pathology.

### **3.2.3 Enamel - dentin fracture**

As with any type of crown fracture, location of the fragments is important because they may have been swallowed, aspirated, or embedded into the adjacent soft tissues (Hill and Picton 1981, Josell 1982,).

Fracture of a crown into dentine exposes thousands of dentinal tubules per square millimeter. These tubules constitute a potential pathway for bacteria and other irritants to reach the pulp and hence cause pulp inflammation (Wilson 1995); the immediate therapy, which should be performed as soon as possible, is directed at preserving the integrity of the underlying pulpal tissues (Josell 1995). Covering of the dentin also alleviates the thermal sensitivity that is often experienced with a fractured tooth. This can be done by sealing the exposed dentin tubules with either a glass ionomer or a dentin-bonding agent in conjunction with a composite resin restoration (Dummett 2000). However, patient cooperation and the possibility of inadequate moisture control are factors that must be considered (Jacobson 1981, Wilson 1995). For children who are uncooperative, the treatment can be restricted to the smoothing of any sharp edges (Mackie and Blinkhorn 1996).

In the case of extensive loss of tooth substance, the afflicted tooth can be restored with a full-coverage restoration such as a composite resin strip crown (Dummett

2000). Another alternative is a stainless steel crown, especially if adequate isolation and moisture control cannot be obtained (Wilson 1995). When the esthetics are of concern to the parent and the child is cooperative, a stainless steel crown with an open-faced composite resin window, or a veneer on the labial metal surface can be used (Dummett 2000). However, these types of treatment may make it difficult to observe colour changes in the crown. No matter what the treatment was, postoperative monitoring for clinical and radiographic pathology is essential due to the sequelae that can occur. For the example, Kenwood and Seow (1989) found that almost 20% of crown fracture injuries show signs of pulp necrosis and 20% subsequently exhibited root canal obliteration.

#### **3.2.4 Complicated crown fractures**

A complicated crown fracture is one that involves the pulp so usually they present with slight hemorrhage from the exposed part of the pulp; thus, the pulp is exposed to contamination by microorganisms. Therapy should be directed towards minimizing this contamination so as to improve the prognosis. The therapy of choice depends on the extent of the exposure, the length of time since the injury, the condition of the pulp, and the presence and nature of any accompanying injuries (Josell 1982; as shown in Figure 8).

It has been stated that primary teeth that have sustained crown fractures that expose the pulp with roots that have been resorbed to a greater extent than one half of the total root dimension should be extracted (Dummett 2000).



Where the pulp is exposed, a lack of cooperation on behalf of the child usually dictates that the treatment of choice is extraction of the tooth (Mackie and Blinkhorn 1996). However, pulp capping, pulpotomy or pulpectomy procedures may be attempted in selected cases.

Conservation of radicular pulp tissue with varying degrees of coronal pulp tissue removal followed by sealing against microleakage is the ultimate treatment goal for primary teeth that will not exfoliate in the near future (Dummett 2000).

If the exposure is extremely small; that is less than 1.0mm and recent (maximum 4-5 hours), a calcium hydroxide dressing may be placed over the site and the tooth restored with either a stainless steel crown or composite resin (Kopel 1992). There have also been recommendations by Cvek (1978) and Zilberman and co-workers (1986) that the exposure site should be enlarged by removing 1 to 2mm of pulp tissue. This partial pulpotomy, before the placement of the capping material allows a closer contact of more capping medicament with the actual pulp tissue in order to bring about a favorable results (Cvek 1978). This approach also allows the resultant blood clot to be removed; a factor that may reduce the likelihood of internal resorption. Ram and Holan (1994) reported short-term success with the partial pulpotomy technique for a primary central incisor that had sustained a complicated coronal fracture in a 14-month-old child. If the exposure is large or has been present for more than a few hours, then a pulpotomy or pulpectomy is indicated depending on the condition of the pulp tissue.

The pulpotomy is the most widely advocated treatment for exposed primary pulps

because of its consistently reported higher success rates when compared with direct pulp capping (Mathewson and Primosch 1995). When the exposed pulp has been contaminated due to extensive crown loss, or a time delay of greater than 24 hours, complete pulpectomy or even extraction may provide the best insurance against residual infection. In the pulpectomy for primary teeth the canals must be obturated with a resorbable paste such as zinc-oxide-eugenol, calcium hydroxide, or an iodoform containing preparation to facilitate the normal exfoliation process. However, the clinician must be cognizant of the possibility of pigmented root canal preparations causing discolouration of the crown. After pulpectomy, full coverage of the crown is indicated to ensure durability of the tooth.

Sadly, no long-term controlled studies on large numbers of teeth have been conducted to evaluate the prognosis of crown fractures in the primary dentition.

### **3.2.5 Crown-root fractures (complicated and uncomplicated)**

Crown-root fractures of primary teeth which are relatively rare are, in the anterior region, usually caused by direct trauma. In the posterior regions, fractures of the buccal or lingual cusps may occur. These fractures frequently extend below the gingival margin.

Displacement of the coronal fragment is often minimal because of the tight gingival collar of the primary tooth, which accounts for why these fractures are frequently overlooked, particularly in the posterior regions (Wilson 1995). Although the fracture line is usually single, multiple fractures can occur (Andreasen 1981).

Crown-root fractures in primary teeth may cause few symptoms; nevertheless, treatment should be administered as soon as possible. The rationale is the same as for crown fractures (Wilson 1995). The extent of the fracture can be determined by removing the coronal portion of the tooth; the site should be assessed for evidence of pulpal exposure (Figure 9). If the fracture does not extend too far below the gingiva, pulp therapy can be performed (Figure 10), protection against bacterial leakage achieved, and the tooth adequately restored; provided the child's cooperation permits this form of therapy (Wilson 1995, Dummett 2000).

However, complicated crown-root fractures are often so extensive that the teeth are not restorable so extraction is the treatment of choice. Any remaining apical portion of the root can be left to resorb naturally (Andreasen and Andreasen 1992, Josell 1995). A blow that is of a great enough magnitude to cause a crown-root fracture usually produces a luxation injury as well, which further compromise the success of the pulp therapy (Dummett 2000).

### **3.2.6 Root fractures**

Root fractures are relatively uncommon among traumatized primary teeth. They occasionally escape radiographic detection immediately after the injury, while radiographs taken later may clearly reveal the fracture. This is due to the development of either a haematoma or granulation tissue between the fragments, which displaces the coronal fragment incisally, or it may be due to resorption at the fracture line that is part of the healing process (Andreasen and Andreasen 1994). In addition, the primary dentition presents special radiographic problems because of

superimposition of the permanent teeth which impedes detection of a fracture near to the apex. Root fracture occurs most often in the apical or middle third of the root and only rarely in the coronal one third (Andreasen 1981).

Primary teeth with root fractures but without dislocation and excessive mobility may be preserved and normal exfoliation can be anticipated (Figure 11). Consequently, these cases can be treated conservatively (Wilson 1995, Dummett 2000). Splinting is usually difficult, if not impossible, to perform in the primary dentition because of the diminutive size of the teeth and the lack of patient cooperation (Wilson 1995, Mackie and Blinkhorn 1996). In addition, the value of this procedure has not been clearly demonstrated. Healing has to be encouraged in spite of mobility at the fracture line, this usually results in the interposition of connective tissue (Andreasen and Andreasen 1994). Primary teeth with mobility and severe dislocation of the crown fragment should, as a principle be extracted because pulp necrosis is likely to develop (Wilson 1995). If rapid root resorption is observed at the fracture site, remove of only the coronal portion or, root canal therapy of only the coronal portion is all that is necessary (Figure 12). Some authors have advised that in order to avoid trauma to the permanent tooth germs, no effort should be made to remove the apical fragment, because normal physiological resorption can be anticipated (Andreasen and Andreasen 1990, Mackie and Blinkhorn 1996, Dummett 2000, Tsukiboshi 2000). This is especially true in cases where the fracture is in the apical one third of the root. The residual small segment may be left to resorb as part of the normal exfoliation process (Dummett 2000).

Root fractures in the primary dentition should have a similar prognosis to those in

the permanent dentition unless complicating underlying conditions exist. In some instances, pulpal infection occurs in the coronal segment of the tooth, even then only the coronal fragment needs to be extracted; the apical fragment can be left to resorb physiologically (Wilson 1995, Mackie and Blinkhorn 1996).

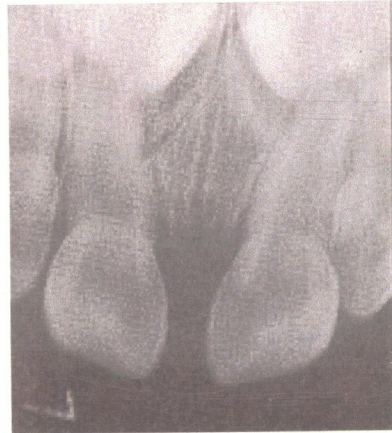
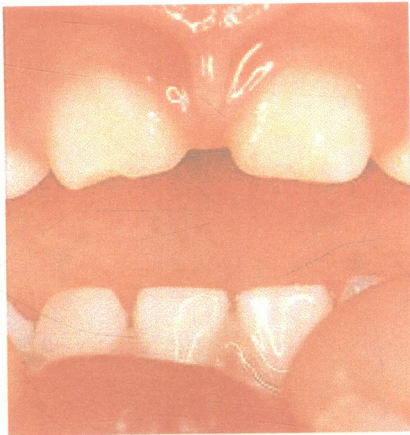


Figure 1a Initial examination, 2-year 2-month-old girl. Chief complaint is: concussion of anterior teeth. Neither discoloration nor obliteration is observed.

(Tsukiboshi 2000)

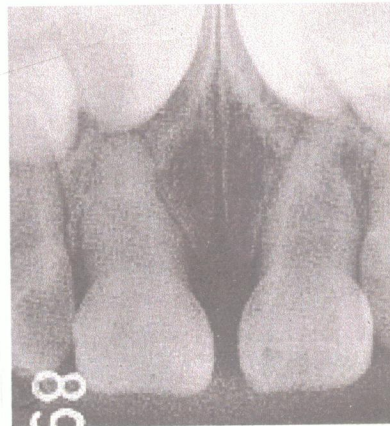
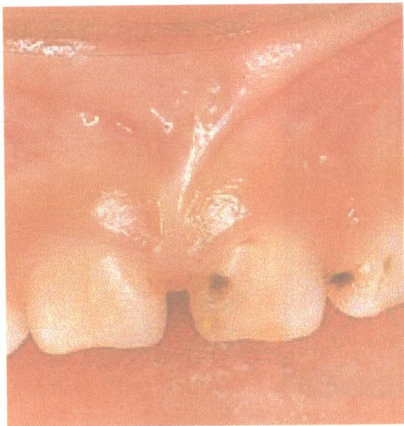


Figure 1b Two years and three months later. Note discoloration of the crown of 61 and a small facial abscess. Obliteration of the pulp cavity is not observed in this tooth but can be seen in the adjacent tooth which is not discoloured.

(Tsukiboshi 2000)

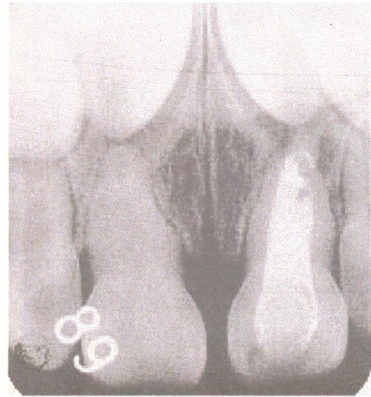
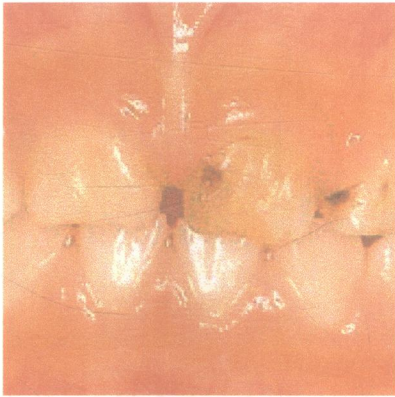


Figure 1c Two years and ten months later. Seven months after endodontic treatment of 61.

(Tsukiboshi 2000)

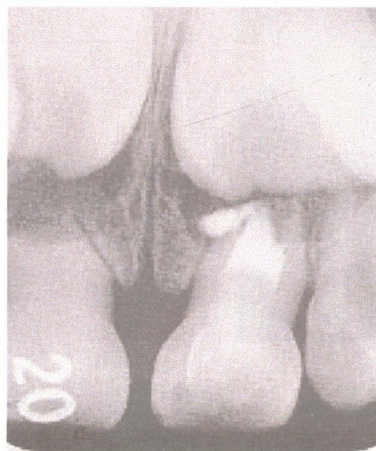


Figure 1d Four years later, immediately after retreatment of 61. A delay is expected in the root resorption of the tooth.

(Tsukiboshi 2000)



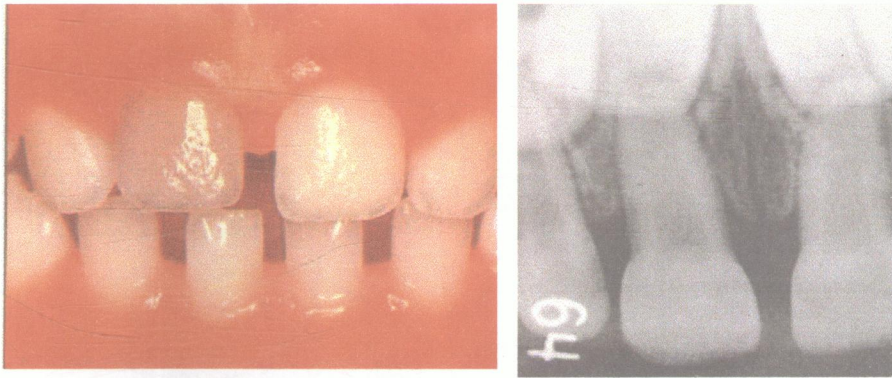


Figure 2a Initial examination, 4-year-old-girl. Chief complaint: discolouration of tooth 51. Subluxation 1 to 2 months earlier is suspected.

(Tsukiboshi 2000)

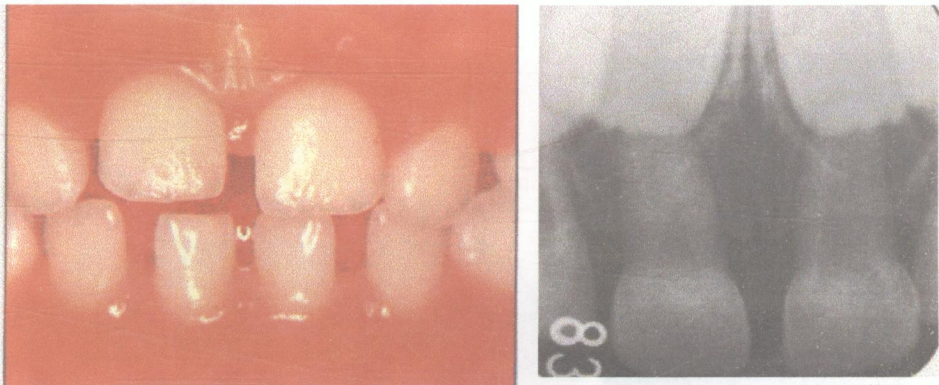


Figure 2b Six months later. No discolouration of 51. Also note pulp obliteration. Treatment is unnecessary.

(Tsukiboshi 2000)



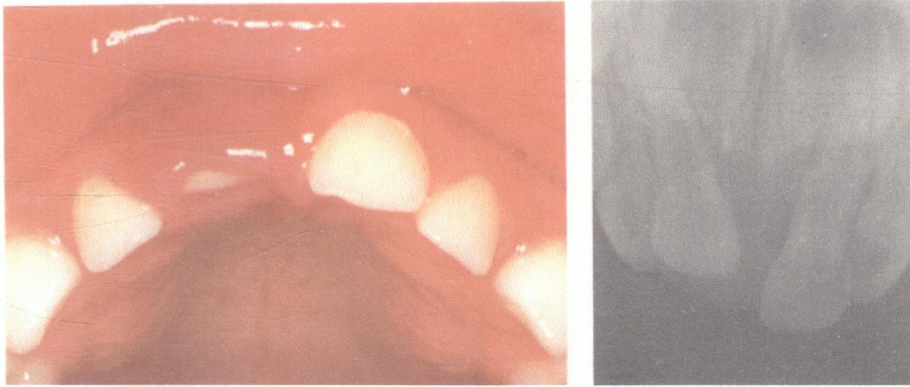


Figure 3a This 2-year-old boy suffered an intrusion of 51. The foreshortened appearance of the intruded tooth implies labial displacement. Spontaneous re-eruption is therefore anticipated.

(Andreasen and Andreasen 1992)

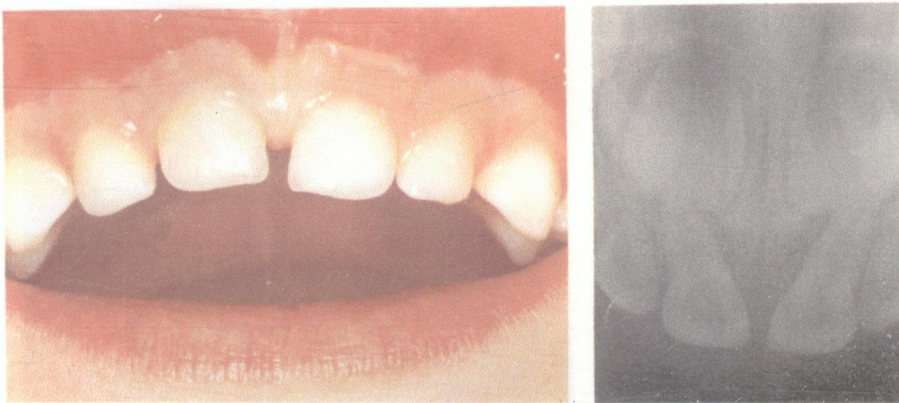


Figure 3b Follow-up 1 year after injury. The tooth is in normal position. Crown colour is normal and the radiograph shows no sign of pathology.

(Andreasen and Andreasen 1992)

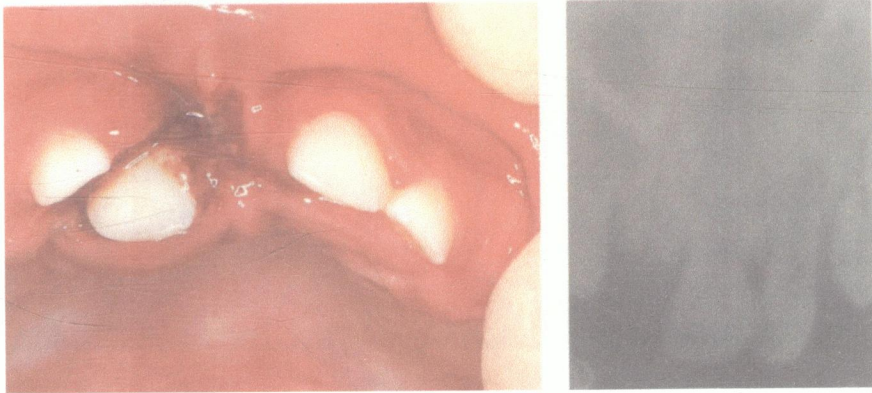


Figure 4a This 1-year-old boy received an axial impact, resulting in the intrusion of 51. Note the displacement of the permanent tooth germ in the follicle. Removal of the primary incisor is mandatory.

(Andreasen and Andreasen 1992)

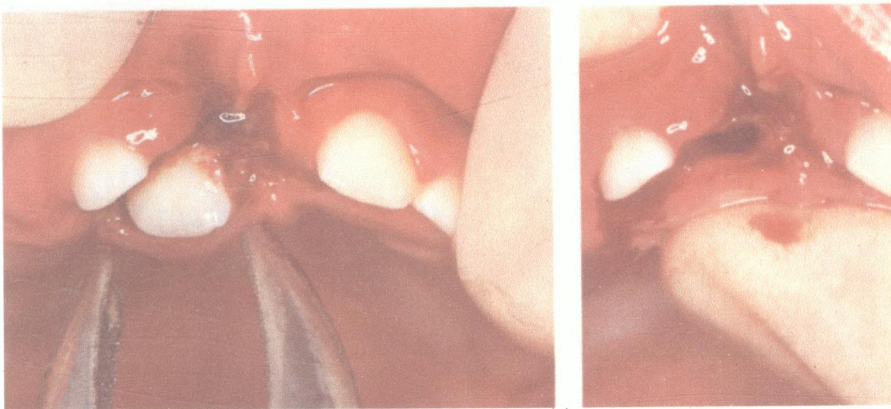


Figure 4b Removing the displaced tooth. Using sedation and topical anesthesia, the tooth is grasped proximally with forceps and removed in a labial direction. The fractured and displaced palatal bone is repositioned with digital pressure and a suture placed to close the entrance to the socket.

(Andreasen and Andreasen 1992)

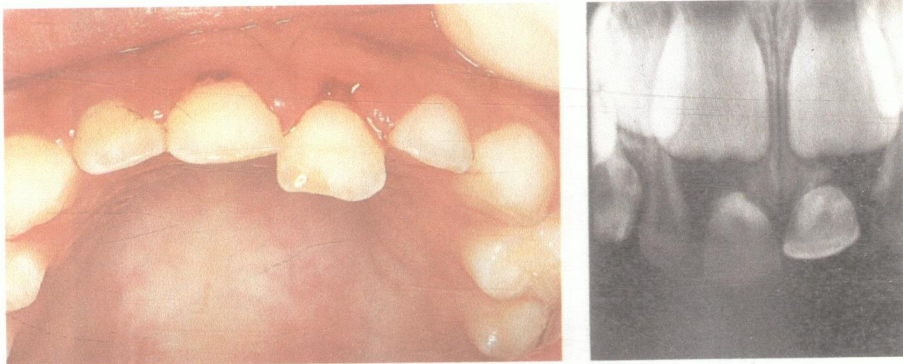


Figure 5a This 4-year-old boy suffered a lateral luxated of the left maxillary primary central incisor. Repositioning is indicated due to occlusal interference.  
(Andreasen and Andreasen 1994)

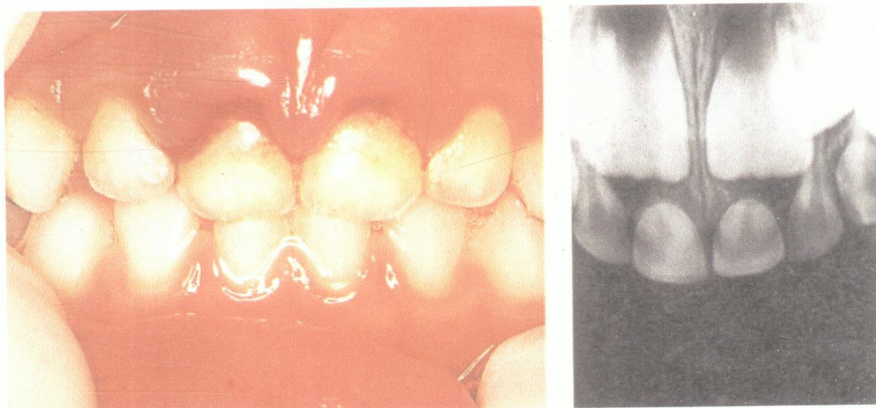


Figure 5b Post-operative condition. The tooth has been adequately repositioned, as revealed both clinically and radiographically.  
(Andreasen and Andreasen 1994)



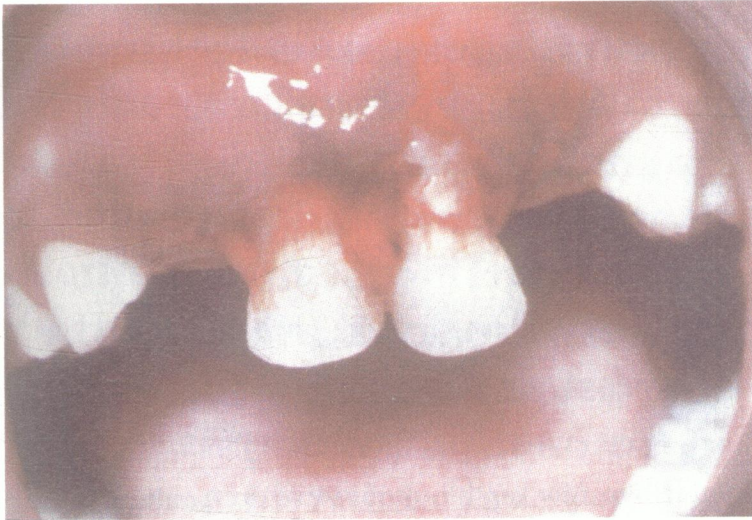

Figure 6 Extrusion of maxillary primary central incisors. These teeth should be extracted.

(Dummett 2000)

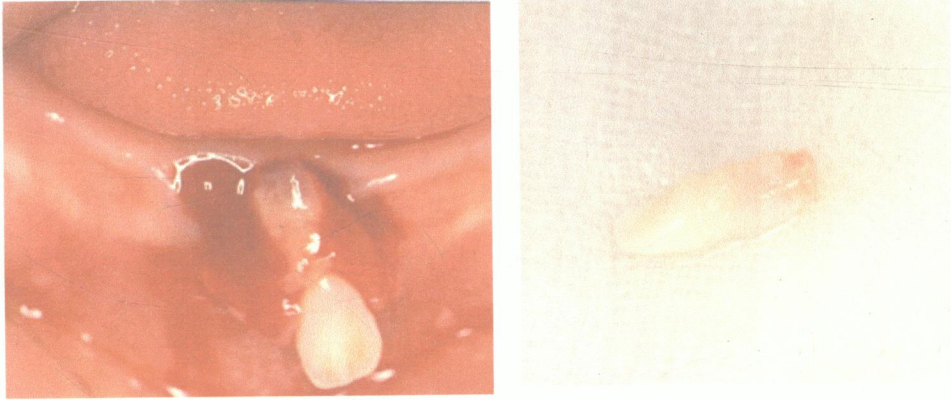


Figure 7a Initial examination of 9-month-old girl with avulsion of 71 and 81.  
(Tsukiboshi 2000)

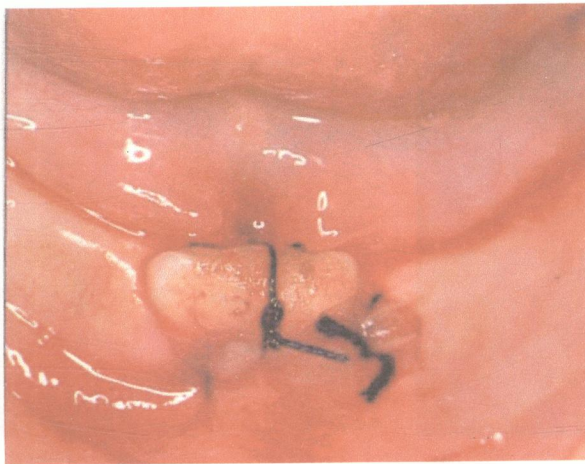


Figure 7b Immediately after reimplantation. A composite resin was used to splint both teeth, and the lacerated gingival tissues were sutured.  
(Tsukiboshi 2000)

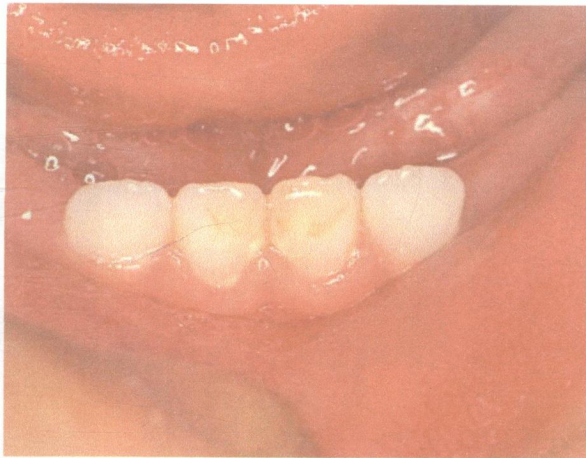


Figure 7c Four months later.

(Tsukiboshi 2000)

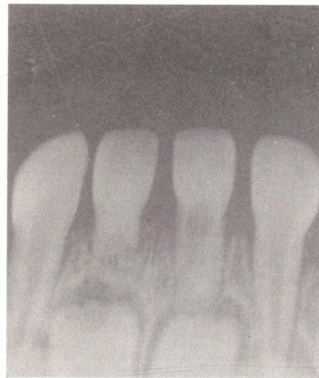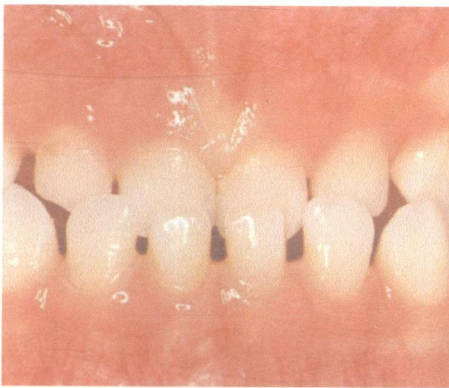


Figure 7d Two years and three months later.

(Tsukiboshi 2000)

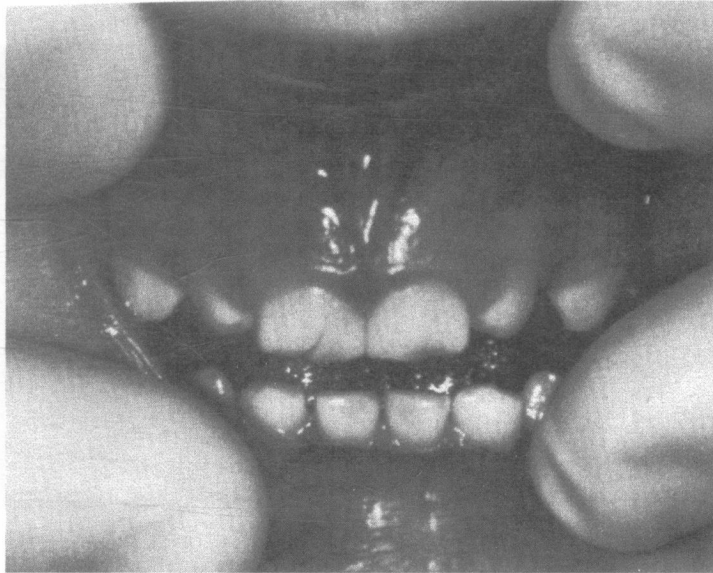


Figure 8 Primary central incisor that suffered a crown fracture in addition to lingual lateral luxation. The luxation injury interfered with occlusion and compromised the pulp. Extraction was deemed to be the treatment of choice. (Wilson 1995)

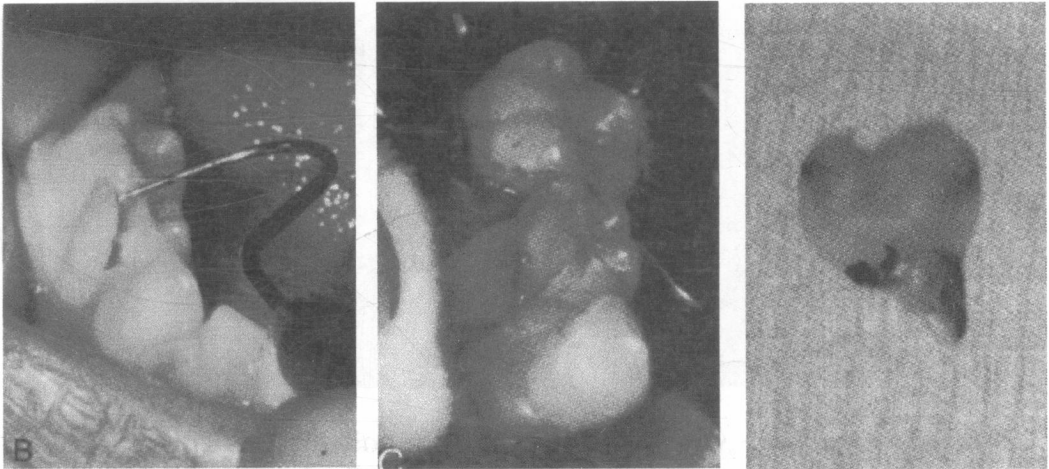


Figure 9a A 5-year-old girl fell from a shopping cart, hitting her chin on the floor. Clinically, she suffered pain when biting in occlusion. Further examination revealed a crown-root fracture of the mandibular first primary molar as a result of indirect trauma. The fragment was removed without pulp exposure.

(Wilson 1995)

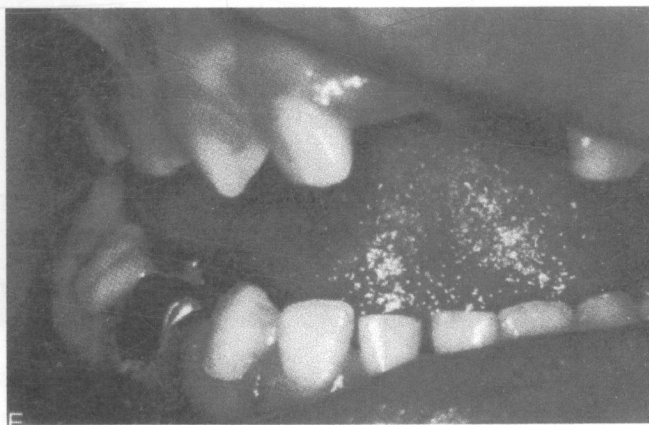


Figure 9b Stainless steel crown was placed to preserve the function of this tooth and for space maintenance.

(Wilson 1995)



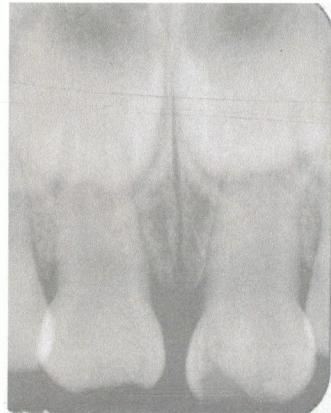
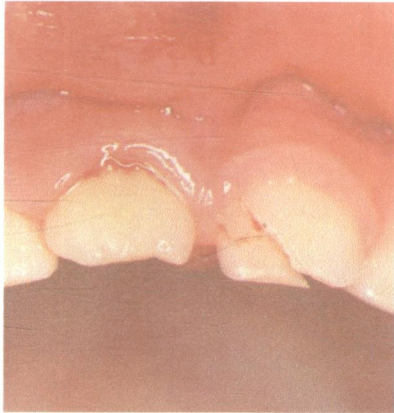


Figure 10a Initial examination, 2-year 7-month-old boy. Crown-root fracture with pulp exposure can be seen on 61.

(Tsukiboshi 2000)

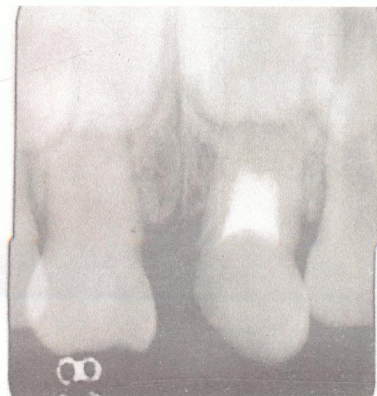
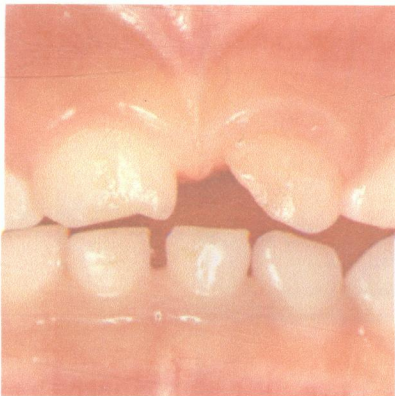
Figure 10b Four months after root canal treatment is performed. Calcium hydroxide was used for root canal filling.

(Tsukiboshi 2000)

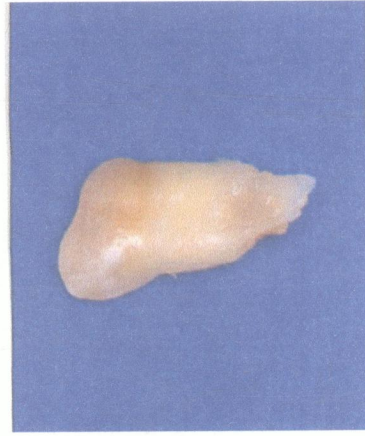
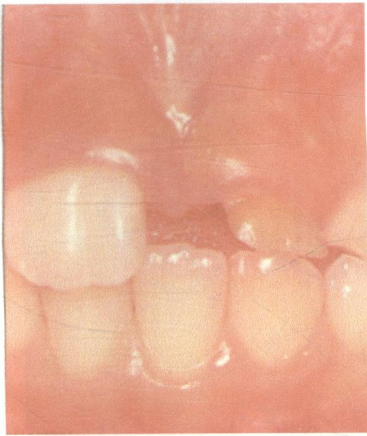
Figure 10c After 5 years and 7 months. Note the incomplete root resorption of the tooth and it was extracted that day.

(Tsukiboshi 2000)

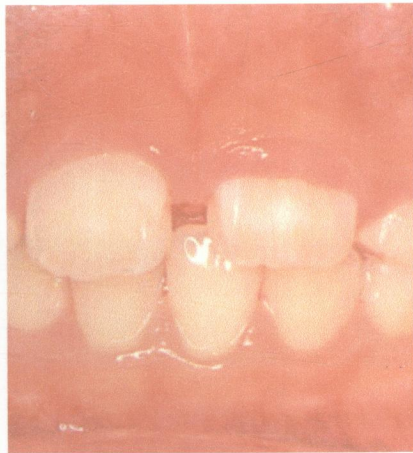


Figure 10d Three months after extraction of 61. 21 is erupting and soon will be positioned similar to 11.

(Tsukiboshi 2000)

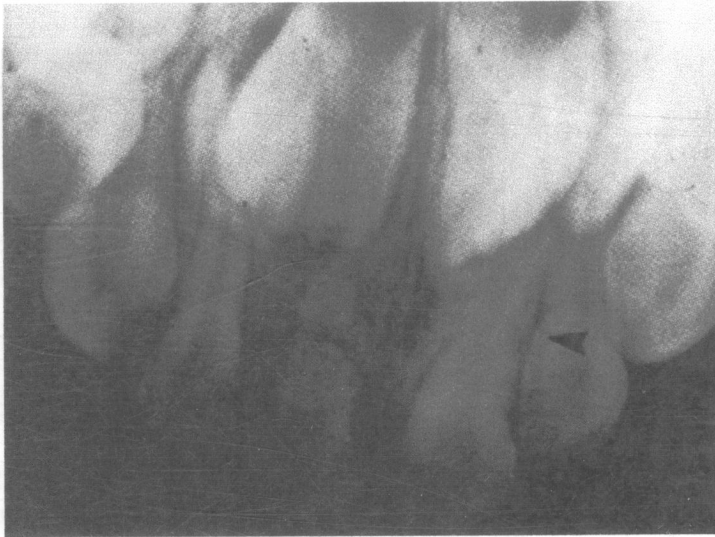

Figure 11 Recent mid root fracture is noted on 51, and 61 shows evidence of healing of a previous root fracture (arrow).

(Wilson 1995)

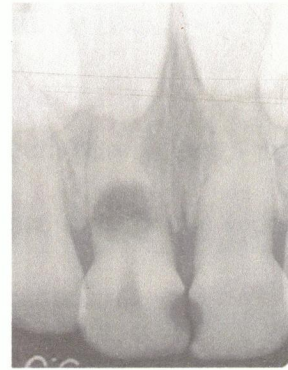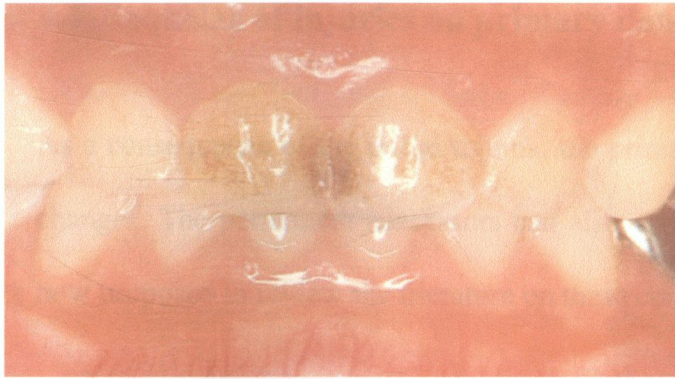


Figure 12a Initial examination, 5-year 4-month-old girl. Chief complaint: gingival abscess labial to 51 caused by root fracture.

(Tsukibishi 2000)

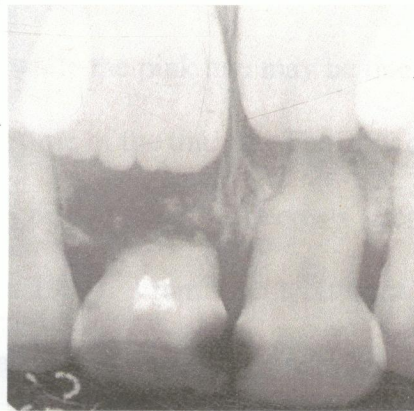

Figure 12b One year after endodontic treatment of the coronal segment with calcium hydroxide was performed. The apical fragment of the tooth has been resorbed.

(Tsukiboshi 2000)

---

---

## 4.0 Sequelae of Injuries

---

---

### 4.1 Sequelae of injuries on primary dentition

As a consequence of the initial trauma, the primary teeth may undergo unfavorable changes. The permanent successors can also experience undesirable sequelae. It is now proposed to review the literature on these complications.

Discoloration has been reported as frequently following trauma to primary teeth (Soxman et al. 1984, Mackie and Blinkhorn 1996, Tsukiboshi 2000). The results of Fried and co-workers (1998) suggested an increase in the amount of tooth discoloration over time. Discoloration can range from yellow or pink to grey or black (Bennett 1964). The yellowish hue is thought to be due to partial obliteration of the pulp chamber; while the pink hue may be due to blood pigments entering the dentinal tubules at the time of the trauma. The grey or black discoloration of a tooth is generally thought to be due to pulpal necrosis (Bennett 1964, Soxman et al. 1984, Mackie and Blinkhorn 1996). From the literature it appears that there are differing opinions as to the treatment of discolored teeth. Several authors have suggested that grey and/or black discoloured teeth are a source of infection and should therefore be extracted (Soxman et al. 1984, Bennett 1964). While Jacobsen and Sangnes (1978) have found that some grey teeth eventually turned yellow, indicating that the pulp space has become obliterated. However, the discoloration of primary teeth has also been shown to be associated with various irreversible pulp changes (Soxman et al. 1984). For example, periapical osteitis was found in 82% of grey teeth within one

month of trauma (Ellis and Davey 1960). As a consequence of these differing opinions, discoloration of the tooth should be used as an adjunct to the diagnosis, but not the sole criterion in determining the need for extraction. Interestingly, it has been reported that 72% of discolored primary teeth failed to develop any radiographic and/or clinical evidence of pathology (Sonis 1987).

Calcific metamorphosis and internal root resorption are said to be common sequelae of traumatic injury in the primary dentition (Peterson et al. 1985); yet the treatment of these conditions varies from one extreme to another. Calcific metamorphosis is not actively treated by most practitioners, since the teeth usually exfoliate normally. While extraction or pulp therapy are the recommended treatment alternatives for primary teeth with internal resorption, because such changes are usually irreversible, and may contribute to development defects of the underlying permanent tooth (McDonald and Avery 1978), there are no recent studies to convincingly support the latter opinion, so it should be interpreted with caution.

The calcific metamorphosis is demonstrated by a large calcific mass, which has numerous cell lacunae, most of which are empty. Braham and Morris (1980) and Stafne (1969) considered this manifestation to be relatively benign, and not to normally affect the viability of the tooth; nor has it frequently been shown to occur with, or to precipitate unfavorable pulpal conditions. Nevertheless, regular observation of primary teeth undergoing calcific metamorphosis is important because simultaneous resorptive activities have also been shown to occur (Peterson et al. 1985).

In addition, inflammatory root resorption is also known to be one of the sequelae of various types of injury. Kenwood and Seow (1989) in a studies of 69 teeth found that 7.2% displayed evidence of external root resorption, while only 1.5% suffered internal root resorption.

Although there are potentially a lot of possible consequences following trauma, very few parents appear to be concerned with them. According to Garcia-Godoy and his co-workers (1989), the reason for parents seeking dental treatment after trauma varied according to the type of injury. Most parents sought help for their child because of their reaction to the clinical condition, or to the subsequent change in the tooth; such as an abscess. As a consequence it has been suggested that an awareness program should be developed to encourage parents to seek treatment immediately after trauma to a primary tooth rather than waiting for the manifestation of the consequences (Garcia-Godoy 1989).

#### **4.2 Sequelae of injuries on permanent dentition**

The close relationship between the apices of primary teeth and the developing permanent successors explains why injuries to primary teeth are easily transmitted to the permanent dentition. The extent and nature of the malformation in the permanent teeth as a result of disturbances in odontogenesis may vary according to the time, site and extent of the initial trauma.

According to the studies of Ravn (1968) and Andreasen and Ravn (1971); disturbances in the permanent dentition appear to be related to the type of injury



sustained. The low frequency of disturbances found after subluxation and extrusive luxation injuries indicates that the impact causes only a minor disturbance to the thin soft tissue, or hard tissue barrier between the primary tooth and its permanent successor. By contrast, in cases of intrusion when the alveolar socket is fractured or crushed the chance of a direct transfer of injury to the developing permanent tooth is more likely.

There is a direct relationship between the age of the child at the time of the injury and evidence of disturbances in the permanent dentition. This relationship possibly indicates that the developing permanent tooth germ is especially sensitive to injuries during its early developmental stages. Andreasen and Ravn (1971) found that disturbances to the permanent teeth appeared to be less frequent in cases where the traumatic injury occurred at an age of more than 4 years (24-25%) compared to younger age groups such as 0 to 2 years and 3 to 4 years, where the disturbances occurred in 63% and 53% of the children respectively.

When the stage of development of the permanent tooth at the time of injury is considered instead of the age, the following relation to disturbances in the permanent dentition appears. Enamel discolorations occurs in the early stages of both crown and root formation, whereas enamel discoloration, associated with the circular type of enamel hypoplasia, is only found among teeth injured during crown formation.

Morphologic examination of the available material reveals that the injuries to the permanent teeth can, according to Andreasen and Ravn (1971), be grouped in the following manner:



### **4.2.1 Discoloration**

This may manifest as a white discoloration of the enamel; or as a white and yellow-brown or yellow-brown discoloration of enamel. These defects appear as sharply demarcated colour changes, most often located on the vestibular surface of crown. Their extent varies from tiny spots to large areas while the enamel surface is usually intact.

### **4.2.2 White or yellow-brown discoloration and horizontal enamel hypoplasia**

The typical finding in this group is a narrow horizontal indentation, which encircles the crown cervical to the discoloured areas. This type of discolorations usually occurs without the presence of a localized defect in the surface layer of the enamel.

### **4.2.3 Crown dilaceration**

This type of malformation is usually confined to the central incisors. Pulpal necrosis may develop after a tooth with a crown-dilaceration erupts (Castaldi 1959).

The acute deviation of the crown portion is usually buccally among affected maxillary incisors while the opposite deviation is mainly found in the mandible. Exceptions to this rule are cases where less than a quarter of the crown has formed at the time of the traumatic impact (Andreasen 1981).

#### **4.2.4 Odontome-like malformation**

These malformations are confined to the incisor region especially in the maxilla. Most often this type of malformation shows a conglomeration of hard tissue having the morphology of a complex odontome (Andreasen 1981).

#### **4.2.5 Root duplication (bifid root)**

Radiographically, the duplication of the root is seen as a division of the root into a mesial and a distal portion (Andreasen 1981).

#### **4.2.6 Vestibular root angulation**

These lesions appear as a marked curvature confined to the root portion of the tooth. Affected teeth are usually impacted (Andreasen 1981).

#### **4.2.7 Lateral root angulation or dilaceration**

These lesions appear as mesial or distal bending of the root portion of the tooth. The bending of the root appears to be slightly more apically positioned than in the group with vestibular angulation, and all the teeth are found to be fully erupted (Andreasen 1981).

#### **4.2.8 Partial or complete arrest of root formation**

Usually, these malformed teeth erupt into a normal position in the dental arch. Avulsion is usually the injury that has affected the tooth in the primary dentition (Andreasen 1981).

#### **4.2.9 Sequestration of permanent tooth germ**

This is an exceedingly rare sequelae of traumatic injuries to the primary dentition (Broglia and Dana 1967, Aleyt 1969). The sequestration takes a protracted course and could be regarded as a manifestation of precocious eruption of a developed tooth germ prior to adequate root formation.

#### **4.2.10 Ectopic, premature or delayed eruption or impaction**

These manifestations can be considered to be a secondary clinical finding associated with any of the other types of complication that have previously been described (Andreasen and Ravn 1971).

Ectopic eruption and an abnormal final position of the permanent incisors in the arch of permanent teeth are other possible outcomes which can follow traumatic injuries to their predecessors (Korf 1965, Hawes 1966, Brin et al. 1988). This can be explained by the physical displacement of the permanent germ at the time of the injury. Another possible explanation is the lack of eruption guidance from the

prematurely lost primary incisor, so leading to eruption of the permanent incisor in labial or lingual version.

When "watchful waiting" is selected as the means to manage an intrusion injury in the primary dentition, the intruded incisor may become ankylosed, or exhibit delayed root resorption. This can lead to retention of the primary incisor and disruption of the eruption pathway of the permanent successor (Ravn 1968, Brown et al. 1985).

The potential for these possible sequelae needs to be explained to parents of injured children so that, in the future, they are prepared for them, should they occur, in their child.

---

---

## 5.0 Conclusions

---

---

Following a review of the available literature it appears that the rationales for the treatment of most of the injuries sustained by the primary teeth as the consequences of trauma, are based upon case reports rather than well controlled longitudinal research data, or the long term review of sequential patients. Whilst this information is helpful when making a diagnosis and formulating a treatment plan, the weakness in the quality of these data must be realised.

The available research data indicates that no active treatment should be provided for concussed and subluxated teeth unless a tooth is excessively mobile (Mackie and Warren 1988, Andreasen and Andreasen 1994, Mackie and Blinkhorn 1996, Tsukiboshi 2000). However, parents should be informed about the long term consequences of injuries on the primary teeth which can be a greyish brown discoloration of the crown, pulp obliteration, or abscess formation; and the importance of monitoring on a regular basis. Nevertheless, if the tooth exhibits excessive mobility then short-term splinting, for seven to ten days, or extraction should be considered in relation to the child's behavior and any potential risk of the teeth being inhaled or aspirated (Fried et al. 1996).

Many authorities, including Ravn (1968), Andreasen and Ravn (1973), Andreasen and Andreasen (1994), Wilson (2000), and Dummett (2000) have suggested a "wait and see" policy for intruded and laterally luxated primary teeth which are not displaced in a direction toward the underlying successor, in the expectation that

there will be spontaneous eruption or correction of the tooth. However, if there is not some movement of an intruded tooth within a 4 week period after an injury, or if it is displaced and considered to encroach on the developing permanent tooth bud, removal of the displaced tooth is, according to Wilson (1995), essential. In addition, Wilson (1995) and Tsukiboshi (2000) have suggested the reposition of the luxated tooth with the use of gentle finger pressure if an interference does exist.

According to Josell (1995), Wilson (1995), and Dummett (2000) an extruded primary tooth which is only slightly displaced from the socket yet not excessively mobile, can usually be repositioned. Whilst the tooth which is extremely mobile with incisal displacement of more than 2mm should be extracted to avoid the potential of chronic peri-radicular infection.

The predominant opinion for the treatment of an avulsed primary tooth is that the tooth should not be reimplanted due to the risk of chronic infection and subsequent dystrophic changes to the developing tooth (Andreasen and Andreasen 1994, Wilson 1995, Josell 1995, Mackie and Blinkhorn 1996). Nevertheless, the success rate for the reimplantation of avulsed primary incisors after short periods of time have been reported by some investigators (Eisenberg 1965, Ravn 1968, Weiger and Heuchert 1999). However, it is prudent to have more data from large controlled studies to confirm the successful outcomes of reimplanting avulsed primary teeth before this technique can be recommended for avulsed primary teeth.

Although enamel infractions may not require initial therapy the teeth still need to be periodically evaluated for possible adverse sequelae (Jacobsen 1981, Josell 1995).

The best management for a fracture of enamel of a primary tooth is smoothing of the sharp margins of the fracture area to prevent any irritation to the tongue or other soft tissues (Dummett 2000).

For a crown fracture and a crown-root fracture; the extent of the fracture and evidence of pulp exposure have to be determined. If the pulp is not exposed, sealing of the exposed dentinal tubules with either a glass ionomer, or a dentin-bonding agent in conjunction with a composite resin restoration, or a stainless steel crown with an open-faced composite resin window is recommended. However, the level of the child's cooperation and the possibility of limited moisture control need to be taken into consideration (Jacobsen 1981, Wilson 1995, Dummett 2000). If a pulp exposure is present, or the child is uncooperative, the treatment of choice is extraction (Mackie and Blinkhorn 1996). Nevertheless, Kopel (1992) recommended the placement of a calcium hydroxide dressing over an exposure site of less than 1.0mm.

The partial pulpotomy for primary incisors which have sustained a complicated coronal fracture has been reported to produce at least short term success (Cvek 1978, Zilberman et al. 1989, Ravn and Holan 1994). Furthermore, Mathewson and Primosch (1995) have indicated high success rates for the treatment of exposed primary pulps treated by pulpotomies. In instances when the exposed pulp has been contaminated due to extensive crown loss, or a time delay of greater than 24 hours, complete pulpectomy or extraction may well be the treatment of choice (Josell 1995).

Primary tooth with a root fracture, but without dislocation and excessive mobility of the coronal portion, may be preserved and treated conservatively (Wilson 1995, Dummett 2000). While those with excessive mobility and severe dislocation of a crown fragment should be extracted to avoid the development of pulp necrosis (Wilson 1995). However, many authors support the notion not to remove the apical fragment, because normal physiologic resorption can be expected to gradually dispose of the root fragment (Andreasen and Andreasen 1990, Mackie and Blinkhorn 1996, Dummett 2000, Tsukiboshi 2000).

When managing traumatic injuries to the primary teeth, no matter how convincing the epidemiologic data, the clinician must be conscious of the ability of the child to cooperate in order that the apparently optimal treatment can be performed successfully. Furthermore, no matter what the nature of the injury, it is prudent for a regimen of regular long term reviews to be implemented for all children who have experienced trauma to their primary teeth.



---

---

## 6.0 References

---

---

Andreasen F.M., Daugaard-Jensen J.

Treatment of traumatic dental injuries in children

Current Opinion in Dentistry 1991; 1: 535-546.

Andreasen F.M., Pedersen B.V.

Prognosis of luxated permanent teeth- the development of pulp necrosis

Endodontic and Dental Traumatology 1985; 1: 207-220.

Andreasen J.O.

Etiology and pathogenesis of traumatic dental injuries. A clinical study of 1,298 cases

Scandinavian Journal of Dental Reserch 1970; 78: 329-342.

Andreasen J.O.

Traumatic Injuries of the teeth

Copenhagen, Munksgaard, 2<sup>nd</sup> edition 1981.

Andreasen J.O., Andreasen F.M.

Essentials of traumatic injuries to teeth

Copenhagen, Munksgaard 1992.

Andreasen J.O., Andreasen F.M.

Textbook and color atlas of traumatic injuries to the teeth

Copenhagen, Munksgaard, 3<sup>rd</sup> edition 1994.

Andreasen J.O., Ravn J.J.

The effect of traumatic injuries to primary teeth on their permanent successors.

II. A clinical and radiographic follow-up study of 213 teeth

Scandinavian Journal of Dental Research 1971; 79: 284-294.

Andreasen J.O., Ravn J.J.

Epidemiology of traumatic dental injuries to primary and permanent teeth in a

Danish population sample

International Journal of Oral Surgery 1972; 1: 235-239.

Andreasen J.O., Sundstrom B., Ravn J.J.

The effect of traumatic injuries to primary teeth on their permanent successors

A clinical and histologic study of 117 injured permanent teeth

Scandinavian Journal of Dental Research 1971; 79: 219-283.

Bennett D.

Traumatized anterior teeth

British Dental Journal 1964; 116: 52-55.

Bhat M., Li S-H.

Consumer product-related tooth injuries treated in hospital emergency room:

United States, 1979-87

Community Dentistry and Oral Epidemiology 1990; 18: 133-138.

Bijella M.F., Yared F.N., Bijella V.T., Lopes E.S.

Accurrence of primary incisor traumatism in Brazilian children a house-to-house survey

Journal of Dentistry for Children 1990; 57: 424-427.

Borssen E., Holm A-K.

Traumatic dental injuries in a cohort of 16-year-olds in Northern Sweden

Endodontics and Dental Traumatology 1997; 13: 276-280.

Borum M.K., Andreasen J.O.

Sequelae of trauma to primary maxillary incisors, I. Complications in the primary dentition

Endodontics and Dental Traumatology 1998; 14: 31-44.

Braham R.L., Morris M.E.

Textbook of Pediatric Dentistry

Baltimore, Williams & Wilkins Company 1980: 273.

Brin I, Bassat B.Y., Zilberman Y., Fuks A.

Effect of trauma to the primary incisors on the alignment of their permanent successors in Israelis

Community Dentistry and Oral Epidemiology 1988; 16: 104-198.

Broglia M.L., Dana F.

Manifestazioni cliniche delle lesioni traumatiche accidentali della dentatura deciduas

Minerva Stomatology 1967; 16: 623-635.

Brown DA, Kodama R., Yacobi R, Lee J., Chiang S.

Intrusive luxation: Diagnosis, complications and treatment

Ontario Dentist 1985; 62:12-18.

Castaldi C.R.

Traumatic injury to unerupted incisors following a blow to the primary teeth

Journal of Canadian Dental Association 1959; 25: 752-762.

Cvek M.

A clinical report a partial pulpotomy and capping with calcium hydroxide in permanent incisors with complicated crown fracture

Journal of Endodontics 1978; 4: 232-237.

Davis M.J.

Management of traumatic dental injuries in children

New York State Dental Journal 1988; 54: 22-24.

Davis G.R., Domoto P.K., Levy R.L.

The dentist's role in child abuse and neglect: Issues, identification and management

Journal of Dentistry for Children 1979; 46: 185-192.

DeVore D.T.

Legal considerations of treatment following trauma to teeth

The Dental Clinics of North America 1995; 39: 203-219.

Dummett C.O.

Dental Management of Traumatic injuries to the primary dentition

Journal of the California Dental Association 2000; 28: 338-845.

Eisenberg M.

Reimplantation of a deciduous tooth

Oral Surgery 1965; 19: 588-590.

Ellis R., Davey K.

The classification and treatment of Injuries to the Teeth of Children

4<sup>th</sup> edition Ellis RG, Chicago: Year Book Publishers, Inc 1960.

Ferguson F., Ripa L.W.

Prevalence and type of traumatic injuries to the anterior teeth of preschool children

Journal of Pedodontics 1979; 4: 3-8.

Filippi A., Pohl Y., Kirschner H.

Replantation of avulsed primary anterior teeth: Treatment and limitations

Journal of Dentistry for Children 1997: 272-275.

Fried I., Erickson P., Schwartz S., Keenam K.

Subluxation injuries of maxillary primary anterior teeth: epidemiology and prognosis of 207 traumatized teeth

American Academy of Pediatric Dentistry 1996; 18: 145-151.

Forsberg C.M., Tedestam G.

Traumatic injuries to teeth in Swedish Children living in an urban area

Swedish Dental Journal 1990; 3: 115-122.

Garcia-Godoy F.

A classification for traumatic injuries to primary and permanent teeth

Journal of Pedodontics 1981; 5: 295-297.

Garcia-Godoy F., Garcia-Godoy F, Garcia-Godoy F.M.

Primary teeth traumatic injuries at a private pediatric dental center

Endodontics and Dental Traumatology 1987; 3: 126-129.

Garcia-Godoy F., Garcia-Godoy F., Garcia-Godoy F.M.

Reasons for seeking treatment after traumatic dental injuries

Endodontics and Dental Traumatology 1989; 5: 180-181.

Garcia-Godoy F., Garcia-Godoy F., Olivo M.

Injuries to primary and permanent teeth treated in private paedodontic practice

Journal of Canadian Dental Association 1979; 45: 281-284.

Garcia-Godoy F., Morban-Lauder F., Corominas L.R., Franjul R.A., Noyola M.

Traumatic dental injuries in preschool children from Santo Domingo

Community Dentistry and Oral Epidemiology 1983; 11: 127-130.

Glendor U., Halling A., Andersson L., Eilert-Petersson E.

Incidence of traumatic tooth injuries in children and adolescents in the country  
of Vastmanland, Sweden

Swedish Dental Journal 1996; 20: 15-27.

Graitcer P.L

Beyond mouthguards: An overview of injury preventions and control

Dental Hygienist News 1994; 7: 21-22.

Gutmann J.L, Gutmann M.S.E.

Cause, Incidence, and Prevention of trauma to teeth

Dental Clinics of North America 1995; 39: 1-13.

Hargreaves J.A.

Emergency treatment for injuries to anterior teeth

International Dental Journal 1974; 24: 18-29.

Hargreaves J.A., Cleaton-Jones P.E., Roberts G.J., Williams S., Matejka J.M.

Trauma to primary teeth of South African pre-school children

Endodontics and Dental Traumatology 1999; 15: 73-76.

Hawes R.

Traumatized primary teeth

Dental Clinics of North America 1966; 10: 391-404.

Hayrimen-Immonen R., Sane J., Perkki K., Malmstrom M.

A six year follow-up study of sports-related dental injuries in children and adolescents

Endodontics and Dental Traumatology 1990; 6: 208-212.

Hill F.J., Picton J.F.

Fractured incisor fragment in the tongue: A case report

Pediatric Dentistry 1981; 3: 337.

Holan G., Ram D.

Aspiration of an avulsed primary incisor. A case report.

International Journal of Paediatric Dentistry 2000; 10: 150-152.



Holm A-K

Oral health in 4-year-old Swedish children

Community Dentistry and Oral Epidemiology 1975; 3: 25-33.

Jacobsen I.

Clinical problems in the mixed dentition: traumatized teeth-evaluation, treatment and prognosis

International Dental Journal 1981; 31: 99-104.

Jacobsen I., Sangnes G.

Traumatized primary anterior teeth. Prognosis related to calcific reactions in the pulp cavity

Acta Odontologica Scandinavica 1978; 36: 199-204.

Johnson J.E.

Causes of accidental injuries to the teeth and jaws

Journal of Public Health Dentistry 1975; 35: 123-131.

Johnson R.

Descriptive classification of traumatic injuries to the teeth and supporting structures

Journal of American Dental Association 1981; 102: 195-197.

Josell S.D.

Evaluation, Diagnosis, and Treatment of the traumatized patient

Dental Clinics of North America 1995; 39: 15-24.

Josell S.D, Abrams R.G.

Traumatic injuries to the dentition and its supporting structures

Pediatric Clinic of North America 1982; 29: 717-741.

Kawashima Z., Pineda L.F.

Replanting avulsed primary teeth

Journal of American Dental Association 1992;123: 90-92.

Kenwood M., Seow W.K.

Sequelae of trauma to the primary teeth dentition

Journal of Pedodontics 1989; 13: 230-238.

Kopel H.M.

Considerations for the direct pulp capping procedure in primary teeth: A review  
of the literature

Journal of Dentistry for Children 1992; 141-149.

Korf S.R.

The eruption of permanent central incisors following premature loss of their  
antecedents

Journal of Dentistry for Children 1965; 32: 39-44.

Laskin D.M.

The recognition of child abuse

Journal of Oral Surgery 1978; 36: 349.

Lind V., Wallin H., Egermark-Eriksson J., Bernhold M.

Indirekta traumaskador. Kliniska skador pa permanenta incisiver som foljd av trauma mot temporara incisiver

Sveriges Tandl-Forb Tidn 1970; 62: 738-756.

Mackie I.C., Blinkhorn A.S.

Dental Trauma: 1.General history, examination and management of trauma to the primary dentition

Dental Update: 23(2) 1996: 69-71.

Mackie I.C., Warren V.N.

Dental Trauma: 1.General aspects of management, and trauma to the primary dentition

Dental Update 1988; 15(4): 155-159.

Diab M., El Badrawy H.E.

Intrusion injuries of primary incisors. Part III: effects on the permanent successors

Quintessence International 2000; 31: 377-384.

Mathewson R.J., Primosch R.E., Morrison J.T.

Fundamentals of Pediatric Dentistry

Quintessence Publishing Company, 3<sup>rd</sup> edition 1995.

McDonald N., Strassler H.E.

Evaluation for tooth stabilization and treatment of traumatized teeth

Dental Clinics of North America 1999; 43: 135-149.

McDonald R.E., Avery D.R.

Dentistry for the child and adolescent

The C.V. Mosby Company, 3<sup>rd</sup> edition 1978: 316.

Moss S.J., Maccaro H.

Examination, evaluation and behavior management following injury to primary incisors

New York State Dental Journal 1985; 51: 87-92.

Mueller G.H., Whitsett B.D.

Management of an avulsed deciduous incisor. Report of a case.

Oral Surgery, Medicine and Oral Pathology 1978; 46: 442-426.

Oikarinen K., Kassila O.

Causes and types of traumatic tooth injuries treated in a public dental health clinic

Endodontics and Dental Traumatology 1987; 3: 172-177.

Perez R., Berkowitz R., McIlveen L., Forrester D.

Dental trauma in children: a survey

Endodontics and Dental Traumatology 1991; 7: 212-213.

Peterson D.S., Taylor M.H., Marley J.F.

Calcific metamorphosis with internal resorption

Oral Surgery , Medicine and Oral Pathology 1985; 60(2): 231-233.

Ram D., Holan G.

Partial pulpotomy in a traumatized primary incisor with pulp exposure: case report

Pediatric Dentistry 1994; 16: 46.

Ravn J.J.

Sequelae of mechanical trauma in the deciduous dentition

Journal of Dentistry for Children 1968; 35: 281-289.

Ravn J.J.

Dental injuries in Copenhagen school children, school years 1967-1972

Community Dentistry and Oral Epidemiology 1974; 2: 231-245.

Sanchez A.V., Garcia-Godoy F.

Traumatic dental injuries in 3- to 13-year old boys in Monterrey, Mexico.

Endodontics and Dental Traumatology 1990; 6: 63-65.

Sanchez S.R., Sanchez R.R., Garcia-Godoy F.

Traumatismos de los dientes anteriores en niños preescolares

Acta Odontologica Scandinavica 1981; 2: 17-23.

Schatz J.P., Joho J.P.

A retrospective study of dento-alveolar injuries

Endodontics and Dental Traumatology 1994; 10: 11-14.

Schutzmannsky G.

Unfallverletzungen an jugendlichen Zähnen

Dtsch Stomatology 1963; 13 : 919-927.

Sonis A.

Longitudinal study of discolored primary teeth and effect on succedaneous teeth

Journal of Pedodontics 1987; 11: 247-252.

Soporowski N.J., Allred M.S., Needleman H.L.

Luxation injuries of primary anterior teeth prognosis and related correlates

Pediatric Dentistry 1994; 16: 96-101.

Soxman J.A., Nazif M.M., Bouquot J.

Pulpal pathology in relation to discoloration of primary anterior teeth

Journal of Dentistry for Children 1984; 51: 282-284.

Stafne E.C.

Oral reontgenographic diagnosis

Philadelphia, W.B. Saunders Company 1969: 67-68.

Tate R.J.

Facial injuries associated with the battered child syndrome

British Journal of Oral and Maxillofacial Surgery 1971; 9: 41-45.

Tronstad L.

Root resorption- etiology, terminology and clinical manifestations

Endodontics and Dental Traumatology 1988; 4: 241-252.

Tsukiboshi M.

Treatment Planning for Traumatized teeth

Chicago, Quintessence Publishing 2000.

Von Arx T.

Traumatology in the deciduous dentition (I). The clinical and therapeutic aspects

Schweizer Monatsschrift fur Zahnmedizin 1990; 100: 1194-1208.

Weiger R., Heuchert T.

Management of an avulsed primary incisor

Endodontics and Dental Traumatology 1999; 15: 138-143.

Wilson C.F.

Management of trauma to primary and developing teeth

Dental Clinic of North America 1995; 39: 133-167.

Yagot K.H., Naqat N.Y., Kuder S.A.

Traumatic dental injuries in nursery school children from Boghdad, Iraq

Community Dentistry and Oral Epidemiology 1988; 16: 292-293.

Zadik D.

A survey of traumatized primary anterior teeth in Jerusalem preschool children

Community Dentistry and Oral Epidemiology 1976; 4: 149-151.

Zilbermann Y., Ben Bassat Y., Lustmann J.

Effect of trauma to primary incisors on root development of their permanent  
successors

Pediatric Dentistry 1986; 8: 289-293.



---

---

## **Appendix 1**

---

---

**Statistics on the frequency of injuries to the primary  
dentition of children from different countries in the world**

**Table 1 : The percentage of traumatic dental injuries in the primary dentition of children from different countries**

<b>Author</b>	<b>Country</b>	<b>Age group (yrs)</b>	<b>Sample size</b>	<b>Percentage of dental injuries</b>
Schutzmannsky 1963	Germany	2-6	338	10.9
Lind et al. 1970	Sweden	0-7	702	12.5
Andreasen & Ravn 1972	Denmark	3-7	487	30.2
Holm & Arvidsson 1974	Sweden	3	208	24.0
Holm 1975	Sweden	4	206	30.0
Zadik 1976	Israel	5	965	11.1
Garcia-Godoy et al.1983	Dominican Republic	3-5	800	35.0
Yagot et al. 1988	Iraq	1-4	2,389	24.4
Forsberg & Tedestam1990	Sweden	1-6	58	12.0
Bijella et al. 1990	Brazil	1-6	576	30.2
Borssen & Holm 1997	Sweden	1-16	3,007	20.0
Hargreaves et al. 1999	South Africa	1-5	1,466	15.0

**Table 2: Prevalence of traumatic dental injuries to the primary teeth of 5-year-old children in different countries**

Author	Year	Country	Sex	
			boy (%)	girl (%)
Andreasen & Ravn	1974	Denmark	31.3	24.6
Garcia-Godoy et al.	1983	Dominican Republic	33.6	28.9
Forsberg & Tedestam	1990	Sweden	28.0	16.0
Sanchez & Garcia-Godoy	1990	Mexico	40.0	30

**Table 3 : Distribution of injuries to the primary dentition according to gender**

<b>Author</b>	<b>Year</b>	<b>Age in years</b>	<b>Frequency of injuries boy : girl</b>
Andreasen & Ravn	1974	5	1.27:1
Zadik	1976	5	1:1*
Garcia-Godoy et al.	1987	0-8	1.5:1
Oikarinen & Kassila	1987	<7	1.9:1
Perez et al.	1991	<5	1.82:1
Schatz & Joho	1994	1.3-16.1	1:1*
Borssen & Holm	1997	1-16	1.5:1
Hargreaves et al.	1999	1-5	1:1*

\* variation between genders not statistically significant.

**Table 4 : The peak age for traumatic injuries to the primary dentition**

Author	Year	Age in years		Age in years boys and girls
		boys	girls	
Andreasen & Ravn	1972	2-4	2-3	-
Ferguson & Ripa	1979	-	-	4-5
Garcia-Godoy et al.	1979	3-4	1-4	-
Sanchez et al.	1981	-	-	4
Garcia-Godoy et al.	1983	-	-	4-5
Garcia-Godoy et al.	1987	1-2	1-2, 3-4	1-2
Forsberg & Tedestam	1990	5	3	-
Glendor et al.	1996	3-4	5-6	-
Fried et al.	1996	3-4	1-3	-
Borssen & Holm	1997	4	4	-
Hargreaves et al.	1999	-	-	4-5
Clifton & Dummett	2000	-	-	2-4

**Table 5 : The most commonly affected teeth for traumatic injuries to the primary dentition**

<b>Author</b>	<b>Year</b>	<b>Location</b>
Andreasen & Ravn	1972	central incisors
Zadik	1976	maxillary central incisors (91.6%)
Schatz & Joho	1994	maxillary incisors (59%)
Fried et al.	1996	central incisors (66.2%)
Borssen & Holm	1997	maxillary central incisors

---

---

## **Appendix 2**

---

---

### **The classification of the injuries**

## **Classification of injuries**

### **A) Injuries to the hard dental tissues and pulp**

#### **A.1 Enamel infraction**

*Description:* Incomplete fracture (crack) of enamel without loss of tooth structure

#### **A.2 Enamel fracture (uncomplicated crown fracture)**

*Description:* A fracture with loss of tooth substance confined to the enamel

#### **A.3 Enamel-Dentin fracture (uncomplicated crown fracture)**

*Description:* A fracture with loss of tooth substance confined to enamel and dentin, but not involving the pulp.

*Signs/Symptoms:* The dentinal tubules connect to the pulp, and fracture may lead to inflammation or necrosis and/or abscess formation. The tooth may be sensitive to cold or air.

#### **A.4 Enamel-Dentin fracture involving the pulp (complicated crown fracture)**

*Description:* A fracture involving enamel and dentin, and exposing the pulp.

*Signs/Symptoms:* An exposure of the pulp indicates bacterial contamination that can cause necrosis of the pulp and/or abscess. The tooth may have the appearance of bleeding or may display a small red spot.



#### **A.5 Uncomplicated crown-root fracture**

*Description:* A fracture involving enamel, dentin and cementum, but not exposing the pulp.

*Signs/Symptoms:* Though similar to crown fracture, crown-root fracture starts above the gingival margin of the tooth and continues subgingivally to a point within the tooth's alveolar socket. If the fracture fragments are not displaced, this type of injury may not be clinically detected. The extent of the fracture must be determined by removing the coronal portion of the tooth; the site should be assessed for evidence of pulp exposure.

#### **A.6 Complicated crown-root fracture**

*Description:* A fracture involving enamel, dentin and cementum, and exposing the pulp.

#### **A.7 Root fracture**

*Description:* A fracture involving dentin, cementum, and the pulp. Root fractures can be further classified according to displacement of the coronal fragment, see under luxation injuries.

*Signs/Symptoms:* Root fractures are often presented when other types of dental injuries have been sustained by the adjacent teeth. Teeth are often mobile, but the degree of mobility can be quite variable and depends on the location of the fracture on the root.

## **B) Injuries to the periodontal tissues**

### **B.1 Concussion**

*Description:* An injury to the tooth-supporting structure without abnormal loosening or displacement of the tooth, but with marked reaction to percussion. Vascular structures entering the apex of the tooth may be damaged.

*Signs/Symptoms:* Exaggerated sensitivity when percussed or when pressure is placed on the tooth during chewing, biting, or testing mobility.

### **B.2 Subluxation (loosening/mobility)**

*Description:* Injured tooth appears to be in proper position and undamaged, but mobility (abnormal loosening) is evident when assessed. Tooth may appear slightly extruded secondary to edema at apex of root (Josell 1995)

*Signs/Symptoms:* Teeth may be sensitive to pressure and percussion. These teeth often exhibit bleeding around the gingival margin.

### **B.3 Extrusive luxation (peripheral dislocation, partial avulsion)**

*Description:* Partial displacement of the tooth out of its socket

*Signs/Symptoms:* Tooth appears to be out of alignment with the adjacent teeth.

### **B.4 Lateral luxation**

*Description:* Displacement of the tooth in a direction other than axially. This is accompanied by comminution or fracture of the alveolar socket.

## **B.5 Intrusive luxation (central dislocation)**

*Description:* Displacement of the tooth into the alveolar bone. This injury is accompanied by comminution or fracture of the alveolar socket and it is the most severe form of luxation (McDonald and Strassler 1999) because the damage to the tooth and the alveolus requires the most complex treatment. The periodontal ligament sustains severe damage.

*Signs/Symptoms:* The patient presents with what appears to be a submerged tooth that is shorter than its partner on the contralateral side.

## **B.6 Avulsion (exarticulation)**

*Description:* Complete displacement of tooth from its alveolar socket. During primary dentition years, occurs in infants learning to walk. Most commonly occurs in children aged 7-10 years in mixed dentition (Josell 1995).

*Signs/Symptoms:* Tooth is traumatically lost from its bony socket. The periodontal ligament is ripped from the alveolus, and the blood vessels, lymphatics, and innervation are torn from the apex of the tooth.

## **C) Injuries to the supporting bones**

### **C.1 Comminution of the mandibular or maxillary alveolar socket**

Crushing and compressing of the alveolar socket. This condition is found concomitantly with intrusive and lateral luxations.

## **C.2 Fracture of the mandibular or maxillary alveolar socket wall**

A fracture confined to the facial or oral socket wall.

## **C.3 Fracture of the mandibular or maxillary alveolar process**

A fracture of the alveolar process, which may or may not involve the alveolar socket.

## **C.4 Fracture of mandible or maxilla**

A fracture involving the base of the mandible or maxilla and often the alveolar process. The fracture may or may not involve the alveolar socket.

## **D) Injuries to the gingiva and oral mucosa**

### **D.1 Laceration of gingiva or oral mucosa**

A shallow or deep wound in the mucosa resulting from a tear, and is usually produced by a sharp object.

### **D.2 Contusion of gingiva or oral mucosa**

A bruise usually produced by impact with a blunt object and not accompanied by a break in the mucosa, usually causing submucosal hemorrhage.

### **D.3 Abrasion of gingiva or oral mucosa**

A superficial wound produced by rubbing or scraping of the mucosa leaving a raw, bleeding surface.

---

---

## **Appendix 3**

---

---

**Statistics on the frequency of the various types of injuries to  
the primary teeth**

**Table 6 : Percentage of injuries to the primary teeth in different countries**

Country	Study	Injury															
		Infracton	Uncomplicated crown fracture	Uncomplicated crown root fracture	Uncomplicated crown root fracture	Complicated crown fracture	Complicated crown root fracture	Root fracture	Concussion	Subluxation	Intrusion	Extrusion	Lateral luxation	Exarticulation	No specific crown fracture	Discoloration	No specific luxation
Germany	Schulzmannsky 1963 2-6 yrs, N=338		29%										10%	-	61%	-	-
Denmark	Andreasen & Ravn 1972 0-7yrs, N=147	-	15%	-	1%	-	1%	4%	-	6%	7%	-	7%	3%	-	51%	4%
Israel	Zadik 1976 5yrs, N=131	62.60%	-	-	0.90%	-	-	-	-	-	6.50%	12.10%	-	-	17.70%	-	-
Dominican Republic	Garcia-Godoy 1987 0-8yrs, N=114	-	11.20%	0.80%	2.40%	0.80%	4.80%	42.40%	6.40%	10.40%	0.80%	9.60%	10.40%	-	-	-	-
Sweden	Forsberg & Tedestam 1980 1-6yrs, N=58	-	9.80%	2.90%	-	2.90%	26.90%	22.50%	22.50%	8.40%	4.20%	9.80%	12.60%	-	-	-	-
Germany	Von Arx 1991 1-7yrs, N=195	-	6%	0.50%	1.50%	1.50%	0.50%	-	18%	14%	-	40%	18%	-	-	-	-
Switzerland	Schatz & Joho 1994 1.3-16.1yrs, N=300	-	19%			12%			18.30%	23%	23%	10.30%	6.40%	-	-	-	-
Sweden	Glendor et al. 1996 0-12yrs, N=323	2%	10%	0.50%	2%	0.50%	2.00%	13%	28%	15%	6%	13%	8%	-	-	-	-
Sweden	Borssen & Holm 1997 1-16yrs, N=3007	1%	5%	-	0.50%	-	1.50%	3%	45%	7%	3%	4.50%	8%	-	-	-	21.50%
South Africa	Hargreaves et al. 1999 1-5yrs, N=1466	-	83%	-	0.70%	-	-	-	2.50%			8.20%	-	5.60%	-	-	-

\*N = The number of studied cases

---

---

## **Appendix 4**

---

---

### **Examination and Diagnosis of Dental Injuries**

## **Examination and Diagnosis**

Rational therapy depends upon a correct diagnosis, which can be achieved with the help of various examination techniques. While a dental injury can often present a complex picture, most injuries can be broken down into several smaller components. Information gained from the various examination procedures will assist the clinician in identifying the nature of the injuries and determining treatment priorities (Andreasen 1985, Hargreaves 1974). It must be remembered that an incomplete examination can lead to inaccurate diagnosis and hence less successful treatment. Therefore, it is proposed to review how an injured child should be examined so as to ensure a correct diagnosis of the injuries and that the appropriate therapy is prescribed.

Examining a child who has suffered from trauma to the teeth often involves dealing with both distraught parents and an apprehensive child. The dentist should record the essential details of the incident and carry out a thorough examination. A quiet, confident manner and sympathetic approaches by both the dentist and the dental nurse is essential to ensure that the parents feel confident that the situation is under control and this allowed the injured child to calm down.

### **A) History Taking**

When examining a child with orofacial injuries, the clinician should not assume the absence of other injuries. An evaluation of the medical history and immunization status; and a general appraisal of the child's physical condition and neurologic status



are necessary. The history of the traumatic incident should be obtained from the child and/or parent or accompanying adult, if possible (Josell 1995). If the medical history includes a cardiac or other condition that requires antibiotic prophylaxis prior to dental treatment, this therapy should commence as soon as possible.

During the history taking the general state and appearance of the child can be assessed; and is an essential first part of the examination. Visual assessment of the child can begin immediately the child enters the dental office. If the patient is inambulate, is vomiting, has an uneven stare or abnormal eye movements; or has an irregular respiratory pattern, then a systematic injury or neurological damage cannot be ruled out a warrant further investigation. Any signs of clear fluid or evidence of bleeding from the nose or ears may indicate damage to the cranial base and hence possible neurological injury. Any clear fluids cannot be assumed to be tears. Mackie and Blinkhorn (1996) mentioned a number of key points that they considered should be carefully recorded when a child presents with trauma.

- (i) When did the accident occur? The time between the accident and initial presentation can influence the treatment.
- (ii) Where did the accident occur? If the accident occurred outdoors, the child's anti-tetanus status should be ascertained as soon as possible after undertaking any emergency treatment.
- (iii) How did the accident occur? A general description of how the accident occurred will provide useful information as to the possibility of other injuries.
- (iv) Has the child any other symptoms? If he or she has lost consciousness, is vomiting, has amnesia, headache, or bleeding

and/or loss of cerebrospinal fluid from the nose or ears, immediate referral to the local hospital is indicated. A further indicator of a possible head injury is general drowsiness: this may occur several hours after an accident.

- (v) Have the lost teeth been accounted for? If there is any possibility that a tooth has been inhaled, the child must be referred for a chest radiograph.

It is important to write a clear and accurate record of events in all cases of trauma, as these may be required for legal purposes, such as insurance claims following accidents or criminal injuries.

## **B) Extra-oral Examination**

Both the patient and the parents can be distressed by the appearance of soft tissue injury and blood on the child's face. By gently cleaning the face with a piece of gauze and warm water all concerned are often reassured that the injury is not as serious as it may have initially appeared. Cleaning also facilitates more accurate assessment of the injury.

If a young child will not sit on the dental chair, the examination may be conveniently carried out by sitting opposite the parent who holds their child on their lap. The child is then slowly leaned back so that his or her head is on the dentist's lap while the child can look up at the parent, with whom eye contact is maintained. The dentist can gently hold the head while the parent reassuringly holds the child's

hands. This enables an examination to be conducted with minimal stress for both the parent and child.

The extra-oral examination should concentrate on looking for lacerations, haematomas, bleeding, sub conjunctival haemorrhage, or any signs, which may indicate other injuries. Facial bones should be palpated gently to investigate any abnormalities or step deformities, which could indicate the presence of a fracture; however, if swelling and pain make the palpation difficult, radiographs should be taken. The child should be asked to open and close the mouth, as any restriction or deviation could indicate a condylar fracture (Mackie and Blinkhorn 1996).

### **C) Intra-oral Examination**

It is necessary to evaluate intra-oral bleeding sites and swellings, and lacerations of the mucosa and gingival tissues; some of which may be difficult to examine visually because of blood or other debris (Andreasen 1994), in which case the area can be cleaned with dampened gauze, irrigation, and/or suction; however, it is prudent to avoid use an air syringe during the initial phases of the evaluation. The dentition should be checked for abnormalities in the alignment of the teeth and for displaced, fractured, cracked, or abnormally occluding teeth (Josell 1995).

The mobility of the teeth in the traumatized area, the adjacent teeth and these in the corresponding region of the opposing arch should be assessed by attempting to move the tooth (or teeth) horizontally or vertically. This may be done with a tongue blade or dental instrument; movement of teeth with finger pressure may allow the clinician

to overlook subtle degrees of mobility (Josell 1995). Primary teeth with resorption may exhibit mobility unrelated to the injury. When en bloc movement of several teeth occurs during the process of evaluating individual tooth mobility, a fracture of the alveolar process may be present (Andreasen 1981, Josell and Abrams 1991). Gentle pressure of the teeth may elicit extreme sensitivity or tenderness if the periodontal tissues are traumatized. It is kind to the child not to use percussion.

Pulp testing of teeth during the clinical evaluation process is of doubtful value due to its poor correlation with the actual histological status of the tooth and the difficulty that a young child may have in providing reliable responses (Dummett 2000).

#### **D) Radiographic Examination**

Radiographs tend to be the best source of information for diagnosing the extent of the traumatized hard tissues as well as a good means of documenting the post-treatment outcomes of traumatic injury management (Dummett 2000).

All the injured teeth should be radiographed plus the immediately adjacent teeth and the teeth in the opposing arch to the injured teeth. This examination serves two purposes (Andreasen 1994):

- (i) it reveals the stage of root formation, and
- (ii) it discloses injuries affecting the root portion of the tooth and the periodontal structures.

Maxillary and mandibular periapical radiographs are important in identifying the presence of post-traumatic dystrophic changes in afflicted teeth such as pathologic root resorption and calcific metamorphosis.

A pan oral type of film can be easy to take and is excellent for fractures of the body and ramus of the mandible, but of little value for traumatized incisors due to the obscuring effect of the vertebral column.

Diagnostic radiographs taken after trauma have traditionally been either the periapical or an occlusal view of the affected teeth and adjacent structures. A single film may be inadequate to demonstrate a root fracture due to the angulation of the film and the fracture (Davis 1988). A lateral film oriented parallel to the sagittal plane and perpendicular to the central ray is an excellent way to determine the anterior-posterior relationship of an intruded, or laterally luxated primary incisor, or fractured root relative to the underlying permanent successor (Dummett 2000). This view is obtained by having the child or parent hold an occlusal size film parallel to the sagittal plane. The film may be taped to the child's outer cheek or a tongue blade may be taped to the back of the film and used as a handle (Davis 1988). The central beam should be aligned parallel to and passing along the labial surfaces of the central incisors. The exposure time needs to be increased by 50%.

If there is any possibility that a tooth fragment, or a foreign body may be imbedded in the soft tissue, a radiograph of that soft tissue should be obtained using approximately one-quarter the exposure required for a normal dental radiograph of that area. A periapical film can be placed inside the buccal sulcus to gain an image

of a foreign body in the lip or an occlusal film can be placed in a lateral position. The faster “Ekta-speed” film is preferable to “Ultra-speed” and provides an accurate image for the identification of tooth fragments or objects within soft tissues (Davis 1988).

When a tooth, or teeth have been avulsed and not recovered after the accident, the child should be questioned about any loss of consciousness or coughing. If either of these symptoms occurred the possibility of inhalation or deglutition of the tooth must be precluded. A radiograph of the chest and stomach, usually both structures can be shown on the same film, should be taken.

All radiographs should be stored carefully as they provide a record for comparison on future occasions (Andreasen 1994), and they serve as a medico-legal record.

X15060296

