

Medialisation thyroplasty for unilateral vocal fold paralysis associated with chronic pulmonary tuberculosis

Paul KY Lam 林建業
William I Wei 韋霖

Improved hygiene and public awareness have led to a steady decline in the incidence of pulmonary tuberculosis in developed countries. Nonetheless, long-term sequelae like unilateral vocal fold paralysis should not be underestimated in a modern society. We report three patients with chronic lung fibrosis following pulmonary tuberculosis leading to unilateral vocal fold paralysis. All three patients had hoarseness and chronic aspiration on swallowing. Early diagnosis and prompt surgical intervention are essential if this potentially fatal complication is to be prevented.

Introduction

Improved hygiene and public awareness have led to a steady decline in the incidence of pulmonary tuberculosis (PTB) in developed countries.¹ Better socio-economic conditions and a more effective public health policy in Hong Kong led to a remarkable drop in the notification rate per 100 000 population, from 528.9 in 1954 to 90.5 in 2004.² Despite such a sharp decline in PTB, some long-term sequelae, such as unilateral vocal fold paralysis, remain and should not be underestimated even in a modern society. Pulmonary tuberculosis may involve the recurrent laryngeal nerve, either as a result of inflammatory lymphadenopathy or chronic lung fibrosis.³ The latter is usually irreversible, even with anti-tuberculous treatment, thus early diagnosis and surgical intervention are of the utmost importance. We present three patients, who suffered from unilateral left vocal fold paralysis caused by post-PTB chronic lung fibrosis. They all underwent medialisation thyroplasty and had satisfactory speech and swallowing outcomes.

Case reports

Case 1

A 58-year-old man with chronic obstructive pulmonary disease, bronchiectasis, and a history of treated PTB 30 years earlier, complained of hoarseness for 3 months. He described easy aspiration when swallowing, followed by difficulty coughing out the aspirated materials. There was no concomitant medical illness able to account for his symptoms. The patient was referred to the Voice Clinic at Queen Mary Hospital in February 2001 and underwent laryngoscopic examination. This showed a left vocal fold paralysis with a persistent glottic gap on phonation (Fig 1a). A transnasal upper endoscopy (including pharyngoscopy, bronchoscopy, and oesophagoscopy) detected no abnormalities and a computed tomographic (CT) scan of the thorax showed gross parenchymal destruction at both upper lobes with formation of large bullae at the apices. Cystic and fibrotic changes were also observed in the right middle, right lower, and left upper lobes. The overall findings were consistent with previous PTB infection. The diagnosis of post-PTB lung fibrosis and traction bronchiectasis was confirmed by repeating the chest X-ray on several occasions. A sputum smear and culture was negative for acid-fast bacillus and sputum cytology was negative for malignancy. We performed a medialisation thyroplasty as proposed by Isshiki et al⁴ under local anaesthesia. During the procedure, a 10-mm x 5-mm window was made 5 mm posterior to the thyroid cartilage midline. A self-fabricated silastic implant was then used to medialise the paralysed vocal fold (Fig 1b). The patient's postoperative course was uneventful and both his speech and swallowing were rectified. This patient remained well for 3 years after surgery but died from an exacerbation of bronchiectasis and decompensated type II respiratory failure.

Case 2

A 79-year-old woman with bronchiectasis was referred to our division in June 2001 with a

Key words
Tuberculosis, pulmonary; Vocal fold
paralysis

Hong Kong Med J 2007;13:327-9

Division of Otorhinolaryngology,
Head and Neck Surgery, Department
of Surgery, University of Hong Kong
Medical Centre, Queen Mary Hospital,
Pokfulam Road, Hong Kong
PKY Lam, FRCS (Edin)
WI Wei, FRCS (Eng)

Correspondence to: Dr PKY Lam
E-mail: lamkiy1@netvigator.com

內置甲狀軟骨成形術治療因慢性肺結核兼發的單側聲帶麻痺

在已發展國家，隨着環境衛生的改善以及公眾的警覺性漸高，肺結核病例不斷穩定下降，但是其長遠的後遺症如單側聲帶麻痺的問題卻不應忽視。本文報告三個病例，病人同樣患上肺結核，繼而出現慢性肺纖維化，最後導致單側聲帶麻痺。三名患者均有聲嘶和慢性誤咽。及早確診並及時施行手術，才能預防這種可能致命的併發症。

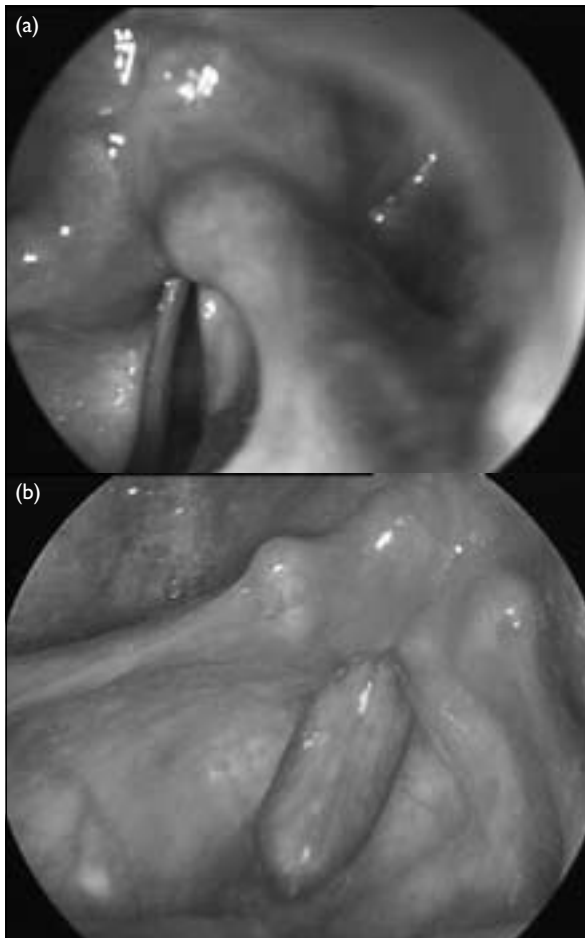


FIG 1. Laryngoscopic examination
Paralysed left vocal fold before (a) and after (b) medialisation thyroplasty

history of hoarseness for 1 year. She also complained of aspiration if drinking fast. She had been treated for PTB 51 years earlier and had no other significant medical history that might explain her symptoms. On laryngoscopic examination, the left vocal fold was paralysed and there was a persistent glottic gap and inadequate compensation of the contralateral vocal fold. A thorough head and neck examination and transnasal upper endoscopic examination were all normal except for the left vocal fold paralysis. Computed tomographic scanning of the

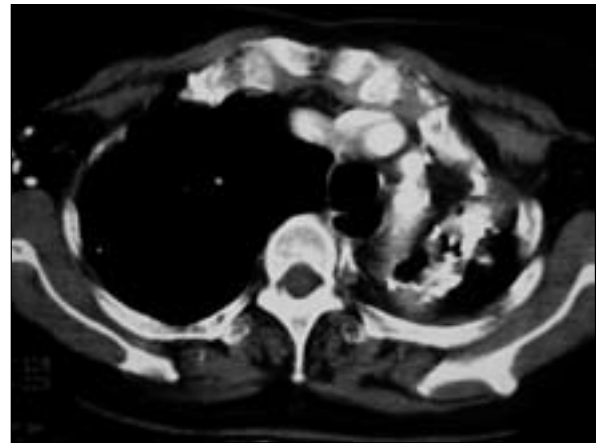


FIG 2. Post-contrast axial computed tomographic thorax
There were calcified lesions with fibrosis present in the left upper lobe, associated with a mediastinal shift to the left side. Calcified lymph nodes were also evident in the right axilla

thorax revealed a collapsed left upper lobe with a mediastinal shift to the left. There was significant loss of left lung volume and the overall features were consistent with old PTB changes (Fig 2). A sputum smear and culture for acid-fast bacillus was negative and sputum cytology was negative for malignancy. She refused to have any surgical intervention so was referred to our speech therapist for conservative treatment. Both her speech and swallowing problems persisted for the next 6 months so she eventually agreed to have surgery. A medialisation thyroplasty was performed as described in case 1; and an 8-mm x 4-mm window was made due to the smaller female larynx. The surgery was uneventful and speech and swallowing were successfully rehabilitated. She was last seen 5 years after surgery and remained well with a repeated chest X-ray showing chronic PTB changes and no other significant pathology.

Case 3

An 82-year-old man presented to our division in October 2003 with a 6-month history of hoarseness and recurrent aspiration on swallowing. He had chronic obstructive pulmonary disease, emphysema, PTB treated 5 years earlier, and no other significant medical illness. On laryngoscopic examination, the left vocal fold was found to be paralysed leaving a large glottic gap. A transnasal upper endoscopy and a head and neck examination were normal. Computed tomographic scanning from the skull base to the thorax showed extensive fibrosis and lung destruction in both upper lobes. Pleural thickening was noted in the upper part of the hemi thorax on both sides. The overall features were compatible with longstanding PTB. A sputum smear and culture for acid-fast bacilli was negative and sputum cytology was negative for malignancy. A medialisation

thyroplasty was performed as in case 1 with a 10-mm x 5-mm window made for vocal fold medialisation. The patient recovered well postoperatively, achieving satisfactory speech and swallowing. He did, however, need home oxygen 7 months after surgery for his end-stage lung disease. Chest X-rays done on several occasions confirmed post-PTB lung fibrosis. He died 9 months after surgery from decompensated type II respiratory failure.

Discussion

We have reported three cases involving patients with left vocal fold paralysis, all of whom were diagnosed with chronic PTB based on their histories, the findings on CT imaging and repeated chest X-rays, and the lack of other identifiable medical or surgical causes. Chronic PTB predominantly involving the upper lobes is a well-documented cause of vocal fold paralysis. Intrathoracic disease usually affects only the left recurrent laryngeal nerve, whilst the right one may be affected in apical pleural fibrosis or by cervical lymph nodes. In all three cases, extensive pulmonary fibrosis in the upper lobes suggested that the left recurrent laryngeal nerve could be affected by either entrapment in the scar or traction neuropathy.³

With widespread use of effective anti-tuberculous treatment, vocal fold paralysis rarely complicates primary tuberculous mediastinal lymphadenopathy. With improved hygiene and nutrition, more patients with treated tuberculous lesions live long enough to develop chronic lung fibrosis. This immobility of the vocal fold is usually irreversible and does not respond to anti-tuberculous chemotherapy.

Unilateral vocal fold paralysis with inadequate compensation by the contralateral vocal fold usually presents with hoarseness. Some patients may develop severe symptoms such as aspiration, poor coughing effort, or pneumonia. Heitmiller et al⁵ showed that in patients with unilateral vocal fold motion impairment, aspiration was seen in 38% and laryngeal penetration in 12%. Normal swallowing involves repeated vocal

fold closure, which implies a period of apnoea. In patients with compromised pulmonary capacity like post-PTB chronic lung fibrosis, these repeated instances of forced apnoea during every swallow may lead to insidious fatigue of the airway protective mechanism. Thus, as they eat a meal, patients increase their risk of aspiration.⁶ In debilitated patients with compromised pulmonary function, aspiration can be a life-threatening event.

The timing of surgical intervention for unilateral vocal fold paralysis depends on the severity of symptoms and the recovery potential. Since the majority of chronic PTB patients have irreversible vocal fold paralysis, surgical medialisation should be undertaken early for persistent aspiration. Vocal fold augmentation with Teflon has been largely superseded by the use of fat, collagen, or hyaluronic acid injections.⁷ Nonetheless, spontaneous absorption of the injected fat, collagen, or hyaluronic acid makes the outcome unpredictable. Medialisation thyroplasty is now being selected as a more reliable treatment alternative. Paralysed vocal folds are medialised by inserting a carved silastic implant or other alloplastic materials through a window in the thyroid alar cartilage to correct glottic insufficiency. If this procedure is performed under local anaesthesia with concomitant flexible laryngoscopic assessment and evaluation of the patient's voice, we can optimise the vocal fold position intra-operatively. With successful glottic closure, normal speech can be restored and aspiration pneumonitis can be prevented.

Chronic PTB lung fibrosis presenting with unilateral vocal fold paralysis still happens in developed societies. Since respiratory or family physicians see most cases of unilateral vocal fold paralysis secondary to chronic PTB, prompt referral to an otorhinolaryngologist of patients with chronic lung fibrosis presenting with breathy voices and choking is of tremendous importance. Chronic aspiration, recurrent pneumonitis, and the low rate of spontaneous recovery all support early surgical medialisation of the paralysed fold to prevent a potentially fatal outcome.

References

1. World Health Organization. Global tuberculosis control: surveillance, planning, financing. WHO Report 2003 (WHO/CDS/TB/2003.316). Geneva: WHO; 2003.
2. Annual Report 2004. Appendix 1. Hong Kong: Tuberculosis and Chest Service, Department of Health; 2004.
3. Gupta SK. The syndrome of spontaneous laryngeal palsy in pulmonary tuberculosis. *J Laryngol Otol* 1960;74:106-13.
4. Isshiki N, Morita H, Okamura H, Hiramoto M. Thyroplasty as a new phonosurgical technique. *Acta Otolaryngol* 1974;78:451-7.
5. Heitmiller RF, Tseng E, Jones B. Prevalence of aspiration and laryngeal penetration in patients with unilateral vocal fold motion impairment. *Dysphagia* 2000;15:184-7.
6. Olsson R, Nilsson H, Ekberg O. Simultaneous videoradiography and pharyngeal solid state manometry (videomanometry) in 25 nondysphagic volunteers. *Dysphagia* 1995;10:36-41.
7. Zeitels SM, Casiano RR, Gardner GM, et al. Management of common voice problems: Committee report. *Otolaryngol Head Neck Surg* 2002;126:333-48.