

# Visualising vitreous through modified trans-scleral illumination by maximising the Tyndall effect

M Veckeneer,<sup>1</sup> D Wong<sup>2,3</sup>

<sup>1</sup> Rotterdam Eye Hospital, Rotterdam, The Netherlands;

<sup>2</sup> The Eye Institute, LKS Faculty of Medicine, HBHA, The University of Hong Kong, China;

<sup>3</sup> The Royal Liverpool University Hospital, Liverpool, UK

Correspondence to:  
Dr M Veckeneer, Rotterdam Eye Hospital, Schiedamsevest 180, 3011 BH, Rotterdam, The Netherlands; [m.veckeneer@oogziekenhuis.nl](mailto:m.veckeneer@oogziekenhuis.nl)

Accepted 9 November 2008

## ABSTRACT

**Background:** A new technique for visualisation of the vitreous base is described. It uses a standard lightpipe for scleral indentation and transillumination. Visualisation of the vitreous using low light levels can be achieved by enhancing the Tyndall effect.

**Discussion:** Perfluorocarbon liquid (PFCL) is used to confine the aqueous environment to the anterior vitreous cavity and triamcinolone is added to increase light scatter. The technique clearly differentiates vitreous from PFCL and infusion fluid, and facilitates trimming of the vitreous base, draining of subretinal fluid and air/fluid exchange.

The vitreous is transparent by design and is normally best seen by light scatter or the Tyndall effect.<sup>1,2</sup> As such, the illumination ideally should come from the side. For the posterior vitreous, we are reliant on a divergent beam emerging from a fibre-optic light pipe. This increases the angle between illumination and viewing. For the anterior vitreous and the vitreous base, visualisation presents further challenges. Even with indirect viewing systems and wide-angle lenses, it is necessary to indent the sclera in order to bring the pre-equatorial retina, ora serrata and the pars plana into view. It is possible for an assistant to perform this indentation, but the control is less than ideal. An additional difficulty is obtaining optimal illumination. This could be from the co-axial illumination from the operating microscope. Because the angle between illumination and viewing is small (virtually co-axial), the vitreous is not well seen, and the view is subjected to interfering specular reflections from the tear film, cornea and lens. Alternatively, one or more 25-gauge (or smaller) light pipes could be secured at the pars plana via extra sclerotomies.<sup>3</sup> With this means, the surgeon can then perform the indentation and carry out the vitrectomy in a bimanual fashion. Despite the small gauge, vitreous incarceration into these ports is inevitable and may give rise to complications.<sup>4-6</sup> Strong chandelier fibre probes have been reported to cause thermal damage.<sup>7</sup> We describe a technique that improves visualisation of the vitreous base using transillumination.

Diaphanoscopy or transillumination is a simple and effective technique for illuminating a body cavity and determining the translucency of its walls. Diaphanoscopy was an important tool to investigate maxillary sinuses before x ray invention. Forensic diaphanoscopy is used to determine the presence or absence of subcutaneous invisible haematomas. It is also still considered helpful for breast cancer screening. Transillumination has been used in ophthalmology for fundus examination,

diagnosis and treatment of choroidal melanoma delineating tumour for plaque radiotherapy and peroperatively to help locate the posterior border of the ciliary body and to aid sulcus intraocular lens suturing.<sup>8-10</sup>

When the principle of transillumination is applied during vitrectomy, the light that is transmitted through the sclera, choroid and retinal pigment epithelium is used to visualise the vitreous.<sup>11</sup> The transmission of light from a standard 20-gauge light-pipe is, however, substantially reduced by the eye wall. It is most likely because of this limitation that the “diaphanosopic illuminator” described by Schmidt *et al*<sup>12</sup> for visualisation in pars plana vitrectomy was not widely adopted.

Our technique improves visualisation of the vitreous base by amplifying this low transilluminated light.

## METHODS

We have applied the technique on a consecutive series of cases and audited the results of our surgery for the treatment of rhegmatogenous retinal detachment. We also present the experience of a surgeon newly adopting the technique of using triamcinolone.

## Description of surgical technique

The method consists of three essential steps:

1. Filling the vitreous cavity with PFCL up to and beyond the retinal breaks.
2. Injecting triamcinolone acetonide crystals at both sclerotomy ports. As the PFCL bubble displaces the remaining vitreous upwards, the crystals are concentrated in the peripheral vitreous. In addition, the PFCL bubble prevents triamcinolone crystals gaining access to the subretinal space and stabilises the retina during vitreous cutting.
3. Scleral indentation using a conventional light pipe. As the crystals settle in the vitreous base, they greatly amplify the light transmitted through the sclera by increasing the Tyndall scattering. An extra refinement is to use a sleeve over the conventional light probe. An example of such a sleeve is that produced by DORC (Zuidland, The Netherlands) (figs 1, 2).

Applying triamcinolone crystals to visualise vitreous during surgery was first suggested by Peyman *et al*.<sup>13</sup> We have found that diluting triamcinolone acetonide (Kenalog) with balanced salt solution by one to one reduces the size of the crystals, and this promotes a more diffuse spread of the triamcinolone throughout the vitreous cortex.



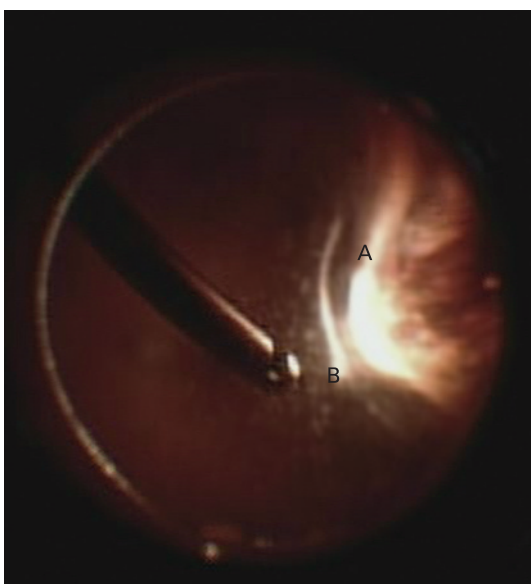
**Figure 1** DORC "Lightindenter". This device is a disposable sleeve that can be applied over a conventional 20- or 23-gauge light probe (developed by DORC in collaboration with Dr Gabor Scharioth). The smooth surface is designed to reduce the abrasion of conjunctiva and sclera. The sleeve also increases the stiffness of the light pipe to facilitate the indentation process.

Others have also found that dilution can alter steroid particle size.<sup>14 15</sup>

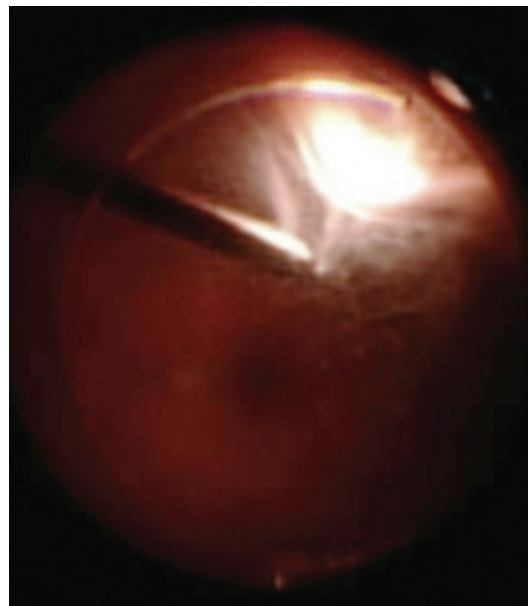## RESULTS

One of us (MV) performs over 500 vitreoretinal interventions annually (fellowship trained 1999). When vitrectomy is performed to treat a rhegmatogenous retinal detachment, the standard approach involves three-port pars plana vitrectomy (PPV) using 20-gauge instruments, heavy liquid to reattach the retina, 360° endolaser, fluid/air exchange and, depending on location, number and size of breaks, SF6 gas tamponade.

The modified transillumination technique was adopted mid 2005. Prior to this, visualisation of the peripheral fundus was routinely done by using the light from the operating microscope and performing a peripheral scleral indentation. From mid 2005 onwards, transillumination using the light pipe to indent the eye as a bimanual technique was combined with the use of triamcinolone to enhance the visualisation of the vitreous base. The fundus was visualised with the indirect wide-angle viewing system (EIBOS, Möller-Wedel, Wedel, Germany)



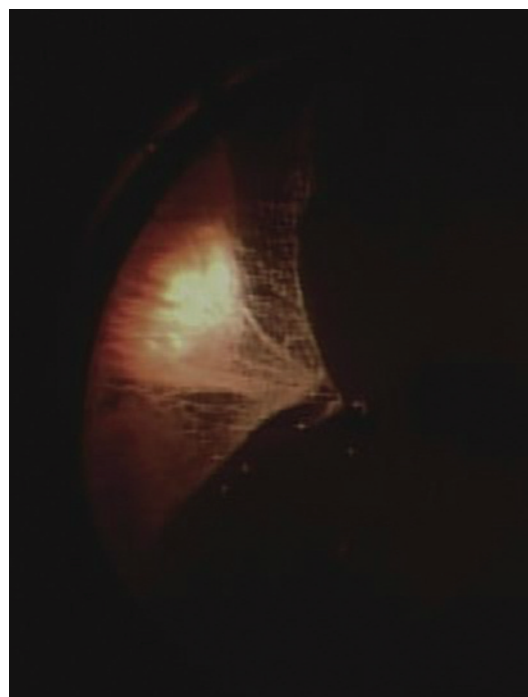
**Figure 3** Double light reflexes. This image shows the presence of two strong light reflexes, one from the transilluminated light coming through the full thickness of the eye wall (A) and the other its reflection from the interface between the vitreous and the perfluorocarbon liquid (PFCL) (B). The residual vitreous base occupies the space between the PFCL and the eye wall. The distance between the two light reflexes therefore gave some indication of the extent of vitreous base trimming.



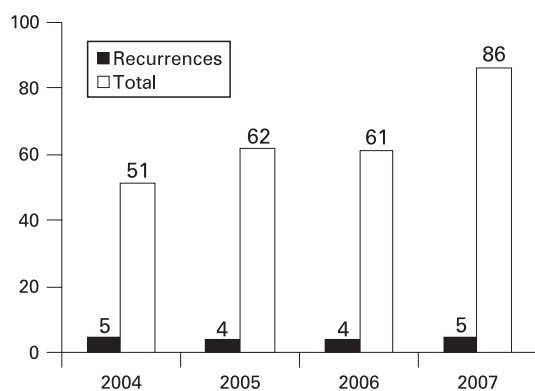
**Figure 2** Maximising the Tyndall effect. The vitreous base with enmeshed triamcinolone can be clearly visualised with the transilluminated light.

With a follow-up of at least 6 months, 5.8% failures occurred in 2007 as compared with 9.8% in 2004. These results seem to indicate that a good anatomical outcome can be achieved using the novel method for vitreous base visualisation and removal.

In our experience, indenting with the lightpipe did not cause any more discomfort than with a standard scleral depressor and can be achieved under general or local anaesthesia. The height of the required indentation to achieve good visualisation is greatly reduced with transillumination when combined with wide-angle viewing. Indentation using the direct viewing through the



**Figure 4** Uncrossed indentation. Indenting near the cutter port allows incarcerated vitreous to be removed without lens touch.



**Figure 5** Primary success rate of vitrectomy for rhegmatogenous retinal detachment.

operating microscope and its illumination generally needed to be higher, as the viewing angle was smaller. The cover sleeve “Lightindentor” (fig 1) is designed to provide a smooth and rounded surface to minimise trauma to the conjunctiva and to reduce discomfort. The sleeve also adds stiffness such that indentation can also be achieved using smaller-gauge light pipes.

The coauthor (DW) has been using transillumination with a light pipe for over 10 years. He found that the use of PFCL and triamcinolone significantly enhanced the view of the peripheral vitreous. The adoption of this new technique showed two additional advantages over simple transillumination:

1. A double light reflex (one from transmitted light and one from bubble surface) was often seen, and this increased our perception of depth. The distance between both reflexes gave an idea of the extent of vitreous trimming (fig 3).
2. The movement of the crystals also gave useful feedback. Crystals in the vitreous moved en masse because they were enmeshed in a gel-like structure. Triamcinolone on the surface of the PFCL swirled like debris riding on a current. This information enabled the surgeon to know whether he was using the vitreous cutter to remove vitreous gel or merely to aspirate PFCL or BSS. During the surgical step of air/PFCL exchange, the aim was to completely remove the subretinal fluid through a break in the retina before aspirating the heavy liquid. The presence of the triamcinolone on the surface of the PFCL bubble highlighted the interface between the heavy liquid and preretinal fluid. Aspiration of the PFCL was easily recognised by a rush of the crystals towards the cutter.

The triamcinolone also highlighted the incarcerated vitreous at the sclerotomy sites. Even in the phakic eye, using careful indentation (light indenting near the cutter port), we were able to deal with the incarcerated vitreous without lens touch (fig 4).

Between January 2004 and December 2007, a total of 260 cases of rhegmatogenous retinal detachment were treated with

vitrectomy. Results from the audit of the anatomical success rate for primary vitrectomy to treat RRD are shown in fig 5.

## DISCUSSION

The Tyndall effect allows us to visualise vitreous, which by nature is transparent. The effect is augmented by increasing the angle between illumination and observation axes up to 90°. It is also enhanced by increasing the size of the light-scattering elements within the vitreous, which in this case is achieved by the addition of triamcinolone. The transilluminated light is reflected off the convex upper surface of the PFCL bubble, which acts as a mirror. That means the vitreous is illuminated from different angles maximising the scatter of light.

Our technique involves maximising the low amount of illumination afforded by transillumination not only to identify relatively transparent vitreous tissue, but also to differentiate it from PFCL and infusion fluid. We recommend its use in all cases for which tight trimming of the vitreous base is considered important especially in retinal detachment and proliferative diabetic retinopathy.

**Acknowledgements:** The authors would like to acknowledge G Scharioth, who helped in the development of the Lightindentor.

**Competing interests:** None.

## REFERENCES

1. **Sebag J**, Balazs EA. Morphology and ultrastructure of human vitreous fibers. *Invest Ophthalmol Vis Sci* 1989;**30**:1867–71.
2. **Sebag J**. Imaging vitreous. *Eye* 2002;**16**:429–39.
3. **Oshima Y**, Awah CC, Tano Y. Self-retaining 27-gauge transconjunctival chandelier endoillumination for panoramic viewing during vitreous surgery. *Am J Ophthalmol* 2007;**143**:166–7.
4. **Koch FH**, Luloh KP, Singh P, *et al*. “Mini-gauge” pars plana vitrectomy: “inside-out view” with the GRIN solid rod endoscope. *Ophthalmologica* 2007;**221**:356–62.
5. **López-Guajardo L**, Vleming-Pinilla E, Pareja-Esteban J, *et al*. Ultrasound biomicroscopy study of direct and oblique 25-gauge vitrectomy sclerotomies. *Am J Ophthalmol* 2007;**143**:881–3.
6. **Wan T**, Hu J, Luo Y, *et al*. Experimental study of the healing condition of sclerotomy sites after 25-gauge transconjunctival sutureless sclerotomy and 20-gauge vitrectomy. *Yan Ke Xue Bao* 2007;**23**:37–42.
7. **Shimada H**, Nakashizuka H, Hattori T, *et al*. Thermal injury caused by chandelier fiber probe. *Am J Ophthalmol* 2007;**143**:167–9.
8. **Rönnerstam R**. Fundus examination using transscleral illumination. *Albrecht Von Graefes Arch Klin Exp Ophthalmol* 1977;**201**:295–6.
9. **Terasaki H**, Miyake Y, Awaya S, *et al*. Identification of anterior uveal tumor border by transscleral transillumination and an ophthalmic endoscope. *Am J Ophthalmol* 1997;**123**:138–40.
10. **Horiguchi M**, Hirose H, Koura T, *et al*. Identifying the ciliary sulcus for suturing a posterior chamber intraocular lens by transillumination. *Arch Ophthalmol* 1993;**111**:1693–5.
11. **Wong D**, Stanga P, Briggs M, *et al*. Case selection in macular relocation surgery for age related macular degeneration. *Br J Ophthalmol* 2004;**88**:186–90.
12. **Schmidt JC**, Nietgen GW, Hesse L, *et al*. External diaphanoscopy illuminator: a new device for visualization in pars plana vitrectomy. *Retina* 2000;**20**:103–6.
13. **Peyman GA**, Cheema R, Conway MD, *et al*. Triamcinolone acetonide as an aid to visualization of the vitreous and the posterior hyaloid during pars plana vitrectomy. *Retina* 2000;**20**:554–5.
14. **Benzon HT**, Chew TL, McCarthy RJ, *et al*. Comparison of the particle sizes of different steroids and the effect of dilution: a review of the relative neurotoxicities of the steroids. *Anesthesiology* 2007;**106**:331–8.
15. **Knight J**. *Science of everyday things*. Farmington Hills: Gale Group, 2002.