

# A HISTOLOGICAL GRADING SYSTEM FOR EVALUATING DISC DEGENERATION IN THE MOUSE

<sup>+1,3</sup>Yang, F; <sup>1</sup>Leung, VYL; <sup>2</sup>Danny, Chan; <sup>1</sup>Luk, KDK; <sup>1</sup>Cheung, KMC

<sup>+1</sup> Department of Orthopaedics & Traumatology; <sup>2</sup> Department of Biochemistry; University of Hong Kong, Hong Kong  
<sup>3</sup> Institute of Biomedical and health engineering, Shenzhen Institutes of advanced technology, Chinese Academy of Science  
[yangf99@yahoo.com](mailto:yangf99@yahoo.com); [cheungmc@hkucc.hku.hk](mailto:cheungmc@hkucc.hku.hk)

## INTRODUCTION

Previously we have created a simple mouse model to study the disc degeneration in mice, using the technique of annular puncture in the mouse tail. The punctured mouse disc undergoes the progressive morphological changes over a period of 12 weeks. Degenerative changes were observed in both annulus fibrosus (AF) and nucleus pulposus (NP), such as appearance of cell clusters in NP and formation of cracks in AF. The objective of the current study is to establish a histological grading system to describe these degenerative changes and evaluate the severity of the degeneration in the punctured murine discs. We hope that this histological grading system can be useful in future study to evaluate the disc degeneration in the mouse.

## METHODS

With approval by the local ethics committee, the tail (caudal 4-5 level) of thirty mice aged 10 weeks were punctured under microscopic guidance using a 31G needle. 5 mice were sacrificed at each time point: Pre-op, 1, 2, 6, and 12 weeks after surgery. The punctured disc and adjacent level control discs were removed for tissue processing and sectioning at 5 µm thickness. Safranin O staining was used to stain the histological sections. Two observers participated the histological grading of the punctured murine discs. Mann Whitney test was used for the statistical analysis of the histological scores at different time points.

## RESULTS

Grade 0 to 4 was used to reflect the different degenerative changes in AF or NP region. Definition of each histological score in AF or NP was summarized in Table 1; histological appearance corresponding to each grade in AF or NP was shown in Figure 1. The scores of AF and NP were added up to reflect the severity of the degeneration of the whole disc. Using this established histological grading system, we found that histological score of murine discs at 2 weeks after the puncture is significantly higher than the pre-op group ( $P < 0.01$ ) (Figure 2); histological score at 12 weeks after the puncture is significantly higher than the 2 weeks group ( $P < 0.05$ ), reflecting the puncture induced disc degeneration is a progressive process.

## DISCUSSION

This is the first description of a histological grading system in the injury induced murine model of disc degeneration. The punctured mouse disc degenerated progressively as evidenced by the increase of the histological score. Interestingly the significant increase of histological score from pre-op to 2 wks was associated with the “chondrocytic transformation” of NP within 2 weeks, and the progressive elevation of the histological score from 2 to 12 weeks also correlate well with the fibrocartilagenous transformation at late stage of disc degeneration at 12 weeks. While the molecular mechanism of such transformation is still not known, this grading system may be useful for evaluating the severity of injury induced disc degeneration.

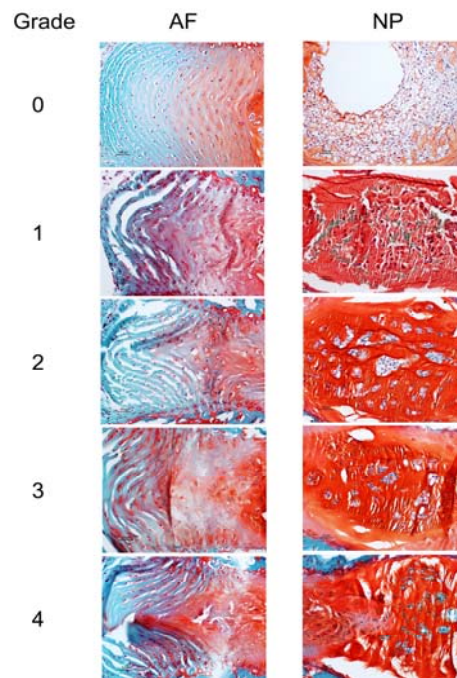


Figure 1 Safranin O staining of the intervertebral disc

Grade	AF	NP
0	Discrete and well-opposed lamellae	highly hydrated; many notochordal cells
1	Moderately serpentine with rupture	honeycomb structure; decreased hydration
2	Severely serpentine with rupture; reversed tour	many cell clusters
3	Indistinct; disorganized AF material	cell cluster decreased; minor clefts formation
4	Clefts formed; lamellae fragmentation	Occupied by connective tissue

Table 1 definition of the histological grading scale

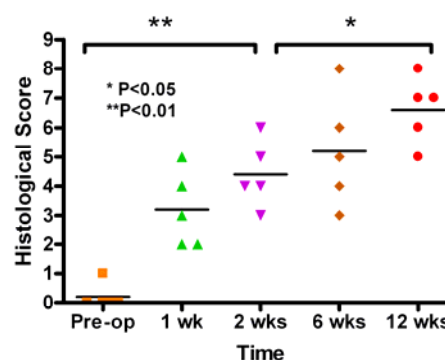


Figure 2 Change of histological score in the punctured disc

## REFERENCE

Sotashi et al. Spine 2004; 30(1); 15-24